

World Journal of *Clinical Cases*

World J Clin Cases 2024 April 6; 12(10): 1714-1856



Contents

Thrice Monthly Volume 12 Number 10 April 6, 2024

EDITORIAL

- 1714 Pitfalls in internal jugular vein cannulation
Nag DS, Swain A, Sahu S, Swain BP, Sam M

MINIREVIEWS

- 1718 Discontinuation of therapy in inflammatory bowel disease: Current views
Meštrović A, Kumric M, Bozic J

ORIGINAL ARTICLE

Retrospective Study

- 1728 Two-stage extraction by partial grinding of impacted mandibular third molar in close proximity to the inferior alveolar nerve
Luo GM, Yao ZS, Huang WX, Zou LY, Yang Y
- 1733 Clinical efficacy of femtosecond laser-assisted phacoemulsification in diabetic cataract patients
Tang YF, Duan ZH
- 1742 Impact of transcranial electrical stimulation on serum neurotrophic factors and language function in patients with speech disorders
Sun L, Xiao K, Shen XY, Wang S

Clinical and Translational Research

- 1750 Identification of marker genes associated with N6-methyladenosine and autophagy in ulcerative colitis
Liu XY, Qiao D, Zhang YL, Liu ZX, Chen YL, Que RY, Cao HY, Dai YC

CASE REPORT

- 1766 Demyelinating neuropathy in patients with hepatitis B virus: A case report
Yan XX, Huang J, Lin J
- 1772 Successful treatment of *Purpureocillium lilacinum* pulmonary infection with isavuconazole: A case report
Yang XL, Zhang JY, Ren JM
- 1778 Cellular angiofibroma arising from the rectocutaneous fistula in an adult: A case report
Chen HE, Lu YY, Su RY, Wang HH, Chen CY, Hu JM, Kang JC, Lin KH, Pu TW
- 1785 Jaffe-Campanacci syndrome resulted in amputation: A case report
Jiang J, Liu M

- 1793** Paradoxical herniation associated with hyperbaric oxygen therapy after decompressive craniectomy: A case report
Ye ZX, Fu XX, Wu YZ, Lin L, Xie LQ, Hu YL, Zhou Y, You ZG, Lin H
- 1799** Subdural effusion associated with COVID-19 encephalopathy: A case report
Xue ZY, Xiao ZL, Cheng M, Xiang T, Wu XL, Ai QL, Wu YL, Yang T
- 1804** Cemented vertebra and adjacent vertebra refractured in a chronic kidney disease-mineral and bone disorder patient: A case report
Zhang TD, Cao S, Ren HY, Li YM, Yuan YM
- 1810** Idiopathic mesenteric phlebosclerosis missed by a radiologist at initial diagnosis: A case report
Wang M, Wan YX, Liao JW, Xiong F
- 1817** Gallbladder carcinosarcoma with a poor prognosis: A case report
Dai Y, Meng M, Luo QZ, Liu YJ, Xiao F, Wang CH
- 1824** Unique method for removal of knotted lumbar epidural catheter: A case report
Deng NH, Chen XC, Quan SB
- 1830** Moyamoya syndrome may result from psoriasis: Four case reports
Chen ZY, Yu XQ, Xiang YY, Liu LH, Yin XP
- 1837** Thoracic spinal cord injury and paraplegia caused by intradural cement leakage after percutaneous kyphoplasty: A case report
Mao Z, Xiong ZH, Li JF
- 1844** Panhypopituitarism caused by a suprasellar germinoma: A case report
Roganovic J, Saric L, Segulja S, Dordevic A, Radosevic M
- 1851** Can we triumph over locally advanced cervical cancer with colossal para-aortic lymph nodes? A case report
Alzibdeh A, Mohamad I, Wahbeh L, Abuhijlih R, Abuhijla F

ABOUT COVER

Peer Reviewer of *World Journal of Clinical Cases*, Sanjeet Singh Avtaar Singh, MBChB, MSc, PhD, Department of Cardiothoracic Surgery, Royal Infirmary of Edinburgh, Edinburgh EH16 4SA, United Kingdom.
sanjeetsinghtoor@gmail.com

AIMS AND SCOPE

The primary aim of *World Journal of Clinical Cases* (WJCC, *World J Clin Cases*) is to provide scholars and readers from various fields of clinical medicine with a platform to publish high-quality clinical research articles and communicate their research findings online.

WJCC mainly publishes articles reporting research results and findings obtained in the field of clinical medicine and covering a wide range of topics, including case control studies, retrospective cohort studies, retrospective studies, clinical trials studies, observational studies, prospective studies, randomized controlled trials, randomized clinical trials, systematic reviews, meta-analysis, and case reports.

INDEXING/ABSTRACTING

The WJCC is now abstracted and indexed in Science Citation Index Expanded (SCIE, also known as SciSearch®), Journal Citation Reports/Science Edition, Current Contents®/Clinical Medicine, PubMed, PubMed Central, Reference Citation Analysis, China Science and Technology Journal Database, and Superstar Journals Database. The 2023 Edition of Journal Citation Reports® cites the 2022 impact factor (IF) for WJCC as 1.1; IF without journal self cites: 1.1; 5-year IF: 1.3; Journal Citation Indicator: 0.26; Ranking: 133 among 167 journals in medicine, general and internal; and Quartile category: Q4.

RESPONSIBLE EDITORS FOR THIS ISSUE

Production Editor: *Si Zhao*; Production Department Director: *Xu Guo*; Cover Editor: *Jin-Lei Wang*.

NAME OF JOURNAL

World Journal of Clinical Cases

ISSN

ISSN 2307-8960 (online)

LAUNCH DATE

April 16, 2013

FREQUENCY

Thrice Monthly

EDITORS-IN-CHIEF

Bao-Gan Peng, Salim Surani, Jerzy Tadeusz Chudek, George Kontogeorgos, Maurizio Serati

EDITORIAL BOARD MEMBERS

<https://www.wjgnet.com/2307-8960/editorialboard.htm>

PUBLICATION DATE

April 6, 2024

COPYRIGHT

© 2024 Baishideng Publishing Group Inc

INSTRUCTIONS TO AUTHORS

<https://www.wjgnet.com/bpg/gerinfo/204>

GUIDELINES FOR ETHICS DOCUMENTS

<https://www.wjgnet.com/bpg/GerInfo/287>

GUIDELINES FOR NON-NATIVE SPEAKERS OF ENGLISH

<https://www.wjgnet.com/bpg/gerinfo/240>

PUBLICATION ETHICS

<https://www.wjgnet.com/bpg/GerInfo/288>

PUBLICATION MISCONDUCT

<https://www.wjgnet.com/bpg/gerinfo/208>

ARTICLE PROCESSING CHARGE

<https://www.wjgnet.com/bpg/gerinfo/242>

STEPS FOR SUBMITTING MANUSCRIPTS

<https://www.wjgnet.com/bpg/GerInfo/239>

ONLINE SUBMISSION

<https://www.f6publishing.com>



Thoracic spinal cord injury and paraplegia caused by intradural cement leakage after percutaneous kyphoplasty: A case report

Zi Mao, Zhi-Hong Xiong, Jun-Feng Li

Specialty type: Orthopedics

Provenance and peer review:

Unsolicited article; Externally peer reviewed.

Peer-review model: Single blind

Peer-review report's scientific quality classification

Grade A (Excellent): A

Grade B (Very good): 0

Grade C (Good): 0

Grade D (Fair): 0

Grade E (Poor): 0

P-Reviewer: Hassel B, Norway

Received: January 2, 2024

Peer-review started: January 2, 2024

First decision: February 9, 2024

Revised: January 28, 2024

Accepted: March 18, 2024

Article in press: March 18, 2024

Published online: April 6, 2024



Zi Mao, Zhi-Hong Xiong, Department of Pain Management, The Affiliated Hospital of Yunnan University, Kunming 650000, Yunnan Province, China

Jun-Feng Li, Department of Medical Administration, The Affiliated Hospital of Yunnan University, Kunming 650000, Yunnan Province, China

Corresponding author: Zi Mao, MMed, Doctor, Department of Pain Management, Affiliated Hospital of Yunnan University, No. 176 Qingnian Road, Wuhua District, Kunming 650000, Yunnan Province, China. maozhi0314@sina.com

Abstract

BACKGROUND

Percutaneous kyphoplasty (PKP) is a pivotal intervention for osteoporotic fractures, pathological vertebral compression fractures, and vertebral bone tumors. Despite its efficacy, the procedure presents challenges, notably complications arising from intradural cement leakage. Timely and accurate diagnosis, coupled with emergent intervention is imperative to improve patient prognosis. This case report illuminates the intricacies and potential complications associated with PKP, emphasizing the critical need for vigilant monitoring, prompt diagnosis, and immediate intervention to mitigate adverse outcomes.

CASE SUMMARY

A 58-year-old male patient, experiencing a T7 osteoporosis-related pathological compression fracture, underwent PKP at a local hospital. Two weeks post-procedure, the patient developed paraplegic and dysuric symptoms, necessitating emergency decompression surgery. Gradual improvement was achieved, marked by the restoration of muscle strength, sensation, and mobility.

CONCLUSION

PKP Intradural cement leakage following PKP is unusual and potentially fatal. Prompt imaging examinations, urgent evaluation, and the decompression surgery are essential, which help alleviate symptoms associated with spinal damage, markedly improving the overall prognosis.

Key Words: Percutaneous kyphoplasty; Intradural cement leakage; Complication; Decompression surgery; Case report

©The Author(s) 2024. Published by Baishideng Publishing Group Inc. All rights reserved.

Core Tip: The report describes the first documented case of a patient experiencing spinal cord injury, paraplegia, and cerebrospinal fluid leakage after percutaneous kyphoplasty, with subsequent remission achieved through emergency decompression surgery at our hospital.

Citation: Mao Z, Xiong ZH, Li JF. Thoracic spinal cord injury and paraplegia caused by intradural cement leakage after percutaneous kyphoplasty: A case report. *World J Clin Cases* 2024; 12(10): 1837-1843

URL: <https://www.wjgnet.com/2307-8960/full/v12/i10/1837.htm>

DOI: <https://dx.doi.org/10.12998/wjcc.v12.i10.1837>

INTRODUCTION

Percutaneous vertebroplasty (PVP) and percutaneous kyphoplasty (PKP) have emerged as increasingly common techniques for treating osteoporotic and pathological vertebral compression fractures since the late 1980s, with PKP representing a refinement and advancement of PVP[1]. The mechanism of PKP encompasses the reinforcement of vertebral strength, enhancement of spinal stability, and alleviation of spinal pain. Comparative studies have demonstrated that PKP exhibits superior clinical efficacy, safety, pain reduction, and a lower incidence of complications when compared with PVP. Consequently, PKP is widely considered a more suitable treatment modality for most patients with osteoporotic and pathological vertebral compression fractures, as well as vertebral bone tumors[2]. Although rare, complications associated with cement leakage after PKP include symptomatic neurological compromise on nerve roots or the spinal cord, paraplegia, cerebrospinal fluid leakage, pulmonary embolism, and infection. A recent study analyzing 138 articles, encompassing 1027 levels treated with either PVP or PKP, reported no untoward cement-leak-related complications. The authors suggested that cement extravasation may be clinically insignificant, asserting that emergency decompression surgery for cement leaks is unnecessary[3]. Conversely, another recent literature review revealed only seven documented cases of neurological deficits caused by intradural cement leakage after PVP. These cases resulted in residual functional impairment necessitating emergency decompression surgery, highlighting the urgent nature of intradural cement leakage and the need for timely intervention[4]. Notably, there is currently no reported instance of serious complications associated with intradural cement leakage following PKP in the available literature. This report describes the first documented case of a patient experiencing spinal cord injury, paraplegia, and cerebrospinal fluid leakage after PKP, with subsequent remission following emergency decompression surgery at our hospital.

CASE PRESENTATION

Chief complaints

A 58-year-old male patient was admitted to our hospital complaining of lower back pain on September 15, 2023.

History of present illness

Two months before admission, the patient presented with lower back pain, leading to a diagnosis of herpes zoster at the local hospital outpatient clinic. Despite receiving oral medication and infusion therapy, the symptoms persisted. Subsequently, on August 27, the patient sought care at the Orthopedics Department of the local hospital and was admitted. He was diagnosed with T7 osteoporosis and a pathological compression fracture, prompting the performance of PKP on September 4 (Figure 1). Post-operation, the patient experienced relief from lower back pain; however, he developed bilateral hypochondrium pain and abdominal discomfort. Over the following week, the lower back pain and bilateral hypochondrium pain worsened, accompanied by progressive numbness and weakness in both lower extremities.

History of past illness

The patient had suffered from hypertension for 2 years and underwent PKP at a local hospital on September 4, 2023.

Personal and family history

The patient's medical history inquiry revealed the absence of any pertinent familial medical background or genetic predispositions to the observed condition.

Physical examination

During the physical examination, the patient's vital signs were assessed and found to be stable: body temperature was 36.2°C, blood pressure was 120/78 mmHg, heart rate was 73 bpm, and respiratory rate was 20 breaths/min. Examinations of the heart, lungs, and abdomen revealed no specific findings. Upon special examination, positive results were noted for percussion tenderness of the thoracic spinous process, positive findings for extensive tenderness beside the spinous process, and positive tenderness in the bilateral hypochondrium. Muscle strength in both lower limbs, tendon reflexes, and cutaneous sensation exhibited no significant abnormalities. The visual analog scale (VAS) for pain was recorded as 6.

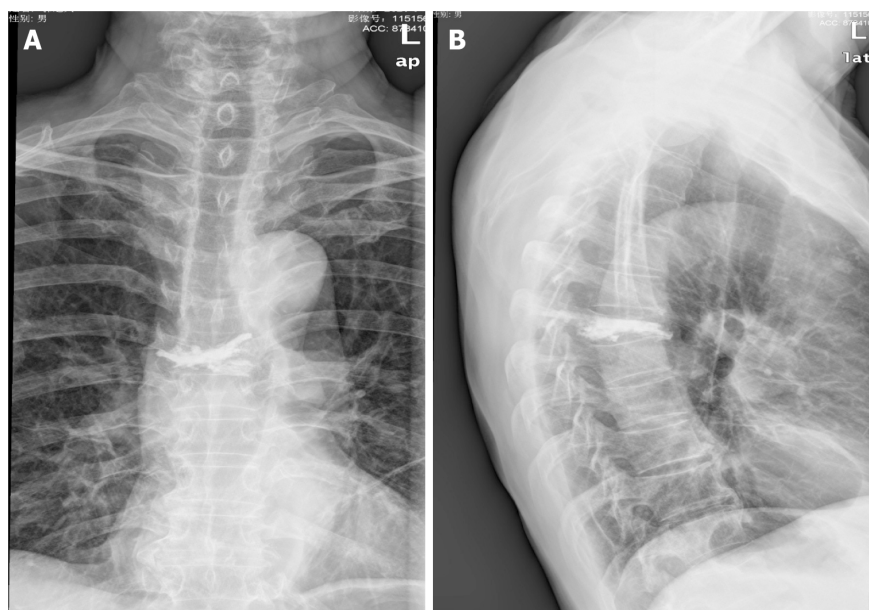


Figure 1 X-ray of the thoracic spine. A: Anteroposterior image of T7 after percutaneous kyphoplasty (PKP); B: Lateral image of T7 after PKP.

Laboratory examinations

Routine blood examination, liver function, electrolyte, infectious disease-related laboratory tests, coagulation function, rheumatoid factors, and the antistreptolysin O test all yielded normal results. Abnormal test findings are detailed in [Table 1](#).

Imaging examinations

Three days after admission, the patient presented with lower abdominal pain, dysuria, loss of sensation below the T7 level, and immobility of both lower limbs. On September 19, 2023, T2-weighted magnetic resonance imaging (MRI) was conducted. The MRI revealed a wedge-shaped T7 vertebra, indicating spinal canal stenosis and spinal cord compression resulting from the protrusion of T7 vertebra cement into the spinal canal ([Figure 2](#)). Based on these abnormal findings, it was hypothesized that the patient's paralysis symptoms were associated with the inadvertent leakage of cement into the spinal canal during the kyphoplasty procedure.

FINAL DIAGNOSIS

The patient was diagnosed with thoracic spinal cord injury and paraplegia of both lower limbs.

TREATMENT

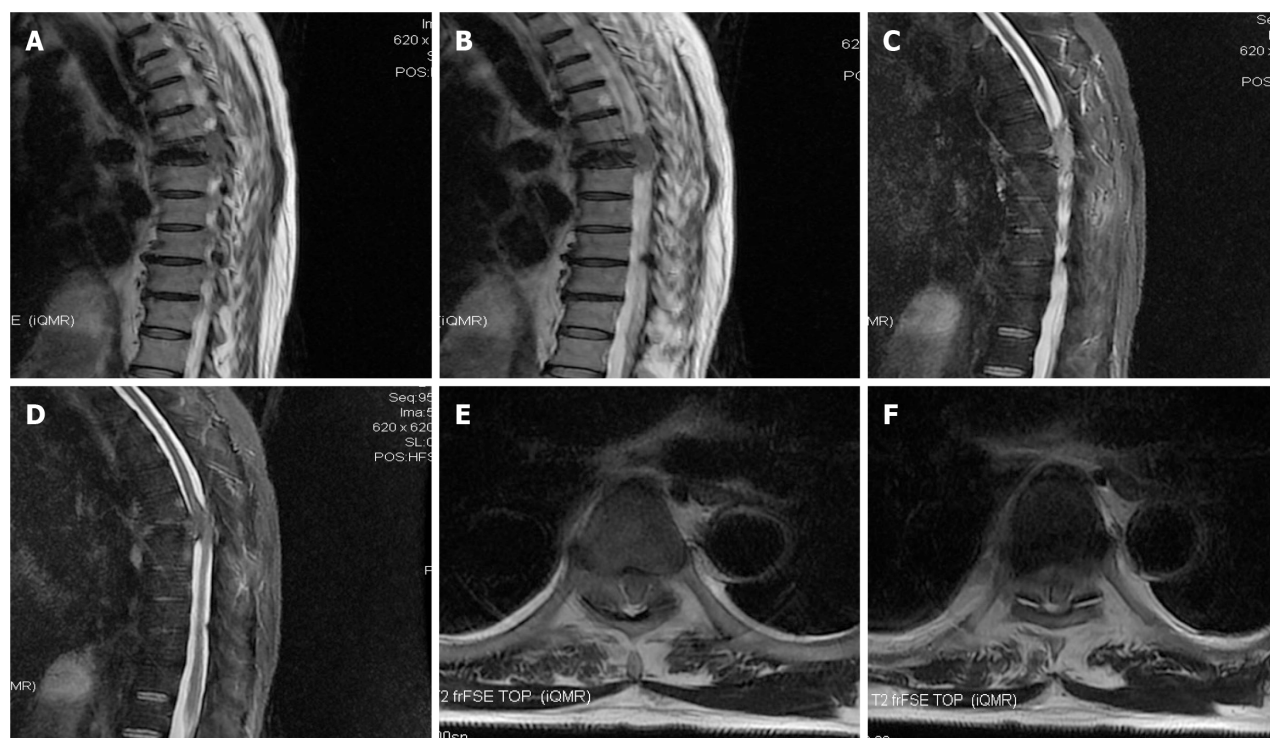
Urgent surgical interventions, including the incision and exploration of the spinal canal, posterolateral decompression, T7 subtotal vertebrectomy, and posterior instrumented spinal fusion (T5-T11), were performed on September 20, 2023 ([Figure 3](#)). During the operation, it was observed that cement had leaked into the dura within the spinal canal, compressing the spinal cord from the left side and causing contusions to both the spinal cord and nerve root. Post-surgery, the patient was promptly transferred to the intensive care unit (ICU) for vigilant postoperative monitoring. While in the ICU, the patient received standard treatment comprising routine mannitol and dexamethasone to mitigate spinal cord edema. Additionally, a preventative anti-infection regimen involving ceftriaxone was administered to reduce the risk of central nervous system infection.

OUTCOME AND FOLLOW-UP

The day after admission to the ICU, the patient was successfully weaned off the ventilator, and exhibited stability in both respiratory and circulatory systems. Subsequently, he was transferred to a regular ward. Over time, the patient experienced gradual improvement in muscle strength, sensation, and overall mobility, leading to a safe discharge one-week post-surgery. At the one-month follow-up, a diagnosis of pancreatic cancer was made at the local hospital. It was hypothesized that the T7 pathological compression fracture was associated with the presence of pancreatic cancer. Unfortunately, the patient opted to discontinue treatment, marking a regrettable conclusion to his medical care.

Table 1 Abnormal test results

Tests	Results	Normal range
Triglyceride (mmol/L)	3.94	< 1.7
Uric acid (μmol/L)	649	208-428
Creatinine (μmol/L)	229	57-97
C-reactive protein (mg/L)	14.3	≤ 5
Erythrocyte sedimentation rate (mm/h)	49	< 15
Urine protein	1+	Negative

**Figure 2** Preoperative T2-weighted magnetic resonance imaging of the thoracic spine. A-D: Sagittal view; E and F: Axial view.

DISCUSSION

Currently, PKP is the preferred and optimal treatment for osteoporotic and pathological vertebral compression fractures, representing an innovative departure from traditional PVP. PKP offers distinct advantages by addressing kyphosis deformity, streamlining procedures to reduce operation time, utilizing an expandable balloon to restore vertebral height, and reinforcing the vertebra while minimizing cement leakage[5,6]. Notably, the reported rate of cement leakage exceeds 80% in PVP but remains below 50% in PKP[3,7]. Cement leakage into the perivertebral or intervertebral disc space generally manifests without significant clinical symptoms. However, when it occurs in the spinal canal or epidural space, it may lead to neurological symptoms or infections, while entry into the paraspinal venous system can result in embolism [8]. Research by Hulme *et al*[9] highlighted that cement leakage in PVP primarily occurs in the spinal canal and epidural region, whereas in PKP, it predominantly occurs in the perivertebral and intervertebral disc space. Several established risk factors for cement leakage include vertebral cortex fragmentation, defects in posterior vertebral walls, pathological compression fractures, high resistance in vertebrae (fracture compression greater than 2/3 or old fracture), a large volume of injected cement, low cement viscosity, low bone mineral density, intravertebral cleft, and Schmorl nodes[10-12]. While cement infiltration into the dura is a rare and serious complication, it has been reported in PVP cases. Herein, we present the first documented case of spinal cord injury, paraplegia, and cerebrospinal fluid leakage due to cement leakage into the intradural space after PKP.

As shown in previously published studies in the same field, the primary cause of dural rupture in this context is attributed to iatrogenic techniques. Specifically, the complication arises from repeated punctures and inaccurate needle angles during the procedure, leading to rupture of the pedicle or vertebral wall cortex and subsequent dural penetration. This sequence of events can result in cement extravasation into the intradural space following withdrawal of the puncture needle[13-16]. In the case of PKP, the recovery effect of the vertebral anterior margin, operative time, and improvement of

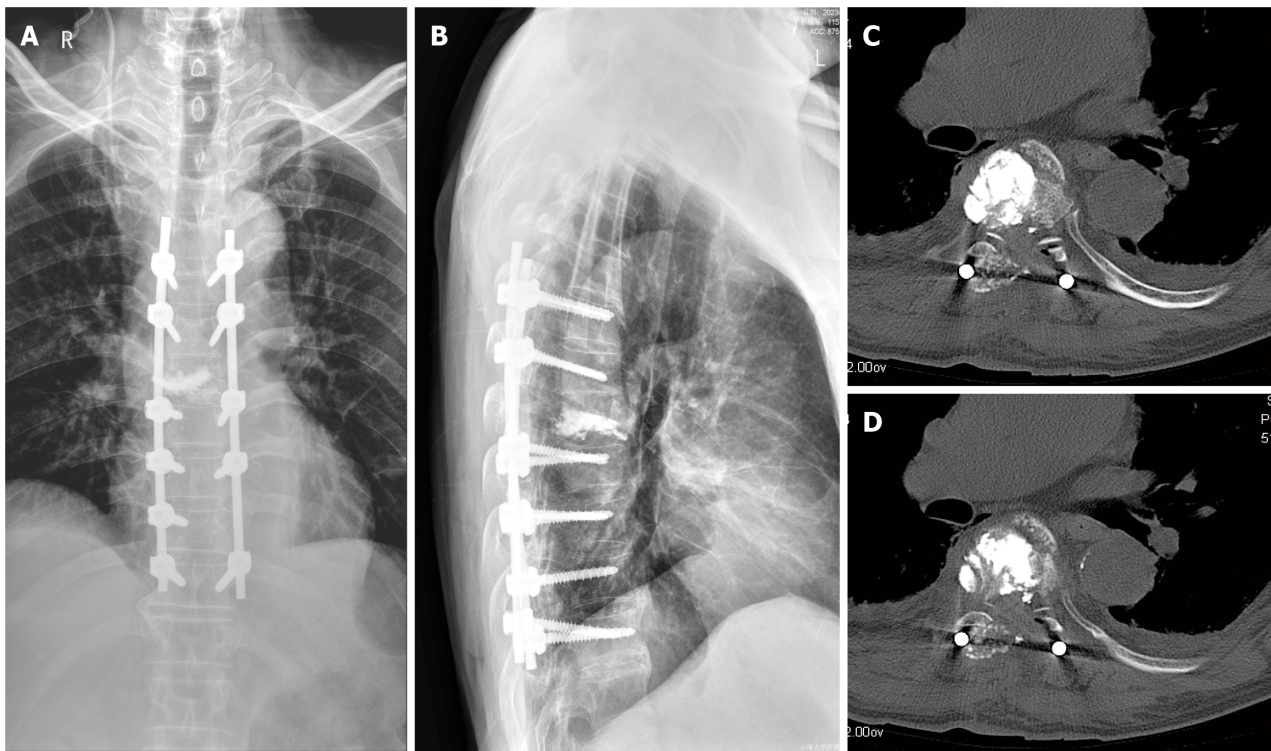


Figure 3 Postoperative image examinations: T7 subtotal vertebrectomy, and posterior instrumentation. A and B: Anteroposterior and lateral X-ray; C and D: Axial computed tomography scan.

postoperative low back pain VAS did not show a significant difference between unilateral and bilateral punctures. However, unilateral puncture demonstrated the advantage of a shorter operative time and reduced cement injection[17]. It is crucial to note that in the unilateral approach, an excessively large puncture angle may lead to damage to the medial wall of the pedicle. Therefore, during the procedure, the needle tip should not traverse the medial border of the pedicle on the anteroposterior view until it reaches the posterior cortex of the vertebral body on the lateral view[13-16].

To effectively prevent cement leakage, several key strategies based on summarized experiences have been identified. Firstly, comprehensive preoperative imaging, including computed tomography (CT) and MRI examinations, is imperative to fully understand the conditions of the injured vertebrae. Careful consideration and meticulous operation are particularly crucial for vertebral bodies with cortical damage. Intraoperatively, maintaining clear visualization of the cement is essential, as blurry images and blind punctures not only heighten the risk of cement leakage but also contribute to the inability to detect intraoperative leakage[18]. Secondly, the selection of cement with an appropriate viscosity is crucial. This, coupled with a strategy to reduce repeated punctures and avoid damaging the medial wall of the pedicle, allows for better control over the speed of cement injection[19]. Studies by Lu *et al*[20] have suggested that infusing a smaller dose (1.8-3 mL) of cement during PKP can achieve equivalent clinical effects to conventional doses (3.5-6 mL) while significantly reducing the incidence of cement leakage. Thirdly, precise control of the strength and depth of the screw tap and guide needle is essential to prevent rupture of the vertebral anterior cortex and subsequent cement extravasation. Implementation of these strategies collectively enhances the safety and efficacy of the PKP procedure[18-20].

Postoperative and meticulous CT scans play a pivotal role in accurately assessing cement leakage. For patients displaying intradural cement leakage and varying degrees of neurological deficits, prompt decompression surgery is imperative[13-16,21-24]. Literature reviews in this specific field indicate symptom improvement in the majority of patients, except one elderly patient who opted against open surgery[24]. Neurological deficits may arise from thermal injury resulting from the exothermic reaction at the posterior cortex of cement leakage in the spinal canal[25]. Early surgical intervention facilitates the removal of cement, reduces chronic inflammation and fibrosis on the cement surface, and prevents further damage to nerve tissue. In our case, the patient developed neurological symptoms, including urination disturbance and paraplegia, two weeks post-PKP. After confirming the precise location of cement leakage by MRI, immediate decompression surgery was performed. After the operation, the patient's muscle power gradually recovered. Our analysis suggests that the root cause of cement leakage in this patient may be attributed to the puncture technique employed by the surgeon.

CONCLUSION

In presenting this rare and distinctive case of intradural cement leakage following PKP, we emphasize the critical role of refining surgical techniques, conducting thorough preoperative evaluations, ensuring clear intraoperative visualization of

the cement, and carefully selecting cement with appropriate viscosity and quantity to mitigate the risk of such complications. In the event of neurological deficits post-PKP, swift action is essential. Performing a prompt CT scan or MRI exploration is imperative to precisely identify the site of cement leakage, facilitating urgent surgical decompression. Our findings underscore the significance of a comprehensive approach to enhance procedural safety and address complications swiftly for improved neurological outcomes.

FOOTNOTES

Author contributions: Xiong ZH and Li JF contributed equally to this work; Xiong ZH and Li JF performed the research and analysis; Mao Z analyzed the data and wrote the manuscript.

Informed consent statement: Informed written consent was obtained from the patient for publication of this report and any accompanying images.

Conflict-of-interest statement: All authors have nothing to disclose.

CARE Checklist (2016) statement: The authors have read the CARE Checklist (2016), and the manuscript was prepared and revised according to the CARE Checklist (2016).

Open-Access: This article is an open-access article that was selected by an in-house editor and fully peer-reviewed by external reviewers. It is distributed in accordance with the Creative Commons Attribution NonCommercial (CC BY-NC 4.0) license, which permits others to distribute, remix, adapt, build upon this work non-commercially, and license their derivative works on different terms, provided the original work is properly cited and the use is non-commercial. See: <https://creativecommons.org/licenses/by-nc/4.0/>

Country/Territory of origin: China

ORCID number: Zi Mao [0009-0002-8522-7302](https://orcid.org/0009-0002-8522-7302).

S-Editor: Liu JH

L-Editor: A

P-Editor: Zhao S

REFERENCES

- Gosev I, Nascimben L, Huang PH, Mauri L, Steigner M, Mizuguchi A, Shah AM, Aranki SF. Right ventricular perforation and pulmonary embolism with polymethylmethacrylate cement after percutaneous kyphoplasty. *Circulation* 2013; **127**: 1251-1253 [PMID: [23509033](#) DOI: [10.1161/CIRCULATIONAHA.112.144535](#)]
- Hu KZ, Chen SC, Xu L. Comparison of percutaneous balloon dilation kyphoplasty and percutaneous vertebroplasty in treatment for thoracolumbar vertebral compression fractures. *Eur Rev Med Pharmacol Sci* 2018; **22**: 96-102 [PMID: [30004560](#) DOI: [10.26355/eurrev_201807_15370](#)]
- Rose LD, Bateman G, Ahmed A. Clinical significance of cement leakage in kyphoplasty and vertebroplasty: a systematic review. *Eur Spine J* 2023 [PMID: [37999769](#) DOI: [10.1007/s00586-023-08026-3](#)]
- Ma QH, Liu GP, Sun Q, Li JG. Delayed complications of intradural cement leakage after percutaneous vertebroplasty: A case report. *World J Clin Cases* 2022; **10**: 8998-9003 [PMID: [36157648](#) DOI: [10.12998/wjcc.v10.i25.8998](#)]
- Li Y, Jing Q, Chen F, Xu Y. Comparative Analysis of Therapeutic Outcomes and Prognoses Among Osteoporosis Patients with Varied Bone Mineral Density T-Values Following Percutaneous Kyphoplasty. *Altern Ther Health Med* 2023 [PMID: [38064631](#)]
- Alarkawi D, Bliuc D, Tran T, Ahmed LA, Emaus N, Bjørnerem A, Jørgensen L, Christoffersen T, Eisman JA, Center JR. Impact of osteoporotic fracture type and subsequent fracture on mortality: the Tromsø Study. *Osteoporos Int* 2020; **31**: 119-130 [PMID: [31654084](#) DOI: [10.1007/s00198-019-05174-5](#)]
- Wang B, Zhao CP, Song LX, Zhu L. Balloon kyphoplasty versus percutaneous vertebroplasty for osteoporotic vertebral compression fracture: a meta-analysis and systematic review. *J Orthop Surg Res* 2018; **13**: 264 [PMID: [30348192](#) DOI: [10.1186/s13018-018-0952-5](#)]
- Verlaan JJ, Oner FC, Dhert WJ. Anterior spinal column augmentation with injectable bone cements. *Biomaterials* 2006; **27**: 290-301 [PMID: [16102818](#) DOI: [10.1016/j.biomaterials.2005.07.028](#)]
- Hulme PA, Krebs J, Ferguson SJ, Berlemann U. Vertebroplasty and kyphoplasty: a systematic review of 69 clinical studies. *Spine (Phila Pa 1976)* 2006; **31**: 1983-2001 [PMID: [16924218](#) DOI: [10.1097/01.brs.0000229254.89952.6b](#)]
- Chen C, Fan P, Xie X, Wang Y. Risk Factors for Cement Leakage and Adjacent Vertebral Fractures in Kyphoplasty for Osteoporotic Vertebral Fractures. *Clin Spine Surg* 2020; **33**: E251-E255 [PMID: [32011354](#) DOI: [10.1097/BSD.0000000000000928](#)]
- Gao C, Zong M, Wang WT, Xu L, Cao D, Zou YF. Analysis of risk factors causing short-term cement leakages and long-term complications after percutaneous kyphoplasty for osteoporotic vertebral compression fractures. *Acta Radiol* 2018; **59**: 577-585 [PMID: [28782368](#) DOI: [10.1177/0284185117725368](#)]
- Zhan Y, Jiang J, Liao H, Tan H, Yang K. Risk Factors for Cement Leakage After Vertebroplasty or Kyphoplasty: A Meta-Analysis of Published Evidence. *World Neurosurg* 2017; **101**: 633-642 [PMID: [28192270](#) DOI: [10.1016/j.wneu.2017.01.124](#)]
- Bhide RP, Barman A, Varghese SM, Chatterjee A, Mammen S, George J, Thomas R. A rare presentation of subacute progressive ascending myelopathy secondary to cement leakage in percutaneous vertebroplasty. *Am J Phys Med Rehabil* 2014; **93**: 431-436 [PMID: [24322431](#) DOI: [10.1097/PHM.0000000000000028](#)]

- 14 **Chen CH**, Chuang MT, Wang CK. Intradural cement leakage after vertebroplasty. *Spine J* 2015; **15**: 1493-1494 [PMID: [25801388](#) DOI: [10.1016/j.spinee.2015.03.025](#)]
- 15 **Baek IH**, Park HY, Kim KW, Jang TY, Lee JS. Paraplegia due to intradural cement leakage after vertebroplasty: a case report and literature review. *BMC Musculoskelet Disord* 2021; **22**: 741 [PMID: [34454446](#) DOI: [10.1186/s12891-021-04625-7](#)]
- 16 **Grelat M**, Le Van T, Fahed E, Beaurain J, Madkouri R. Rare Complication of Percutaneous Technique: Intradural Cement Leakage and Its Surgical Treatment. *World Neurosurg* 2018; **118**: 97 [PMID: [30026152](#) DOI: [10.1016/j.wneu.2018.07.045](#)]
- 17 **Qiao Y**, Wang X, Liu Y, Hu J, Yuan FH, Zhao ZG. Comparison of Unilateral and Bilateral Percutaneous Kyphoplasty for Osteoporotic Vertebral Compression Fractures. *J Pain Res* 2023; **16**: 1813-1823 [PMID: [37273274](#) DOI: [10.2147/JPR.S393333](#)]
- 18 **Potet J**, Weber-Donat G, Curis E, Arnaud FX, Thome A, Valbousquet L, Peroux E, Geffroy Y, Bouzad C, Kervella Y, Lahutte M, Ukkola-Pons E, Baccialone J, Teriitehau CA. Incidence of pulmonary cement embolism after real-time CT fluoroscopy-guided vertebroplasty. *J Vasc Interv Radiol* 2013; **24**: 1853-1860 [PMID: [23958047](#) DOI: [10.1016/j.jvir.2013.05.048](#)]
- 19 **Habib M**, Serhan H, Marchek C, Baroud G. Cement leakage and filling pattern study of low viscous vertebroplastic versus high viscous confidence cement. *SAS J* 2010; **4**: 26-33 [PMID: [25802646](#) DOI: [10.1016/j.esas.2010.01.001](#)]
- 20 **Lu LM**, Ni XH, Ni JP, Tan W, Zhu XY, Yin S, Wu JS, Xu FC, Zhao QM. Clinical effect of unilateral balloon infusion of low dose bone cement in PKP for osteoporotic thoracolumbar compression fractures in the elderly. *Eur Rev Med Pharmacol Sci* 2022; **26**: 3642-3647 [PMID: [35647845](#) DOI: [10.26355/eurrev_202205_28859](#)]
- 21 **Sabuncuoğlu H**, Dinçer D, Güçlü B, Erdoğan E, Hatipoğlu HG, Özdoğan S, Timurkaynak E. Intradural cement leakage: a rare complication of percutaneous vertebroplasty. *Acta Neurochir (Wien)* 2008; **150**: 811-815 [PMID: [18509588](#) DOI: [10.1007/s00701-008-1503-3](#)]
- 22 **Teng MM**, Cheng H, Ho DM, Chang CY. Intraspinous leakage of bone cement after vertebroplasty: a report of 3 cases. *AJNR Am J Neuroradiol* 2006; **27**: 224-229 [PMID: [16418389](#)]
- 23 **Shapiro S**, Abel T, Purvines S. Surgical removal of epidural and intradural polymethylmethacrylate extravasation complicating percutaneous vertebroplasty for an osteoporotic lumbar compression fracture. Case report. *J Neurosurg* 2003; **98**: 90-92 [PMID: [12546397](#) DOI: [10.3171/spi.2003.98.1.0090](#)]
- 24 **Chen YJ**, Tan TS, Chen WH, Chen CC, Lee TS. Intradural cement leakage: a devastatingly rare complication of vertebroplasty. *Spine (Phila Pa 1976)* 2006; **31**: E379-E382 [PMID: [16721284](#) DOI: [10.1097/01.brs.0000219495.57470.67](#)]
- 25 **Lai PL**, Tai CL, Chen LH, Nien NY. Cement leakage causes potential thermal injury in vertebroplasty. *BMC Musculoskelet Disord* 2011; **12**: 116 [PMID: [21615939](#) DOI: [10.1186/1471-2474-12-116](#)]



Published by **Baishideng Publishing Group Inc**
7041 Koll Center Parkway, Suite 160, Pleasanton, CA 94566, USA

Telephone: +1-925-3991568

E-mail: office@baishideng.com

Help Desk: <https://www.f6publishing.com/helpdesk>

<https://www.wjgnet.com>

