

## Endoscopic band ligation for bleeding lesions in the small bowel

Takashi Ikeya, Naoki Ishii, Yuto Shimamura, Kaoru Nakano, Mai Ego, Kenji Nakamura, Koichi Takagi, Katsuyuki Fukuda, Yoshiyuki Fujita

Takashi Ikeya, Naoki Ishii, Yuto Shimamura, Kaoru Nakano, Mai Ego, Kenji Nakamura, Koichi Takagi, Katsuyuki Fukuda, Yoshiyuki Fujita, Department of Gastroenterology, St. Luke's International Hospital, Tokyo 104-8560, Japan

**Author contributions:** Ikeya T and Ishii N conceived of and designed the study; Shimamura Y, Ego M and Nakano K analyzed the data; Ikeya T, Ishii N, Shimamura Y, Nakamura K, Takagi K and Fukuda K performed the therapeutic endoscopy; Ikeya T and Ishii N edited the manuscript; Ikeya T and Ishii N drafted the manuscript; and Fujita Y revised the manuscript.

**Correspondence to:** Takashi Ikeya, MD, Department of Gastroenterology, St. Luke's International Hospital, 9-1 Akashi-cho, Chuo-ku, Tokyo 104-8560, Japan. [takashiikeya@live.jp](mailto:takashiikeya@live.jp)

Telephone: +81-3-35415151 Fax: +81-3-35440649

Received: April 23, 2014 Revised: July 7, 2014

Accepted: September 4, 2014

Published online: October 16, 2014

### Abstract

**AIM:** To investigate the safety and efficacy of endoscopic band ligation (EBL) for bleeding lesions in the small bowel.

**METHODS:** This is a retrospective study evaluating EBL in six consecutive patients (three males, three females, 46-86 years of age) treated between May 2009 and February 2014: duodenal vascular ectasia; 1, jejunal bleeding diverticulum; 1, ileal Dieulafoy's lesion; 1 and ileal bleeding diverticula; 3. The success of the initial hemostasis was evaluated, and patients were observed for early rebleeding (within 30 d after EBL), and complications such as perforation and abscess formation. Follow-up endoscopies were performed in four patients.

**RESULTS:** Initial hemostasis was successfully achieved with EBL in all six patients. Eversion was not sufficient in four diverticular lesions. Early rebleeding occurred three days after EBL in one ileal diverticulum, and a

repeat endoscopy revealed dislodgement of the O-band and ulcer formation at the banded site. This rebleeding was managed conservatively. Late rebleeding occurred in this case (13 and 21 mo after initial EBL), and re-EBL was performed. Follow-up endoscopies revealed scar formation and the disappearance of vascular lesions at the banded site in the case with a duodenal bleeding lesion, and unresolved ileal diverticula in three cases. Surgery or transarterial embolization was not required without any complications during the median follow-up period of 45 (range, 2-83) mo.

**CONCLUSION:** EBL is a safe and effective endoscopic treatment for hemostasis of bleeding lesions in the small bowel.

© 2014 Baishideng Publishing Group Inc. All rights reserved.

**Key words:** Endoscopic band ligation; Small bowel; Diverticular hemorrhage; Jejunal bleeding; Ileal bleeding; Therapeutic endoscopy; Hemostasis

**Core tip:** There have been few reports regarding the use of endoscopic band ligation (EBL) for the treatment of bleeding lesions in the small intestine. The present study demonstrates safe and effective use of EBL to treat six patients with small bowel lesions including, duodenal vascular ectasia, ileal Dieulafoy's lesion, and jejunal and ileal bleeding diverticula. Although the bleeding was successfully managed in all patients, those with diverticular bleeding in the small bowel should be closely monitored after an initial EBL.

Ikeya T, Ishii N, Shimamura Y, Nakano K, Ego M, Nakamura K, Takagi K, Fukuda K, Fujita Y. Endoscopic band ligation for bleeding lesions in the small bowel. *World J Gastrointest Endosc* 2014; 6(10): 488-492 Available from: URL: <http://www.wjgnet.com/1948-5190/full/v6/i10/488.htm> DOI: <http://dx.doi.org/10.4253/wjge.v6.i10.488>

## INTRODUCTION

Endoscopy can be used to both diagnose and treat bleeding in the small bowel. Enteroscopic techniques such as argon plasma coagulation (APC) and endoscopic clipping have been well studied<sup>[1-5]</sup>. Endoscopic band ligation (EBL) had been used for the treatment of esophageal varices<sup>[6-10]</sup>. Recently, EBL has been applied for hemostasis of colonic diverticular hemorrhage<sup>[11-15]</sup> and non-variceal upper gastrointestinal bleeding<sup>[16-20]</sup>. There are some reports concerning the use of EBL for treating small intestinal bleeding lesions<sup>[13,21-23]</sup>, though the safety and efficacy of this use has not been established. However, a recent report indicates that EBL is unsafe and unsuitable for hemostasis in the small bowel<sup>[24,25]</sup>. Therefore, the aim of this study was to retrospectively investigate the safety and efficacy of EBL for the treatment of bleeding lesions in the small bowel.

## MATERIALS AND METHODS

### Patient population

For this study, six consecutive patients (three males and three females, between 46 and 86 years of age) that were admitted to St. Luke's International Hospital and treated with EBL for gastrointestinal bleeding between May 2009 and February 2014 were included. After receiving standard supportive medical care including fluid resuscitation and hemodynamic monitoring, endoscopy was performed for the diagnosis and treatment of the bleeding lesions in the small bowel, including a duodenal vascular ectasia (one case), jejunal bleeding diverticulum (one case), ileal Dieulafoy's lesion (one case) and ileal bleeding diverticula (three cases). A bleeding diverticulum was defined as a diverticulum with stigmata of recent hemorrhage such as active bleeding, a non-bleeding visible vessel, or an adherent clot<sup>[26,27]</sup>. Informed written consent was obtained from all patients for endoscopy and EBL.

### Endoscopic procedures

For the duodenal vascular lesion, a colonoscopy (PCF-Q260JI; Olympus Medical Systems, Tokyo, Japan) rather than a gastroscopy was performed because the lesion was located at the horizontal portion of the duodenum. To treat the jejunal bleeding diverticulum, double-balloon enteroscopy (EN-450P5/20; Fujifilm Co., Tokyo, Japan) was performed. Colonoscopies were performed for the four ileal lesions following bowel preparation with polyethylene glycol. Bleeding lesions were identified and marked with hemoclips or by injecting carbon ink near the lesions. The endoscope was then reinserted after a band-ligator device (MD-48710 EVL Devices; Sumitomo Bakelite Co Ltd., Tokyo, Japan) was attached to the tip. The lesions were suctioned into the ligator cup, and the O-band was released. A repeat endoscopy was performed in the event of rebleeding after EBL. The success of the initial hemostasis, the incidence of early rebleeding (within 30 d after EBL), and complications such as perforation

and abscess formation were evaluated retrospectively. Eversion after EBL was assessed in the diverticular lesions<sup>[12,15]</sup>. Follow-up endoscopies were performed.

## RESULTS

The characteristics of the six cases of bleeding lesions and results from the EBL are presented in Table 1. EBL was completed, and initial hemostasis was achieved in all the patients. Endoscopic views of the duodenal vascular ectasia and EBL procedure are shown in Figure 1. Eversion was not sufficient after EBL in the diverticular lesions (Figure 2A-C). Early rebleeding occurred in one case of ileal diverticulum (case 5) 3 d after EBL. A repeat endoscopy in this case revealed dislodgement of the O-band and ulcer formation at the banded site (Figure 2D). It was managed conservatively, and additional treatments such as endoscopic hemostasis or surgery were not required. A six-month follow-up endoscopy for the duodenal case revealed scar formation and the disappearance of vascular lesions at the banded site. However, EBL was unable to resolve three of the ileal diverticula as observed during follow-up endoscopies performed 3 to 29 mo after the initial EBL (cases 4, 5 and 6). Follow-up endoscopies were not performed for the jejunal diverticular (case 2) and ileal Dieulafoy's (case 3) lesions. Late rebleeding occurred in the ileal case (case 5; 13 and 21 mo after initial EBL), and re-EBL was performed. Surgery or transarterial embolization was not required, and no complications were reported in any of the cases during the median follow-up period of 45 (range, 2-83) mo.

## DISCUSSION

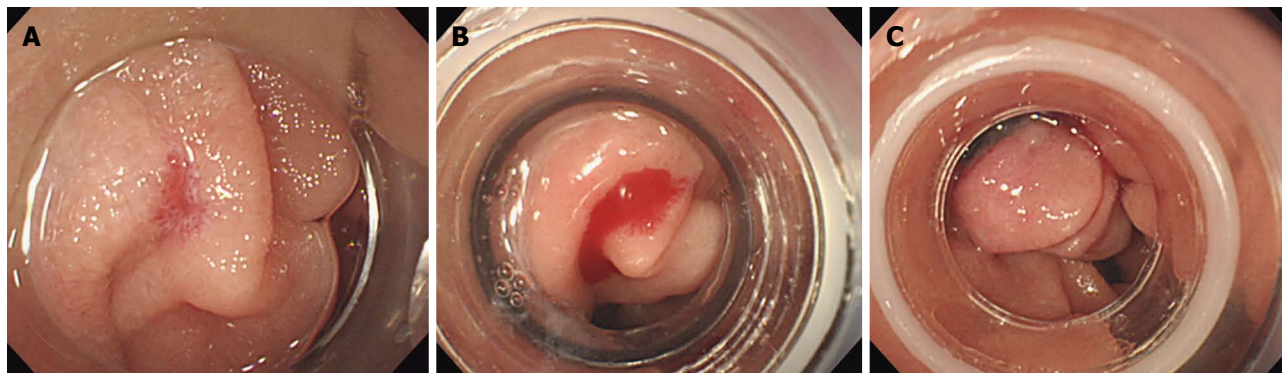
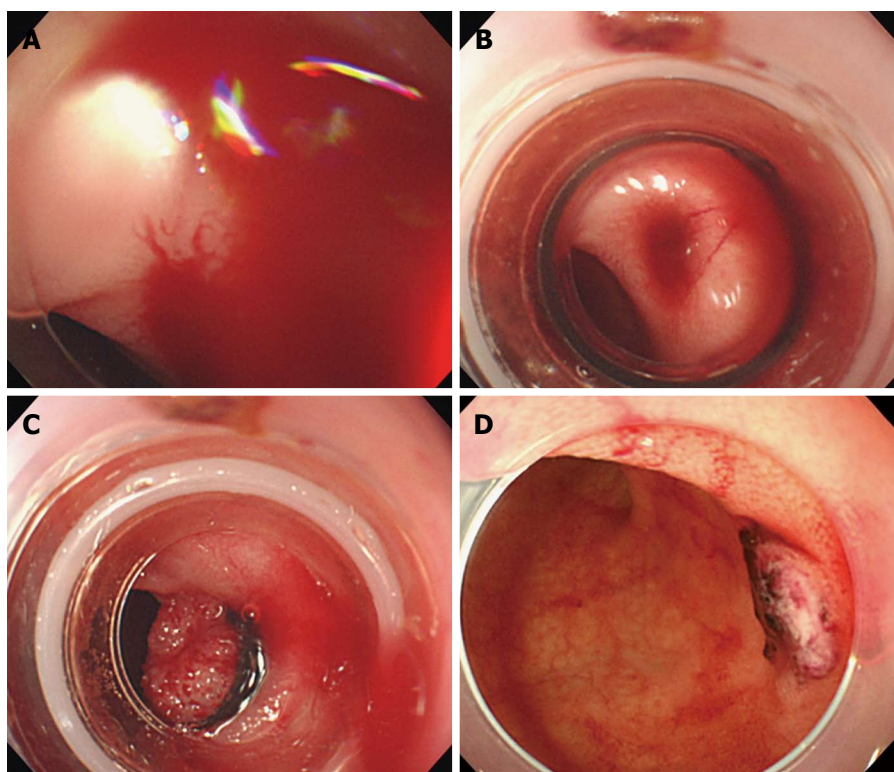
This is a retrospective case series demonstrating the use of EBL for the treatment of bleeding lesions in the small bowel. For these procedures, a band-ligator device commonly available for the treatment of esophageal varices was used, which has recently been used for colonic diverticular hemorrhage<sup>[11-15]</sup>. EBL was successful in achieving immediate hemostasis in all cases, despite the limited operability of the endoscope within the reduced diameter of the small bowel relative to other digestive tracts. In addition, hemostatic methods are also restricted by the thin walls of the small bowel, which are vulnerable to perforation during contact coagulation. However, no such complications occurred in the present study. EBL is not hindered by difficult positioning of bleeding lesions or endoscope instability because it is not necessary to place the lesions in the same direction of the endoscopic working channel.

Although eversion of colonic bleeding diverticula can be obtained with EBL<sup>[11-15]</sup>, it was not observed in the diverticular lesions of the small bowel. Insufficient eversion may be the cause for the early dislodgement of the O-band and early rebleeding that occurred in one case of an ileal diverticulum, though it was managed conservatively without the need for additional treatments. How-

**Table 1** Characteristics and results of small bowel bleeding lesions treated with endoscopic band ligation

Case	Age	Sex	Bleeding lesion	Location	EBL successful	Eversion after EBL	Procedural time (min)	Complications	Early rebleeding
1	86	F	Vascular ectasia	Duodenum	Yes	Yes	31	None	No
2	62	M	Diverticular bleeding (non-bleeding visible vessel)	Jejunum	Yes	No	168	None	No
3	61	F	Dieulafoy's lesion	Terminal ileum	Yes	Yes	38	None	No
4	46	M	Diverticular bleeding (active bleeding)	Terminal ileum	Yes	No	58	None	No
5	85	F	Diverticular bleeding (adherent clot)	Terminal ileum	Yes	No	80	None	Yes
6	71	M	Diverticular bleeding (adherent clot)	Terminal ileum	Yes	No	58	None	No

EBL: Endoscopic band ligation.

**Figure 1** Endoscopic views of the vascular ectasia. A: Bleeding at the horizontal portion of the duodenum; B: View through the band-ligator device; C: Endoscopic band ligation was performed.**Figure 2** Endoscopic views of the ileal diverticulum. A: Active bleeding; B: View through the band-ligator device; C: Endoscopic band ligation was performed. However, eversion of the banded diverticulum was not sufficient; D: Repeat endoscopic view of O-band dislodgement and ulcer formation at the banded site.



ever, late rebleeding from the same diverticula might not be prevented, as EBL did not resolve bleeding diverticula in the small bowel.

The length of the EBL procedure is an important issue, though it was not compared with alternatives in the present study. For this procedure, the endoscope must be withdrawn in order to attach the band-ligator device, and then reinserted. In the current study, procedural time was minimized by marking the identified bleeding lesions with hemoclips or carbon ink, which could be easily detected during the re-insertion of the endoscope. In addition, this study demonstrated the safety of the EBL procedure. It was reported that EBL was not safe for treatment of the small bowel, as histologic evaluation revealed inclusion of the muscularis propria and serosa by the band-ligator<sup>[24,25]</sup>. There were no complications or instances of perforation or penetration in the present study, though the study was limited to only six cases.

In conclusion, although it might be precarious to draw conclusions from small sample size and more data was needed to evaluate the use of EBL in small intestine lesions, the results of the present study indicate that EBL may be a safe and effective endoscopic treatment for bleeding lesions in the small bowel. However, patients with diverticular bleeding in the small bowel should be closely monitored after initial EBL. Further studies incorporating larger patient populations will help to validate the safety and efficacy of this procedure.

## COMMENTS

### Background

Single-balloon, double-balloon, and capsule endoscopies are commonly and widely used treatment procedures. Endoscopic band ligation (EBL) is a procedure that has been used to treat colonic diverticular hemorrhage, though it has not been thoroughly evaluated as a viable treatment option for small intestinal bleeding, despite its increasing incidence.

### Research frontiers

EBL is considered to be a useful and safe treatment for esophageal varices and colonic diverticular hemorrhaging. Although the safety and efficacy of EBL for treatment of small intestinal bleeding is not known, a recent report indicates that it can result in inclusion of the muscularis propria and serosa of the small bowel.

### Innovations and breakthroughs

This study is the first to report on the use of EBL for treatment of patients with duodenal, jejunal, and ileal bleeding. In all six cases, immediate hemostasis was achieved with no complications, such as perforation or abscess formation.

### Applications

The results of this study suggest that EBL is a safe and effective option to achieve hemostasis in the small bowel.

### Terminology

Endoscopic band ligation is an endoscopic technique involving elastic bands to treat varices. Diverticular hemorrhaging of the small intestine can involve the duodenum, jejunum or terminal ileum. Dieulafoy's lesion is a lesion with a dilated tortuous arteriole. Vascular ectasia is dilated small blood vessel.

### Peer review

The manuscript titled as "Endoscopic band ligation for bleeding lesions in the small bowel" is a large patient series which describes the method of treatment of bleeding originated from small bowel. It can be published due to its originality.

## REFERENCES

- 1 Yamamoto H, Sekine Y, Sato Y, Higashizawa T, Miyata T, Iino S, Ido K, Sugano K. Total enteroscopy with a non-surgical steerable double-balloon method. *Gastrointest Endosc* 2001; **53**: 216-220 [PMID: 11174299 DOI: 10.1067/mge.2001.112181]
- 2 Yamamoto H, Yano T, Kita H, Sunada K, Ido K, Sugano K. New system of double-balloon enteroscopy for diagnosis and treatment of small intestinal disorders. *Gastroenterology* 2003; **125**: 1556; author reply 1556-1557 [PMID: 14628813 DOI: 10.1016/j.gastro.2003.03.004]
- 3 Yamamoto H, Kita H, Sunada K, Hayashi Y, Sato H, Yano T, Iwamoto M, Sekine Y, Miyata T, Kuno A, Ajibe H, Ido K, Sugano K. Clinical outcomes of double-balloon endoscopy for the diagnosis and treatment of small-intestinal diseases. *Clin Gastroenterol Hepatol* 2004; **2**: 1010-1016 [PMID: 15551254 DOI: 10.1016/S1542-3565(04)00453-7]
- 4 Yano T, Yamamoto H, Sunada K, Miyata T, Iwamoto M, Hayashi Y, Arashiro M, Sugano K. Endoscopic classification of vascular lesions of the small intestine (with videos). *Gastrointest Endosc* 2008; **67**: 169-172 [PMID: 18155439 DOI: 10.1016/j.gie.2007.08.005]
- 5 Kawamura T, Yasuda K, Tanaka K, Uno K, Ueda M, Sanada K, Nakajima M. Clinical evaluation of a newly developed single-balloon enteroscopy. *Gastrointest Endosc* 2008; **68**: 1112-1116 [PMID: 18599052 DOI: 10.1016/j.gie.2008.03.1063]
- 6 Stiegmann GV, Goff JS, Sun JH, Wilborn S. Endoscopic elastic band ligation for active variceal hemorrhage. *Am Surg* 1989; **55**: 124-128 [PMID: 2644882]
- 7 Saeed ZA, Michaletz PA, Winchester CB, Woods KL, Dixon WB, Hieser MC, Gentry KR, Ramirez FC. Endoscopic variceal ligation in patients who have failed endoscopic sclerotherapy. *Gastrointest Endosc* 1990; **36**: 572-574 [PMID: 2279645 DOI: 10.1016/S0016-5107(90)71166-2]
- 8 Laine L, Stein C, Sharma V. Randomized comparison of ligation versus ligation plus sclerotherapy in patients with bleeding esophageal varices. *Gastroenterology* 1996; **110**: 529-533 [PMID: 8566601 DOI: 10.1053/gast.1996.v110.pm8566601]
- 9 Sackmann M, Gerbes AL. Application of a multiple-band ligator in active variceal bleeding. *Endoscopy* 1996; **28**: 533 [PMID: 8886655 DOI: 10.1055/s-2007-1005549]
- 10 Tripathi D, Lui HF, Helmy A, Dabos K, Forrest E, Stanley AJ, Jalan R, Redhead DN, Hayes PC. Randomised controlled trial of long term portographic follow up versus variceal band ligation following transjugular intrahepatic portosystemic stent shunt for preventing oesophageal variceal rebleeding. *Gut* 2004; **53**: 431-437 [PMID: 14960530 DOI: 10.1136/gut.2003.013532]
- 11 Witte JT. Band ligation for colonic bleeding: modification of multiband ligating devices for use with a colonoscope. *Gastrointest Endosc* 2000; **52**: 762-765 [PMID: 11115913 DOI: 10.1067/mge.2000.109872]
- 12 Farrell JJ, Graeme-Cook F, Kelsey PB. Treatment of bleeding colonic diverticula by endoscopic band ligation: an in-vivo and ex-vivo pilot study. *Endoscopy* 2003; **35**: 823-829 [PMID: 14551859 DOI: 10.1055/s-2003-42611]
- 13 Ishii N, Uemura M, Itoh T, Horiki N, Setoyama T, Matsuda M, Suzuki S, Iizuka Y, Fukuda K, Fujita Y. Endoscopic band ligation for the treatment of bleeding colonic and ileal diverticula. *Endoscopy* 2010; **42** Suppl 2: E82-E83 [PMID: 20195977 DOI: 10.1055/s-0029-1243828]
- 14 Ishii N, Itoh T, Uemura M, Maruyama M, Horiki N, Setoyama T, Matsuda M, Suzuki S, Iizuka Y, Fukuda K, Fujita Y. Endoscopic band ligation with a water-jet scope for the treatment of colonic diverticular hemorrhage. *Dig Endosc* 2010; **22**: 232-235 [PMID: 20642616 DOI: 10.1111/

- j.1443-1661.2010.00993.x]
- 15 **Ishii N**, Setoyama T, Deshpande GA, Omata F, Matsuda M, Suzuki S, Uemura M, Iizuka Y, Fukuda K, Suzuki K, Fujita Y. Endoscopic band ligation for colonic diverticular hemorrhage. *Gastrointest Endosc* 2012; **75**: 382-387 [PMID: 21944311 DOI: 10.1016/j.gie.2011.07.030]
- 16 **Tseng C**, Burke S, Connors P, Green R, Carr-Locke DL. Endoscopic band ligation for treatment of non-variceal upper gastrointestinal bleeding. *Endoscopy* 1991; **23**: 297-298 [PMID: 1743136 DOI: 10.1055/s-2007-1010693]
- 17 **Campo R**, Brullet E. Endoscopic treatment of gastric angiodysplasia with elastic band ligation. *Gastrointest Endosc* 1996; **43**: 502-504 [PMID: 8726767 DOI: 10.1016/S0016-5107(96)70295-X]
- 18 **Gerson LB**, Yap E, Slosberg E, Soetikno RM. Endoscopic band ligation for actively bleeding Dieulafoy's lesions. *Gastrointest Endosc* 1999; **50**: 454-455 [PMID: 10462679]
- 19 **Nikolaidis N**, Zazos P, Gioulema O, Budas K, Marakis G, Paroutoglou G, Eugenidis N. Endoscopic band ligation of Dieulafoy-like lesions in the upper gastrointestinal tract. *Endoscopy* 2001; **33**: 754-760 [PMID: 11558028 DOI: 10.1055/s-2001-16522]
- 20 **Matsui S**, Kamisako T, Kudo M, Inoue R. Endoscopic band ligation for control of nonvariceal upper GI hemorrhage: comparison with bipolar electrocoagulation. *Gastrointest Endosc* 2002; **55**: 214-218 [PMID: 11818925 DOI: 10.1067/mge.2002.121337]
- 21 **Murray KF**, Jennings RW, Fox VL. Endoscopic band ligation of a Dieulafoy lesion in the small intestine of a child. *Gastrointest Endosc* 1996; **44**: 336-339 [PMID: 8885358 DOI: 10.1016/S0016-5107(96)70176-1]
- 22 **Junquera F**, Brullet E, Campo R, Calvet X, Puig-Diví V, Vergara M. Usefulness of endoscopic band ligation for bleeding small bowel vascular lesions. *Gastrointest Endosc* 2003; **58**: 274-279 [PMID: 12872104 DOI: 10.1067/mge.2003.357]
- 23 **Suzuki S**, Ishii N, Matsuda M, Setoyama T, Uemura M, Iizuka Y, Fukuda K, Fujita Y. Endoscopic band ligation with double-balloon enteroscopy for treatment of jejunal diverticular bleeding. *Dig Endosc* 2011; **23**: 267 [PMID: 21699572 DOI: 10.1111/j.1443-1661.2010.01086.x]
- 24 **Barker KB**, Arnold HL, Fillman EP, Palekar NA, Gering SA, Parker AL. Safety of band ligator use in the small bowel and the colon. *Gastrointest Endosc* 2005; **62**: 224-227 [PMID: 16046983 DOI: 10.1016/S0016-5107(05)00557-2]
- 25 **Kakutani H**, Sasaki S, Ueda K, Takakura K, Sumiyama K, Imazu H, Hino S, Kawamura M, Tajiri H. Is it safe to perform endoscopic band ligation for the duodenum? A pilot study in ex vivo porcine models. *Minim Invasive Ther Allied Technol* 2013; **22**: 80-83 [PMID: 22793777 DOI: 10.3109/13645706.2012.703955]
- 26 **Jensen DM**, Machicado GA, Jutabha R, Kovacs TO. Urgent colonoscopy for the diagnosis and treatment of severe diverticular hemorrhage. *N Engl J Med* 2000; **342**: 78-82 [PMID: 10631275 DOI: 10.1056/NEJM200001133420202]
- 27 **Jensen DM**. The ins and outs of diverticular bleeding. *Gastrointest Endosc* 2012; **75**: 388-391 [PMID: 22248606 DOI: 10.1016/j.gie.2011.09.004]

**P- Reviewer:** Gurkan A, Radojcic BS, Sofi A   **S- Editor:** Song XX  
**L- Editor:** A   **E- Editor:** Zhang DN





Published by **Baishideng Publishing Group Inc**

8226 Regency Drive, Pleasanton, CA 94588, USA

Telephone: +1-925-223-8242

Fax: +1-925-223-8243

E-mail: [bpgoffice@wjgnet.com](mailto:bpgoffice@wjgnet.com)

Help Desk: <http://www.wjgnet.com/esps/helpdesk.aspx>

<http://www.wjgnet.com>

