

## Endoscopic ultrasound-guided drainage of postoperative intra-abdominal abscesses

Koichiro Mandai, Koji Uno, Kenjiro Yasuda

Koichiro Mandai, Koji Uno, Kenjiro Yasuda, Department of Gastroenterology, Kyoto Second Red Cross Hospital, Kamigyo-ku, Kyoto 602-8026, Japan

**Author contributions:** Mandai K collected the data and wrote the paper; Uno K and Yasuda K revised the paper.

**Ethics approval:** The study was reviewed and approved by the Kyoto Second Red Cross Hospital Institutional Review Board.

**Informed consent:** All study participants provided informed consent prior to study enrollment.

**Conflict-of-interest:** There are no conflicts of interest to declare.

**Open-Access:** This article is an open-access article which was selected by an in-house editor and fully peer-reviewed by external reviewers. It is distributed in accordance with the Creative Commons Attribution Non Commercial (CC BY-NC 4.0) license, which permits others to distribute, remix, adapt, build upon this work non-commercially, and license their derivative works on different terms, provided the original work is properly cited and the use is non-commercial. See: <http://creativecommons.org/licenses/by-nc/4.0/>

**Correspondence to:** Koichiro Mandai, MD, Department of Gastroenterology, Kyoto Second Red Cross Hospital, 355-5 Haruobi-cho, Kamigyo-ku, Kyoto 602-8026, Japan. [mandai@gmail.com](mailto:mandai@gmail.com)

**Telephone:** +81-75-2315171

**Fax:** +81-75-2563451

**Received:** October 4, 2014

**Peer-review started:** October 6, 2014

**First decision:** October 29, 2014

**Revised:** November 12, 2014

**Accepted:** January 8, 2015

**Article in press:** January 8, 2015

**Published online:** March 21, 2015

### Abstract

Although endoscopic ultrasound (EUS)-guided drainage has become the standard procedure for pancreatic pseudocysts in recent years and is generally regarded as a safe and effective method, there have been few reports of EUS-guided drainage of postoperative intra-abdominal abscesses. Here we report our experience with 4 cases of postoperative intra-

abdominal abscesses for which EUS-guided drainage was performed between May 2011 and May 2014. Distal pancreatectomy had been performed in 3 cases, whereas low anterior resection for rectal cancer was performed in the remaining case. All patients underwent transgastric naso-cystic drainage, which resulted in clinical improvement without complications, even when performed within 4 wk after surgery. On average, the naso-cystic drain was removed 10 d after placement, with no abscess recurrence. Based on these findings, we believe that EUS-guided drainage of postoperative intra-abdominal abscesses is a safe and effective method, although further large-scale investigations are required to confirm our findings.

**Key words:** Postoperative intra-abdominal abscess; Endoscopic ultrasonography; Endoscopic ultrasound-guided drainage; Transgastric drainage; Naso-cystic drainage

© The Author(s) 2015. Published by Baishideng Publishing Group Inc. All rights reserved.

**Core tip:** There have been few reports of endoscopic ultrasound (EUS)-guided drainage of postoperative intra-abdominal abscesses, although EUS-guided drainage has become the standard procedure for pancreatic pseudocysts in recent years. Here we report our experience with 4 cases. Transgastric naso-cystic drainage was performed for all patients and resulted in clinical improvement without complications, even when performed within 4 wk after surgery. On average, the naso-cystic drain was removed 10 d after placement, with no abscess recurrence. We believe that EUS-guided drainage of postoperative intra-abdominal abscesses is a safe and effective method, although further large-scale investigations are required to confirm our findings.

Mandai K, Uno K, Yasuda K. Endoscopic ultrasound-guided

drainage of postoperative intra-abdominal abscesses. *World J Gastroenterol* 2015; 21(11): 3402-3408 Available from: URL: <http://www.wjgnet.com/1007-9327/full/v21/i11/3402.htm> DOI: <http://dx.doi.org/10.3748/wjg.v21.i11.3402>

## INTRODUCTION

Traditionally, postoperative intra-abdominal abscesses have been managed by percutaneous or surgical drainage. Image-guided percutaneous drainage is reported to be a minimally invasive and effective method<sup>[1]</sup>.

Although endoscopic ultrasound (EUS)-guided drainage for pancreatic pseudocysts is regarded as a safe and effective standard method<sup>[2-7]</sup>, there have been few reports of EUS-guided drainage of postoperative intra-abdominal abscesses<sup>[8,9]</sup>.

Herein, we examined 4 cases of EUS-guided drainage of postoperative intra-abdominal abscesses performed at our institution to evaluate the safety and efficacy of this procedure.

## CASE REPORT

Between May 2011 and May 2014, we experienced 4 cases of postoperative intra-abdominal abscesses for which EUS-guided drainage was performed. The indication of EUS-guided drainage was limited to cases in which adhesion of the abscess and digestive wall was highly suspected on computed tomography (CT).

All procedures were performed using a convex-type echoendoscope (GE-UC2000P or GF-UCT260; Olympus Medical Systems, Tokyo, Japan). A 19-gauge needle (EchoTip; Cook Medical, Winston-Salem, NC, United States or Expect; Boston Scientific Japan, Tokyo, Japan, or SonoTip; Medi-Globe, Rosenheim, Germany) was used to puncture the abscess. The fluid content was aspirated, and a sample of the aspirate was sent for Gram staining and culture. Subsequently, a small dose of contrast agent was injected, and a 0.025-inch guidewire (VisiGlide; Olympus Medical Systems) was introduced through the needle and coiled into the abscess under fluoroscopic guidance. In cases of only naso-cystic drainage, the fistula was dilated using a 7-Fr dilation catheter (Soehendra Biliary Dilation Catheter; Cook Medical), and a 6-Fr pigtail nasal biliary catheter (nasal biliary drainage set; Cook Medical) was subsequently placed. In cases of both naso-cystic and internal drainage, the fistula was dilated using a 7-Fr dilation catheter (Soehendra Biliary Dilation Catheter; Cook Medical) and a balloon catheter (Maxforce TTS biliary balloon dilator, 6 mm; Boston Scientific Japan). Next, two 0.025-inch guidewires (VisiGlide; Olympus Medical Systems) were placed in the abscess using a double lumen catheter (Uneven Double Lumen Catheter; PIOLAX, Kanagawa,

Japan), and a 6-Fr pigtail nasal biliary catheter (nasal biliary drainage set; Cook Medical) and 7-Fr double pigtail biliary stent (Zimmon Biliary Stent; Cook Medical) were subsequently placed. The naso-cystic drainage catheter was irrigated once daily with 10-20 mL of sterile saline in all patients. Characteristics of the 4 cases are summarized in Table 1.

### Case 1

A 60-year-old woman underwent laparoscopic low anterior resection for rectal cancer. She developed a high fever after surgery, and CT revealed fluid collection around the anastomotic intestine and in the subdiaphragmatic area. We diagnosed this fluid collection as an abscess, and surgical drainage was consequently performed on postoperative day 17. Although the drain was removed and the patient was discharged on postoperative day 44, she was readmitted for high fever on postoperative day 64. CT revealed an encapsulated fluid collection (maximum axis, 61 mm) in the left subdiaphragmatic area close to the fornix of the stomach (Figure 1A). We again diagnosed this fluid collection as an abscess; and, as antibiotic administration did not improve the patient's condition, EUS-guided transgastric drainage was performed, and a 6-Fr pigtail nasal biliary catheter was placed on postoperative day 69 (Figure 1B, C). Gram staining and culture of a sample of the aspirate confirmed extended-spectrum beta lactamase (ESBL)-producing *Escherichia coli*, *Enterococcus*, and anaerobic bacteria. Antibiotics were administered until postoperative day 74, and CT on postoperative day 75 showed that the abscess had decreased in size (Figure 1D). The nasal biliary catheter was removed on postoperative day 80. The patient was discharged on postoperative day 99. At the latest follow-up (3 years after discharge), no abscess recurrence was noted.

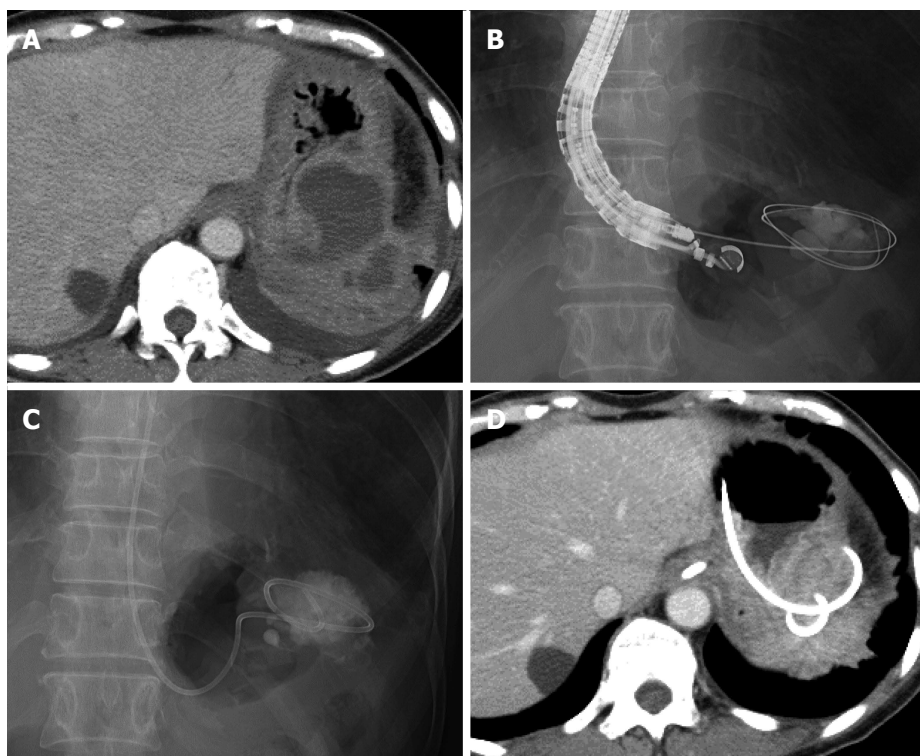
### Case 2

A 46-year-old woman underwent distal pancreatectomy for a mucinous cystic neoplasm of the pancreas. She developed high fever on postoperative day 24, and CT revealed irregular fluid collection (maximum axis, 54 mm) around the resection stump of the pancreas close to the gastric wall (Figure 2A). The fluid collection was diagnosed as an abscess; and, accordingly, EUS-guided transgastric drainage was performed and a 6-Fr pigtail nasal biliary catheter was placed on postoperative day 26 (Figure 2B-D). Gram staining and culture of a sample of the aspirate confirmed methicillin-resistant *Staphylococcus aureus* (MRSA). CT on postoperative day 37 showed that the abscess had decreased in size (Figure 2E), and the nasal biliary catheter was removed on the same day. Antibiotics were administered until postoperative day 38. The patient was discharged on postoperative day 40. At the latest follow-up (2 years after discharge), no abscess

**Table 1 Patient characteristics**

Case	Age (yr)/sex	Primary disease	Surgical procedure	Abscess size (mm)	Primary treatment for abscess	EUS-D route	Time to EUS-D (d)	EUS-D modality	Drainage length (d)	Complications/abscess recurrence
1	60/F	Rectal cancer	Low anterior rectal resection	61 × 55	Surgical drainage	TG	69 p.o.	6-Fr NB	11	None
2	46/F	MCN	Distal pancreatectomy	54 × 33	None	TG	26 p.o.	6-Fr NB	11	None
3	74/M	PDAC	Distal pancreatectomy	62 × 35	None	TG	10 p.o.	7-Fr stent	20	None
4	69/M	IPMN	Distal pancreatectomy	66 × 42	None	TG	21 p.o.	6-Fr NB	8	None
				70 × 45	Percutaneous drainage	TG	18 p.o.	7-Fr stent, 6-Fr NB	7-Fr stent: no removal 6-Fr NB: 10 per-cutaneous: 24	None

EUS-D: Endoscopic ultrasound-guided drainage; TG: Transgastric; p.o.: Postoperative day; MCN: Mucinous cystic neoplasm; NB: Nasal biliary catheter; PDAC: Pancreatic ductal adenocarcinoma; IPMN: Intraductal papillary mucinous neoplasm.



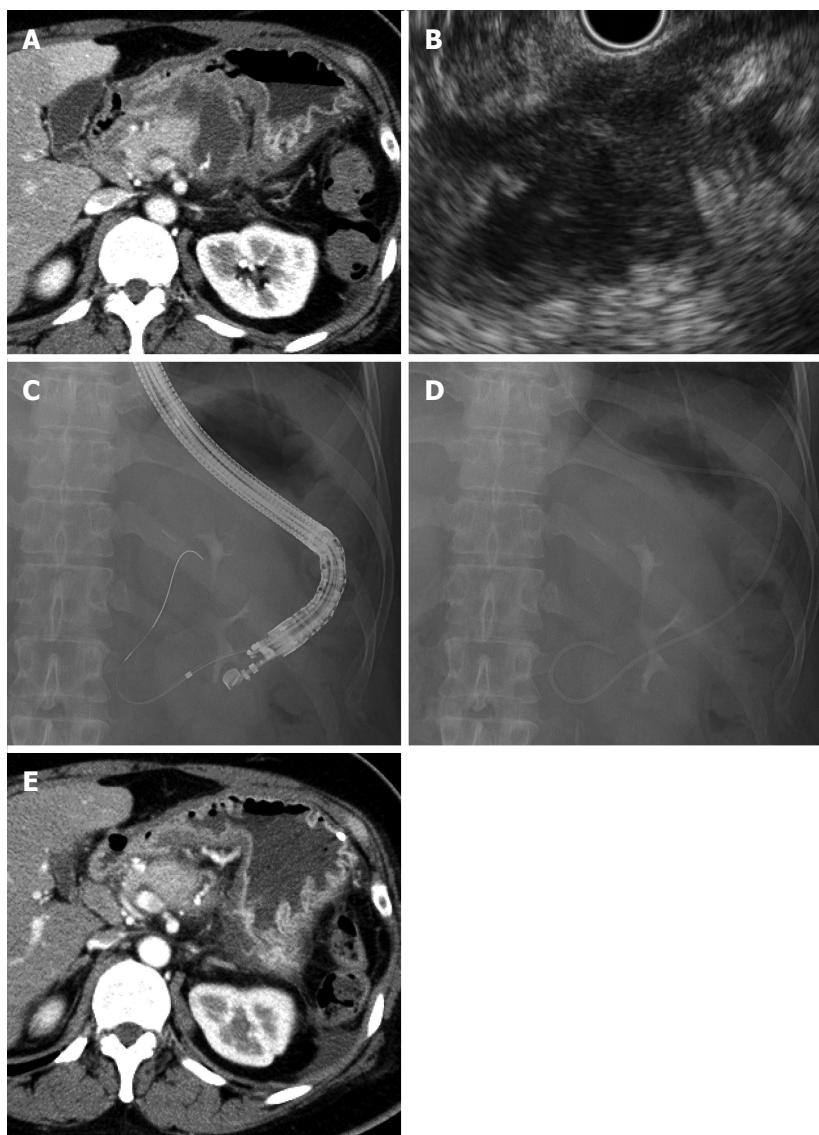
**Figure 1 Case 1.** A: Computed tomography (CT) reveals an encapsulated fluid collection in the left subdiaphragmatic area close to the fornix of the stomach; B and C: Fluoroscopy image showing the guidewire inserted into the fluid collection under endoscopic ultrasound (EUS)-guidance and placement of a 6-Fr nasal biliary catheter; D: Six days after EUS-guided drainage, CT reveals that the drain was placed and that the fluid collection decreased.

recurrence was observed.

### Case 3

A 74-year-old man underwent distal pancreatectomy for pancreatic ductal adenocarcinoma. He developed high fever on postoperative day 9, and CT revealed fluid collection (maximum axis, 62 mm) around the resection stump of the pancreas close to the gastric wall (Figure 3A). We diagnosed this fluid collection as an abscess, and EUS-guided transgastric drainage was performed and a 7-Fr double pigtail stent was placed on postoperative day 10 (Figure 3B). Gram

staining and culture of a sample of the aspirate confirmed methicillin-susceptible *Staphylococcus aureus* (MSSA), and antibiotics were administered until postoperative day 15. However, the patient developed high fever after drainage, and CT on postoperative day 17 revealed another fluid collection (maximum axis, 66 mm) at the left side of the previously drained abscess (Figure 3C). EUS-guided transgastric drainage was performed again, and a 6-Fr pigtail nasal biliary catheter was placed on postoperative day 21 (Figure 3D, E). Gram staining and culture of a sample of the aspirate again



**Figure 2 Case 2.** A: Computed tomography (CT) reveals irregular fluid collection around the resection stump of the pancreas at the dorsal side of the stomach; B: Endoscopic ultrasound (EUS) reveals an irregular and cloudy fluid collection close to the gastric wall; C and D: Fluoroscopy image showing the dilation catheter inserted over the guidewire and placement of a 6-Fr nasal biliary catheter; E: Eleven days after EUS-guided drainage, CT reveals that the fluid collection decreased.

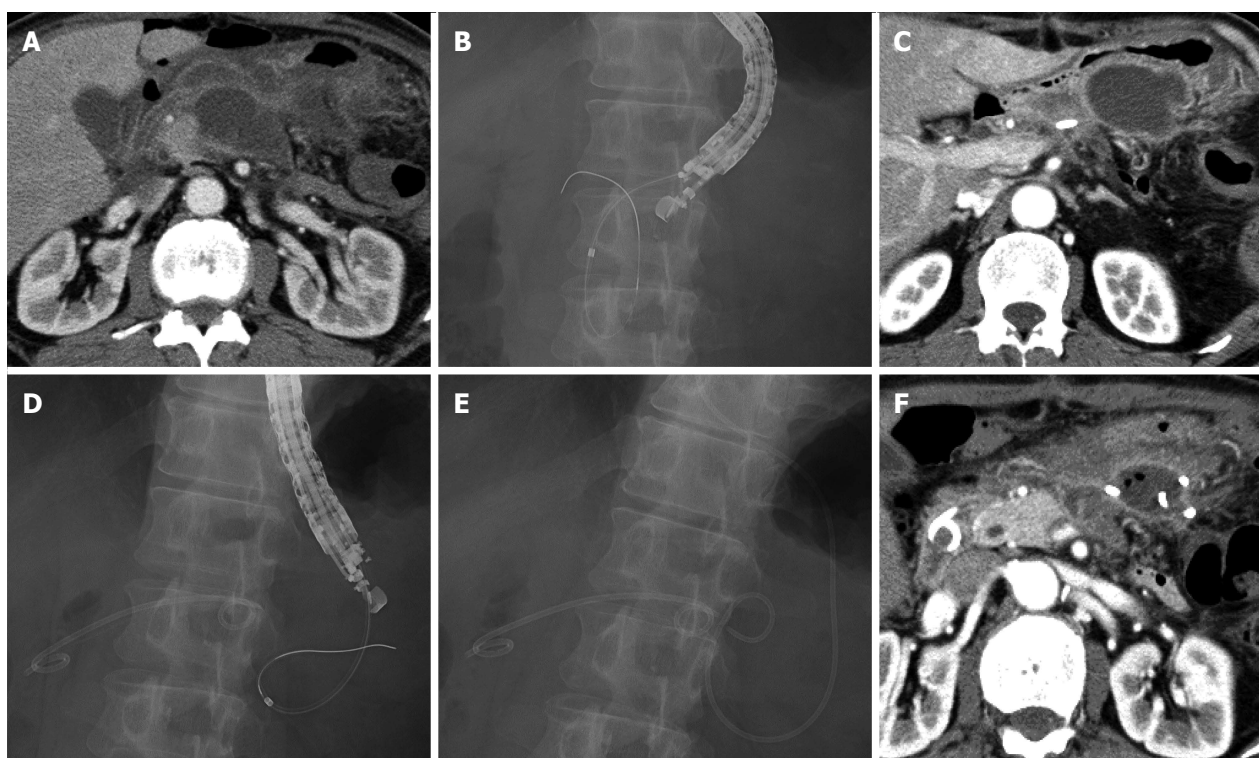confirmed MSSA, and antibiotics were administered until postoperative day 24. CT on postoperative day 28 showed that the abscess had decreased in size (Figure 3F), and the nasal biliary catheter and the 7-Fr double pigtail stent were removed on postoperative days 29 and 30, respectively. The patient was discharged on postoperative day 32. At the latest follow-up (1 year after discharge), no abscess recurrence was observed.

#### Case 4

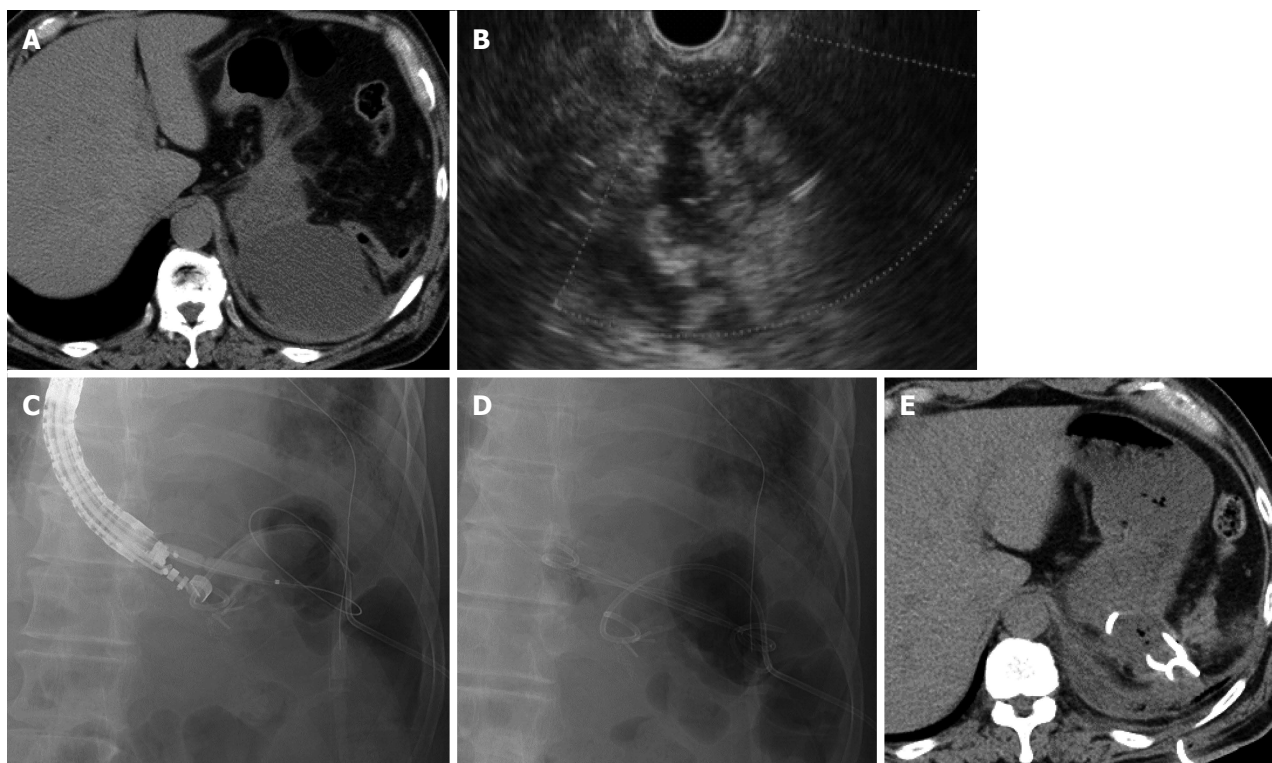
A 69-year-old man underwent distal pancreatectomy for intraductal papillary mucinous neoplasm of the pancreas. He developed high fever on postoperative day 9, and CT revealed a fluid collection (maximum axis, 70 mm) at the dorsal side of the fornix close to the gastric wall (Figure 4A). We diagnosed this fluid collection as an abscess, and conventional ultrasound-

guided percutaneous drainage was performed on the same day. However, the high fever persisted after drainage, and EUS-guided transgastric drainage was consequently performed together with placement of a 7-Fr double pigtail stent and a 6-Fr pigtail nasal biliary catheter on postoperative day 18 (Figure 4B-D). Gram staining and culture of a sample of the aspirate revealed *Enterococcus*, and antibiotics were administered until postoperative day 21. CT on postoperative day 28 showed that the abscess had decreased in size (Figure 4E), and the nasal biliary catheter and the percutaneous drain were removed on postoperative days 28 and 33, respectively. The 7-Fr double pigtail stent was not removed, and the patient was discharged on postoperative day 36. At the latest follow-up (6 mo after discharge), no abscess recurrence was noted.





**Figure 3 Case 3.** A: Computed tomography (CT) reveals fluid collection around the resection stump of the pancreas; B: Fluoroscopy image showing the dilation catheter inserted over the guidewire; C: Seven days after endoscopic ultrasound (EUS)-guided internal drainage, CT reveals another fluid collection on the left side of the previously drained abscess; D and E: Fluoroscopy image showing the placement of the 7-Fr double pigtail stent and insertion of the dilation catheter into the new abscess. Moreover, a 6-Fr nasal biliary catheter was placed; F: Seven days after EUS-guided naso-cystic drainage, CT reveals that the fluid collection decreased.



**Figure 4 Case 4.** A: Computed tomography (CT) reveals fluid collection at the dorsal side of the fornix close to the gastric wall; B: Endoscopic ultrasound (EUS) showing the fluid collection, which was punctured by a 19-gauge needle; C and D: Fluoroscopy image showing placement of the percutaneous drain and insertion of the 6-mm balloon catheter over the guidewire. Both a 7-Fr double pigtail stent and a 6-Fr nasal biliary catheter are placed; E: Ten days after EUS-guided drainage, CT reveals that the fluid collection decreased.

## DISCUSSION

Image-guided percutaneous drainage has been performed for postoperative intra-abdominal abscesses as a minimally invasive method. Azeem *et al.*<sup>[10]</sup> reported that endoscopic drainage with or without EUS was as effective as percutaneous drainage in patients with pancreatic fluid collection after distal pancreatectomy, and that primary endoscopic drainage may be associated with a shorter hospital stay. Although their report suggested the importance of endoscopic drainage of pancreatic fluid collection after pancreatic resection, to our knowledge, there have been no reports comparing the outcomes of EUS-guided drainage and image-guided percutaneous drainage for the treatment of postoperative intra-abdominal abscesses.

In this study, EUS-guided transgastric drainage for postoperative intra-abdominal abscesses was performed in all 4 patients and resulted in clinical improvement in all cases. Furthermore, naso-cystic drainage was performed within 4 wk of surgery in 3 of the 4 patients, with no complications in any patient, suggesting that early EUS-guided drainage after surgery is safe. Similarly, Tilara *et al.*<sup>[8]</sup> also reported that early drainage (within 30 d after surgery) of postoperative pancreatic fluid collections was not associated with an increased risk of complications.

In all 4 of our cases, naso-cystic drainage was performed. The naso-cystic drain was removed on day 11 after placement in cases 1 and 2, day 8 in Case 3, and day 10 in Case 4 (mean, day 10 after naso-cystic drainage), and there was no recurrence of the abscess after naso-cystic drain removal in any case. Taken together, these outcomes suggest the efficacy of naso-cystic drainage, but further investigations are required to confirm these results and to determine whether naso-cystic drainage alone is effective, as internal drainage and percutaneous drainage were also performed before naso-cystic drainage in Cases 3 and 4, respectively. Furthermore, the necessity of internal drainage stent removal and the appropriate time of stent removal should be investigated in cases of both naso-cystic and internal drainage. Several recent studies of EUS-guided drainage of pancreatic pseudocysts recommend both internal and naso-cystic drain placement by first using the double guidewire technique, followed by naso-cystic drain removal after improvement of infection<sup>[3,6]</sup>; however, there is no consensus regarding the optimal drainage method and time for drain removal.

Thus, based on our present cases, we believe that EUS-guided drainage of postoperative intra-abdominal abscesses is a safe and effective method; however, further large-scale investigations are required to confirm our findings.

## COMMENTS

### Case characteristics

The 4 patients (2 male, 2 female) developed high fever after abdominal surgery (pancreatectomy or low anterior resection for rectal cancer).

### Clinical diagnosis

In addition to high fever, all patients had general fatigue.

### Differential diagnosis

Postoperative intra-abdominal fluid collection was performed to diagnose infection.

### Laboratory diagnosis

Gram staining and culture of samples of collected fluid confirmed extended-spectrum beta lactamase-producing *Escherichia coli*, *Enterococcus*, and anaerobic bacteria in the first patient, methicillin-resistant *Staphylococcus aureus* in the second patient, methicillin-susceptible *Staphylococcus aureus* in the third patient, and *Enterococcus* in the fourth patient.

### Imaging diagnosis

Computed tomography revealed fluid collection close to the gastric wall in all 4 patients.

### Pathological diagnosis

Pathological examination of the fluid collection was not performed in any of the patients.

### Treatment

All 4 patients underwent endoscopic ultrasound (EUS)-guided transgastric naso-cystic drainage, and in 2 of the 4 patients, internal drainage was also performed.

### Related reports

Earlier reports state that EUS-guided drainage of postoperative peripancreatic fluid collections is safe and effective, and we believe that this case report adds our findings that early EUS-guided transgastric drainage within 4 wk of surgery is also safe and effective.

### Term explanation

Naso-cystic drainage describes a method of external drainage via the nose.

### Experiences and lessons

This case report presents data showing that early EUS-guided drainage within 4 wk of surgery for postoperative intra-abdominal abscesses is safe and effective.

### Peer-review

This is a well-written case report of a novel application of therapeutic EUS. Although 3 of 4 cases death with post-pancreatic surgery fluid collections, the 4th case is the first to report drainage of an abscess by EUS after colorectal surgery.

## REFERENCES

- 1 **Kassi F**, Dohan A, Soyer P, Vicaut E, Boudiaf M, Valleur P, Pocard M. Predictive factors for failure of percutaneous drainage of postoperative abscess after abdominal surgery. *Am J Surg* 2014; **207**: 915-921 [PMID: 24280147 DOI: 10.1016/j.amjsurg.2013.07.041]
- 2 **Lopes CV**, Pesenti C, Bories E, Caillol F, Giovannini M. Endoscopic-ultrasound-guided endoscopic transmural drainage of pancreatic pseudocysts and abscesses. *Scand J Gastroenterol* 2007; **42**: 524-529 [PMID: 17454865 DOI: 10.1080/00365520601065093]
- 3 **Itoi T**, Itokawa F, Tsuchiya T, Kawai T, Moriyasu F. EUS-guided pancreatic pseudocyst drainage: simultaneous placement of stents and nasocystic catheter using double-guidewire technique. *Dig Endosc* 2009; **21** Suppl 1: S53-S56 [PMID: 19691736 DOI: 10.1111/j.1443-1661.2009.00851.x]
- 4 **Seewald S**, Ang TL, Richter H, Teng KY, Zhong Y, Groth S, Omar S, Soehendra N. Long-term results after endoscopic drainage and necrosectomy of symptomatic pancreatic fluid collections. *Dig Endosc* 2012; **24**: 36-41 [PMID: 22211410 DOI: 10.1111/j.1443-1661.2011.01162.x]
- 5 **Sadik R**, Kalaitzakis E, Thune A, Hansen J, Jönson C. EUS-guided drainage is more successful in pancreatic pseudocysts compared

- with abscesses. *World J Gastroenterol* 2011; **17**: 499-505 [PMID: 21274380 DOI: 10.3748/wjg.v17.i4.499]
- 6 **Kato S**, Katanuma A, Maguchi H, Takahashi K, Osanai M, Yane K, Kim T, Kaneko M, Takaki R, Matsumoto K, Matsumori T, Gon K, Tomonari A. Efficacy, Safety, and Long-Term Follow-Up Results of EUS-Guided Transmural Drainage for Pancreatic Pseudocyst. *Diagn Ther Endosc* 2013; **2013**: 924291 [PMID: 23554548 DOI: 10.1155/2013/924291]
  - 7 **Lin H**, Zhan XB, Sun SY, Yang XJ, Jin ZD, Zou DW, Li ZS. Stent selection for endoscopic ultrasound-guided drainage of pancreatic fluid collections: a multicenter study in china. *Gastroenterol Res Pract* 2014; **2014**: 193562 [PMID: 25018767 DOI: 10.1155/2014/193562]
  - 8 **Tilara A**, Gerdes H, Allen P, Jarnagin W, Kingham P, Fong Y, DeMatteo R, D'Angelica M, Schattner M. Endoscopic ultrasound-guided transmural drainage of postoperative pancreatic collections. *J Am Coll Surg* 2014; **218**: 33-40 [PMID: 24099888 DOI: 10.1016/j.jamcollsurg.2013.09.001]
  - 9 **Varadarajulu S**, Wilcox CM, Christein JD. EUS-guided therapy for management of peripancreatic fluid collections after distal pancreatectomy in 20 consecutive patients. *Gastrointest Endosc* 2011; **74**: 418-423 [PMID: 21679939 DOI: 10.1016/j.gie.2011.03.1242]
  - 10 **Azeem N**, Baron TH, Topazian MD, Zhong N, Fleming CJ, Kendrick ML. Outcomes of endoscopic and percutaneous drainage of pancreatic fluid collections arising after pancreatic tail resection. *J Am Coll Surg* 2012; **215**: 177-185 [PMID: 22634120 DOI: 10.1016/j.jamcollsurg.2012.03.015]

**P- Reviewer:** Chisthi MM, Teshima CW, Yoshida H **S- Editor:** Ma YJ  
**L- Editor:** A **E- Editor:** Wang CH





Published by **Baishideng Publishing Group Inc**

8226 Regency Drive, Pleasanton, CA 94588, USA

Telephone: +1-925-223-8242

Fax: +1-925-223-8243

E-mail: [bpgoffice@wjgnet.com](mailto:bpgoffice@wjgnet.com)

Help Desk: <http://www.wjgnet.com/esps/helpdesk.aspx>

<http://www.wjgnet.com>



ISSN 1007-9327

