

2015 Advances in Gastric Cancer

Evaluation and treatment of malignant ascites secondary to gastric cancer

Hiromichi Maeda, Michiya Kobayashi, Junichi Sakamoto

Hiromichi Maeda, Michiya Kobayashi, Cancer Treatment Center, Kochi Medical School, Kochi 783-8505, Japan

Junichi Sakamoto, Tokai Central Hospital, Sohara Higashijima-cho, Kakamigahara 504-8601, Japan

Author contributions: Maeda H wrote the manuscript; Kobayashi M and Sakamoto J contributed to conception of this study and revised the draft.

Supported by Non-profit Epidemiological and Clinical Research Organization.

Conflict-of-interest statement: There is no conflict of interest to disclose.

Open-Access: This article is an open-access article which was selected by an in-house editor and fully peer-reviewed by external reviewers. It is distributed in accordance with the Creative Commons Attribution Non Commercial (CC BY-NC 4.0) license, which permits others to distribute, remix, adapt, build upon this work non-commercially, and license their derivative works on different terms, provided the original work is properly cited and the use is non-commercial. See: <http://creativecommons.org/licenses/by-nc/4.0/>

Correspondence to: Junichi Sakamoto, MD, PhD, Tokai Central Hospital, Sohara Higashijima-cho, Kakamigahara, Gifu 504-8601, Japan. sakamjun@tokaihp.jp
Telephone: +81-58-3823101
Fax: +81-58-3820229

Received: April 23, 2015

Peer-review started: April 24, 2015

First decision: July 13, 2015

Revised: July 26, 2015

Accepted: September 13, 2015

Article in press: September 13, 2015

Published online: October 21, 2015

Abstract

Malignant ascites affects approximately 10% of

patients with gastric cancer (GC), and poses significant difficulties for both patients and clinicians. In addition to the dismal general condition of affected patients and the diversity of associated complications such as jaundice and ileus, problems in assessing scattered tumors have hampered the expansion of clinical trials for this condition. However, the accumulation of reported studies is starting to indicate that the weak response to treatment in GC patients with malignant ascites is more relevant to their poor prognosis rather than to the ascites volume at diagnosis. Therefore, precise assessment of initial state of ascites, repetitive evaluation of treatment efficacy, selection of suitable treatment, and swift transition to other treatment options as needed are paramount to maximizing patient benefit. Accurately determining ascites volume is the crucial first step in clinically treating a patient with malignant ascites. Ultrasonography is commonly used to identify the existence of ascites, and several methods have been proposed to estimate ascites volume. Reportedly, the sum of the depth of ascites at five points (named "five-point method") on three panels of computed tomography images is well correlated to the actual ascites volume and/or abdominal girth. This method is already suited to repetitive assessment due to its convenience compared to the conventional volume rendering method. Meanwhile, a new concept, "Clinical Benefit Response in GC (CBR-GC)", was recently introduced to measure the efficacy of chemotherapy for malignant ascites of GC. CBR-GC is a simple and reliable patient-oriented evaluation system based on changes in performance status and ascites, and is expected to become an important clinical endpoint in future clinical trials. The principal of treatment for GC patients with ascites is palliation and prevention of ascites-related symptoms. The treatment options are various, including a standard treatment based on the available guidelines, cytoreductive surgery with hyperthermic intraperitoneal chemotherapy (HIPEC), laparoscopic HIPEC alone, intravenous chemotherapy, intraperitoneal chemotherapy, and molecular targeting

therapy. Although each treatment option is valid, further research is imperative to establish the optimal choice for each patient.

Key words: Ascites; Clinical benefit; Gastric cancer; Peritoneal dissemination; Paclitaxel

© **The Author(s)** 2015. Published by Baishideng Publishing Group Inc. All rights reserved.

Core tip: Malignant ascites affects approximately 10% of patients with gastric cancer (GC) and poses significant problems for treatment. Accurate and repetitive measurement of ascites volume during treatment is clinically imperative for effective decisions surrounding treatment continuation. Meanwhile, clinical benefit response in GC, a patient-oriented assessment framework of treatment efficacy, should be used in future clinical trials for malignant ascites caused by GC. Although several treatment options have been reported, further studies are mandatory to develop a solid and optimal treatment strategy.

Maeda H, Kobayashi M, Sakamoto J. Evaluation and treatment of malignant ascites secondary to gastric cancer. *World J Gastroenterol* 2015; 21(39): 10936-10947 Available from: URL: <http://www.wjgnet.com/1007-9327/full/v21/i39/10936.htm> DOI: <http://dx.doi.org/10.3748/wjg.v21.i39.10936>

INTRODUCTION

Malignant ascites caused by gastric cancer (GC) is an accumulation of excess fluid within the abdominal cavity associated with serious clinical problems. First, it is one of the late manifestations of GC, and thus is often accompanied by a severely impaired patient condition^[1-3]. A retrospective study of 119 patients with malignant ascites due to GC revealed that 31% of these patients were classed as having as Eastern Cooperative Oncology Group performance status (ECOG-PS) of 3 or more^[2]. Generally, such patients have difficulties in receiving standard treatment and show dismal prognosis, with a reported median survival time of 4.6 mo when treated with 5-fluorouracil alone or 5-fluorouracil plus methotrexate^[3]. Consequently, these GC patients are often excluded from clinical trials^[1] and attract only limited attention with respect to management strategies, thus further veiling the condition and possible treatment of ascites development.

Adequately assessing both ascites volume and treatment efficacy is another clinical problem for patients with malignant ascites due to GC^[4]. Because it is difficult to measure the exact nature and extent of disseminated tumors on radiological examination^[5], the evaluation of treatment efficacy has empirically relied on changes in the ascites volume. In clinical trials, each

protocol had arbitrarily defined the response of ascites to treatment or applied ambiguous definitions of the condition, further complicating inter-trial comparisons. Indeed, the lack of a "standard" method to evaluate treatment efficacy for these patients in daily clinical practice urgently demands the development of a reliable assessment framework.

Despite these documented difficulties, pioneers in this field have successfully conducted several phase II studies or retrospectively reported precious results for specific treatment options, and based on these results, patients and clinicians now have expanded treatment options^[6]. For instance, long-term survival was achieved after combination therapy of surgical treatment and chemotherapy among selected patients with ascites and GC, although these reports presented limited patient numbers^[7-9]. However, the data has not yet been integrated and selecting the most suitable treatment remains a great burden for both patients and clinicians.

In this manuscript, we first review the relevant literature to elucidate the incidence of ascites development among patients with GC. Then, we introduce recently reported methods to measure ascites volume by computed tomography (CT), and explain a new concept for evaluating treatment efficacy based on patient-oriented parameters. Finally, we discuss each treatment option with respect to future directions.

INCIDENCE OF ASCITES DUE TO GC

Data showing the incidence of ascites secondary to GC are scarce and glancing. The development of malignant ascites, an end-stage manifestation of GC, requisitely depends on the tumor stage at diagnosis of primary lesions. Thus, in countries where GC is diagnosed at an earlier stage through validated screening programs^[10,11], the incidence of malignant ascites could be relatively low. Contrarily, in countries where less attention is paid to GC due to its lower morbidity, diagnosis of the disease is often delayed until symptoms develop. Therefore, the available literature covers a range of incidence rates of ascites development due to GC across various countries and study periods (Table 1).

Specifically, a retrospective study analyzing more than 7000 patients who underwent gastrectomy in a single Japanese institution from 1960 to 1988 found that 14.2% of the patients developed peritoneal recurrence^[10]. Similarly, a Japanese nationwide study in 2009 suggested that 9.9% of 13002 patients who underwent gastrectomy in 2002 died from peritoneal involvement of GC during the 5-year follow-up period^[12], while further studies also suggested that approximately 40% of consecutive patients with peritoneal dissemination also showed malignant ascites^[13,14]. Thus, these previous data indicated that approximately 4%-5% of all patients undergoing gastrectomy would

Table 1 Incidence of peritoneal dissemination and ascites development due to gastric cancer

Ref.	No. of patients	Period	Country	Status of primary disease	Incidence
Development of peritoneal dissemination					
Nakajima <i>et al</i> ^[10]	7060	1960-1988	Japan	After gastrectomy	14.2%
Nashimoto <i>et al</i> ^[12]	13002	2002	Japan	After gastrectomy	9.9% (related to death)
Development of ascites					
Lello <i>et al</i> ^[15]	356	1980-2004	Norway	At initial diagnosis	6.2%
Yajima <i>et al</i> ^[31]	293	1988-2002	Japan	GC with T2-3 at diagnosis	15.0%
Fang <i>et al</i> ^[16]	5542	2007-2012	China	At initial diagnosis	2.6% ¹
				During the course of disease	3.7% ¹
Kitayama <i>et al</i> ^[14]	83	2006-2008	Japan	Peritoneal recurrence	40.0%
Tahara <i>et al</i> ^[13]	56	1993-1999	Japan	Peritoneal recurrence	46.4%

¹Diagnosis of malignant ascites is limited to ascites with positive cytology.

be subsequently diagnosed with malignant ascites.

More direct evidence on the incidence of ascites comes from a retrospective analysis in a hospital serving a single, well-defined area of Norway^[15]. The authors analyzed 354 patients with clear chart descriptions and identified 6.2% (22/354) as having ascites at the diagnosis of GC. A similar, larger scale retrospective study from China identified ascites in 2.6% of GC patients at the time of initial diagnosis, and in 3.7% of patients thereafter^[16]. In these Chinese patients, the diagnosis of malignant ascites was confined to cytology-positive cases, therefore the real prevalence of ascites due to GC would be somewhat higher than that reported^[2].

Malignant ascites due to GC is often accompanied by other symptoms related to peritoneal dissemination, a particular recurrence mode of GC^[17,18] that can cause obstruction of the gastrointestinal tract, bile duct, and ureter. In addition, half of the patients with peritoneal recurrence have concomitant recurrence sites^[17], including lymph nodes, liver, and lung, necessitating the systemic evaluation of each site using imaging modalities. We thus consider that diversity among the accompanying symptoms and conditions of GC patients with malignant ascites could induce factors that hinder clear depiction of these patients in the literature and consequently, could obstruct the establishment of reliable guidelines.

Based on the available data, we estimate that 3%-6% of patients with GC has ascites to some extent at the initial presentation of cancer. Eventually, 10%-15% of those patients treated by curative resection will develop peritoneal recurrence and approximately half of them are likely to develop ascites. Thus, 8%-13.5% of the total number of patients diagnosed with GC will have accompanying malignant ascites. However, the incidence of "massive" malignant ascites that defies conventional treatment remains obscure.

PATHOPHYSIOLOGY

Ascites develops from an imbalance between the production and drainage of peritoneal fluid^[19-22]. In

adults, the serous membrane covers nearly 2 m² of the peritoneal surface^[23], and the cavity typically contains 50-100 mL of fluid that turns over at the rate of 5 mL/24 h^[24]. Peritoneal fluid is generated by the transudation of plasma from peritoneal capillaries^[19], and it serves to lubricate the serous membrane. The fluid eventually drains into the lymphatic system *via* open-ended channels (named stomata) and then into the systemic circulation through the right thoracic duct^[24].

Among multiple factors, increased vascular permeability due to vascular endothelial growth factor (VEGF) is considered an important driver of increased ascites production. Zebrowski *et al*^[25] demonstrated markedly elevated VEGF levels in malignant ascites including from GC. They further showed augmented permeability of endothelial cells *in vitro* when cultured with malignant ascites. Another important factor in the development of ascites is matrix metalloproteinase-9 and -2, a key enzyme in tumor cell metastasis to distant organs due to its role in breaking down the tissue matrix. Reportedly, matrix metalloproteinase enhances the release of biologically active VEGF in a time- and dose-dependent manner, and might thus be a key regulator of VEGF in ascites production^[26]. In fact, inhibition of matrix metalloproteinase significantly suppressed tumor growth in a rodent model of metastasis^[27]. Several other factors could also play a role in the development of malignant ascites during cancer (Table 2), and each could be a potential target of prevention and treatment.

IDENTIFYING AND ASSESSING ASCITES VOLUME

Objectively evaluating the nature and volume of ascites is the first step in treating patients with ascites and peritoneal dissemination of GC. Cytology should be always considered at the initial evaluation because a positive result is diagnostic, while increased levels of carcinoembryonic antigen in ascites suggests the pathological accumulation of peritoneal fluid due to GC^[2]. However, it should be noted that the sensitivity

Table 2 Factors influencing development of ascites due to gastric cancer^[19-26]

Increased fluid production
Increased vascular permeability due to increased VEGF and/or MMP-2/-9
Neovascularization of peritoneum
Peritoneal inflammation
Increased portal pressure due to tumor metastasis
High protein concentrations in ascites
Lower concentration of serum proteins due to undernutrition
Decreased drainage of peritoneal fluid
Obstruction of lymphatics

MMP: Matrix metalloproteinase; VEGF: Vascular endothelial growth factor.

of these two measures is relatively low^[2], and negative results warrant an integrated evaluation of the ascites based on a range of clinical data.

Although the relationship between ascites volume at diagnosis and prognosis remains controversial^[14,28], a weak response of ascites to the anti-cancer treatment is well correlated with poor prognosis^[1,14], suggesting that frequent and repetitive volume assessment is particularly important for decision making concerning continuation or withdrawal of the ongoing treatment.

ULTRASONOGRAPHY

In this field, the use of endoscopic ultrasonography is increasingly reported^[29,30], because of its excellent ability to detect subtle ascites. This modality would therefore be especially beneficial for predicting prognosis in patients with GC, based on patients with ascites apparently having poorer outcomes than those patients without ascites^[16,31-33]; however, the technique requires considerable expertise and is invasive for patients. Abdominal ultrasonography is often used in the emergency room and daily clinical practice due to its convenience, and thus is likely to first detect ascites. Recently, ultrasonography technologies allowed development of much smaller devices, which will eventually eliminate unnecessary further confirmatory examination with invasive modalities^[34].

Indeed, as early as 1996 Inadomi *et al.*^[35] developed a protocol to measure ascites volume with ultrasonography, in patients with portal hypertension. They regarded the ascites in the abdominal cavity as a fluid retained in the base of a large sphere, and developed an algorithm accordingly using two variables: the ascites depth, defined as the distance to the deepest point of the ascites, and abdominal circumference. The calculated value proved to be well correlated with the ascites volume determined by distribution (dilution) of radiolabeled tracer. However, this method had the remaining problem that patients needed to remain in a prone position on their hands and knees for 10 min, and it is not clear whether it could be used in patients

with postoperative intraperitoneal adhesions.

More recently, Irshad *et al.*^[36] reported notable findings of correlation between the smallest depth of ascites on ultrasonography and the subsequent drained volume of ascites. They conducted 60 paracenteses in 29 patients after evaluating the length between the most superficial bowel loop and the abdominal wall. They found that the length measured by ultrasonography was well correlated to the amount of drained fluid, and concluded that ultrasonography could successfully estimate the ascites volume. Establishment of a validated volume-measuring method based on ultrasonography would obviously be a great benefit for patients who require frequent monitoring, and thus further development of these initial studies are eagerly awaited.

FIVE-POINT METHOD ON CT

The recent development of multi-detector CT permits small amounts of ascites to be detected^[31,32] and thus imaged by reconstruction of three-dimensional imaging. Although a volume-rendering algorithm applied to such imaging would enable accurate assessment of ascites volume, the procedure requires an appreciable amount of time regardless of the operator expertise. To reduce the burden, Oriuchi *et al.*^[4] developed a very simple method to estimate ascites volume using the horizontal plane of CT imaging. In this technique, ascites depth was measured at five points on three CT images and the sum of measurements for each patient was multiplied by 200 (Figure 1). The estimated ascites volume was then correlated with the volume calculated with 3D-CT in patients having > 300 mL of ascites. The authors reported that this protocol was reliable even in patients with a history of surgical intervention that might cause changes of their ascites distribution due to adhesion. The accuracy of this method was confirmed by two following studies: one for assessing the ascites due to GC^[1] and one for assessing ascites due to a perforated peptic ulcer of the upper gastrointestinal tract^[37].

Of note, the horizontal plane of CT imaging at the level of the superior mesenteric artery occasionally does not depict the spleen, and ascites can occur in patients who undergo splenectomy with gastrectomy. In such cases, volume assessment could instead use the distance from the inner surface of the abdominal wall to the surface of an internal organ at a defined line (Figure 1). This alternative method is also reliable for assessing chronological changes in ascites volume (personal communication with Dr. Oriuchi). Despite the apparent limitation of only a small number of patients examined thus far and the lack of explicit evidence for using an alternative measuring parameter rather than the standard one of the distance between spleen and abdominal wall, this CT-based method is fascinating and warrants further exploration.

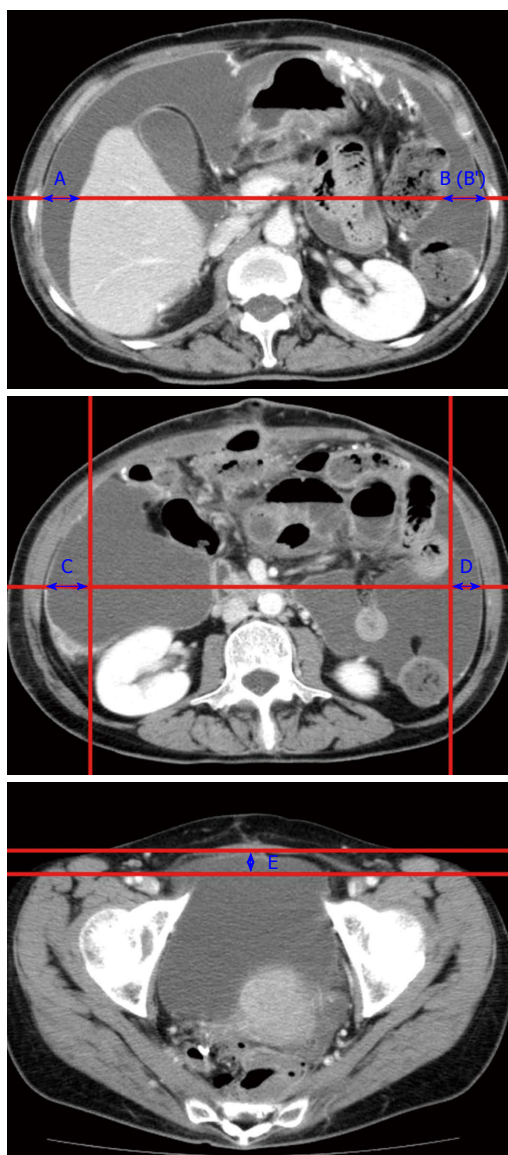


Figure 1 Five-point method to measure ascites volume. Upper: Line between the bilateral antero-posterior mid-points of the abdominal wall is drawn at the plane of the root of the superior mesenteric artery. The distances between the inner surface of the right abdominal wall and the liver (A cm), and between the inner surface of the left abdominal wall and spleen (B cm) are obtained. When spleen is not observed on this plane, the distance between the left abdominal wall and margin to the ascites and internal organs are measured (B' cm); Middle: The lower pole of the left kidney is observed on this plane. The sagittal line from the bilateral paracolic gutter, and between the bilateral antero-posterior midpoints of the abdominal wall is drawn. The distances C (cm) and D (cm) are thus obtained. Lower: A line between the anterior sides of the bilateral femoral artery is drawn. The distance between the inner surface of the abdomen (at the middle) and the line is obtained (E cm). The ascites volume is calculated by the equation of $(A + B + C + D + E) \times 200$ (mL).

CLINICAL ENDPOINT OF TREATMENT FOR ASCITES

Because the peritoneal dissemination sparsely distributes in the abdominal cavity rather than forming a large mass, patients with malignant ascites often lacks measurable lesions. In addition to the ascites volume, the assessment of treatment efficacy in

such cases has to be based on the integrated clinical information^[38]. Standardized evaluation methods are required to select the patients who should continue the current treatment, and identify the patients who should receive other treatments because of disease progression. The candidate for the clinical endpoint of the treatment could be an improvement of quality of life (QOL) measured by established questionnaires. However, the assessment is often difficult to achieve due to its complexity; Badgwell *et al.*^[39] courageously demonstrated the difficulty of conducting self-reporting assessment of QOL using Functional Assessment of Cancer Therapy-General (FACT-G)^[40]. Only 39% of the patients with incurable cancer and gastrointestinal obstruction completed the questions concerning quality of life and treatment satisfaction at one-month follow up. Based on our similar clinical experiences and observations, we noticed the need for new convenient method to evaluate the treatment efficacy for malignant ascites due to GC, and "Clinical Benefit Response in GC (CBR-GC)" was proposed^[1,41].

CONCEPT OF CLINICAL BENEFIT RESPONSE IN GC

CBR is an established palliative endpoint for gastrointestinal tract malignancy that is particularly applied in clinical trials for the treatment of pancreatic cancer^[42-44]. CBR is based on three clinical factors: the change in pain, Karnofsky PS, and body weight, although because of the hierarchical structure of CBR, its use is slightly complicated and vulnerable to missing data^[44]. In contrast, CBR-GC is a newly proposed concept for evaluating the response of malignant ascites due to GC to anti-cancer therapy. This evaluation system has two major components: (1) change in ECOG-PS; and (2) change in ascites evaluated using the patient-oriented method.

Change in ascites (response) with treatment (lateral axis of Figure 2) is determined by abdominal girth and intensity of palliation, which comprises the use of diuretics and paracentesis. When the abdominal girth decreases in volume and the intensity of palliation is not increased, the response of ascites is termed "Positive". Meanwhile, either or both an increase in abdominal girth and increased intensity of treatment is classed as a "Negative" response to treatment. Comprehensive judgment is then based on the general assessment of ascites response and ECOG-PS. Positive CRB-GC is defined by an improvement of either or both ascites and ECOG-PS without deterioration of any parameter. If the CRB-GC is not positive, the status is determined as negative.

CLINICAL USE OF CBR-GC

When CRB-GC was used to evaluate the efficacy of paclitaxel treatment in patients with malignant ascites

		Ascites fluid			
			Positive	Stable	Negative
		Abdominal girth Treatment intensity	Decreased and Not increased	No change and Not increased	Increased and/or increased
ECOG-PS	Improvement				
	Stable				
	Deterioration				

Positive CBR-GC

Negative CBR-GC

Figure 2 Clinical benefit response in gastric cancer. CBR-GC is defined by the ascites response to treatment (horizontal axis) and ECOG-PS (vertical axis). Response of ascites is judged by a combination of abdominal girth and treatment intensity. CBR-GC: Clinical benefit response in gastric cancer; ECOG-PS: Eastern Cooperative Oncology Group performance status.

due to GC, 39.1% had a positive CRB-GC, suggesting that CRB-GC could serve as a prognostic predictor in such patients. The median survival time of patients with positive CRB-GC was 9.9 mo, while that of patients with negative CRB-GC was 3.6 mo (*P* value not shown).

The possible limitation of CRB-GC is that subtle alleviation of ascites-related symptoms, which could be of real importance for patients, might be overlooked when solely based on these two factors of ascites response and ECOG-PS, when clinically, symptom improvement should signal continuation of the treatment to prevent deterioration in the patient's condition. However, CRB-GC could become negative when both ascites and ECOG-PS are "stable". Thus, further study is necessary to clarify whether this new evaluation system is adequately correlated with subtle symptom alleviation. As suggested by the authors, the relationship between improvement in patient quality of life and CRB-GC status should be addressed. Additionally, the abdominal girth seems precarious compared to the volume measurement by CT, and the threshold of decrease or increase in abdominal girth has to be clearly defined. Although, the authors found that the 5% of possible error did not change the primary results, the exact threshold of change in abdominal girth that determines "no change" should be verified.

TREATMENT

Choosing a treatment option for GC with malignant ascites also relies on the patient's general condition. Despite the presence of ascites, standard treatment as per the guidelines^[45-47] should be the first choice when the patients are motivated enough and in a good general condition without insufficiency of vital organs. While many alternative treatment options have been reported, evidence-based guidelines for each remain to be developed.

SYSTEMIC CHEMOTHERAPY

Paclitaxel monotherapy

Pharmacokinetic studies of paclitaxel shows that

concentration of this drug in ascites remains within the optimal range up to 72 h after intravenous administration at the dose used in a weekly regimen^[48], while a similar dose of paclitaxel maintains the serum concentration above the minimum effective concentration at least for 24 h^[49]. The bulky molecular structure, molecular weight, and high affinity to proteins in ascites probably delays the clearance of paclitaxel from the peritoneal cavity^[48], possibly explaining its efficacy on ascites and peritoneal dissemination. Imamoto *et al.*^[1] conducted a phase II study focusing on the efficacy of paclitaxel monotherapy in patients with malignant ascites due to GC, recruiting 64 patients with a median ascites volume of 2796 mL (range, 122 mL to 7623 mL). This paclitaxel monotherapy regimen achieved volume reduction in 31.1% of patients (Table 3) and 39.1% of the patients experienced positive CBR-GC. We consider that the low frequency of adverse events and the treatment efficacy warrants applying this treatment for a wider range of patients^[1,6,50-52].

Docetaxel

Pharmacokinetics study of docetaxel after synchronous administration with fluoropyrimidines demonstrated that docetaxel concentration in ascites remained high up to 24 h after the intravenous administration^[53]. This synchronous administration of two different anti-cancer agents achieved a median survival time of 7.2 mo in 24 patients with GC and malignant ascites. However, the author noted that the concentration of docetaxel in ascites was not correlated with the reduction in ascites, leaving the possibility of a significant influence due to the fluoropyrimidine.

Evidence concerning the direct effect of docetaxel monotherapy on malignant ascites due to GC is not available, to our knowledge; however, the weekly docetaxel monotherapy achieved disease stabilization (defined as a complete response, partial response, or stable disease lasting more than 100 d) in 36% of elderly patients or patients with impaired performance status, with an acceptable safety profile^[54]. In addition, several case reports demonstrated its efficacy in treating patients with peritoneal recurrence and/or malignant ascites refractory to paclitaxel^[55,56]. Gligorov

Table 3 Systemic chemotherapy for patients with malignant ascites due to gastric cancer

Ref.	Regimen	No. patients	ECOG-PS 0/1/2	Ascites volume	Prior chemotherapy	Main findings	Grade 3 or more AE
Imamoto <i>et al</i> ^[1]	Paclitaxel ¹	64	24/28/12	Mean: 2906 mL (range: 122-7623 mL)	37	Positive CRB-GC: 39.1% MST 5.2 mo Positive CRB-GC: 9.9 mo Non-response: 3.6 mo	Neutropenia: 19.1% Hyponatremia: 19.1% Anorexia: 22.2%
Hironaka <i>et al</i> ^[51]	Paclitaxel ¹	38 (21)	12/15/11	ND	38	Ascites volume reduction: 5/21	Neutropenia: 32% Leukopenia: 29% Death within 30 d of the last administration
Takeyoshi <i>et al</i> ^[58]	Paclitaxel Doxifluridine ²	24	8/4/2012	ND	14	MST: 7.2 mo 1-yr OS: 29.2 and RR: 41.7%	Leukopenia: 25% Elevated alt: 12.5%
Iwasa <i>et al</i> ^[59]	Paclitaxel	25	1/19/5	Non: 1	7	Ascites volume reduction: 44% MST: 8.0 mo	Neutropenia: 12% Anemia: 12% Hyponatremia: 16% Anorexia: 16%
Oh <i>et al</i> ^[60]	Fluorouracil Leucovorin ³	48	0-1/2: 26/22	Mild: 6 Moderate: 2 Masive: 16	27	MST: 8.4 mo Ascites volume reduction: 35.4%	Neutropenia 18.8% (per cycle) Nausea: 6.3% Febrile neutropenia: 2.6% (per cycle)
Yamao <i>et al</i> ^[38]	Methotrexate Fluorouracil ⁵	37	8/24/5	ND	0	Ascites volume reduction: 35.1%	Neutropenia: 27% Elevated total bilirubin: 24.3% Anemia: 24.3%
Nakayama <i>et al</i> ^[62]	Methotrexate	47 (23)	10/13/24	ND	8/47	Ascites volume reduction: 15/23 MST 211 d	Leukopenia: 21.3% Neutropenia: 19.1% Nausea: 2.1% Anorexia: 2.1%
	Fluorouracil Cisplatin ⁶						

¹Eighty mg/m² of paclitaxel intravenously on day 1, 8, 15, every 4 wk; ²80 mg/m² of paclitaxel intravenously on day 1, 8, 15, every 4 wk and doxifluridine 533 mg/m² at day 1-5, every week; ³500 mg/m² of fluorouracil, 250 mg/m² of leucovorin, and 60 mg/m² of paclitaxel intravenously on day 1, 8, 15, every 4 wk; ⁴85 mg/m² of oxaliplatin on day 1, 20 mg/m² of leucovorin, 400 mg/m² of fluorouracil on day 1 and 2, followed by 600 mg/m² of fluorouracil over 22 h, every 2 wk; ⁵100 mg/m² of methotrexate and 600 mg/m² of fluorouracil intravenously, every week; ⁶30 mg/m² of methotrexate, 600 mg/m² of fluorouracil on day 1 and 8, 6 mg/m² cisplatin on days 1-14, every 4 wk. AE: Adverse event; ND: Not described; ECOG-PS: Eastern Cooperative Oncology Group performance status.

et al^[57] cautiously summarized the difference between taxanes, and found favorable molecular features, pharmacokinetics, and drug interactions of docetaxel as an anti-cancer drug. Thus, a phase II study is urgently needed to adequately determine the efficacy and safety of docetaxel monotherapy, ideally in comparison with paclitaxel, for patients with malignant ascites due to GC.

Combination therapy

The advantage of combination therapy over monotherapy has to be more definitively proved in clinical trials before wide take-up by clinicians, with several one-arm phase II studies favouring monotherapy^[58-60]. Takeyoshi *et al*^[58] performed a Phase II trial to evaluate combination therapy of paclitaxel and doxifluridine, an intermediate metabolite of capecitabine, and found that the treatment yielded an ascites response rate of 41.7% and MST of 215 d (equivalent to 7.2 mo) in 24 patients, with a 25% occurrence rate of grade 3/4 leukopenia. The accompanying pharmacokinetics study revealed that the ascites concentration of paclitaxel following such therapy was within the therapeutic range up to 72 h, which is consistent with previous reports of monotherapy^[48]. Similarly, paclitaxel and

5-fluorouracil achieved a median overall survival of 8.0 mo and ascites response rate of 44% in patients with massive ascites or inadequate oral intake^[59].

Korean scholars reported the effectiveness of modified FOLFOX-4 in patients with malignant ascites due to GC with the protocol regime applied as first-line, second-, or third-line treatment^[60]. A decrease or disappearance of ascites was observed in 35.4% (17/48) patients, with a median overall survival of 8.4 mo; however, the treatment could be harsh because grade 3 neutropenia was not uncommon (0.188 event per cycle) and grade 4 febrile neutropenia occurred 6 times among 233 treatment cycles.

In terms of methotrexate, two phase II clinical trials explored the efficacy of combination therapy of methotrexate and 5-fluorouracil^[38,61], and found complete disappearance of ascites or apparent reduction of ascites in 35%-54% of the patients. A study of more complicated combination chemotherapy with methotrexate, a-fluorouracil, and low-dose cisplatin for diffuse-type advanced and recurrent GC (KDOG9501) recruited 47 patients, 23 patients of which had significant amounts of ascites^[62]. The results showed that 4 out of 23 ascites disappeared, while 11 patients had decreased ascites, thus 65.2%

of the patients with ascites experienced improvement. The median survival time was reported to be 211 d (equivalent to 7.0 mo). However, a recent phase III clinical trial including 237 patients with peritoneal dissemination (among them, 171 patients had malignant ascites) suggested that the combination therapy is not superior to 5-fluorouracil monotherapy in terms of overall survival^[63].

INTRAPERITONEAL CHEMOTHERAPY

Anti-cancer drugs administered into the peritoneal cavity penetrate the tumor nodules by passive diffusion. Because penetration depth is limited^[64], such intraperitoneal administration is not sufficient to treat larger nodules, and combinations of intravenous and intraperitoneal administration of anti-tumor drugs have been attempted to treat such cases. Cisplatin is an effective agent to treat GC when it is administered intravenously. However, intraperitoneal administration of cisplatin is not a common practice due to its proven lack of benefit as adjuvant chemotherapy^[65], probably due to immediate clearance from the peritoneal cavity. To prolong the effect of cisplatin within the abdominal cavity, a new drug delivery system has to be developed. In this context, the commonly applied agents are taxanes. For instance, a phase II randomized trial comparing intravenous and intraperitoneal paclitaxel administration has been implemented by Kodera *et al.*^[66] (UMIN000002957) under the supervision of Ministry of Health, Labor and Welfare as an advanced medical treatment project of the government.

For treatment of patients with malignant ascites due to GC, Kitayama *et al.*^[14] evaluated the efficacy of synchronous administration of intravenous and intraperitoneal paclitaxel, and oral administration of S-1. The study enrolled 33 patients with ascites due to GC, 9 of which had more than 2500 mL of ascites before treatment. After the initiation of the treatment, 70% of the cases showed > 50% reduction in ascites volume and an associated improvement in prognosis, with a median survival time of 455 d. Another study from the same group further showed that the combination treatment could be safely followed by curative resection (gastrectomy) in selected patients^[7]. In such cases, the one-year survival rate was 82% with a median survival time of 26.4 mo. Meanwhile, the patients with refractory ascites against treatment had a median survival time of 12.1 mo. As discussed by the authors, the benefit of salvage gastrectomy remains unclear; however, such treatment is apparently beneficial for selected patient because 5-year survival could be achieved by this sequential treatment. The frequent adverse events for this regimen were neutropenia and leukopenia (25% of patients), while occlusion or infection of the access port is also conceivable with the intraperitoneal chemotherapy.

HYPERTHERMIC INTRAPERITONEAL CHEMOTHERAPY AND CYTOREDUCTIVE SURGERY

HIPEC after cytoreductive surgery has received increasing attention due to its efficacy in treating peritoneal dissemination of GC^[67,68]. We speculate that many of the patients in these cited studies had some degree of malignant ascites; however, there was little focus on the efficacy of HIPEC with/without cytoreduction in patients with significant amounts of malignant ascites. Yang *et al.*^[8] explored the clinical benefit of this combination therapy in 28 patients with GC and heavy ascites or peritoneal carcinomatosis. Of these patients, 20 had ascites and positive cytology, and the detailed information of 12 patients with ascites was available. These patients died at 2, 3, 8, 8, 9.5, 9.5, 10.5, and 29.5 mo after surgery, and survival was confirmed at 3, 5, 9, and 19 mo, yielding a median survival time of 9.5 mo (95%CI: 7.6-11.4 mo). Although the beneficial effect of this treatment seems marginal for the majority of patients, long-term survival was observed and this is generally difficult to achieve with other modalities. Unfortunately, the study did not elucidate the preoperative factors significant for long-term survival, and thus patient selection would become an important issue to be solved. In addition, the related complications and even mortality associated with this combination regime might attenuate its attractiveness.

Another of HIPEC demonstrated that only 14 out of 45 patients with peritoneal dissemination of GC could undergo optimal cytoreductive surgery, (meaning no visible tumor residue or only residual nodules < 2.5 mm). The authors performed HIPEC only in these 14 patients because the penetration of chemotherapeutic agents into tissue nodules is limited and they considered that performing HIPEC in patients with large residual nodules would not be beneficial^[9]. Consequently, the optimal treatment group with cytoreduction and HIPEC showed longer median survival than cytoreduction only (median survival time of 18 mo vs 6 mo, $P = 0.0007$). They also found that the preoperative risk factors of incomplete cytoreduction were retention of ascites and preoperative malnutrition (prognostic nutrition index). Indeed, attempting to perform cytoreductive surgery with HIPEC on patients with GC and ascites is in and of itself a challenging task.

Because cytoreductive surgery and HIPEC could be too damaging for patients with GC and an already poor general condition, reduced invasiveness was attempted by using laparoscopic intraperitoneal hyperthermic chemotherapy. Reports of this modification are still scant and the survival benefit remains unclear^[69-71]; however, the recurrence of ascites development was suppressed in the majority of studied cases and thus exploration of this treatment might be justified.

MOLECULAR TARGETING THERAPY

Molecular targeting therapies such as bevacizumab^[72], cetuximab^[73,74], panitumumab^[75], and everolimus^[76] have not shown significant survival benefit in patients with GC. Thus, these agents are unlikely to be used vigorously for malignant ascites secondary to GC. Trastuzumab is a humanized monoclonal antibody targeting human epidermal growth factor receptor type 2 (HER-2), and some clinical trials demonstrated the efficacy and safety of combination therapy with trastuzumab, cisplatin, and fluoropyrimidines^[77,78]. Although the protocols used did not exclude the existence of ascites, data concerning ascites response was seldom described. An ongoing phase II trial focusing on patients with unmeasurable lesions of HER2-positive GC (UMIN000007941) may give some further indication for this treatment of malignant ascites.

Recently the clinical benefit of catumaxomab was reported. This chimeric antibody of mouse-derived anti-EpCAM Fab region and a rat antiCD3 Fab can recognize epithelial cell adhesion molecule-expressing tumor cells, CD-positive T cells, and Fc γ receptor-positive immune cells, and improved the quality of life in patients with ascites due to several kinds of malignancies compared to best supportive care^[79,80]. Because this treatment did not prolong survival time, catumaxomab should be considered only in patients whose cancer is difficult to treat by conventional regimes. Meanwhile, the efficacy of combination therapy with catumaxomab and chemotherapy, which has minimum toxicity, such as monotherapy of taxanes, should be explored for severely deteriorated patients with GC and malignant ascites, as suggested by Imamoto *et al.*^[1].

CONCLUSION

Malignant ascites is a common manifestation of end-stage GC, affecting approximately 10% of patients. Because prognosis in these patients can be predicted during treatment by changes in the ascites volume, repetitive and objective evaluation of such volumes is critically important to maximize patient outcomes. Meanwhile, CBR-GC can assess the treatment efficacy based on changes in ECOG-PS and ascites due to anti-cancer treatments, and should be used for such assessments in future clinical trials.

For patients with malignant ascites due to GC, a guidelines-based standard treatment should be the first considered. In many cases, however, an alternative treatment has to be chosen from the wide range of options, based on the patient's general condition, their understanding of the disease, and support from personal circumstances. Despite the progress in this field, the best supportive care is often the only thing that can be offered to patients suffering from end-stage GC. Thus, more understanding of

this condition and development of evidence-based treatment strategies, together with new treatment options, are necessary.

ACKNOWLEDGMENTS

We greatly thank Dr. Tsutomu Namikawa for kind advice in the preparation of this manuscript, and Ms. Rieko Yamaguchi for excellent data management.

REFERENCES

- 1 **Imamoto H**, Oba K, Sakamoto J, Iishi H, Narahara H, Yumiba T, Morimoto T, Nakamura M, Oriuchi N, Kakutani C, Morita S, Shiozaki H. Assessing clinical benefit response in the treatment of gastric malignant ascites with non-measurable lesions: a multicenter phase II trial of paclitaxel for malignant ascites secondary to advanced/recurrent gastric cancer. *Gastric Cancer* 2011; **14**: 81-90 [PMID: 21327925 DOI: 10.1007/s10120-011-0016-6]
- 2 **Jung M**, Jeung HC, Lee SS, Park JY, Hong S, Lee SH, Noh SH, Chung HC, Rha SY. The clinical significance of ascitic fluid CEA in advanced gastric cancer with ascites. *J Cancer Res Clin Oncol* 2010; **136**: 517-526 [PMID: 19774395 DOI: 10.1007/s00432-009-0684-3]
- 3 **Iwasa S**, Nakajima TE, Nakamura K, Takashima A, Kato K, Hamaguchi T, Yamada Y, Shimada Y. First-line fluorouracil-based chemotherapy for patients with severe peritoneal disseminated gastric cancer. *Gastric Cancer* 2012; **15**: 21-26 [PMID: 21573919 DOI: 10.1007/s10120-011-0056-y]
- 4 **Oriuchi N**, Nakajima T, Mochiki E, Takeyoshi I, Kanuma T, Endo K, Sakamoto J. A new, accurate and conventional five-point method for quantitative evaluation of ascites using plain computed tomography in cancer patients. *Jpn J Clin Oncol* 2005; **35**: 386-390 [PMID: 15976067 DOI: 10.1093/jjco/hyi109]
- 5 **Barni S**, Cabiddu M, Ghilardi M, Petrelli F. A novel perspective for an orphan problem: old and new drugs for the medical management of malignant ascites. *Crit Rev Oncol Hematol* 2011; **79**: 144-153 [PMID: 20708947 DOI: 10.1016/j.critrevonc.2010.07.016]
- 6 **Sakamoto J**, Matsui T, Kodera Y. Paclitaxel chemotherapy for the treatment of gastric cancer. *Gastric Cancer* 2009; **12**: 69-78 [PMID: 19562460 DOI: 10.1007/s10120-009-0505-z]
- 7 **Kitayama J**, Ishigami H, Yamaguchi H, Yamashita H, Emoto S, Kaisaki S, Watanabe T. Salvage gastrectomy after intravenous and intraperitoneal paclitaxel (PTX) administration with oral S-1 for peritoneal dissemination of advanced gastric cancer with malignant ascites. *Ann Surg Oncol* 2014; **21**: 539-546 [PMID: 23975319 DOI: 10.1245/s10434-013-3208-y]
- 8 **Yang XJ**, Li Y, Yonemura Y. Cytoreductive surgery plus hyperthermic intraperitoneal chemotherapy to treat gastric cancer with ascites and/or peritoneal carcinomatosis: Results from a Chinese center. *J Surg Oncol* 2010; **101**: 457-464 [PMID: 20401915 DOI: 10.1002/jso.21519]
- 9 **Benizri EI**, Bereder JM, Rahili A, Bernard JL, Benchimol D. Ascites and malnutrition are predictive factors for incomplete cytoreductive surgery for peritoneal carcinomatosis from gastric cancer. *Am J Surg* 2013; **205**: 668-673 [PMID: 23369310 DOI: 10.1016/j.amjsurg.2012.06.009]
- 10 **Nakajima T**, Nishi M, Kajitani T. Improvement in treatment results of gastric cancer with surgery and chemotherapy: experience of 9,700 cases in the Cancer Institute Hospital, Tokyo. *Semin Surg Oncol* 1991; **7**: 365-372 [PMID: 1759085 DOI: 10.1002/ssu.2980070608]
- 11 **Kunisaki C**, Ishino J, Nakajima S, Motohashi H, Akiyama H, Nomura M, Matsuda G, Otsuka Y, Ono HA, Shimada H. Outcomes of mass screening for gastric carcinoma. *Ann Surg Oncol* 2006; **13**: 221-228 [PMID: 16411143 DOI: 10.1245/ASO.2006.04.028]
- 12 **Nashimoto A**, Akazawa K, Isobe Y, Miyashiro I, Katai H, Kodera Y, Tsujitani S, Seto Y, Furukawa H, Oda I, Ono H, Tanabe S,

- Kaminishi M. Gastric cancer treated in 2002 in Japan: 2009 annual report of the JGCA nationwide registry. *Gastric Cancer* 2013; **16**: 1-27 [PMID: 22729699 DOI: 10.1007/s10120-012-0163-4]
- 13 **Tahara M**, Ohtsu A, Boku N, Nagashima F, Muto M, Sano Y, Yoshida M, Mera K, Hironaka S, Tajiri H, Yoshida S. Sequential methotrexate and 5-fluorouracil therapy for gastric cancer patients with peritoneal dissemination: a retrospective study. *Gastric Cancer* 2001; **4**: 212-218 [PMID: 11846065 DOI: 10.1007/s10120-001-8012-x]
 - 14 **Kitayama J**, Ishigami H, Kaisaki S, Hidemura A, Kato M, Otani K, Kamei T, Soma D, Miyato H, Yamashita H, Nagawa H. Weekly intravenous and intraperitoneal paclitaxel combined with S-1 for malignant ascites due to advanced gastric cancer. *Oncology* 2010; **78**: 40-46 [PMID: 20197706 DOI: 10.1159/000290955]
 - 15 **Lello E**, Furnes B, Edna TH. Short and long-term survival from gastric cancer. A population-based study from a county hospital during 25 years. *Acta Oncol* 2007; **46**: 308-315 [PMID: 17450465 DOI: 10.1080/02841860600996462]
 - 16 **Fang N**, Zhang HQ, He B, Xie M, Lu S, Wan YY, Wang NR. Clinicopathological characteristics and prognosis of gastric cancer with malignant ascites. *Tumour Biol* 2014; **35**: 3261-3268 [PMID: 24282088 DOI: 10.1007/s13277-013-1426-3]
 - 17 **D'Angelica M**, Gonen M, Brennan MF, Turnbull AD, Bains M, Karpeh MS. Patterns of initial recurrence in completely resected gastric adenocarcinoma. *Ann Surg* 2004; **240**: 808-816 [PMID: 15492562 DOI: 10.1097/01.sla.0000143245.28656.15]
 - 18 **Maehara Y**, Hasuda S, Koga T, Tokunaga E, Kakeji Y, Sugimachi K. Postoperative outcome and sites of recurrence in patients following curative resection of gastric cancer. *Br J Surg* 2000; **87**: 353-357 [PMID: 10718807 DOI: 10.1046/j.1365-2168.2000.01358.x]
 - 19 **Adam RA**, Adam YG. Malignant ascites: past, present, and future. *J Am Coll Surg* 2004; **198**: 999-1011 [PMID: 15194082 DOI: 10.1016/j.jamcollsurg.2004.01.035]
 - 20 **Sangisetty SL**, Miner TJ. Malignant ascites: A review of prognostic factors, pathophysiology and therapeutic measures. *World J Gastrointest Surg* 2012; **4**: 87-95 [PMID: 22590662 DOI: 10.4240/wjgs.v4.i4.87]
 - 21 **Cavazzoni E**, Bugiantella W, Graziosi L, Franceschini MS, Donini A. Malignant ascites: pathophysiology and treatment. *Int J Clin Oncol* 2013; **18**: 1-9 [PMID: 22460778 DOI: 10.1007/s10147-012-0396-6]
 - 22 **Saif MW**, Siddiqui IA, Sohail MA. Management of ascites due to gastrointestinal malignancy. *Ann Saudi Med* 2009; **29**: 369-377 [PMID: 19700895 DOI: 10.4103/0256-4947.55167]
 - 23 **Esperanca MJ**, Collins DL. Peritoneal dialysis efficiency in relation to body weight. *J Pediatr Surg* 1966; **1**: 162-169
 - 24 **Blackburn SC**, Stanton MP. Anatomy and physiology of the peritoneum. *Semin Pediatr Surg* 2014; **23**: 326-330 [PMID: 25459436 DOI: 10.1053/j.sempedsurg.2014.06.002]
 - 25 **Zebrowski BK**, Liu W, Ramirez K, Akagi Y, Mills GB, Ellis LM. Markedly elevated levels of vascular endothelial growth factor in malignant ascites. *Ann Surg Oncol* 1999; **6**: 373-378 [PMID: 10379858 DOI: 10.1007/s10434-999-0373-0]
 - 26 **Belotti D**, Paganoni P, Manenti L, Garofalo A, Marchini S, Taraboletti G, Giavazzi R. Matrix metalloproteinases (MMP9 and MMP2) induce the release of vascular endothelial growth factor (VEGF) by ovarian carcinoma cells: implications for ascites formation. *Cancer Res* 2003; **63**: 5224-5229 [PMID: 14500349]
 - 27 **Watson SA**, Morris TM, Robinson G, Crimmin MJ, Brown PD, Hardcastle JD. Inhibition of organ invasion by the matrix metalloproteinase inhibitor batimastat (BB-94) in two human colon carcinoma metastasis models. *Cancer Res* 1995; **55**: 3629-3633 [PMID: 7627972]
 - 28 **Iwasa S**, Nakajima TE, Nakamura K, Takashima A, Kato K, Hamaguchi T, Yamada Y, Shimada Y. Systemic chemotherapy for peritoneal disseminated gastric cancer with inadequate oral intake: a retrospective study. *Int J Clin Oncol* 2011; **16**: 57-62 [PMID: 20949367 DOI: 10.1007/s10147-010-0135-9]
 - 29 **Sultan J**, Robinson S, Hayes N, Griffin SM, Richardson DL, Preston SR. Endoscopic ultrasonography-detected low-volume ascites as a predictor of inoperability for oesophagogastric cancer. *Br J Surg* 2008; **95**: 1127-1130 [PMID: 18655220 DOI: 10.1002/bjs.6299]
 - 30 **Lee YT**, Ng EK, Hung LC, Chung SC, Ching JY, Chan WY, Chu WC, Sung JJ. Accuracy of endoscopic ultrasonography in diagnosing ascites and predicting peritoneal metastases in gastric cancer patients. *Gut* 2005; **54**: 1541-1545 [PMID: 15955787]
 - 31 **Yajima K**, Kanda T, Ohashi M, Wakai T, Nakagawa S, Sasamoto R, Hatakeyama K. Clinical and diagnostic significance of preoperative computed tomography findings of ascites in patients with advanced gastric cancer. *Am J Surg* 2006; **192**: 185-190 [PMID: 16860627 DOI: 10.1016/j.amjsurg.2006.05.007]
 - 32 **Cheong JC**, Choi WH, Kim DJ, Park JH, Cho SJ, Choi CS, Kim JS. Prognostic significance of computed tomography defined ascites in advanced gastric cancer. *J Korean Surg Soc* 2012; **82**: 219-226 [PMID: 22493762 DOI: 10.4174/jkss.2012.82.4.219]
 - 33 **Chang DK**, Kim JW, Kim BK, Lee KL, Song CS, Han JK, Song IS. Clinical significance of CT-defined minimal ascites in patients with gastric cancer. *World J Gastroenterol* 2005; **11**: 6587-6592 [PMID: 16425349 DOI: 10.3748/wjg.v11.i42.6587]
 - 34 **Colli A**, Prati D, Fraquelli M, Segato S, Vescovi PP, Colombo F, Balduini C, Della Valle S, Casazza G. The use of a pocket-sized ultrasound device improves physical examination: results of an in- and outpatient cohort study. *PLoS One* 2015; **10**: e0122181 [PMID: 25793296 DOI: 10.1371/journal.pone.0122181]
 - 35 **Inadomi J**, Cello JP, Koch J. Ultrasonographic determination of ascitic volume. *Hepatology* 1996; **24**: 549-551 [PMID: 8781322 DOI: 10.1002/hep.510240314]
 - 36 **Irshad A**, Ackerman SJ, Anis M, Campbell AS, Hashmi A, Baker NL. Can the smallest depth of ascitic fluid on sonograms predict the amount of drainable fluid? *J Clin Ultrasound* 2009; **37**: 440-444 [PMID: 19618437 DOI: 10.1002/jcu.20616]
 - 37 **Ishiguro T**, Kumagai Y, Baba H, Tajima Y, Imaizumi H, Suzuki O, Kuwabara K, Matsuzawa T, Sobajima J, Fukuchi M, Ishibashi K, Mochiki E, Ishida H. Predicting the amount of intraperitoneal fluid accumulation by computed tomography and its clinical use in patients with perforated peptic ulcer. *Int Surg* 2014; **99**: 824-829 [PMID: 25437594 DOI: 10.9738/INTSURG-D-14-00109.1]
 - 38 **Yamamoto T**, Shimada Y, Shirao K, Ohtsu A, Ikeda N, Hyodo I, Saito H, Iwase H, Tsuji Y, Tamura T, Yamamoto S, Yoshida S. Phase II study of sequential methotrexate and 5-fluorouracil chemotherapy against peritoneally disseminated gastric cancer with malignant ascites: a report from the Gastrointestinal Oncology Study Group of the Japan Clinical Oncology Group, JCOG 9603 Trial. *Jpn J Clin Oncol* 2004; **34**: 316-322 [PMID: 15333683 DOI: 10.1093/jjco/hyh063]
 - 39 **Badgwell B**, Krouse R, Klimberg SV, Bruera E. Outcome measures other than morbidity and mortality for patients with incurable cancer and gastrointestinal obstruction. *J Palliat Med* 2014; **17**: 18-26 [PMID: 24341323 DOI: 10.1089/jpm.2013.0240]
 - 40 **Cella DF**, Tulskey DS, Gray G, Sarafian B, Linn E, Bonomi A, Silberman M, Yellen SB, Winicour P, Brannon J. The Functional Assessment of Cancer Therapy scale: development and validation of the general measure. *J Clin Oncol* 1993; **11**: 570-579 [PMID: 8445433]
 - 41 **Sakamoto J**, Morita S, Yumiba T, Narahara H, Kinoshita K, Nakane Y, Imamoto H, Shiozaki H. A phase II clinical trial to evaluate the effect of paclitaxel in patients with ascites caused by advanced or recurrent gastric carcinoma: a new concept of clinical benefit response for non-measurable type of gastric cancer. *Jpn J Clin Oncol* 2003; **33**: 238-240 [PMID: 12865468 DOI: 10.1093/jjco/hyg048]
 - 42 **Rothenberg ML**, Moore MJ, Cripps MC, Andersen JS, Portenoy RK, Burris HA, Green MR, Tarassoff PG, Brown TD, Casper ES, Storniolo AM, Von Hoff DD. A phase II trial of gemcitabine in patients with 5-FU-refractory pancreas cancer. *Ann Oncol* 1996; **7**: 347-353 [PMID: 8805925 DOI: 10.1093/oxfordjournals.annonc.a010600]
 - 43 **Burris H**, Storniolo AM. Assessing clinical benefit in the treatment

- of pancreas cancer: gemcitabine compared to 5-fluorouracil. *Eur J Cancer* 1997; **33** Suppl 1: S18-S22 [PMID: 9166095 DOI: 10.1016/S0959-8049(96)00324-3]
- 44 **Bernhard J**, Dietrich D, Glimelius B, Bodoky G, Scheithauer W, Herrmann R. Clinical benefit response in pancreatic cancer trials revisited. *Oncol Res Treat* 2014; **37**: 42-48 [PMID: 24613908 DOI: 10.1159/000357965]
- 45 **Ajani JA**, Barthel JS, Bekaii-Saab T, Bentrem DJ, D'Amico TA, Das P, Denlinger C, Fuchs CS, Gerdes H, Hayman JA, Hazard L, Hofstetter WL, Ilson DH, Keswani RN, Kleinberg LR, Korn M, Meredith K, Mulcahy MF, Orringer MB, Osarogiagbon RU, Posey JA, Sasson AR, Scott WJ, Shibata S, Strong VE, Washington MK, Willett C, Wood DE, Wright CD, Yang G. Gastric cancer. *J Natl Compr Canc Netw* 2010; **8**: 378-409 [PMID: 20410333]
- 46 **Waddell T**, Verheij M, Allum W, Cunningham D, Cervantes A, Arnold D. Gastric cancer: ESMO-ESSO-ESTRO clinical practice guidelines for diagnosis, treatment and follow-up. *Eur J Surg Oncol* 2014; **40**: 584-591 [PMID: 24685156 DOI: 10.1016/j.ejso.2013.09.020]
- 47 **Japanese Gastric Cancer Association**. Japanese gastric cancer treatment guidelines 2010 (ver. 3). *Gastric Cancer* 2011; **14**: 113-123 [PMID: 21573742 DOI: 10.1007/s10120-011-0042-4]
- 48 **Kobayashi M**, Sakamoto J, Namikawa T, Okamoto K, Okabayashi T, Ichikawa K, Araki K. Pharmacokinetic study of paclitaxel in malignant ascites from advanced gastric cancer patients. *World J Gastroenterol* 2006; **12**: 1412-1415 [PMID: 16552811 DOI: 10.3748/wjg.v12.i9.1412]
- 49 **Kobayashi M**, Oba K, Sakamoto J, Kondo K, Nagata N, Okabayashi T, Namikawa T, Hanazaki K. Pharmacokinetic study of weekly administration dose of paclitaxel in patients with advanced or recurrent gastric cancer in Japan. *Gastric Cancer* 2007; **10**: 52-57 [PMID: 17334719 DOI: 10.1007/s10120-006-0411-6]
- 50 **Kadokura M**, Iwasa S, Honma Y, Kato K, Hamaguchi T, Yamada Y, Enomoto N, Shimada Y. Weekly paclitaxel as second-line chemotherapy in Japanese patients with advanced gastric cancer. *Anticancer Res* 2013; **33**: 4547-4552 [PMID: 24123029]
- 51 **Hironaka S**, Zenda S, Boku N, Fukutomi A, Yoshino T, Onozawa Y. Weekly paclitaxel as second-line chemotherapy for advanced or recurrent gastric cancer. *Gastric Cancer* 2006; **9**: 14-18 [PMID: 16557431 DOI: 10.1007/s10120-005-0351-6]
- 52 **Shimoyama R**, Yasui H, Boku N, Onozawa Y, Hironaka S, Fukutomi A, Yamazaki K, Taku K, Kojima T, Machida N, Todaka A, Tomita H, Sakamoto T, Tsushima T. Weekly paclitaxel for heavily treated advanced or recurrent gastric cancer refractory to fluorouracil, irinotecan, and cisplatin. *Gastric Cancer* 2009; **12**: 206-211 [PMID: 20047125 DOI: 10.1007/s10120-009-0524-9]
- 53 **Tamegai H**, Kaiga T, Kochi M, Fujii M, Kanamori N, Mihara Y, Funada T, Shimizu H, Jinno D, Takayama T. Pharmacokinetics of docetaxel in gastric cancer patients with malignant ascites. *Cancer Chemother Pharmacol* 2013; **71**: 727-731 [PMID: 23314679 DOI: 10.1007/s00280-012-2066-9]
- 54 **Abbrederis K**, Lorenzen S, von Weikersthal LF, Vehling-Kaiser U, Schuster T, Rothling N, Peschel C, Lordick F. Weekly docetaxel monotherapy for advanced gastric or esophagogastric junction cancer. Results of a phase II study in elderly patients or patients with impaired performance status. *Crit Rev Oncol Hematol* 2008; **66**: 84-90 [PMID: 18243012 DOI: 10.1016/j.critrevonc.2007.12.001]
- 55 **Nishikawa K**, Iwase K, Aono T, Yoshida H, Nomura M, Tamagawa H, Matsuda C, Deguchi T, Kawada J, Higashi S, Deguchi K, Noguchi Y, Okumura Y, Nomura M, Fushimi H, Takagi M, Fukui A, Fujitani K, Endo S, Tanaka Y. [A case of paclitaxel-resistant recurrent gastric cancer responsive to S-1 plus docetaxel]. *Gan To Kagaku Ryoho* 2013; **40**: 2259-2261 [PMID: 24394078]
- 56 **Kimura Y**, Imasato M, Yano H, Taniguchi H, Danno K, Kanoh T, Ohnishi T, Tono T, Nakano Y, Monden T, Imaoka S. Paclitaxel-resistant recurrent gastric cancer responsive to docetaxel: a case report. *Gan To Kagaku Ryoho* 2011; **38**: 643-645 [PMID: 21498996]
- 57 **Gligorov J**, Lotz JP. Preclinical pharmacology of the taxanes: implications of the differences. *Oncologist* 2004; **9** Suppl 2: 3-8 [PMID: 15161985 DOI: 10.1634/theoncologist.9-suppl_2-3]
- 58 **Takeyoshi I**, Makita F, Iwazaki S, Ishikawa H, Kakinuma S, Sato Y, Ohya T, Nakagami K, Tomizawa N, Izumi M, Kobayashi I, Tanahashi Y, Kobayashi J, Kamoshita N, Kawate S, Sunose Y, Sakamoto I, Yoshinari D, Yamada T, Okabe T. Weekly paclitaxel in combination with doxifluridine for peritoneally disseminated gastric cancer with malignant ascites. *Anticancer Res* 2011; **31**: 4625-4630 [PMID: 22199340]
- 59 **Iwasa S**, Goto M, Yasui H, Nishina T, Takahari D, Nakayama N, Taira K, Kusaba H, Fuse N, Hironaka S, Shimada Y, Nakajima TE. Multicenter feasibility study of combination therapy with fluorouracil, leucovorin and paclitaxel (FLTAX) for peritoneal disseminated gastric cancer with massive ascites or inadequate oral intake. *Jpn J Clin Oncol* 2012; **42**: 787-793 [PMID: 22782960 DOI: 10.1093/jjco/hys111]
- 60 **Oh SY**, Kwon HC, Lee S, Lee DM, Yoo HS, Kim SH, Jang JS, Kim MC, Jeong JS, Kim HJ. A Phase II study of oxaliplatin with low-dose leucovorin and bolus and continuous infusion 5-fluorouracil (modified FOLFOX-4) for gastric cancer patients with malignant ascites. *Jpn J Clin Oncol* 2007; **37**: 930-935 [PMID: 18211984 DOI: 10.1093/jjco/hym131]
- 61 **Imazawa M**, Kojima T, Boku N, Onozawa Y, Hironaka S, Fukutomi A, Yasui H, Yamazaki K, Taku K. Efficacy of sequential methotrexate and 5-fluorouracil (MTX/5FU) in improving oral intake in patients with advanced gastric cancer with severe peritoneal dissemination. *Gastric Cancer* 2009; **12**: 153-157 [PMID: 19890695 DOI: 10.1007/s10120-009-0517-8]
- 62 **Nakayama N**, Koizumi W, Tanabe S, Sasaki T, Saigenji K. A phase II study of combined chemotherapy with methotrexate, 5-fluorouracil, and low-dose cisplatin (MFP) for histologically diffuse-type advanced and recurrent gastric cancer (KDOG9501). *Gastric Cancer* 2006; **9**: 185-191 [PMID: 16952036 DOI: 10.1007/s10120-006-0371-x]
- 63 **Shirao K**, Boku N, Yamada Y, Yamaguchi K, Doi T, Goto M, Nasu J, Denda T, Hamamoto Y, Takashima A, Fukuda H, Ohtsu A. Randomized Phase III study of 5-fluorouracil continuous infusion vs. sequential methotrexate and 5-fluorouracil therapy in far advanced gastric cancer with peritoneal metastasis (JCOG0106). *Jpn J Clin Oncol* 2013; **43**: 972-980 [PMID: 24014884 DOI: 10.1093/jjco/hyt114]
- 64 **Los G**, Mutsaers PH, van der Vijgh WJ, Baldew GS, de Graaf PW, McVie JG. Direct diffusion of cis-diamminedichloroplatinum(II) in intraperitoneal rat tumors after intraperitoneal chemotherapy: a comparison with systemic chemotherapy. *Cancer Res* 1989; **49**: 3380-3384 [PMID: 2720692]
- 65 **Sautner T**, Hofbauer F, Depisch D, Schiessel R, Jakesz R. Adjuvant intraperitoneal cisplatin chemotherapy does not improve long-term survival after surgery for advanced gastric cancer. *J Clin Oncol* 1994; **12**: 970-974 [PMID: 8164049]
- 66 **Kodera Y**, Imano M, Yoshikawa T, Takahashi N, Tsuburaya A, Miyashita Y, Morita S, Nakao A, Sakamoto J, Sasako M. A randomized phase II trial to test the efficacy of intra-peritoneal paclitaxel for gastric cancer with high risk for the peritoneal metastasis (INPACT trial). *Jpn J Clin Oncol* 2011; **41**: 283-286 [PMID: 20947926 DOI: 10.1093/jjco/hyq187]
- 67 **Coccolini F**, Cotte E, Glehen O, Lotti M, Poiasina E, Catena F, Yonemura Y, Ansaloni L. Intraperitoneal chemotherapy in advanced gastric cancer. Meta-analysis of randomized trials. *Eur J Surg Oncol* 2014; **40**: 12-26 [PMID: 24290371 DOI: 10.1016/j.ejso.2013.10.019]
- 68 **Yonemura Y**, Kawamura T, Bandou E, Takahashi S, Sawa T, Matsuki N. Treatment of peritoneal dissemination from gastric cancer by peritonectomy and chemohyperthermic peritoneal perfusion. *Br J Surg* 2005; **92**: 370-375 [PMID: 15739249 DOI: 10.1002/bjs.4695]
- 69 **Garofalo A**, Valle M, Garcia J, Sugarbaker PH. Laparoscopic intraperitoneal hyperthermic chemotherapy for palliation of debilitating malignant ascites. *Eur J Surg Oncol* 2006; **32**: 682-685 [PMID: 16631341 DOI: 10.1016/j.ejso.2006.03.014]

- 70 **Facchiano E**, Scaringi S, Kianmanesh R, Sabate JM, Castel B, Flamant Y, Coffin B, Msika S. Laparoscopic hyperthermic intraperitoneal chemotherapy (HIPEC) for the treatment of malignant ascites secondary to unresectable peritoneal carcinomatosis from advanced gastric cancer. *Eur J Surg Oncol* 2008; **34**: 154-158 [PMID: 17640844 DOI: 10.1016/j.ejso.2007.05.015]
- 71 **Ba MC**, Cui SZ, Lin SQ, Tang YQ, Wu YB, Wang B, Zhang XL. Chemotherapy with laparoscope-assisted continuous circulatory hyperthermic intraperitoneal perfusion for malignant ascites. *World J Gastroenterol* 2010; **16**: 1901-1907 [PMID: 20397270 DOI: 10.3748/wjg.v16.i15.1901]
- 72 **Shen L**, Li J, Xu J, Pan H, Dai G, Qin S, Wang L, Wang J, Yang Z, Shu Y, Xu R, Chen L, Liu Y, Yu S, Bu L, Piao Y. Bevacizumab plus capecitabine and cisplatin in Chinese patients with inoperable locally advanced or metastatic gastric or gastroesophageal junction cancer: randomized, double-blind, phase III study (AVATAR study). *Gastric Cancer* 2015; **18**: 168-176 [PMID: 24557418 DOI: 10.1007/s10120-014-0351-5]
- 73 **Richards D**, Kocs DM, Spira AI, David McCollum A, Diab S, Hecker LI, Cohn A, Zhan F, Asmar L. Results of docetaxel plus oxaliplatin (DOCOX) ± cetuximab in patients with metastatic gastric and/or gastroesophageal junction adenocarcinoma: results of a randomised Phase 2 study. *Eur J Cancer* 2013; **49**: 2823-2831 [PMID: 23747051 DOI: 10.1016/j.ejca.2013.04.022]
- 74 **Lordick F**, Kang YK, Chung HC, Salman P, Oh SC, Bodoky G, Kurteva G, Volovat C, Moiseyenko VM, Gorbunova V, Park JO, Sawaki A, Celik I, Götte H, Melezinková H, Moehler M. Capecitabine and cisplatin with or without cetuximab for patients with previously untreated advanced gastric cancer (EXPAND): a randomised, open-label phase 3 trial. *Lancet Oncol* 2013; **14**: 490-499 [PMID: 23594786 DOI: 10.1016/S1470-2045(13)70102-5]
- 75 **Waddell T**, Chau I, Cunningham D, Gonzalez D, Okines AF, Okines C, Wotherspoon A, Saffery C, Middleton G, Wadsley J, Ferry D, Mansoor W, Crosby T, Coxon F, Smith D, Waters J, Iveson T, Falk S, Slater S, Peckitt C, Barbachano Y. Epirubicin, oxaliplatin, and capecitabine with or without panitumumab for patients with previously untreated advanced oesophagogastric cancer (REAL3): a randomised, open-label phase 3 trial. *Lancet Oncol* 2013; **14**: 481-489 [PMID: 23594787 DOI: 10.1016/S1470-2045(13)70096-2]
- 76 **Ohtsu A**, Ajani JA, Bai YX, Bang YJ, Chung HC, Pan HM, Sahmoud T, Shen L, Yeh KH, Chin K, Muro K, Kim YH, Ferry D, Tebbutt NC, Al-Batran SE, Smith H, Costantini C, Rizvi S, Lebwohl D, Van Cutsem E. Everolimus for previously treated advanced gastric cancer: results of the randomized, double-blind, phase III GRANITE-1 study. *J Clin Oncol* 2013; **31**: 3935-3943 [PMID: 24043745 DOI: 10.1200/JCO.2012.48.3552]
- 77 **Bang YJ**, Van Cutsem E, Feyereislova A, Chung HC, Shen L, Sawaki A, Lordick F, Ohtsu A, Omuro Y, Satoh T, Aprile G, Kulikov E, Hill J, Lehle M, Rüschoff J, Kang YK. Trastuzumab in combination with chemotherapy versus chemotherapy alone for treatment of HER2-positive advanced gastric or gastro-oesophageal junction cancer (ToGA): a phase 3, open-label, randomised controlled trial. *Lancet* 2010; **376**: 687-697 [PMID: 20728210 DOI: 10.1016/S0140-6736(10)61121-X]
- 78 **Kurokawa Y**, Sugimoto N, Miwa H, Tsuda M, Nishina S, Okuda H, Imamura H, Gamoh M, Sakai D, Shimokawa T, Komatsu Y, Doki Y, Tsujinaka T, Furukawa H. Phase II study of trastuzumab in combination with S-1 plus cisplatin in HER2-positive gastric cancer (HERBIS-1). *Br J Cancer* 2014; **110**: 1163-1168 [PMID: 24473399 DOI: 10.1038/bjc.2014.18]
- 79 **Heiss MM**, Murawa P, Koralewski P, Kutarska E, Kolesnik OO, Ivanchenko VV, Dudnichenko AS, Aleknaviciene B, Razbadauskas A, Gore M, Ganea-Motan E, Ciuleanu T, Wimberger P, Schmittl A, Schmalfeldt B, Burges A, Bokemeyer C, Lindhofer H, Lahr A, Parsons SL. The trifunctional antibody catumaxomab for the treatment of malignant ascites due to epithelial cancer: Results of a prospective randomized phase II/III trial. *Int J Cancer* 2010; **127**: 2209-2221 [PMID: 20473913 DOI: 10.1002/ijc.25423]
- 80 **Wimberger P**, Gilet H, Gonschior AK, Heiss MM, Moehler M, Oskay-Oezcelik G, Al-Batran SE, Schmalfeldt B, Schmittl A, Schulze E, Parsons SL. Deterioration in quality of life (QoL) in patients with malignant ascites: results from a phase II/III study comparing paracentesis plus catumaxomab with paracentesis alone. *Ann Oncol* 2012; **23**: 1979-1985 [PMID: 22734013 DOI: 10.1093/annonc/mds178]

P- Reviewer: Ierardi E S- Editor: Ma YJ L- Editor: A
E- Editor: Ma S





Published by **Baishideng Publishing Group Inc**

8226 Regency Drive, Pleasanton, CA 94588, USA

Telephone: +1-925-223-8242

Fax: +1-925-223-8243

E-mail: bpgoffice@wjgnet.com

Help Desk: <http://www.wjgnet.com/esps/helpdesk.aspx>

<http://www.wjgnet.com>



ISSN 1007-9327

