

Endoscopic options for treatment of dysplasia in Barrett's esophagus

R Brooks Vance, Kerry B Dunbar

R Brooks Vance, Kerry B Dunbar, VA North Texas Healthcare System, Dallas VA Medical Center, University of Texas Southwestern Medical Center, Dallas, TX 75231, United States

Author contributions: Both Vance RB and Dunbar KB provided substantial contributions to conception and design, acquisition of data, as well as the drafting the article or revising it critically for important intellectual content, and gave final approval of the version to be published.

Conflict-of-interest statement: Dr. R Brooks Vance and Dr. Kerry B Dunbar have no conflicts of interest to report.

Open-Access: This article is an open-access article which was selected by an in-house editor and fully peer-reviewed by external reviewers. It is distributed in accordance with the Creative Commons Attribution Non Commercial (CC BY-NC 4.0) license, which permits others to distribute, remix, adapt, build upon this work non-commercially, and license their derivative works on different terms, provided the original work is properly cited and the use is non-commercial. See: <http://creativecommons.org/licenses/by-nc/4.0/>

Correspondence to: Kerry B Dunbar, MD, PhD, Associate Professor of Medicine, VA North Texas Healthcare System, Dallas VA Medical Center, University of Texas Southwestern Medical Center, 4500 South Lancaster Road, GI Lab CA 111-B1, Dallas, TX 75231, United States. kerry.dunbar@utsouthwestern.edu
Telephone: +1-214-8571603
Fax: +1-214-8571571

Received: April 28, 2015

Peer-review started: May 5, 2015

First decision: September 8, 2015

Revised: September 17, 2015

Accepted: November 10, 2015

Article in press: November 11, 2015

Published online: December 25, 2015

Abstract

Recent advances in the endoscopic treatment of dysplasia

in Barrett's esophagus (BE) have allowed endoscopists to provide effective and durable eradication therapies. This review summarizes the available endoscopic eradication techniques for dysplasia in patients with BE including endoscopic mucosal resection, endoscopic submucosal dissection, photodynamic therapy, argon plasma coagulation, radiofrequency ablation and cryotherapy.

Key words: Dysplasia; Barrett's esophagus; Endoscopic therapy; Endoscopic mucosal resection; Radiofrequency ablation; Endoscopy; Photodynamic therapy

© **The Author(s) 2015.** Published by Baishideng Publishing Group Inc. All rights reserved.

Core tip: Endoscopic treatment of high-grade dysplasia in Barrett's esophagus (BE) has become the standard of care for patients with this premalignant condition. In this review, we highlight the efficacy, durability and safety of the available endoscopic therapies for BE with high-grade dysplasia.

Vance RB, Dunbar KB. Endoscopic options for treatment of dysplasia in Barrett's esophagus. *World J Gastrointest Endosc* 2015; 7(19): 1311-1317 Available from: URL: <http://www.wjgnet.com/1948-5190/full/v7/i19/1311.htm> DOI: <http://dx.doi.org/10.4253/wjge.v7.i19.1311>

INTRODUCTION

Barrett's esophagus (BE) is defined by the "American Gastroenterological Association" (AGA) as "a condition in which any extent of metaplastic columnar epithelium that predisposes to cancer development replaces the stratified squamous epithelium that normally lines the distal esophagus", (Figure 1)^[1]. The existence of intestinal metaplasia (IM) in the esophagus predisposes to development of esophageal adenocarcinoma and BE

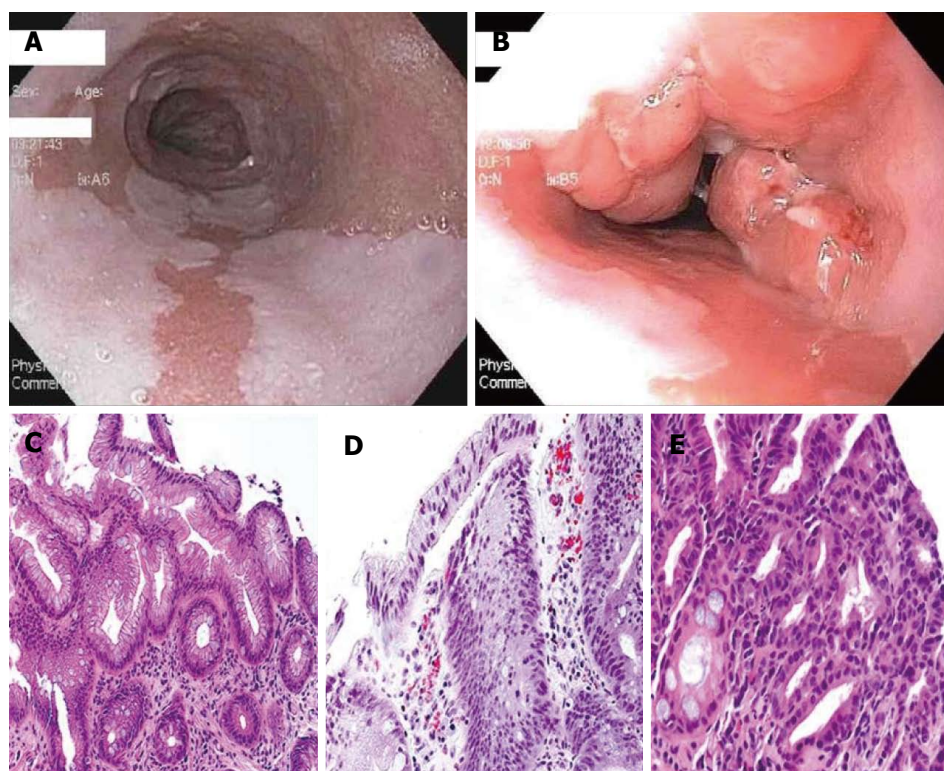


Figure 1 Histopathology pictures. A: White-light endoscopic image of long segment BE; B: White-light endoscopic image of BE with nodular mucosa found to be HGD; C: Hematoxylin and eosin (HE) stain of Barrett's mucosa; D: HE of Barrett's mucosa with LGD; E: Barrett's mucosa with HGD. Histopathology pictures courtesy of Purva Gopal, MD, Department of Pathology, University of Texas Southwestern Medical Center, Dallas, Texas. HGD: High-grade dysplasia; LGD: Low-grade dysplasia; BE: Barrett's esophagus.

has become a well-recognized and treatable condition. The estimates of progression of non-dysplastic BE to adenocarcinoma are variable but uniformly low, ranging from 0.12% to as high as 2.9% per year, with more recent studies reporting lower rates of progression, generally less than 0.5% per year^[2,3]. However, the incidence of progression to adenocarcinoma in patients with BE with dysplasia is up to five times as high as in non-dysplastic BE^[2]. The presence of high-grade dysplasia (HGD, Figure 1) in BE portends a significant risk of progression to adenocarcinoma, calculated to be up to a 6% annual risk in one meta-analysis^[3].

The need for non-invasive strategies to treat dysplasia in patients with BE has become an impetus for gastrointestinal endoscopists to develop new and effective endoscopic techniques. In this paper, we review the different options for treatment of dysplasia in BE, with a focus on endoscopic treatment of HGD.

SURGICAL TREATMENTS

In the past, the gold standard of therapy for HGD was esophagectomy, a procedure with well-recognized morbidity and perioperative mortality as high as 10%^[4,5]. More recently, laparoscopic approaches and techniques such as the transhiatal esophagectomy have become more common. These techniques have lower morbidity than some of the older surgical techniques, including reduced hospital length of stay, fewer major complications,

and less post-operative dumping syndrome^[6,7]. Surgical therapy is a valid curative option for patients in whom there is suspicion of cancer invading the submucosa or if lymph node metastases are present. In patients with early esophageal adenocarcinoma, up to 20% of patients with cancer involving the submucosa will have lymph node metastases, with the risk increasing further with growth of the tumor into the deeper submucosa. In contrast, the risk of lymph node metastases in patients with intramucosal adenocarcinoma (*i.e.*, not invading the submucosa) is much lower at less than 2%^[8].

While endoscopic therapy of HGD has become increasingly common, esophagectomy is still an option for patients. The AGA and American Society of Gastrointestinal Endoscopists (ASGE) still acknowledge esophagectomy as a therapeutic option in appropriate patients with BE and HGD, while the American College of Gastroenterology (ACG) guidelines on BE state that esophagectomy is no longer the necessary treatment response to HGD^[1,9,10].

ENDOSCOPIC TREATMENTS

For patients with HGD limited to the esophageal mucosa, endoscopic eradication has become the mainstay of therapy. Multiple modalities compatible with endoscopy have been studied including both mechanical removal of tissue and ablative techniques. Methods that involve tissue resection include endoscopic mucosal resection (EMR) and endoscopic submucosal dissection (ESD).

The ablative techniques include several older techniques such as photodynamic therapy (PDT), laser therapy with Nd:YAG (neodymium-doped yttrium aluminum garnet; Nd:Y₃Al₅O₁₂) or potassium titanyl phosphate (KTP) lasers, multipolar electrocoagulation (MPEC), argon plasma coagulation (APC), and newer techniques such as cryotherapy and radiofrequency ablation (RFA). These therapies are tailored to the type of HGD present, specifically whether the dysplasia is visible, raised, discolored or nodular; features which have been associated with higher rates of malignancy compared to flat mucosa^[11]. It is important to note that all the endoscopic treatments described below require acid suppression therapy for success, namely proton pump inhibitor (PPI) therapy.

EMR AND ESD

EMR, initially developed in Japan for treatment of superficial squamous cell esophageal carcinoma, is now the treatment of choice for nodular HGD in the esophagus^[12]. It is also considered helpful diagnostic tool to evaluate for adenocarcinoma invading the submucosa, as well as to determine whether mucosal nodules harbor dysplasia. EMR is useful in staging, as illustrated by Wani *et al.*^[13]'s study which found that in patients with BE and dysplasia or early cancer, EMR resulted in upstaging of the diagnosis in 10% of patients and downgrading of the diagnosis in 21%. The two main EMR techniques are use of an endoscopic resection cap (ER-cap) (Olympus, Tokyo, Japan), which varies in terms of shape and texture and a multi-band ligator (Wilson-Cook, Indianapolis, United States) used for multiband mucosectomy (MBM). A diathermic snare is used for resection in both techniques. A submucosal lift with saline or a more viscous solution such as hydroxypropyl methylcellulose (artificial tears) can also be employed prior to resection when using the ER-cap method and is sometimes used with MBM. Pouw *et al.*^[14] performed a randomized controlled trial comparing of ER-cap and MBM and found that MBM was less costly and resulted in fewer acute complications without any significant difference in the depth of tissue resected.

EMR has been shown to be safe and effective as monotherapy for eradication of HGD in several studies. The reported rates of remission from HGD after EMR range from 87%-96% with median follow-up of 22-28 mo^[15-17]. The long term remission rate and the durability of EMR as a solo modality for treatment are not currently known; therefore, these patients should be maintained in a surveillance endoscopy program. Complications of EMR include bleeding, perforation, and most commonly stricture formation. The frequency of stricture development reported in EMR studies varies widely, from 12.5% to 88%, depending on the extent of EMR and number of sessions^[15-17]. For the majority of patients, post-EMR strictures are easily treated with endoscopic dilation techniques. In general, the smaller the area of resection, the lower the likelihood of stricture formation^[17].

ESD is a safe and effective therapy for early gastric cancers and large dysplastic colon polyps^[18,19]. Technically, the procedure differs from EMR in that a specialized ESD knife is used to access the submucosal space and dissect the superficial lesion away from the submucosa. As with EMR, a cushion of fluid is first injected to lift the lesion of interest and protect the esophageal wall from deeper penetration of the ESD knife. This fluid typically contains a viscous agent to allow for a sustained lift and a dye to help identify tissue planes for appropriate dissection^[20]. The rationale for using ESD is that this technique can allow for a larger and more precise area of dysplastic tissue removal than EMR can safely target.

ESD has recently been evaluated in the management of BE with HGD and early adenocarcinoma. A German group reported a 77% curative resection rate in a small group of patients with a recurrence rate of 5.9% in two years follow-up. The complication rate was 27% for this group of patients and included one perforation and three strictures^[21]. A retrospective analysis of 70 Belgian patients who underwent ESD reported a curative resection rate of 64% for patients with HGD and 85% for patients with early adenocarcinoma. At a median follow-up of 20 mo, 92% of patients retained remission from neoplasia. Strictures formed in 60% of patients and these were managed endoscopically^[22]. The technique of ESD requires specific training and is only safe in qualified hands in high volume centers. At this time, the ASGE is the only major United States GI society that recognizes ESD as a potential treatment for visible HGD^[10].

PDT

PDT is a technique for endoscopic ablation using either 5-aminolevulinic acid or porfimer sodium as a photosensitizing agent followed by exposure to laser light, which causes a photochemical reaction, damaging both mucosal and deeper tissues. The largest study of PDT was a randomized clinical trial evaluating PDT plus omeprazole vs omeprazole alone, which showed that patients treated with PDT had a HGD eradication rate of 77% compared to 39% in the omeprazole-alone group. With 5-year follow-up 15% of patients treated with PDT had progressed to cancer, compared to 29% in the omeprazole group^[23]. In one longer-term follow-up study of 66 patients with HGD and early adenocarcinoma who underwent PDT, in the calculated 5-year survival was 97% in patients with HGD and 80% in those with early adenocarcinoma without significant long-term complications^[24]. Currently, all three major United States societies mention PDT as an option for ablating HGD in BE^[1,9,10].

LASER THERAPIES

Nd:YAG and KTP laser-derived thermal therapies have also been evaluated as a treatment tool for HGD in BE. Both Nd:YAG and KTP are crystals that when used in lasers produce wavelengths of light that can damage

tissue, such as dysplastic BE. These lasers have typically been studied in tandem with one another or combined with another mode of therapy. Sharma *et al.*^[25] reported a series of seven patients with BE and HGD who were not surgical candidates who underwent combination therapy with Nd:YAG laser and monopolar electrocautery. The dysplasia was eradicated in all seven with only residual metaplasia in three patients over a mean follow-up of 3.4 years. Nd:YAG-enhanced KTP laser was also shown to be safe and effective in pilot study of 10 patients with 100% eradication of dysplasia on follow-up esophageal biopsies and no recurrence on average follow-up of 10 mo^[26]. Laser treatment is rarely used at this time as other therapies have become more popular.

APC AND MULTIPOLAR ELECTROCOAGULATION

APC is another form of endoscopic thermal therapy using the medium of argon gas to conduct electrical current leading to tissue destruction. The therapy is performed *via* a catheter that fits through the endoscope working channel. MPEC utilizes electrical current through an endoscopic catheter to cause localized tissue destruction. One prospective trial compared APC and MPEC for treatment of dysplastic BE and found no statistical difference in either endoscopic or histologic eradication of dysplasia^[27]. However, MPEC required significantly fewer endoscopic therapy sessions with a trend toward better histologic eradication. There were no serious adverse events but 8% of patients treated with MPEC and 13% of patients treated with APC experienced transient upper GI symptoms. While APC is not typically used as a solo modality for treatment of BE and dysplasia, APC can be used to treat small areas of residual BE. In one study of patient with BE and HGD who underwent mucosectomy, treatment of residual disease with APC was found to prolong recurrence-free survival^[28].

CRYOTHERAPY

The goal of this endoscopic therapy is to use freeze-thaw cycles for the destruction of tissue. Cryotherapy is performed using low-pressure liquid nitrogen (CSA Medical, Maryland, United States) or carbon dioxide (GI Supply, Pennsylvania, United States) delivered *via* spray catheter. One of the earlier prospective studies of cryotherapy found a 94% eradication rate for HGD with complications including chest pain and dysphagia, as well as one gastric perforation^[29]. Recently, a prospective cohort study of 96 patients (two-thirds of whom had HGD) underwent cryotherapy, resulting in a complete eradication rate of 81% for HGD. Only three patients developed a stricture in the 37 mo of follow-up^[30]. The durability of cryotherapy in preventing disease recurrence has come into question. Halsey *et al.*^[31] published data suggesting that up to 30% of patients treated with cryotherapy experienced disease recurrence at a median

of 6.5 mo, and 10% had a second recurrence. However, a more recent single center retrospective cohort reported a HGD eradication rate of 100% with sustained remission in 97% of patients with previous HGD over a range of 24-57 mo^[32]. At this time, only in the ASGE guidelines is cryotherapy specifically mentioned as a treatment option for dysplasia in BE^[10].

RFA

RFA has emerged as the ablative technique of choice for BE with HGD because of the quality of evidence to support the ease of its administration, its efficacy, and safety profile. The procedure involves the direct application of radiofrequency energy to the esophageal mucosa, using either a balloon for circumferential treatment and more focal treatment through an attachment to the end of the endoscope or a small catheter that can pass through the working channel (Barxx/Covidien, Dublin, Ireland). With these tools, RFA can be applied to the mucosa circumferentially or focally. In the landmark multicenter sham-controlled randomized controlled trial by Shaheen *et al.*^[33], RFA resulted in eradication of dysplasia in 81% of patients with HGD. The treatment also decreased the progression of dysplasia to cancer. Complications were rare in this study, with only a 6% rate of stricture formation over 12 mo of follow-up^[33]. RFA has also been shown to be successful in eradicating persistent dysplasia after initial therapy with PDT. In one study, RFA used as rescue therapy after PDT treatment successfully eradicated residual HGD in 86% of patients^[34].

For some patients with BE, multiple endoscopic therapies are required for treatment. RFA is most effective on smooth BE mucosa, and is not adequate treatment for nodular dysplasia. As a result, endoscopists have been combining endoscopic eradication therapies, most commonly EMR and RFA. With combination therapy, visible or nodular dysplasia can be precisely removed with EMR, and any residual dysplasia or metaplasia can be systematically treated with RFA, typically performed after the EMR site has healed. One retrospective study of combination therapy reported an 86% complete eradication rate of HGD, but complete eradication of only 62% of nondysplastic intestinal metaplasia^[35]. More recently, a multicenter prospective trial in Europe (EURO II) evaluated the efficacy and safety of such a treatment strategy. EMR was performed on visible abnormalities within the BE segment and the remaining visible Barrett's mucosa was treated with RFA 6 wk later. Patients underwent a median of two RFA sessions. This combination of procedures achieved a 92% complete eradication rate for HGD and neoplasia and complete eradication of intestinal metaplasia in 87% of patients. At 36 mo of follow-up, only 4% of patients had recurrence of neoplasia. There were no major complications from the procedures and the rate of esophageal stenosis rate was 6%^[36].

The existing evidence for treatment of low-grade dysplasia (LGD, Figure 1) in BE (most often with RFA) is

less abundant than studies of patients with BE and HGD. However, a recent randomized clinical trial (the SURF trial) showed a significantly lower rate of progression of LGD to either HGD or adenocarcinoma over three years after RFA^[37]. Complicating the decision to ablate LGD is the fact that there is significant disagreement between pathologists on the definition of LGD. Several studies have highlighted the discrepancy in pathologist interobserver agreement when evaluating specimens with LGD. In one such study, expert pathologist confirmed only 15% of previously diagnosed LGD^[38]. The AGA recommends RFA as therapy for BE with LGD based on high quality evidence while the ASGE dictates that RFA should be considered as therapy for LGD, and ACG acknowledges the effectiveness of RFA for LGD^[1,9,10].

RISK OF RECURRENCE AFTER ENDOSCOPIC THERAPY

Recurrence after endoscopic therapy is a concern for gastroenterologists treating patients with dysplastic BE and the rates of recurrence vary widely depending on the study. Gupta *et al*^[39] noted that IM returned in up to 33% of patients at 2 years after endoscopic therapy including RFA. A smaller percentage of recurrent IM was dysplastic (22%). The investigators were unable to identify any predictors for recurrence in this particular population of patients^[39]. Other groups have tried to define predictors for recurrence of IM after definitive ablative therapy. In one recent large retrospective analysis, researchers found a slightly lower recurrence rate of 20% at 2.4 years for either IM or dysplasia. These investigators were able to identify risk factors for recurrence of BE and neoplasia, which included a worse pre-treatment histology, older age, and longer BE segments^[40]. A single-center retrospective analysis of patients who achieved complete eradication of both IM and dysplasia with RFA found the one-year recurrence rate of IM to be 25% while dysplasia recurred in 8.5% of patients^[41]. In contrast, a systematic review and meta-analysis of prospective and retrospective studies of RFA found that recurrence of dysplasia and IM was much lower after RFA treatment, with a 0.9% pooled recurrence rate for dysplasia and a 13% rate of recurrence for IM with an average follow-up of 1.5 years. There was wide range of IM recurrence rates reported in this study, ranging from 8% to 21%^[42].

ENDOSCOPIC THERAPY OF NON-DYSPLASTIC BE

The debate rages on in the world of BE whether ablation of non-dysplastic Barrett's esophagus (NDBE) should be performed. Endoscopists advocating ablation of NDBE extrapolate the success of RFA in patients with HGD and LGD, applying these findings to non-dysplastic metaplasia. Another argument favoring ablation of NDBE is the lack of randomized controlled trials showing that

surveillance of BE reduces mortality from esophageal adenocarcinoma, and thus other interventions should be considered^[43,44]. Endoscopists who argue against ablation of NDBE focus on the lack of high quality evidence available to support such a notion and the very low rates of progression to cancer reported for non-dysplastic BE. Other issues proposed in the argument against ablation of nondysplastic BE include issues related to subjecting large numbers of patients to multiple endoscopic procedures, and the associated costs of the procedures and risk of complications^[45]. One other argument against ablation of non-dysplastic BE is the possibility of missing subtle nodularity or mucosal changes that would be optimally treated with EMR, and instead burying it with suboptimal RFA therapy^[45,46]. More prospective randomized controlled trials are needed to study the utility of RFA and other endoscopic therapies to treat NDBE. The AGA and ASGE mention that RFA could be considered for selected patients with NDBE thought to be at increased risk of progression to HGD and cancer^[1,10].

CONCLUSION

The treatment options for HGD in BE have evolved into less-invasive therapies. There are now highly effective endoscopic therapies that are less morbid than esophagectomy. Most patients are treated with a combination of endoscopic resection and RFA with good outcomes. However, it is the job of the gastrointestinal endoscopist to be vigilant in surveillance for possible dysplasia recurrence in these patients. We have not yet reached the point where a patient can be told he or she has experienced complete eradication with no possibility of recurrence, and all patients should remain in surveillance. Until that time comes, we will continue to sharpen the endoscopic tools that will help us along the way to a durable cure.

REFERENCES

- 1 **Spechler SJ**, Sharma P, Souza RF, Inadomi JM, Shaheen NJ. American Gastroenterological Association medical position statement on the management of Barrett's esophagus. *Gastroenterology* 2011; **140**: 1084-1091 [PMID: 21376940 DOI: 10.1053/j.gastro.2011.01.030]
- 2 **Hvid-Jensen F**, Pedersen L, Drewes AM, Sørensen HT, Funch-Jensen P. Incidence of adenocarcinoma among patients with Barrett's esophagus. *N Engl J Med* 2011; **365**: 1375-1383 [PMID: 21995385 DOI: 10.1056/NEJMoa1103042]
- 3 **Rastogi A**, Puli S, El-Serag HB, Bansal A, Wani S, Sharma P. Incidence of esophageal adenocarcinoma in patients with Barrett's esophagus and high-grade dysplasia: a meta-analysis. *Gastrointest Endosc* 2008; **67**: 394-398 [PMID: 18045592 DOI: 10.1016/j.gie.2007.07.019]
- 4 **Bailey SH**, Bull DA, Harpole DH, Rentz JJ, Neumayer LA, Pappas TN, Daley J, Henderson WG, Krasnicka B, Khuri SF. Outcomes after esophagectomy: a ten-year prospective cohort. *Ann Thorac Surg* 2003; **75**: 217-222; discussion 222 [PMID: 12537219]
- 5 **Birkmeyer JD**, Siewers AE, Finlayson EV, Stukel TA, Lucas FL, Batista I, Welch HG, Wennberg DE. Hospital volume and surgical mortality in the United States. *N Engl J Med* 2002; **346**: 1128-1137 [PMID: 11948273]
- 6 **Connors RC**, Reuben BC, Neumayer LA, Bull DA. Comparing

- outcomes after transthoracic and transhiatal esophagectomy: a 5-year prospective cohort of 17,395 patients. *J Am Coll Surg* 2007; **205**: 735-740 [PMID: 18035255]
- 7 **Peyre CG**, DeMeester SR, Rizzetto C, Bansal N, Tang AL, Ayazi S, Leers JM, Lipham JC, Hagen JA, DeMeester TR. Vagal-sparing esophagectomy: the ideal operation for intramucosal adenocarcinoma and barrett with high-grade dysplasia. *Ann Surg* 2007; **246**: 665-671; discussion 671-674 [PMID: 17893503]
 - 8 **Dunbar KB**, Spechler SJ. The risk of lymph-node metastases in patients with high-grade dysplasia or intramucosal carcinoma in Barrett's esophagus: a systematic review. *Am J Gastroenterol* 2012; **107**: 850-862; quiz 863 [PMID: 22488081 DOI: 10.1038/ajg.2012.78]
 - 9 **Wang KK**, Sampliner RE. Updated guidelines 2008 for the diagnosis, surveillance and therapy of Barrett's esophagus. *Am J Gastroenterol* 2008; **103**: 788-797 [PMID: 18341497 DOI: 10.1111/j.1572-0241.2008.01835.x]
 - 10 **Evans JA**, Early DS, Fukami N, Ben-Menachem T, Chandrasekhara V, Chathadi KV, Decker GA, Fanelli RD, Fisher DA, Foley KQ, Hwang JH, Jain R, Jue TL, Khan KM, Lightdale J, Malpas PM, Maple JT, Pasha SF, Saltzman JR, Sharaf RN, Shergill A, Dornitz JA, Cash BD. The role of endoscopy in Barrett's esophagus and other premalignant conditions of the esophagus. *Gastrointest Endosc* 2012; **76**: 1087-1094 [PMID: 23164510 DOI: 10.1016/j.gie.2012.08.004]
 - 11 **Buttar NS**, Wang KK, Sebo TJ, Riehle DM, Krishnadath KK, Lutzke LS, Anderson MA, Pettersen TM, Burgart LJ. Extent of high-grade dysplasia in Barrett's esophagus correlates with risk of adenocarcinoma. *Gastroenterology* 2001; **120**: 1630-1639 [PMID: 11375945 DOI: 10.1053/gast.2001.25111]
 - 12 **Inoue H**, Endo M, Takeshita K, Yoshino K, Muraoka Y, Yoneshima H. A new simplified technique of endoscopic esophageal mucosal resection using a cap-fitted panendoscope (EMRC). *Surg Endosc* 1992; **6**: 264-265 [PMID: 1465738]
 - 13 **Wani S**, Abrams J, Edmundowicz SA, Gaddam S, Hovis CE, Green D, Gupta N, Higbee A, Bansal A, Rastogi A, Early D, Lightdale CJ, Sharma P. Endoscopic mucosal resection results in change of histologic diagnosis in Barrett's esophagus patients with visible and flat neoplasia: a multicenter cohort study. *Dig Dis Sci* 2013; **58**: 1703-1709 [PMID: 23633158 DOI: 10.1007/s10620-013-2689-7]
 - 14 **Pouw RE**, van Vilsteren FG, Peters FP, Alvarez Herrero L, Ten Kate FJ, Visser M, Schenk BE, Schoon EJ, Peters FT, Houben M, Bisschops R, Weusten BL, Bergman JJ. Randomized trial on endoscopic resection-cap versus multiband mucosectomy for piecemeal endoscopic resection of early Barrett's neoplasia. *Gastrointest Endosc* 2011; **74**: 35-43 [PMID: 21704807 DOI: 10.1016/j.gie.2011.03.1243]
 - 15 **Larghi A**, Lightdale CJ, Ross AS, Fedi P, Hart J, Rotterdam H, Noffsinger A, Memeo L, Bhagat G, Waxman I. Long-term follow-up of complete Barrett's eradication endoscopic mucosal resection (CBE-EMR) for the treatment of high grade dysplasia and intramucosal carcinoma. *Endoscopy* 2007; **39**: 1086-1091 [PMID: 17701854 DOI: 10.1055/s-2007-966788]
 - 16 **Gerke H**, Siddiqui J, Nasr I, Van Handel DM, Jensen CS. Efficacy and safety of EMR to completely remove Barrett's esophagus: experience in 41 patients. *Gastrointest Endosc* 2011; **74**: 761-771 [PMID: 21824611 DOI: 10.1016/j.gie.2011.06.009]
 - 17 **Chennat J**, Konda VJ, Ross AS, de Tejada AH, Noffsinger A, Hart J, Lin S, Ferguson MK, Posner MC, Waxman I. Complete Barrett's eradication endoscopic mucosal resection: an effective treatment modality for high-grade dysplasia and intramucosal carcinoma—an American single-center experience. *Am J Gastroenterol* 2009; **104**: 2684-2692 [PMID: 19690526 DOI: 10.1038/ajg.2009.465]
 - 18 **Kim DY**, Hong SJ, Cho GS, Jeong GA, Kim HK, Han JP, Lee YN, Ko BM, Lee MS. Long-term efficacy of endoscopic submucosal dissection compared with surgery for early gastric cancer: a retrospective cohort study. *Gut Liver* 2014; **8**: 519-525 [PMID: 25228976 DOI: 10.5009/gnl13061]
 - 19 **Bialek A**, Pertkiewicz J, Karpínska K, Marlicz W, Bielicki D, Starzyńska T. Treatment of large colorectal neoplasms by endoscopic submucosal dissection: a European single-center study. *Eur J Gastroenterol Hepatol* 2014; **26**: 607-615 [PMID: 24743502 DOI: 10.1097/MEG.000000000000079]
 - 20 **Maple JT**, Abu Dayyeh BK, Chauhan SS, Hwang JH, Komanduri S, Manfredi M, Konda V, Murad FM, Siddiqui UD, Banerjee S. Endoscopic submucosal dissection. *Gastrointest Endosc* 2015; **81**: 1311-1325 [PMID: 25796422 DOI: 10.1016/j.gie.2014.12.010]
 - 21 **Höbel S**, Dautel P, Baumbach R, Oldhafer KJ, Stang A, Feyerabend B, Yahagi N, Schrader C, Faiss S. Single center experience of endoscopic submucosal dissection (ESD) in early Barrett's adenocarcinoma. *Surg Endosc* 2015; **29**: 1591-1597 [PMID: 25294533]
 - 22 **Chevaux JB**, Piessevaux H, Jouret-Mourin A, Yeung R, Danse E, Deprez PH. Clinical outcome in patients treated with endoscopic submucosal dissection for superficial Barrett's neoplasia. *Endoscopy* 2015; **47**: 103-112 [PMID: 25412090 DOI: 10.1055/s-0034-1390982]
 - 23 **Overholt BF**, Wang KK, Burdick JS, Lightdale CJ, Kimmey M, Nava HR, Sivak MV, Nishioka N, Barr H, Marcon N, Pedrosa M, Bronner MP, Grace M, Depot M. Five-year efficacy and safety of photodynamic therapy with Photofrin in Barrett's high-grade dysplasia. *Gastrointest Endosc* 2007; **66**: 460-468 [PMID: 17643436 DOI: 10.1016/j.gie.2006.12.037]
 - 24 **Pech O**, Gossner L, May A, Rabenstein T, Vieth M, Stolte M, Berres M, Ell C. Long-term results of photodynamic therapy with 5-aminolevulinic acid for superficial Barrett's cancer and high-grade intraepithelial neoplasia. *Gastrointest Endosc* 2005; **62**: 24-30 [PMID: 15990815 DOI: 10.1016/S0016-5107(05)00333-0]
 - 25 **Sharma P**, Jaffe PE, Bhattacharyya A, Sampliner RE. Laser and multipolar electrocoagulation ablation of early Barrett's adenocarcinoma: long-term follow-up. *Gastrointest Endosc* 1999; **49**: 442-446 [PMID: 10202056 DOI: 10.1016/S0016-5107(99)70040-4]
 - 26 **Gossner L**, May A, Stolte M, Seitz G, Hahn EG, Ell C. KTP laser destruction of dysplasia and early cancer in columnar-lined Barrett's esophagus. *Gastrointest Endosc* 1999; **49**: 8-12 [PMID: 9869716 DOI: 10.1016/S0016-5107(99)70438-4]
 - 27 **Dulai GS**, Jensen DM, Cortina G, Fontana L, Ippoliti A. Randomized trial of argon plasma coagulation vs. multipolar electrocoagulation for ablation of Barrett's esophagus. *Gastrointest Endosc* 2005; **61**: 232-240 [PMID: 15729231 DOI: 10.1016/S0016-5107(04)02576-3]
 - 28 **Manner H**, Rabenstein T, Pech O, Braun K, May A, Pohl J, Behrens A, Vieth M, Ell C. Ablation of residual Barrett's epithelium after endoscopic resection: a randomized long-term follow-up study of argon plasma coagulation vs. surveillance (APE study). *Endoscopy* 2014; **46**: 6-12 [PMID: 24353120 DOI: 10.1055/s-0033-1358813]
 - 29 **Greenwald BD**, Dumot JA, Horwhat JD, Lightdale CJ, Abrams JA. Safety, tolerability, and efficacy of endoscopic low-pressure liquid nitrogen spray cryotherapy in the esophagus. *Dis Esophagus* 2010; **23**: 13-19 [PMID: 19515183 DOI: 10.1111/j.1442-2050.2009.00991.x]
 - 30 **Gosain S**, Mercer K, Twaddell WS, Uradomo L, Greenwald BD. Liquid nitrogen spray cryotherapy in Barrett's esophagus with high-grade dysplasia: long-term results. *Gastrointest Endosc* 2013; **78**: 260-265 [PMID: 23622979 DOI: 10.1016/j.gie.2013.03.002]
 - 31 **Halsey KD**, Chang JW, Waldt A, Greenwald BD. Recurrent disease following endoscopic ablation of Barrett's high-grade dysplasia with spray cryotherapy. *Endoscopy* 2011; **43**: 844-848 [PMID: 21826629 DOI: 10.1055/s-0030-1256649]
 - 32 **Ghorbani S**, Tsai FC, Greenwald BD, Jang S, Dumot JA, McKinley MJ, Shaheen NJ, Habr F, Coyle WJ. Safety and efficacy of endoscopic spray cryotherapy for Barrett's dysplasia: results of the National Cryospray Registry. *Dis Esophagus* 2015 Feb 24; Epub ahead of print [PMID: 25708903 DOI: 10.1111/dote.12330]
 - 33 **Shaheen NJ**, Sharma P, Overholt BF, Wolfsen HC, Sampliner RE, Wang KK, Galanko JA, Bronner MP, Goldblum JR, Bennett AE, Jobe BA, Eisen GM, Fennerty MB, Hunter JG, Fleischer DE, Sharma VK, Hawes RH, Hoffman BJ, Rothstein RI, Gordon SR, Mashimo H, Chang KJ, Muthusamy VR, Edmundowicz SA, Spechler SJ, Siddiqui AA, Souza RF, Infantolino A, Falk GW, Kimmey MB, Madanick RD, Chak A, Lightdale CJ. Radiofrequency ablation in Barrett's esophagus with dysplasia. *N Engl J Med* 2009; **360**: 2277-2288 [PMID: 19474425 DOI:

- 10.1056/NEJMoa0808145]
- 34 **Dunn JM**, Banks MR, Oukrif D, Mackenzie GD, Thorpe S, Rodriguez-Justo M, Winstanley A, Bown SG, Novelli MR, Lovat LB. Radiofrequency ablation is effective for the treatment of high-grade dysplasia in Barrett's esophagus after failed photodynamic therapy. *Endoscopy* 2011; **43**: 627-630 [PMID: 21717379 DOI: 10.1055/s-0030-1256443]
 - 35 **Haidry RJ**, Dunn JM, Butt MA, Burnell MG, Gupta A, Green S, Miah H, Smart HL, Bhandari P, Smith LA, Willert R, Fullarton G, Morris J, Di Pietro M, Gordon C, Penman I, Barr H, Patel P, Boger P, Kapoor N, Mahon B, Hoare J, Narayanasamy R, O'Toole D, Cheong E, Direkze NC, Ang Y, Novelli M, Banks MR, Lovat LB. Radiofrequency ablation and endoscopic mucosal resection for dysplastic barrett's esophagus and early esophageal adenocarcinoma: outcomes of the UK National Halo RFA Registry. *Gastroenterology* 2013; **145**: 87-95 [PMID: 23542069 DOI: 10.1053/j.gastro.2013.03.045]
 - 36 **Phoa KN**, Pouw RE, Bisschops R, Pech O, Ragunath K, Weusten BL, Schumacher B, Rembacken B, Meining A, Messmann H, Schoon EJ, Gossner L, Mannath J, Seldenrijk CA, Visser M, Lerut T, Seewald S, Ten Kate FJ, Ell C, Neuhaus H, Bergman JJ. Multimodality endoscopic eradication for neoplastic Barrett oesophagus: results of an European multicentre study (EURO-II). *Gut* 2015 Mar 2; Epub ahead of print [PMID: 25731874 DOI: 10.1136/gutjnl-2015-309298]
 - 37 **Phoa KN**, van Vilsteren FG, Weusten BL, Bisschops R, Schoon EJ, Ragunath K, Fullarton G, Di Pietro M, Ravi N, Visser M, Offerhaus GJ, Seldenrijk CA, Meijer SL, ten Kate FJ, Tijssen JG, Bergman JJ. Radiofrequency ablation vs endoscopic surveillance for patients with Barrett esophagus and low-grade dysplasia: a randomized clinical trial. *JAMA* 2014; **311**: 1209-1217 [PMID: 24668102 DOI: 10.1001/jama.2014.2511]
 - 38 **Curvers WL**, ten Kate FJ, Krishnadath KK, Visser M, Elzer B, Baak LC, Bohmer C, Mallant-Hent RC, van Oijen A, Naber AH, Scholten P, Busch OR, Blaauwgeers HG, Meijer GA, Bergman JJ. Low-grade dysplasia in Barrett's esophagus: overdiagnosed and underestimated. *Am J Gastroenterol* 2010; **105**: 1523-1530 [PMID: 20461069 DOI: 10.1038/ajg.2010.171]
 - 39 **Gupta M**, Iyer PG, Lutzke L, Gorospe EC, Abrams JA, Falk GW, Ginsberg GG, Rustgi AK, Lightdale CJ, Wang TC, Fudman DI, Poneris JM, Wang KK. Recurrence of esophageal intestinal metaplasia after endoscopic mucosal resection and radiofrequency ablation of Barrett's esophagus: results from a US Multicenter Consortium. *Gastroenterology* 2013; **145**: 79-86.e1 [PMID: 23499759 DOI: 10.1053/j.gastro.2013.03.008]
 - 40 **Pasricha S**, Bulsiewicz WJ, Hathorn KE, Komanduri S, Muthusamy VR, Rothstein RI, Wolfson HC, Lightdale CJ, Overholt BF, Camara DS, Dellon ES, Lyday WD, Ertan A, Chmielewski GW, Shaheen NJ. Durability and predictors of successful radiofrequency ablation for Barrett's esophagus. *Clin Gastroenterol Hepatol* 2014; **12**: 1840-7.e1 [PMID: 24815329 DOI: 10.1016/j.cgh.2014.04.034]
 - 41 **Vaccaro BJ**, Gonzalez S, Poneris JM, Stevens PD, Capiak KM, Lightdale CJ, Abrams JA. Detection of intestinal metaplasia after successful eradication of Barrett's Esophagus with radiofrequency ablation. *Dig Dis Sci* 2011; **56**: 1996-2000 [PMID: 21468652 DOI: 10.1007/s10620-011-1680-4]
 - 42 **Orman ES**, Li N, Shaheen NJ. Efficacy and durability of radiofrequency ablation for Barrett's Esophagus: systematic review and meta-analysis. *Clin Gastroenterol Hepatol* 2013; **11**: 1245-1255 [PMID: 23644385 DOI: 10.1016/j.cgh.2013.03.039]
 - 43 **Inadomi JM**. Surveillance in Barrett's esophagus: a failed premise. *Keio J Med* 2009; **58**: 12-18 [PMID: 19398879]
 - 44 **Ganz RA**, Mitlyng B, Leon S. The case for ablating nondysplastic Barrett's esophagus. *Gastrointest Endosc* 2014; **80**: 866-872 [PMID: 25436398 DOI: 10.1016/j.gie.2014.06.010]
 - 45 **Lightdale CJ**. Radiofrequency ablation for nondysplastic Barrett's esophagus: certainly not for all. *Gastrointest Endosc* 2014; **80**: 873-876 [PMID: 25436399 DOI: 10.1016/j.gie.2014.05.331]
 - 46 **Spechler SJ**, Souza RF. Barrett's esophagus. *N Engl J Med* 2014; **371**: 836-845 [PMID: 25162890 DOI: 10.1056/NEJMra1314704]

P- Reviewer: Anadol Z, dos Santos JS **S- Editor:** Ji FF
L- Editor: A **E- Editor:** Lu YJ





Published by **Baishideng Publishing Group Inc**

8226 Regency Drive, Pleasanton, CA 94588, USA

Telephone: +1-925-223-8242

Fax: +1-925-223-8243

E-mail: bpgoffice@wjgnet.com

Help Desk: <http://www.wjgnet.com/esps/helpdesk.aspx>

<http://www.wjgnet.com>

