

2016 Liver Transplantation: Global view

Management issues in post living donor liver transplant biliary strictures

Manav Wadhawan, Ajay Kumar

Manav Wadhawan, Ajay Kumar, Fortis Escorts Liver and Digestive Diseases Institute, Okhla, New Delhi 110025, India

Author contributions: Wadhawan M designed research, collected data, performed ERCP's, analyzed data, and wrote paper; Kumar A designed research, performed ERCP's and wrote paper.

Conflict-of-interest statement: There is no conflict of interest with anyone on the data published.

Open-Access: This article is an open-access article which was selected by an in-house editor and fully peer-reviewed by external reviewers. It is distributed in accordance with the Creative Commons Attribution Non Commercial (CC BY-NC 4.0) license, which permits others to distribute, remix, adapt, build upon this work non-commercially, and license their derivative works on different terms, provided the original work is properly cited and the use is non-commercial. See: <http://creativecommons.org/licenses/by-nc/4.0/>

Correspondence to: Ajay Kumar, MD, DM, MAMS, FRCP (Glasgow), Chief and Executive Director, Fortis Escorts Liver and Digestive Diseases Institute, Okhla, New Delhi 110025, India. ajaykge@hotmail.com

Received: May 14, 2015

Peer-review started: May 15, 2015

First decision: September 8, 2015

Revised: March 12, 2016

Accepted: March 22, 2016

Article in press: March 23, 2016

Published online: April 8, 2016

Abstract

Biliary complications are common after living donor liver transplant (LDLT) although with advancements in surgical understanding and techniques, the incidence is decreasing. Biliary strictures are more common than leaks. Endoscopic retrograde cholangiopancreatography (ERCP) is the first line modality of treatment of post

LDLT biliary strictures with a technical success rate of 75%-80%. Most of ERCP failures are successfully treated by percutaneous transhepatic biliary drainage (PTBD) and rendezvous technique. A minority of patients may require surgical correction. ERCP for these strictures is technically more challenging than routine as well post deceased donor strictures. Biliary strictures may increase the morbidity of a liver transplant recipient, but the mortality is similar to those with or without strictures. Post transplant strictures are short segment and soft, requiring only a few session of ERCP before complete dilatation. Long-term outcome of patients with biliary stricture is similar to those without stricture. With the introduction of new generation cholangioscopes, ERCP success rate may increase, obviating the need for PTBD and surgery in these patients.

Key words: Living donor liver transplant; Biliary complications; Biliary strictures; Endoscopic retrograde cholangiopancreatography; Percutaneous transhepatic biliary drainage

© **The Author(s) 2016.** Published by Baishideng Publishing Group Inc. All rights reserved.

Core tip: Biliary complications are the Achilles heel of liver transplantation and are more common in live related liver transplant than cadaver liver transplant. Endoscopic retrograde cholangiopancreatography along with percutaneous transhepatic biliary drainage is successful in managing more than 90% of biliary complications after liver transplant. Although strictures increase morbidity after liver transplant, the mortality rates are not influenced by biliary strictures. This review provides diagnostic approach and management algorithm of these biliary structures in the setting of right lobe liver transplant.

Wadhawan M, Kumar A. Management issues in post living donor liver transplant biliary strictures. *World J Hepatol* 2016;

8(10): 461-470 Available from: URL: <http://www.wjgnet.com/1948-5182/full/v8/i10/461.htm> DOI: <http://dx.doi.org/10.4254/wjh.v8.i10.461>

INTRODUCTION

Liver transplantation has become a well-established treatment for end stage liver disease^[1]. Living donor liver transplant (LDLT) is still the predominant form for transplantation in eastern part of the world including India. Biliary leaks and strictures are still recognized as the most common complications after LDLT. Biliary complications after orthotopic liver transplantation (OLT) are evaluated and treated by endoscopy; only a few require percutaneous interventions. Surgical intervention is necessary only in treatment failures as a backup option^[2]. Non-anastomotic stricture (NAS) are uncommon and difficult to treat with endoscopic retrograde cholangiopancreatography (ERCP)/percutaneous transhepatic biliary drainage (PTBD). NAS's often require re-transplant as the only effective treatment option. This review will focus on the diagnosis and management of anastomotic biliary strictures (ABS) after LDLT.

MAGNITUDE OF THE PROBLEM AND CONTRIBUTING FACTORS

Incidence of biliary complications after liver transplantation has been variably reported between 5%-40% (Table 1). The incidence is higher after LDLT compared to deceased donor liver transplant (DDLTL)^[3]. Over last 3 decades the reported incidence of bile leaks as well strictures is decreasing (Table 1)^[4-15]. This can be ascribed to better understanding of the technical causes leading to biliary complications.

Although the cause of biliary complications is mainly technical, various factors have been implicated in the development of these complications. Overview of the possible contributory factors and role of each has been listed in Table 2^[12,14-22].

In LDLT the anastomosis is made between right anterior and posterior ducts of the donor with the common hepatic duct of the recipient. The various types of anastomoses are shown in Figure 1. There could be one anastomosis if common trunk of right hepatic duct is available (Figure 2) or there could be two or more anastomoses (Figure 3). Usually, in case of double duct anastomosis, native right anterior and right posterior are used to anastomose to donor ducts. If the two ducts are close together, sometimes ductoplasty with single recipient duct is done (Figure 4). In rare circumstances, surgeons have used cystic duct for anastomosis to one of the ducts of the donor. In our own experience, the use of cystic duct for anastomosis leads to stricture formation in almost all cases (unpublished data). Once the stricture develops in cystic duct anastomosis, it is technically almost impossible to handle with endoscopy

Table 1 Evolution of post living donor liver transplant biliary complications with the changing time

Ref.	Year	Country	n	Follow-up (mo)	Leaks	Strictures
Sugawara <i>et al</i> ^[4]	2003	Japan	92	45	20.6%	9.7%
Gondolesi <i>et al</i> ^[5]	2004	United States	96	24.2	21.9%	22.9%
Lee <i>et al</i> ^[6]	2004	South Korea	31	10.5	6.5%	12.9%
Liu <i>et al</i> ^[7]	2004	China	41	13.3	7.3%	24.3%
Soejima <i>et al</i> ^[8]	2006	Japan	182	21	11.5%	25.3%
Shah <i>et al</i> ^[9]	2007	Canada	128	23	14.8%	17.1%
Mita <i>et al</i> ^[10]	2008	Japan	231			9.5%
Marubashi <i>et al</i> ^[11]	2009	Japan	83	32.4	1.2%	7.2%
Kim <i>et al</i> ^[12]	2010	South Korea	22	51.3	0%	9.1%
Wadhawan <i>et al</i> ^[14]	2013	India	65	28	8.8%	10.3%
Mizuno <i>et al</i> ^[13]	2014	Japan	108	58.4	5.6%	13.9%
Vij <i>et al</i> ^[15]	2015	India	127	9.32	0.7%	0%

(Figures 5 and 6). At our center, we have abandoned using cystic duct of the recipient for ductal anastomosis.

DIAGNOSIS

Biliary complications related to anastomosis could be leaks or strictures. The diagnosis of biliary complications is made on the basis of clinical symptoms (jaundice, itching, bilious drainage, and cholangitis), deranged liver function tests (LFT), and/or radiologic imaging. Imaging plays a very important role in diagnosis as well management of biliary problems. Ultrasonography (USG), magnetic resonance cholangiopancreatography (MRCP), hepatobiliary scintigraphy (HBS) as well as computerized tomogram (CT) have an important role in diagnosis and management of biliary problems.

The timeline for biliary complications after transplant is shown in Figure 7^[23].

Most bile leaks would present early after transplant (within first few weeks), almost all would manifest in 3 mo^[23]. Leaks presenting early after transplants are usually diagnosed clinically by the presence of bile in the drains. Sometimes, even early bile leaks may be tricky to diagnose as many patients produce large amount of peritoneal fluid for a few days after transplant, thus diluting the bile. On the other hand, late leaks may present after drain removal with pain abdomen and fever with or without jaundice and septicemia. Role of static imaging (USG, CT, MRCP) in diagnosis of leaks is mainly to diagnose collections. However, HBS may be useful to diagnose subclinical leaks (cut surface leaks after LDLT, minor leaks from anastomotic site not apparent on drain)^[24]. Minor bile leaks may have minimal derangement of LFT's, any fever with pain abdomen should raise a suspicion of bile leak. Any undiagnosed sepsis in post-operative setting, should raise the suspicion of bile leak and all efforts should be made to diagnose it.

Biliary strictures usually present later than leaks but within first year after transplant^[23]. The most common

Table 2 Overview of factors contributing to biliary complications

Ref.	Year	Factor	Inference
Dalgic <i>et al</i> ^[16]	2005	Corner sparing sutures	Decreased incidence of complications
Castaldo <i>et al</i> ^[17]	2007	Continuous <i>vs</i> interrupted sutures	No difference in two techniques
Soejima <i>et al</i> ^[18]	2008	Hilar dissection to preserve blood supply	Decreased incidence of complications
Lin <i>et al</i> ^[19]	2009	Microsurgical biliary reconstruction	Decreased incidence of complications
Kim <i>et al</i> ^[12]	2010	Telescopic reconstruction of bile duct	Decreased incidence of complications
Chok <i>et al</i> ^[20]	2011	CIT and acute cellular rejection	Higher biliary complications with increased CIT Acute cellular rejection predicted biliary strictures
Horster <i>et al</i> ^[21]	2013	HCV infection as etiology	Higher incidence of biliary complications in patients with HCV infection and higher viral load
Wadhawan <i>et al</i> ^[14]	2013	Type of anastomosis	Higher incidence of biliary complications in double duct and cystic duct anastomosis
Mathur <i>et al</i> ^[22]	2015	Internal biliary stenting	No difference in complications with or without stenting
Vij <i>et al</i> ^[15]	2015	Corner sparing sutures Bile duct mucosal eversion	Decreased incidence of biliary complications

CIT: Cold ischemia time; HCV: Hepatitis C virus.

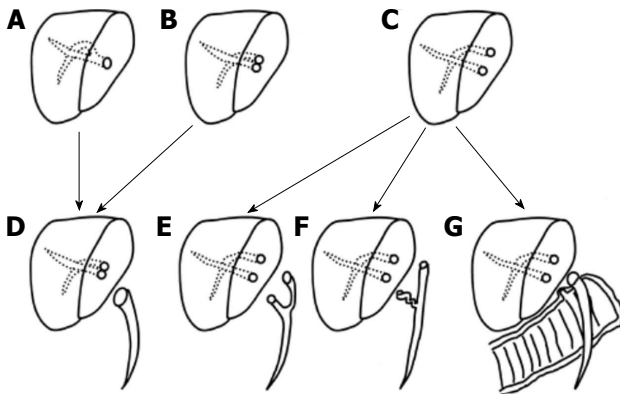


Figure 1 Types of biliary anastomoses and corresponding biliary reconstructions^[54]. A: Single duct anastomosis; B: Double duct - minimum distance between two donor ducts, requires ductoplasty with recipient CBD; C: Double duct - two donor duct are far away, requires two separate duct anastomosis or a hepaticojejunostomy; D: Single duct to duct reconstruction; E: Double duct to duct reconstruction using right and left hepatic ducts; F: Double duct to duct reconstruction using cystic and CHD; G: Mixed type using duct to duct and hepaticojejunostomy. CHD: Common hepatic duct; CBD: Common bile duct.

presenting symptoms of stricture is itching with or without jaundice. LFT reveal a cholestatic pattern; bilirubin rise may be late in the course after LDLT. Less commonly, cholangitis may be the presentation of a biliary stricture. The first investigation in such cases is ultrasound of the abdomen. The presence of ductal dilatation has a high positive predictive value for the diagnosis of a stricture^[25]. However, ductal dilatation is not prominent in many cases after LDLT. Absence of ductal dilatation has been previously reported to be an unreliable indicator of adequate biliary drainage^[26]. It has been shown that donor bile ducts do not respond to the distal obstruction by same extent of dilatation as the non transplant liver^[27]. MRCP has a sensitivity and specificity of 85%-90% in diagnosing biliary strictures after transplant^[28,29]. The phenomenon of limited dilatation of donor ducts further underestimates the diagnosis of strictures on MRCP imaging. Specific criteria have

been proposed for diagnosis on MRCP imaging^[30]. The variables that need to be studied in MRCP include type of anastomosis, length of stricture, length of common stump proximal to the anastomosis and differential diameters of recipient and donor ducts, *etc.* These help in the diagnosis as well as planning of endoscopic treatment.

Acute cellular rejection is an important differential when we have graft dysfunction. In fact rejection has been shown to be associated with stricture^[21]. In our own experience, in the presence of ductal dilatation patients should be first taken for biliary decompression and if graft dysfunction persists, they should be treated for rejection. In the absence of dilatation, a liver biopsy may help in diagnosing the predominant cause of graft dysfunction.

HBS has been used in diagnosing the biliary obstruction with variable results^[31,32]. It has a high positive predictive value but low sensitivity and specificity. Hence it is not widely used in the diagnosis of strictures.

Despite the fact that diagnostic ERCP is on its way out, it still remains an important modality to diagnose and confirm suspected biliary strictures after transplant. Sometimes in doubtful cases, a direct cholangiography [ERCP, percutaneous transhepatic cholangiography (PTC)] is required for the diagnosis. Thus direct cholangiography is the gold standard not only in establishing the diagnosis but also in allowing therapeutic intervention in the same setting. ERCP being less invasive with lower complication rates, is the modality of choice and is preferred over PTC^[2,14].

MANAGEMENT

Biliary strictures can be managed by either endoscopic access (ERCP) or by percutaneous access (PTBD). All over the world, ERCP is the treatment of choice for management of biliary strictures after LDLT and is preferred over PTBD. Only one trial has compared the two modalities head to head^[33]. The results of this study showed similar success and complication rates for

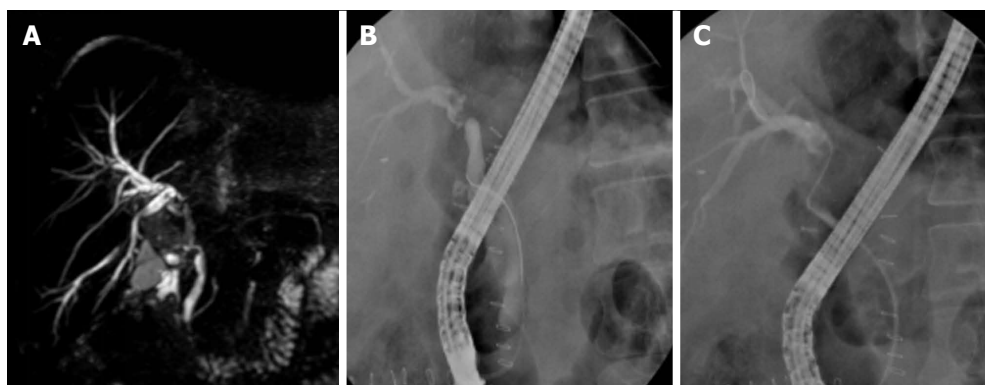


Figure 2 Anastomotic stricture - single duct anastomosis. A: Magnetic resonance cholangiopancreatography shows stricture at the anastomotic site of a single duct anastomosis; B: Endoscopic retrograde cholangiopancreatography (ERCP) in the same patient shows the stricture; C: ERCP in same patient shows guide wire negotiated across the stricture.

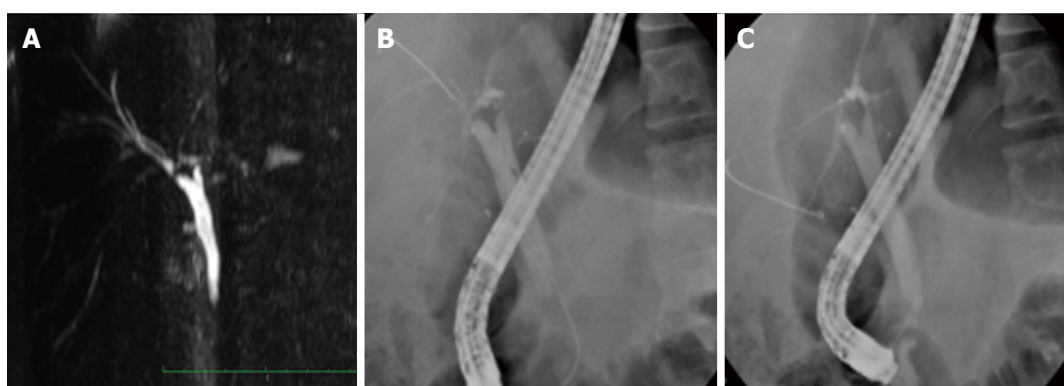


Figure 3 Anastomotic stricture - double duct anastomosis. A: Magnetic resonance cholangiopancreatography image shows stricture across both RASD as well as RPSD ductal anastomosis; B: Endoscopic retrograde cholangiopancreatography (ERCP) image shows guide wire negotiated across RPSD in this patient; C: ERCP image shows guidewire negotiated across RASD in this patient.

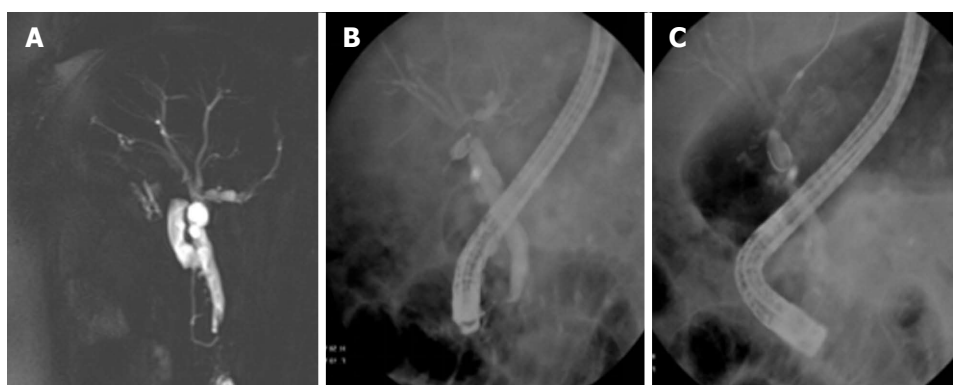


Figure 4 Anastomotic stricture - ductoplasty. A: Magnetic resonance cholangiopancreatography image of a ductoplasty of RASD and RPSD to common hepatic duct; B: Endoscopic retrograde cholangiopancreatography (ERCP) image shows stricture at ductoplasty site; C: ERCP image shows guide wire across one ductal system.

both approach. However, the number of interventions required was higher in the percutaneous arm. Despite sparse comparative data, ERCP is the preferred approach with PTBD being reserved for rescue in cases of failed ERCP/stenting. PTBD is considered more invasive, with a higher incidence of complications like hemorrhage, bile leak from entry site and need to keep an external stent that is liable to be displaced inadvertently.

Definitions of stricture and endoscopic outcomes

Classical definition of anastomotic biliary stricture on cholangiography is a dominant narrowing at the anastomotic site without effective drainage of the contrast material^[34]. However, the diagnosis of stricture is nowadays made on MR cholangiography rather than direct cholangiography. The parameters to be studied on MRCP examination include the presence and location of

Table 3 Definitions

Term	Definition
Anastomotic biliary stricture	ERCP/PTC - Dominant narrowing at the anastomotic site without effective drainage of the contrast material MRCP - More than 50% reduction in anastomotic diameter compared to intrahepatic duct
Successful initial endoscopic outcome	Stricture negotiated with stent with continuous improvement in liver functions
Successful long-term endoscopic outcome	Persistent patency of the anastomotic site on cholangiography after stent removal (anastomotic site > 80% of intrahepatic ductal diameter)
Initial endoscopic treatment failure	Inability to negotiate the stricture on ERCP
Endoscopic treatment failure	Persistence of the stricture after 12 mo of therapy
Persistent ABS	Visible stricture on cholangiography after stent removal, measuring less than 80% of the diameter of the intrahepatic duct or hindering effective drainage of contrast medium
Recurrence of stricture	Biochemical derangement with ERCP documented recurrence of stricture after initial success

ERCP: Endoscopic retrograde cholangiopancreatography; PTC: Percutaneous transhepatic cholangiography; ABS: Anastomotic biliary strictures; MRCP: Magnetic resonance cholangiopancreatography.

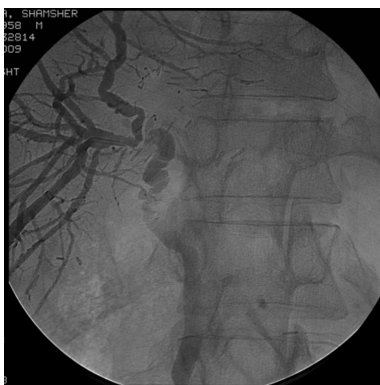

Figure 5 Anastomotic stricture - cystic duct anastomosis (endoscopic retrograde cholangiopancreatography failed, patient underwent percutaneous transhepatic biliary drainage).

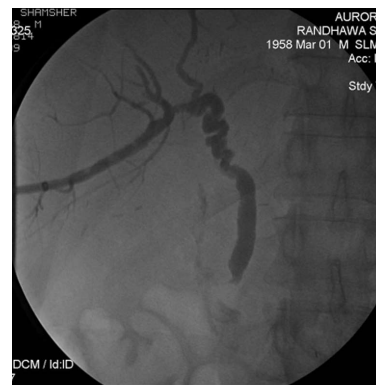


Figure 6 Cystic duct anastomosis after dilatation. This patient developed stricture again and underwent a hepaticojejunostomy.

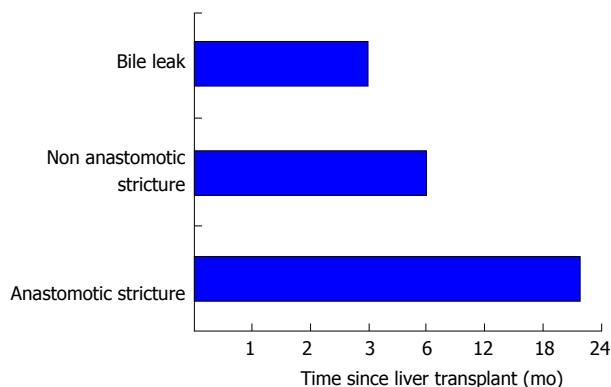


Figure 7 Timeline of biliary complications after transplant.

any strictures, upstream duct dilatation, the diameter of the ducts proximal to the anastomotic site (donor duct), distal to the anastomotic site (recipient duct) (Table 3).

ABS is diagnosed when the diameter of the anastomosis is less than 50% of the proximal (donor) bile duct^[35]. If ABS is diagnosed, the length and diameter of the stricture is recorded. Also to be noted is the size discrepancy as well as angulation between donor and recipient ducts^[34]. The percent stenosis is calculated as the difference between the donor duct diameter and the stricture diameter, divided by the donor duct

diameter. In case of multiple duct anastomoses, details of each anastomosis have to be recorded as it has implications on number of stents to be placed. Also in case of a single duct anastomosis, the possibility of stricture extending intrahepatic is to be considered (this can convert a single duct anastomosis similar to double duct thus mandating more than one stent). Although more than 50% change in diameter of anastomosis to intrahepatic (donor duct) is taken as suggestive of stricture, this has not been validated in any of the trials. There are no studies comparing the relative diameters in asymptomatic individuals compared to those with biochemical derangements.

Successful initial endoscopic outcome is defined as the continuous improvement in LFT. Successful long-term endoscopic outcome refers to persistent patency of the anastomotic site on cholangiography after stent removal. The biliary anastomosis is considered patent on cholangiography when the narrowest diameter at the anastomosis is greater than 80% of the upstream intrahepatic (donor) duct diameter, and spontaneous emptying of contrast medium is seen on fluoroscopy^[2]. Initial endoscopic treatment failure is defined as inability to negotiate the stricture on ERCP^[14]. Endoscopic treatment failure is defined as persistence of the stricture after 12 mo of therapy. A persistent ABS is defined as a visible stricture on cholangiography after stent

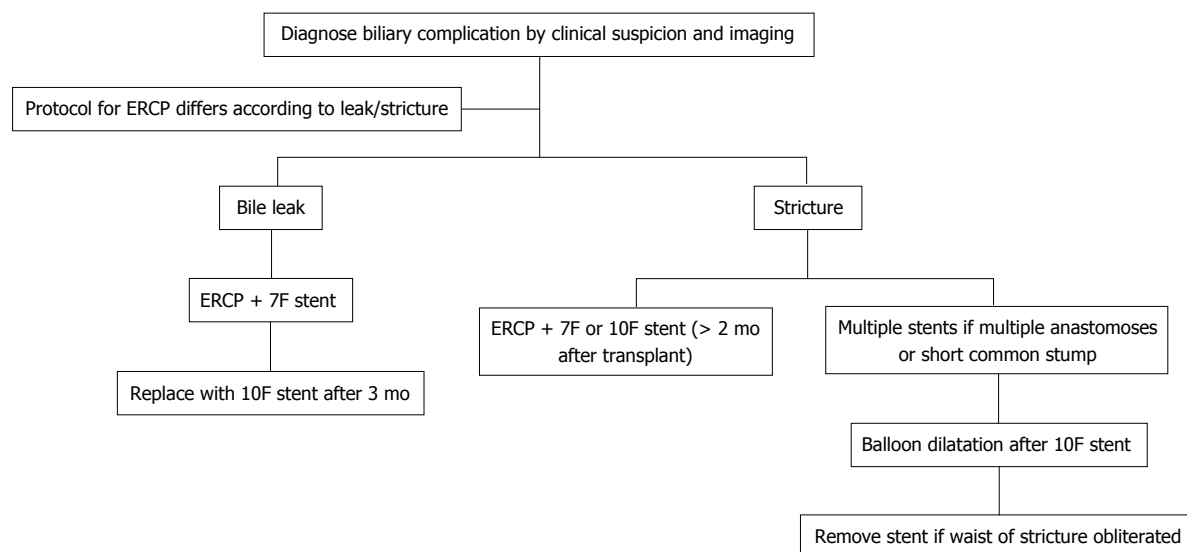


Figure 8 Protocol for endoscopic intervention (please see text also). ERCP: Endoscopic retrograde cholangiopancreatography.

removal, measuring less than 80% of the diameter of the intrahepatic duct or hindering effective drainage of contrast medium. Recurrence of stricture is defined as biochemical derangement with ERCP documented recurrence of stricture after initial success.

Timing of intervention

There is no data available on the timing of intervention after development of biliary stricture. There is a fear of disrupting the anastomosis if ERCP is done early (first few weeks). However, there is no published data to substantiate that fear. In our own center, we tend to delay ERCP for at least 3 wk. Also we feel that early biliary leaks may merit surgery than ERCP.

The success rate also depends on the time gap between the transplant to the presentation of biliary stricture. We have found that strictures that present early have a higher rate of successful outcome after ERCP. This is probably explained by the fact that early strictures are often soft involving short segment and hence are easily negotiable on ERCP. Those presenting late (generally in such cases there is a lag period between onset of symptoms and time of presentation) often have very tight strictures, making the negotiation of stricture difficult. The rate of salvage PTBD as well requirement of surgical intervention is higher in these cases.

Protocol of endoscopic intervention

The intervention protocols vary between institutions. Most centers would only stent the stricture after initial sphincterotomy at the first ERCP. Balloon dilatation is usually done in subsequent ERCP's. But there are institutions where balloon dilatation is carried out at the first ERCP itself^[36]. Usually after the initial ERCP, stents are replaced every 3 mo with larger stents. Stents placed for longer time are more likely to get blocked predisposing to cholangitis^[37-39]. Use of multiple

stents has shown better long-term success than single stents^[40,41].

There are 4 published trials comparing stenting alone vs stenting and balloon dilatation. Three of these are in post DDLT biliary strictures and only one was in LDLT patients^[42]. This trial showed better long-term outcomes with a combination of both strategies compared to either alone.

The protocol we follow at our center is described as follows (Figure 8)^[14]. The initial stenting is done with 7F/10F plastic stent depending on the timing of presentation after transplant. We use 7F stents initially for those with biliary leak in addition to stricture, and in those presenting very early after transplant (within 2 mo). Patients presenting after 2 mo of transplant usually undergo either a 10F stent (single duct anastomosis) or two 7F stents (double duct anastomosis). We always place stents across all anastomoses even if only one has a stricture as we feel stenting only one duct may block the other biliary system leading to cholangitis. We use the same strategy of stenting both anterior and posterior duct in a single duct anastomosis if the common duct of donor is small. We do not use balloon dilatation in first ERCP for the fear of anastomotic disruption. The stents are usually exchanged after 3 mo. We perform balloon dilatation with 6 mm or 10 mm biliary dilatation balloon (depending on the size of intrahepatic ducts) during second ERCP. The stents are removed if the waist of stricture is completely obliterated. Each patient requires about 2-3 stent exchanges over 6-12 mo. This is quite less than what is seen in other cases of benign biliary strictures (Iatrogenic post cholecystectomy and strictures associated with chronic pancreatitis). This could be due to the fact that these patients are on immunosuppression and thus do not have significant fibrosis.

The success rate of ERCP in post LDLT biliary strictures has been reported between 60%-75%^[9,14,41-45].

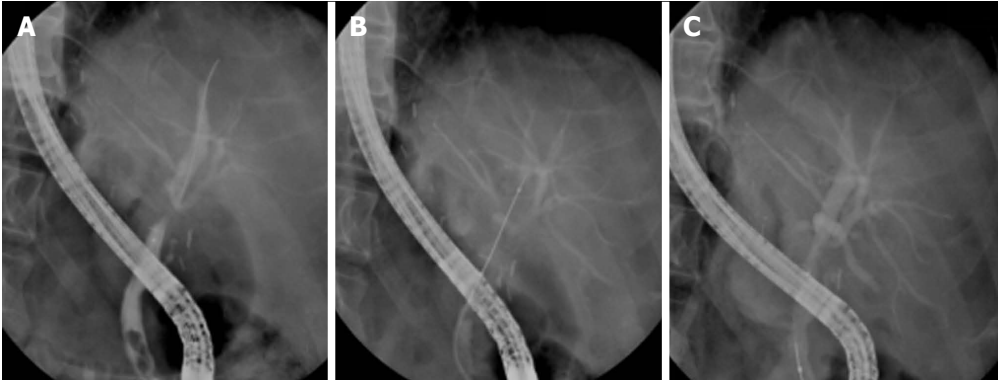


Figure 9 Balloon dilatation of biliary stricture. A: Endoscopic retrograde cholangiopancreatography (ERCP) images show stricture at the anastomotic site; B: ERCP image showing balloon dilatation of the stricture; C: Successful obliteration of the waist of stricture after balloon dilatation.

This is lower than reported success rate for post DDLT strictures (80%-90%)^[3]. The reasons for lower success in LDLT strictures are multiple and will be discussed in detail in technical challenges section.

There are reports of use of covered self-expandable metal stents (SEMS) in treatment of biliary leaks and strictures after transplant. However, most of the data is in post DDLT strictures^[46,47]. The smaller size of donor liver ducts as well as very short common duct stump and discrepancy between recipient and donor duct size make it unsuitable for use in LDLT strictures. Moreover, using a fully covered stent in LDLT strictures will compromise the patency of the contralateral duct. We do not use SEMS in post LDLT strictures.

Technical challenges

The ERCP procedure is much more challenging in post LDLT compared to DDLT recipient. The anastomosis is much higher and peripheral making the access difficult^[44]. There is also a size discrepancy between donor and recipient ducts adding to the difficulty. The role of ischemia element at the anastomotic site often leads to the stricture extending intrahepatic, hence often converting single duct anastomosis akin to double duct anastomosis (separation of anterior and posterior segments of the donor liver)^[48]. The hypertrophy of the partial liver in LDLT often creates a sharp angulation between donor and recipient ducts. This angulation when complicated by a stricture often leads to a very difficult situation less amenable to successful endoscopic treatment^[49]. Kyoto group has described a similar anomaly as crane neck deformity, in which the biliary anastomosis is located at a point that is far below the highest portion of the recipient duct^[43]. This is particularly difficult to negotiate with ERCP, but salvage PTBD is often successful in such cases.

A peculiar problem arises when strictures are associated with leaks also. In this scenario, the guide wire repeatedly slips preferentially into the leak area without negotiating the stricture (path of least resistance). In such cases also, ERCP is often unsuccessful and PTBD is required.

Newer techniques like cholangioscopy (spyglass)

have been described in LDLT for traversing difficult strictures^[50,51]. However in our limited experience of three cases, we did not find it of any additional benefit. We found that limited visibility and steering ability of the currently available devices is the major problem hindering the usefulness. With the improving technology and introduction of better cholangioscopes, this may help in negotiating difficult strictures.

Another novel technique using magnets to traverse difficult biliary strictures after LDLT has been described^[52,53]. This was initially described in LDLT from Korea by Jang *et al*^[52]. Subsequently, a through the scope magnet has been used by Turkey group with very good results. A similar technique with use of EUS-ERCP interface has also been successfully used to repair biliary anastomosis after LDLT^[54]. Ersoz *et al*^[55] described a novel technique using standard balloon to negotiate S shaped difficult strictures. With further refinement of these technique, it may help prevent surgery in difficult to negotiate biliary strictures after LDLT.

Long-term outcomes

Long-term data after removal of stents is sparse. The only published paper which discusses long-term outcome, reported a stent free status in 42.5% of patients at a median follow-up of 33 mo^[38]. In our own experience, 90% of the patients after balloon dilatation are free of stents at a median of 1 year after initial ERCP (Figure 9). The recurrence rate after stent removal is around 20% at a median follow-up of 30 mo after last balloon dilatation (unpublished data). Most patients who have recurrence of stricture after balloon dilatation are successfully treated by repeat ERCP only^[33].

Failure of endoscopic treatment

The failure rate of endoscopic management in LDLT strictures varies from 25%-40% in various studies. The reasons for higher failure rate compared to DDLT have been discussed in technical considerations section. Patients who fail ERCP are usually successfully managed by PTBD. We at our center always do a rendezvous ERC procedure after a successful PTBD (Figure 10)^[14]. Stenting *via* PTC route has been described but is not

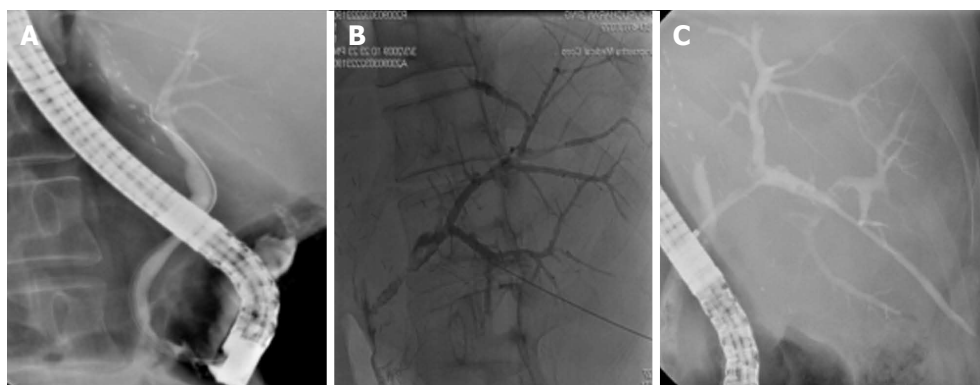

Figure 10 Rendezvous procedure. A: Endoscopic retrograde cholangiopancreatography opacified only RASD; B: RPSD accessed via percutaneous transhepatic biliary drainage; C: Rendezvous procedure being performed.

widely practiced as it entails dilatation of liver tract of PTBD^[33]. In our series the technical success rate of ERCP was 75%, majority of the failures were managed by PTBD (combined success rate of 91%). However, in small number of patients, where both ERCP and PTBD fail (about 9%), surgical intervention in the form of hepaticojejunostomy is required^[14].

Complications

Complication rates after ERCP have been variably reported between 10%-24%^[14,32,39-44]. Due to altered duodenal anatomy (upper abdominal surgery), the approach to the papilla becomes difficult as after any other upper abdominal surgery. The incidence of complications including pancreatitis rates are similar as in non-transplant ERCP's. We have seen proximal migration of plastic stents in significant number of patients. Removal of these becomes quite difficult. To avoid that, we have started using single pigtail stents.

Biliary complications and graft survival

Most of the biliary strictures are now managed successfully with non-surgical approach (ERCP or PTBD). The success rate of these interventions is very high with minimum morbidity and almost no mortality. At least two trials have analyzed the effect of biliary complications on graft survival in LDLT^[14,37]. Both concluded that there is no effect of biliary complications on patient or graft survival. However, both these trials had analyzed strictures in relation to mortality. We believe that if the data on bile leaks is analyzed separately, the results may be different as bile leaks predispose to sepsis and graft dysfunction early after liver transplant.

Future directions

Biliary strictures are the commonest complication of liver transplant both OLT and LDLT. Despite that there is no consensus on numerous management issues in it. We need more evidence to show what is the best protocol, i.e., only balloon or balloon dilatation plus stent, how many stents, for how long. Natural history of treated biliary strictures needs to be further studied. Newer

devices to facilitate difficult stricture cannulation during endoscopy need to be developed. Digital spyglass may be one such modality. Any bad/favorable prognostic signs for endoscopic treatment need to be defined. Above all more effort is required to refine the surgical techniques to avoid these strictures.

CONCLUSION

Biliary complications are common after LDLT, strictures seen more commonly than leaks. With refining surgical skills and better understanding of factors predisposing to biliary strictures, the incidence of biliary complications is decreasing. ERCP is the first line modality of treatment of post LDLT biliary strictures with a technical success rate of 75%-80%. Most of ERCP failures are successfully handled by PTBD. A minority of patients may require surgical correction. ERCP for post LDLT strictures is technically more challenging than routine ERCP's as well post DDLT strictures ERCP's. With the introduction of new generation cholangioscopes, ERCP success rate may increase, obviating the need for PTBD and surgery in the management.

REFERENCES

- 1 **Busuttil RW**, Farmer DG, Yersiz H, Hiatt JR, McDiarmid SV, Goldstein LI, Saab S, Han S, Durazo F, Weaver M, Cao C, Chen T, Lipshutz GS, Holt C, Gordon S, Gornbein J, Amersi F, Ghobrial RM. Analysis of long-term outcomes of 3200 liver transplantations over two decades: a single-center experience. *Ann Surg* 2005; **241**: 905-916; discussion 916-918 [PMID: 15912040 DOI: 10.1097/01.sla.0000164077.77912.98]
- 2 **Nacif LS**, Bernardo WM, Bernardo L, Andraus W, Torres L, Chaib E, D'Albuquerque LC, Maluf-Filho F. Endoscopic treatment of post-liver transplantation anastomotic biliary stricture: systematic review and meta-analysis. *Arq Gastroenterol* 2004; **51**: 240-249 [PMID: 25296086 DOI: 10.1590/S0004-28032014000300014]
- 3 **Sharma S**, Gurakar A, Jabbour N. Biliary strictures following liver transplantation: past, present and preventive strategies. *Liver Transpl* 2008; **14**: 759-769 [PMID: 18508368 DOI: 10.1002/lt.21509]
- 4 **Sugawara Y**, Sano K, Kaneko J, Akamatsu N, Kishi Y, Kokudo N, Makuuchi M. Duct-to-duct biliary reconstruction for living donor liver transplantation: experience of 92 cases. *Transplant Proc*

- 2003; **35**: 2981-2982 [PMID: 14697955 DOI: 10.1016/j.transproceed.2003.10.046]
- 5 **Gondolesi GE**, Varotti G, Florman SS, Muñoz L, Fishbein TM, Emre SH, Schwartz ME, Miller C. Biliary complications in 96 consecutive right lobe living donor transplant recipients. *Transplantation* 2004; **77**: 1842-1848 [PMID: 15223901 DOI: 10.1097/01.TP.0000123077.78702.0C]
- 6 **Lee KW**, Joh JW, Kim SJ, Choi SH, Heo JS, Lee HH, Park JW, Lee SK. High hilar dissection: new technique to reduce biliary complication in living donor liver transplantation. *Liver Transpl* 2004; **10**: 1158-1162 [PMID: 15350008 DOI: 10.1002/lt.20230]
- 7 **Liu CL**, Lo CM, Chan SC, Fan ST. Safety of duct-to-duct biliary reconstruction in right-lobe live-donor liver transplantation without biliary drainage. *Transplantation* 2004; **77**: 726-732 [PMID: 15021836 DOI: 10.1097/01.TP.0000116604.89083.2F]
- 8 **Soejima Y**, Taketomi A, Yoshizumi T, Uchiyama H, Harada N, Ijichi H, Yonemura Y, Ikeda T, Shimada M, Maehara Y. Biliary strictures in living donor liver transplantation: incidence, management, and technical evolution. *Liver Transpl* 2006; **12**: 979-986 [PMID: 16721777 DOI: 10.1002/lt.20740]
- 9 **Shah SA**, Grant DR, McGilvray ID, Greig PD, Selzner M, Lilly LB, Girgrah N, Levy GA, Cattral MS. Biliary strictures in 130 consecutive right lobe living donor liver transplant recipients: results of a Western center. *Am J Transplant* 2007; **7**: 161-167 [PMID: 17227565 DOI: 10.1111/j.1600-6143.2006.01601.x]
- 10 **Mita A**, Hashikura Y, Masuda Y, Ohno Y, Urata K, Nakazawa Y, Ikegami T, Terada M, Yamamoto H, Miyagawa S. Nonsurgical policy for treatment of bilioenteric anastomotic stricture after living donor liver transplantation. *Transpl Int* 2008; **21**: 320-327 [PMID: 18069923 DOI: 10.1111/j.1432-2277.2007.00609.x]
- 11 **Marubashi S**, Dono K, Nagano H, Kobayashi S, Takeda Y, Umeshita K, Monden M, Doki Y, Mori M. Biliary reconstruction in living donor liver transplantation: technical invention and risk factor analysis for anastomotic stricture. *Transplantation* 2009; **88**: 1123-1130 [PMID: 19898209 DOI: 10.1097/TP.0b013e3181ba184a]
- 12 **Kim SH**, Lee KW, Kim YK, Cho SY, Han SS, Park SJ. Tailored telescopic reconstruction of the bile duct in living donor liver transplantation. *Liver Transpl* 2010; **16**: 1069-1074 [PMID: 20818745 DOI: 10.1002/lt.22116]
- 13 **Mizuno S**, Inoue H, Tanemura A, Murata Y, Kuriyama N, Azumi Y, Kishiwada M, Usui M, Sakurai H, Tabata M, Yamada R, Yamamoto N, Sugimoto K, Shiraki K, Takei Y, Isaji S. Biliary complications in 108 consecutive recipients with duct-to-duct biliary reconstruction in living-donor liver transplantation. *Transplant Proc* 2014; **46**: 850-855 [PMID: 24767364 DOI: 10.1016/j.transproceed.2013.11.035]
- 14 **Wadhawan M**, Kumar A, Gupta S, Goyal N, Shandil R, Taneja S, Sibal A. Post-transplant biliary complications: an analysis from a predominantly living donor liver transplant center. *J Gastroenterol Hepatol* 2013; **28**: 1056-1060 [PMID: 23432435 DOI: 10.1111/jgh.12169]
- 15 **Vij V**, Makki K, Chorasiya VK, Sood G, Singhal A, Dargan P. Targeting the Achilles' heel of adult living donor liver transplant: Corner-sparing sutures with mucosal eversion technique of biliary anastomosis. *Liver Transpl* 2016; **22**: 14-23 [PMID: 26390361 DOI: 10.1002/lt.24343]
- 16 **Dalgic A**, Moray G, Emiroglu R, Sozen H, Karakayali H, Boyacioglu S, Bilgin N, Haberal M. Duct-to-duct biliary anastomosis with a "corner-saving suture" technique in living-related liver transplantation. *Transplant Proc* 2005; **37**: 3137-3140 [PMID: 16213329 DOI: 10.1016/j.transproceed.2005.08.046]
- 17 **Castaldo ET**, Pinson CW, Feurer ID, Wright JK, Gorden DL, Kelly BS, Chari RS. Continuous versus interrupted suture for end-to-end biliary anastomosis during liver transplantation gives equal results. *Liver Transpl* 2007; **13**: 234-238 [PMID: 17256781 DOI: 10.1002/lt.20986]
- 18 **Soejima Y**, Fukuhara T, Morita K, Yoshizumi T, Ikegami T, Yamashita Y, Sugimachi K, Taketomi A, Maehara Y. A simple hilar dissection technique preserving maximum blood supply to the bile duct in living donor liver transplantation. *Transplantation* 2008; **86**: 1468-1469 [PMID: 19034019 DOI: 10.1097/TP.0b013e318188d4dc]
- 19 **Lin TS**, Concejero AM, Chen CL, Chiang YC, Wang CC, Wang SH, Liu YW, Yang CH, Yong CC, Jawan B, Cheng YF. Routine microsurgical biliary reconstruction decreases early anastomotic complications in living donor liver transplantation. *Liver Transpl* 2009; **15**: 1766-1775 [PMID: 19938121 DOI: 10.1002/lt.21947]
- 20 **Chok KS**, Chan SC, Cheung TT, Sharr WW, Chan AC, Lo CM, Fan ST. Bile duct anastomotic stricture after adult-to-adult right lobe living donor liver transplantation. *Liver Transpl* 2011; **17**: 47-52 [PMID: 21254344 DOI: 10.1002/lt.22188]
- 21 **Horster S**, Bäuerlein FJ, Mandel P, Raziorrouh B, Hopf C, Stemmler HJ, Guba M, Angele M, Stangl M, Rentsch M, Frey L, Kaspar M, Kaczmarek I, Eberle J, Nickel T, Gruener N, Zachoval R, Diepolder H. Influence of hepatitis C virus infection and high virus serum load on biliary complications in liver transplantation. *Transpl Infect Dis* 2013; **15**: 306-313 [PMID: 23489913 DOI: 10.1111/tid.12069]
- 22 **Mathur AK**, Nadig SN, Kingman S, Lee D, Kinkade K, Sonnenday CJ, Welling TH. Internal biliary stenting during orthotopic liver transplantation: anastomotic complications, post-transplant biliary interventions, and survival. *Clin Transplant* 2015; **29**: 327-335 [PMID: 25604635 DOI: 10.1111/ctr.12518]
- 23 **Ayoub WS**, Esquivel CO, Martin P. Biliary complications following liver transplantation. *Dig Dis Sci* 2010; **55**: 1540-1546 [PMID: 20411422 DOI: 10.1007/s10620-010-1217-2]
- 24 **Young SA**, Sfakianakis GN, Pyrsopoulos N, Nishida S. Hepatobiliary scintigraphy in liver transplant patients: the "blind end sign" and its differentiation from bile leak. *Clin Nucl Med* 2003; **28**: 638-642 [PMID: 12897647]
- 25 **Kok T**, Van der Sluis A, Klein JP, Van der Jagt EJ, Peeters PM, Slooff MJ, Bijleveld CM, Haagsma EB. Ultrasound and cholangiography for the diagnosis of biliary complications after orthotopic liver transplantation: a comparative study. *J Clin Ultrasound* 1996; **24**: 103-115 [PMID: 8838298]
- 26 **St Peter S**, Rodriguez-Davalos MI, Rodriguez-Luna HM, Harrison EM, Moss AA, Mulligan DC. Significance of proximal biliary dilatation in patients with anastomotic strictures after liver transplantation. *Dig Dis Sci* 2004; **49**: 1207-1211 [PMID: 15387348 DOI: 10.1023/B:DDAS.0000037814.96308.7a]
- 27 **Venu M**, Brown RD, Lepe R, Berkes J, Cotler SJ, Benedetti E, Testa G, Venu RP. Laboratory diagnosis and nonoperative management of biliary complications in living donor liver transplant patients. *J Clin Gastroenterol* 2007; **41**: 501-506 [PMID: 17450034 DOI: 10.1097/01.mcg.0000247986.95053.2a]
- 28 **Fulcher AS**, Turner MA. Orthotopic liver transplantation: evaluation with MR cholangiography. *Radiology* 1999; **211**: 715-722 [PMID: 10352596 DOI: 10.1148/radiology.211.3.r99jn17715]
- 29 **Kitazono MT**, Qayyum A, Yeh BM, Chard PS, Ostroff JW, Coakley FV. Magnetic resonance cholangiography of biliary strictures after liver transplantation: a prospective double-blind study. *J Magn Reson Imaging* 2007; **25**: 1168-1173 [PMID: 17520726 DOI: 10.1002/jmri.20927]
- 30 **Linhares MM**, Gonzalez AM, Goldman SM, Coelho RD, Sato NY, Moura RM, Silva MH, Lanzoni VP, Salzedas A, Serra CB, Succi T, D'Ippolito G, Szejnfeld J, Triviño T. Magnetic resonance cholangiography in the diagnosis of biliary complications after orthotopic liver transplantation. *Transplant Proc* 2004; **36**: 947-948 [PMID: 15194328 DOI: 10.1016/j.transproceed.2004.04.005]
- 31 **Kim YJ**, Lee KT, Jo YC, Lee KH, Lee JK, Joh JW, Kwon CH. Hepatobiliary scintigraphy for detecting biliary strictures after living donor liver transplantation. *World J Gastroenterol* 2011; **17**: 2626-2631 [PMID: 21677831 DOI: 10.3748/wjg.v17.i21.2626]
- 32 **Kurzawinski TR**, Selves L, Farouk M, Dooley J, Hilson A, Buscombe JR, Burroughs A, Rolles K, Davidson BR. Prospective study of hepatobiliary scintigraphy and endoscopic cholangiography for the detection of early biliary complications after orthotopic liver transplantation. *Br J Surg* 1997; **84**: 620-623 [PMID: 9171746 DOI: 10.1046/j.1365-2168.1997.02653.x]

- 33 **Lee SH**, Ryu JK, Woo SM, Park JK, Yoo JW, Kim YT, Yoon YB, Suh KS, Yi NJ, Lee JM, Han JK. Optimal interventional treatment and long-term outcomes for biliary stricture after liver transplantation. *Clin Transplant* 2008; **22**: 484-493 [PMID: 18318735 DOI: 10.1111/j.1399-0012.2008.00813.x]
- 34 **Beltrán MM**, Marugán RB, Oton E, Blesa C, Nuño J. Accuracy of magnetic resonance cholangiography in the evaluation of late biliary complications after orthotopic liver transplantation. *Transplant Proc* 2005; **37**: 3924-3925 [PMID: 16386586 DOI: 10.1016/j.transproceed.2005.10.044]
- 35 **Pasha SF**, Harrison ME, Das A, Nguyen CC, Vargas HE, Balan V, Byrne TJ, Douglas DD, Mulligan DC. Endoscopic treatment of anastomotic biliary strictures after deceased donor liver transplantation: outcomes after maximal stent therapy. *Gastrointest Endosc* 2007; **66**: 44-51 [PMID: 17591473 DOI: 10.1016/j.gie.2007.02.017]
- 36 **Hsieh TH**, Mekeel KL, Crowell MD, Nguyen CC, Das A, Aqel BA, Carey EJ, Byrne TJ, Vargas HE, Douglas DD, Mulligan DC, Harrison ME. Endoscopic treatment of anastomotic biliary strictures after living donor liver transplantation: outcomes after maximal stent therapy. *Gastrointest Endosc* 2013; **77**: 47-54 [PMID: 23062758 DOI: 10.1016/j.gie.2012.08.034]
- 37 **Rizk RS**, McVicar JP, Emond MJ, Rohrmann CA, Kowdley KV, Perkins J, Carithers RL, Kimmey MB. Endoscopic management of biliary strictures in liver transplant recipients: effect on patient and graft survival. *Gastrointest Endosc* 1998; **47**: 128-135 [PMID: 9512276 DOI: 10.1016/S0016-5107(98)70344-X]
- 38 **Morelli J**, Mulcahy HE, Willner IR, Cunningham JT, Draganov P. Long-term outcomes for patients with post-liver transplant anastomotic biliary strictures treated by endoscopic stent placement. *Gastrointest Endosc* 2003; **58**: 374-379 [PMID: 14528211 DOI: 10.1067/S0016-5107(03)00011-7]
- 39 **Schwartz DA**, Petersen BT, Poterucha JJ, Gostout CJ. Endoscopic therapy of anastomotic bile duct strictures occurring after liver transplantation. *Gastrointest Endosc* 2000; **51**: 169-174 [PMID: 10650259 DOI: 10.1016/S0016-5107(00)70413-5]
- 40 **Chang JH**, Lee IS, Choi JY, Yoon SK, Kim DG, You YK, Chun HJ, Lee DK, Choi MG, Chung IS. Biliary Stricture after Adult Right-Lobe Living-Donor Liver Transplantation with Duct-to-Duct Anastomosis: Long-Term Outcome and Its Related Factors after Endoscopic Treatment. *Gut Liver* 2010; **4**: 226-233 [PMID: 20559526 DOI: 10.5009/gnl.2010.4.2.226]
- 41 **Tashiro H**, Itamoto T, Sasaki T, Ohdan H, Fudaba Y, Amano H, Fukuda S, Nakahara H, Ishiyama K, Ohshita A, Kohashi T, Mitsuta H, Chayama K, Asahara T. Biliary complications after duct-to-duct biliary reconstruction in living-donor liver transplantation: causes and treatment. *World J Surg* 2007; **31**: 2222-2229 [PMID: 17885788 DOI: 10.1007/s00268-007-9217-x]
- 42 **Park JS**, Kim MH, Lee SK, Seo DW, Lee SS, Han J, Min YI, Hwang S, Park KM, Lee YJ, Lee SG, Sung KB. Efficacy of endoscopic and percutaneous treatments for biliary complications after cadaveric and living donor liver transplantation. *Gastrointest Endosc* 2003; **57**: 78-85 [PMID: 12518136 DOI: 10.1067/mge.2003.11]
- 43 **Hisatsune H**, Yazumi S, Egawa H, Asada M, Hasegawa K, Kodama Y, Okazaki K, Itoh K, Takakuwa H, Tanaka K, Chiba T. Endoscopic management of biliary strictures after duct-to-duct biliary reconstruction in right-lobe living-donor liver transplantation. *Transplantation* 2003; **76**: 810-815 [PMID: 14501859 DOI: 10.1097/01.TP.0000083224.00756.8F]
- 44 **Tsujino T**, Isayama H, Sugawara Y, Sasaki T, Kogure H, Nakai Y, Yamamoto N, Sasahira N, Yamashiki N, Tada M, Yoshida H, Kokudo N, Kawabe T, Makuuchi M, Omata M. Endoscopic management of biliary complications after adult living donor liver transplantation. *Am J Gastroenterol* 2006; **101**: 2230-2236 [PMID: 16952286 DOI: 10.1111/j.1572-0241.2006.00797.x]
- 45 **Kao D**, Zepeda-Gomez S, Tandon P, Bain VG. Managing the post-liver transplantation anastomotic biliary stricture: multiple plastic versus metal stents: a systematic review. *Gastrointest Endosc* 2013; **77**: 679-691 [PMID: 23473000 DOI: 10.1016/j.gie.2013.01.015]
- 46 **Martins FP**, Phillips M, Gaidhane MR, Schmitt T, Kahaleh M. Biliary leak in post-liver-transplant patients: is there any place for metal stent? *HPB Surg* 2012; **2012**: 684172 [PMID: 22619479]
- 47 **Kaffes A**, Griffin S, Vaughan R, James M, Chua T, Tee H, Dinesen L, Corte C, Gill R. A randomized trial of a fully covered self-expandable metallic stent versus plastic stents in anastomotic biliary strictures after liver transplantation. *Therap Adv Gastroenterol* 2014; **7**: 64-71 [PMID: 24587819 DOI: 10.1177/1756283X13503614]
- 48 **Zoepl T**, Maldonado de Dechêne EJ, Dechêne A, Malágo M, Beckebaum S, Paul A, Gerken G, Hilgard P. Optimized endoscopic treatment of ischemic-type biliary lesions after liver transplantation. *Gastrointest Endosc* 2012; **76**: 556-563 [PMID: 22898414 DOI: 10.1016/j.gie.2012.04.474]
- 49 **Yazumi S**, Yoshimoto T, Hisatsune H, Hasegawa K, Kida M, Tada S, Uenoyama Y, Yamauchi J, Shio S, Kasahara M, Ogawa K, Egawa H, Tanaka K, Chiba T. Endoscopic treatment of biliary complications after right-lobe living-donor liver transplantation with duct-to-duct biliary anastomosis. *J Hepatobiliary Pancreat Surg* 2006; **13**: 502-510 [PMID: 17139423 DOI: 10.1007/s00534-005-1084-y]
- 50 **Parsi MA**, Guardino J, Vargo JJ. Peroral cholangioscopy-guided stricture therapy in living donor liver transplantation. *Liver Transpl* 2009; **15**: 263-265 [PMID: 19177445 DOI: 10.1002/lt.21584]
- 51 **Yazumi S**, Chiba T. Biliary complications after a right-lobe living donor liver transplantation. *J Gastroenterol* 2005; **40**: 861-865 [PMID: 16211341 DOI: 10.1007/s00535-005-1698-5]
- 52 **Jang SI**, Kim JH, Won JY, Lee KH, Kim HW, You JW, Itoi T, Lee D. Magnetic compression anastomosis is useful in biliary anastomotic strictures after living donor liver transplantation. *Gastrointest Endosc* 2011; **74**: 1040-1048 [PMID: 21855872 DOI: 10.1016/j.gie.2011.06.026]
- 53 **Parlak E**, Küçükay F, Köksal AŞ, Eminler AT, Uslan Mİ, Yılmaz S. Recanalization of complete anastomotic biliary obstruction after living donor related liver transplantation with a novel through-the-scope magnet. *Liver Transpl* 2015; **21**: 711-712 [PMID: 25641753 DOI: 10.1002/lt.24084]
- 54 **Perez-Miranda M**, Aleman N, de la Serna Higuera C, Gil-Simon P, Perez-Saborido B, Sanchez-Antolin G. Magnetic compression anastomosis through EUS-guided choledochoduodenostomy to repair a disconnected bile duct in orthotopic liver transplantation. *Gastrointest Endosc* 2014; **80**: 520-521 [PMID: 25127949 DOI: 10.1016/j.gie.2014.06.042]
- 55 **Ersoz G**, Tekin F, Ozutemiz O, Tekesin O. A novel technique for biliary strictures that cannot be passed with a guide wire. *Endoscopy* 2007; **39** Suppl 1: E332 [PMID: 18273782 DOI: 10.1055/s-2007-966559]

P- Reviewer: Gassler N, Tekin F S- Editor: Kong JX

L- Editor: A E- Editor: Liu SQ





Published by **Baishideng Publishing Group Inc**

8226 Regency Drive, Pleasanton, CA 94588, USA

Telephone: +1-925-223-8242

Fax: +1-925-223-8243

E-mail: bpgoffice@wjgnet.com

Help Desk: <http://www.wjgnet.com/esps/helpdesk.aspx>

<http://www.wjgnet.com>

