

## Pharmacotherapy for the management of achalasia: Current status, challenges and future directions

Ammar Nassri, Zeeshan Ramzan

Ammar Nassri, Department of Internal Medicine, University of Texas at Austin Dell Medical School, Austin, TX 78701, United States

Zeeshan Ramzan, Gastrointestinal Section, Department of Internal Medicine, VA North Texas Healthcare System, Dallas, TX 75216, United States

Zeeshan Ramzan, Department of Medicine, Division of Gastroenterology and Hepatology, University of Texas Southwestern Medical Center at Dallas, Dallas, TX 75390, United States

**Author contributions:** Nassri A and Ramzan Z contributed equally to this work.

**Conflict-of-interest statement:** The authors have no conflicts of interest.

**Open-Access:** This article is an open-access article which was selected by an in-house editor and fully peer-reviewed by external reviewers. It is distributed in accordance with the Creative Commons Attribution Non Commercial (CC BY-NC 4.0) license, which permits others to distribute, remix, adapt, build upon this work non-commercially, and license their derivative works on different terms, provided the original work is properly cited and the use is non-commercial. See: <http://creativecommons.org/licenses/by-nc/4.0/>

**Correspondence to:** Zeeshan Ramzan, MD, Assistant Professor, Gastrointestinal Section, Department of Internal Medicine, VA North Texas Healthcare System, 4500 S. Lancaster Road, Dallas, TX 75216, United States. [zeeshanramzan@hotmail.com](mailto:zeeshanramzan@hotmail.com)  
Telephone: +1-214-8571591

Received: June 24, 2015

Peer-review started: June 26, 2015

First decision: August 26, 2015

Revised: September 6, 2015

Accepted: October 16, 2015

Article in press: October 19, 2015

Published online: November 6, 2015

### Abstract

This article reviews currently available pharmacological options available for the treatment of achalasia, with a special focus on the role of botulinum toxin (BT) injection due to its superior therapeutic effect and side effect profile. The discussion on BT includes the role of different BT serotypes, better pharmacological formulations, improved BT injection techniques, the use of sprouting inhibitors, designer recombinant BT formulations and alternative substances used in endoscopic injections. The large body of ongoing research into achalasia and BT may provide a stronger role for BT injection as a form of minimally invasive, cost effective and efficacious form of therapy for patients with achalasia. The article also explores current issues and future research avenues that may prove beneficial in improving the efficacy of pharmacological treatment approaches in patients with achalasia.

**Key words:** Botulinum toxin; Pharmacotherapy; Botox; Achalasia; Sprouting inhibitors

© **The Author(s) 2015.** Published by Baishideng Publishing Group Inc. All rights reserved.

**Core tip:** Botulinum toxin (BT) injection is the most common and effective pharmacological therapy used in the treatment of achalasia, and is commonly used in the elderly, those with multiple comorbidities, patients at high risk for surgery and as a salvage therapy. This article discusses new advances related to the pharmacological management of achalasia that may help to optimize minimally invasive treatment approaches in patients with achalasia, and discusses improvements in endoscopic injection techniques, the use of sclerosants, new BT formulations, alternate serotypes, sprouting inhibitors and designer recombinant BT formulations.

Nassri A, Ramzan Z. Pharmacotherapy for the management of achalasia: Current status, challenges and future directions. *World J Gastrointest Pharmacol Ther* 2015; 6(4): 145-155 Available from: URL: <http://www.wjgnet.com/2150-5349/full/v6/i4/145.htm> DOI: <http://dx.doi.org/10.4292/wjgpt.v6.i4.145>

## INTRODUCTION

Esophageal achalasia is an idiopathic motility disorder characterized by an incomplete relaxation of the lower esophageal sphincter (LES) in response to swallowing as well as aperistalsis in the esophagus resulting in impaired food bolus transport<sup>[1]</sup>. First described by Sir Thomas Willis in 1674, it was not until 1928 with the work of Hurst<sup>[2]</sup> and Rake<sup>[3]</sup> that the pathophysiology was realized to be a failure in LES relaxation.

Clinically, dysphagia is the most common presenting symptom in patients with achalasia. Other symptoms may include regurgitation, chest pain, heartburn, weight loss, postprandial aspiration and nocturnal coughing<sup>[4]</sup>. The incidence of achalasia in studies ranges between 0.5-1.2/100000 per year<sup>[5]</sup> and the estimated prevalence is around 10/100000<sup>[6]</sup>. There does not seem to be a distinct pattern of incidence as it occurs equally in both sexes, all races and at any age<sup>[5]</sup>.

Although the cause of idiopathic achalasia is largely unknown, the general pathophysiology has been studied extensively. There is a hallmark loss of esophageal nitric oxide-inhibitory postganglionic neurons in the myenteric plexus of the lower esophagus<sup>[7]</sup>. The excitatory neurons remain unaffected, leading to an imbalance between excitatory and inhibitory neurons and resultant increase in LES pressure<sup>[8]</sup>. However, it is as of yet still unclear as to why there is a loss of these enteric neurons in patients who develop idiopathic achalasia. There is evidence to support a combination of autoimmune, infectious and genetic factors. It is now accepted that a viral or unknown environmental trigger causes an inflammatory cell infiltrate of the myenteric plexus, which in genetically predisposed individuals triggers an autoimmune response causing destruction of the inhibitory myenteric ganglion<sup>[8,9]</sup>.

Diagnostic evaluation includes endoscopy, radiological imaging and esophageal manometry. Upper endoscopy may reveal resistance while traversing the LES with the endoscope, described as a "pop" sensation in the literature. Barium esophagogram shows a classic "bird's beak" appearance in the region of the LES which is highly suggestive of achalasia. However, esophageal manometry revealing incomplete LES relaxation and aperistalsis in the esophageal body is considered the gold standard investigation for diagnosis<sup>[1]</sup>.

There is no curative treatment for achalasia. The most effective form of treatment is a myotomy which can be performed endoscopically or surgically. Endoscopic myotomy can be performed by pneumatic balloon dilation or *via* a new procedure called peroral

endoscopic myotomy (POEM). Surgical options include the laparoscopic Heller myotomy which is routinely accompanied by fundoplication to decrease the risk of severe symptomatic gastroesophageal reflux disease (GERD), as well as older open techniques which are now rarely used<sup>[10]</sup>. Medical forms of treatment primarily include the injection of botulinum toxin (BT) into the LES, nitrates and calcium channel blockers. BT is the most effective and commonly used pharmacological agent and will be discussed in detail in the subsequent sections.

## BT FOR ACHALASIA

### History

Since its use was first described in 1977 in children with strabismus, BT has been increasingly used in various fields and diseases, from the treatment of focal dystonias, spasticity and urinary incontinence to becoming the most widely used injection in cosmetic procedures worldwide<sup>[11,12]</sup>.

The use of BT for the treatment of achalasia was first described by Pasricha *et al.*<sup>[13]</sup> in 1994 in a pilot study, which was followed by a double blinded trial<sup>[14]</sup> in which patients with achalasia were randomized to treatment either with BT injection or placebo (saline) injection into the LES. At one week, 90% of the BT injection group showed significant symptom reduction and a significant decrease in mean LES pressure. At 6 mo approximately two thirds of the patients were still in remission. Since the publication of this seminal study many studies have investigated the role of BT in the management of achalasia<sup>[15]</sup>.

### Pharmacology and mechanism of action

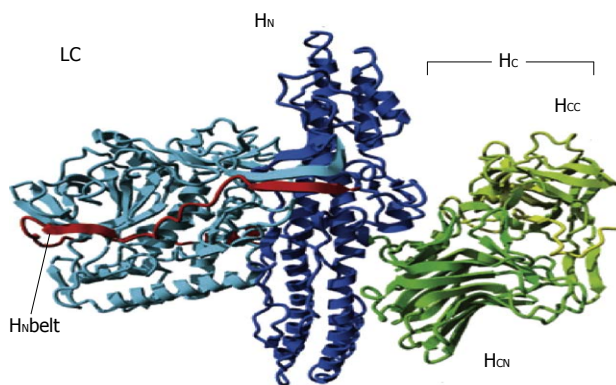
Every BT serotype is initially synthesized as a 150 kDa neurotoxin polypeptide chain with low intrinsic activity along with a set of neuro-toxin associated proteins (NAP), which are believed to protect the neurotoxin from proteases in the gastrointestinal tract<sup>[16]</sup>. The BT precursor is cleaved *in vivo* into a 100 kDa heavy chain (HC) and 50 kDa light chain (LC) linked by a disulfide bridge as well as a poorly structured protein segment called the belt. The HC can functionally be split into the heavy chain carboxy terminus (H-C) and heavy chain amino terminus (H-N) (Figure 1). The H-C, which can further be split into two subdomains, is responsible for neuronal receptor recognition and binding whilst the H-N is responsible for facilitating translocation of the LC into the cytosol<sup>[17]</sup>. The HC binds to transiently expressed specific cell receptors as well as to a polysialoganglioside, the disulfide bond is reduced and the light chain is internalized by exploiting synaptic vesicle recycling and diffusing into the cytosol. BT has a high affinity and specificity for target cells and requires two different co-receptors found on the neuronal surface, although different serotypes have different receptors<sup>[12]</sup>.

Once inside the cell, the light chain proceeds to cleave one or more of the soluble NSF-attachment protein

**Table 1** Properties of commercially available botulinum toxin drugs

	<b>Botox®</b>	<b>Dysport®</b>	<b>Xeomin®</b>	<b>NeuroBloc® Myobloc®</b>
Manufacturer	Allergan Inc. Irvine, CA, United States	Ipsen Pharma Boulogne- Billancourt, France	Merz Pharmaceuticals Frankfurt/M, Germany	United States WorldMeds Louisville, KY, United States
Pharmaceutical preparation	Powder	Powder	Powder	Ready-to-use solution 5000 MU-E/mL
Storage conditions	Below 8 °C	Below 8 °C	Below 25 °C	Below 8 °C
Shelf life	36 mo	24 mo	36 mo	24 mo
Botulinum toxin type	A	A	A	B
Clostridium botulinum strain	Hall A	Ipsen strain	Hall A	Bean B
SNARE target	SNAP25	SNAP25	SNAP25	VAMP
Purification process	Precipitation and chromatography	Precipitation and chromatography	Precipitation and chromatography	Precipitation and chromatography
pH-value of the reconstituted preparation	7.4	7.4	7.4	5.6
Stabilisation	Vacuum drying	Freeze-drying (lyophilisate)	Vacuum drying	pH-reduction
Excipients	Human serum albumin 500 µg/100 MU-vial; NaCl 900 µg/100 MU-vial buffer system	Human serum albumin 125 µg/500 MU-vial; Lactose 2500 µg/100 MU-vial buffer system	Human serum albumin 1000 µg/100 MU-vial; Sucrose 4.7 mg/100 MU-vial buffer system	Human serum albumin 500 µg/mL; Disodium succinate 0.01 mol/L; Sodium chloride 0.1 mol/L; H <sub>2</sub> O; Hydrochloric acid
Biological activity	50/100 MU-A/vial	500 MU-I/vial	50/100 MU-M/vial	1.0/2.5/10.0 kMU-E/vial
Biological activity in relation to Botox®	1	1:2-1:3	1	1:40
Specific biological activity	60 MU-EV/ngBNT	100 MU-EV/ngBNT	167 MU-EV/ngBNT	5 MU-EV/ngBNT

SNARE: Soluble NSF-attachment protein receptor; NSF: N-ethylmaleimide-sensitive fusion protein; SNAP-25: Synaptosomal-associated protein of 25 kDa; BNT: Botulinum neurotoxin; MU-A: Mouse unit in the Allergan mouse lethality assay; MU-E: Mouse unit in the Solstice mouse lethality assay; MU-I: Mouse unit in the Ipsen mouse lethality assay; MU-M: Mouse unit in the Merz mouse lethality assay; MU-EV: Equivalence mouse unit. 1 MU-EV = 1 MU-A = 1 MU-M = 3 MU-I = 40 MU-E. Adapted with permission from Dressler<sup>[11]</sup>.



**Figure 1** Structure of botulinum toxin A. The Cα backbone is represented as ribbons with the LC in cyan, the HN in dark blue and the HC in a green to yellow gradient highlighting the HCN and HCC subdomains. The HN belt is in red. HN + HC: 100 kDa heavy chain; HN: 50 kDa amino terminus; HC: 50 kDa carboxy terminal of the heavy chain; HCC: β-beta tree foil fold heavy chain subdomain; HCN: β-sheet jelly roll fold heavy chain subdomain; LC: Light chain. Adapted with permission from Montal<sup>[17]</sup>.

receptor (SNARE) complex proteins, which are required for synaptic vesicle fusion with the active zone of the neuronal synapse (Figure 2). Cleavage by BT causes impairment of vesicle fusion and inhibition of synaptic activity<sup>[16]</sup>.

Although the effects of BT on the nerve terminal are long lasting, they are however reversible and do not lead to neurodegeneration<sup>[18]</sup>. After inhibition of synaptic vesicle fusion by BT, neuronal sprouts begin to develop from motor nerve terminals that establish synaptic activity. Ultimately, synaptic activity at the motor neuron

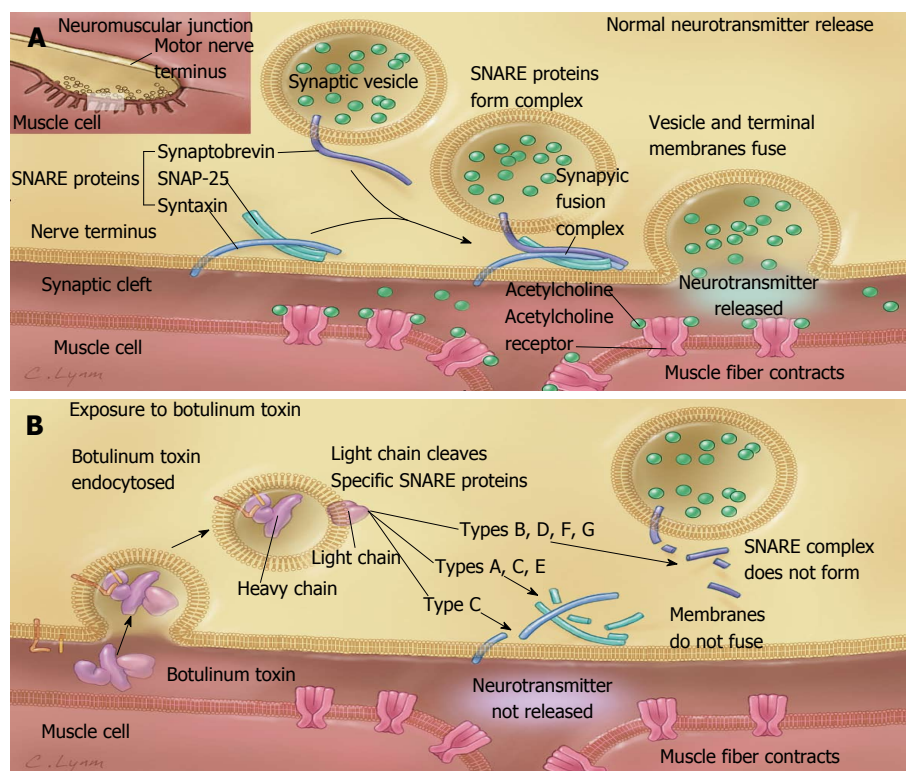
endplate is restored, and the neuronal sprouts retract completely<sup>[18,19]</sup>.

### Formulations (Table 1)

BT is commercially produced by the anaerobic fermentation of *Clostridium botulinum* although in nature it is also produced by other related species such as *C. barati* and *C. butyricum*<sup>[16]</sup>. There are eight immunologically distinct serotypes of Botulinum identified, with type H being only recently discovered<sup>[20]</sup>.

As of now, the Food and Drug Administration (FDA) has approved two serotypes, type A and type B for use in humans for various clinical indications. There are seven subtypes of BT (A) (A1-A7) that have been described, but all three formulations of BT (A) available for clinical use in patients with achalasia are of the A1 subtype. They include Abobotulinum (ABO; Dysport®/Azzalure®), Incobotulinum (INCO; Xeomin®/Bocouture®) and Onabotulinum (ONA; Botox®/Vistabel®). BT (A) is the most widely used and best studied formulations of BT<sup>[21]</sup>. Although Rimaotulinumtoxin B (Neurobloc®/Myobloc®) is available commercially, it has not been widely studied in patients with achalasia.

The biological activity of BT is measured in a mouse lethality assay (LD<sub>50</sub>), *i.e.*, the dose of toxin capable of killing 50% of a group of mice, and units are given in mouse units (MU)<sup>[11]</sup>. Concern for mouse welfare has prompted the investigation of more humane cell-based assays, with several being proposed such as the recently published compound muscle action potential assay<sup>[22]</sup>. The different formulations of BT (A) have varying



**Figure 2 Mechanism of action of botulinum neurotoxin.** A: Release of acetylcholine at the neuromuscular junction is mediated by the assembly of a synaptic fusion complex that allows the membrane of the synaptic vesicle containing acetylcholine to fuse with the neuronal cell membrane. The synaptic fusion complex is a set of SNARE proteins, which include synaptobrevin, SNAP-25, and syntaxin. After membrane fusion, acetylcholine is released into the synaptic cleft and then bound by receptors on the muscle cell; B: Botulinum toxin binds to the neuronal cell membrane at the nerve terminus and enters the neuron by endocytosis. The light chain of botulinum toxin cleaves specific sites on the SNARE proteins, preventing complete assembly of the synaptic fusion complex and thereby blocking acetylcholine release. Botulinum toxins types B, D, F, and G cleave synaptobrevin; types A, C, and E cleave SNAP-25; and type C cleaves syntaxin. Without acetylcholine release, the muscle is unable to contract. SNARE: Soluble NSF-attachment protein receptor; NSF: N-ethylmaleimide-sensitive fusion protein; SNAP-25: Synaptosomal-associated protein of 25 kD. Reproduced with permission from Aron *et al*<sup>[9]</sup>.

potencies which have been compared in several studies. One MU of ONA has been shown to be equivalent to 1 MU of INCO<sup>[23-25]</sup>, whilst a conversion rate of 1 MU: 2-3 MU between ONA and ABO has been proposed in various studies<sup>[26,27]</sup>, as well as 1:2.5 for aesthetic indications<sup>[25]</sup>.

The potency of BT (A) and BT (B) is difficult to compare directly. BT (B) has relatively weaker motor side effects and stronger autonomic effects than BT (A), even when used at standard dose. In one study for example, patients who received BT (B) reported higher incidences of constipation and lower saliva production<sup>[28]</sup>.

All of the currently available BT (A) drugs are sold in powdered form and have to be reconstituted, whereas BT (B) (Neurobloc®/Myobloc®) is available as a ready to use solution. In addition, only INCO can be stored at room temperatures while the other formulations need special storage temperatures<sup>[11]</sup>.

In the available commercial formulations, BT is stored with excipients such as NaCl/lactose/sucrose as well as albumin to decrease the risk of inactivation during preparation and storage. Out of the three formulations of BT (A), ABO has the least amount of albumin, which may partially explain the lower amount of available toxin per injected unit, as well as the shorter shelf life and decreased duration of stability after reconstitution

compared to ONA and INCO<sup>[12]</sup>.

### Dosages and techniques

The technique used to inject BT into the LES is still largely followed as described in the pilot study by Pasricha *et al*<sup>[13]</sup>. The LES is visually identified during upper endoscopy and aliquots containing 20-25 U of BT (A) are injected in quadrants for a total of 80-100 U.

Several studies have used slightly different techniques in their studies, although to date there are no randomized controlled trials comparing these different methodologies. In one study, patients received two injections spaced 1 cm apart in each of four quadrants for a total of eight injections equaling 100 U of BT (A). The response rate was 89.65% at 30 d and 55.17% at one year but fell to 13.79% at 2 years<sup>[29]</sup>. In another study involving seven patients, 100 U of BT (A) was injected in eight aliquots, with four injections each at the LES and approximately 4 cm above the LES, respectively<sup>[30]</sup>. At follow up, only 28.6% of patients were in remission.

Other investigators have attempted to find the optimal dose of BT. In one study<sup>[31]</sup>, 118 achalasia patients were randomized into three treatment arms to receive 50 U, 100 U or 200 U of BT (A). At 30 d, 82%



of patients were considered responders, and based on symptom scores the proportion of responders was slightly higher in the higher dose group, albeit not statistically significant. Similarly, the change in LES pressure was comparable in all three groups. To determine whether the timing of administration had any effect on duration of action, responders to 100 U of BT (A) were injected with a similar dose of 100 U 30 d later. At the end of follow up, patients that received 2 doses of 100 U 30 d apart were found to be more likely in remission (19%,  $P < 0.04$ ) compared to 47% and 43% in the 50 U group and single dose 200 U group respectively. This study demonstrated a statistically insignificant therapeutic effect with dose escalation of BT, but clearly showed decrease in relapse rates with repeat BT injection.

### Safety and side effects

BT (A) injection into the LES is extremely well tolerated, with the most common side effect usually being transient chest pain<sup>[32]</sup>. On the other hand, BT-B, by virtue of its stronger anticholinergic effects, has been noted to cause autonomic side effects like dry mouth and jitteriness even in small doses<sup>[11]</sup>.

### Efficacy in achalasia

BT injection is considered effective in the short term, but has a high rate of relapse requiring a need for reinjection. For example, one meta-analysis<sup>[33]</sup> evaluated nine studies with a total of 315 patients, and found that the rate of symptomatic improvement at one month to be 78.7%, but gradually decreased to 70% at 3 mo, 53.3% at 6 mo and 40.6% at 1 year. Furthermore, at least a second treatment was required in 46.6% of patients. Generally speaking, there is almost universal symptom relapse by two years<sup>[34]</sup>, although some studies have shown continued efficacy in up to 34% of patients at two years<sup>[35]</sup>. The efficacy of BT with repeat injections decreases and is thought to be secondary to antibody formation.

### Current role in treatment

Overall, pneumatic dilation and myotomy have superior long term efficacy than BT injection in treating patients with achalasia<sup>[10]</sup>.

In a Cochrane review comparing BT with pneumatic dilation, there was no significant difference in rates of remission at 4 wk after intervention. However, BT was significantly less effective in maintaining symptom remission at six months and one year<sup>[33]</sup>.

Similarly, one meta-analysis analyzed studies comparing pneumatic dilation with BT injection and found a remission rate of 65.8% at one year for pneumatic dilation compared to 36% for BT injection (RR = 2.20, 95%CI: 1.51-3.20,  $P < 0.0001$ )<sup>[36]</sup>.

In a prospective randomized study evaluating BT injection with Heller myotomy, the authors found that results at 6 mo were comparable; however, the efficacy of BT injection decreased thereafter and the probability

of being symptom free at 2 years was 87.5% after Heller myotomy and only 34% after BT injection ( $P < 0.05$ )<sup>[35]</sup>.

POEM is a novel endoscopic treatment for achalasia which is a minimally invasive alternative to conventional Heller myotomy. Although to our knowledge no prospective trials have compared BT injection to POEM, various studies have compared Heller myotomy with POEM and found favorable results. One meta-analysis evaluating a total of four studies found that POEM had comparable complications [odds ratio (OR) = 1.17, 95%CI: 0.53-2.56,  $P = 0.70$ ] and symptom recurrence (OR = 0.24, 95%CI: 0.04-1.55,  $P = 0.13$ ) as Heller Myotomy on short term follow up<sup>[37]</sup>.

The response to BT seems to be unaffected by prior therapy such as prior pneumatic dilation or myotomy, which highlights an important role for BT injection in patients who have failed prior surgical or endoscopic therapy. In one study<sup>[38]</sup>, the response to BT injection in achalasia was compared in patients without prior therapy, with prior dilation and with prior myotomy. Neither LES pressures nor symptom scores differed between groups. At 6 mo the remission rate was 71.4% in those who received prior dilation, 71.4% in prior myotomy and 73.9% in prior BT injection.

Pneumatic dilation comes with recognized risks, including esophageal perforation (approximately 1.6%) as well as symptomatic heartburn in up to 45% of patients<sup>[33]</sup>. Likewise, myotomy may be associated with risks, most noticeably esophageal perforation and postoperative GERD<sup>[39]</sup>, and due to the nature of the procedure may not be suitable for patients with multiple comorbidities or at high risk.

For this reason, several expert guidelines have suggested that BT injection may play a role in the elderly, in patients with extensive co-morbidities or who are poor surgical candidates and as a salvage therapy in patients who have failed other therapeutic modalities<sup>[1,39-43]</sup>.

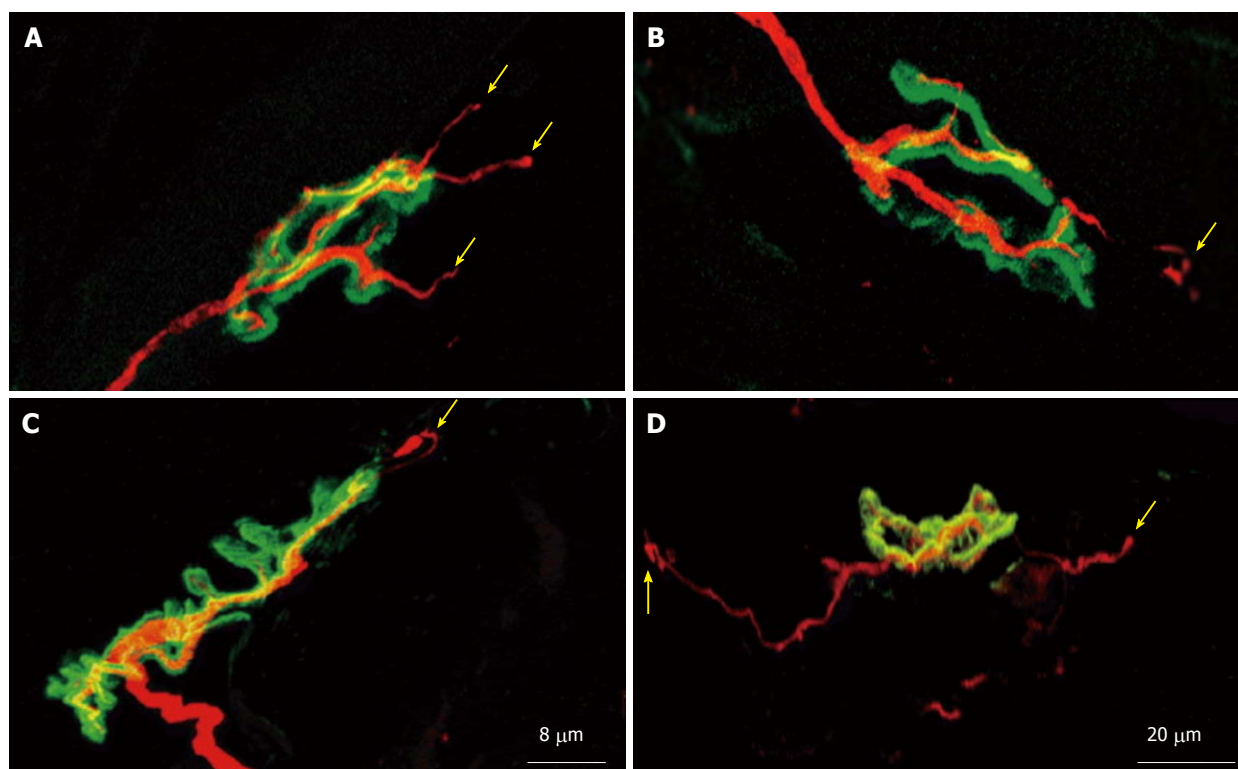
## FUTURE DIRECTIONS

### Inhibition of sprouting

As mentioned previously, the major cause of BT's limited long term efficacy is the sprouting phenomenon, in which the presynaptic nerve terminals begin to produce sprouting nerve collaterals with a corresponding increase in acetylcholine receptors and ultimately restoration of conduction at the neuromuscular junction (Figure 3).

Several animal model studies investigating nerve sprouting demonstrated a complex array of neural factors and neuroreceptors upregulated and involved in the process of neuronal regeneration and sprout formation, including nerve growth factor (NGF), brain-derived neurotrophic factor (BDNF), glial cell line derived neurotrophic factor (GDNF) and insulin-like growth factor 1 (IGF-1)<sup>[44-48]</sup>.

A limited number of studies have investigated the effect of neutralizing substances against these factors



**Figure 3** Neuronal sprouting and remodeling of the neuromuscular junction. Remodeling of the neuromuscular junction in extensor digitorum longus muscle at 10 (A-C) and 21 d (D) after a single injection of botulinum neurotoxin type C. Axons and nerve terminals were immunolabelled (red). To localize the junctions, nicotinic acetylcholine receptors were stained (green). Note the sprouts that emerge from the original motor endplate and project along muscle fibers (yellow arrows). Reproduced with permission from Morbiato *et al.*<sup>[50]</sup>.

on the process of sprout formation, as well as the effects of co-injection of alternate substances with BT in hopes of decreasing the rate of neuronal sprouting and thereby increasing the duration of action and efficacy of BT injection. In a murine model Streppel *et al.*<sup>[49]</sup> demonstrated that neutralizing antibodies to NGF, BDNF, and IGF1 significantly reduced nerve sprouting. In an animal model, Harrison *et al.*<sup>[50]</sup> demonstrated that injection of anti-IGF1 or corticotropin-releasing factor after BT injection reduced axonal sprouting, prevented the up regulation of neuromuscular junctions and increased duration of BT efficacy.

Ricin-mAb35 is an immunotoxin composed of ricin, a toxin that inhibits protein synthesis, conjugated to a monoclonal antibody to the nicotinic acetylcholine receptor. Christiansen *et al.*<sup>[51]</sup> found that injection of BT followed by Ricin-mAb35 into animal optic muscles resulted in decreased twitch and tetanic force at 6 mo compared to BT alone. Most recently, Jiang *et al.*<sup>[52]</sup> investigated the adjunct use of acrylamide injection to botulinum toxin injection. Acrylamide is a cumulative dose related neurotoxin that causes retrograde necrotizing neuropathy. Acrylamide injection after BT injection in the gastrocnemius muscles of rats was found to inhibit nerve sprouting as measured by electromyography and pathological observation of nerve fibers per unit. In this study, after the injection of BT (A) plus acrylamide, the increase in the number of nerve fibers was significantly reduced, the peak time of sprouting was delayed to 8-10 wk, and the peak nerve

fiber counts were significantly lower than that in the BT-A group ( $10.65 \pm 0.32 \times 10^8/\text{m}^2$  vs  $14.33 \pm 0.45 \times 10^8/\text{m}^2$ ,  $P < 0.05$ ).

No study has yet investigated use of BT injection with sprouting inhibitors in achalasia models. Hence, it remains to be seen if this can prolong the therapeutic efficacy of BT injection in patients with achalasia.

#### Use of specific subtypes of BT (A)

As mentioned above, as of now studies have primarily utilized BT (A) for achalasia. Of the three formulations of BT (A) that are available on the market (ABO, ONA INCO), INCO (Xeomin®, Boucuture®) differs from ABO and ONA in that only the 150 kDa neurotoxin itself is included and is devoid of the NAPs that are included in the ABO and ONA formulations. NAPs are naturally produced with the neurotoxin and are thought to protect the toxin from proteolytic and acidic degradation whilst in the gastrointestinal tract<sup>[12]</sup>. However, they are not known to play a role in the neurotoxin induced blockade of cholinergic transmission. Building on previous animal studies that demonstrated increased immune response and presence of neutralizing antibodies in BT (A) complex compared to pure BT (A), Wang *et al.*<sup>[53]</sup> recently studied the inflammatory cytokine release between human neuroblastoma cells treated with pure BT (A), BT (A) + NAPs complex or NAPs alone. They found that exposure to BT (A) + NPA complex significantly increased release of IL-6, MCP-1, IL-8, TNF- $\alpha$  and RANTES compared to controls.

In addition, it appears that while pure BT binds solely to neuronal cells, NAPs bind to neuronal as well as to non-neuronal cells, demonstrating that they may not simply be as passive as previously thought. It is likely that the hemagglutinins in the BT (A) complex bind to dendritic cells which act as antigen presenting cells in the early stages of the immune response. This is likely to result in increased immunogenicity and the formation of an immune response against the BT agent, although the level of antibody titers necessary to effect BT's clinical efficacy is unknown due to heterogeneity of available studies, and their presence may or may not affect patient's responsiveness to BT<sup>[12]</sup>.

Factors that decrease the efficacy of BT over time are poorly understood. Suboptimal reconstitution of BT by physicians may decrease the efficacy of the BT preparation as shown in a recent study<sup>[54]</sup>. Similarly, it has been proposed that establishing practices to reduce the risk of neutralizing antibodies such as lower dosing frequency, longer treatment intervals, and lower number of injections may decrease the likelihood of their development<sup>[12,55]</sup>.

### Testing and availability of serotypes other than (A)/(B)

As of yet, only serotypes A and B have been FDA approved for use in human subjects<sup>[11]</sup>. However, almost all studies investigating the use of BT in achalasia patients were done using serotype A<sup>[15]</sup>. Hence, it is unknown if the other serotypes may prove more effective by decreasing the response of neutralizing antibodies or whether their use of different neuronal surface type receptors or cleavage of different SNARE proteins may prove less likely to elicit neuronal sprouting which is what primarily contributes towards the high relapse rate seen in achalasia patients treated with BT.

### Recombinant BT

Part of BT's unique attraction is its particularly long persistence in the neuron and prolonged mode of action. Interestingly, different BT serotypes have been found to have varying duration of action. For example, in one study BT (E) was found to exert its activity for only about 2-3 wk in murine models compared to around 10 mo with BT (A)<sup>[56]</sup>. However, BT (E) cleaves more C-terminal residues from synaptosomal-associated protein of 25 kD (SNAP-25) than BT (A) causing a greater disruption of exocytosis resulting in quicker and greater neurotransmission blockade<sup>[57]</sup>. Studies have shown that the differential persistence of BT (A) vs BT (E) may be secondary to different susceptibility of the LC to various ubiquitin-dependent proteolysis pathways in the neuron through its interaction with RING finger protein TRAF2<sup>[58]</sup>.

A few studies have investigated the translational applications of genetically modified BT. One study genetically fused BT (E) LC to an enzymatically inactive BT (A) mutant, resulting in an end product that had BT (A)'s stability and persistence, as well as BT (E)'s potent cleavage of SNAP-25 and resultant neuromuscular

paralysis<sup>[57]</sup>. Given BT ubiquitous use in many different fields, ongoing research to produce BT mutant strains that have stronger potency and persistence may prove beneficial in diseases such as achalasia.

### Improvisations in BT injection techniques

As of yet, the endoscopic injection procedure for achalasia has largely remained unchanged since first introduced by Pasricha *et al*<sup>[14]</sup>. BT injection into the LES is routinely performed during endoscopy, which may mean that precise injection into the LES may not be possible due to lack of visualization. This may contribute to the lower rates of efficacy of BT injection or early relapse in some patients.

The utility of endoscopic ultra sound (EUS) in achalasia patients was first reported by Devière *et al*<sup>[59]</sup> in 1989 using an early 7.5 MHz ultrasound endoscope to measure the thickness of the LES in achalasia patients. A subsequent case series demonstrated technical feasibility, safety and decrease in dysphagia scores in a series of four patients. However, the study included a very small sample size and there was no comparison between standard endoscopic injection and EUS-guided BT injection<sup>[60]</sup>. Recently, a study compared EUS-guided BT injection in achalasia patients compared to conventional endoscopic BT injection<sup>[61]</sup>. Patients that received EUS-guided injections benefited from higher rate of relief and significantly lower rate of symptomatic relapse.

In summary, there is no gold standard for injection technique or dosage of BT injected, with different authors utilizing different dosages and techniques. Randomized trials are needed to determine optimum dosage, formulation and technique of injection.

### Injection of sclerosing agents

Alternative agents for the treatment of achalasia have been investigated. Ethanolamine Oleate (EO) is a sclerosant which is FDA approved for the treatment of bleeding esophageal varices, and is also used for lower extremity varicosities and vascular lesions. EO is a synthetic salt comprising of ethanolamine and oleic acid. When injected, EO produces an inflammatory response resulting in necrosis and fibrosis in the epithelium and submucosal tissue. First investigated for the use in the treatment of achalasia by Moretó *et al*<sup>[62]</sup> over 20 years ago, a long term study has since been published evaluating the long term efficacy of EO injection<sup>[63]</sup>. The authors included 103 patients in the study, with a mean follow up of 84.5 mo for patients who received EO. The cumulative expectancy of being free from recurrence was 90% at 50 mo.

Niknam *et al*<sup>[64]</sup> investigated the long term efficacy of EO in patients with achalasia who were resistant or poor candidate for pneumatic dilation or surgery. Of 220 patients who were evaluated for inclusion, thirty one patients met the inclusion criteria. EO was injected into the LES three times at two week intervals, and followed for a duration of 30.16 ± 11.3 mo with primary endpoints

being symptomatic improvement on the achalasia symptom scale (ASS) and results of timed barium esophagram. At 1.5 mo post injection, the mean ASS, volume of barium and LES were significantly decreased compared to pretreatment ( $P = 0.0001$ ). Symptom score and volume of barium remained significantly improved at 6 mo and one year intervals. Recently, Mikaeli *et al.*<sup>[65]</sup> prospectively compared BT to EO in a cohort of patients who were poor candidates for pneumatic dilation or surgery. Out of the 189 patients evaluated, 10 were included in EO group vs 11 in the BT group, with a mean duration of  $27.38 \pm 16.49$  mo of follow up. No statistically significant differences were found between either treatment groups.

## NITRATES

The effects of short acting nitrates such as amyl or acetyl nitrate and sublingual nitroglycerin on achalasia patients was first evaluated by investigators in the 1940's and 1950's<sup>[66-69]</sup>, but their use was abandoned due to the short duration of action (less than 30 min) and significant side effects such as hypotension and headaches.

With the subsequent introduction and widespread use of isosorbide dinitrate, Gelfond *et al.*<sup>[70]</sup> evaluated its use in patients with achalasia and found significant clinical improvement in dysphagia and decrease in LES pressures on manometry. However, the use of nitrates in achalasia has been severely limited by its transient or poor efficacy in a significant subset of patients, high rate of tachyphylaxis, and high incidence of side effects such as headache and hypotension. Hence, nitrates have been poorly evaluated in high quality randomized controlled trials as was shown in a 2004 Cochrane review<sup>[71]</sup>.

The use of nitrates has largely been relegated for use in those patients unable or unwilling to undergo any other treatment modality, although even in this respect it has largely been replaced by calcium channel blockers, which have been shown to be better tolerated and have a larger body of data investigating their use.

## CALCIUM CHANNEL BLOCKERS

The efficacy of calcium channel blockers on achalasia was first investigated in the late 1970's and 1980's<sup>[72-76]</sup>. Calcium channel blockers inhibit cellular uptake of calcium, thereby impeding contraction and promoting relaxation. Nifedipine has been shown to decrease LES pressures and provide symptomatic relief, although with variable efficacy demonstrating benefit in between 50% and 90% of cases<sup>[77]</sup>. In one small prospective study where nifedipine was titrated to a dose of 10-30 mg before meals, the overall symptom scores decreased compared with placebo, but symptoms such as dysphagia, chest pain or regurgitation were still present on most days<sup>[78]</sup>.

Up to 30% of patients may experience significant side effects from calcium channel blockers such as

peripheral edema and headaches which may limit their clinical utility. In addition, tachyphylaxis is also an issue with calcium channel blockers and the use of these drugs often induces tolerance<sup>[79]</sup>. Only a handful of studies have looked at calcium channel blockers prospectively, and the studies are limited by short follow up and very small sample sizes<sup>[77]</sup>. Studies comparing nitrates and calcium channel blockers have suggested that nitrates work faster and may be more effective compared with nifedipine<sup>[76,80]</sup>, but have limited clinical use due to more significant side effects. In another study, nifedipine was prospectively compared with verapamil, and while verapamil also decreased mean LES pressures, it did not provide effective symptomatic relief compared with nifedipine<sup>[81]</sup>.

## OTHERS PHARMACOLOGICAL AGENTS

Other early studies have investigated the effect of different pharmacological agents on the LES in patients with achalasia. Administration of phosphodiesterase inhibitors such as sildenafil<sup>[82,83]</sup> was found to have a reduction in LES pressure in achalasia patients, as was carbutole, a beta 2 adrenergic agent<sup>[84]</sup>, morphine<sup>[85]</sup>, loperamide<sup>[86]</sup>, anticholinergics like cimetropium bromide<sup>[87]</sup> and butylscopolamine<sup>[88]</sup>, vasoactive intestinal peptide<sup>[89]</sup>, terbutaline<sup>[90]</sup> and aminophylline<sup>[90]</sup>. However, the clinical utility of these agents is not clear as they have only been studied in very small sample sizes demonstrating proof of concept results and short duration of action.

## CONCLUSION

BT injection into the LES is the most commonly used initial therapy in patients with achalasia. Although lauded for its remarkably safety profile and short time efficacy, issues with need for repeat injection and decreased efficacy over time have relegated it to use in patients unable to undergo more long lasting procedures such as myotomy and as a form of salvage therapy. However the large body of ongoing research into BT may provide a stronger role for BT injection as a form of minimally invasive, cost effective and efficacious form of therapy for patients with achalasia. Further research in achalasia models are needed to investigate the role of different BT serotypes, better pharmacological formulations, better BT injection techniques, the use of sprouting inhibitors, designer recombinant BT formulations and alternative substances used in endoscopic injections. In addition, as more research demonstrates an autoimmune component in the pathophysiology of achalasia, the need for studies investigating the use of immune therapy in achalasia models becomes ever important. Various medications like calcium channel blocker and nitrates have been shown to have a role in treatment, but their widespread use is limited largely by the high incidence of side effects. Newer oral pharmacological agents with high potency and fewer side effects may prove beneficial



as an alternative treatment modality in patients with achalasia.

## REFERENCES

- 1 **Triadafilopoulos G**, Boeckxstaens GE, Gullo R, Patti MG, Pandolfino JE, Kahrilas PJ, Duranceau A, Jamieson G, Zaninotto G. The Kagoshima consensus on esophageal achalasia. *Dis Esophagus* 2012; **25**: 337-348 [PMID: 21595779 DOI: 10.1111/j.1442-2050.2011.01207.x]
- 2 **Hurst A**. The treatment of achalasia of the cardia: so-called 'cardiospasm'. *Lancet* 1927; **209**: 618-619 [DOI: 10.1016/S0140-6736(00)73391-5]
- 3 **Rake A**. Achalasia and Degeneration of Auerbach's Plexus. *Proc R Soc Med* 1928; **21**: 1775-1777
- 4 **Fisichella PM**, Carter SR, Robles LY. Presentation, diagnosis, and treatment of oesophageal motility disorders. *Dig Liver Dis* 2012; **44**: 1-7 [PMID: 21697019 DOI: 10.1016/j.dld.2011.05.003]
- 5 **O'Neill OM**, Johnston BT, Coleman HG. Achalasia: a review of clinical diagnosis, epidemiology, treatment and outcomes. *World J Gastroenterol* 2013; **19**: 5806-5812 [PMID: 24124325 DOI: 10.3748/wjg.v19.i35.5806]
- 6 **Sadowski DC**, Ackah F, Jiang B, Svenson LW. Achalasia: incidence, prevalence and survival. A population-based study. *Neurogastroenterol Motil* 2010; **22**: e256-e261 [PMID: 20465592 DOI: 10.1111/j.1365-2982.2010.01511.x]
- 7 **Goldblum JR**, Whyte RI, Orringer MB, Appelman HD. Achalasia. A morphologic study of 42 resected specimens. *Am J Surg Pathol* 1994; **18**: 327-337 [PMID: 8141427 DOI: 10.1097/00000478-199404000-00001]
- 8 **Petersen RP**, Martin AV, Pellegrini CA, Oelschlager BK. Synopsis of investigations into proposed theories on the etiology of achalasia. *Dis Esophagus* 2012; **25**: 305-310 [PMID: 20002702 DOI: 10.1111/j.1442-2050.2009.01030.x]
- 9 **Latiano A**, Palmieri O, Bossa F, Latiano T, Corritore G, De Santo E, Martino G, Merla A, Valvano MR, Cuttitta A, Mazza T, Annese V, Andriulli A. Impact of genetic polymorphisms on the pathogenesis of idiopathic achalasia: Association with IL33 gene variant. *Hum Immunol* 2014; **75**: 364-369 [PMID: 24468584 DOI: 10.1016/j.humimm.2014.01.004]
- 10 **Rohof WO**, Boeckxstaens GE. Treatment of the patient with achalasia. *Curr Opin Gastroenterol* 2012; **28**: 389-394 [PMID: 22508324 DOI: 10.1097/MOG.0b013e328353af8f]
- 11 **Dressler D**. Clinical applications of botulinum toxin. *Curr Opin Microbiol* 2012; **15**: 325-336 [PMID: 22770659 DOI: 10.1016/j.mib.2012.05.012]
- 12 **Frevert J**. Pharmaceutical, biological, and clinical properties of botulinum neurotoxin type A products. *Drugs R D* 2015; **15**: 1-9 [PMID: 25559581 DOI: 10.1007/s40268-014-0077-1]
- 13 **Pasricha PJ**, Ravich WJ, Hendrix TR, Sostre S, Jones B, Kalloo AN. Treatment of achalasia with intrasphincteric injection of botulinum toxin. A pilot trial. *Ann Intern Med* 1994; **121**: 590-591 [PMID: 8085691 DOI: 10.7326/0003-4819-121-8-199410150-00006]
- 14 **Pasricha PJ**, Ravich WJ, Hendrix TR, Sostre S, Jones B, Kalloo AN. Intrasphincteric botulinum toxin for the treatment of achalasia. *N Engl J Med* 1995; **332**: 774-778 [PMID: 7862180 DOI: 10.1056/NEJM199503233321203]
- 15 **Ramzan Z**, Nassri AB. The role of Botulinum toxin injection in the management of achalasia. *Curr Opin Gastroenterol* 2013; **29**: 468-473 [PMID: 23695428 DOI: 10.1097/MOG.0b013e328362292a]
- 16 **Tighe AP**, Schiavo G. Botulinum neurotoxins: mechanism of action. *Toxicon* 2013; **67**: 87-93 [PMID: 23201505 DOI: 10.1016/j.toxicon.2012.11.011]
- 17 **Montal M**. Botulinum neurotoxin: a marvel of protein design. *Annu Rev Biochem* 2010; **79**: 591-617 [PMID: 20233039 DOI: 10.1146/annurev.biochem.051908.125345]
- 18 **de Paiva A**, Meunier FA, Molgó J, Aoki KR, Dolly JO. Functional repair of motor endplates after botulinum neurotoxin type A poisoning: biphasic switch of synaptic activity between nerve sprouts and their parent terminals. *Proc Natl Acad Sci USA* 1999; **96**: 3200-3205 [PMID: 10077661 DOI: 10.1073/pnas.96.6.3200]
- 19 **Meunier FA**, Lisk G, Sesardic D, Dolly JO. Dynamics of motor nerve terminal remodeling unveiled using SNARE-cleaving botulinum toxins: the extent and duration are dictated by the sites of SNAP-25 truncation. *Mol Cell Neurosci* 2003; **22**: 454-466 [PMID: 12727443 DOI: 10.1016/S1044-7431(02)00016-7]
- 20 **Dover N**, Barash JR, Hill KK, Xie G, Arnon SS. Molecular characterization of a novel botulinum neurotoxin type H gene. *J Infect Dis* 2014; **209**: 192-202 [PMID: 24106295 DOI: 10.1093/infdis/jit450]
- 21 **Truong DD**, Stenner A, Reichel G. Current clinical applications of botulinum toxin. *Curr Pharm Des* 2009; **15**: 3671-3680 [PMID: 19925419 DOI: 10.2174/138161209789271843]
- 22 **Torii Y**, Goto Y, Nakahira S, Ginnaga A. Establishment of alternative potency test for botulinum toxin type A using compound muscle action potential (CMAP) in rats. *Toxicon* 2014; **90**: 97-105 [PMID: 25110177 DOI: 10.1016/j.toxicon.2014.07.013]
- 23 **Poulain B**, Trevidic P, Clave M, Aharoni C, Baspeyras M, Bui P, Cartier H, Charavel MH, Coulon P, Dahan S, Dallara JM, Delonca D, Dumas L, Essayagh E, Galatoire O, Georgieu N, Grangier Y, Humbert P, Le Pillouer-Prost A, Mojjallal A. Clinical equivalence of conventional OnabotulinumtoxinA (900 KDa) and IncobotulinumtoxinA (neurotoxin free from complexing proteins - 150 KDa): 2012 multidisciplinary French consensus in aesthetics. *J Drugs Dermatol* 2013; **12**: 1434-1446 [PMID: 24301246]
- 24 **Lorenc ZP**, Kenkel JM, Fagien S, Hirmand H, Nestor MS, Sclafani AP, Sykes JM, Waldorf HA. Consensus panel's assessment and recommendations on the use of 3 botulinum toxin type A products in facial aesthetics. *Aesthet Surg J* 2013; **33**: 35S-40S [PMID: 23515197 DOI: 10.1177/1090820X13480479]
- 25 **Carruthers J**, Fournier N, Kerscher M, Ruiz-Avila J, Trindade de Almeida AR, Kaeuper G. The convergence of medicine and neurotoxins: a focus on botulinum toxin type A and its application in aesthetic medicine--a global, evidence-based botulinum toxin consensus education initiative: part II: incorporating botulinum toxin into aesthetic clinical practice. *Dermatol Surg* 2013; **39**: 510-525 [PMID: 23458295 DOI: 10.1111/dsu.12148]
- 26 **Ranoux D**, Gury C, Fondarai J, Mas JL, Zuber M. Respective potencies of Botox and Dysport: a double blind, randomised, crossover study in cervical dystonia. *J Neurol Neurosurg Psychiatry* 2002; **72**: 459-462 [PMID: 11909903 DOI: 10.1136/jnnp.72.4.459]
- 27 **Ravenni R**, De Grandis D, Mazza A. Conversion ratio between Dysport and Botox in clinical practice: an overview of available evidence. *Neurol Sci* 2013; **34**: 1043-1048 [PMID: 23576131 DOI: 10.1007/s10072-013-1357-1]
- 28 **Tintner R**, Gross R, Winzer UF, Smalky KA, Jankovic J. Autonomic function after botulinum toxin type A or B: a double-blind, randomized trial. *Neurology* 2005; **65**: 765-767 [PMID: 16157918 DOI: 10.1212/01.wnl.0000174433.76707.8c]
- 29 **Zhu Q**, Liu J, Yang C. Clinical study on combined therapy of botulinum toxin injection and small balloon dilation in patients with esophageal achalasia. *Dig Surg* 2009; **26**: 493-498 [PMID: 20090338 DOI: 10.1159/000229784]
- 30 **Gutschow CA**, Töx U, Leers J, Schäfer H, Prenzel KL, Hölscher AH. Botox, dilation, or myotomy? Clinical outcome of interventional and surgical therapies for achalasia. *Langenbecks Arch Surg* 2010; **395**: 1093-1099 [PMID: 20845045 DOI: 10.1007/s00423-010-0711-5]
- 31 **Annese V**, Bassotti G, Coccia G, Dinelli M, D'Onofrio V, Gatto G, Leandro G, Repici A, Testoni PA, Andriulli A. A multicentre randomised study of intrasphincteric botulinum toxin in patients with oesophageal achalasia. GISMAD Achalasia Study Group. *Gut* 2000; **46**: 597-600 [PMID: 10764700 DOI: 10.1136/gut.46.5.597]
- 32 **D'Onofrio V**, Annese V, Miletto P, Leandro G, Marasco A, Sodano P, Iaquinio G. Long-term follow-up of achalasic patients treated with botulinum toxin. *Dis Esophagus* 2000; **13**: 96-101; discussion 102-103 [PMID: 14601898 DOI: 10.1046/j.1442-2050.2000.00094.x]
- 33 **Campos GM**, Vittinghoff E, Rabl C, Takata M, Gadenstätter M, Lin F, Ciovia R. Endoscopic and surgical treatments for achalasia: a systematic review and meta-analysis. *Ann Surg* 2009; **249**: 45-57 [PMID: 19106675 DOI: 10.1097/SLA.0b013e31818e43ab]

- 34 **Allescher HD**, Storr M, Seige M, Gonzales-Donoso R, Ott R, Born P, Frimberger E, Weigert N, Stier A, Kurjak M, Rösch T, Classen M. Treatment of achalasia: botulinum toxin injection vs. pneumatic balloon dilation. A prospective study with long-term follow-up. *Endoscopy* 2001; **33**: 1007-1017 [PMID: 11740642 DOI: 10.1055/s-2001-18935]
- 35 **Zaninotto G**, Annese V, Costantini M, Del Genio A, Costantino M, Epifani M, Gatto G, D'onofrio V, Benini L, Contini S, Molena D, Battaglia G, Tardio B, Andriulli A, Ancona E. Randomized controlled trial of botulinum toxin versus laparoscopic heller myotomy for esophageal achalasia. *Ann Surg* 2004; **239**: 364-370 [PMID: 15075653 DOI: 10.1097/01.sla.0000114217.52941.c5]
- 36 **Wang L**, Li YM, Li L. Meta-analysis of randomized and controlled treatment trials for achalasia. *Dig Dis Sci* 2009; **54**: 2303-2311 [PMID: 19107596 DOI: 10.1007/s10620-008-0637-8]
- 37 **Wei M**, Yang T, Yang X, Wang Z, Zhou Z. Peroral esophageal myotomy versus laparoscopic Heller's myotomy for achalasia: a meta-analysis. *J Laparoendosc Adv Surg Tech A* 2015; **25**: 123-129 [PMID: 25683071 DOI: 10.1089/lap.2014.0454]
- 38 **Storr M**, Born P, Frimberger E, Weigert N, Rösch T, Meining A, Classen M, Allescher HD. Treatment of achalasia: the short-term response to botulinum toxin injection seems to be independent of any kind of pretreatment. *BMC Gastroenterol* 2002; **2**: 19 [PMID: 12175425]
- 39 **Stefanidis D**, Richardson W, Farrell TM, Kohn GP, Augenstein V, Fanelli RD. SAGES guidelines for the surgical treatment of esophageal achalasia. *Surg Endosc* 2012; **26**: 296-311 [PMID: 22044977 DOI: 10.1007/s00464-011-2017-2]
- 40 **Eckardt AJ**, Eckardt VF. Treatment and surveillance strategies in achalasia: an update. *Nat Rev Gastroenterol Hepatol* 2011; **8**: 311-319 [PMID: 21522116 DOI: 10.1038/nrgastro.2011.68]
- 41 **Pandolfino JE**, Gawron AJ. Achalasia: a systematic review. *JAMA* 2015; **313**: 1841-1852 [PMID: 25965233 DOI: 10.1001/jama.2015.2996]
- 42 **Katada N**, Sakuramoto S, Yamashita K, Shibata T, Moriya H, Kikuchi S, Watanabe M. Recent trends in the management of achalasia. *Ann Thorac Cardiovasc Surg* 2012; **18**: 420-428 [PMID: 23099422 DOI: 10.5761/atcs.ra.12.01949]
- 43 **Boeckstaens GE**, Zaninotto G, Richter JE. Achalasia. *Lancet* 2014; **383**: 83-93 [PMID: 23871090 DOI: 10.1016/S0140-6736(13)60651-0]
- 44 **Meyer M**, Matsuoka I, Wetmore C, Olson L, Thoenen H. Enhanced synthesis of brain-derived neurotrophic factor in the lesioned peripheral nerve: different mechanisms are responsible for the regulation of BDNF and NGF mRNA. *J Cell Biol* 1992; **119**: 45-54 [PMID: 1527172 DOI: 10.1083/jcb.119.1.45]
- 45 **Boyd JG**, Gordon T. Neurotrophic factors and their receptors in axonal regeneration and functional recovery after peripheral nerve injury. *Mol Neurobiol* 2003; **27**: 277-324 [PMID: 12845152]
- 46 **Raivich G**, Kreutzberg GW. Peripheral nerve regeneration: role of growth factors and their receptors. *Int J Dev Neurosci* 1993; **11**: 311-324 [PMID: 8356900 DOI: 10.1016/0736-5748(93)90003-V]
- 47 **McMahon SB**, Priestley JV. Peripheral neuropathies and neurotrophic factors: animal models and clinical perspectives. *Curr Opin Neurobiol* 1995; **5**: 616-624 [PMID: 8580713 DOI: 10.1016/0959-4388(95)80067-0]
- 48 **MacLennan AJ**, Devlin BK, Neitzel KL, McLaurin DL, Anderson KJ, Lee N. Regulation of ciliary neurotrophic factor receptor alpha in sciatic motor neurons following axotomy. *Neuroscience* 1999; **91**: 1401-1413 [PMID: 10391446 DOI: 10.1016/S0306-4522(98)00717-9]
- 49 **Streppel M**, Azzolin N, Dohm S, Guntinas-Lichius O, Haas C, Grothe C, Wevers A, Neiss WF, Angelov DN. Focal application of neutralizing antibodies to soluble neurotrophic factors reduces collateral axonal branching after peripheral nerve lesion. *Eur J Neurosci* 2002; **15**: 1327-1342 [PMID: 11994127 DOI: 10.1046/j.1460-9568.2002.01971.x]
- 50 **Harrison AR**, Berbos Z, Zaldivar RA, Anderson BC, Semmer M, Lee MS, McLoon LK. Modulating neuromuscular junction density changes in botulinum toxin-treated orbicularis oculi muscle. *Invest Ophthalmol Vis Sci* 2011; **52**: 982-986 [PMID: 21087967 DOI: 10.1167/iops.10-6427]
- 51 **Christiansen SP**, Anderson BC, McLoon LK. Botulinum toxin pretreatment augments the weakening effect of injection with ricin-mAb35 in rabbit extraocular muscle. *J AAPOS* 2008; **12**: 122-127 [PMID: 18258470 DOI: 10.1016/j.jaapos.2007.11.001]
- 52 **Jiang H**, Xiang Y, Hu X, Cai H. Acrylamide inhibits nerve sprouting induced by botulinum toxin type A. *Neural Regen Res* 2014; **9**: 1525-1531 [PMID: 25317170 DOI: 10.4103/1673-5374.139479]
- 53 **Wang L**, Sun Y, Yang W, Lindo P, Singh BR. Type A botulinum neurotoxin complex proteins differentially modulate host response of neuronal cells. *Toxicon* 2014; **82**: 52-60 [PMID: 24560879 DOI: 10.1016/j.toxicon.2014.02.004]
- 54 **Carey WD**. Incorrect reconstitution of incobotulinumtoxinA leads to loss of neurotoxin. *J Drugs Dermatol* 2014; **13**: 735-738 [PMID: 24918566]
- 55 **Lacy BE**, Weiser K, Kennedy A. Botulinum toxin and gastrointestinal tract disorders: panacea, placebo, or pathway to the future? *Gastroenterol Hepatol* (NY) 2008; **4**: 283-295 [PMID: 21960915]
- 56 **Whitemarsh RC**, Tepp WH, Johnson EA, Pellett S. Persistence of botulinum neurotoxin A subtypes 1-5 in primary rat spinal cord cells. *PLoS One* 2014; **9**: e90252 [PMID: 24587301 DOI: 10.1371/journal.pone.0090252]
- 57 **Wang J**, Zurawski TH, Meng J, Lawrence G, Olango WM, Finn DP, Wheeler L, Dolly JO. A dileucine in the protease of botulinum toxin A underlies its long-lived neuroparalysis: transfer of longevity to a novel potential therapeutic. *J Biol Chem* 2011; **286**: 6375-6385 [PMID: 21138836 DOI: 10.1074/jbc.M110.181784]
- 58 **Tsai YC**, Maditz R, Kuo CL, Fishman PS, Shoemaker CB, Oyler GA, Weissman AM. Targeting botulinum neurotoxin persistence by the ubiquitin-proteasome system. *Proc Natl Acad Sci USA* 2010; **107**: 16554-16559 [PMID: 20823219 DOI: 10.1073/pnas.1008302107]
- 59 **Devieere J**, Dunham F, Rickaert F, Bourgeois N, Cremer M. Endoscopic ultrasonography in achalasia. *Gastroenterology* 1989; **96**: 1210-1213 [PMID: 2647577]
- 60 **Hoffman BJ**, Knapple WL, Bhutani MS, Verne GN, Hawes RH. Treatment of achalasia by injection of botulinum toxin under endoscopic ultrasound guidance. *Gastrointest Endosc* 1997; **45**: 77-79 [PMID: 9013174]
- 61 **Ciulla A**, Cremona F, Genova G, Maiorana AM. Echo-guided injection of botulinum toxin versus blind endoscopic injection in patients with achalasia: final report. *Minerva Gastroenterol Dietol* 2013; **59**: 237-240 [PMID: 23831914]
- 62 **Moretó M**, Ojembarrena E, Rodríguez ML. Endoscopic injection of ethanolamine as a treatment for achalasia: a first report. *Endoscopy* 1996; **28**: 539-545 [PMID: 8911800 DOI: 10.1055/s-2007-1005551]
- 63 **Moretó M**, Ojembarrena E, Barturen A, Casado I. Treatment of achalasia by injection of sclerosant substances: a long-term report. *Dig Dis Sci* 2013; **58**: 788-796 [PMID: 23179151 DOI: 10.1007/s10620-012-2476-x]
- 64 **Niknam R**, Mikaeli J, Fazlollahi N, Mahmoudi L, Mehrabi N, Shirani S, Malekzadeh R. Ethanolamine oleate as a novel therapy is effective in resistant idiopathic achalasia. *Dis Esophagus* 2014; **27**: 611-616 [PMID: 23927485 DOI: 10.1111/dote.12122]
- 65 **Mikaeli J**, Veisari AK, Fazlollahi N, Mehrabi N, Soleimani HA, Shirani S, Malekzadeh R. Ethanolamine oleate versus botulinum toxin in the treatment of idiopathic achalasia. *Ann Gastroenterol* 2015; **28**: 229-235 [PMID: 25830939]
- 66 **Ritvo M**, McDonald EJ. Value of nitrates in cardiospasm (achalasia of esophagus): preliminary report. *Am J Roentgenol* 1940; **43**: 500-508
- 67 **Douthwaite A**. Achalasia of cardia. Treatment with nitrites. *Lancet* 1943; **2**: 353-354 [DOI: 10.1016/S0140-6736(00)72548-7]
- 68 **Field C**. Octyl nitrite in achalasia of the cardia. *Lancet* 1944; **2**: 848-851 [DOI: 10.1016/S0140-6736(00)58788-1]
- 69 **Lorber SH**, Shay H. Roentgen studies of esophageal transport in patients with dysphagia due to abnormal motor function. *Gastroenterology* 1955; **28**: 697-714; discussion, 715-716 [PMID: 14380583]
- 70 **Gelfond M**, Rozen P, Keren S, Gilat T. Effect of nitrates on LOS pressure in achalasia: a potential therapeutic aid. *Gut* 1981; **22**:

- 312-318 [PMID: 7239323 DOI: 10.1136/gut.22.4.312]
- 71 **Wen ZH**, Gardener E, Wang YP. Nitrates for achalasia. *Cochrane Database Syst Rev* 2004; **15**: CD002299 [PMID: 14973987 DOI: 10.1002/14651858.CD002299.pub2]
  - 72 **Weiser HF**, Lepsien G, Golenhofen K, Schattenmann G, Siewert R. [Clinical and experimental studies on the efficiency of nifedipine on smooth muscle strips of the esophagus (author's transl)]. *Z Gastroenterol* 1977; **15**: 691-698 [PMID: 595746]
  - 73 **Becker BS**, Burakoff R. The effect of verapamil on the lower esophageal sphincter pressure in normal subjects and in achalasia. *Am J Gastroenterol* 1983; **78**: 773-775 [PMID: 6650465]
  - 74 **Traube M**, Hongo M, Magyar L, McCallum RW. Effects of nifedipine in achalasia and in patients with high-amplitude peristaltic esophageal contractions. *JAMA* 1984; **252**: 1733-1736 [PMID: 6471300 DOI: 10.1001/jama.1984.03350130047033]
  - 75 **Román FJ**, Montes J, Bortolotti M. Effects of nifedipine in achalasia and patients with high-amplitude peristaltic esophageal contractions. *JAMA* 1985; **253**: 2046-2047 [PMID: 3974095 DOI: 10.1001/jama.1985.03350380062018]
  - 76 **Gelfond M**, Rozen P, Gilat T. Isosorbide dinitrate and nifedipine treatment of achalasia: a clinical, manometric and radionuclide evaluation. *Gastroenterology* 1982; **83**: 963-969 [PMID: 6288509]
  - 77 **Bassotti G**, Annese V. Review article: pharmacological options in achalasia. *Aliment Pharmacol Ther* 1999; **13**: 1391-1396 [PMID: 10571593 DOI: 10.1046/j.1365-2036.1999.00645.x]
  - 78 **Traube M**, Dubovik S, Lange RC, McCallum RW. The role of nifedipine therapy in achalasia: results of a randomized, double-blind, placebo-controlled study. *Am J Gastroenterol* 1989; **84**: 1259-1262 [PMID: 2679048]
  - 79 **Dughera L**, Chiaverina M, Cacciottella L, Cisarò F. Management of achalasia. *Clin Exp Gastroenterol* 2011; **4**: 33-41 [PMID: 21694870 DOI: 10.2147/CEG.S11593]
  - 80 **Bortolotti M**, Coccia G, Brunelli F, Sarti P, Mazza M, Bagnato F, Barbara L. Isosorbide dinitrate or nifedipine: which is preferable in the medical therapy of achalasia? *Ital J Gastroenterol* 1994; **26**: 379-382 [PMID: 7703511]
  - 81 **Triadafilopoulos G**, Aaronson M, Sackel S, Burakoff R. Medical treatment of esophageal achalasia. Double-blind crossover study with oral nifedipine, verapamil, and placebo. *Dig Dis Sci* 1991; **36**: 260-267 [PMID: 1995258 DOI: 10.1007/BF01318193]
  - 82 **Bortolotti M**, Mari C, Lopilato C, Porrazzo G, Miglioli M. Effects of sildenafil on esophageal motility of patients with idiopathic achalasia. *Gastroenterology* 2000; **118**: 253-257 [PMID: 10648452 DOI: 10.1016/S0016-5085(00)85560-2]
  - 83 **Eherer AJ**, Schwetz I, Hammer HF, Petnehazy T, Scheidl SJ, Weber K, Krejs GJ. Effect of sildenafil on oesophageal motor function in healthy subjects and patients with oesophageal motor disorders. *Gut* 2002; **50**: 758-764 [PMID: 12010875 DOI: 10.1136/gut.50.6.758]
  - 84 **DiMarino AJ**, Cohen S. Effect of an oral beta2-adrenergic agonist on lower esophageal sphincter pressure in normals and in patients with achalasia. *Dig Dis Sci* 1982; **27**: 1063-1066 [PMID: 6129117 DOI: 10.1007/BF01391441]
  - 85 **Penagini R**, Bartesaghi B, Zannini P, Negri G, Bianchi PA. Lower oesophageal sphincter hypersensitivity to opioid receptor stimulation in patients with idiopathic achalasia. *Gut* 1993; **34**: 16-20 [PMID: 8381758 DOI: 10.1136/gut.34.1.16]
  - 86 **Penagini B**, Negri G, Bianchi PA. Effect of loperamide on lower oesophageal sphincter pressure in idiopathic achalasia. *Scand J Gastroenterol* 1994; **29**: 1057-1060 [PMID: 7886391 DOI: 10.3109/00365529409094887]
  - 87 **Marzio L**, Grossi L, DeLaurentiis MF, Cennamo L, Lapenna D, Cuccurullo F. Effect of cimetropium bromide on esophageal motility and transit in patients affected by primary achalasia. *Dig Dis Sci* 1994; **39**: 1389-1394 [PMID: 8026247 DOI: 10.1007/BF02088038]
  - 88 **Wright JT**. Buscopan and oesophageal achalasia. *Br J Radiol* 1961; **34**: 113-119 [PMID: 13786799 DOI: 10.1259/0007-1285-34-398-113]
  - 89 **Guelrud M**, Rossiter A, Souney PF, Rossiter G, Fanikos J, Mujica V. The effect of vasoactive intestinal polypeptide on the lower esophageal sphincter in achalasia. *Gastroenterology* 1992; **103**: 377-382 [PMID: 1634056]
  - 90 **Wong RK**, Maydonovitch C, Garcia JE, Johnson LF, Castell DO. The effect of terbutaline sulfate, nitroglycerin, and aminophylline on lower esophageal sphincter pressure and radionuclide esophageal emptying in patients with achalasia. *J Clin Gastroenterol* 1987; **9**: 386-389 [PMID: 3116071 DOI: 10.1097/00004836-198708000-00006]
  - 91 **Arnon SS**, Schechter R, Inglesby TV, Henderson DA, Bartlett JG, Ascher MS, Eitzen E, Fine AD, Hauer J, Layton M, Lillibridge S, Osterholm MT, O'Toole T, Parker G, Perl TM, Russell PK, Swerdlow DL, Tonn K. Botulinum toxin as a biological weapon: medical and public health management. *JAMA* 2001; **285**: 1059-1070 [PMID: 11209178]
  - 92 **Morbiato L**, Carli L, Johnson EA, Montecucco C, Molgó J, Rossetto O. Neuromuscular paralysis and recovery in mice injected with botulinum neurotoxins A and C. *Eur J Neurosci* 2007; **25**: 2697-2704 [PMID: 17561839 DOI: 10.1111/j.1460-9568.2007.05529.x]

**P- Reviewer:** Herbella FAM, Tan YY **S- Editor:** Ji FF  
**L- Editor:** A **E- Editor:** Li D





Published by **Baishideng Publishing Group Inc**

8226 Regency Drive, Pleasanton, CA 94588, USA

Telephone: +1-925-223-8242

Fax: +1-925-223-8243

E-mail: [bpgoffice@wjgnet.com](mailto:bpgoffice@wjgnet.com)

Help Desk: <http://www.wjgnet.com/esps/helpdesk.aspx>

<http://www.wjgnet.com>

