

Living donor liver transplantation with abdominal wall reconstruction for hepatocellular carcinoma with needle track seeding

Horng-Ren Yang, Ashok Thorat, Kanellos Gesakis, Ping-Chun Li, Kidakorn Kiranantawat, Hung Chi Chen, Long-Bin Jeng

Horng-Ren Yang, Ashok Thorat, Ping-Chun Li, Long-Bin Jeng, Department of Surgery and Organ Transplantation Center, China Medical University Hospital, Taichung 40447, Taiwan

Horng-Ren Yang, Ping-Chun Li, Long-Bin Jeng, College of Medicine, China Medical University, Taichung 40447, Taiwan

Kanellos Gesakis, Kidakorn Kiranantawat, Hung Chi Chen, Department of Plastic and Reconstructive Surgery, China Medical University Hospital, Taichung 40447, Taiwan

Author contributions: All authors contributed to this paper.

Institutional review board statement: This is to state that the present retrospective study was approved by the IRB of the China medical university hospital.

Informed consent statement: Informed consent was obtained prior to initiation of procedure.

Conflict-of-interest statement: No conflict of interests among the authors.

Open-Access: This article is an open-access article which was selected by an in-house editor and fully peer-reviewed by external reviewers. It is distributed in accordance with the Creative Commons Attribution Non Commercial (CC BY-NC 4.0) license, which permits others to distribute, remix, adapt, build upon this work non-commercially, and license their derivative works on different terms, provided the original work is properly cited and the use is non-commercial. See: <http://creativecommons.org/licenses/by-nc/4.0/>

Correspondence to: Long-Bin Jeng, Professor, Chief, Department of Surgery and Organ Transplantation Center, China Medical University Hospital, 2, Yuh-Der Road, Taichung 40447, Taiwan. otc@mail.cmuh.org.tw
 Telephone: +886-04-22052121
 Fax: +886-04-22029083

Received: June 27, 2015
 Peer-review started: July 12, 2015

First decision: August 26, 2015

Revised: October 17, 2015

Accepted: November 10, 2015

Article in press: November 11, 2015

Published online: December 24, 2015

Abstract

Malignant cell seeding in subcutaneous tissues along the needle track and/or percutaneous biliary drainage catheters is rare complication, but pose various technical issues in planning surgical treatment of such patients. If underlying primary hepatic malignancy can be treated, an aggressive resection of subcutaneous tissue bearing cancer cell with subsequent abdominal wall reconstruction has been sporadically reported. But, when hepatic resection is not possible due to underlying advanced cirrhosis, liver transplantation along with abdominal wall resection and subsequent reconstruction remains only feasible option. Herein, we describe our successful experience of living donor liver transplantation for hepatocellular carcinoma with full-thickness abdominal wall resection bearing the tumor seeding followed by reconstruction in single stage surgery.

Key words: Living donor liver transplantation; Tumour seeding; Hepatocellular carcinoma; Abdominal wall resection

© The Author(s) 2015. Published by Baishideng Publishing Group Inc. All rights reserved.

Core tip: Metastatic cell seeding can rarely occur in hepatocellular carcinoma secondary to procedures such as liver biopsy and percutaneous biliary drainage catheters. Abdominal resection bearing the malignant

cells with resection of underlying liver cancer is the only curative option. But, if the resection of the liver is not possible due to poor underlying liver functions, liver transplantation (LT) can still be performed with excision of the subcutaneous malignant track. In this case report we are presenting our successful experience with living donor LT combined with abdominal wall resection and reconstruction using thigh myocutaneous pedicle flap in a single stage surgery.

Yang HR, Thorat A, Gesakis K, Li PC, Kiranantawat K, Chen HC, Jeng LB. Living donor liver transplantation with abdominal wall reconstruction for hepatocellular carcinoma with needle track seeding. *World J Transplant* 2015; 5(4): 360-365 Available from: URL: <http://www.wjgnet.com/2220-3230/full/v5/i4/360.htm> DOI: <http://dx.doi.org/10.5500/wjt.v5.i4.360>

INTRODUCTION

Percutaneous transhepatic biliary drainage (PTBD) can cause metastatic tumor seeding along the biliary catheter^[1,2]. Seeding can also occur due to the needle biopsy of hepatocellular carcinoma (HCC) affecting as much as 0.5%-5% of patients undergoing computed tomography (CT)-guided biopsy for suspicious HCC which cannot be ruled out by other modalities of investigations^[3]. Aggressive surgical approach is often suggested including the excision of tumor seeding along with hepatic resection for the primary tumor. But, if underlying primary tumor is unresectable due to cirrhosis, then the condition potentially becomes inoperable with survival ranging from 6 to 8 mo. Liver transplantation (LT) precluded for the obvious reason of extra-hepatic spread and high chances of recurrence within few months of surgery.

Although expanded criteria for HCC patients are increasingly used in high volume liver transplant centers, patients with extra-hepatic spread have traditionally being contraindicated for LT. As tumor cell seeding along the catheter track is not in true sense extra-hepatic metastasis, but, an iatrogenic spilling of cancer cells in subcutaneous track, LT along with wide excision of abdominal wall and simultaneous abdominal wall reconstruction still remains a feasible option. In absence of extra-hepatic spread to other organs, LT with abdominal wall reconstruction can be considered. But, requires wide excision of anterior abdominal wall bearing the needle-track malignancy. After resection of full thickness abdominal wall, it is often impossible to achieve fascia-to-fascia closure under acceptable tension because of tissue loss and abdominal wall retraction requiring free pedicle musculofascial flap for reconstruction.

The abdominal wall defects, thus formed, can be classified into topographic subunits to assist the systematic approach of the abdominal reconstruction^[4]. The large abdominal wall defects can be reconstructed using autologous tissues from a local or distant source,

even as innervated flaps which can provide dynamic support that simulates the normal action of the abdominal wall. Free flaps are indicated when no other options are available, particularly when local tissues have been significantly destroyed or when pedicle flaps cannot reach or are insufficient in size^[5].

Various thigh flaps have been used and described throughout the years for reconstruction of abdominal wall defects including tensor fasciae latae myocutaneous, rectus femoris muscle or myocutaneous, anterolateral thigh fasciocutaneous, and sartorius muscle myocutaneous flaps^[6-8].

Although abdominal wall reconstruction following LT for abdominal wall necrosis has been reported^[9], this is the first instance of living donor liver transplantation (LDLT) for HCC patient with subcutaneous tumor seeding with excision and reconstruction of abdominal wall in single stage. This also presents a new frontier for advanced treatment option with prolonged disease free survival. Herein we present our experience of LDLT for HCC patient with abdominal wall reconstruction using chimeric extended thigh pedicle flap.

CASE REPORT

A 47-year-old chronic hepatitis B carrier patient with history of hypertension presented with jaundice and fever in emergency department for which he underwent initial evaluation. On CT scan images intrahepatic inflammatory mass in S5 with right intrahepatic duct stones and biliary obstruction were noted. Alfa fetoprotein (AFP) was 3.37 ng/mL at the time of admission. PTBD was performed to relieve obstruction and CT guided needle biopsy of inflammatory mass was done by gastroenterologist. Liver biopsy was inconclusive and showed acute and chronic inflammatory cells with micro abscesses. Bile culture revealed *E. coli* and *Pseudomonas* for which broad spectrum antibiotics were given. After one month of PTBD, bloody discharge in drain was noted with subsequent fistula formation at the drain site and first time surgeon's consultation was sought. CT scan was repeated and showed persistence of the mass in segment 5 (S5) of right liver extending to involve segment 6 (S6) partially (Figure 1). HCC was suspected and the biopsy of the fistula track was done that revealed carcinomatous cells favoring HCC suggesting tumour seeding. The PTBD catheter was removed during the biopsy session. But, resection of the liver bearing the HCC was not possible due to Child C liver cirrhosis. Patient was then evaluated for LDLT with abdominal wall resection bearing tumour seeding and subsequent reconstruction. Patient and his family were explained about the possible risk and high chances of recurrence. Systemic evaluation did not reveal any other extra-hepatic metastasis except for the tumour seeding thus confirmed in the subcutaneous track. Plastic and reconstructive surgical team was consulted and abdominal wall resection and reconstruction was planned along with LDLT as a single stage surgery. Patient's HCC

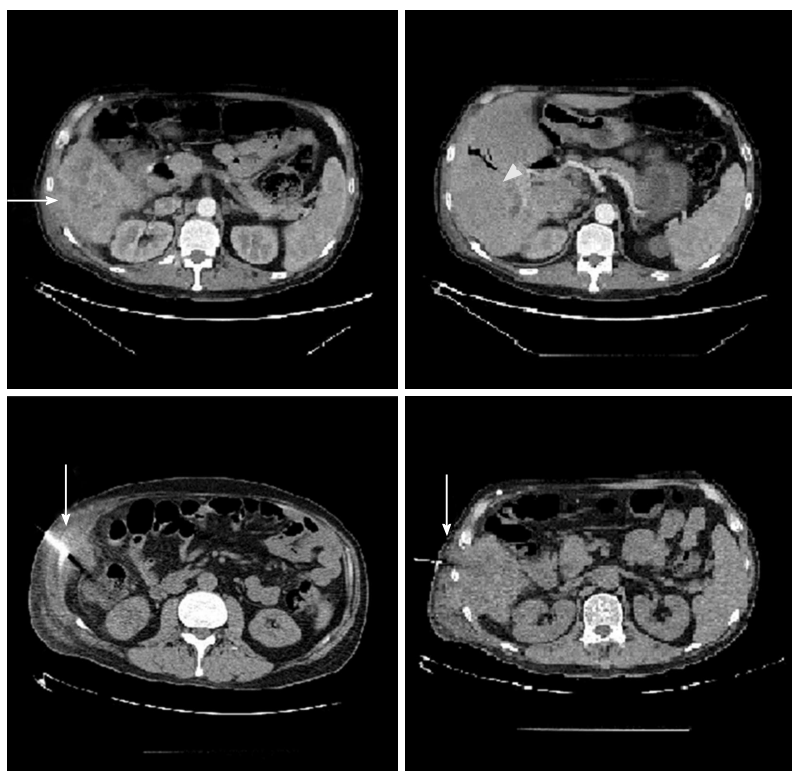


Figure 1 Computed tomography scan images of the liver. The vertical white arrows show the site of needle biopsy. The horizontal white arrow shows tumour mass in S5 extending to S6 and the arrow head shows the site of right intrahepatic duct dilatation.

was within University of California at San Francisco criteria with a single, large nodule in S5 and S6, and a diameter of 6.3 cm.

Patient's diseased liver was explanted through standard liver transplant recipient surgery procedure with bilateral subcostal incision and midline extension till xiphoid. After native liver was removed, donor liver allograft was implanted and vascular reconstruction was achieved by standard anastomotic techniques (right hepatic vein to inferior vena cava, porto-portal anastomosis and hepatic artery to recipient right hepatic artery anastomosis). Biliary continuity was restored by duct-to-duct anastomosis. After recipient surgery was completed, the subcutaneous malignant track was excised. A wide local excision of the full-thickness abdominal wall was performed and subsequent reconstruction of abdominal wall was done by plastic surgery team. Patient recovered well postoperatively without any undue complications. Immunosuppressants were given as per our institution protocol^[10]. No postoperative anticoagulation was used. Patient did not receive any postoperative adjuvant radiotherapy. The abdominal reconstruction site was inspected periodically and showed satisfactory healing. Patient was discharged 4th week after the LDLT. The explant liver pathology revealed non-capsulated HCC mixed with cholangiocarcinoma cells. The pathological examination of the excised abdominal wall showed cluster of atypical neoplastic cells with hyperchromatic nuclei with pleomorphism within suppurative inflammatory cells. After 18 mo of LDLT,

patient was diagnosed to have multiple lung metastases. Patient expired at 22 mo after transplantation.

Procedure of abdominal wall reconstruction

The patient was prepared on supine position, the defect was measured and a combined pedicle flap of anterolateral thigh (ALT), vastus lateralis (VL) and tensor fascia latae (TFL) pedicle muscle flap was designed (Figure 2). The landmark was made over the anterior and lateral surface of the right thigh. The axis was drawn from the right anterior superior iliac spine to the lateral border of the patella. The skin incision was made along the anterior border of the flap. The distal end of the flap was incised. The VL muscle was elevated. The perforators supplying the skin flap were identified but not dissected. The branches supplying the other muscles were divided. The combined flap was elevated based on the descending and transverse branches of lateral femoral circumflex artery (LFCA) and was transposed upwards for reconstruction of the abdominal wall defect. Inset was performed in layers, with the deep fascia sutured to the musculofascial layer of the abdomen to restore abdominal wall support. Vascular anastomoses were achieved by microvascular suturing technique. The fascia was closed with 1-0 and 2-0 PDS sutures. Meticulous hemostasis was carried out and size 10 JP drain was placed. The skin was closed using 3-0 PDS sutures. The donor site was partially closed and the rest of the donor site skin defect was covered with a split thickness skin graft (10/1000 inch in thickness) taken from the right thigh. Tie-over dressings were applied over the skin graft (Figure 3).

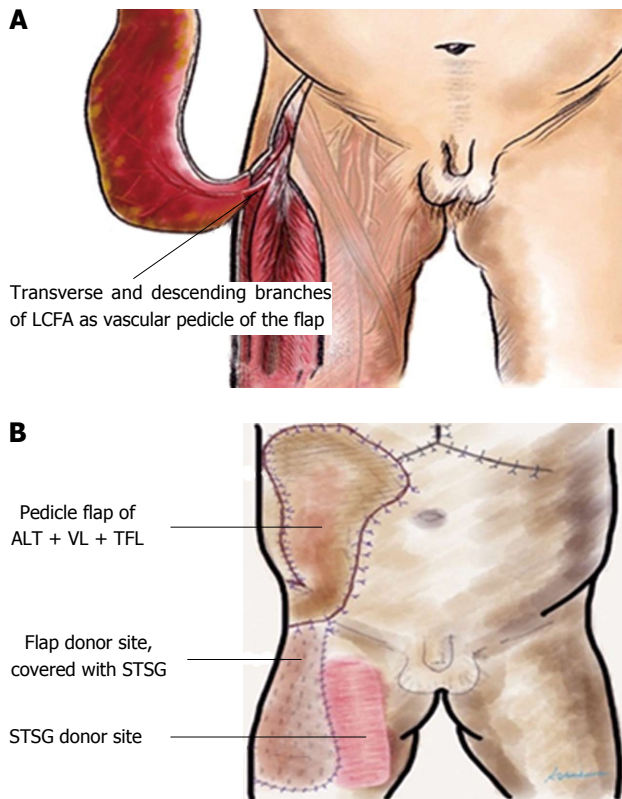


Figure 2 Diagrammatic depiction of the myocutaneous pedicle flap for abdominal wall reconstruction. A: Extended right thigh flap based on the transverse and descending branches of the LCFA; B: Pedicle flap of ALT + VL + TFL for coverage of right abdominal wall defect. Donor site covered with STSG taken from the right thigh. LCFA: Lateral circumflex femoral artery; ALT: Anterolateral thigh; VL: Vastus lateralis; TFL: Tensor fascia latae; STSG: Split thickness skin graft.

DISCUSSION

This is so far the first reported case of successful LDLT with abdominal wall resection followed by reconstruction in recipient with HCC and subcutaneous tumor seeding. Expanded criteria for LT for HCC have largely mentioned about the tumour numbers and diameter, but extra-hepatic metastasis is traditionally considered as contraindication for LT. But, tumor seeding along the PTBD catheter and/or needle biopsy track is an iatrogenic extra-hepatic spread of HCC and in absence of any other systemic involvement the subcutaneous disease can be resected and reconstructed. In this case, however, it was unclear if the tumour seeding was secondary to PTBD or needle biopsy as both procedures were done at same time and more or less through same area.

The mechanisms of metastatic tumor seeding along a PTBD catheter can be largely explained by catheter manipulation^[11]. This may cause tumor cell disruption and dissemination within biliary system and may give rise to observed tumor seeding. Seeding along the PTBD tract can occur at numerous sites, including the skin, abdominal wall, chest wall, liver parenchyma, or catheter entry site into the biliary tract, but it is usually difficult to treat. Fine needle biopsy of HCC is also one

of the causes for tumor seeding. In this recipient, fine needle biopsy was also done after PTBD catheter was placed. Meta-analysis by Silva *et al.*^[12] analyzed 8 studies published before 2007 with a total of 1340 patients and concluded the overall risk of needle tract seeding following biopsy of HCC to be 2.7% or 0.9% per year.

Although, aggressive resection of subcutaneous tumor seeding in selected patients is reported^[13,14], LT for underlying unresectable malignancy combined with abdominal wall resection and reconstruction has never been described before.

In this case, we first carried out total hepatectomy and liver allograft was implanted. After biliary anastomosis was done by usual duct to duct anastomosis technique, *en bloc* tissue resection from the skin to the parietal peritoneum was done to remove entire thickness of abdominal wall carrying inflamed subcutaneous fistulous track to obtain oncological clear margin. This was the first experience in the field of LDLT and there was scientific unclear data regarding the dimensions of the abdominal wall to be resected, we performed a wide excision of abdominal wall over the right hypochondrium that was 5 cm in radius (10 cm × 10 cm). Although reconstruction of abdominal wall using prosthetic material has been reported, we preferred free pedicled combined thigh flap as chances of infection are high using prosthetic material in patients who are under immunosuppression. Also, by using free tissue transfer, it can be used to reconstruct large, full-thickness defects in any region of the abdominal wall. The tensor fascia lata muscle can also be reinnervated to reconstruct the motor function of the abdominal wall^[2].

The pathological examination of the excised abdominal wall showed cluster of atypical neoplastic cells with hyperchromatic nuclei with pleomorphism within suppurative inflammatory cells. The atypical cells were immunoreactive to CK8 on immunohistochemistry. This justifies the wide local excision of the tumour bearing area to achieve oncological clearance and reduce the local recurrence of cancer.

Rarity of the condition and doubt about disease free survival, both, limits the experience of transplant surgeon in this context. Although patient expired at 22 mo after transplantation, there was no local recurrence and the reconstructed abdominal site remained healthy. With 18 mo of disease free survival achieved in this recipient, needle track seeding in HCC patients can thus be treated with more aggressive treatment option. Early detection of the subcutaneous seeding and wide resection with an adequate surgical margin may increase the chance of survival if primary malignancy can be treated in such patients (liver resection or LT). Although this surgery is technically demanding and complex, we conclude that LDLT along with abdominal wall reconstruction is a feasible option in patients with subcutaneous tumor seeding with unresectable liver primary; however, further studies are warranted to conclude the safety of this procedure.

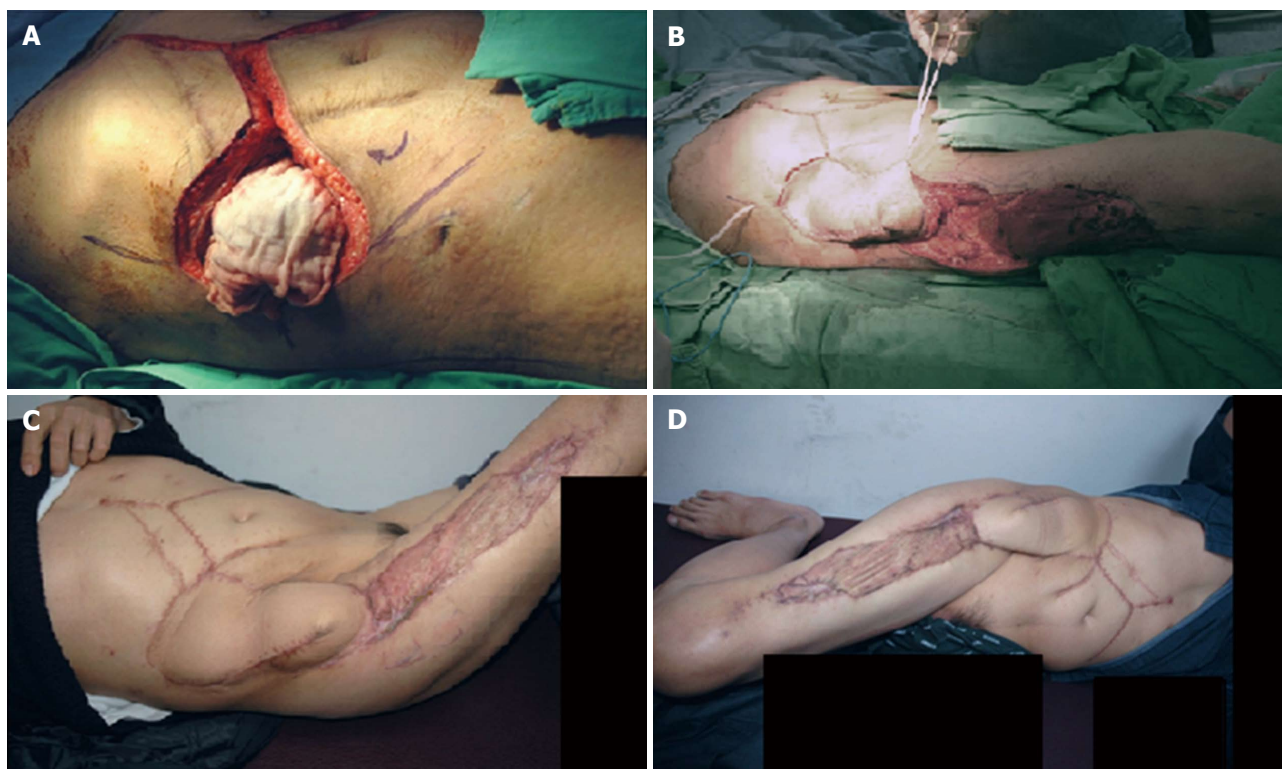


Figure 3 Recipient's intraoperative and follow up images. A: Ten centimeter × 10 cm diameter right abdominal wall defect following the wide local excision of the area; B: Perioperative picture of the transposition of the right thigh extended pedicle flap and coverage of the right side abdominal wall defect; C: Post operative picture from the outpatient clinic on a three months follow up; D: Post operative picture from the outpatient clinic on a six months follow up.

COMMENTS

Case characteristics

Unresectable hepatocellular carcinoma with needle track seeding in subcutaneous tissue of right hypochondrium.

Clinical diagnosis

Child C cirrhosis with hepatocellular carcinoma (HCC) with Intrahepatic stones with needle track tumor seeding.

Differential diagnosis

Intrahepatic stones with abscess formation.

Imaging diagnosis

Computed tomography angiography confirmed the diagnosis of HCC.

Treatment

Living donor liver transplantation (LDLT) with abdominal wall resection and reconstruction in single stage surgery.

Related reports

LDLT with abdominal wall reconstruction for HCC and needle track seeding is never reported before. This is first successful case to highlight surgical details in this case scenario.

Term explanation

LDLT is most common modality of liver transplantation in Asia due to scarce deceased donor organs.

Experiences and lessons

Meticulous surgical planning with plastic reconstructive surgical team is important. Full thickness wide excision of the tumor bearing subcutaneous track

and subsequent pedicle flap can effectively treat such condition.

Peer-review

The submitted manuscript by Yang *et al* reports the case of a living donor liver transplantation associated with abdominal wall reconstruction in a single stage surgery to treat hepatocellular carcinoma with malignant cell seeding of a percutaneous biliary drainage.

REFERENCES

- 1 **Chapman WC**, Sharp KW, Weaver F, Sawyers JL. Tumor seeding from percutaneous biliary catheters. *Ann Surg* 1989; **209**: 708-713; discussion 713-715 [PMID: 2658881]
- 2 **Mizuno T**, Ishizaki Y, Komuro Y, Yoshimoto J, Sugo H, Miwa K, Kawasaki S. Surgical treatment of abdominal wall tumor seeding after percutaneous transhepatic biliary drainage. *Am J Surg* 2007; **193**: 511-513 [PMID: 17368301 DOI: 10.1016/j.amjsurg.2006.03.011]
- 3 **Bruix J**, Sherman M, Llovet JM, Beaugrand M, Lencioni R, Burroughs AK, Christensen E, Pagliaro L, Colombo M, Rodés J. Clinical management of hepatocellular carcinoma. Conclusions of the Barcelona-2000 EASL conference. European Association for the Study of the Liver. *J Hepatol* 2001; **35**: 421-430 [PMID: 11592607 DOI: 10.1016/S0168-8278(01)00130-1]
- 4 **Rod JR**, James BL, Fred LH, Julie L, Hobar FC. An algorithm for abdominal wall reconstruction. *Plast Reconstr Surg* 2000; **104**: 202-213
- 5 **Lowe JB**. Updated algorithm for abdominal wall reconstruction. *Clin Plast Surg* 2006; **33**: 225-240, vi [PMID: 16638465 DOI: 10.1016/j.cps.2005.12.004]
- 6 **Cunha-Gomes D**, Choudhari C, Bhatena HM, Kavarana NM. The hemithigh microvascular transfer (combined anterolateral thigh flap and tensor fasciae latae flap) for a full thickness abdominal wall reconstruction: a case report. *Acta Chir Plast* 1999; **41**: 71-73 [PMID: 10641324]
- 7 **Tellioglu AT**, Karabağ O. Application of a sartorius muscle flap

- during abdominal wall reconstruction. *Ann Plast Surg* 1999; **42**: 703-705 [PMID: 10382814 DOI: 10.1097/00000637-199906000-00024]
- 8 **Sensöz O**, Ustüner TE, Taner OF. Use of a sartorius myofasciocutaneous flap for reconstruction of a large, full-thickness abdominal wall defect. *Ann Plast Surg* 1990; **25**: 193-196 [PMID: 2146916 DOI: 10.1097/00000637-199009000-00007]
- 9 **Rieger UM**, Petschke F, Djedovic G, Engelhardt TO, Biehl M, Pierer G. Abdominal wall reconstruction after extensive abdominal wall necrosis resulting from chevron incision for liver transplant and subsequent Y-shaped incision for re-transplantation-clinical experience and literature review. *J Plast Reconstr Aesthet Surg* 2012; **65**: e71-e73 [PMID: 22115912 DOI: 10.1016/j.bjps.2011.11.021]
- 10 **Jeng LB**, Thorat A, Hsieh YW, Yang HR, Yeh CC, Chen TH, Hsu SC, Hsu CH. Experience of using everolimus in the early stage of living donor liver transplantation. *Transplant Proc* 2014; **46**: 744-748 [PMID: 24767339 DOI: 10.1016/j.transproceed.2013.11.068]
- 11 **Loew R**, Dueber C, Schwarting A, Thelen M. Subcutaneous implantation metastasis of a cholangiocarcinoma of the bile duct after percutaneous transhepatic biliary drainage (PTBD). *Eur Radiol* 1997; **7**: 259-261 [PMID: 9038127 DOI: 10.1007/s003300050147]
- 12 **Silva MA**, Hegab B, Hyde C, Guo B, Buckels JA, Mirza DF. Needle track seeding following biopsy of liver lesions in the diagnosis of hepatocellular cancer: a systematic review and meta-analysis. *Gut* 2008; **57**: 1592-1596 [PMID: 18669577 DOI: 10.1136/gut.2008.149062]
- 13 **Inagaki M**, Yabuki H, Hashimoto M, Maguchi M, Kino S, Sawa M, Ojima H, Tokusashi Y, Miyokawa N, Kusano M, Kasai S. Metastatic seeding of bile duct carcinoma in the transhepatic catheter tract: report of a case. *Surg Today* 1999; **29**: 1260-1263 [PMID: 10639708 DOI: 10.1007/BF02482219]
- 14 **Sakata J**, Shirai Y, Wakai T, Nomura T, Sakata E, Hatakeyama K. Catheter tract implantation metastases associated with percutaneous biliary drainage for extrahepatic cholangiocarcinoma. *World J Gastroenterol* 2005; **11**: 7024-7027 [PMID: 16437610]

P- Reviewer: Maroni L **S- Editor:** Ji FF
L- Editor: A **E- Editor:** Li D





Published by **Baishideng Publishing Group Inc**

8226 Regency Drive, Pleasanton, CA 94588, USA

Telephone: +1-925-223-8242

Fax: +1-925-223-8243

E-mail: bpgoffice@wjgnet.com

Help Desk: <http://www.wjgnet.com/esps/helpdesk.aspx>

<http://www.wjgnet.com>

