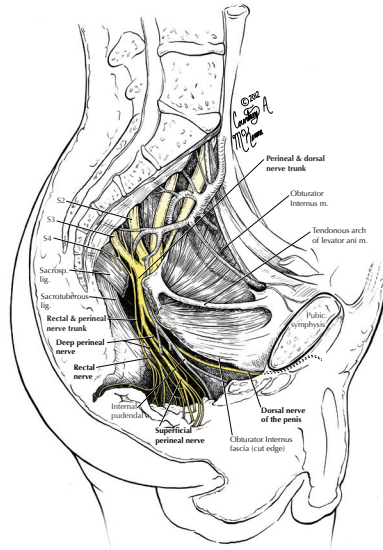




JOURNAL COPYRIGHT PERMISSION LICENSE

Description of the Image(s): Courtney McKenna owns the copyright to the following image:



Description of the Work: In the event that the work is published by Surgical and Radiological Anatomy, Courtney McKenna hereby grants permission to reproduce the above image for use in the work specified:

Article Entitled: 3T Magnetic Resonance Neurography of Pudendal Nerve with Cadaveric Dissection Correlation

Authored by: Avneesh Chhabra, MD; Courtney McKenna, MA; Vibhor Wadhwa, MD; Gaurav K Thawait, MD; John A Carrino, MD, MPH; Gary P Lees, MS, CMI; AL Dellon, MD, PHD, FACS

Published in: World Journal of Radiology

License Granted: Courtney McKenna hereby grants limited, non-exclusive worldwide print and electronic rights, including online versions, in their original form and only for use in the work specified. This grant applies to a single printed issue of the periodical and in special supplement editions. Includes distribution of same issue on publisher's website, reprints. Includes translation into all languages.

Ownership of original artwork, copyright, and all rights not specifically transferred herein remain the exclusive property of Courtney McKenna.

Credit: Publisher shall credit the images source as such: "printed with permission from © 2016 Courtney A McKenna."

Grantee: **Journal Title:** World Journal of Radiology

Permission granted:

Courtney McKenna

February 1, 2016
date