

## Secondary aorto-esophageal fistula after thoracic aortic aneurysm endovascular repair treated by covered esophageal stenting

Mary Tao, Eran Shlomovitz, Gail Darling, Graham Roche-Nagle

Mary Tao, Graham Roche-Nagle, Division of Vascular Surgery, Toronto General Hospital, Toronto M5G 2C4, Ontario, Canada

Eran Shlomovitz, Department of Interventional Radiology, Peter Munk Cardiac Centre, Toronto General Hospital, Toronto M5G 2C4, Ontario, Canada

Gail Darling, Department of Thoracic Surgery, Toronto General Hospital, Toronto M5G 2C4, Ontario, Canada

**Author contributions:** Tao M and Roche-Nagle G wrote the manuscript; Shlomovitz E and Darling G were involved in editing the manuscript; Roche-Nagle G designed the study.

**Institutional review board statement:** Researchers are advised to consult with the REB when uncertainty exists and when formal and systematic collection of human subjects' research will be occurring.

**Informed consent statement:** The patient has died no consent obtained.

**Conflict-of-interest statement:** The authors declare no conflicts of interest regarding this manuscript.

**Open-Access:** This article is an open-access article which was selected by an in-house editor and fully peer-reviewed by external reviewers. It is distributed in accordance with the Creative Commons Attribution Non Commercial (CC BY-NC 4.0) license, which permits others to distribute, remix, adapt, build upon this work non-commercially, and license their derivative works on different terms, provided the original work is properly cited and the use is non-commercial. See: <http://creativecommons.org/licenses/by-nc/4.0/>

**Manuscript source:** Invited manuscript

**Correspondence to:** Dr. Graham Roche-Nagle, Assistant Professor, Division of Vascular Surgery, Toronto General Hospital, 200 Elizabeth St. Toronto M5G 2C4, Ontario, Canada. [graham.roche-nagle@uhn.ca](mailto:graham.roche-nagle@uhn.ca)  
Telephone: +1-416-3405332

Fax: +1-416-3405029

Received: February 22, 2016

Peer-review started: February 23, 2016

First decision: March 25, 2016

Revised: April 15, 2016

Accepted: June 14, 2016

Article in press: June 16, 2016

Published online: August 16, 2016

### Abstract

Thoracic endovascular aortic repair for thoracic aortic aneurysms is an accepted alternative to open surgery, especially in patients with significant comorbidities. The procedure itself has a low risk of complications and fistulas to surrounding organs are rarely reported. An 86-year-old patient was admitted to our hospital with gastro intestinal (GI) bleeding and a suspected aorto-esophageal fistula. Eight months prior, the patient had undergone a stent graft repair of a mycotic thoracic aneurysm. Computerized tomography angiography and upper GI endoscopy confirmed an aorto-esophageal fistula, which was treated by esophageal stenting. With early recognition, esophageal stenting may have a role in the initial emergency control of bleeding from and palliation of aorto-esophageal fistula.

**Key words:** Endovascular therapy; Bleeding; Aortic aneurysm

© **The Author(s) 2016.** Published by Baishideng Publishing Group Inc. All rights reserved.

**Core tip:** Thoracic endovascular aortic repair (TEVAR) for thoracic aortic aneurysms is an accepted alternative to open surgery, especially in patients with significant comorbidities. The procedure itself has a low risk of

complications and fistulas to surrounding organs are rarely reported. Aorto-esophageal fistula post-TEVAR is a very rare entity; however, it is a devastating and usually fatal condition. Treatment options are very restricted, as these patients are often not candidates for complex surgery. We consider the placement of a covered self-expanding esophageal stent to be useful in the management of secondary aorto-esophageal fistula after TEVAR to prevent re-bleeding in the fragile patient.

Tao M, Shlomovitz E, Darling G, Roche-Nagle G. Secondary aorto-esophageal fistula after thoracic aortic aneurysm endovascular repair treated by covered esophageal stenting. *World J Clin Cases* 2016; 4(8): 233-237 Available from: URL: <http://www.wjgnet.com/2307-8960/full/v4/i8/233.htm> DOI: <http://dx.doi.org/10.12998/wjcc.v4.i8.233>

## INTRODUCTION

Thoracic endovascular aortic repair (TEVAR) is a minimally invasive and generally excellent modality to treat descending thoracic aortic aneurysms. Nevertheless, several complications including paraplegia, stroke and occasionally aorto-esophageal fistula (AEF) may occur<sup>[1-4]</sup>. Aorto-esophageal fistula post-TEVAR is a rare entity with a reported incidence of 1.7%-1.9%<sup>[1-3]</sup>, however, it is a devastating and usually fatal condition. Treatment options are very restricted, as these patients are often not fit for complex surgery. Conservative management outcomes are almost always fatal due to recurrent hemorrhage or chronic infection and mediastinitis. In this paper, we present a case of secondary AEF post-TEVAR with insertion of a covered self-expanding esophageal stent to control gastrointestinal bleeding.

## CASE REPORT

An 86-year-old woman was admitted to hospital with back pain and investigations demonstrated lumbar spine discitis. She developed progressive dyspnea, dysphagia, bilateral swelling of the arms and a leukocytosis. Chest radiography showed a widened mediastinum, bilateral pleural effusions and tracheal deviation (Figure 1). Computed tomography of the chest with intravenous contrast showed a saccular thoracic aortic aneurysm (5.0 cm × 5.0 cm) with surrounding hematoma compressing the trachea, esophagus and superior vena cava (Figure 2A). She was transferred to our center and received an endovascular stent graft (Figure 2B).

She re-presented to hospital 8 mo later following an upper gastro intestinal (GI) bleed and computerized tomography (CT) suggested an aorto-esophageal fistula (Figure 3). The patient was not a candidate for open surgery and transferred for emergency gastroscopy and esophageal stent insertion. There was a large clot in the upper mid esophagus and an 18 mm diameter

× 150 mm Niti-S esophageal stent (Taewoong Medical, Seoul, South Korea) was inserted to tamponade the bleeding point. The patient had persistent nausea, reflux and vomiting for 24 h post stent insertion. Chest X-ray demonstrated the stent had migrated distally resulting in these symptoms (Figure 4). She returned for repeat gastroscopy which confirmed migration of the stent through the gastro-esophageal junction. The initial stent was repositioned into the upper esophagus and a Double Niti-S™ esophageal stent (Taewoong Medical) 20 mm × 100 mm was placed, partially overlapping with the previous stent. She was commenced on lifelong antibiotic therapy and was discharged well from hospital 7 d after presentation. Unfortunately she died from a myocardial infarction 8 mo later.

## DISCUSSION

The first report of aorto-esophageal fistula was in 1818 due to a beef bone fragment<sup>[5]</sup>. A large review of 500 cases identified three major causes<sup>[6]</sup>. The main aetiological factor identified being aortic disease with 54.2% of cases secondary to rupture of a descending thoracic aorta aneurysm into the oesophagus. Foreign body ingestion (19.2%) and advanced esophageal carcinoma (17.0%) were the next commonest causes.

Endovascular stent graft implantation procedures are performed in patients with aneurysms of the aorta or other large vessels. The goal of the procedure is to preserve vessel patency and to prevent the aneurysm from rupture. Formation of aorto-esophageal and aorto-bronchial fistulas is a rare (0.5%-1.7%), but serious complication of stent graft implantation to thoracic aorta<sup>[3]</sup>. They are most frequently caused by infection of the prosthesis, compression, ischemia, local inflammatory reaction and subsequent necrosis<sup>[2]</sup>. Aorto-esophageal fistulas are more common (68%) than aortobronchial (5%) and both types of fistulas coexist in 26% of cases.

Eggebrecht *et al*<sup>[2]</sup> followed up 268 patients undergoing TEVAR, AEF occurred in 5 (1.9%). Secondary AEF can develop late after thoracic aortic surgery in up to 1.7% of patients<sup>[7]</sup>. The incidence of post-TEVAR AEF is comparable to the incidence after open repair surgery<sup>[1]</sup>. The largest risk factor for fistula formation is infection of the prosthesis. The incidence of peri-graft infection is reported to be as high as 0.5%-5%<sup>[2]</sup>. Other factors increasing the risk of complications such as fistulas include pseudoaneurysms as in our case, emergency surgeries and intraoperative complications.

The primary presentation is massive hematemesis, often resulting in exsanguination<sup>[2]</sup>. Other presentations include: (1) severe backache<sup>[8]</sup>; (2) fever<sup>[8]</sup>; and (3) chest pain<sup>[9]</sup>. The "classic" symptom of AEF involves Chiari's triad of aorto-esophageal syndrome-chest pain, episode of small hematemesis followed by massive hematemesis<sup>[10]</sup>.

The exact pathophysiologic mechanisms of AEF formation secondary to TEVAR are unknown thus far. There are different theories. A pathophysiologic mechanism of secondary AEF after TEVAR has been

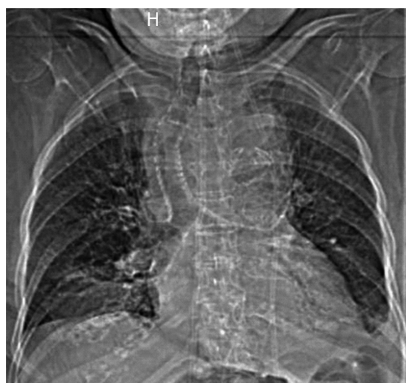

Figure 1 Chest radiography showed a widened mediastinum and tracheal deviation.

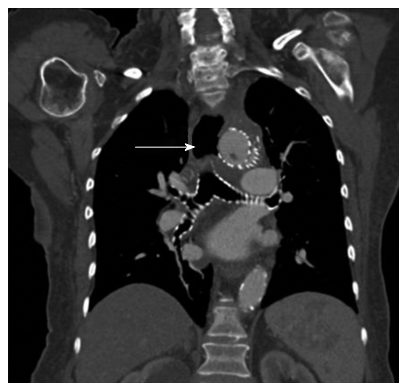


Figure 3 Computed tomography demonstrating an aorto-esophageal fistula (arrow).

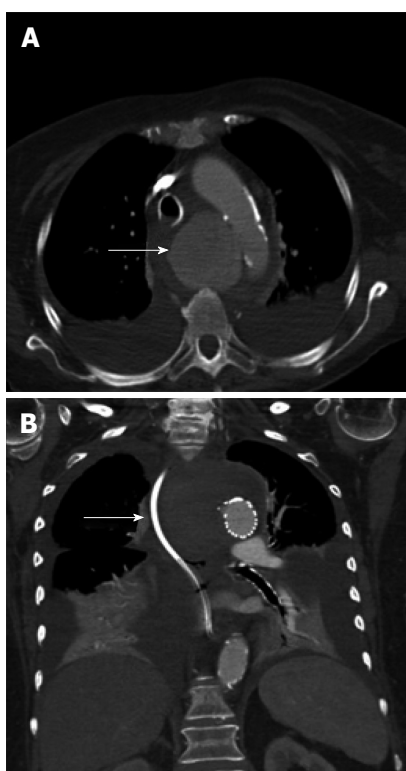


Figure 2 Computed tomography of the chest with intravenous contrast showed a saccular thoracic aortic aneurysm (5.0 cm × 5.0 cm) (arrow). Pre (A) and post (B) TEVAR with surrounding hematoma compressing the trachea, esophagus and superior vena cava. TEVAR: Thoracic endovascular aortic repair.

hypothesized<sup>[11]</sup>. Direct erosion of the rigid stent-graft through the aorta into the esophagus or pressure necrosis of the esophageal wall due to the ongoing forces of the self-expanding stent graft. Potential ischemic esophageal necrosis due to stent-graft occlusion of aortic side branches that feed the esophagus or most likely in our case infection of stent-graft prosthesis that eventually extends to the esophagus eroding its wall. Pressure necrosis mechanisms also occur in the presence of endoleak that enlarge the aneurysm sac or in an already large aneurysm sac prior to TEVAR<sup>[2,11,12]</sup>.

Any patient with a previous history of thoracic aortic

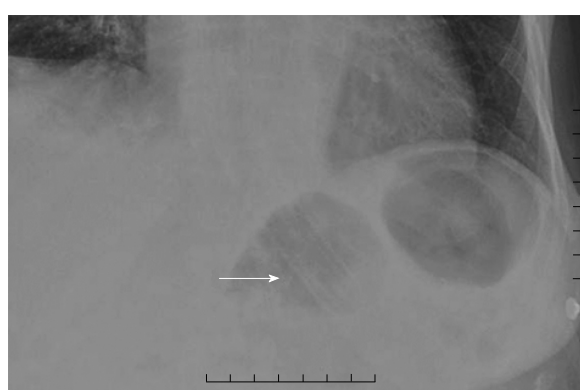

Figure 4 Chest X-ray demonstrating migration of the esophageal stent to the level of the gastroesophageal junction (arrow).

surgery and hematemesis should have a suspected AEF. Computed tomography angiography (CTA) is the initial investigation of choice in a case of suspected AEF looking for close approximation of the TEVAR and esophagus with or without air present. It can be confirmed by prompt upper GI endoscopy.

A treatment consensus for AEF, especially after previous TEVAR, has not been agreed upon. Conservative management of this condition almost invariably results in a fatal outcome. However, a more aggressive surgical strategy involving esophageal diversion or resection, extensive debridement, and aortic graft interposition is associated with significant mortality and morbidity<sup>[13,14]</sup>. The majority of patients who undergo TEVAR for aortic pathology have significant comorbidities precluding open surgical rescue. In this frail population management includes the use of broad-spectrum antibiotics, proton pump inhibition, and potential enteral feeding *via* percutaneous endoscopic gastrostomy (PEG) to bypass the esophageal fistula.

In our case we chose to place a self-expanding esophageal stent as a palliative measure. Esophageal diversion or resection was not possible due to her age and co-morbidities and re-stenting her aorta was not felt to be indicated. An esophageal stent may prevent re-bleeding and allow the patient to eat normally so is a good palliative option. When considering this option

it is important to understand that stenting the “normal” esophagus is not always effective. Incomplete seal or stent migration requiring repositioning or replacement may be necessary as seen in our case. In a study of 187 esophageal stents insertions, 29 (17%) patients required repositioning or replacement<sup>[3]</sup>. There are a number of reports describing the use of self-expanding esophageal stents in this setting. Eggebrecht *et al*<sup>[2]</sup> inserted self-expanding esophageal stents in three patients with secondary AEF after endovascular stent grafting, with two patients surviving for 2-6 mo<sup>[2]</sup>. Onodera *et al*<sup>[4]</sup> reported a case where a covered self-expanding esophageal stent was inserted to prevent re-bleeding, and re-bleeding did not occur for 52 d post-insertion. In our case the patient did not re-bleed and died of a myocardial infarction 8 mo post stenting. Therefore, placement of a covered self-expanding esophageal stent may be useful to prevent re-bleeding for a substantial period of time.

The Taewoong Niti-S esophageal stents, such as the one utilized in this case encompass a family of fully covered esophageal stents for various indications. The stent design consists of a self-expanding, braided nitinol (nickel titanium alloy). The stents are covered with a polyurethane membrane throughout their length designed to resist tissue ingrowth. To reduce the risk of migration the “S” esophageal stents are designed with both proximal and distal flares which are 8 mm wider than the shaft. Such flares are meant to anchor the stents in position across an obstructing esophageal lesion or resist migration through the gastroesophageal junction. In instances similar with this case where no obstructing lesion exists, there remains a significant risk of migration. The DOUBLE Niti-S esophageal stent is designed to further minimize this risk of migration. This stent has the same basic characteristics as the “S” type esophageal stent, including flared ends and a polyurethane membrane internal covering. However, the design also includes an outer layer consisting of an uncovered nitinol mesh intended to more firmly embed into the surrounding tissues. This additional second layer also increases the radial force exerted by the stent, further reducing the risk of migration<sup>[15]</sup>.

During endoscopy, there is direct visualization of the pathology and a guide wire is placed in the stomach under direct vision. Guide wire choice is best individualized to the patient’s overall situation for esophageal stent placement. Stents can be deployed under fluoroscopic guidance, endoscopic guidance, or a combination of the two. Ideally however, both modalities should be used and are complementary in the safe and accurate deployment of esophageal stents. Although the learning curve for placement of esophageal stents is not known a certain comfort level with both modalities is extremely useful in the management of these patients especially in the acute setting.

An aortoesophageal fistula presents a challenge for even the most experienced thoracic and vascular surgeons with a high mortality rate. We consider the placement of a covered self-expanding esophageal

stent to be a valuable option for the management of secondary AEF after TEVAR and to prevent re-bleeding in the frail patient. The Taewoong Niti-S esophageal stent should be considered to reduce risk of migration. This treatment allows the patient to eat normally while providing the best palliation method in an often terminal condition.

## COMMENTS

### Case characteristics

An 86-year-old patient was admitted with gastro intestinal (GI) bleeding and a suspected aortoesophageal fistula.

### Clinical diagnosis

GI bleeding on the background of aortic surgery should always raise suspicion of aorto-enteric fistula.

### Differential diagnosis

Hemorrhagic gastritis, esophageal varices, Mallory-Weiss tear, Neoplasm, Dieulafoy lesion or Aorto-enteric fistula.

### Laboratory diagnosis

The hemoglobin was reduced.

### Imaging diagnosis

Computerized tomography angiography and upper GI endoscopy confirmed an aortoesophageal fistula.

### Treatment

A covered esophageal stent was inserted to tamponade the bleeding point.

### Related reports

Thoracic endovascular aortic repair (TEVAR) is a minimally invasive and generally excellent modality to treat descending thoracic aortic aneurysms. Aortoesophageal fistula post-TEVAR is a rare entity. There are few reports describing the use of self-expanding esophageal stents in this setting.

### Term explanation

Aortoesophageal fistula post-TEVAR is an infrequent presentation likely caused by direct erosion of the rigid stent-graft through the aorta into the esophagus or pressure necrosis of the esophageal wall due to the ongoing forces of the self-expanding stent graft.

### Experiences and lessons

The authors consider the placement of a covered self-expanding esophageal stent to be useful in the management of secondary aortoesophageal fistula (AEF) after TEVAR to prevent re-bleeding in the fragile patient.

### Peer-review

The author reported a rare case of AEF following endovascular repair of thoracic aortic aneurysm. The paper is well written.

## REFERENCES

- 1 Chiesa R, Melissano G, Marone EM, Marrocco-Trischitta MM, Kahlberg A. Aorto-oesophageal and aortobronchial fistulae following thoracic endovascular aortic repair: a national survey. *Eur J Vasc Endovasc Surg* 2010; **39**: 273-279 [PMID: 20096612 DOI: 10.1016/j.ejvs.2009.12.007]
- 2 Eggebrecht H, Mehta RH, Dechene A, Tsagakis K, Kühl H, Huptas S, Gerken G, Jakob HG, Erbel R. Aortoesophageal fistula after thoracic aortic stent-graft placement: a rare but catastrophic complication of a novel emerging technique. *JACC Cardiovasc Interv*



- 2009; **2**: 570-576 [PMID: 19539264 DOI: 10.1016/j.jcin.2009.03.010]
- 3 **Lee SH**, Song PS, Kim WS, Park KB, Choi SH. A case of stent graft infection coupled with aorto-esophageal fistula following thoracic endovascular aortic repair in a complex patient. *Korean Circ J* 2012; **42**: 366-368 [PMID: 22701140 DOI: 10.4070/kcj.2012.42.5.36]
- 4 **Onodera M**, Inoue Y, Fujino Y, Kikuchi S, Endo S. A case of secondary aortoesophageal fistula inserted a covered self-expanding esophageal stent to control gastrointestinal bleeding. *Case Rep Gastrointest Med* 2013; **2013**: 857135 [PMID: 23781353 DOI: 10.1155/2013/857135]
- 5 **Dubruel O**. Observation sur la perforation de l'oesophage et de l'aorte thoracique par une portion d'os oval: avec des réflexions. *J Univ Sci Med* 1818; **9**: 357-363
- 6 **Hollander JE**, Quick G. Aortoesophageal fistula: a comprehensive review of the literature. *Am J Med* 1991; **91**: 279-287 [PMID: 1892150 DOI: 10.1016/0002-9343(91)90129-L]
- 7 **Grabenwöger M**, Alfonso F, Bachet J, Bonser R, Czerny M, Eggebrecht H, Evangelista A, Fattori R, Jakob H, Lönn L, Nienaber CA, Rocchi G, Rousseau H, Thompson M, Weigang E, Erbel R. Thoracic Endovascular Aortic Repair (TEVAR) for the treatment of aortic diseases: a position statement from the European Association for Cardio-Thoracic Surgery (EACTS) and the European Society of Cardiology (ESC), in collaboration with the European Association of Percutaneous Cardiovascular Interventions (EAPCI). *Eur Heart J* 2012; **33**: 1558-1563 [PMID: 22561257 DOI: 10.1093/eurheartj/ehs074]
- 8 **Gavens E**, Zaidi Z, Al-Jundi W, Kumar P. Aortoesophageal fistula after endovascular aortic aneurysm repair of a mycotic thoracic aneurysm. *Int J Vasc Med* 2011; **2011**: 649592 [PMID: 21904681 DOI: 10.1155/2011/649592]
- 9 **Yavuz S**, Kanko M, Ciftci E, Parlar H, Agirbas H, Berki T. Aortoesophageal fistula secondary to thoracic endovascular aortic repair of a descending aortic aneurysm rupture. *Heart Surg Forum* 2011; **14**: E249-E251 [PMID: 21859645 DOI: 10.1532/HSF98.20101179]
- 10 **Aziz S**, McWilliams R, Rashid A, Gosney JR, Harris PL, Stables RH. Late aortic rupture due to stent margin pseudoaneurysm formation complicating endovascular stent graft repair of a thoracic aortic mycotic aneurysm. *EJVES Extra* 2006; **12**: 30-34 [DOI: 10.1016/j.ejvsextra.2006.02.004]
- 11 **Xi EP**, Zhu J, Zhu SB, Zhang Y. Secondary aortoesophageal fistula after thoracic aortic aneurysm endovascular repair: literature review and new insights regarding the hypothesized mechanisms. *Int J Clin Exp Med* 2014; **7**: 3244-3252 [PMID: 25419355]
- 12 **Girdauskas E**, Falk V, Kuntze T, Borger MA, Schmidt A, Scheinert D, Mohr FW. Secondary surgical procedures after endovascular stent grafting of the thoracic aorta: successful approaches to a challenging clinical problem. *J Thorac Cardiovasc Surg* 2008; **136**: 1289-1294 [PMID: 19026818 DOI: 10.1016/j.jtcvs.2008.05.053]
- 13 **Czerny M**, Zimpfer D, Fleck T, Gottardi R, Cejna M, Schoder M, Lammer J, Wolner E, Grabenwöger M, Mueller MR. Successful treatment of an aortoesophageal fistula after emergency endovascular thoracic aortic stent-graft placement. *Ann Thorac Surg* 2005; **80**: 1117-1120 [PMID: 16122507 DOI: 10.1016/j.athoracsur.2004.02.136]
- 14 **Topel I**, Stehr A, Steinbauer MG, Piso P, Schlitt HJ, Kasprzak PM. Surgical strategy in aortoesophageal fistulae: endovascular stentgrafts and in situ repair of the aorta with cryopreserved homografts. *Ann Surg* 2007; **246**: 853-859 [PMID: 17968179 DOI: 10.1097/SLA.0b013e3180caa3c9]
- 15 **Kim ES**, Jeon SW, Park SY, Cho CM, Tak WY, Kweon YO, Kim SK, Choi YH. Comparison of double-layered and covered Niti-S stents for palliation of malignant dysphagia. *J Gastroenterol Hepatol* 2009; **24**: 114-119 [PMID: 19054264 DOI: 10.1111/j.1440-1746.2008.05674.x]

**P- Reviewer:** Gao BL, Koletsis EN, Liu DL

**S- Editor:** Qiu S **L- Editor:** A **E- Editor:** Zhang FF





Published by **Baishideng Publishing Group Inc**

8226 Regency Drive, Pleasanton, CA 94588, USA

Telephone: +1-925-223-8242

Fax: +1-925-223-8243

E-mail: [bpgoffice@wjgnet.com](mailto:bpgoffice@wjgnet.com)

Help Desk: <http://www.wjgnet.com/esps/helpdesk.aspx>

<http://www.wjgnet.com>

