

Current debate in the oncologic management of rectal cancer

Trish Millard, Paul R Kunk, Erika Ramsdale, Osama E Rahma

Trish Millard, Paul R Kunk, Erika Ramsdale, Division of Hematology-Oncology, Department of Medicine, University of Virginia Health System, Charlottesville, VA 22908, United States

Osama E Rahma, Center for Immuno-Oncology/GI Oncology, Dana-Farber Cancer Institute, Boston, MA 02215, United States

Author contributions: All authors equally contributed to this paper with conception and design of the study, literature review and analysis, drafting and critical revision and editing, and final approval of the final version.

Conflict-of-interest statement: No potential conflicts of interest. No financial disclosure.

Open-Access: This article is an open-access article which was selected by an in-house editor and fully peer-reviewed by external reviewers. It is distributed in accordance with the Creative Commons Attribution Non Commercial (CC BY-NC 4.0) license, which permits others to distribute, remix, adapt, build upon this work non-commercially, and license their derivative works on different terms, provided the original work is properly cited and the use is non-commercial. See: <http://creativecommons.org/licenses/by-nc/4.0/>

Manuscript source: Invited manuscript

Correspondence to: Osama E Rahma, MD, Assistant Professor, Center for Immuno-Oncology/GI Oncology, Dana-Farber Cancer Institute, 450 Brookline Avenue, M1B13, Boston, MA 02215, United States. osamae_rahma@dfci.harvard.edu
Telephone: +1-617-6326954
Fax: +1-617-5827227

Received: March 26, 2016
Peer-review started: March 27, 2016
First decision: May 17, 2016
Revised: July 1, 2016
Accepted: August 27, 2016
Article in press: August 29, 2016
Published online: October 15, 2016

Abstract

Despite the considerable amount of research in the

field, the management of locally advanced rectal cancer remains a subject to debate. To date, effective treatment centers on surgical resection with the standard approach of total mesorectal resection. Radiation therapy and chemotherapy have been incorporated in order to decrease local and systemic recurrence. While it is accepted that a multimodality treatment regimen is indicated, there remains significant debate for how best to accomplish this in regards to order, dosing, and choice of agents. Preoperative radiation is the standard of care, yet remains debated with the option for chemoradiation, short course radiation, and even ongoing studies looking at the possibility of leaving radiation out altogether. Chemotherapy was traditionally incorporated in the adjuvant setting, but recent reports suggest the possibility of improved efficacy and tolerance when given upfront. In this review, the major studies in the management of locally advanced rectal cancer will be discussed. In addition, future directions will be considered such as the role of immunotherapy and ongoing trials looking at timing of chemotherapy, inclusion of radiation, and non-operative management.

Key words: Chemoradiation; Immunotherapy; Non-operative management; Neoadjuvant chemotherapy; Rectal cancer

© **The Author(s) 2016.** Published by Baishideng Publishing Group Inc. All rights reserved.

Core tip: Numerous controversies exist within the treatment of locally advanced rectal cancer. This review article summarizes the relevant evidence for rectal cancer treatment and offers opinions on how to interpret the data in clinical practice. Additional information is provided on novel areas of interest that are being actively explored such as the role of immunotherapy, the need for biomarkers, and the non-operative management.

Millard T, Kunk PR, Ramsdale E, Rahma OE. Current debate in the management of rectal cancer. *World J Gastrointest*

Oncol 2016; 8(10): 715-724 Available from: URL: <http://www.wjgnet.com/1948-5204/full/v8/i10/715.htm> DOI: <http://dx.doi.org/10.4251/wjgo.v8.i10.715>

INTRODUCTION

Over the last several decades, the approach to treat locally advanced rectal cancer has become more complex. Surgical and pathologic advances as well as multimodality approaches combining surgery, chemotherapy, and radiation therapy (RT) have decreased recurrence rates and improved quality of care. The mainstay of treatment to date has been surgical resection, and total mesorectal excision (TME) is the current standard. The goal of adjuvant therapy (radiation and chemotherapy) is to further decrease the rate of local and distant recurrences. Fluoropyrimidine-based chemotherapy both sensitizes the tumor cells to radiation as well as eliminates micrometastatic disease. However, despite refinements in the treatment of locally advanced rectal cancer, substantial controversies remain: Among them, the optimal course of radiation, sequencing of therapy, and surgical approach to clinical complete responses to neoadjuvant therapy. In this article, we highlight several of the prominent controversies in the treatment of locally advanced rectal cancer and provide a platform for discussion of evolving areas of interest within the field.

TIMING OF RADIATION AND SHORT COURSE RADIATION VS LONG COURSE CHEMORADIATION

The use of radiation therapy prior to surgery, rather than after surgery, is currently the standard of care for locally advanced rectal cancer. This is based on two large studies showing decreased local recurrence when radiation is used in the neoadjuvant setting (Table 1). In the Dutch TME trial, patients were randomized to RT and TME or to TME alone. This study showed an overall 5-year local recurrence rate of 4.6% in patients treated with radiation and TME and of 11% in the TME group ($P < 0.0001$) with no statistical significant difference in the rate of distant metastases^[1,2]. In the German CAO/ARO/AIO-94 phase III trial, patients were randomly assigned to preoperative or postoperative chemoradiation (CRT). Although the 5-year local relapse rate was better in the preoperative RT group (13% vs 6%, $P = 0.006$)^[3], the updated follow-up showed no statistical difference in the 10-year cumulative incidence of local relapse, disease-free survival or distant metastases^[4].

Both short course radiation therapy and long course CRT have been found to be effective in this setting, but no agreement exists in regards to the ideal method of neoadjuvant radiation-based treatments despite the publication of randomized, prospective data.

Neoadjuvant short course RT and long course CRT have been compared in three randomized, prospective trials (Table 1). The Trans-Tasman Radiation Oncology Group randomized cT3N0-2M0 rectal cancer patients (within 12 cm from the anal verge) to pre-operative short course radiation of 5x5Gy/fraction or CRT to a total dose of 50.4 Gy (28 fractions). The patients in the short course randomization proceeded to surgery within 3-7 d after radiation completion and were treated with 6 monthly cycles of adjuvant fluorouracil (425 mg/m²) 4-6 wk after surgery. The patients in the CRT group were treated with continuous infusion FU (225 mg/m²) daily for the duration of the radiation, followed by surgery 6 wk later and four monthly cycles of adjuvant fluorouracil (425 mg/m²). Interestingly, there was no significant difference in three-year local recurrence rate (7.5% vs 4.4%, $P = 0.24$) or five-year distant recurrence rate (27% vs 30%, $P = 0.92$) between the two groups. However, pathologic downstaging was significantly more common in the CRT than in short course group (45% vs 28%, $P = 0.002$), but there was no difference in organ sparing surgeries, nor any difference in late toxicities (5.8% vs 8.2%, $P = 0.53$)^[5]. The authors concluded that long course CRT may be more effective than short course for distal tumors, based on a trend toward decrease in local recurrence. In a similar design, the Polish Colorectal Study Group randomized patients with cT3-4 resectable rectal cancer to either CRT (50.4 Gy in 28 fractions with bolus 5-fluorouracil and leucovorin) followed by surgery 4-6 wk later or to short course radiation (25 Gy in 5 fractions) followed by surgery 7 d later. As seen in the Trans-Tasman Radiation Oncology Group there was no statistical significant difference in the 4-year local recurrence rate (10.6% in the short course group vs 15.6% in the CRT group, $P = 0.21$). However, there was a significant difference in the pathologic complete response (pCR) in favor of the CRT group, and the short course group was significantly more likely to have a positive surgical margin^[6]. Although intriguing, this is likely due to the early surgery in the short course group rather than type of radiation as a longer interval before surgery has been shown to increase the rate of pCR^[7]. There was no difference in the rate of sphincter preservation, overall survival, or the incidence of late toxicity at a median follow up of 4 years incidence between the two groups^[6]. The Polish Colorectal Study Group most recently reported on a study randomizing patients to preoperative short course RT with consolidation FOLFOX4 for 3 cycles or to preoperative CRT. There was no statistical difference in rate of pCR between the short course consolidation and CRT groups (16% vs 11.5%, $P = 0.19$) and no difference at 3 years in overall survival, disease-free survival, and cumulative incidence of local failure^[8].

Although preoperative radiation is shown to be superior to postoperative radiation in terms of improving local recurrence rate, it remains unclear whether short course RT or long course CRT is preferable. The use of

Table 1 Landmark radiation trials in rectal cancer

Ref.	Study type	Treatment	Outcomes disease control	Overall survival	Comments
Dutch TME Trial van Gijn <i>et al</i> ^[1]	Phase III <i>n</i> = 1805	RT + TME <i>vs</i> TME alone	5-yr LR 4.6% <i>vs</i> 11% (<i>P</i> < 0.0001) 10-yr DR 25% <i>vs</i> 28% (<i>P</i> = 0.21)	48% <i>vs</i> 49% (<i>P</i> = 0.86) (10-yr)	
German CAO/ARO/ AIO-94 Sauer <i>et al</i> ^[3]	Phase III <i>n</i> = 823	Preoperative <i>vs</i> Postoperative CRT	5-yr LR 6% <i>vs</i> 13% (<i>P</i> = 0.006) 10-yr LR 7.1% <i>vs</i> 10.1% (<i>P</i> = 0.048) 10-yr DR 29.8% <i>vs</i> 29.6% (<i>P</i> = 0.9)	59.6% <i>vs</i> 59.9% (<i>P</i> = 0.85) (10-yr)	
TTROG Trial 01.04 Ngan <i>et al</i> ^[5]	Phase III <i>n</i> = 326	Preoperative RT <i>vs</i> CRT	3-yr LR 7.5% <i>vs</i> 4.4% (<i>P</i> = 0.24) 5-yr DR 27% <i>vs</i> 30% (<i>P</i> = 0.92)	74% <i>vs</i> 70% (0.62) (5-yr)	Short course RT with more pathologic downstaging (28% <i>vs</i> 45%b). No difference in organ sparing surgeries or late toxicities
Polish Colorectal Study Group Bujko <i>et al</i> ^[6]	Phase III <i>n</i> = 316	Preoperative RT <i>vs</i> CRT	4-yr LR 10.6% <i>vs</i> 15.6% (<i>P</i> = 0.21) 4-yr DR 31.4% <i>vs</i> 34.6% (<i>P</i> = 0.54)	67.2% <i>vs</i> 66.2% (<i>P</i> = 0.960) (4-yr)	CRT with improved pCR is attributed to longer interval before surgery. No difference in rate of sphincter preservation or late toxicities
Polish II Multicentre Bujko <i>et al</i> ^[8]	Phase III <i>n</i> = 515	Preoperative RT with adjuvant FOLFOX4 <i>vs</i> CRT	R0 77% <i>vs</i> 71% (<i>P</i> = 0.081) pCR 16% <i>vs</i> 11.5% (<i>P</i> = 0.19)	73% <i>vs</i> 64.5% (<i>P</i> = 0.055) (3-yr)	Published at GI ASCO 2016 with median follow up of 35 mo

LR: Local recurrence; DR: Distant recurrence; RT: Radiation therapy; TME: Total mesorectal excision; CRT: Chemotherapy radiation therapy.

CRT did improve downstaging in both of these studies, but this is likely due to the difference in timing between completion of radiotherapy and surgical resection between the two groups. The advantages of short course RT include reduced duration and cost of therapy, but there remains concerns about late toxicity. In addition, it remains unclear whether CRT provides any meaningful long term advantages given lack of benefit in controlling distant metastases or improving overall survival.

CHEMOTHERAPY COMPONENT OF CHEMORADIATION: WHICH AGENTS?

Standard neoadjuvant CRT includes a fluoropyrimidine as the chemotherapy component, primarily due to the radiation sensitization activity of these drugs. Capecitabine, an oral prodrug converted to 5-fluorouracil (5-FU) by intracellular thymidine phosphorylase, has been shown to be non-inferior to infusional 5-FU for this indication^[9,10]. It is unclear, however, whether multi-agent chemotherapy regimens combined with radiotherapy can improve outcomes. Several studies (Table 2) have investigated the addition of oxaliplatin to fluorouracil-based neoadjuvant CRT including the NSABP R-04^[9], the STAR-01^[11], the ACCORD 12/0405-ProDIGE 2^[12], and the PETACC-6^[13]. These studies added weekly oxaliplatin to either infusional fluorouracil or capecitabine in combination with preoperative radiation. The results of these studies showed no difference in therapeutic outcomes, including pathologic complete response, locoregional control, and survival outcomes, and there was an increase in grade 3-4 treatment toxicities in patients treated with oxaliplatin. In contrast, the results of the German CAO/ARO/AIO-04 suggest a

possible benefit with the addition of oxaliplatin to CRT. In this trial, patients with T3-4 or cN+ rectal cancer were randomized to preoperative long course CRT with infusional fluorouracil (1000 mg/m² days 1-5 and 29-33) followed by surgery and four cycles of adjuvant bolus fluorouracil (500 mg/m² days 1-5 and 29) or to preoperative CRT with infusional fluorouracil (250 mg/m² days 1-14 and 22-35) and oxaliplatin (50 mg/m² days 1, 8, 22, and 29) followed by surgery and eight cycles of adjuvant infusional fluorouracil (2400 mg/m² days 1-2 and 15-16), leucovorin (400 mg/m² days 1 and 15), and oxaliplatin (100 mg/m² days 1 and 15). Patients in the investigational arm had a higher pathologic complete response rate (17% *vs* 13%, *P* = 0.038) and a higher disease free survival (DFS) at 3 years (75.9% *vs* 71.2%, *P* = 0.03), without increases in overall toxicity^[14,15]. The results should be interpreted with caution given that different fluorouracil dosing and regimens were used in the two treatment arms. It is also unclear whether the improved DFS is attributable to the adjuvant inclusion of oxaliplatin. Moreover, the patients in the oxaliplatin arm were treated with eight cycles of adjuvant chemotherapy, but the control patients only received four cycle. Thus, this difference in protocol may contribute to the difference in disease free survival.

ADJUVANT CHEMOTHERAPY: WHAT AND WHEN?

Modern surgical techniques combined with radiotherapy have dramatically improved locoregional control of locally advanced rectal cancer, but systemic control remains a significant issue. Distant relapse is now the main driver of adverse survival outcomes in this disease. The rationale for adjuvant chemotherapy in surgically resected rectal

Table 2 Landmark chemotherapy studies in locally advanced rectal cancer

Ref.	Study type	Treatment	Outcomes	Comments
TIMING Garcia-Aguilar <i>et al</i> ^[22]	Phase II <i>n</i> = 144	All treated with CRT If evidence of response, given 2 cycles upfront FOLFOX6 then TME If no response, proceed to TME 6 wk after CRT	70 patients treated with upfront FOLFOX6 74 patients proceeded directly to TME pCR 25% <i>vs</i> 18% (<i>P</i> > 0.05)	No difference in toxicities
MSKCC Cercek <i>et al</i> ^[23]	Retrospective <i>n</i> = 61	Upfront FOLFOX (median 7 cycles) followed by CRT	Patients with TME (49): 100% R0 resections pCR 27%	Non-randomized, retrospective data
Calvo <i>et al</i> ^[24]	Prospective non-randomized <i>n</i> = 116	Upfront FOLFOX-4 (2 cycles) followed by CRT compared to historical controls treated with CRT	52 patients treated with upfront FOLFOX pCR 29% <i>vs</i> 8% (<i>P</i> = 0.006)	3 patients in FOLFOX had grade 3-4 toxicities (<i>vs</i> 0). No difference in surgical complications
Chau <i>et al</i> ^[25]	Prospective non-randomized <i>n</i> = 77	Upfront CAPOX (4 cycles) followed by CRT with TME 6 wk later	R0 resections in all but 1 patient pCR 24%, additional 48% with only microscopic tumor foci	10% with cardiac or thromboembolic toxicity during CAPOX. 12% with grade 3-4 diarrhea during CAPOX
Schou <i>et al</i> ^[26]	Prospective non-randomized <i>n</i> = 84	Upfront CAPOX (2 cycles) followed by CRT with TME 6 wk later	94% R0 resections pCR 23% 5-yr DFS 63%, 5-yr OS 67%	Grade 3-4 toxicities in 18%
Marechal <i>et al</i> ^[27]	Phase II, randomized <i>n</i> = 57	Randomized to preoperative CRT followed by TME <i>vs</i> upfront FOLFOX followed by CRT and TME	ypT0-1N0 34.5% <i>vs</i> 32.1% (<i>P</i> = 0.85) pCR 28% <i>vs</i> 25% (<i>P</i> = 0.92) pCR 16% <i>vs</i> 16% (<i>P</i> = 0.904)	A pre-planned interim analysis no difference in primary endpoints; study closed prematurely for futility
STAR-01 Aschele <i>et al</i> ^[11]	Phase III <i>n</i> = 747	Preoperative CRT with fluorouracil \pm oxaliplatin	pCR 16% <i>vs</i> 16% (<i>P</i> = 0.904)	Oxaliplatin group had more grade 3-4 adverse events (24% <i>vs</i> 8% <i>P</i> < 0.001)
ACCORD12/0405-Prodige 2 Gérard <i>et al</i> ^[12]	Phase III <i>n</i> = 598	Preoperative CRT with capecitabine \pm oxaliplatin	pCR 19.2% <i>vs</i> 13.9% (<i>P</i> = 0.09)	Oxaliplatin group had more grade 3-4 adverse events (25% <i>vs</i> 1%, <i>P</i> < 0.001)
NSABP R-04 O'Connell <i>et al</i> ^[9]	Phase III <i>n</i> = 1608	Preoperative CRT with fluorouracil \pm oxaliplatin <i>vs</i> Preoperative CRT with capecitabine \pm oxaliplatin	FU <i>vs</i> Cap: pCR 17.8% <i>vs</i> 20.7% (<i>P</i> = 0.14) Oxaliplatin <i>vs</i> No Oxaliplatin: pCR 19.5% <i>vs</i> 17.8% (<i>P</i> = 0.42) pCR 11.3% <i>vs</i> 13.3% (<i>P</i> = 0.31)	Patients treated with oxaliplatin experienced significantly more grade 3 or 4 diarrhea (<i>P</i> < 0.001)
PETACC-6 Schmoll <i>et al</i> ^[13]	Phase III <i>n</i> = 1094	Preoperative CRT with capecitabine \pm oxaliplatin (adjuvant chemo same drugs as preoperative)	pCR 11.3% <i>vs</i> 13.3% (<i>P</i> = 0.31)	Patients treated with preoperative oxaliplatin had significant more grade 3-4 adverse events (36.7% <i>vs</i> 15.1%)
German CAO/ARO/AIO-04 Rodel <i>et al</i> ^[15]	Phase III <i>n</i> = 1236	Preoperative CRT with fluorouracil \pm oxaliplatin (adjuvant chemo same drugs as preoperative)	pCR 17% <i>vs</i> 13% (<i>P</i> = 0.038) 3-yr DFS 75.9% <i>vs</i> 71.2%	Different fluorouracil dosing/schedule and different number of adjuvant cycles used across the arms
EORTC 22921 Bosset <i>et al</i> ^[19]	Phase III <i>n</i> = 1011	Preoperative RT + adjuvant FU/L <i>vs</i> preoperative RT <i>vs</i> CRT with adjuvant FU/L <i>vs</i> CRT	10-yr LR 14.5% <i>vs</i> 22.4% <i>vs</i> 11.7% <i>vs</i> 11.8% (<i>P</i> = 0.0017) ^a 10-yr DR 35.9% <i>vs</i> 39.6% <i>vs</i> 34.1% <i>vs</i> 33.4% (<i>P</i> = 0.52)	Any chemotherapy (neoadjuvant only, adjuvant only, or both) had significant reduction in local recurrence, but no difference in OS. Used concomitant bolus FU dosing not commonly utilized in the United States, and only four cycles of adjuvant chemotherapy

^a*P* < 0.01 any chemo *vs* no chemo. LR: Local recurrence; DR: Distant recurrence; TME: Total mesorectal excision; CRT: Chemotherapy radiation therapy.

cancer is largely extrapolated from colon cancer data^[16], but is also supported by a meta-analysis of randomized trials that compared surgery with or without adjuvant chemotherapy for rectal cancer^[17]. The European Organization for Research and Treatment of Cancer (EORTC) 22921 phase III trial randomized patients with clinical stage II or III resectable rectal cancer to preoperative radiation with or without concomitant fluorouracil (350 mg/m² IV bolus over 5 d) with leucovorin (20 mg/m² IV) followed by either surveillance or four cycles of adjuvant fluorouracil/leucovorin^[18]. There was no difference in the 10-year overall survival between patients getting adjuvant chemotherapy or not (51.8% *vs* 48.4%, *P* = 0.32). Additionally, the rate of

distant metastasis between all arms had no significant difference (34.1%-39.6%). However, the three arms receiving any chemotherapy (neoadjuvant only, adjuvant only, or both) had significant reduction in local recurrence (11.8%-14.5%) compared to those treated with radiation alone (22.4%, *P* = 0.0017), but this did not translate to an overall survival advantage^[19]. Notably, the EORTC 22921 trial incorporated a concomitant bolus fluorouracil dosing not commonly utilized in the United States, and only four cycles of adjuvant chemotherapy were given. Moreover, there were significant deviations from planned treatment, with 26.9% in the adjuvant group never initiating adjuvant therapy, most commonly due to post-operative complications, and less than 43% of

patients received the planned dose within the scheduled time interval^[18]. Despite the controversial results of the EORTC 22921, there remains substantial interest in the use of systemic chemotherapy, both as adjuvant therapy and as CRT, to decrease distant metastatic disease and improve survival^[20]. The theoretical advantages of systemic chemotherapy include eradicating distant micrometastases and providing ideal systemic treatment prior to a large and potential debilitating surgery (and thus a less fit patient)^[21].

Given the difficulties with adherence to postoperative chemotherapy, there is now significant interest in the utility of administering chemotherapy preoperatively (Table 2). In the phase II TIMING trial, stage II and III rectal cancer patients were treated with CRT, and those patients with evidence of clinical response 4 wk after CRT received two cycles of modified FOLFOX-6 followed by TME 3-5 wk later. The remainder of the patients proceeded to TME 6 wk after completion of CRT. The preliminary results from this study showed pathologic complete response of 25% in those treated with the upfront modified FOLFOX-6 compared to 18% in those who proceeded to surgery directly, but this result did not reach statistical significance^[22]. Memorial Sloan-Kettering Cancer Center (MSKCC) reported on its institutional experience offering upfront FOLFOX for patients with high-risk locally advanced rectal cancer. Sixty-one patients received induction FOLFOX (median 7 cycles), and of the 49 patients who proceeded to TME all had R0 resections and 47% had greater than 90% tumor response, with 27% pathologic complete responses^[23]. Despite the encouraging results of this trial, it should be interpreted with caution given the small sample size, the retrospective nature of the analyses, and the lack of randomization.

Several non-randomized studies have been conducted to investigate the use of neoadjuvant chemotherapy. Calvo *et al.*^[24] reported on patients with locally advanced rectal cancer treated with two cycles of induction FOLFOX-4 (oxaliplatin 85 mg/m² D1, 5-FU 400 mg/m² IV bolus and 600 mg/m² IV continuous in 22 h on D1 and D2, folinic acid 200 mg/d IV D1 and D2) followed by immediate CRT. Compared to patients treated with preoperative CRT alone, there was no significant difference in toxicities and patients treated with the induction chemotherapy had significantly more ypT0 (29% vs 8%, $P = 0.006$)^[24]. Chau *et al.*^[25] reported on 77 consecutive patients with MRI-defined poor-risk locally advanced rectal cancer treated with 12 wk of neoadjuvant chemotherapy (CAPOX: Oxaliplatin 130 mg/m² every 3 wk with capecitabine 2000 mg/m² 14 d on with 7 d off) followed by CRT with TME 6 wk after completion of CRT. All but one of the patients had R0 resections, pCR was seen in 16 patients, and an additional 32 patients had only microscopic tumor foci^[25]. Schou *et al.*^[26] report on 84 consecutive patients with locally advanced rectal cancer treated with two cycles of CAPOX before CRT followed by TME 6 wk later. An R0 resection was seen in 94% of patients, a pCR was seen in 23% of patients, and T downstaging occurred in

69%^[26]. Additional phase II studies examining the benefit of neoadjuvant chemotherapy have been reported. Marechal *et al.*^[27] reported on a phase II study of patients with T2-T4/N+ locally advanced rectal cancer who were randomly assigned to preoperative CRT (continuous infusion fluorouracil) or to oxaliplatin, folinic acid, and 5-FU followed by CRT and surgery. There was no difference in rate of patients with ypT0-1N0 (32.1% for patients with treated with neoadjuvant chemotherapy vs 34.5% for patients treated with CRT alone, $P = 0.85$), and there was no difference in pCR between the two groups. The patients treated with induction chemotherapy had significantly more grade 3-4 toxicities than those treated with CRT (35% vs 7%, $P = 0.017$). The results of these non-randomized studies show improved local control with neoadjuvant chemotherapy as well as good tolerance.

CAN RADIATION BE OMITTED?

Given potential improved pathological and clinical responses and good treatment tolerance with the incorporation of neoadjuvant systemic chemotherapy, some have questioned whether radiation can be omitted completely. The GEMCAD 0801 phase II trial included 46 patients with resectable T3N0-2 rectal adenocarcinoma and treated with four cycles of neoadjuvant capecitabine and oxaliplatin with bevacizumab (for the first 3 cycles) before TME. Pathologic CR occurred in 20% and T downstaging was observed in 48% of patients. It was noted that there was a 13% rate of anastomotic leak, which is higher than expected, and could be attributed to bevacizumab^[28]. Another phase II trial that was conducted at MSKCC administered six cycles of FOLFOX with bevacizumab for cycles 1-4 to newly diagnosed stage II-III rectal cancer. Patients with progression were treated with CRT followed by TME, and those that had stable disease or better proceeded directly to TME. All patients except 2 underwent surgery and they all had R0 resections with a 25% pCR rate, with no local recurrence at 4 years^[29]. Based on these results, the PROSPECT (Preoperative Radiation or Selective Preoperative Radiation and Evaluation Before Chemotherapy and TME) trial was launched^[30]. The PROSPECT trial is a phase II/III randomized trial designed to address whether preoperative radiation therapy can be used more selectively in locally advanced rectal cancer (Figure 1). Patients with T2N1 or T3N0-1 rectal cancer are randomized to either standard CRT or to six cycles of FOLFOX. Patients on the investigational arm undergo repeat staging prior to surgery, and those who fail to have a response of at least 20% per RECIST criteria proceed to treatment with CRT prior to surgery. Adjuvant chemotherapy with FOLFOX is suggested but not required. The outcomes of this study may change the paradigm of rectal cancer neoadjuvant treatment.

NON-OPERATIVE APPROACH

Neoadjuvant CRT results in significant downstaging of

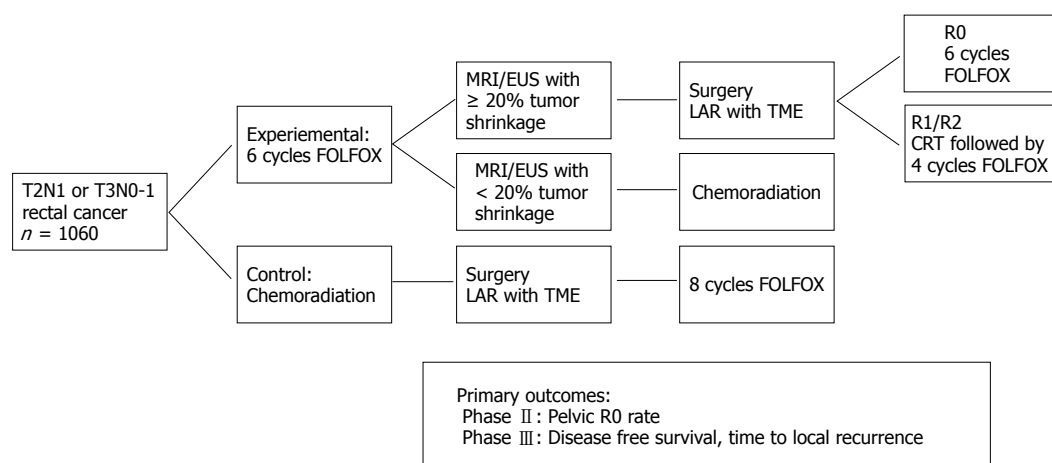


Figure 1 Preoperative radiation or selective preoperative radiation and evaluation before chemotherapy and total mesorectal excision trial investigating rectal cancer treatment without radiation. TME: Total mesorectal excision; MRI: Magnetic resonance imaging. Adapted from Clinicaltrials.gov.

locally advanced rectal cancer, and 15%-27% of patients will have a pathologic complete response (pCR)^[31]. The main question is whether patients who achieve pCR could be monitored rather than operated on in order to avoid the post-surgical comorbidities. Complete pathological response was found to correlate with 5-year DFS in a meta-analysis of patients with locally advanced rectal cancer treated with preoperative CRT (5 year DFS for patients with a pCR was 83.3% compared to 65.6% for those without pCR, $P < 0.0001$)^[31]. For those patients with a pCR to neoadjuvant treatment, a nonoperative approach has been investigated in several case series^[32-34]. Habr-Gama *et al.*^[33-35] reported on patients with clinical T2-4, N0-1 rectal cancer treated with CRT followed by assessment for clinical response 8 wk later. In this trial, 26.8% of the patients had a complete clinical response (cCR) based on exam, imaging, and endoscopy (including biopsies) and were subsequently monitored expectantly. The first year of surveillance included monthly physical exam, digital rectal exam, proctoscopy, and serum CEA levels as well as CT scans of the abdomen and pelvis every six months. Follow up visits were spaced to every two months for the second year and to every six months for the third year. Two patients developed local recurrence 56 and 65 mo after completion of CRT and were treated successfully with transanal full-thickness excision and salvage brachytherapy, respectively. Three patients developed systemic metastases for an overall recurrence rate of 7%, and no cancer related deaths occurred with a median follow up of 57.3 mo^[33]. Subsequent publications from this group showed similar results^[34]. A large phase II trial by MSKCC (Figure 2) is underway to further investigate the efficacy and safety of a non-operative approach. Patients with T3-4N0-1 locally advanced rectal cancer by MRI all receive neoadjuvant CRT and 4 mo of chemotherapy (CAPOX or FOLFOX), with randomization of the sequence of receipt. Patients with a cCR or near-cCR on follow-up examination will proceed to nonoperative expectant

management every 3 mo for two years and every 6 mo thereafter^[36,37]. This investigated approach may save patients the comorbidities associated with surgical intervention. However, if this approach is proven to be effective there needs to be a standard approach to surveillance. A small study reported data on the utility of combining clinical assessment (DRE and endoscopy) with T2W-MRI and diffusion-weighted MRI as having a 98% posttest probability for a cCR^[38].

Clinical downstaging from neoadjuvant therapy has instigated interest in other surgical management options; though TME has significantly improved outcomes, it is associated with considerable morbidity, including long term consequences such as fecal incontinence, urinary dysfunction, sexual dysfunction, and permanent ostomy^[39]. These issues can significantly impair patients' quality of life. Case series and retrospective data have indicated that carefully selected patients may have good oncologic outcomes from less aggressive surgical procedures^[40,41]. A prospective study of 10 patients with T3 rectal cancer who were deemed unfit for a radical surgical excision with TME or refused large surgery, were treated with CRT followed by transanal excision with no recurrence at 24 mo follow up^[42]. Another small but prospective and randomized study compared 100 patients with cT2N0 rectal cancer treated with CRT and randomized to either TME or endoluminal locoregional resection by transanal endoscopic microsurgery. There was no difference in local recurrence or metastatic recurrence, but these findings are limited by the small number of patients and that the patients were early stage and not being the definition of locally advanced disease^[43]. More recent evidence comes from a non-randomized, phase II trial of 79 patients with cT2N0 distal rectal cancer treated with neoadjuvant CRT followed by local excision. The primary endpoint, 3-year DFS, was 88.2%, and eight (10%) patients had recurrence (5 distant and 3 local)^[44]. This study shows that patients with cT2N0 distal rectal cancer may be treated with local excision, but is limited by lack of comparative results.

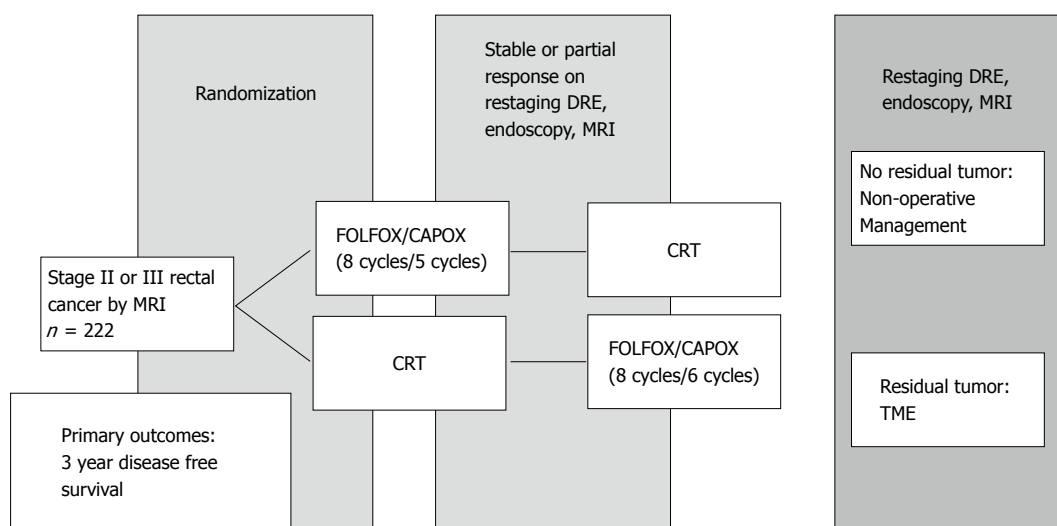


Figure 2 Memorial Sloan-Kettering Cancer Center phase II study of non-operative approach. TME: Total mesorectal excision; MRI: Magnetic resonance imaging. Adapted from Clinicaltrials.gov.

Local excision is an option for patients who cannot tolerate a major surgery, but it remains uncertain if this approach results in similar oncologic outcomes particularly in locally advanced stages of disease.

CONCLUSION

Despite considerable advances in rectal cancer treatment over the last two decades, controversies remain. The current standard is to treat patients with preoperative radiation, but the optimal course (CRT or 5×5 Gy) is not known. Studies suggest that the addition of oxaliplatin to CRT does not provide significant additional benefit and adds toxicity. As new approaches to chemotherapy are investigated, the inclusion of RT is being questioned. However, the optimal approach and timing for systemic chemotherapy in locally advanced rectal cancer has not been answered. Even the role of surgery, the traditional sine qua non of rectal cancer therapy, is being questioned, with non-operative approaches to management demonstrating excellent outcomes without the consequences of surgery.

Further refinements in approach may rely on the identification of predictive biomarkers in this disease. Advances in genomic and molecular tumor profiling have facilitated this search. Biopsy specimens from 52 patients with rectal cancer planned for preoperative radiotherapy were submitted to gene expression profiling using DNA microarray analysis (U95Av2 Gene Chip). The profiles of radiation responders and non-responders were compared, and thirty-three novel genes were identified with differential expression; these genes could predict response with an accuracy of 88.6%^[45]. Similar studies have been conducted to predict response to CRT^[46-49]. DNA microanalysis has identified genes predictive of response, but no genes were reported consistently across the studies. Nishioka *et al.*^[48] attempted to identify a candidate gene using immunohistochemistry (IHC) to

validate the DNA microarray results. Among 20 patient biopsies, 17 potentially predictive genes were identified. Matrix metalloproteinase-7 (MMP7) was identified as the gene with the largest difference between responders and non-responders and was analyzed with IHC. MMP7 was found to be overexpressed by IHC in 4 out of 10 responders and 0 out of 7 non-responders. Watanabe *et al.*^[49] used DNA microanalysis to identify four genes (LRRIQ3, FRMD3, SAMD5, and TMC7) expressed in responders to CRT with 89.1% prediction accuracy and validated the gene expression by RT-PCR analyses. While these results are intriguing, widespread clinical application remains limited by lack of reproducibility and the need for independent validation across separate cohorts.

Another area of investigation is the tumor micro-environment and how it interacts with the immune system. Immunologic features of tumor microenvironment may predict tumor response to therapy as well as form the basis for innovative treatment strategies. Studies of colorectal cancer showed that the patterns of immune cell infiltration within tumors had prognostic significance and lead to the development of the Immune Score^[50-52]. The densities of CD45RO⁺ memory T-cells and CD8⁺ cytotoxic T-cells tumor infiltrating lymphocytes (TILs) were determined for patients with stage I and II colorectal cancer. Higher densities at both the center of the tumor and the invasive margin were predictive of superior patient outcomes including disease free, disease specific, and overall survival ($P < 0.001$)^[52]. Not only does the number of CD8⁺ TILs correlate with survival, but it has been shown to have superior prognostication than the TNM staging^[53]. Although it is evident that colorectal tumors are infiltrated by the immune cells, mainly T-cells, this infiltration is not sufficient to induce tumor response. This may be due in part to the immune suppression provided by the activation of immune checkpoints, such as PD-L1/PD-1 pathway. Examination of colorectal tumors showed

PD-L1 expression in 37% of mismatch repair (MMR)-proficient tumors and in 29% of MMR-deficient tumors, with a strong correlation between PD-L1 expression and infiltration with CD8⁺ T-cells in the MMR-proficient tumors ($P = 0.0001$)^[54]. However, treatment with PD-L1 monoclonal antibody nivolumab showed no objective responses in 18 patients with colorectal cancer^[55]. More recent data revealed that high microsatellite instable tumors selectively exhibit upregulated expression of immune checkpoints including those being studied as drug targets: PD-1, PD-L1, CTLA4, LAG-3, and IDO^[56]. Accordingly, microsatellite stability may be a biomarker for immunotherapy in colorectal cancer, given the fact that tumors with microsatellite instabilities tend to have higher mutational loads leading to a better recognition by the immune system. Another area of active investigation is combination therapy of immunotherapy and CRT. Based on preliminary data showing that neoadjuvant CRT can lead to increase T-cells in rectal cancer^[57], we are currently in the process of conducting a phase II study investigating neoadjuvant CRT and pembrolizumab (anti-PD-1) in patients with stage II and III rectal cancer cancer^[58]. Furthermore, novel clinical trial designs need to be implemented in the neoadjuvant setting in colorectal cancer. The National Cancer Institute is planning to launch a large clinical trial to evaluate 3-year DFS in patients managed with total neoadjuvant therapy and TME or non-operative management, compared with standard historical controls managed according to standard of care (CRT and TME followed by adjuvant chemotherapy). The historical control arm continues to enroll patients while the adaptive trial design allows the addition of other investigational arms. This novel trial design and others will bring more advances to the field that may change the paradigm of rectal cancer treatment.

REFERENCES

- 1 van Gijn W, Marijnen CA, Nagtegaal ID, Kranenbarg EM, Putter H, Wiggers T, Rutten HJ, Pahlman L, Glimelius B, van de Velde CJ. Preoperative radiotherapy combined with total mesorectal excision for resectable rectal cancer: 12-year follow-up of the multicentre, randomised controlled TME trial. *Lancet Oncol* 2011; **12**: 575-582 [PMID: 21596621 DOI: 10.1016/s1470-2045(11)70097-3]
- 2 Kusters M, Marijnen CA, van de Velde CJ, Rutten HJ, Lahaye MJ, Kim JH, Beets-Tan RG, Beets GL. Patterns of local recurrence in rectal cancer; a study of the Dutch TME trial. *Eur J Surg Oncol* 2010; **36**: 470-476 [PMID: 20096534 DOI: 10.1016/j.ejso.2009.11.011]
- 3 Sauer R, Becker H, Hohenberger W, Rödel C, Wittekind C, Fietkau R, Martus P, Tschmelitsch J, Hager E, Hess CF, Karstens JH, Liersch T, Schmidberger H, Raab R. Preoperative versus postoperative chemoradiotherapy for rectal cancer. *N Engl J Med* 2004; **351**: 1731-1740 [PMID: 15496622 DOI: 10.1056/NEJMoa040694]
- 4 Sauer R, Liersch T, Merkel S, Fietkau R, Hohenberger W, Hess C, Becker H, Raab HR, Villanueva MT, Witzigmann H, Wittekind C, Beissbarth T, Rödel C. Preoperative versus postoperative chemoradiotherapy for locally advanced rectal cancer: results of the German CAO/ARO/AIO-94 randomized phase III trial after a median follow-up of 11 years. *J Clin Oncol* 2012; **30**: 1926-1933 [PMID: 22529255 DOI: 10.1200/jco.2011.40.1836]
- 5 Ngan SY, Burmeister B, Fisher RJ, Solomon M, Goldstein D, Joseph D, Ackland SP, Schache D, McClure B, McLachlan SA, McKendrick J, Leong T, Hartopanu C, Zalberg J, Mackay J. Randomized trial of short-course radiotherapy versus long-course chemoradiation comparing rates of local recurrence in patients with T3 rectal cancer: Trans-Tasman Radiation Oncology Group trial 01.04. *J Clin Oncol* 2012; **30**: 3827-3833 [PMID: 23008301 DOI: 10.1200/jco.2012.42.9597]
- 6 Bujko K, Nowacki MP, Nasierowska-Guttmejer A, Michalski W, Bebenek M, Kryj M. Long-term results of a randomized trial comparing preoperative short-course radiotherapy with preoperative conventionally fractionated chemoradiation for rectal cancer. *Br J Surg* 2006; **93**: 1215-1223 [PMID: 16983741 DOI: 10.1002/bjs.5506]
- 7 Petrelli F, Sgroi G, Sarti E, Barni S. Increasing the Interval Between Neoadjuvant Chemoradiotherapy and Surgery in Rectal Cancer: A Meta-analysis of Published Studies. *Ann Surg* 2016; **263**: 458-464 [PMID: 24263329 DOI: 10.1097/sla.0000000000000368]
- 8 Bujko K, Sklodowska M. Neoadjuvant chemoradiation for fixed cT3 or cT4 rectal cancer: Results of a Polish II multicentre phase III study. San Francisco, CA: Proceedings of the ASCO Gastrointestinal Cancers Symposium, 2016
- 9 O'Connell MJ, Colangelo LH, Beart RW, Petrelli NJ, Allegra CJ, Sharif S, Pitot HC, Shields AF, Landry JC, Ryan DP, Parda DS, Mohiuddin M, Arora A, Evans LS, Bahary N, Soori GS, Eakle J, Robertson JM, Moore DF, Mullane MR, Marchello BT, Ward PJ, Wozniak TF, Roh MS, Yothers G, Wolmark N. Capecitabine and oxaliplatin in the preoperative multimodality treatment of rectal cancer: surgical end points from National Surgical Adjuvant Breast and Bowel Project trial R-04. *J Clin Oncol* 2014; **32**: 1927-1934 [PMID: 24799484 DOI: 10.1200/jco.2013.53.7753]
- 10 Hofheinz RD, Wenz F, Post S, Matzdorff A, Laechelt S, Hartmann JT, Müller L, Link H, Moehler M, Kettner E, Fritz E, Hieber U, Lindemann HW, Grunewald M, Kremers S, Constantin C, Hipp M, Hartung G, Gencer D, Kienle P, Burkholder I, Hochhaus A. Chemoradiotherapy with capecitabine versus fluorouracil for locally advanced rectal cancer: a randomised, multicentre, non-inferiority, phase 3 trial. *Lancet Oncol* 2012; **13**: 579-588 [PMID: 22503032 DOI: 10.1016/s1470-2045(12)70116-x]
- 11 Aschele C, Cionini L, Lonardi S, Pinto C, Cordio S, Rosati G, Artale S, Tagliagambe A, Ambrosini G, Rosetti P, Bonetti A, Negru ME, Tronconi MC, Luppi G, Silvano G, Corsi DC, Boicchio AM, Chialoulon G, Gallo M, Boni L. Primary tumor response to preoperative chemoradiation with or without oxaliplatin in locally advanced rectal cancer: pathologic results of the STAR-01 randomized phase III trial. *J Clin Oncol* 2011; **29**: 2773-2780 [PMID: 21606427 DOI: 10.1200/jco.2010.34.4911]
- 12 Gérard JP, Azria D, Gourgou-Bourgade S, Martel-Laffay I, Hennequin C, Etienne PL, Vendrely V, François E, de La Roche G, Bouché O, Mirabel X, Denis B, Mineur L, Berdah JF, Mahé MA, Bécouarn Y, Dupuis O, Lledo G, Montoto-Grillot C, Conroy T. Comparison of two neoadjuvant chemoradiotherapy regimens for locally advanced rectal cancer: results of the phase III trial ACCORD 12/0405-ProDIGE 2. *J Clin Oncol* 2010; **28**: 1638-1644 [PMID: 20194850 DOI: 10.1200/jco.2009.25.8376]
- 13 Schmoll HJ, Haustermans K, Price TJ, Nordlinger B, Hofheinz R, Daisne JF, Janssens J, Brenner B, Schmidt P, Reinle H, Hollerbach S, Caca K, Fauth F, Hannig C, Zalberg JR, Tebbutt NC, Mauer ME, Messina C, Manfred P. Preoperative chemoradiotherapy and postoperative chemotherapy with capecitabine and oxaliplatin versus capecitabine alone in locally advanced rectal cancer: Disease-free survival results at interim analysis. *J Clin Oncol* 2014; **32** suppl: abstr 3501
- 14 Rödel C, Liersch T, Becker H, Fietkau R, Hohenberger W, Hothorn T, Graeven U, Arnold D, Lang-Welzenbach M, Raab HR, Sülberg H, Wittekind C, Potapov S, Staib L, Hess C, Weigang-Köhler K, Grabenbauer GG, Hoffmanns H, Lindemann F, Schlenska-Lange A, Folprecht G, Sauer R. Preoperative chemoradiotherapy and postoperative chemotherapy with fluorouracil and oxaliplatin versus fluorouracil alone in locally advanced rectal cancer: initial results of the German CAO/ARO/AIO-04 randomised phase 3 trial. *Lancet Oncol* 2012; **13**: 679-687 [PMID: 22627104 DOI: 10.1016/s1470-2045(12)70187-0]
- 15 Rödel C, Liersch T, Fietkau R, Hohenberger W, Graeven U, Hothorn

- T, Arnold D, Raab H-R, Wittekind C, Hess CF, Staib L, Becker H, Sauer R, German Rectal Cancer Study Group. Preoperative chemoradiotherapy and postoperative chemotherapy with 5-fluorouracil and oxaliplatin versus 5-fluorouracil alone in locally advanced rectal cancer: Results of the German CAO/ARO/AIO-04 randomized phase III trial. *J Clin Oncol* 2014; **32**: 3500
- 16 **André T**, Boni C, Navarro M, Tabernero J, Hickish T, Topham C, Bonetti A, Clingan P, Bridgewater J, Rivera F, de Gramont A. Improved overall survival with oxaliplatin, fluorouracil, and leucovorin as adjuvant treatment in stage II or III colon cancer in the MOSAIC trial. *J Clin Oncol* 2009; **27**: 3109-3116 [PMID: 19451431 DOI: 10.1200/jco.2008.20.6771]
- 17 **Petersen SH**, Harling H, Kirkeby LT, Wille-Jørgensen P, Mocellin S. Postoperative adjuvant chemotherapy in rectal cancer operated for cure. *Cochrane Database Syst Rev* 2012; **(3)**: CD004078 [PMID: 22419291 DOI: 10.1002/14651858.CD004078.pub2]
- 18 **Bosset JF**, Collette L, Calais G, Mineur L, Maingon P, Radosevic-Jelic L, Daban A, Bardet E, Beny A, Ollier JC. Chemotherapy with preoperative radiotherapy in rectal cancer. *N Engl J Med* 2006; **355**: 1114-1123 [PMID: 16971718 DOI: 10.1056/NEJMoa060829]
- 19 **Bosset JF**, Calais G, Mineur L, Maingon P, Stojanovic-Rundic S, Bensadoun RJ, Bardet E, Beny A, Ollier JC, Bolla M, Marchal D, Van Laethem JL, Klein V, Giral J, Clavère P, Glanzmann C, Cellier P, Collette L. Fluorouracil-based adjuvant chemotherapy after preoperative chemoradiotherapy in rectal cancer: long-term results of the EORTC 22921 randomised study. *Lancet Oncol* 2014; **15**: 184-190 [PMID: 24440473 DOI: 10.1016/s1470-2045(13)70599-0]
- 20 **Hong TS**, Ryan DP. Adjuvant Chemotherapy for Locally Advanced Rectal Cancer: Is It a Given? *J Clin Oncol* 2015; **33**: 1878-1880 [PMID: 25940719 DOI: 10.1200/jco.2015.60.8554]
- 21 **Glynn-Jones R**, Grainger J, Harrison M, Ostler P, Makris A. Neoadjuvant chemotherapy prior to preoperative chemoradiation or radiation in rectal cancer: should we be more cautious? *British J Cancer* 2006; **94**: 363-371 [DOI: 10.1038/sj.bjc.6602960]
- 22 **Garcia-Aguilar J**, Smith DD, Avila K, Bergsland EK, Chu P, Krieg RM. Optimal timing of surgery after chemoradiation for advanced rectal cancer: preliminary results of a multicenter, nonrandomized phase II prospective trial. *Ann Surg* 2011; **254**: 97-102 [PMID: 21494121 DOI: 10.1097/SLA.0b013e3182196e1f]
- 23 **Cercek A**, Goodman KA, Hajj C, Weisberger E, Segal NH, Reidy-Lagunes DL, Stadler ZK, Wu AJ, Weiser MR, Paty PB, Guillem JG, Nash GM, Temple LK, Garcia-Aguilar J, Saltz LB. Neoadjuvant chemotherapy first, followed by chemoradiation and then surgery, in the management of locally advanced rectal cancer. *J Natl Compr Canc Netw* 2014; **12**: 513-519 [PMID: 24717570]
- 24 **Calvo FA**, Serrano FJ, Diaz-González JA, Gomez-Espi M, Lozano E, Garcia R, de la Mata D, Arranz JA, García-Alfonso P, Pérez-Manga G, Alvarez E. Improved incidence of pT0 downstaged surgical specimens in locally advanced rectal cancer (LARC) treated with induction oxaliplatin plus 5-fluorouracil and preoperative chemoradiation. *Ann Oncol* 2006; **17**: 1103-1110 [PMID: 16670204 DOI: 10.1093/annonc/mdl085]
- 25 **Chau I**, Brown G, Cunningham D, Tait D, Wotherspoon A, Norman AR, Tebbutt N, Hill M, Ross PJ, Massey A, Oates J. Neoadjuvant capecitabine and oxaliplatin followed by synchronous chemoradiation and total mesorectal excision in magnetic resonance imaging-defined poor-risk rectal cancer. *J Clin Oncol* 2006; **24**: 668-674 [PMID: 16446339 DOI: 10.1200/jco.2005.04.4875]
- 26 **Schou JV**, Larsen FO, Rasch L, Linnemann D, Langhoff J, Høgdall E, Nielsen DL, Vistisen K, Fromm J, Jensen BV. Induction chemotherapy with capecitabine and oxaliplatin followed by chemoradiotherapy before total mesorectal excision in patients with locally advanced rectal cancer. *Ann Oncol* 2012; **23**: 2627-2633 [PMID: 22473488 DOI: 10.1093/annonc/mds056]
- 27 **Maréchal R**, Vos B, Polus M, Delaunoy T, Peeters M, Demetter P, Hendlisz A, Demols A, Franchimont D, Verset G, Van Houtte P, Van de Stadt J, Van Laethem JL. Short course chemotherapy followed by concomitant chemoradiotherapy and surgery in locally advanced rectal cancer: a randomized multicentric phase II study. *Ann Oncol* 2012; **23**: 1525-1530 [PMID: 22039087 DOI: 10.1093/annonc/mdr473]
- 28 **Fernandez-Martos C**, Brown G, Estevan R, Salud A, Montagut C, Maurel J, Safont MJ, Aparicio J, Feliu J, Vera R, Alonso V, Gallego J, Martin M, Pera M, Sierra E, Serra J, Delgado S, Roig JV, Santos J, Pericay C. Preoperative chemotherapy in patients with intermediate-risk rectal adenocarcinoma selected by high-resolution magnetic resonance imaging: the GEMCAD 0801 Phase II Multicenter Trial. *Oncologist* 2014; **19**: 1042-1043 [PMID: 25209376 DOI: 10.1634/theoncologist.2014-0233]
- 29 **Schrag D**, Weiser MR, Goodman KA, Gonen M, Hollywood E, Cercek A, Reidy-Lagunes DL, Gollub MJ, Shia J, Guillem JG, Temple LK, Paty PB, Saltz LB. Neoadjuvant chemotherapy without routine use of radiation therapy for patients with locally advanced rectal cancer: a pilot trial. *J Clin Oncol* 2014; **32**: 513-518 [PMID: 24419115 DOI: 10.1200/jco.2013.51.7904]
- 30 **Alliance for Clinical Trials in Oncology**. Chemotherapy Alone or Chemotherapy Plus Radiation Therapy in Treating Patients With Locally Advanced Rectal Cancer Undergoing Surgery. In: ClinicalTrials.gov [Internet]. Bethesda (MD): National Library of Medicine (US). Available from: URL: <https://clinicaltrials.gov/ct2/show/NCT01515787>
- 31 **Maas M**, Nelemans PJ, Valentini V, Das P, Rödel C, Kuo LJ, Calvo FA, Garcia-Aguilar J, Glynn-Jones R, Haustermans K, Mohiuddin M, Pucciarelli S, Small W, Suárez J, Theodoropoulos G, Biondo S, Beets-Tan RG, Beets GL. Long-term outcome in patients with a pathological complete response after chemoradiation for rectal cancer: a pooled analysis of individual patient data. *Lancet Oncol* 2010; **11**: 835-844 [PMID: 20692872 DOI: 10.1016/s1470-2045(10)70172-8]
- 32 **Maas M**, Beets-Tan RG, Lambregts DM, Lammering G, Nelemans PJ, Engelen SM, van Dam RM, Jansen RL, Sosef M, Leijten JW, Hulsewé KW, Buijsen J, Beets GL. Wait-and-see policy for clinical complete responders after chemoradiation for rectal cancer. *J Clin Oncol* 2011; **29**: 4633-4640 [PMID: 22067400 DOI: 10.1200/jco.2011.37.7176]
- 33 **Habr-Gama A**, Perez RO, Nadalin W, Sabbaga J, Ribeiro U, Silva e Sousa AH, Campos FG, Kiss DR, Gama-Rodrigues J. Operative versus nonoperative treatment for stage 0 distal rectal cancer following chemoradiation therapy: long-term results. *Ann Surg* 2004; **240**: 711-717 [PMID: 15383798]
- 34 **Habr-Gama A**, Perez RO, Proscurshim I, Campos FG, Nadalin W, Kiss D, Gama-Rodrigues J. Patterns of failure and survival for nonoperative treatment of stage c0 distal rectal cancer following neoadjuvant chemoradiation therapy. *J Gastrointest Surg* 2006; **10**: 1319-1328 [PMID: 17175450 DOI: 10.1016/j.gassur.2006.09.005]
- 35 **Habr-Gama A**, Perez RO. Non-operative management of rectal cancer after neoadjuvant chemoradiation. *Br J Surg* 2009; **96**: 125-127 [PMID: 19160360 DOI: 10.1002/bjs.6470]
- 36 **Memorial Sloan Kettering Cancer Center**. Trial Evaluating 3-year Disease Free Survival in Patients With Locally Advanced Rectal Cancer Treated With Chemoradiation Plus Induction or Consolidation Chemotherapy and Total Mesorectal Excision or Non-operative Management. In: ClinicalTrials.gov [Internet]. Bethesda (MD): National Library of Medicine (US). Available from: URL: <https://clinicaltrials.gov/ct2/show/NCT02008656>
- 37 **Smith JJ**, Chow OS, Gollub MJ, Nash GM, Temple LK, Weiser MR, Guillem JG, Paty PB, Avila K, Garcia-Aguilar J. Organ Preservation in Rectal Adenocarcinoma: a phase II randomized controlled trial evaluating 3-year disease-free survival in patients with locally advanced rectal cancer treated with chemoradiation plus induction or consolidation chemotherapy, and total mesorectal excision or nonoperative management. *BMC Cancer* 2015; **15**: 767 [PMID: 26497495 DOI: 10.1186/s12885-015-1632-z]
- 38 **Maas M**, Lambregts DM, Nelemans PJ, Heijnen LA, Martens MH, Leijten JW, Sosef M, Hulsewé KW, Hoff C, Breukink SO, Stassen L, Beets-Tan RG, Beets GL. Assessment of Clinical Complete Response After Chemoradiation for Rectal Cancer with Digital Rectal Examination, Endoscopy, and MRI: Selection for Organ-Saving Treatment. *Ann Surg Oncol* 2015; **22**: 3873-3880 [PMID: 26198074 DOI: 10.1245/s10434-015-4687-9]
- 39 **Flooden H**, Lindgren R, Hallböök O, Matthiessen P. Evaluation

- of long-term anorectal function after low anterior resection: a 5-year follow-up of a randomized multicenter trial. *Dis Colon Rectum* 2014; **57**: 1162-1168 [PMID: 25203371 DOI: 10.1097/dcr.0000000000000197]
- 40 **Yeo SG**, Kim DY, Kim TH, Kim SY, Chang HJ, Park JW, Choi HS, Oh JH. Local excision following pre-operative chemoradiotherapy-induced downstaging for selected cT3 distal rectal cancer. *Jpn J Clin Oncol* 2010; **40**: 754-760 [PMID: 20457724 DOI: 10.1093/jjco/hyq062]
 - 41 **Stipa F**, Picchio M, Burza A, Soricelli E, Vitelli CE. Long-term outcome of local excision after preoperative chemoradiation for ypT0 rectal cancer. *Dis Colon Rectum* 2014; **57**: 1245-1252 [PMID: 25285690 DOI: 10.1097/dcr.0000000000000221]
 - 42 **Kennelly RP**, Heeney A, White A, Fennelly D, Sheahan K, Hyland JM, O'Connell PR, Winter DC. A prospective analysis of patient outcome following treatment of T3 rectal cancer with neo-adjuvant chemoradiotherapy and transanal excision. *Int J Colorectal Dis* 2012; **27**: 759-764 [PMID: 22173716 DOI: 10.1007/s00384-011-1388-0]
 - 43 **Lezoche E**, Baldarelli M, Lezoche G, Paganini AM, Gesuita R, Guerrieri M. Randomized clinical trial of endoluminal locoregional resection versus laparoscopic total mesorectal excision for T2 rectal cancer after neoadjuvant therapy. *Br J Surg* 2012; **99**: 1211-1218 [PMID: 22864880 DOI: 10.1002/bjs.8821]
 - 45 **Garcia-Aguilar J**, Renfro LA, Chow OS, Shi Q, Carrero XW, Lynn PB, Thomas CR, Chan E, Cataldo PA, Marcet JE, Medich DS, Johnson CS, Oommen SC, Wolff BG, Pigazzi A, McNevin SM, Pons RK, Bleday R. Organ preservation for clinical T2N0 distal rectal cancer using neoadjuvant chemoradiotherapy and local excision (ACOSOG Z6041): results of an open-label, single-arm, multi-institutional, phase 2 trial. *Lancet Oncol* 2015; **16**: 1537-1546 [PMID: 26474521 DOI: 10.1016/s1470-2045(15)00215-6]
 - 45 **Watanabe T**, Komuro Y, Kiyomatsu T, Kanazawa T, Kazama Y, Tanaka J, Tanaka T, Yamamoto Y, Shirane M, Muto T, Nagawa H. Prediction of sensitivity of rectal cancer cells in response to preoperative radiotherapy by DNA microarray analysis of gene expression profiles. *Cancer Res* 2006; **66**: 3370-3374 [PMID: 16585155 DOI: 10.1158/0008-5472.can-05-3834]
 - 46 **Rimkus C**, Friederichs J, Boulesteix AL, Theisen J, Mages J, Becker K, Nekarda H, Rosenberg R, Janssen KP, Siewert JR. Microarray-based prediction of tumor response to neoadjuvant radiochemotherapy of patients with locally advanced rectal cancer. *Clin Gastroenterol Hepatol* 2008; **6**: 53-61 [PMID: 18166477 DOI: 10.1016/j.cgh.2007.10.022]
 - 47 **Ghadimi BM**, Grade M, Difilippantonio MJ, Varma S, Simon R, Montagna C, Füzesi L, Langer C, Becker H, Liersch T, Ried T. Effectiveness of gene expression profiling for response prediction of rectal adenocarcinomas to preoperative chemoradiotherapy. *J Clin Oncol* 2005; **23**: 1826-1838 [PMID: 15774776 DOI: 10.1200/jco.2005.00.406]
 - 48 **Nishioka M**, Shimada M, Kurita N, Iwata T, Morimoto S, Yoshikawa K, Higashijima J, Miyatani T. Gene expression profile can predict pathological response to preoperative chemoradiotherapy in rectal cancer. *Cancer Genomics Proteomics* 2011; **8**: 87-92 [PMID: 21471518]
 - 49 **Watanabe T**, Kobunai T, Akiyoshi T, Matsuda K, Ishihara S, Nozawa K. Prediction of response to preoperative chemoradiotherapy in rectal cancer by using reverse transcriptase polymerase chain reaction analysis of four genes. *Dis Colon Rectum* 2014; **57**: 23-31 [PMID: 24316942 DOI: 10.1097/01.dcr.0000437688.33795.9d]
 - 50 **Galon J**, Pagès F, Marincola FM, Angell HK, Thurin M, Lugli A, Zlobec I, Berger A, Bifulco C, Botti G, Tatangelo F, Britten CM, Kreiter S, Chouchane L, Delrio P, Arndt H, Asslaber M, Maio M, Masucci GV, Mihm M, Vidal-Vanaclocha F, Allison JP, Gnjjatic S, Hakansson L, Huber C, Singh-Jasuja H, Ottensmeier C, Zwierzina H, Laghi L, Grizzi F, Ohashi PS, Shaw PA, Clarke BA, Wouters BG, Kawakami Y, Hazama S, Okuno K, Wang E, O'Donnell-Tormey J, Lagorce C, Pawelec G, Nishimura MI, Hawkins R, Lapointe R, Lundqvist A, Khleif SN, Ogino S, Gibbs P, Waring P, Sato N, Torigoe T, Itoh K, Patel PS, Shukla SN, Palmqvist R, Nagtegaal ID, Wang Y, D'Arrigo C, Kopetz S, Sinicrope FA, Trinchieri G, Gajewski TF, Ascierto PA, Fox BA. Cancer classification using the Immunoscore: a worldwide task force. *J Transl Med* 2012; **10**: 205 [PMID: 23034130 DOI: 10.1186/1479-5876-10-205]
 - 51 **Galon J**, Costes A, Sanchez-Cabo F, Kirilovsky A, Mlecnik B, Lagorce-Pagès C, Tosolini M, Camus M, Berger A, Wind P, Zinzindohoué F, Bruneval P, Cugnenc PH, Trajanoski Z, Fridman WH, Pagès F. Type, density, and location of immune cells within human colorectal tumors predict clinical outcome. *Science* 2006; **313**: 1960-1964 [PMID: 17008531 DOI: 10.1126/science.1129139]
 - 52 **Pagès F**, Kirilovsky A, Mlecnik B, Asslaber M, Tosolini M, Bindea G, Lagorce C, Wind P, Marliot F, Bruneval P, Zatloukal K, Trajanoski Z, Berger A, Fridman WH, Galon J. In situ cytotoxic and memory T cells predict outcome in patients with early-stage colorectal cancer. *J Clin Oncol* 2009; **27**: 5944-5951 [PMID: 19858404 DOI: 10.1200/jco.2008.19.6147]
 - 53 **Mlecnik B**, Tosolini M, Kirilovsky A, Berger A, Bindea G, Meatchi T, Bruneval P, Trajanoski Z, Fridman WH, Pagès F, Galon J. Histopathologic-based prognostic factors of colorectal cancers are associated with the state of the local immune reaction. *J Clin Oncol* 2011; **29**: 610-618 [PMID: 21245428 DOI: 10.1200/jco.2010.30.5425]
 - 54 **Droeser RA**, Hirt C, Viehl CT, Frey DM, Nebiker C, Huber X, Zlobec I, Eppenberger-Castori S, Tzankov A, Rosso R, Zuber M, Muraro MG, Amicarella F, Cremonesi E, Heberer M, Iezzi G, Lugli A, Terracciano L, Sconocchia G, Oertli D, Spagnoli GC, Tornillo L. Clinical impact of programmed cell death ligand 1 expression in colorectal cancer. *Eur J Cancer* 2013; **49**: 2233-2242 [PMID: 23478000 DOI: 10.1016/j.ejca.2013.02.015]
 - 55 **Brahmer JR**, Tykodi SS, Chow LQ, Hwu WJ, Topalian SL, Hwu P, Drake CG, Camacho LH, Kauh J, Odunsi K, Pitot HC, Hamid O, Bhatia S, Martins R, Eaton K, Chen S, Salay TM, Alaparthi S, Grosso JF, Korman AJ, Parker SM, Agrawal S, Goldberg SM, Pardoll DM, Gupta A, Wigginton JM. Safety and activity of anti-PD-L1 antibody in patients with advanced cancer. *N Engl J Med* 2012; **366**: 2455-2465 [PMID: 22658128 DOI: 10.1056/NEJMoa1200694]
 - 56 **Llora NJ**, Cruise M, Tam A, Wicks EC, Hechenbleikner EM, Taube JM, Blosser RL, Fan H, Wang H, Lubner BS, Zhang M, Papadopoulos N, Kinzler KW, Vogelstein B, Sears CL, Anders RA, Pardoll DM, Housseau F. The vigorous immune microenvironment of microsatellite instable colon cancer is balanced by multiple counter-inhibitory checkpoints. *Cancer Discov* 2015; **5**: 43-51 [PMID: 25358689 DOI: 10.1158/2159-8290.cd-14-0863]
 - 57 **Shinto E**, Hase K, Hashiguchi Y, Sekizawa A, Ueno H, Shikina A, Kajiura Y, Kobayashi H, Ishiguro M, Yamamoto J. CD8+ and FOXP3+ tumor-infiltrating T cells before and after chemoradiotherapy for rectal cancer. *Ann Surg Oncol* 2014; **21** Suppl 3: S414-S421 [PMID: 24566864 DOI: 10.1245/s10434-014-3584-y]
 - 58 **Rahma O**. Trial of Chemoradiation and Pembrolizumab in Patients With Rectal Cancer. In: ClinicalTrials.gov [Internet]. Bethesda (MD): National Library of Medicine (US). Available from: URL: <https://clinicaltrials.gov/ct2/show/NCT02586610>

P-Reviewer: Campos FG, Gu GL, Maeda K, Wasserberg N

S-Editor: Qi Y **L-Editor:** A **E-Editor:** Lu YJ





Published by **Baishideng Publishing Group Inc**

8226 Regency Drive, Pleasanton, CA 94588, USA

Telephone: +1-925-223-8242

Fax: +1-925-223-8243

E-mail: bpgoffice@wjgnet.com

Help Desk: <http://www.wjgnet.com/esps/helpdesk.aspx>

<http://www.wjgnet.com>

