

Success of photodynamic therapy in palliating patients with nonresectable cholangiocarcinoma: A systematic review and meta-analysis

Harsha Moole, Harsha Tathireddy, Sirish Dharmapuri, Vishnu Moole, Raghuvveer Boddireddy, Pratyusha Yedama, Sowmya Dharmapuri, Achuta Uppu, Naveen Bondalapati, Abhiram Duvvuri

Harsha Moole, Harsha Tathireddy, Department of Medicine, University of Illinois College of Medicine, Peoria, IL 61637, United States

Sirish Dharmapuri, Department of Medicine, Wilkes-Barre Veterans Affairs Medical Center, Scranton, PA 18711, United States

Vishnu Moole, Raghuvveer Boddireddy, Pratyusha Yedama, Sowmya Dharmapuri, Department of Medicine, NTR University of Health Sciences, Andhra Pradesh 520008, India

Achuta Uppu, Department of Medicine, Albert Einstein College of Medicine, Bronx, New York, NY 10461, United States

Naveen Bondalapati, Department of Medicine, Barnes Jewish Christian Medical Group, Christian Hospital, St. Louis, MO 63136, United States

Abhiram Duvvuri, Division of Gastroenterology and Hepatology, Kansas City Veteran Affairs Medical Center, Kansas City, MO 64128, United States

Author contributions: Moole H contributed to conception and design of the study, acquisition of data, analysis and interpretation of data, drafting the article, critical revision, and final approval; Tathireddy H, Boddireddy R, Yedama P, Dharmapuri S, Uppu A and Bondalapati N contributed to acquisition of data, analysis and interpretation of data, drafting the article, final approval; Moole V and Dharmapuri S contributed to interpretation of data, revising the article, final approval; Duvvuri A contributed to conception and design of the study, critical revision, final approval.

Conflict-of-interest statement: The authors deny any conflict of interest.

Data sharing statement: No additional data are available.

Open-Access: This article is an open-access article which was selected by an in-house editor and fully peer-reviewed by external reviewers. It is distributed in accordance with the Creative

Commons Attribution Non Commercial (CC BY-NC 4.0) license, which permits others to distribute, remix, adapt, build upon this work non-commercially, and license their derivative works on different terms, provided the original work is properly cited and the use is non-commercial. See: <http://creativecommons.org/licenses/by-nc/4.0/>

Manuscript source: Unsolicited manuscript

Correspondence to: Harsha Moole, MD, Clinical Associate, Department of Medicine, University of Illinois College of Medicine, Peoria, IL 61637, United States. harsha1778@yahoo.co.in
Telephone: +1-309-6557257
Fax: +1-844-8936705

Received: June 21, 2016

Peer-review started: June 21, 2016

First decision: August 22, 2016

Revised: September 9, 2016

Accepted: October 10, 2016

Article in press: October 10, 2016

Published online: February 21, 2017

Abstract

AIM

To perform a systematic review and meta-analysis on clinical outcomes of photodynamic therapy (PDT) in non-resectable cholangiocarcinoma.

METHODS

Included studies compared outcomes with photodynamic therapy and biliary stenting (PDT group) vs biliary stenting only (BS group) in palliation of non-resectable cholangiocarcinoma. Articles were searched in MEDLINE, PubMed, and EMBASE. Pooled proportions were calculated using fixed and random effects model. Heterogeneity among studies was assessed using the I^2 statistic.

RESULTS

Ten studies ($n = 402$) that met inclusion criteria were included in this analysis. The P for χ^2 heterogeneity for all the pooled accuracy estimates was > 0.10 . Pooled odds ratio for successful biliary drainage (decrease in bilirubin level $> 50\%$ within 7 days after stenting) in PDT *vs* BS group was 4.39 (95%CI: 2.35-8.19). Survival period in PDT and BS groups were 413.04 d (95%CI: 349.54-476.54) and 183.41 (95%CI: 136.81-230.02) respectively. The change in Karnofsky performance scores after intervention in PDT and BS groups were +6.99 (95%CI: 4.15-9.82) and -3.93 (95%CI: -8.63-0.77) respectively. Odds ratio for post-intervention cholangitis in PDT *vs* BS group was 0.57 (95%CI: 0.35-0.94). In PDT group, 10.51% (95%CI: 6.94-14.72) had photosensitivity reactions that were self-limiting. Subgroup analysis of prospective studies showed similar results, except the incidence of cholangitis was comparable in both groups.

CONCLUSION

In palliation of unresectable cholangiocarcinoma, PDT seems to be significantly superior to BS alone. PDT should be used as an adjunct to biliary stenting in these patients.

Key words: Photodynamic therapy; Biliary stenting; Unresectable cholangiocarcinoma; Outcome; Systematic review; Meta-analysis

© The Author(s) 2017. Published by Baishideng Publishing Group Inc. All rights reserved.

Core tip: Role of photodynamic therapy (PDT) in unresectable cholangiocarcinoma has been scarcely described in the past. However most of these studies included patients who also underwent additional palliative measures simultaneously. Hence, overall safety and efficacy of photodynamic therapy is not clear. This is the first systematic review and meta-analysis evaluating exclusively the role of PDT in these patients. PDT with biliary stenting was compared to biliary stenting (BS) alone. PDT seems to be relatively safe and significantly superior to BS alone in this patient population.

Moole H, Tathireddy H, Dharmapuri S, Moole V, Boddireddy R, Yedama P, Dharmapuri S, Uppu A, Bondalapati N, Duvvuri A. Success of photodynamic therapy in palliating patients with unresectable cholangiocarcinoma: A systematic review and meta-analysis. *World J Gastroenterol* 2017; 23(7): 1278-1288 Available from: URL: <http://www.wjgnet.com/1007-9327/full/v23/i7/1278.htm> DOI: <http://dx.doi.org/10.3748/wjg.v23.i7.1278>

INTRODUCTION

Cholangiocarcinoma is the primary cancer of bile ducts. It is an aggressive disease with dismal prognosis. It is a

rare cancer comprising less than 2% of all cancers but the incidence has been increasing in the past decade^[1]. Approximately 60%-70% of these tumors are located within 2 cm from the bifurcation of the common bile duct (hilar cholangiocarcinoma, also called Klatskin tumor), extrahepatic cholangiocarcinoma occur in approximately 20%-30% and intrahepatic in the remaining 5%-10%.

Bismuth-Corellette system is used to classify hilar cholangiocarcinoma into four types (Type I-IV). Bismuth Type I is limited to the common hepatic duct below the confluence of the right and left hepatic duct, Type II involves tumor infiltration at the confluence without communication between left and right hepatic ducts, Type III involves tumor extension into one main hepatic duct and the secondary bile ducts, Type IV involves bilateral hepatic ducts and the secondary intrahepatic ducts. It is asymptomatic in the early stages and difficult to diagnose.

Complete tumor resection with negative margins (R0) is the only curative option but only 20%-30% of patients are candidates for curative resection^[2,3]. Five year survival rates after curative R0 resection is about 30%-50%^[2-7]. The remaining 70%-80% present at an advanced stage and are nonresectable due to locally advanced disease (Involvement of vessels or bilateral extension beyond secondary radicals) or presence of distant metastases^[3,8,9].

Palliation is the primary management option in these patients. Chemotherapy and radiotherapy have limited role and do not prolong life in advanced cholangiocarcinoma^[10]. Palliative biliary decompression by transpapillary or percutaneous insertion of biliary stent alleviates obstructive cholestasis and is currently the standard of care^[11-17]. However, stent patency rates are limited by tumor ingrowth or overgrowth^[18-22]. Most patients die from complications of obstructive cholestasis such as cholangitis, biliary sepsis or liver failure.

Photodynamic therapy (PDT) is a new local-ablative, tumor-specific treatment that has shown promising results and is now the standard of care for nonresectable cholangiocarcinoma^[23-26]. PDT involves administration of a photosensitizing drug with affinity for neoplastic tissue and subsequent selective irradiation with light of a defined wavelength. The resulting interaction between light and photosensitizing agent causes death of tumor cells, and neovascular cells by formation of oxygen free radicals^[27-29].

The first case of successful PDT for non resectable cholangiocarcinoma was described by McCaughan *et al*^[30] in 1991. Many studies have since then confirmed the significant advantage of using PDT in patients with nonresectable Cholangiocarcinoma. Most of these studies included patients that additionally received other palliative treatments (surgery, radiotherapy, chemotherapy)^[23,24]. The aim of this study is to evaluate the success of photodynamic therapy exclusively,

and its impact on survival, morbidity, biliary drainage and quality of life in patients with nonresectable cholangiocarcinoma through a systematic review and meta-analysis of the literature.

MATERIALS AND METHODS

Study selection criteria

Studies evaluating the role of PDT as a palliative option in patients with advanced non-resectable cholangiocarcinoma, were included in this meta-analysis. Prospective studies, retrospective studies and randomized controlled trials (RCTs) were included. Subgroup analysis was performed on prospective studies to negate the heterogeneity introduced by retrospective studies. Studies that used PDT as a neo-adjuvant therapy in patients with resectable cholangiocarcinoma were excluded. Studies that used chemotherapy or radiation therapy along with PDT in patients with resectable or unresectable cholangiocarcinoma were excluded. Studies without original data, perspective articles review articles, and expert opinions were excluded from this meta-analysis. Only full text articles, peer reviewed and published in international journals were included in this analysis. If there were duplicate studies, the most complete and latest study was included in this meta-analysis.

Data collection and extraction

The study design was written in accordance to PRISMA (Preferred Reporting Items for Systematic Reviews and Meta-Analyses) statement^[31]. Articles were systematically searched in Medline, PubMed, Ovid journals, EMABSE, Cumulative Index for Nursing and Allied Health Literature, ACP journal club, DARE, International Pharmaceutical Abstracts, old Medline, Medline nonindexed citations, OVID Healthstar, and Cochrane Central Register of Controlled Trials (CENTRAL). The search was performed for the years 1966 to May 2016. Abstracts were manually searched in the major gastroenterology journals for the past 3 years. Study authors for the abstracts included in this analysis were contacted when the required data for the outcome measures could not be determined from the publications. The MeSH search headings used were "photodynamic therapy", "PDT", "cholangiocarcinoma", "hilar malignancy", "percutaneous trans-hepatic biliary drainage", "malignant biliary obstruction", "biliary drainage", "endoscopic biliary drainage". The reference lists of the included studies were manually searched for any relevant publications. Two authors (HM and VM) independently searched and extracted the data into an abstraction form. Any differences were resolved by mutual agreement. If the disagreement persisted, the final decision was made by a third author (AD) after reviewing the relevant information. The agreement between reviewers for the collected data was quantified using the Cohen's κ ^[32]. Data was extracted from the

selected studies and entered into a standardized data collection form. The following variables were recorded: name and year of study; type of study; median age; male/female distribution; total number of patient included; number of patients that had PDT along with biliary stenting; number of patients that underwent biliary stenting only; PDT agent, PDT route, stent type - metal vs plastic, post treatment survival in PDT plus stenting group (in days), post treatment survival in biliary stenting group, over all adverse events (hepatic abscess/cholangitis/perihepatic abscess/drain site infection, photosensitivity) in both groups, cholangitis in both groups, photosensitivity in PDT group, Karnofsky performance scores (pre-treatment, post treatment and change in score after treatment) in both groups, median number of PDT sessions per patient in each study, bilirubin levels scores (pre-treatment, post treatment and change in score after treatment) in both groups.

Definitions

Successful biliary drainage was defined as a reduction in serum total bilirubin > 50 % at 2 wk and to a value below 3.0 mg/dL at 4 wk follow up. Technical success was defined as successfully placed stent in the appropriate location, confirmed radiographically and/or endoscopically. Stent patency is defined as time interval between biliary stent insertion and the need for an un-anticipated re-interventions.

Quality of studies

Clinical trials designed with a control and treatment arms can be assessed for quality of the study. A number of criteria have been used to assess this quality of a study (*e.g.*, randomization, selection bias of the arms in the study, concealment of allocation, and blinding of outcome). Jadad score was used to evaluate the quality of randomized studies. Cochrane Collaborations and the Quality of Reporting of Meta-analysis guidelines were followed to assess the quality of studies^[33,34]. Quality of retrospective studies were assessed using Newcastle-Ottawa Scale^[35].

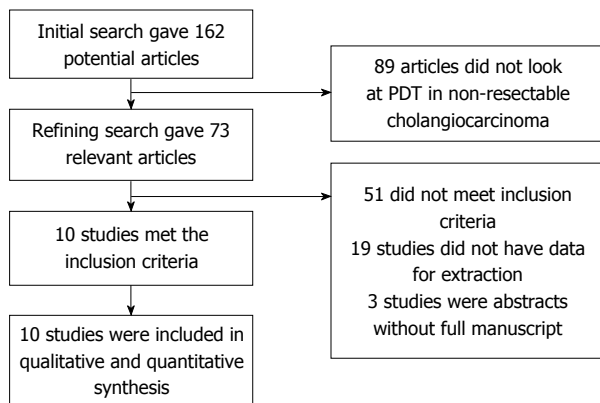
Statistical analysis

This meta-analysis was performed by calculating pooled proportions. First the individual study proportion of survival (in days), adverse events, Karnofsky scores *etc.*, were transformed into a quantity using Freeman-Tukey variant of the arcsine square root transformed proportion. The pooled proportion is calculated as the back-transform of the weighted mean of the transformed proportions, using inverse arcsine variance weights for the fixed effects model and DerSimonian-Laird weights for the random effects model^[36,37]. Random effects model was used if the heterogeneity was significant, and fixed effects model was used if heterogeneity was non-significant. Forest plots were drawn to show the point estimates in each study in

Table 1 Characteristics of included studies

Study	Type	n	PDT, n	BS, n	M/F	Age	Cancer type	PDT agent	PDT route	Stenting route	Stent type	PDT sessions per patient
Ortner <i>et al</i> ^[43] , 2003	RCT	39	20	19	NA	66	Non resectable CCA	Photofrin 2 mg/kg	Endoscopic	EBD or PTBD - Double stenting	Plastic	2
Dumoulin <i>et al</i> ^[44] , 2003	P	44	24	20	19/25	77	Non resectable CCA	Photofrin 2 mg/kg	Endoscopic	EBD or PTBD	Plastic followed by metal 4 wk later	NA
Cheon <i>et al</i> ^[45] , 2004	R	47	27	20	38/9	63	Non resectable CCA	Photogem	Endoscopic	PTBD in PDT, EBD in other	Plastic	2
Wiedmann <i>et al</i> ^[46] , 2004	P	23	23	NA	15/8	68	Non resectable CCA	Photofrin 2 mg/kg	Endoscopic	EBD or PTBD	Plastic or Metal	3
Shim <i>et al</i> ^[47] , 2005	P	24	24	NA	NA	58	Non resectable CCA	Photofrin 2 mg/kg	Percutaneous	PTBD	Plastic	2
Zoepf <i>et al</i> ^[48] , 2005	RCT	32	16	16	20/12	68	Non resectable CCA	Photosan-3	Endoscopic or percutaneous	EBD or PTBD	Plastic	2
Witzigmann <i>et al</i> ^[49] , 2006	P	124	68	56	59/65	69	Non resectable CCA	Photofrin 2 mg/kg	Endoscopic	EBD or PTBD	Plastic	2
Prasad <i>et al</i> ^[50] , 2007	R	25	25	NA	20/5	64	Non resectable CCA	Photofrin 2 mg/kg	Endoscopic or percutaneous	PTBD	Plastic	1
Lee <i>et al</i> ^[51] , 2012	R	33	18	15	24/9	66	Non resectable CCA	Photofrin 2 mg/kg	Endoscopic or percutaneous	EBD or PTBD	Metal	1
Wagner <i>et al</i> ^[52] , 2013	P	11	11	NA	8/3	76	Non resectable CCA	Temoporfin	Endoscopic	EBD or PTBD	Plastic	1

PDT: Photodynamic therapy; BS: Biliary stenting group; EBD: Endoscopic biliary drainage; PTBD: Percutaneous transhepatic biliary drainage; CCA: Cholangiocarcinoma; RCT: Randomized controlled trial; P: Prospective study; R: Retrospective study; NA: Not available.

**Figure 1** Study selection. PDT: Photodynamic therapy.

relation to the summary pooled estimate. The width of the point estimates in the Forest plots indicates the assigned weight to that study. The heterogeneity among studies was tested using I^2 statistic and Cochran's Q test based upon inverse variance weights^[38]. I^2 of 0%-39% was considered as non-significant heterogeneity, 40%-75% as moderate heterogeneity, and 76%-100% as considerable heterogeneity. If P value is > 0.10 , it rejects the null hypothesis that the studies are heterogeneous. The effect of publication and selection bias on the summary estimates was tested by both Harbord-Egger bias indicator^[39] and Begg bias indicator^[40]. Also, funnel plots were constructed to evaluate potential publication bias^[41,42]. Microsoft Excel 2013 software was used to perform statistics for this

meta-analysis. Subgroup analysis was performed on only prospective studies.

RESULTS

Study selection

Initial search identified 162 reference articles, in which 73 articles were selected and reviewed. Data was extracted from 10 studies^[43-52] ($n = 402$) which met the inclusion criterion. All the studies are published as full text articles. Figure 1 shows the flow diagram of search results. Among the 10 studies included in this analysis, only two were RCTs^[43,48]. Three studies^[45,50,51] out of the 10 studies were retrospective studies and the rest were prospective studies^[44,46,47,49,52]. Subgroup analysis was performed on all prospective trials.

The total number of patients included in this meta-analysis is 402, with a predominantly male population (65%). Median age of the patients was 68 years. Table 1 shows the baseline characteristics of the studies. The P for χ^2 heterogeneity for all the pooled accuracy estimates was > 0.10 . The agreement between reviewers for the collected data gave a Cohen's κ value of 1.0.

Studies evaluating survival of patients followed up with the patients till death. Studies describing the adverse events and quality of life had a median follow up period of three months. All except three studies used Photofrin 2 mg/kg as the PDT agent. Photogem^[45], Photosan-3^[48], and Temoporfin^[52] were the three other PDT agents used. PDT was administered via endoscopic

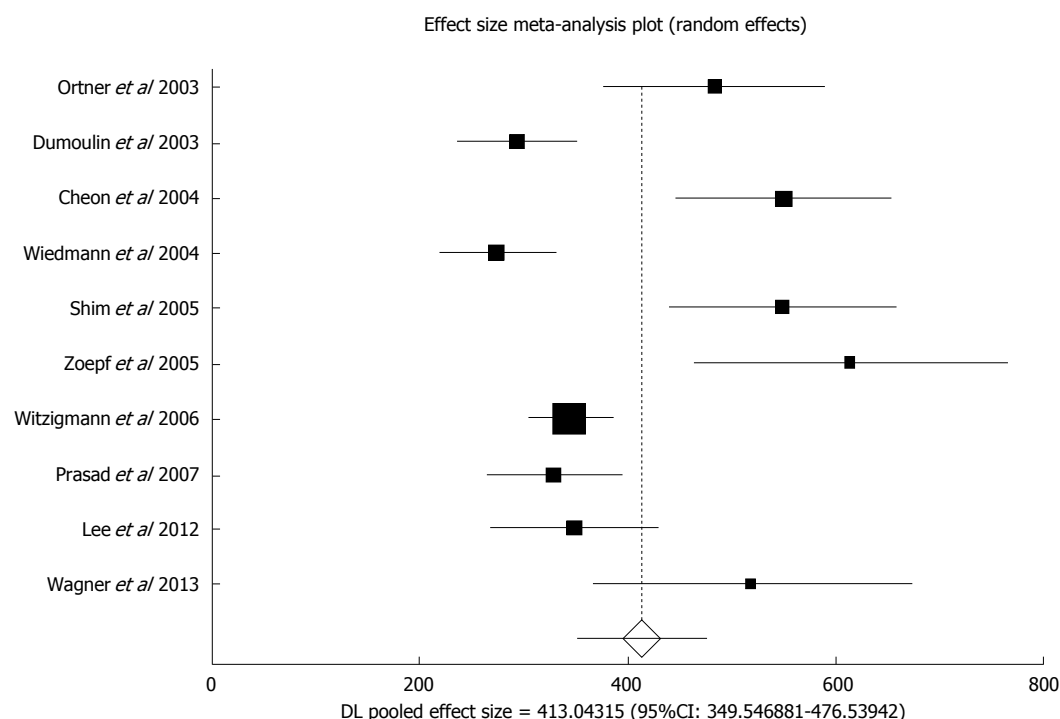


Figure 2 Forest plot - individual study proportions and the pooled estimate of survival period in photodynamic therapy group.

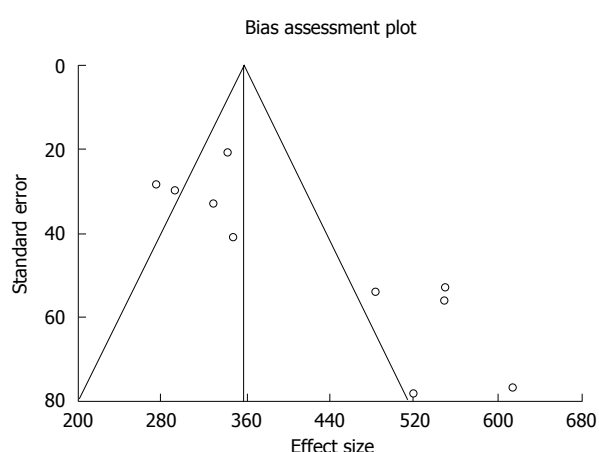


Figure 3 Funnel plot: Survival in photodynamic therapy group.

route in six studies^[43-46,49,52], percutaneous route in one study^[47], and endoscopic or percutaneous route in three studies^[48,50,51]. Biliary stenting was performed by endoscopic route (EBD) or percutaneous tranhepatic route (PTBD) in eight studies^[43-46,48,49,51,52]. Two studies exclusively used PTBD for biliary drainage^[47,50]. Seven studies used plastic biliary stents, one study used only metal stents^[43,45,47-50,52], one study used metal and plastic stents^[46], and one study used plastic stent followed by metal stent^[44]. Median number of PDT sessions per patient was two.

Survival benefit and Quality of life with photodynamic therapy

Data was available in all the ten included studies,

to calculate survival period. In the pooled patient population, the survival periods in PDT group (patient received PDT along with biliary stenting) and biliary stenting only group (BS group) were 413.04 d (95%CI: 349.54-476.54) and 183.41 days (95%CI: 136.81 to 230.02) respectively. I^2 (inconsistency) = 85.1% (95%CI: 73.5%-90.2%). Egger: bias = 5.09 (95%CI: 2.12-8.07), $P = 0.0043$. Figures 2 and 3 are forest plot and funnel plot representing the survival in PDT group. Six out of ten studies^[43,46-49,52] included data regarding Karnofsky performance scores. The change in Karnofsky performance scores after intervention in PDT and BS groups were +6.99 (95%CI: 4.15-9.82) and -3.93 (95%CI: -8.63-0.77) respectively. I^2 (inconsistency) = 97.6% (95%CI: 96.7%-98.1%). Egger: bias = 7.66 (95%CI: -0.22-15.53) $P = 0.054$. Figure 4 is a forest plot representing the change in Karnofsky scores in PDT group.

Biliary drainage outcomes with photodynamic therapy

Three studies^[43,49,51] had data that compared successful biliary drainage in PDT group vs BS group. Pooled odds ratio for successful biliary drainage in PDT group vs BS group was 4.39 (95%CI: 2.35-8.19). I^2 (inconsistency) = 28.8% (95%CI: 0%-79.9%). Horbold-Egger: bias = -1.19 (92.5%CI: -20.32-17.94) $P = 0.69$. Figure 5 is a forest plot of odds ratio for successful biliary drainage. Figure 6 is an L'Abbe plot for the same variable. Bilirubin levels were assessed in all ten studies that evaluated photodynamic therapy. In the pooled study population, pre-treatment bilirubin levels (mg/dL) in PDT and BS group were 6.36 (95%CI: 5.86-6.87) and 7.83

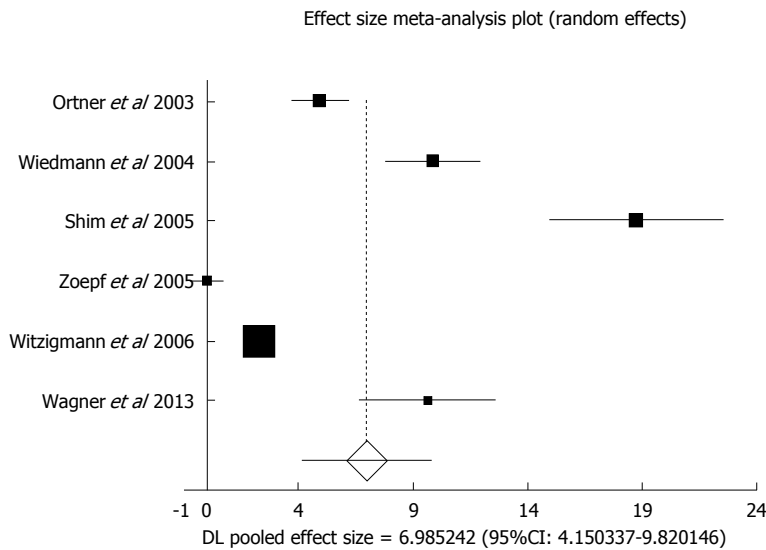


Figure 4 Forest plot - individual study proportions and the pooled estimate of change in Karnofsky performance scores in photodynamic therapy group.

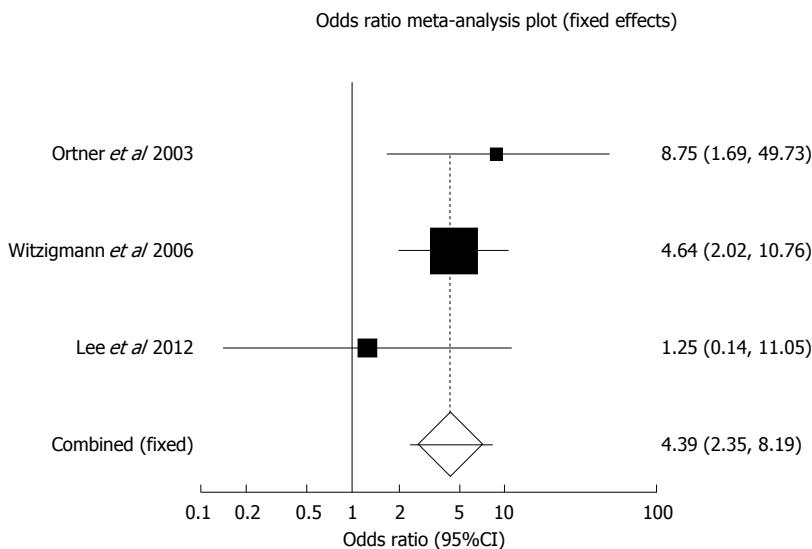


Figure 5 Forest plot - individual study proportions and the pooled estimate of odds ratio - successful biliary drainage in photodynamic therapy group vs biliary stenting group.

(95%CI: 7.08-8.58) respectively. After the intervention (at median follow up period of 3months), the bilirubin levels decreased by 4.23 (95%CI: 3.86-4.60) and 2.45 (95%CI: 2.08-2.81) in PDT and BS group respectively. I^2 (inconsistency) = 97.1% (95%CI: 96.4%-97.7%). Egger: bias = 11.38 (95%CI: 5.28-17.48), P = 0.0026.

Adverse events with PDT

Pooled odds ratio for post-intervention cholangitis episodes in PDT group vs BS group was 0.57 (95%CI: 0.35-0.94). I^2 (inconsistency) = 48.3% (95%CI: 0%-73.4%). Egger: bias = -0.70 (95%CI: -2.44-1.03), P = 0.38. Figure 7 is a forest plot of odds ratio for cholangitis in PDT group vs BS group. Figure 8 is the funnel plot for the same variable. Data regarding photosensitivity secondary to PDT was available in

nine studies. One out of ten studies^[45] did not have information on photosensitivity reactions. In the pooled proportion of patients in PDT group, 10.51% (95%CI: 6.94-14.72) had photosensitivity reactions that were self-limiting. I^2 (inconsistency) = 61.2% (95%CI: 0%-79.5%). Egger: bias = 2.81 (95%CI: 0.38-5.23) P = 0.02. Figure 9 is a forest plot for photosensitivity reactions in PDT group. Due to paucity of data from the individual studies, we were unable to derive at meaningful outcomes regarding overall adverse outcomes and other individual adverse events.

Subgroup analysis of prospective studies

Seven studies^[43,44,46-49,52] with 297 patients that met the inclusion criteria were included in this analysis. Median age of the patients was 68years, with 50%

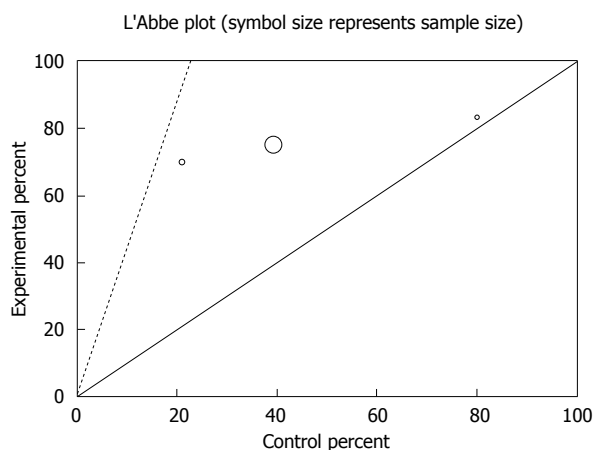


Figure 6 L'Abbe plot for odds ratio - successful biliary drainage in photodynamic therapy group vs biliary stenting group.

females. The P for χ^2 heterogeneity for all the pooled accuracy estimates was > 0.10 . Pooled odds ratio for successful biliary drainage in PDT group vs BS group was 5.33 (95%CI: 2.71-10.50). In the pooled study population, pre-treatment bilirubin levels (mg/dL) in PDT and BS group were 5.92 (95%CI: 5.35-6.50) and 7.18 (95%CI: 6.38-7.99) respectively. After the intervention (at median follow up period of 3months), the bilirubin levels decreased by 4.35 (95%CI: 3.90-4.81) and 2.08 (95%CI: 1.70-2.45) in PDT and BS group respectively. I^2 (inconsistency) = 97.6% (95%CI: 96.8%-98.1%). In the pooled patient population, the survival period in PDT group and BS group were 420.29 (95%CI: 338.69-501.89) and 153.43 (95%CI: 109.09-197.77) respectively. I^2 (inconsistency) = 87% (95%CI: 74.2%-91.9%). The change in Karnofsky performance scores after intervention in PDT and BS groups were +7.08 (95%CI: 4.23-9.93) and -2.39 (95%CI: -2.89 to -1.89) respectively. I^2 (inconsistency) = 97.6% (95%CI: 96.7%-98.1%). Pooled odds ratio for cholangitis to be 0.78 (95%CI: 0.45-1.35) in PDT vs BS group. I^2 (inconsistency) = 45.2% (95%CI: 0%-75.3%). Photosensitivity was present in 11.59% (95%CI: 7.47-16.47) of this PDT subgroup. I^2 (inconsistency) = 69% (95%CI: 5.9%-84.1%).

DISCUSSION

Cholangiocarcinoma is a rare cancer with poor prognosis. About 80% of cholangiocarcinoma present at an advanced stage and are nonresectable. Chemotherapy and radiotherapy, alone do not add any benefit to patient survival and quality of life. Effective palliation by biliary decompression to alleviate symptoms of cholestasis and prevent sepsis is the fundamental goal for most patients with nonresectable cholangiocarcinoma. PDT is a promising and evolving therapy in the management of patients with nonresectable cholangiocarcinoma. Nonresectable

cholangiocarcinoma has a median survival time of 3 mo without intervention^[53] and 4-10 mo with biliary drainage^[3,6,7,19,21,22,53,54]. The current systematic review and meta-analysis shows that PDT combined with biliary stenting improves the success of biliary drainage and improves the survival and quality of life in patients with nonresectable cholangiocarcinoma. For treatment of non resectable cholangiocarcinoma, photosensitizers with the ability to penetrate deep tissue are better compared to those with superficial effect. Chlorine derivatives and hematoporphyrin derivatives usually have a deep tissue penetration.

In the first RCT by Ortner *et al.*^[43], median survival time after PDT was 493 d compared to 98 d in patients receiving biliary stent alone. Another RCT by Zoepf *et al.*^[48] showed similar survival benefit in the PDT group 630 days compared to 210 d in the stent only group. Quality of life (Karnofsky index) significantly improved in the study by Ortner *et al.*^[43] but not in the study by Zoepf *et al.*^[48] due to the higher performance status of enrolled patients at study entry.

Lee *et al.*^[51] stated that the duration of metal stent patency was significantly longer after one session of PDT than in the stent-only group. Longer patency of metal stent by PDT translated to better quality of life by decreasing the number of procedures like stent revision or percutaneous drainage. Witzigmann *et al.*^[49] compared outcomes after palliative PDT and resection therapy. Their study showed that palliative PDT was inferior to complete curative (R0) resection. However, patients with palliative PDT showed similar survival time to that of patients with incomplete resection (R1/R2). Prasad *et al.*^[50] looked at factors associated with increased survival after PDT and found that presence of visible mass on imaging, low serum albumin and prolonged time period between diagnosis and treatment with PDT to be the predicting factors for early mortality. In non-resectable cholangiocarcinoma patients, the option of liver transplant (with eventual neo-adjuvant therapy) should be considered on a individualized basis, since this option has been studied even in patients with initially non resectable cholangiocarcinoma.

PDT was relatively well tolerated with minimal side effects in most studies. Cholangitis was the most common side effect followed by phototoxicity. All patients who had PDT also had biliary stenting. Hence cholangitis, could be a potential complication of biliary stenting as well. It is difficult to ascertain if cholangitis is a complication of PDT alone.

Strengths of this meta-analysis include the high quality methodology of statistical analysis, high quality methodology used in individual studies. This is an updated meta-analysis to pool the evidence for the utility of PDT plus biliary stenting in palliation of non resectable cholangiocarcinoma. Lu *et al.*^[55] was the previous meta-analysis on the topic, however several new studies were published after the first meta-

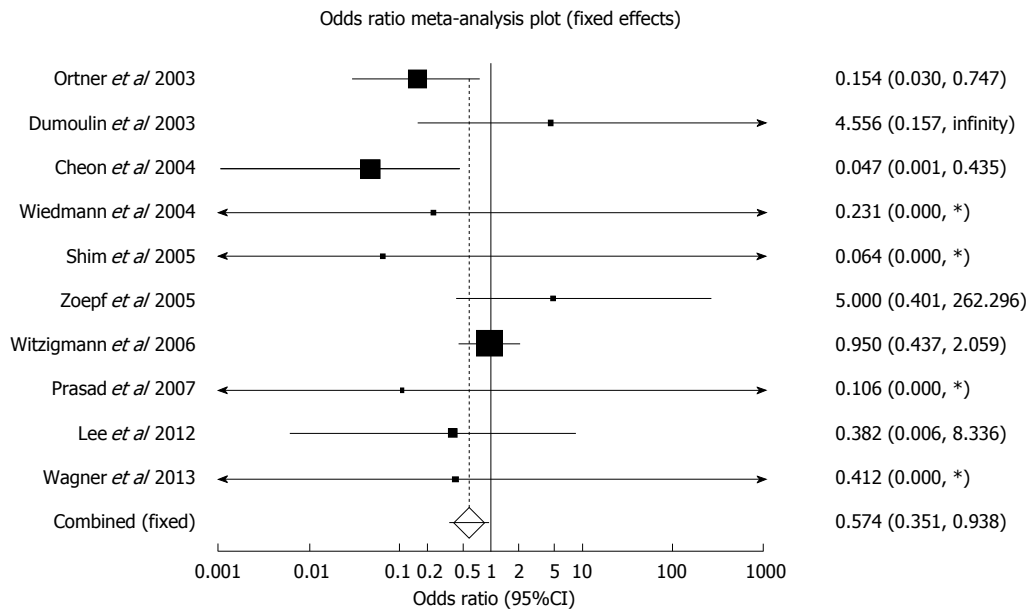


Figure 7 Forest plot - individual study proportions and the pooled estimate of odds ratio - cholangitis in photodynamic therapy group vs biliary stenting group.

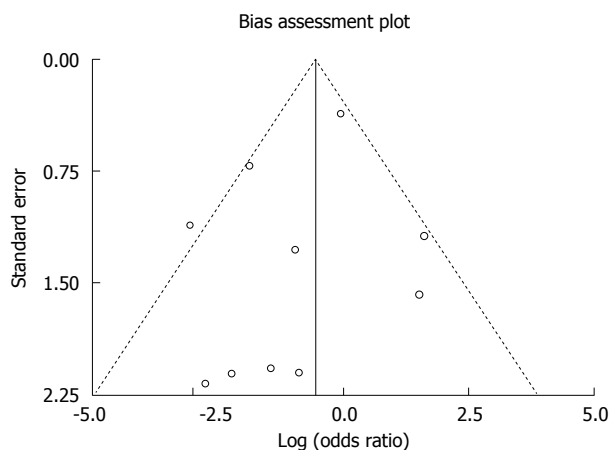


Figure 8 Funnel plot - odds ratio for cholangitis in photodynamic therapy group vs biliary stenting group.

analysis, that necessitated this updated analysis. Combining chemotherapy with PDT has shown survival benefit compared to PDT alone, in patients with hilar non resectable cholangiocarcinoma^[56].

Limitations of this study are: most of the data is synthesized from studies with relatively small sample sizes. Studies differed in the method of PDT (Percutaneous or endoscopic), and the number of sessions of PDT which might have influenced the outcomes. Different types of stents (plastic vs metal) were used and route of stenting varied (endoscopic vs percutaneous transhepatic approach) among the studies, which could have all affected the outcomes. Retrospective studies were included in this meta-analysis. In order to mitigate this issue, we have

performed a sub-group analysis on prospective studies only.

Studies with statistically significant positive results tend to be published and cited. Additionally, smaller studies may show larger treatment effects compared to larger studies. This publication and selection bias may affect the summary estimates. The bias can be estimated using Egger bias indicators and the construction of funnel plots, whose shape can be affected by bias. In the present meta-analysis and systematic review, bias calculations both Egger^[39] and Begg *et al*^[40] bias indicators showed no statistically significant bias. Furthermore, funnel plots were used to evaluate for publication bias among the studies included in the present analysis.

Granted there is availability of operator expertise and infrastructure availability, we believe that PDT along with biliary stenting is an excellent palliative option for non-resectable cholangiocarcinoma. Based on systematic review of literature, it is evident that in patients with resectable cholangiocarcinoma, surgery would still be the best option. The utility of PDT in this patient population (resectable cholangiocarcinoma) has not shown any additional benefit compared to surgery.

Overall, PDT combined with biliary stenting improves the success of biliary drainage and has a significant benefit in improving the survival period and quality of life. PDT is beneficial, minimally invasive, and well tolerated with a favorable side effect profile. We conclude that PDT with biliary stenting could be offered to all patients with nonresectable cholangiocarcinoma as a palliative option.

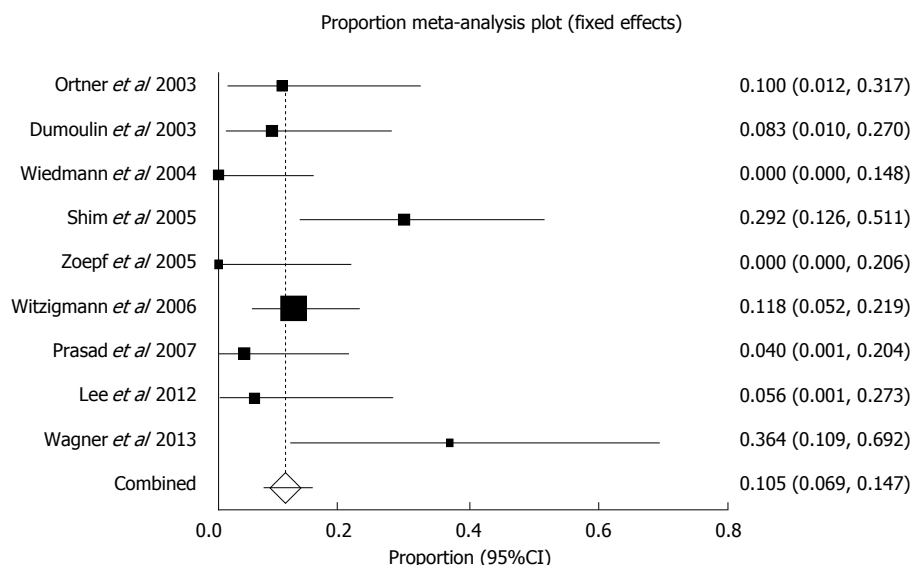


Figure 9 Forest plot - individual study proportions and the pooled estimate of photosensitivity reactions in photodynamic therapy group.

COMMENTS

Background

Photodynamic therapy (PDT) is a new local-ablative, tumor-specific treatment that has shown promising results and is now the standard of care for nonresectable cholangiocarcinoma.

Research frontiers

Many studies have confirmed the significant advantage of using PDT in patients with nonresectable Cholangiocarcinoma. Most of these studies included patients that additionally received other palliative treatments (surgery, radiotherapy, chemotherapy).

Innovations and breakthroughs

PDT combined with biliary stenting improves the success of biliary drainage and has a significant benefit in improving the survival period and quality of life.

Applications

PDT is beneficial, minimally invasive, and well tolerated with a favorable side effect profile. We conclude that PDT with biliary stenting could be offered to all patients with nonresectable cholangiocarcinoma as a palliative option.

Peer-review

The manuscript presents a very excellent research in medical treatment of non-resectable cholangiocarcinoma with PDT using meta-analysis approach. The authors have chosen a good set of objective criteria, aggregated enough information and performed well data analysis with high statistic. The language is well written. The study results should be benefits to medicinal field.

REFERENCES

- 1 Shaib Y, El-Serag HB. The epidemiology of cholangiocarcinoma. *Semin Liver Dis* 2004; **24**: 115-125 [PMID: 15192785 DOI: 10.1055/s-2004-828889]
- 2 Rea DJ, Munoz-Juarez M, Farnell MB, Donohue JH, Que FG, Crownhart B, Larson D, Nagorney DM. Major hepatic resection for hilar cholangiocarcinoma: analysis of 46 patients. *Arch Surg* 2004; **139**: 514-523; discussion 523-525 [PMID: 15136352 DOI: 10.1001/archsurg.139.5.514]
- 3 Jarnagin WR, Fong Y, DeMatteo RP, Gonen M, Burke EC, Bodniewicz BS J, Youssef BA M, Klimstra D, Blumgart LH. Staging, resectability, and outcome in 225 patients with hilar

cholangiocarcinoma. *Ann Surg* 2001; **234**: 507-517; discussion 517-519 [PMID: 11573044]

- 4 Dinant S, Gerhards MF, Rauws EA, Busch OR, Gouma DJ, van Gulik TM. Improved outcome of resection of hilar cholangiocarcinoma (Klatskin tumor). *Ann Surg Oncol* 2006; **13**: 872-880 [PMID: 16614876 DOI: 10.1245/ASO.2006.05.053]
- 5 Hasegawa S, Ikai I, Fujii H, Hatano E, Shimahara Y. Surgical resection of hilar cholangiocarcinoma: analysis of survival and postoperative complications. *World J Surg* 2007; **31**: 1256-1263 [PMID: 17453285 DOI: 10.1007/s00268-007-9001-y]
- 6 Hemming AW, Reed AI, Fujita S, Foley DP, Howard RJ. Surgical management of hilar cholangiocarcinoma. *Ann Surg* 2005; **241**: 693-699; discussion 699-702 [PMID: 15849505]
- 7 Kawasaki S, Imamura H, Kobayashi A, Noike T, Miwa S, Miyagawa S. Results of surgical resection for patients with hilar bile duct cancer: application of extended hepatectomy after biliary drainage and hemihepatic portal vein embolization. *Ann Surg* 2003; **238**: 84-92 [PMID: 12832969 DOI: 10.1097/01.SLA.0000074984.83031.02]
- 8 Nakeeb A, Pitt HA, Sohn TA, Coleman J, Abrams RA, Piantadosi S, Hruban RH, Lillemoe KD, Yeo CJ, Cameron JL. Cholangiocarcinoma. A spectrum of intrahepatic, perihilar, and distal tumors. *Ann Surg* 1996; **224**: 463-473; discussion 473-475 [PMID: 8857851]
- 9 Nathan H, Aloia TA, Vauthey JN, Abdalla EK, Zhu AX, Schulick RD, Choti MA, Pawlik TM. A proposed staging system for intrahepatic cholangiocarcinoma. *Ann Surg Oncol* 2009; **16**: 14-22 [PMID: 18987916 DOI: 10.1245/s10434-008-0180-z]
- 10 Gao F, Bai Y, Ma SR, Liu F, Li ZS. Systematic review: photodynamic therapy for unresectable cholangiocarcinoma. *J Hepatobiliary Pancreat Sci* 2010; **17**: 125-131 [PMID: 19455276 DOI: 10.1007/s00534-009-0109-3]
- 11 Moole H, Dhillon S, Volmar F, Cashman M, Bechtold M, Puli S. Mo1378 Is There a Survival and Morbidity Benefit of Covered Over Uncovered Metal Stents in Malignant Biliary Strictures? A Meta-Analysis and Systematic Review. *Gastrointest Endosc* 2015; **5**: AB399 [DOI: 10.1016/j.gie.2015.03.706]
- 12 Moole H, Bechtold M, Puli S. Mo1037 Comparison of Double Layer Stents and Self-Expandable Metal Stents for Malignant Biliary Strictures: A Meta-Analysis and Systematic Review. *Gastrointest Endosc* 2015; **5**: AB347 [DOI: 10.1016/j.gie.2016.03.548]
- 13 Moole H, Cashman M, Volmar F, Dhillon S, Bechtold M, Puli S. Su1601 Are Covered Metal Stents Better than Uncovered Metal Stents for Malignant Biliary Stricture? A Meta-Analysis and Systematic Review. *Gastrointest Endosc* 2015; **5**: AB346 [DOI:

- 10.1016/j.gie.2015.03.563]
- 14 **Moole H**, Puli S. Sa1408 Are Metal Stents Better Than Plastic Stents for Malignant Distal Common Bile Duct Stricture? A Meta-Analysis and Systematic Review. *Gastrointest Endosc* 2015; **5**: AB202 [DOI: 10.1016/j.gie.2015.03.179]
 - 15 **Moole H**, Cashman M, Volmar F, Dhillon S, Bechtold M, Puli S. Sa1869 Is There a Morbidity and Survival Benefit for Metal Over Plastic Stents in Managing Malignant Distal Biliary Strictures? A Meta-Analysis and Systematic Review. *Gastroenterology* 2015; **148**: S1030
 - 16 **Moole H**, Puli S. Tu1928 Complications of Metal Vs Plastic Stents in Malignant Distal Biliary Strictures: A Meta-Analysis and Systematic Review. *Gastroenterology* 2015; **148**: S1030 [DOI: 10.1016/S0016-5085(15)33521-6]
 - 17 **Moole H**, Puli S. Su1072 Comparison of Complications for Covered Vs Uncovered Metal Stents in Malignant Biliary Strictures: A Meta-Analysis and Systematic Review. *Gastroenterology* 2015; **148**: S400 [DOI: 10.1016/S0016-5085(15)31344-5]
 - 18 **O'Brien S**, Hatfield AR, Craig PI, Williams SP. A three year follow up of self expanding metal stents in the endoscopic palliation of longterm survivors with malignant biliary obstruction. *Gut* 1995; **36**: 618-621 [PMID: 7537708]
 - 19 **Liu CL**, Lo CM, Lai EC, Fan ST. Endoscopic retrograde cholangiopancreatography and endoscopic endoprosthesis insertion in patients with Klatskin tumors. *Arch Surg* 1998; **133**: 293-296 [PMID: 9517743 DOI: 10.1001/archsurg.133.3.293]
 - 20 **Lai EC**, Lo CM, Liu CL. Endoscopic stenting for malignant biliary obstruction. *World J Surg* 2001; **25**: 1289-1295 [PMID: 11596892 DOI: 10.1007/s00268-001-0112-6]
 - 21 **Ducreux M**, Liguory C, Lefebvre JF, Ink O, Choury A, Fritsch J, Bonnel D, Derhy S, Etienne JP. Management of malignant hilar biliary obstruction by endoscopy. Results and prognostic factors. *Dig Dis Sci* 1992; **37**: 778-783 [PMID: 1373361 DOI: 10.1007/BF01296439]
 - 22 **Polydorou AA**, Cairns SR, Dowsett JF, Hatfield AR, Salmon PR, Cotton PB, Russell RC. Palliation of proximal malignant biliary obstruction by endoscopic endoprosthesis insertion. *Gut* 1991; **32**: 685-689 [PMID: 1711994 DOI: 10.1136/gut.32.6.685]
 - 23 **Ortner MA**. Photodynamic therapy of cholangiocarcinoma cancer. *Gastrointest Endosc Clin N Am* 2000; **10**: 481-486 [PMID: 10899258]
 - 24 **Zoeppf T**, Jakobs R, Arnold JC, Apel D, Rosenbaum A, Riemann JF. Photodynamic therapy for palliation of nonresectable bile duct cancer--preliminary results with a new diode laser system. *Am J Gastroenterol* 2001; **96**: 2093-2097 [PMID: 11467637 DOI: 10.1111/j.1572-0241.2001.03968.x]
 - 25 **Rumalla A**, Baron TH, Wang KK, Gores GJ, Stadheim LM, de Groen PC. Endoscopic application of photodynamic therapy for cholangiocarcinoma. *Gastrointest Endosc* 2001; **53**: 500-504 [PMID: 11275896 DOI: 10.1067/mge.2001.113386]
 - 26 **Berr F**, Tannapfel A, Lamesch P, Pahernik S, Wiedmann M, Halm U, Goetz AE, Mössner J, Hauss J. Neoadjuvant photodynamic therapy before curative resection of proximal bile duct carcinoma. *J Hepatol* 2000; **32**: 352-357 [PMID: 10707878 DOI: 10.1016/S0168-8278(00)80083-5]
 - 27 **Nelson JS**, Liaw LH, Orenstein A, Roberts WG, Berns MW. Mechanism of tumor destruction following photodynamic therapy with hematoporphyrin derivative, chlorin, and phthalocyanine. *J Natl Cancer Inst* 1988; **80**: 1599-1605 [PMID: 2973528]
 - 28 **Henderson BW**, Dougherty TJ. How does photodynamic therapy work? *Photochem Photobiol* 1992; **55**: 145-157 [PMID: 1603846 DOI: 10.1111/j.1751-1097.1992.tb04222.x]
 - 29 **Wong Kee Song LM**, Wang KK, Zinsmeister AR. Mono-L-aspartyl chlorin e6 (NPe6) and hematoporphyrin derivative (HpD) in photodynamic therapy administered to a human cholangiocarcinoma model. *Cancer* 1998; **82**: 421-427 [PMID: 9445202 DOI: 10.1002/1097-0142(19980115)82::2<421::AID-CNCR25>3.0.CO;2-O]
 - 30 **McCaughan JS**, Mertens BF, Cho C, Barabash RD, Payton HW. Photodynamic therapy to treat tumors of the extrahepatic biliary ducts. A case report. *Arch Surg* 1991; **126**: 111-113 [PMID: 1824676]
 - 31 **Liberati A**, Altman DG, Tetzlaff J, Mulrow C, Gotzsche PC, Ioannidis JP, Clarke M, Devereaux PJ, Kleijnen J, Moher D. The PRISMA statement for reporting systematic reviews and meta-analyses of studies that evaluate health care interventions: explanation and elaboration. *PLoS Med* 2009; **6**: e1000100 [PMID: 19621070 DOI: 10.1371/journal.pmed.1000100]
 - 32 **Brennan P**, Silman A. Statistical methods for assessing observer variability in clinical measures. *BMJ* 1992; **304**: 1491-1494 [PMID: 1611375]
 - 33 **Jadad AR**, Moore RA, Carroll D, Jenkinson C, Reynolds DJ, Gavaghan DJ, McQuay HJ. Assessing the quality of reports of randomized clinical trials: is blinding necessary? *Control Clin Trials* 1996; **17**: 1-12 [PMID: 8721797 DOI: 10.1016/0197-2456(95)00134-4]
 - 34 **Stroup DF**, Berlin JA, Morton SC, Olkin I, Williamson GD, Rennie D, Moher D, Becker BJ, Sipe TA, Thacker SB. Meta-analysis of observational studies in epidemiology: a proposal for reporting. Meta-analysis Of Observational Studies in Epidemiology (MOOSE) group. *JAMA* 2000; **283**: 2008-2012 [PMID: 10789670 DOI: 10.1001/jama.283.15.2008]
 - 35 **Wells GA**, Shea B, O'Connell D, Peterson J, Welch V, Losos M, Tugwell P. The Newcastle-Ottawa Scale (NOS) for assessing the quality of nonrandomised studies in meta-analyses. 2014. (accessed June 20, 2016). Available from: URL: http://www.ohri.ca/programs/clinical_epidemiology/oxford.asp
 - 36 **Stuart A**, Ord JK. Kendall's Advanced Theory of Statistics. 6th ed. London: Edward Arnold, 1994
 - 37 **DerSimonian R**, Laird N. Meta-analysis in clinical trials. *Control Clin Trials* 1986; **7**: 177-188 [PMID: 3802833 DOI: 10.1016/0197-2456(86)90046-2]
 - 38 **Deeks JJ**. Systematic reviews of evaluations of diagnostic and screening tests. In: Egger M, Smith GD, Altman DG, editors. Systematic Reviews in Health Care. Meta-analysis in context. London: BMJ Books, 2001
 - 39 **Harbord RM**, Egger M, Sterne JA. A modified test for small-study effects in meta-analyses of controlled trials with binary endpoints. *Stat Med* 2006; **25**: 3443-3457 [PMID: 16345038 DOI: 10.1002/sim.2380]
 - 40 **Begg CB**, Mazumdar M. Operating characteristics of a rank correlation test for publication bias. *Biometrics* 1994; **50**: 1088-1101 [PMID: 7786990 DOI: 10.2307/2533446]
 - 41 **Sterne JA**, Egger M, Smith GD. Systematic reviews in health care: Investigating and dealing with publication and other biases in meta-analysis. *BMJ* 2001; **323**: 101-105 [PMID: 11451790]
 - 42 **Sterne JA**, Egger M. Funnel plots for detecting bias in meta-analysis: guidelines on choice of axis. *J Clin Epidemiol* 2001; **54**: 1046-1055 [PMID: 11576817]
 - 43 **Ortner ME**, Caca K, Berr F, Liebetruh J, Mansmann U, Huster D, Voderholzer W, Schachschal G, Mössner J, Lochs H. Successful photodynamic therapy for nonresectable cholangiocarcinoma: a randomized prospective study. *Gastroenterology* 2003; **125**: 1355-1363 [PMID: 14598251 DOI: 10.1016/j.gastro.2003.07.015]
 - 44 **Dumoulin FL**, Gerhardt T, Fuchs S, Scheurle C, Neubrand M, Layer G, Sauerbruch T. Phase II study of photodynamic therapy and metal stent as palliative treatment for nonresectable hilar cholangiocarcinoma. *Gastrointest Endosc* 2003; **57**: 860-867 [PMID: 12776033 DOI: 10.1067/mge.2003.250]
 - 45 **Cheon YK**, Cho YD, Baek SH, Cha SW, Moon JH, Kim YS, Lee JS, Lee MS, Shim CS, Kim BS. [Comparison of survival of advanced hilar cholangiocarcinoma after biliary drainage alone versus photodynamic therapy with external drainage]. *Korean J Gastroenterol* 2004; **44**: 280-287 [PMID: 15564808]
 - 46 **Wiedmann M**, Berr F, Schiefke I, Witzigmann H, Kohlhaw K, Mössner J, Caca K. Photodynamic therapy in patients with non-resectable hilar cholangiocarcinoma: 5-year follow-up of a prospective phase II study. *Gastrointest Endosc* 2004; **60**: 68-75 [PMID: 15229428 DOI: 10.1016/S0016-5107(04)01288-X]
 - 47 **Shim CS**, Cheon YK, Cha SW, Bhandari S, Moon JH, Cho

- YD, Kim YS, Lee LS, Lee MS, Kim BS. Prospective study of the effectiveness of percutaneous transhepatic photodynamic therapy for advanced bile duct cancer and the role of intraductal ultrasonography in response assessment. *Endoscopy* 2005; **37**: 425-433 [PMID: 15844020 DOI: 10.1055/s-2005-861294]
- 48 **Zoeplf T**, Jakobs R, Arnold JC, Apel D, Riemann JF. Palliation of nonresectable bile duct cancer: improved survival after photodynamic therapy. *Am J Gastroenterol* 2005; **100**: 2426-2430 [PMID: 16279895 DOI: 10.1111/j.1572-0241.2005.00318.x]
- 49 **Witzigmann H**, Berr F, Ringel U, Caca K, Uhlmann D, Schoppmeyer K, Tannapfel A, Wittekind C, Mossner J, Hauss J, Wiedmann M. Surgical and palliative management and outcome in 184 patients with hilar cholangiocarcinoma: palliative photodynamic therapy plus stenting is comparable to r1/r2 resection. *Ann Surg* 2006; **244**: 230-239 [PMID: 16858185 DOI: 10.1097/01.sla.0000217639.10331.47]
- 50 **Prasad GA**, Wang KK, Baron TH, Buttar NS, Wongkeesong LM, Roberts LR, LeRoy AJ, Lutzke LS, Borkenhagen LS. Factors associated with increased survival after photodynamic therapy for cholangiocarcinoma. *Clin Gastroenterol Hepatol* 2007; **5**: 743-748 [PMID: 17545000 DOI: 10.1016/j.cgh.2007.02.021]
- 51 **Lee TY**, Cheon YK, Shim CS, Cho YD. Photodynamic therapy prolongs metal stent patency in patients with unresectable hilar cholangiocarcinoma. *World J Gastroenterol* 2012; **18**: 5589-5594 [PMID: 23112552 DOI: 10.3748/wjg.v18.i39.5589]
- 52 **Wagner A**, Kiesslich T, Neureiter D, Friesenbichler P, Puespoek A, Denzer UW, Wolkersdörfer GW, Emmanuel K, Lohse AW, Berr F. Photodynamic therapy for hilar bile duct cancer: clinical evidence for improved tumoricidal tissue penetration by temoporfin. *Photochem Photobiol Sci* 2013; **12**: 1065-1073 [PMID: 23558738 DOI: 10.1039/c3pp25425a]
- 53 **Farley DR**, Weaver AL, Nagorney DM. "Natural history" of unresected cholangiocarcinoma: patient outcome after noncurative intervention. *Mayo Clin Proc* 1995; **70**: 425-429 [PMID: 7537346 DOI: 10.1016/S0025-6196(11)63877-9]
- 54 **Devieere J**, Baize M, de Toeuf J, Cremer M. Long-term follow-up of patients with hilar malignant stricture treated by endoscopic internal biliary drainage. *Gastrointest Endosc* 1988; **34**: 95-101 [PMID: 2835282]
- 55 **Lu Y**, Liu L, Wu JC, Bie LK, Gong B. Efficacy and safety of photodynamic therapy for unresectable cholangiocarcinoma: A meta-analysis. *Clin Res Hepatol Gastroenterol* 2015; **39**: 718-724 [PMID: 26070572 DOI: 10.1016/j.clinre.2014.10.015]
- 56 **Wentrup R**, Winkelmann N, Mitroshkin A, Prager M, Voderholzer W, Schachschal G, Jürgensen C, Büning C. Photodynamic Therapy Plus Chemotherapy Compared with Photodynamic Therapy Alone in Hilar Nonresectable Cholangiocarcinoma. *Gut Liver* 2016; **10**: 470-475 [PMID: 26814610 DOI: 10.5009/gnl15175]

P- Reviewer: Garancini M, Leardkamolkarn V, Onori P, Zhang KQ
S- Editor: Yu J **L- Editor:** A **E- Editor:** Wang CH





Published by **Baishideng Publishing Group Inc**

8226 Regency Drive, Pleasanton, CA 94588, USA

Telephone: +1-925-223-8242

Fax: +1-925-223-8243

E-mail: bpgoffice@wjgnet.com

Help Desk: <http://www.wjgnet.com/esps/helpdesk.aspx>

<http://www.wjgnet.com>



ISSN 1007-9327

