

Paclitaxel-associated reticulate hyperpigmentation: Report and review of chemotherapy-induced reticulate hyperpigmentation

Philip R Cohen

Philip R Cohen, Department of Dermatology, University of California San Diego, San Diego, CA 92131-3643, United States

Author contributions: Cohen PR designed the report, performed the research, collected the patient's clinical data, analyzed the data, and wrote the paper.

Institutional review board statement: The study was reviewed and approved by the University of California San Diego Institutional Review Board.

Informed consent statement: The study participant provided informed written consent prior to study enrollment.

Conflict-of-interest statement: Philip R Cohen has no conflicts of interest. He has received no fees for serving as a speaker, a consultant or an advisory board member. Philip R Cohen has received no research funding. Philip R Cohen is an employee of the University of California San Diego. Philip R Cohen owns no stocks or shares in any organization. Philip R Cohen owns no patents.

Open-Access: This article is an open-access article which was selected by an in-house editor and fully peer-reviewed by external reviewers. It is distributed in accordance with the Creative Commons Attribution Non Commercial (CC BY-NC 4.0) license, which permits others to distribute, remix, adapt, build upon this work non-commercially, and license their derivative works on different terms, provided the original work is properly cited and the use is non-commercial. See: <http://creativecommons.org/licenses/by-nc/4.0/>

Manuscript source: Invited manuscript

Correspondence to: Philip R Cohen, MD, Department of Dermatology, University of California San Diego, 10991 Twinleaf Court, San Diego, CA 92131-3643, United States. mitehead@gmail.com
Telephone: +1-858-6578322

Received: June 26, 2016

Peer-review started: June 29, 2016

First decision: September 5, 2016

Revised: September 26, 2016

Accepted: October 22, 2016

Article in press: October 24, 2016

Published online: December 16, 2016

Abstract

Drug-induced reticulate hyperpigmentation is uncommon. Including the patient described in this report, chemotherapy-associated reticulate hyperpigmentation has only been described in ten individuals. This paper describes the features of a woman with recurrent and metastatic breast cancer who developed paclitaxel-induced reticulate hyperpigmentation and reviews the characteristics of other oncology patients who developed reticulate hyperpigmentation from their antineoplastic treatment. A 55-year-old Taiwanese woman who developed reticulate hyperpigmentation on her abdomen, back and extremities after receiving her initial treatment for metastatic breast cancer with paclitaxel is described. The hyperpigmentation became darker with each subsequent administration of paclitaxel. The drug was discontinued after five courses and the pigment faded within two months. PubMed was searched with the key words: Breast, cancer, chemotherapy, hyperpigmentation, neoplasm, reticulate, tumor, paclitaxel, taxol. The papers generated by the search, and their references, were reviewed. Chemotherapy-induced reticulate hyperpigmentation has been described in four men and six women. Bleomycin, cytoxan, 5-fluorouracil, idarubicin, and paclitaxel caused the hyperpigmentation. The hyperpigmentation faded in 83% of the patients between two to six months after the associated antineoplastic agent was discontinued. In conclusion, chemotherapy-induced reticulate hyperpigmentation is a rare reaction that may occur during treatment with various antineoplastic agents. The hyperpigmentation fades in most individuals once the

treatment is discontinued. Therefore, cancer treatment with the associated drug can be continued in patients who experience this cutaneous adverse event.

Key words: Breast; Cancer; Chemotherapy; Hyperpigmentation; Neoplasm; Reticulate; Tumor; Paclitaxel; Taxol

© The Author(s) 2016. Published by Baishideng Publishing Group Inc. All rights reserved.

Core tip: Chemotherapy-induced reticulate hyperpigmentation has been described in four men and six women being treated for either a hematologic malignancy or a solid tumor. Associated drugs included cytoxan (with or without idarubicin), paclitaxel, 5-fluorouracil and bleomycin. The skin lesions were usually asymptomatic and appeared as linear macular hyperpigmentation that was lacy, net-like, or both on the patient's back. The hyperpigmentation appeared within 3 d to 18 wk after starting the drug and faded within 2 to 6 mo after stopping the medication. Chemotherapy-induced reticulate hyperpigmentation did not require dose reduction or discontinuation of the associated antineoplastic treatment.

Cohen PR. Paclitaxel-associated reticulate hyperpigmentation: Report and review of chemotherapy-induced reticulate hyperpigmentation. *World J Clin Cases* 2016; 4(12): 390-400 Available from: URL: <http://www.wjgnet.com/2307-8960/full/v4/i12/390.htm> DOI: <http://dx.doi.org/10.12998/wjcc.v4.i12.390>

INTRODUCTION

Reticulate pigmentary disorders can be congenital or acquired^[1]. Drug-induced reticulate hyperpigmentation is uncommon^[2]. A woman with paclitaxel-associated reticulate hyperpigmentation is described and antineoplastic therapy-related linear and reticulate hyperpigmentation is reviewed.

CASE REPORT

A 55-year-old Taiwanese woman with metastatic breast cancer to her lungs and bones presented for evaluation of a new asymptomatic rash on her abdomen, back and legs. She had a prior allergic reaction, in 2014, to zoledronic acid after the initial intravenous infusion; non-tender, non-pruritic erythematous patches developed on her proximal medial thighs and inguinal regions, axilla, antecubital fossa and popliteal fossa. The lesions resolved spontaneously and there was no reaction when an alternative agent, denasumab, was given.

In 2004, she was diagnosed with invasive mixed ductal and lobular carcinoma (grade 2, T3N3 with lymphatic vessel invasion, estrogen receptor positive, progesterone receptor negative, and HER2/neu negative) right breast cancer. Treatment included right breast

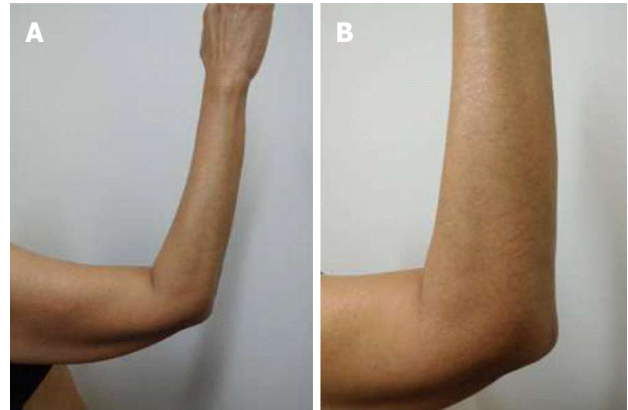


Figure 1 Distant (A) and closer (B) views of paclitaxel-induced reticulate hyperpigmentation on the elbow and extensor right arm.

lumpectomy, chemotherapy (adriamycin and cytoxan, followed by taxol), radiation therapy, and hormonal therapy (for five years); her treatment finished in February 2010.

Follow up workup in July 2014 revealed biopsy-confirmed recurrence of her breast cancer characterized by hilar adenopathy, multiple pulmonary nodules and bony metastases. She began daily letrozole that month.

Restaging, in May 2015 showed disease progression. During the next few months, she was unsuccessfully treated initially with an oral selective estrogen receptor degrader and subsequently with a combination of abemaciclib, exemestane and everolimus. Capecitabine was started in September 2015; erythema appeared on the sun-exposed areas of her face. Subsequently, diffuse and confluent malar postinflammatory hyperpigmentation developed. Increased tumor burden was observed after 4 mo of treatment and the drug was discontinued.

Paclitaxel (80 mg/m²) intravenous weekly therapy was initiated in January 2016. She was premeditated prior to each treatment to prevent hypersensitivity reactions. She received intravenous dexamethasone (10 mg) and famotidine (20 mg) and intramuscular diphenhydramine (25 mg).

Hyperpigmentation on her abdomen, back and extremities was noted to initially appear during the week after receiving her first infusion of paclitaxel and prior to her second treatment. She also noted that the new hyperpigmentation appeared darker (and provided greater contrast with the normal appearing skin of her abdominal striae) on the day of each paclitaxel infusion. In contrast, her facial hyperpigmentation-secondary to capecitabine - was fading.

She was examined after her fifth weekly treatment of paclitaxel. She had dark brown linear and reticulate hyperpigmentation, more prominent proximally than distally, on the extensor arms (Figure 1) and legs (Figure 2), on the back (Figure 3), and on the abdomen (Figure 4). The net-like hyperpigmentation did not occur in the abdominal striae (Figure 4).

Microscopic examination of hyperpigmented skin

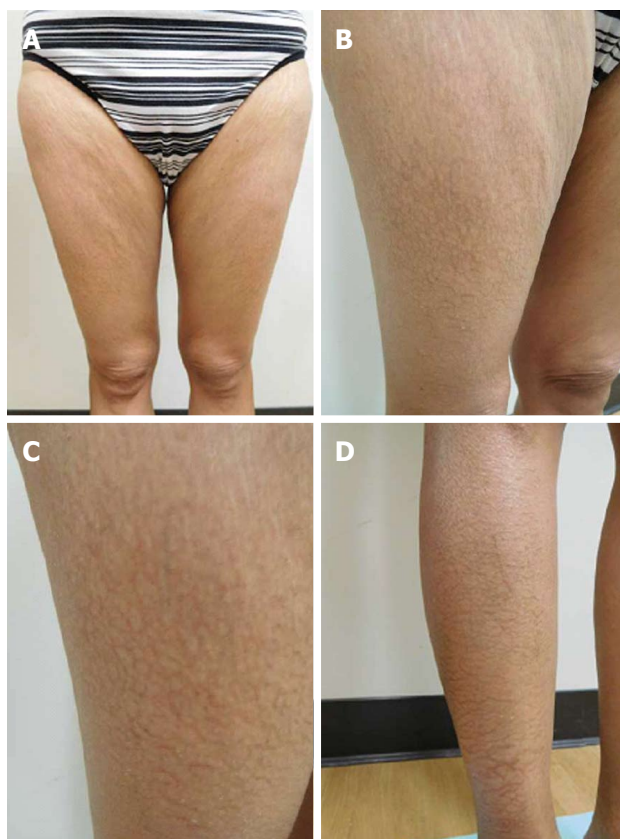

Figure 2 Paclitaxel-associated reticulate hyperpigmentation on the lower extremities. Linear and net-like hyperpigmentation is noted on distant (A), intermediate (B and D) and closer (C) views of the right thigh (B and C) and right pretibial area (D).

and normal appearing skin (for comparison) from the abdomen was performed. The hyperpigmented skin showed not only prominent melanin deposited within the basal layer of the epidermis but also incontinence of melanin pigment and melanophages in the upper dermis (Figure 5); a Fontana-Masson stain confirms the presence of melanin at these locations (Figure 6). In contrast, the normal-appearing skin only showed slight hyperpigmentation of the epidermal basal layer (Figure 7); a Fontana-Masson stain confirmed the sparse presence of melanin in the basal layer of the epidermis and focally in the papillary dermis (Figure 8). A Perl's iron stain, to detect iron, was negative in both the hyperpigmented skin and the normal appearing skin.

In summary, in comparison to the normal-appearing skin, the deposition of melanin in the epidermis and dermis was significantly greater in the areas of hyperpigmentation.

She received two additional courses of paclitaxel. After her seventh treatment, she developed painful and swollen, erythematous scaling plaques on her wrists, posterior neck and right ankle (Figure 9). The right ankle lesion progressed and a similar lesion appeared on her left ankle (Figure 10). Biopsy demonstrated an interface dermatitis. Her ankle lesions prevented her from being able to walk; therefore, her paclitaxel treatments were discontinued. Her symptoms and skin

changes completely resolved.

The reticulate hyperpigmentation had completely faded on her abdomen and legs at follow up 2 mo after stopping the paclitaxel. There was also significant fading of the pigmentation on her back and arms. She is currently being treated with a monthly infusion of faslodex and palbociclib daily for 3 consecutive weeks each month and has not developed chemotherapy-induced reticulate hyperpigmentation.

DISCUSSION

Widespread reticulate hyperpigmentation has, albeit rarely, been observed following exposure to medications^[2]. Reticulate hyperpigmentation has been described in single individuals who have received topical benzoyl peroxide^[3], oral diltiazem^[4], or intravenous regional anesthesia with prilocaine and methylprednisolone^[5]. This pattern of hyperpigmentation has also been observed in individuals receiving antineoplastic therapy.

PubMed was used to search the following terms: Breast, cancer, chemotherapy, hyperpigmentation, neoplasm, reticulate, tumor, paclitaxel, taxol. All papers were reviewed and relevant manuscripts, along with their reference citations, were evaluated. Including the patient reported in this paper, chemotherapy-induced reticulate hyperpigmentation has occurred in 10 individuals (Table 1)^[6-9].

Wright *et al*^[6] initially described reticulate hyperpigmentation resulting from chemotherapy in 1990. Their patient was a 55-year-old man with non-Hodkins lymphoma who "developed striking hyperpigmentation of the skin, consisting of widespread symmetrical reticulate streaks of hyperpigmentation in a racemose pattern on the trunk and limbs". He had received several antineoplastic agents, including bleomycin; the hyperpigmentation developed after 6 wk of treatment and a total dose of 75 mg of bleomycin^[6].

Five years later, in 1995, Allen *et al*^[7] reported a 61-year-old man with metastatic cancer from a bowel primary who "developed an asymptomatic eruption consisting of widespread reticulate erythema and pigmentation" one day after finishing a 48 h intravenous infusion of 680 mg (400 mg/m²) of 5-fluorouracil. His next 5-fluorouracil treatment, three weeks later at half the dose, did not result in recurrence of the eruption. Neither the erythema nor the hyperpigmentation recurred during subsequent treatments at full dose and the hyperpigmentation gradually faded over a period of 16 wk^[7].

A decade would pass before the next descriptions of chemotherapy-associated reticulate hyperpigmentation by Jogi *et al*^[9]. The first patient reported by the investigators was a 63-year-old woman with mucoid epidermoid carcinoma of the parotid gland who was receiving concomitant chemoradiotherapy; three days into her third cycle, which consisted of carboplatin and 5-fluorouracil, she developed a reticulated erythematous

Table 1 Characteristics of patients with chemotherapy-induced reticulate hyperpigmentation

Case	Age (yr) Race Sex	Chemo	Onset (d)	OCF	Site	Histo	Cancer	Seq	Ref.
1	55 NR M	Adria Bleo ¹ Cyclo MTX Vin	42	None	Arms Back Legs ²	DM MBaK MSBaK EM ³	NHL	Persists	6
2	61 Ca M	5-FU ^{1,4}	3	CAE	Back ²	NR	GIT	Faded ⁵	7
3	64 Ca M	Cyt ¹ Ida ¹ Lo	21	None	Back Butt	NR	AML	UK	8C5
4	74 Ca M	Cyclo Cyt ¹ Dexa Ida ¹ Vin	28	Mild Pru	Back Shldr	MBaK MPaD PI	ALL	Faded ⁶	8C2
5	49 Ca W	Pac ¹	126	None	Back Thi	MBaK MPaD PI	BC	Faded ⁷	8C1
6	51 NR W	Cyt ¹ Ida ¹	> 28	None	Back (low)	NR	AML	NR	9C2
7	55 Ta W	Pac ¹	< 7	None	Abd Back Legs	DM MBaK PI	BC ⁸	Faded ⁹	CR
8	61 Ca W	Cyt ¹ Top	28	None	Back Butt Thi	RCM ¹⁰	AML	UK	8C4
9	63 NR W	Carbo 5-FU ¹	3 ¹¹	PAE	Back Butt Thi	NR	MEC	NR	9C1
10	74 Ca W	Carbo Pac ¹	42	PAE Pru	Back	RCM ¹⁰	OC	Faded ¹²	8C3

¹Suspected chemotherapeutic agent causing reticulate hyperpigmentation; ²The hyperpigmentation was widespread; ³Electron microscopy showed: (1) a normal number of melanocytes and (2) an increased number of melanosomes in keratinocytes; ⁴Pigmentation occurred at 400 mg/m³ (680 mg). It did not occur at 200 mg/m³ (340 mg). The dose was increased to 400 mg/m³ and there was no subsequent recurrence; ⁵The hyperpigmentation faded over 16 wk; ⁶The hyperpigmentation faded within 6 mo; ⁷The hyperpigmentation faded within 3 mo; ⁸The patient had mixed lobular and ductal breast cancer metastatic to bone, liver and lungs; ⁹Paclitaxel was discontinued after her 7th weekly treatment. At follow-up 2 mo after stopping paclitaxel, the hyperpigmentation was completely faded on her abdomen and legs. There was also significant fading on her back and arms; ¹⁰Reflectance confocal microscopy showed increased amount of melanin in basal keratinocytes; ¹¹Hyperpigmentation appeared 3 d after starting cycle 3 of chemotherapy; ¹²Slight regression of the hyperpigmentation was observed. Abd: Abdomen; Adria: Adriamycin; ALL: Acute lymphoblastic leukemia; AML: Acute myelogenous leukemia; BC: Breast cancer (metastatic); Bleo: Bleomycin; Butt: Buttocks; Ca: Caucasian; CAE: Concurrent asymptomatic erythema; Carbo: Carboplatin; Chemo: Chemotherapy patient was being treated with; CR: Current report; Cyclo: Cyclophosphamide; Cyt: Cytarabine; Dexa: Dexamethasone; DM: Dermal (papillary) melanophages; EM: Electron microscopy; 5-FU: 5-fluorouracil; GIT: Gastrointestinal carcinoma (metastatic); Histo: Histopathology (hematoxylin and eosin or Fontana Masson or both); Ida: Idarubicin; Lo: Lomustine; Low: Lower; M: Man; MEC: Mucoid epidermoid carcinoma of the parotid gland; MBaK: Melanin increased in basal keratinocytes; MPaD: Melanin in papillary dermis; MBSaK: Melanin increased in suprabasal keratinocytes; MTX: Methotrexate; NHL: Non-Hodgkin lymphoma; NR: Not reported; OC: Ovarian cancer (metastatic); OCF: Other clinical features; Pac: Paclitaxel; PAE: Preexisting asymptomatic erythema; PI: Pigmentary incontinence into the papillary dermis; Pru: Pruritus; RCM: Reflectance confocal microscopy; Seq: Sequellae; Shldr: Shoulders; Symp: Symptoms; Ta: Taiwanese; Thi: Thighs; Top: Topoisomerase II inhibitor; UK: Unknown; Vin: Vincristine; W: Woman.

rash on her back and legs. The erythema eventually changed first to a violaceous and then to a brownish discoloration. During her fourth cycle she was noted to have a reticulated, hyperpigmented macular eruption on her back, posterior thighs, and popliteal fossa^[9].

The second patient reported by Jogi *et al*^[9] in 2005 was a 51-year-old woman with acute myelogenous leukemia. She had received induction chemotherapy with cytarabine and idarubicin. More than four weeks

later, when she returned for a bone marrow biopsy, "she was found to have reticulated hyperpigmented patches on her lower back^[9]".

More recently, after another decade, in 2015 Masson Regnault *et al*^[8] described chemotherapy-related reticulated hyperpigmentation in five oncology patients. Their case series included two men with leukemia, and three women with breast cancer, leukemia, or ovarian carcinoma. The implicated antineoplastic agents-

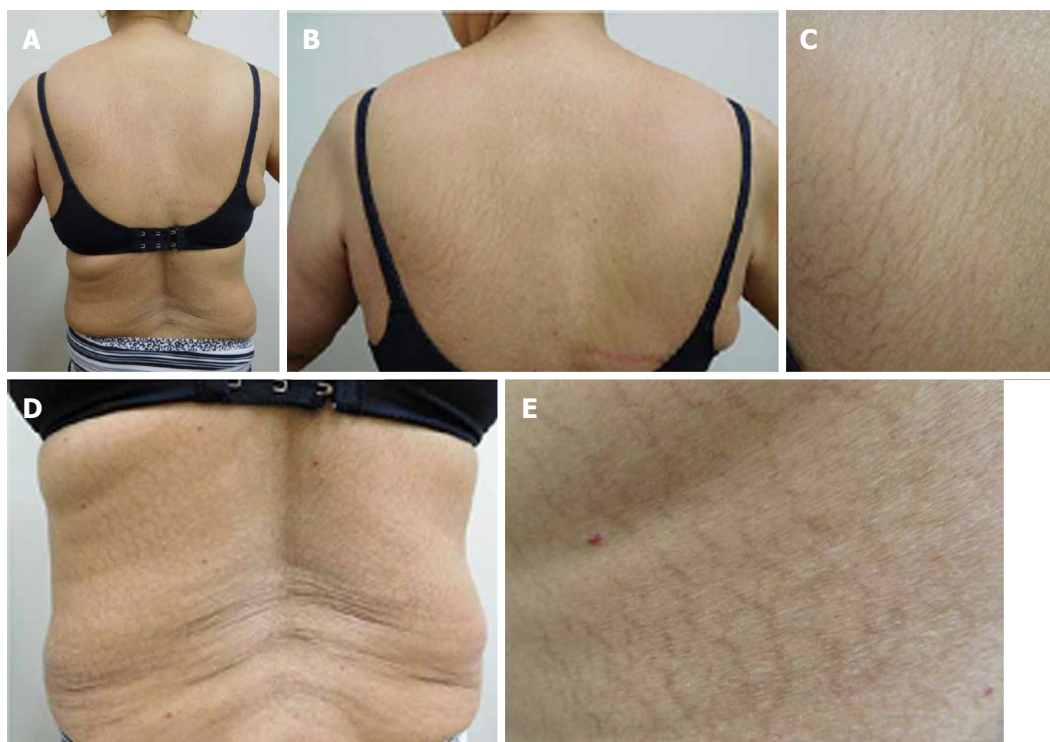


Figure 3 Paclitaxel-associated reticulate hyperpigmentation on the back. Distant (A) view of the back shows reticulate hyperpigmentation following treatment with paclitaxel. Intermediate (B and D) and closer (C and E) views of the upper (B and C) and lower (D and E) back show the linear and net-like hyperpigmentation.

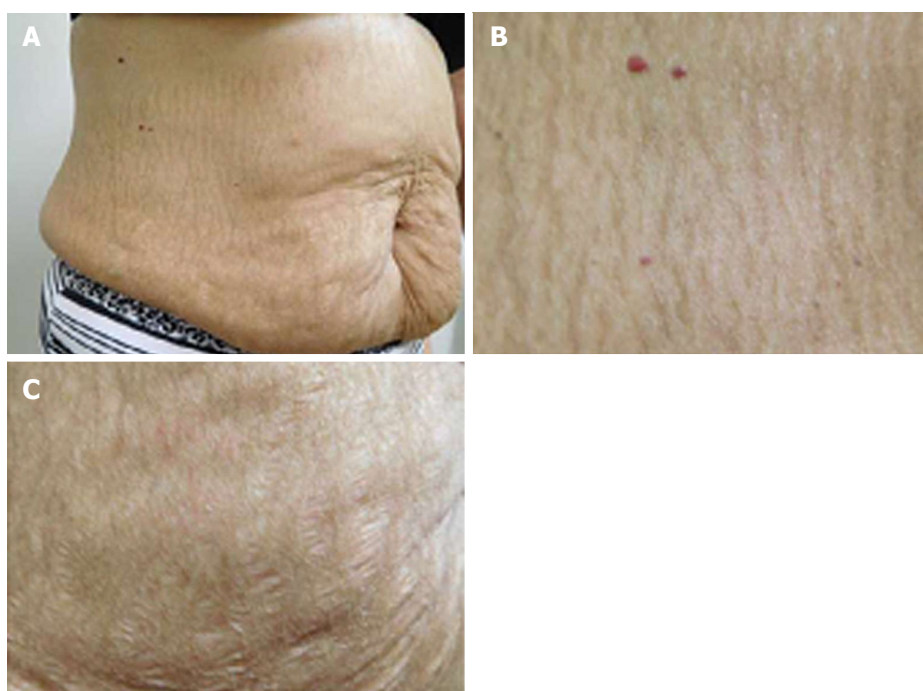

Figure 4 Paclitaxel-associated reticulate hyperpigmentation on the abdomen. Distant (A) and closer (B) views of paclitaxel-induced reticulate hyperpigmentation on the abdomen. The hyperpigmentation spares the stretch marks on the abdomen (C).

received either alone or concurrently-were cytarabine, idarubicin, and paclitaxel^[8].

A reliable and valid method for estimating the probability of adverse drug reactions was established by Naranjo *et al*^[10] in 1981. The current report describes

a woman with metastatic breast cancer. In this patient, chemotherapy-associated reticulate hyperpigmentation developing as an adverse drug reaction induced by paclitaxel would be assigned to a definite probability category according to Naranjo *et al*^[10]'s adverse drug

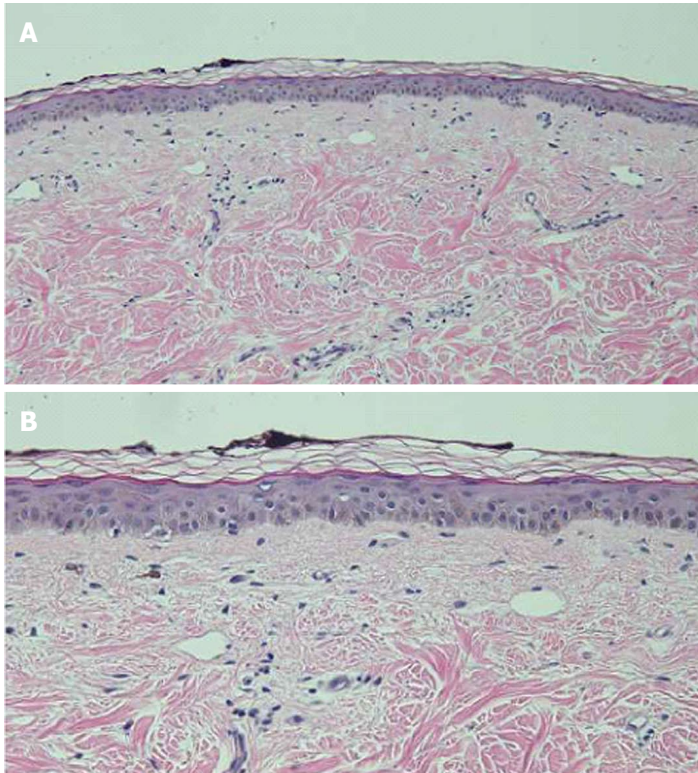


Figure 5 Distant (A) and closer (B) views of a hematoxylin and eosin stained biopsy specimen of the reticulate hyperpigmentation show confluent basilar hyperpigmentation with increased melanin in the basal layers of the epidermis. Melanin is also present in melanophages in the papillary dermis (hematoxylin and eosin; A: $\times 10$; B: $\times 20$).

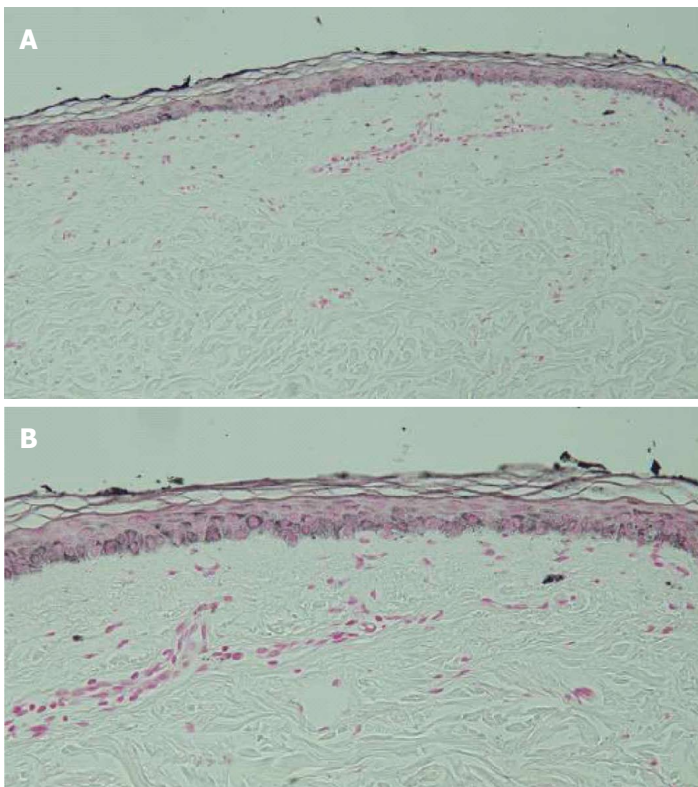


Figure 6 Distant (A) and closer (B) views of a Fontana-Masson stained biopsy specimen of the reticulate hyperpigmentation confirms the increased presence of melanin in the basal keratinocytes of the epidermis and within papillary dermis melanophages (Fontana-Masson; A: $\times 10$; B: $\times 20$).

reaction probability scale (Table 2).

In summary, four men and six women with chemotherapy-induced reticulate hyperpigmentation have been described; the oncology patients ranged from 49 years to 74 years (median = 61 years). The men ranged in age from 55 years to 74 years (median = 63 years). The women ranged in age from 49 years to 74

years (median = 58 years).

Most of the individuals were Caucasian (6/7, 86%). One woman was Taiwanese. The race was not provided for 3 individuals.

Reticulate hyperpigmentation occurred in five patients with hematopoietic malignancies and five individuals with solid tumors. Acute myelogenous leuke-

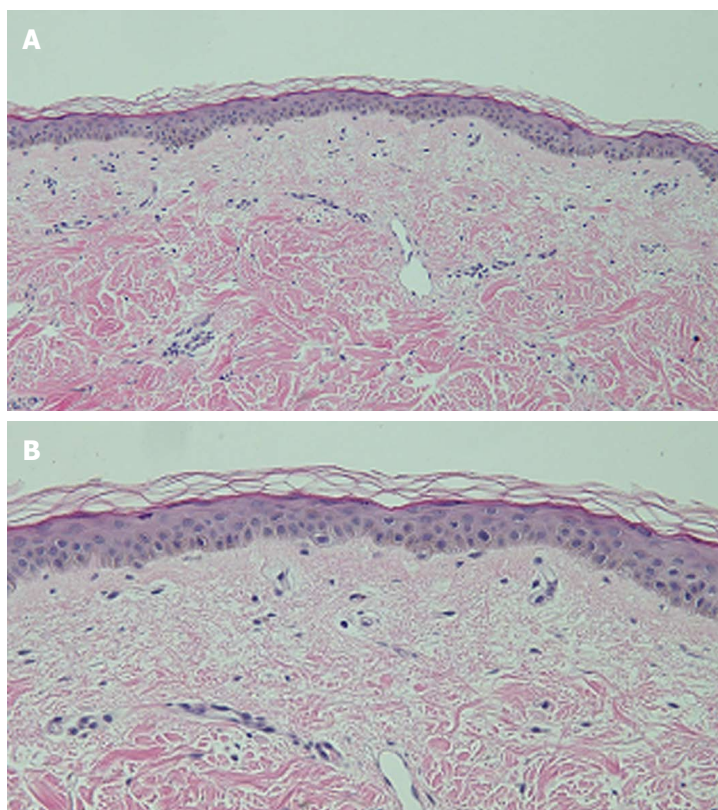


Figure 7 Distant (A) and closer (B) views of a hematoxylin and eosin stained biopsy specimen of normal appearing skin (adjacent to the hyperpigmentation) only shows minimal hyperpigmentation of the basal layer of the epidermis (hematoxylin and eosin; A: $\times 10$; B: $\times 20$).

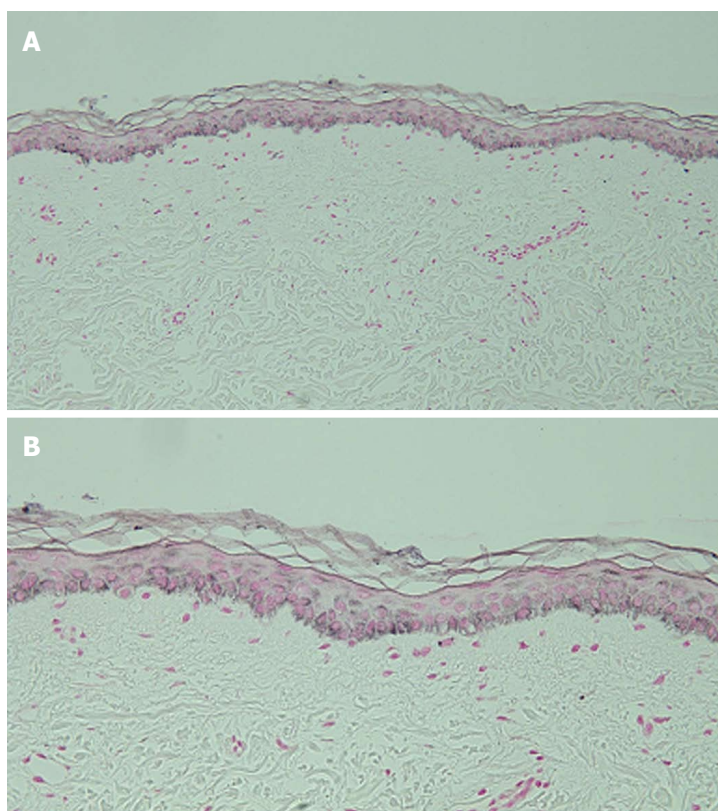


Figure 8 Distant (A) and closer (B) views of a Fontana-Masson stained biopsy specimen of normal appearing skin (adjacent to the hyperpigmentation) confirms the sparse presence of melanin in the epidermal basal layer and focally in the papillary dermis (Fontana-Masson; A: $\times 10$; B: $\times 20$).

mia was the most common cancer (3 patients); other lymphoproliferative disorders included acute lymphoblastic leukemia and non-Hodgkin lymphoma. Breast cancer was the underlying neoplasm in two women; other metastatic solid tumors, each in one patient,

were gastrointestinal tract cancer, mucoid epidermoid carcinoma of the parotid gland, and ovarian carcinoma.

The patients were receiving between one (3 individuals, 30%) to five (2 individuals, 20%) antineoplastic agents. Four patients (40%) were receiving

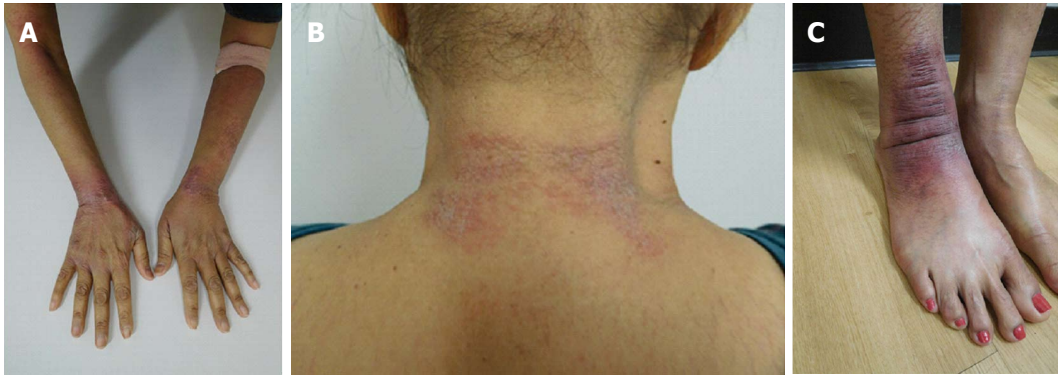

Figure 9 Paclitaxel-associated interface dermatitis presenting as tender and edematous red scaling plaques on the dorsal wrists (A), the posterior neck (B), and the right ankle (C).

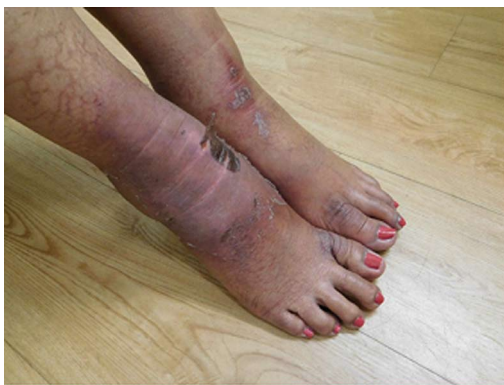

Figure 10 The paclitaxel-associated interface dermatitis lesion on the right ankle progressed in severity and distribution. A similar lesion also developed on the left ankle.

two drugs and one person (10%) was receiving three medications. For all individuals, either one agent (seven patients) or two drugs-cytosin and idarubicin - (three patients) were considered to be the cause of the hyperpigmentation.

Reticulate hyperpigmentation was associated with Cytosin-either alone (in one individual) or concurrent with idarubicin (in three patients). Paclitaxel was the causative agent in three women. Two patients' reticulate hyperpigmentation was related to 5-fluorouracil; bleomycin was the implicated drug in one man.

Paclitaxel is a taxane. It is derived from the bark of the Pacific yew tree (*Taxus brevifolia*). Paclitaxel acts by stabilizing microtubules; this action not only promotes the assembly of tubulin but also prevents the depolymerization of formed polymers. Subsequently, microtubule bundles accumulate and cell death occurs since cell division is interrupted^[11-14].

Paclitaxel is used not only in the management of breast cancer, but also other cancers, such as lung and ovary^[11-15]. Cutaneous adverse effects of paclitaxel (and nab-paclitaxel) include alopecia, erythema multiforme, hand-foot syndrome (acral erythema), hypersensitivity reaction, mucositis, nail changes, photosensitivity reactions, and subacute lupus erythematosus^[15-22]. In addition to the woman with metastatic breast cancer

described in this report, paclitaxel-induced reticulate hyperpigmentation occurred in another woman with metastatic breast cancer and a woman with metastatic ovarian cancer.

The onset of reticulate hyperpigmentation following initiation of the associated chemotherapy ranged from 3 d to 18 wk (median = 28 d). Both patients receiving 5-fluorouracil has the most rapid onset of hyperpigmentation. The appearance of hyperpigmentation in women receiving paclitaxel ranged from less than 7 d in the currently described patient to 126 d in another women with breast cancer; the third woman receiving paclitaxel for ovarian cancer developed hyperpigmentation after 6 wk of treatment.

Associated pruritus or erythema or both were described in 40% (4/10 patients) of the individuals with chemotherapy-induced reticulate hyperpigmentation. Asymptomatic erythema was noted in two patients who had received 5-fluorouracil (one man and one woman) and one woman who had been treated with paclitaxel; the paclitaxel treated woman also had pruritus. Another man who was treated with cytarabine and idarubicin also had mild pruritus.

Chemotherapy-related reticulate hyperpigmentation appears as brown colored macular hyperpigmentation without scaling or other epidermal change that is linear, lacy and/or net-like. It was located on the back of all 10 patients. It was also present on the legs (5 patients), the buttocks (3 patients), the shoulders (2 patients) and the abdomen (1 patient). In the reported patient, the hyperpigmentation was not only on her back, but also on her anterior thighs and abdomen; the pigmentation on her abdomen spared her striae.

Microscopic examination was performed in only four patients^[6,8]. Common histologic features in all of these individuals included increased melanin in the basal layer of the epidermis and melanophages in the papillary dermis. Increased melanin in the suprabasilar keratinocytes was observed in one patient^[6], and melanin pigment incontinence into the upper dermis was noted in three patients^[8]. These pathologic changes are similar to those that have been observed in patients with pigment changes from other chemotherapies^[8].

Table 2 Adverse drug reaction probability scale^{1,2,3,4}

Question	PA	PS
Are there previous conclusive reports on this reaction? Answer score: Yes = +1; No = 0	Yes	1
Did the adverse event appear after the suspected drug was administered? Answer score: Yes = +2; No = -1	Yes	2
Did the adverse reaction improve when the drug was discontinued or a specific antagonist was administered? Answer score: Yes = +1; No = 0	Yes	1
Did the adverse reaction reappear when the drug was readministered? Answer score: Yes = +2; No = -1	Yes	2
Are there alternative causes (other than the drug) that could on their own have caused the reaction? Answer score: Yes = -1; No = +2	No	2
Did the reaction reappear when a placebo was given? Answer score: Yes = -1; No = +1	DNK	0
Was the drug detected in the blood (or other fluids) in concentrations known to be toxic? Answer score: Yes = +1; No = 0	DNK	0
Was the reaction more severe when the dose was increased, or less severe when the dose was decreased? Answer score: Yes = +1; No = 0	DNK	0
Did the patient have a similar reaction to the same or similar drugs in any previous exposure? Answer score: Yes = +1; No = 0	DNK	0
Was the adverse event confirmed by any objective evidence? Answer score: Yes = +1; No = 0	Yes	1
Total score		9

¹An answer is provided for all questions (PA) and a determination of score is provided (PS) to assess the adverse drug reaction; ²An answer of "Do not know" = 0 score; ³From the total score, the adverse drug reaction is assigned a probability category: Definite (greater than or equal to 9), probable (5 to 8), possible (1 to 4), doubtful (less than or equal to 0); ⁴Drug = paclitaxel. DNK: Do not know; PA: Patient answer; PS: Patient score.

Dermoscopy analysis was conducted in a 61-year-old woman with acute myelogenous leukemia. Her reticulate hyperpigmentation appeared 4 wk after treatment with cytarabine and a topoisomerase II inhibitor and showed a hyperpigmented reticulate network; reflectance confocal microscopy of the lesions demonstrated an increased amount of pigment in the basal layer of the epidermis^[8]. Reflectance confocal microscopy was also performed in a 74-year-old woman with ovarian carcinoma; 6 wk after receiving paclitaxel and carboplatin, her hyperpigmentation appeared and showed increased content of melanin in basal keratinocytes^[8].

Electron microscopy studies were performed in one patient-the 55-year-old man with non-Hodgkin lymphoma who received not only bleomycin, but also adriamycin, cyclophosphamide, methotrexate and vincristine. His reticulate hyperpigmentation showed both a marked increase of singly arranged melanosomes in the basal keratinocytes and lipid vacuoles (along with damage to subcellular organelles) in not only the basal keratinocytes but also the melanocytes. In the upper papillary dermis, melanosomal complexes were found in endothelial cells and macrophages^[6].

The pathogenesis of chemotherapy-induced reticulate hyperpigmentation remains to be established. All of the previous investigators-based on dermoscopy, confocal reflectance microscopy, pathology, and electron microscopy findings-hypothesize that the hyperpigmentation results from a secondary increase in melanogenesis caused by a direct toxic effect of the chemotherapy on the melanocytes^[6-9]. Masson Regnault *et al*^[8] also suggest that, in susceptible individuals, local changes in blood flow may partially account for the

lesions being located in areas of contact, such as the back and buttocks.

The reticulate hyperpigmentation persisted while the patients continued to receive the associated anti-neoplastic agent. Subsequent follow-up was provided for 6 individuals. The hyperpigmentation partially or completely resolved in 83% (5/6) of the patients after the chemotherapy has been discontinued. Fading occurred within 2 to 6 mo.

Chemotherapy-induced reticulate hyperpigmentation is a cutaneous reaction that has been described in ten individuals: Four men and six women. The patients were being treated for hematologic malignancies [acute myelogenous leukemia (3 patients), acute lymphoblastic leukemia (1 patient) and non-Hodgkins lymphoma (1 patient)] or solid tumors [breast cancer (2 patients), gastrointestinal carcinoma (1 patient) mucoid epidermal carcinoma of the parotid gland (1 patient) and ovarian cancer (1 patient)]. Cytosan [alone (1 patient) or concurrent with idarubicin (3 patients)] was the most commonly associated drug. Other causative antineoplastic agents included paclitaxel (3 patients), 5-fluorouracil (2 patients) and bleomycin (1 patient). The skin lesions were asymptomatic in most of the oncology patients; pruritus, erythema, or both were noted in four individuals. The linear macular hyperpigmentation was lacy, net-like, or both. It appeared on the back of all patients; other sites included the legs (5 patients), buttocks (3 patients), shoulders (2 patients) and abdomen (1 patient). The hyperpigmentation appeared within 3 d to 18 wk after starting the drug and faded within 2 to 6 mo after stopping the medication. Chemotherapy-induced reticulate hyperpigmentation

does not require dose reduction or discontinuation of the associated antineoplastic treatment.

COMMENTS

Case characteristics

A woman with metastatic breast cancer developed a new asymptomatic rash on her abdomen, back and legs after beginning intravenous weekly therapy with paclitaxel.

Clinical diagnosis

The patient's paclitaxel-induced reticulate hyperpigmentation presented as dark brown linear and net-like hyperpigmentation on the extensor arms and legs, on the back, and on the abdomen with sparing of the abdominal striae.

Differential diagnosis

The clinical differential diagnosis of the patient's chemotherapy-induced reticulate hyperpigmentation includes cutis marmorata, erythema ab igne, livedo reticularis, and vasculitis.

Laboratory diagnosis

Laboratory studies - including complete blood cell counts with platelets and serum chemistries - were normal.

Imaging diagnosis

Imaging studies - including computerized axial tomography scans and positron emission tomography scans - confirmed the presence of metastatic breast cancer in the patient's lungs and bones.

Pathological diagnosis

Hematoxylin and eosin stained sections of a biopsy from the hyperpigmented skin showed deposits of melanin within the basal layer of the epidermis in addition to incontinence of melanin pigment and melanophages in the upper dermis; Fontana-Masson stained sections confirmed the presence of melanin at these locations.

Treatment

The patient's chemotherapy-induced reticulate hyperpigmentation had either completely (on her abdomen and legs) or significantly (on her back and arms) faded by 2 mo after stopping the paclitaxel.

Related reports

Chemotherapy-induced reticulate hyperpigmentation has been described in four men and six women. Five patients had hematopoietic malignancies and five individuals had solid tumors. Reticulate hyperpigmentation was associated with Cytosar-U either alone or concurrent with idarubicin, paclitaxel, 5-fluorouracil or bleomycin.

Term explanation

Reticulate hyperpigmentation refers to the pattern of linear and flat darkening of the skin being either net-like or lacy or both.

Experiences and lessons

Chemotherapy-induced reticulate hyperpigmentation is a morphologically distinctive and clinically benign cutaneous reaction to various antineoplastic agents in oncology patients with either hematologic malignancies or solid tumors that does not require dose reduction or discontinuation of the associated antineoplastic treatment and typically resolves or fades spontaneously within 2 to 6 mo after stopping the medication.

Peer-review

This manuscript reported a case pigmentation after treatment with paclitaxel. The author also reviewed the literature on this phenotype, and provided some pathological examination of the pigmentation area. The manuscript is well written

and is worthy of publication.

REFERENCES

- 1 **Sardana K**, Goel K, Chugh S. Reticulate pigmentary disorders. *Indian J Dermatol Venereol Leprol* 2013; **79**: 17-29 [PMID: 23254725 DOI: 10.4103/0378-6323.104665]
- 2 **Zhang X**, Khimji I, Gurkan UA, Safaei H, Catalano PN, Keles HO, Kayaalp E, Demirci U. Lensless imaging for simultaneous microfluidic sperm monitoring and sorting. *Lab Chip* 2011; **11**: 2535-2540 [PMID: 21677993 DOI: 10.1111/j.1365-2230.2011.04100.x]
- 3 **Weinberg JM**, Moss T, Gupta SM, White SM, Don PC. Reticulate hyperpigmentation of the skin after topical application of benzoyl peroxide. *Acta Derm Venereol* 1998; **78**: 301-302 [PMID: 9689304 DOI: 10.1080/000155598441954]
- 4 **Jaka A**, López-Pestaña A, Tuneu A, Lobo C, López-Núñez M, Ormaechea N. Letter: Photodistributed reticulated hyperpigmentation related to diltiazem. *Dermatol Online J* 2011; **17**: 14 [PMID: 21810399]
- 5 **Patel AN**, Perkins W, Ravenscroft A, Varma S. Extraordinary reticulate hyperpigmentation occurring after Bier block. *Clin Exp Dermatol* 2013; **38**: 94-95 [PMID: 22831778 DOI: 10.1111/j.1365-2230.2012.04431.x]
- 6 **Wright AL**, Bleehen SS, Champion AE. Reticulate pigmentation due to bleomycin: light- and electron-microscopic studies. *Dermatologica* 1990; **180**: 255-257 [PMID: 1694148 DOI: 10.1159/000248042]
- 7 **Allen BJ**, Parker D, Wright AL. Reticulate pigmentation due to 5-fluorouracil. *Int J Dermatol* 1995; **34**: 219-220 [PMID: 7538496 DOI: 10.1111/j.1365-4362.1995.tb01579.x]
- 8 **Masson Regnault M**, Gadaud N, Boulinguez S, Tournier E, Lamant L, Gladieff L, Roche H, Guenounou S, Recher C, Sibaud V. Chemotherapy-Related Reticulate Hyperpigmentation: A Case Series and Review of the Literature. *Dermatology* 2015; **231**: 312-318 [PMID: 26422424 DOI: 10.1159/000439047]
- 9 **Jogi R**, Garman M, Pielop J, Orengo I, Hsu S. Reticulate Hyperpigmentation secondary to 5-fluorouracil and idarubicin. *J Drugs Dermatol* 2005; **4**: 652-656 [PMID: 16167426]
- 10 **Naranjo CA**, Busto U, Sellers EM, Sandor P, Ruiz I, Roberts EA, Janacek E, Domecq C, Greenblatt DJ. A method for estimating the probability of adverse drug reactions. *Clin Pharmacol Ther* 1981; **30**: 239-245 [PMID: 7249508 DOI: 10.1038/cpt.1981.154]
- 11 **Bachegowda LS**, Makower DF, Sparano JA. Taxanes: impact on breast cancer therapy. *Anticancer Drugs* 2014; **25**: 512-521 [PMID: 24552749 DOI: 10.1097/CAD.000000000000090]
- 12 **Binder S**. Evolution of taxanes in the treatment of metastatic breast cancer. *Clin J Oncol Nurs* 2013; **17** Suppl: 9-14 [PMID: 23360698 DOI: 10.1188/13.CJON.S1.9-14]
- 13 **Gradishar WJ**. Taxanes for the treatment of metastatic breast cancer. *Breast Cancer (Auckl)* 2012; **6**: 159-171 [PMID: 23133315 DOI: 10.4137/BCBCR.S8205]
- 14 **Pazdur R**, Kudelka AP, Kavanagh JJ, Cohen PR, Raber MN. The taxoids: paclitaxel (Taxol) and docetaxel (Taxotere). *Cancer Treat Rev* 1993; **19**: 351-386 [PMID: 8106152 DOI: 10.1016/0305-7372(93)90010-O]
- 15 **Donati A**, Castro LG. Cutaneous adverse reactions to chemotherapy with taxanes: the dermatologist's point of view. *An Bras Dermatol* 2011; **86**: 755-758 [PMID: 21987144 DOI: 10.1590/S0365-05962011000400020]
- 16 **Payne AS**, James WD, Weiss RB. Dermatologic toxicity of chemotherapeutic agents. *Semin Oncol* 2006; **33**: 86-97 [PMID: 16473647 DOI: 10.1053/j.seminoncol.2005.11.004]
- 17 **Reyes-Habito CM**, Roh EK. Cutaneous reactions to chemotherapeutic drugs and targeted therapies for cancer: part I. Conventional chemotherapeutic drugs. *J Am Acad Dermatol* 2014; **71**: 203.e1-203.e12; quiz 215-216 [PMID: 25037800 DOI: 10.1016/j.jaad.2014.04.014]
- 18 **Heidary N**, Naik H, Burgin S. Chemotherapeutic agents and the skin: An update. *J Am Acad Dermatol* 2008; **58**: 545-570 [PMID: 18342708 DOI: 10.1016/j.jaad.2008.01.001]
- 19 **Payne JY**, Holmes F, Cohen PR, Gagel R, Buzdar A, Dhingra K. Paclitaxel: severe mucocutaneous toxicity in a patient with

- hyperbilirubinemia. *South Med J* 1996; **89**: 542-545 [PMID: 8638189 DOI: 10.1097/00007611-199605000-00022]
- 20 **Cohen PR**. Photodistributed erythema multiforme: paclitaxel-related, photosensitive conditions in patients with cancer. *J Drugs Dermatol* 2009; **8**: 61-64 [PMID: 19180897]
- 21 **Paul LJ**, Cohen PR. Paclitaxel-associated subungual pyogenic granuloma: report in a patient with breast cancer receiving paclitaxel and review of drug-induced pyogenic granulomas adjacent to and beneath the nail. *J Drugs Dermatol* 2012; **11**: 262-268 [PMID: 22270214]
- 22 **Beutler BD**, Cohen PR. Nab-paclitaxel-associated photosensitivity: report in a woman with non-small cell lung cancer and review of taxane-related photodermatoses. *Dermatol Pract Concept* 2015; **5**: 121-124 [PMID: 26114068 DOI: 10.5826/dpc.0502a24]
- P- Reviewer:** Fang BL, Higa GM, Hakenberg OW, Sugawara I, Shimoyama S, Takahashi T **S- Editor:** Ji FF **L- Editor:** A **E- Editor:** Wu HL





Published by **Baishideng Publishing Group Inc**

8226 Regency Drive, Pleasanton, CA 94588, USA

Telephone: +1-925-223-8242

Fax: +1-925-223-8243

E-mail: bpgoffice@wjgnet.com

Help Desk: <http://www.wjgnet.com/esps/helpdesk.aspx>

<http://www.wjgnet.com>

