

Basic Study

TGR5 expression in benign, preneoplastic and neoplastic lesions of Barrett's esophagus: Case series and findings

Shivali Marketkar, Dan Li, Dongfang Yang, Weibiao Cao

Shivali Marketkar, Dongfang Yang, Weibiao Cao, Department of Pathology, Rhode Island Hospital and Warren Alpert Medical School of Brown University, Providence, RI 02903, United States

Dan Li, Department of Medicine, Rhode Island Hospital and Warren Alpert Medical School of Brown University, Providence, RI 02903, United States

Author contributions: Marketkar S contributed to the design of the study, the data analysis and the interpretation of the data; Li D contributed to the design of the study and the completion of the experiments; Yang D performed the immunohistochemical staining; Cao W contributed to the design of the study, the data analysis and the interpretation of the data and wrote the manuscript; all authors approved the final version of the article to be published.

Institutional review board statement: This study was approved by the Institutional Review Board at the Rhode Island Hospital.

Conflict-of-interest statement: No conflict of interest exists.

Data sharing statement: No additional data are available.

Open-Access: This article is an open-access article which was selected by an in-house editor and fully peer-reviewed by external reviewers. It is distributed in accordance with the Creative Commons Attribution Non Commercial (CC BY-NC 4.0) license, which permits others to distribute, remix, adapt, build upon this work non-commercially, and license their derivative works on different terms, provided the original work is properly cited and the use is non-commercial. See: <http://creativecommons.org/licenses/by-nc/4.0/>

Manuscript source: Unsolicited manuscript

Correspondence to: Weibiao Cao, MD, Department of Pathology, Rhode Island Hospital and Warren Alpert Medical School of Brown University, 593 Eddy St, APC12, Providence, RI 02903, United States. wcao@hotmail.com
Telephone: +1-401-4448578
Fax: +1-401-4445890

Received: July 13, 2016

Peer-review started: July 16, 2016

First decision: August 8, 2016

Revised: September 3, 2016

Accepted: September 28, 2016

Article in press: September 28, 2016

Published online: February 28, 2017

Abstract

AIM

To examine the bile acid receptor TGR5 expression in squamous mucosa, Barrett's mucosa, dysplasia and esophageal adenocarcinoma (EA).

METHODS

Slides were stained with TGR5 antibody. The staining intensity was scored as 1+, 2+ and 3+. The extent of staining (percentage of cells staining) was scored as follows: 1+, 1%-10%, 2+, 11%-50%, 3+, 51%-100%. A combined score of intensity and extent was calculated and categorized as negative, weak, moderate and strong staining. TGR5 mRNA was measured by real time PCR.

RESULTS

We found that levels of TGR5 mRNA were significantly increased in Barrett's dysplastic cell line CP-D and EA cell line SK-GT-4, when compared with Barrett's cell line CP-A. Moderate to strong TGR5 staining was significantly higher in high-grade dysplasia and EA cases than in Barrett's esophagus (BE) or in low-grade dysplasia. Moderate to strong staining was slightly higher in low-grade dysplasia than in BE mucosa, but there is no statistical significance. TGR5 staining had no significant difference between high-grade dysplasia and EA. In addition, TGR5 staining intensity was not associated with the clinical stage, the pathological stage and the status of lymph node metastasis.

CONCLUSION

We conclude that TGR5 immunostaining was much stronger in high-grade dysplasia and EA than in BE mucosa or low-grade dysplasia and that its staining intensity was not associated with the clinical stage, the pathological stage and the status of lymph node metastasis. TGR5 might be a potential marker for the progression from BE to high-grade dysplasia and EA.

Key words: TGR5; Esophageal adenocarcinoma; Bile acid

© **The Author(s) 2017.** Published by Baishideng Publishing Group Inc. All rights reserved.

Core tip: The expression of a bile acid receptor TGR5 at moderate to strong intensity was significantly higher in high-grade dysplasia and esophageal adenocarcinoma (EA) cases than in BE or in low-grade dysplasia, suggesting that TGR5 may play an important role in the progression from Barrett's esophagus to high-grade dysplasia and EA. TGR5 staining intensity was not associated with the clinical stage, the pathological stage and the status of lymph node metastasis, indicating that TGR5 may not be a marker for the prognosis of EA.

Marketkar S, Li D, Yang D, Cao W. TGR5 expression in benign, preneoplastic and neoplastic lesions of Barrett's esophagus: Case series and findings. *World J Gastroenterol* 2017; 23(8): 1338-1344 Available from: URL: <http://www.wjgnet.com/1007-9327/full/v23/i8/1338.htm> DOI: <http://dx.doi.org/10.3748/wjg.v23.i8.1338>

INTRODUCTION

Esophageal adenocarcinoma (EA) is a deadly cancer with an increasing incidence^[1-3]. It has a poor prognosis with a median survival of less than one year^[4,5] and a five-year survival rate of 12.5%-20%^[6,7]. Gastro-esophageal reflux disease (GERD) complicated by Barrett's esophagus (BE)^[8-10] is a major risk factor for EA. BE carries nearly a 30-125-fold increased risk for the development of EA, with best estimates of cancer incidence of 0.12%-0.8% per year^[2,10-14]. However, mechanisms of the progression from BE (intestinal metaplasia) to EA are not fully understood.

Bile acids may play an important role in the progression from BE to EA^[15,16] since (1) exposure of the lower esophagus to duodenal juice in animal models leads to EA^[17-19]; (2) bile acid causes the production of reactive oxygen species and DNA damage in a non-neoplastic Barrett's cell line BAR-T^[20]; (3) bile salts may activate the mitogen-activated protein kinase and NF- κ B pathways^[21,22] thereby enhancing cell proliferation and preventing cell apoptosis; and (4) Barrett's cells

become tumorigenic after long-term exposure to acid and bile acid *in vitro*^[23].

A G protein-coupled receptor TGR5 has been shown to mediate bile acids' effects as a cell-surface receptor^[24]. The TGR5 receptor is abundantly expressed in human monocytes and macrophages, and participates in the regulation of cell metabolism^[25,26]. Primary bile acids (cholic acid, taurocholic acid and glycocholic acid) and secondary bile acids (deoxycholic acid, taurodeoxycholic acid, glycodeoxycholic acid and tauroolithocholic acid) have been shown to bind to TGR5 receptors^[24]. Primary bile acids are much weaker at inducing cyclic AMP production *via* activation of TGR5 than secondary bile acids. Deoxycholic acid, taurodeoxycholic acid, and glycodeoxycholic acid have similar strengths at inducing cyclic AMP production^[24]. TGR5 has been reported to be expressed in human gastric cancers, to promote epithelial-mesenchymal transition in gastric cancer cell lines^[27], and to mediate bile acid-induced cholangiocyte proliferation *in vivo* and *in vitro*^[28].

We have previously shown that TGR5 receptors are present in EA cells and that TGR5 receptors mediate bile acid-induced increase in cell proliferation^[29]. The expression of TGR5 in EA tissues is not well understood. In this study, we examined the bile acid receptor TGR5 expression in squamous mucosa, Barrett's mucosa, dysplasia and EA by immunohistochemistry. We found that TGR5 immunostaining was much stronger in high grade and EA than in BE mucosa or low-grade dysplasia.

MATERIALS AND METHODS

Patients and specimens

Archival cases of BE, low grade dysplasia, high grade dysplasia and EA from 34 patients (18 cases with squamous mucosa, 15 cases with BE, 8 cases with low grade dysplasia, 9 cases with high grade dysplasia and 16 cases with adenocarcinoma) were collected between the years of 2005 and 2013 from the archives of the Department of Pathology at the Rhode Island Hospital (RIH). BE was made based on the histological finding of intestinal metaplasia and the endoscopic finding of column-type mucosa. Patients with previous history of chemoradiation therapy were excluded from the study. Stage was defined according to American Joint Committee on Cancer criteria^[30]. This study was approved by the Institutional Review Board at the RIH. All tissue samples were formalin-fixed and paraffin-embedded. The corresponding hematoxylin-eosin slides were reviewed for confirmation of diagnosis and adequacy of material by Dr. Cao W. The detailed clinicopathological features of the study population are given in Table 1.

Immunohistochemistry

Immunohistochemistry for TGR5 was performed

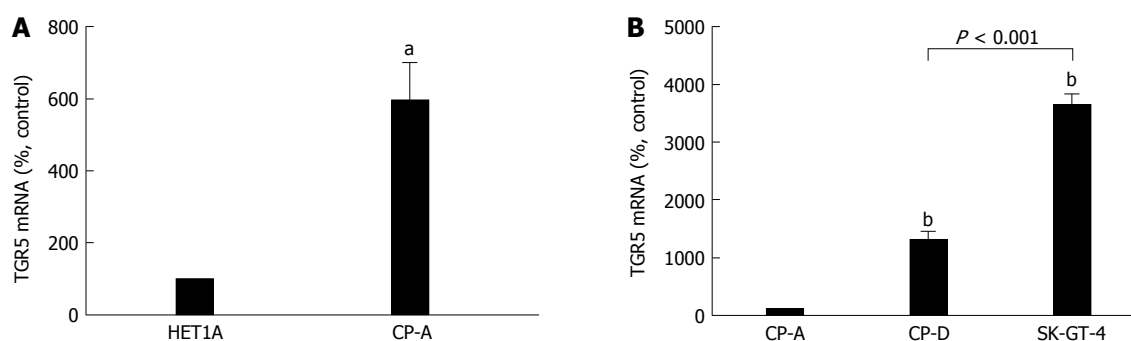


Figure 1 TGR5 mRNA levels in different cell lines. A: TGR5 mRNA level was significantly higher in Barrett's cell line CP-A than in squamous cell line HET-1A; B: Levels of TGR5 mRNA were significantly increased in Barrett's dysplastic cell line CP-D and EA cell line SK-GT-4, when compared with CP-A cells. In addition, TGR5 mRNA was significantly higher in SK-GT-4 cells than in CP-D cells. These data suggest that TGR5 may play an important role in the progression from BE to EA. $n = 3$, t test, $^aP < 0.02$; ANOVA, $^bP < 0.01$ vs CP-A.

Table 1 Clinical features of the study group

Number	34
Age (yr)	
Range	48-91
Median	65.5
Sex, n (%)	
Male	28 (82.4)
Female	6 (17.6)

on 4- μ m paraffin sections. Slides were stained with TGR5 antibody (1:1000, Sigma-Aldrich Co., St. Louis, MO) using the DAKO Envision + Dual Link System and the DAKO Liquid 3,3'-diaminobenzidine (DAB+) Substrate Chromagen System (DAKO North America, Inc., Carpinteria, CA). Bile ducts from liver tissue were used as positive controls. Negative controls included replacement of the primary antibody with non-reacting antibodies of the same species. The specificity of TGR5 antibody has been confirmed by Western Blot analysis in our lab^[31].

Immunohistochemistry assessment

Cancers and non-neoplastic mucosa that displayed a strong, well-localized, strong staining pattern for TGR5 were scored as +3, moderately intense staining as +2, and weak staining as +1. The extent of staining (percentage of cells staining) was scored as follows: 1+ 1%-10%, 2+ 11%-50%, 3+ 51%-100%. A combined score of intensity and extent was calculated and categorized as follows: weak staining 1-2, moderate staining 3-4, strong staining 5-6. All sections were scored independently by WC and SM without knowledge of the clinicopathologic features or clinical outcome.

Cell culture

Cell culture was similar to those we described previously^[29,32,33]. Briefly, human esophageal squamous HET-1A cells were purchased from ATCC, Manassas, VA in 2011 and cultured in the bronchial epithelial cell

medium (BEGM BulletKit, Cambrex, East Rutherford, NJ). Human Barrett's cell line CP-A and Barrett's dysplastic cell line CP-D were bought from ATCC (Manassas, VA) and cultured in Barrett's medium containing keratinocyte medium-2 (Cambrex, Rockland, ME), 1.8 mmol/L CaCl_2 , 5% fetal bovine serum, 400 ng/mL hydrocortisone, 20 ng/mL epidermal growth factor, 0.1 nmol/L cholera toxin, 20 μ g/mL adenine, 5 μ g/mL insulin, 70 μ g/mL bovine pituitary extract, and antibiotics. EA cell line SK-GT-4 was purchased from Sigma and cultured in the Barrett's medium.

Statistical analysis

For immunohistochemical data, statistical differences were determined by χ^2 test. For TGR5 mRNA data, data was expressed as mean \pm SE. Statistical differences between two groups were determined by Student's t test. Differences among multiple groups were tested using analysis of variance and checked for significance using Fisher's protected least significant difference test. P values of 0.05 or less were considered statistically significant.

RESULTS

Expression of TGR5 in different cell lines

We have previously shown that the levels of TGR5 mRNA and protein expression are significantly increased in Barrett's mucosal tissue, when compared with normal esophageal mucosa. TGR5 mRNA and protein levels are significantly higher in EA tissue than in normal esophageal mucosa or in Barrett's mucosa^[29]. Consistent with our previous findings, TGR5 mRNA level was significantly higher in Barrett's cell line CP-A than in squamous cell line HET-1A (Figure 1A). Levels of TGR5 mRNA were significantly increased in Barrett's dysplastic cell line CP-D and EA cell line SK-GT-4, when compared with CP-A cells. In addition, TGR5 mRNA was significantly higher in SK-GT-4 cells than in CP-D cells (Figure 1B). These data suggest that TGR5 may play an important role in the progression

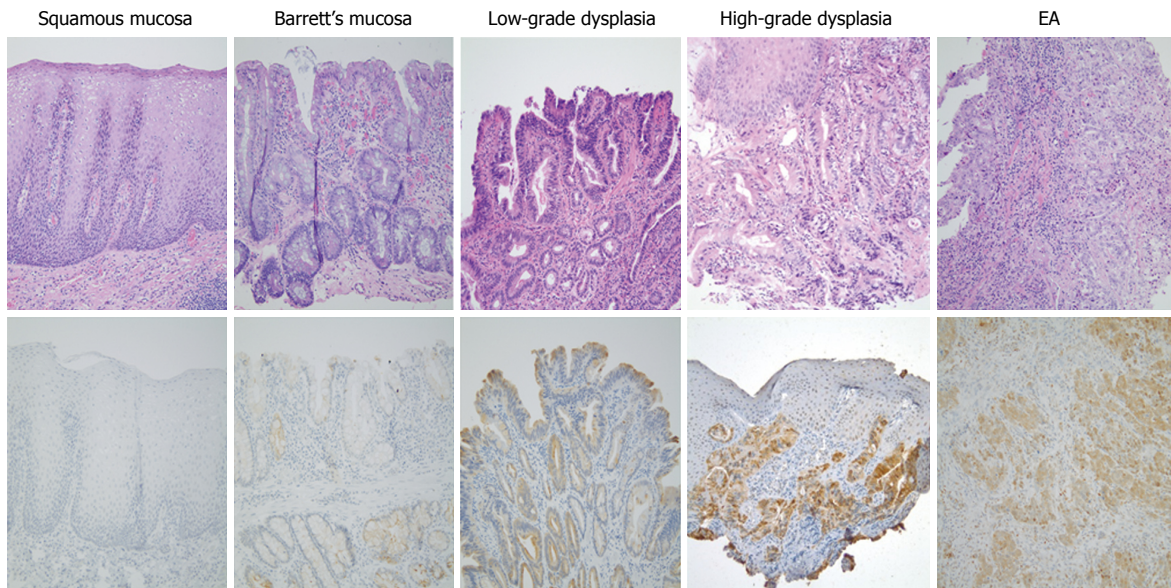


Figure 2 Representative images of squamous mucosa, Barrett's esophagus mucosa, low-grade dysplasia, high-grade dysplasia and esophageal adenocarcinoma. Upper panel: Hematoxylin-eosin staining stain, Lower panel: TGR5 immunostaining, magnification $\times 200$. EA: Esophageal adenocarcinoma.

Table 2 TGR5 expression in squamous mucosa, Barrett's esophagus, low-grade dysplasia, high-grade dysplasia and esophageal adenocarcinoma *n* (%)

	Negative	Weak	Moderate	Strong	
Squamous mucosa, <i>n</i> = 18	13 (72)	5 (28)	0	0	
Barrett's esophagus, <i>n</i> = 15	1 (6.7)	12 (80)	2 (13.3)	0	$P < 0.001$, compared with squamous mucosa
Low grade dysplasia, <i>n</i> = 8	0	5 (62.5)	2 (25)	1 (12.5)	$P > 0.05$, compared with BE
High grade dysplasia, <i>n</i> = 9	1 (11.1)	0	2 (22.2)	6 (66.7)	$P < 0.001$, compared with BE
EA, <i>n</i> = 16	0	0	7 (43.7)	9 (56.3)	$P < 0.05$, compared with low grade dysplasia $P < 0.001$, compared with BE $P < 0.01$, compared with low grade dysplasia

EA: Esophageal adenocarcinoma; BE: Barrett's esophagus.

from BE to EA.

Expression of TGR5 in squamous mucosa, BE mucosa, low grade dysplasia and EA

We have previously shown that TGR5 antibody is relatively specific since only one band was detectable by using TGR5 antibody^[31]. The expression of TGR5 in squamous mucosa, BE mucosa, low-grade dysplasia and EA was further examined by immunohistochemistry. We found that 93.3% Barrett's mucosa showed weak to moderate TGR5 staining, which was significantly higher than squamous mucosa (27.8%) (Figure 2 and Table 2). Moderate to strong TGR5 staining was significantly higher in EA cases (100%) than in BE (13.3%, $P < 0.001$) or in low-grade dysplasia (37.5%, $P < 0.01$) (Figure 2 and Table 2). Similarly, moderate to strong TGR5 staining was significantly higher in high-grade dysplasia cases (88.9%) than in BE (13.3%, $P < 0.001$) or in low-grade dysplasia (37.5%, $P < 0.05$) (Figure 2 and Table 2). Moderate to strong staining was slightly higher in low-grade dysplasia (37.5%) than in BE mucosa (13.3%), but there is no statistical significance. TGR5 staining had no significant difference between

high-grade dysplasia and EA.

Expression of TGR5 in different stages of EA

Next, we compared the expression of TGR5 in different clinical and pathological stages of EA tissues. We found that 100% stage III and IV cases showed moderate to strong staining, which was the same as stage I and II cases (100%; Table 3), indicating that the degree of TGR5 expression might not be associated with clinical stages. T3 and T4 cancers had 63.6% strong TGR5 staining, which was not different from T1 and T2 cancers ($P > 0.05$; Table 4). In addition, TGR5 expression had no significant difference between tumors with and without lymph node metastasis (Table 5).

DISCUSSION

GERD complicated by BE^[8-10] is a major risk factor for EA. There is a progression from BE, to dysplasia and to EA. The mechanisms of progression from BE to EA are not fully understood. Many genetic and epigenetic alterations, chromosomal gains and losses, and hypermethylation of gene promoters may be involved

Table 3 TGR5 expression in different clinical stages of esophageal adenocarcinoma *n* (%)

Clinical stage	Negative	Weak	Moderate	Strong	
I and II, <i>n</i> = 9	0	0	4 (44.4)	5 (55.6)	<i>P</i> > 0.05
III and IV, <i>n</i> = 7	0	0	3 (42.9)	4 (57.1)	

Table 4 TGR5 expression in different pathological stages of esophageal adenocarcinoma *n* (%)

Pathological stage	Negative	Weak	Moderate	Strong	
T1 and T2	0	0	2 (40)	3 (60)	<i>P</i> > 0.05
T3 and T4	0	0	4 (36.4)	7 (63.6)	

Table 5 TGR5 expression in patients with or without lymph node metastasis of esophageal adenocarcinoma *n* (%)

Lymph node metastasis	Negative	Weak	Moderate	Strong	
Positive	0	0	2 (33.3)	4 (66.7)	<i>P</i> > 0.05
Negative	0	0	5 (50)	5 (50)	

in this progression^[13,34]. Bile acids have also been indicated to be involved in this progression^[15,16].

We have previously shown that TGR5 receptors are present in EA cells and that TGR5 mediates bile-acid-induced increase in cell proliferation, suggesting that TGR5 may be important in the development of EA^[29]. We have also reported that moderate to strong TGR5 staining is associated with decreased patient survival in all gastric adenocarcinomas, suggesting that TGR5 may be a negative prognostic marker in gastric cancer^[31]. The histological expression of TGR5 in EA has not been reported.

In this study, we examined TGR5 mRNA expression in different cell lines and found that Barrett's cells CP-A had significantly higher levels of TGR5 mRNA than squamous cells HET-1A. Moreover, Barrett's dysplastic cells CP-D had significantly higher levels of TGR5 mRNA than CP-A cells. EA cells SK-GT-4 had much higher levels of TGR5 mRNA than CP-A or CP-D. These data suggest that TGR5 may be involved in the progression from BE to EA.

Next, we examined the TGR5 expression in squamous mucosa, Barrett's mucosa, dysplasia and EA. We found that moderate to strong TGR5 staining was significantly higher in high-grade dysplasia and EA cases than in BE or in low-grade dysplasia. Moderate to strong staining was slightly higher in low-grade dysplasia than in BE mucosa, but there is no statistical significance. TGR5 staining had no significant difference between high-grade dysplasia and EA. These data further support our above results that TGR5 may play an important role in the progression from BE to EA. How TGR5 is involved in this progression is not clear. Recently we found that TGR5 mediates

bile acid-induced activation of cyclic AMP response element binding protein (CREB) and NADPH oxidase NOX5-S, which produces reactive oxygen species and causes DNA damage^[35]. TGR5 is present in human gastric cancers and promotes epithelial-mesenchymal transition in gastric cancer cell lines^[27]. It also mediates bile acid-induced cholangiocyte proliferation *in vivo* and *in vitro*^[28]. Therefore, we speculate that in Barrett's patients bile acids may activate TGR5 receptors, which activate CREB and NOX5-S. NOX5-S-derived ROS may increase cell proliferation and cause DNA damage, thereby contributing to the progression from BE to EA. TGR5 might be a potential marker for the progression from BE to high-grade dysplasia and EA. In addition, we compared the expression of TGR5 in different clinical stages of EA tissues. We found that 100% stage III and IV cases showed moderate to strong staining, which was the same as stage I and II cases, indicating that the degree of TGR5 expression might not be associated with clinical stages. Moreover, TGR5 expression had no significant difference between tumors with and without lymph node metastasis, indicating that the degree of TGR5 expression may not be related to the status of lymph node metastasis. These data suggest that TGR5 may not be a marker for the prognosis of EA.

In conclusion, TGR5 immunostaining was much stronger in high-grade dysplasia and EA than in BE mucosa or low-grade dysplasia. Its staining intensity was not associated with the clinical stage, pathological stage and the status of lymph node metastasis.

ACKNOWLEDGMENTS

This work was presented in part at CAP 2015.

COMMENTS

Background

Gastroesophageal reflux disease complicated by Barrett's esophagus (BE) is a major risk factor for esophageal adenocarcinoma (EA). However, mechanisms of the progression from BE (intestinal metaplasia) to EA are not fully understood. Recent data suggest that bile acids may play an important role in the progression from BE to EA. We have previously shown that TGR5 receptors are present in EA cells and that TGR5 receptors mediate bile acid-induced increase in cell proliferation. The expression of TGR5 in EA tissues is not well understood. In this study, we examined the bile acid receptor TGR5 expression in squamous mucosa, Barrett's mucosa, dysplasia and EA by immunohistochemistry.

Research frontiers

Bile acids may contribute to the progression from BE (intestinal metaplasia) to EA. The role of a bile acid receptor TGR5 in this progression is not clear.

Innovations and breakthroughs

The expression of a bile acid receptor TGR5 at moderate to strong intensity was significantly higher in high-grade dysplasia and EA cases than in BE or in low-grade dysplasia, suggesting that TGR5 may play an important role in the progression from BE to high-grade dysplasia and EA. TGR5 might be a potential marker for this progression. However, TGR5 may not be a marker for the prognosis of EA.

Applications

TGR5 might be a potential marker for the progression from BE to EA.

Terminology

TGR5 is a G protein-coupled bile acid receptor.

Peer-review

This article is of tremendous importance in highlighting the different expression of TGR5 among different stages of EA.

REFERENCES

- 1 Blot WJ, Devesa SS, Kneller RW, Fraumeni JF. Rising incidence of adenocarcinoma of the esophagus and gastric cardia. *JAMA* 1991; **265**: 1287-1289 [PMID: 1995976 DOI: 10.1001/jama.1991.03460100089030]
- 2 Pennathur A, Gibson MK, Jobe BA, Luketich JD. Oesophageal carcinoma. *Lancet* 2013; **381**: 400-412 [PMID: 23374478]
- 3 Thrift AP, Whiteman DC. The incidence of esophageal adenocarcinoma continues to rise: analysis of period and birth cohort effects on recent trends. *Ann Oncol* 2012; **23**: 3155-3162 [PMID: 22847812 DOI: 10.1093/annonc/mds181]
- 4 Falk GW. Barrett's esophagus. *Gastroenterology* 2002; **122**: 1569-1591 [PMID: 12016424 DOI: 10.1053/gast.2002.33427]
- 5 Crane SJ, Locke GR, Harmsen WS, Zinsmeister AR, Romero Y, Talley NJ. Survival trends in patients with gastric and esophageal adenocarcinomas: a population-based study. *Mayo Clin Proc* 2008; **83**: 1087-1094 [PMID: 18828967 DOI: 10.4065/83.10.1087]
- 6 Sihvo EI, Luostarinen ME, Salo JA. Fate of patients with adenocarcinoma of the esophagus and the esophagogastric junction: a population-based analysis. *Am J Gastroenterol* 2004; **99**: 419-424 [PMID: 15056079 DOI: 10.1111/j.1572-0241.2004.04094.x]
- 7 Hur C, Miller M, Kong CY, Dowling EC, Nattinger KJ, Dunn M, Feuer EJ. Trends in esophageal adenocarcinoma incidence and mortality. *Cancer* 2013; **119**: 1149-1158 [PMID: 23303625 DOI: 10.1002/cncr.27834]
- 8 Lagergren J, Bergström R, Lindgren A, Nyrén O. Symptomatic gastroesophageal reflux as a risk factor for esophageal adenocarcinoma. *N Engl J Med* 1999; **340**: 825-831 [PMID: 10080844 DOI: 10.1056/NEJM199903183401101]
- 9 Pohl H, Wrobel K, Bojarski C, Voderholzer W, Sonnenberg A, Rösch T, Baumgart DC. Risk factors in the development of esophageal adenocarcinoma. *Am J Gastroenterol* 2013; **108**: 200-207 [PMID: 23247577 DOI: 10.1038/ajg.2012.387]
- 10 Kahrilas PJ. The problems with surveillance of Barrett's esophagus. *N Engl J Med* 2011; **365**: 1437-1438 [PMID: 21995392 DOI: 10.1056/NEJMe1108435]
- 11 Kim R, Weissfeld JL, Reynolds JC, Kuller LH. Etiology of Barrett's metaplasia and esophageal adenocarcinoma. *Cancer Epidemiol Biomarkers Prev* 1997; **6**: 369-377 [PMID: 9149898]
- 12 Haggitt RC. Barrett's esophagus, dysplasia, and adenocarcinoma. *Hum Pathol* 1994; **25**: 982-993 [PMID: 7927321 DOI: 10.1016/0046-8177(94)90057-4]
- 13 Wild CP, Hardie LJ. Reflux, Barrett's oesophagus and adenocarcinoma: burning questions. *Nat Rev Cancer* 2003; **3**: 676-684 [PMID: 12951586]
- 14 Hvid-Jensen F, Pedersen L, Drewes AM, Sørensen HT, Funch-Jensen P. Incidence of adenocarcinoma among patients with Barrett's esophagus. *N Engl J Med* 2011; **365**: 1375-1383 [PMID: 21995385 DOI: 10.1056/NEJMoa1103042]
- 15 Kauer WK, Stein HJ. Emerging concepts of bile reflux in the constellation of gastroesophageal reflux disease. *J Gastrointest Surg* 2010; **14** Suppl 1: S9-16 [PMID: 19756880 DOI: 10.1007/s11605-009-1014-4]
- 16 Jankowski JA, Anderson M. Review article: management of oesophageal adenocarcinoma -- control of acid, bile and inflammation in intervention strategies for Barrett's oesophagus. *Aliment Pharmacol Ther* 2004; **20** Suppl 5: 71-80; discussion 95-96 [PMID: 15456468 DOI: 10.1111/j.1365-2036.2004.02143.x]
- 17 Attwood SE, Smyrk TC, DeMeester TR, Mirvish SS, Stein HJ, Hinder RA. Duodeno-esophageal reflux and the development of esophageal adenocarcinoma in rats. *Surgery* 1992; **111**: 503-510 [PMID: 1598670]
- 18 Clark GW, Smyrk TC, Mirvish SS, Anselmino M, Yamashita Y, Hinder RA, DeMeester TR, Birt DF. Effect of gastroduodenal juice and dietary fat on the development of Barrett's esophagus and esophageal neoplasia: an experimental rat model. *Ann Surg Oncol* 1994; **1**: 252-261 [PMID: 7842295 DOI: 10.1007/BF02303531]
- 19 Fein M, Peters JH, Chandrasoma P, Ireland AP, Oberg S, Ritter MP, Bremner CG, Hagen JA, DeMeester TR. Duodeno-esophageal reflux induces esophageal adenocarcinoma without exogenous carcinogen. *J Gastrointest Surg* 1998; **2**: 260-268 [PMID: 9841983]
- 20 Peng S, Huo X, Rezaei D, Zhang Q, Zhang X, Yu C, Asanuma K, Cheng E, Pham TH, Wang DH, Chen M, Souza RF, Spechler SJ. In Barrett's esophagus patients and Barrett's cell lines, ursodeoxycholic acid increases antioxidant expression and prevents DNA damage by bile acids. *Am J Physiol Gastrointest Liver Physiol* 2014; **307**: G129-G139 [PMID: 24852569 DOI: 10.1152/ajpgi.00085.2014]
- 21 Looby E, Abdel-Latif MM, Athié-Morales V, Duggan S, Long A, Kelleher D. Deoxycholate induces COX-2 expression via Erk1/2-, p38-MAPK and AP-1-dependent mechanisms in esophageal cancer cells. *BMC Cancer* 2009; **9**: 190 [PMID: 19534809]
- 22 Wu J, Gong J, Geng J, Song Y. Deoxycholic acid induces the overexpression of intestinal mucin, MUC2, via NF-κB signaling pathway in human esophageal adenocarcinoma cells. *BMC Cancer* 2008; **8**: 333 [PMID: 19014523]
- 23 Das KM, Kong Y, Bajpai M, Kulkarni D, Geng X, Mishra P, Banerjee D, Hirshfield K. Transformation of benign Barrett's epithelium by repeated acid and bile exposure over 65 weeks: a novel in vitro model. *Int J Cancer* 2011; **128**: 274-282 [PMID: 20309934 DOI: 10.1002/ijc.25343]
- 24 Kawamata Y, Fujii R, Hosoya M, Harada M, Yoshida H, Miwa M, Fukusumi S, Habata Y, Itoh T, Shintani Y, Hinuma S, Fujisawa Y, Fujino M. A G protein-coupled receptor responsive to bile acids. *J Biol Chem* 2003; **278**: 9435-9440 [PMID: 12524422 DOI: 10.1074/jbc.M209706200]
- 25 Keitel V, Donner M, Winandy S, Kubitz R, Häussinger D. Expression and function of the bile acid receptor TGR5 in Kupffer cells. *Biochem Biophys Res Commun* 2008; **372**: 78-84 [PMID: 18468513 DOI: 10.1016/j.bbrc.2008.04.171]
- 26 Yang JI, Yoon JH, Myung SJ, Gwak GY, Kim W, Chung GE, Lee SH, Lee SM, Kim CY, Lee HS. Bile acid-induced TGR5-dependent c-Jun-N terminal kinase activation leads to enhanced caspase 8 activation in hepatocytes. *Biochem Biophys Res Commun* 2007; **361**: 156-161 [PMID: 17659258 DOI: 10.1016/j.bbrc.2007.07.001]
- 27 Carino A, Graziosi L, D'Amore C, Cipriani S, Marchianò S, Marino E, Zampella A, Rende M, Mosci P, Distrutti E, Donini A, Fiorucci S. The bile acid receptor GPBAR1 (TGR5) is expressed in human gastric cancers and promotes epithelial-mesenchymal transition in gastric cancer cell lines. *Oncotarget* 2016; **7**: 61021-61035 [PMID: 27409173 DOI: 10.18632/oncotarget.10477]
- 28 Reich M, Deutschmann K, Sommerfeld A, Klindt C, Kluge S, Kubitz R, Ullmer C, Knoefel WT, Herebian D, Mayatepek E, Häussinger D, Keitel V. TGR5 is essential for bile acid-dependent cholangiocyte proliferation in vivo and in vitro. *Gut* 2016; **65**: 487-501 [PMID: 26420419 DOI: 10.1136/gutjnl-2015-309458]
- 29 Hong J, Behar J, Wands J, Resnick M, Wang LJ, DeLellis RA, Lambeth D, Souza RF, Spechler SJ, Cao W. Role of a novel bile acid receptor TGR5 in the development of oesophageal adenocarcinoma. *Gut* 2010; **59**: 170-180 [PMID: 19926617]
- 30 American-Joint-Committee-on-Cancer. AJCC Cancer Staging Manual. 7th ed. New York: Springer 2010: 117-121
- 31 Cao W, Tian W, Hong J, Li D, Tavares R, Noble L, Moss SF, Resnick MB. Expression of bile acid receptor TGR5 in gastric adenocarcinoma. *Am J Physiol Gastrointest Liver Physiol* 2013; **304**: G322-G327 [PMID: 23238937]

- 32 **Hong J**, Li D, Wands J, Souza R, Cao W. Role of NADPH oxidase NOX5-S, NF- κ B, and DNMT1 in acid-induced p16 hypermethylation in Barrett's cells. *Am J Physiol Cell Physiol* 2013; **305**: C1069-C1079 [PMID: 24025864 DOI: 10.1152/ajpcell.00080.2013]
- 33 **Hong J**, Li D, Cao W. Rho Kinase ROCK2 Mediates Acid-Induced NADPH Oxidase NOX5-S Expression in Human Esophageal Adenocarcinoma Cells. *PLoS One* 2016; **11**: e0149735 [PMID: 26901778 DOI: 10.1371/journal.pone.0149735]
- 34 **Souza RF**, Morales CP, Spechler SJ. Review article: a conceptual approach to understanding the molecular mechanisms of cancer development in Barrett's oesophagus. *Aliment Pharmacol Ther* 2001; **15**: 1087-1100 [PMID: 11472311 DOI: 10.1046/j.1365-2036.2001.01046.x]
- 35 **Li D**, Cao W. Bile acid receptor TGR5, NADPH Oxidase NOX5-S and CREB Mediate Bile Acid-Induced DNA Damage In Barrett's Esophageal Adenocarcinoma Cells. *Sci Rep* 2016; **6**: 31538 [PMID: 27511066 DOI: 10.1038/srep31538]

P- Reviewer: Dar NA **S- Editor:** Qi Y **L- Editor:** A
E- Editor: Zhang FF





Published by **Baishideng Publishing Group Inc**

8226 Regency Drive, Pleasanton, CA 94588, USA

Telephone: +1-925-223-8242

Fax: +1-925-223-8243

E-mail: bpgoffice@wjgnet.com

Help Desk: <http://www.wjgnet.com/esps/helpdesk.aspx>

<http://www.wjgnet.com>



ISSN 1007-9327



9 771007 932045