

## Bevacizumab and gastrointestinal bleeding in hereditary hemorrhagic telangiectasia

George Ou, Cherry Galorport, Robert Enns

George Ou, Cherry Galorport, Robert Enns, Division of Gastroenterology, Department of Medicine, St. Paul's Hospital, University of British Columbia, Vancouver, BC V6Z 1Y6, Canada

**Author contributions:** Ou G, Galorport C and Enns R designed the report and drafted the article; Ou G and Galorport C collected the data; Ou G and Enns R drafted the manuscript; all authors contributed to the critical revision and final approval of the manuscript.

**Institutional review board statement:** Not applicable (Ethics approval not required for single case report as per University of British Columbia Research Ethics Board).

**Informed consent statement:** The patient provided written informed consent prior to participation in this case report.

**Conflict-of-interest statement:** The authors have no conflict of interest to declare.

**Open-Access:** This article is an open-access article which was selected by an in-house editor and fully peer-reviewed by external reviewers. It is distributed in accordance with the Creative Commons Attribution Non Commercial (CC BY-NC 4.0) license, which permits others to distribute, remix, adapt, build upon this work non-commercially, and license their derivative works on different terms, provided the original work is properly cited and the use is non-commercial. See: <http://creativecommons.org/licenses/by-nc/4.0/>

**Manuscript source:** Unsolicited manuscript

**Correspondence to:** Robert Enns, MD, FRCPC, Division of Gastroenterology, Department of Medicine, St. Paul's Hospital, University of British Columbia, Suite 770 - 1190 Hornby Street, Vancouver, BC V6Z 1Y6, Canada. [rob.enns@ubc.ca](mailto:rob.enns@ubc.ca)  
Telephone: +1-604-6886332-222  
Fax: +1-604-6892004

Received: August 4, 2016

Peer-review started: August 5, 2016

First decision: August 26, 2016

Revised: September 7, 2016

Accepted: October 17, 2016

Article in press: October 18, 2016

Published online: December 27, 2016

### Abstract

We report a case of severe, refractory gastrointestinal (GI) bleeding in a patient with hereditary hemorrhagic telangiectasia (HHT) whose massive transfusion dependence was lifted shortly after treatment with bevacizumab, an anti-vascular endothelial growth factor. The patient's bleeding had been refractory to repeated endoscopic interventions, tranexamic acid, and tamoxifen. However, following treatment with bevacizumab at 5 mg/kg every other week, nearly 300 units of packed red blood cell transfusions were avoided in one year's time. Despite its relatively high cost, bevacizumab may have a more active role in the management of severe GI bleeding in HHT if such remarkable response can be consistently demonstrated.

**Key words:** Bevacizumab; Vascular endothelial growth factor; Hereditary hemorrhagic telangiectasia; Bleeding; Osler-Weber-Rendu syndrome

© The Author(s) 2016. Published by Baishideng Publishing Group Inc. All rights reserved.

**Core tip:** Management of gastrointestinal (GI) bleeding in patients with hereditary hemorrhagic telangiectasia (HHT) can be challenging when the vascular lesions recur despite repeated endoscopic treatments. There is increasing evidence supporting the use of anti-angiogenesis agents in the management of bleeding in HHT patients. Bevacizumab, a monoclonal antibody against vascular endothelial growth factor, has been shown to reduce recurrent epistaxis. This case demonstrates the therapeutic potential of bevacizumab in patients with severe GI bleeding requiring massive transfusions.

Ou G, Galorport C, Enns R. Bevacizumab and gastrointestinal

bleeding in hereditary hemorrhagic telangiectasia. *World J Gastrointest Surg* 2016; 8(12): 792-795 Available from: URL: <http://www.wjgnet.com/1948-9366/full/v8/i12/792.htm> DOI: <http://dx.doi.org/10.4240/wjgs.v8.i12.792>

## INTRODUCTION

Hereditary hemorrhagic telangiectasia (HHT) is an autosomal dominant condition characterized by vascular malformations that occur systemically, leading to manifestations such as recurrent epistaxis, gastrointestinal (GI) bleeding, and arteriovenous malformations (AVM) of the lung, liver, and brain. Since the discovery of elevated vascular endothelial growth factor (VEGF) expression in patients with HHT<sup>[1]</sup>, reports of bevacizumab, a monoclonal antibody against VEGF, in managing complications of HHT have emerged<sup>[2-16]</sup>, with most of the reported experience in recurrent epistaxis. We present a case of HHT with massive, refractory transfusion requirements secondary to severe GI bleeding that did not respond to conventional therapy, but subsequently achieved transfusion-independence with anti-VEGF mono-therapy.

## CASE REPORT

A 58-year-old female with HHT and positive family history, involving her mother, sister, and daughter, presents with a 30-plus-year history of increasing transfusion dependency due to a combination of daily epistaxis, gastrointestinal bleeding, and intermittent gross hematuria. She did not have hemoptysis. Relevant medical history included hepatitis C infection secondary to transfusions, pulmonary hypertension from high-output cardiac failure secondary to chronic severe anemia, pulmonary AVMs with previous embolizations, and hysterectomy at the age of 26 for menorrhagia.

Her initial transfusion requirement was approximately one unit of packed red blood cells (pRBC) per month, but as of 2003 required > 40 units per year due to persistent epistaxis and increasing upper GI bleeding in the form of melena. Capsule endoscopies and upper endoscopies demonstrated innumerable AVMs in the esophagus, stomach, duodenum, and jejunum, with the bulk of the lesions located in the proximal small bowel where active bleeding was most frequently seen. Mesenteric angiography also demonstrated diffuse vascular abnormality/telangiectasia involving proximal small bowel but no focal AVM amenable to embolization. Biochemical investigations excluding other etiologies included normal renal function, thyroid stimulating hormone, haptoglobin, bilirubin, lactate dehydrogenase, direct agglutination testing, serum protein electrophoresis, serum free light chain, urine protein electrophoresis, and von Willebrand factor studies. Her hepatitis C viral load was low and abdominal ultrasound did not demonstrate cirrhosis.

Her transfusion requirement further escalated despite successful interventions including multiple septal

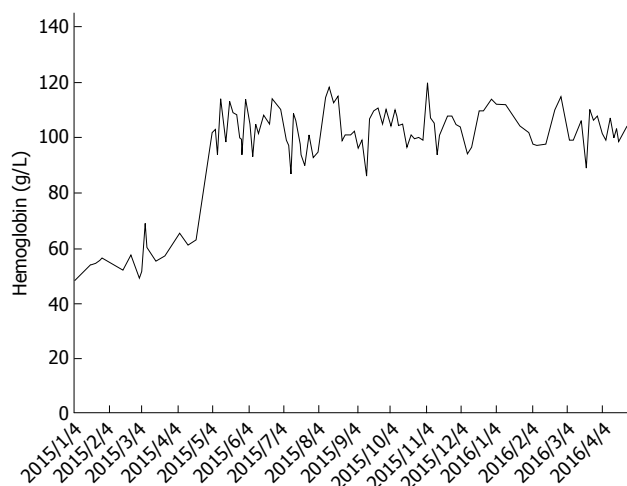
dermatoplasties and facial/nasal vessel angiography with embolization. At least seven upper endoscopies with argon plasma coagulation, two-month tamoxifen therapy, and tranexamic acid which led to upper extremity deep vein thrombosis, were used for ongoing bleeding from the duodenum/proximal jejunum. She received neither estrogen therapy nor thalidomide due to risk of hormone-sensitive malignancy and limited access/financial constraint, respectively. Additionally, her advanced cardiopulmonary comorbidities, which were complications of HHT, precluded surgical resection of the proximal small bowel (*i.e.*, Whipple procedure) containing the majority of the vascular lesions in order to reduce GI bleeding. Between 2008 and 2015, she received on average six units of pRBC weekly (*i.e.*, 312 unit per year) as well as monthly intravenous iron infusion.

In April 2015, she was started on bevacizumab, an anti-VEGF antibody, at 5 mg/kg every two weeks as a last resort. The patient's response to bevacizumab in terms of GI bleeding was immediate and dramatic: Her stools returned to normal color and consistency, and her transfusion requirement dropped to four units per month between May and September, and further down to only two units over the course of the following seven months with intravenous iron supplementation (Figure 1). She continued to experience minor epistaxis that was much less severe than previous, and ongoing microscopic hematuria without proteinuria or renal function impairment.

Over the past 12 mo, the administration of bevacizumab has resulted in a decrease of approximately 290 units of pRBC's and improved the patient's quality of life immensely. The patient has tolerated the infusions without any reported side-effects.

## DISCUSSION

This case highlights the potential challenges in managing HHT with complicated, refractory GI bleeding. In our patient's case, she acquired hepatitis C infection due to repeated transfusions, and developed high-output cardiac failure and pulmonary hypertension due to severe chronic anemia. Her functional capacity was poor due to anemia and pulmonary hypertension, but the need for frequent transfusions three times a week (> 1400 units of pRBC in the five years prior to treatment) also posed a tremendous negative impact on her quality of life in addition to causing a significant burden on the health care system. Fortunately, the patient's response to bevacizumab exceeded our expectations. The greatest hurdle of obtaining the drug was in fact, obtaining approval from regulatory bodies for financial coverage of it. However, after one year, the overall cost to the health care system of avoiding most transfusions is staggering. Given the severity of her blood loss, which to our knowledge is one of the most severe cases reported, our initial goal had been to reduce her transfusion requirement by 40%-50%, but she essentially became transfusion-independent.



**Figure 1 Hemoglobin trend.** Hemoglobin trend before and after initiation of bevacizumab 5 mg/kg every other week starting in April 2015.

We opted to prescribe 5 mg/kg every other week, which is the typical dose for solid organ malignancies, since this is the regimen with the most clinical evidence to date for HHT<sup>[17]</sup>. The optimal dosage and duration of bevacizumab for GI bleeding in HHT remains to be determined, and requires balancing the clinical benefits against potential adverse events of systemic treatment such as hypertension, nephrotic syndrome, poor wound healing, bowel perforation, and thromboembolic events<sup>[18]</sup>. There have been reports successfully utilizing lower doses for GI bleeding, based on the drug's pharmacokinetics<sup>[4,5,7,15]</sup>, but some patients may require higher doses to maintain optimal response<sup>[10]</sup>. Although the specific optimal dosage is not entirely clear at this time, the duration of treatment is likely indefinite as relapses upon discontinuation of therapy have been noted in previous reports, with the interval ranging from one to three months after the last dose<sup>[4,7,8,15]</sup>.

This case demonstrates a remarkable response in regards to GI bleeding to bevacizumab in the setting of HHT. Although not specifically examined yet in our patient, additional benefits such as partial reversal of liver failure and high-output cardiac failure have also been reported<sup>[19-21]</sup>. Despite its high cost, earlier administration should be considered if benefit of this extent is regularly demonstrated in this group of patients as prevention of end organ complications (*i.e.*, cardiac/hepatic) theoretically might have been prevented with early administration. The issue of cost in many situations perhaps should not be paramount when aiming for ideal care in these patients with limited options.

Bevacizumab effectively controlled severe GI bleeding in this patient with complicated HHT.

## COMMENTS

### Case characteristics

A 58-year-old woman with hereditary hemorrhagic telangiectasia (HHT) presented with severe, chronic gastrointestinal (GI) bleeding refractory to multiple treatment modalities.

### Clinical diagnosis

Endoscopies demonstrated numerous arteriovenous malformations in the esophagus, stomach, duodenum, and jejunum. The majority of the lesions were located in the proximal small bowel where active bleeding was frequently seen.

### Differential diagnosis

Vascular lesions of GI tract: Angiodysplasia (sporadic, end-stage renal disease, aortic stenosis, von Willebrand disease, left ventricular assist device), systemic disease (CREST, HHT).

### Laboratory diagnosis

Biochemical investigations included normal renal function, thyroid stimulating hormone, haptoglobin, bilirubin, lactate dehydrogenase, direct agglutination testing, serum protein electrophoresis, serum free light chain, urine protein electrophoresis, and von Willebrand factor studies. Pre-bevacizumab mean hemoglobin was  $57.2 \pm 5.8$  g/dL. Post-bevacizumab hemoglobin was  $103.4 \pm 8.3$  g/dL.

### Imaging diagnosis

Mesenteric angiography did not identify suitable arteriovenous malformation that was amenable to treatment via embolization of the gastroduodenal artery.

### Treatment

Bevacizumab 5 mg/kg infusion every other week.

### Related reports

There is growing evidence in the literature on bevacizumab's efficacy in treating recurrent epistaxis due to HHT, but relatively few reports exist for the management of severe, chronic, refractory GI bleeding. This case highlights the potential utility of bevacizumab for such management.

### Term explanation

HHT is an autosomal dominant condition characterized by vascular malformations that can occur anywhere in the body, leading to various presentations including epistaxis, GI bleeding, high-output cardiac failure, and hypoxemia.

### Experiences and lessons

Earlier administration of bevacizumab should be considered in patients with severe, refractory GI bleeding despite its relatively high cost given the potential benefit.

### Peer-review

This is a pretty straightforward case report.

## REFERENCES

- 1 **Sadick H**, Riedel F, Naim R, Goessler U, Hörmann K, Hafner M, Lux A. Patients with hereditary hemorrhagic telangiectasia have increased plasma levels of vascular endothelial growth factor and transforming growth factor-beta1 as well as high ALK1 tissue expression. *Haematologica* 2005; **90**: 818-828 [PMID: 15951295]
- 2 **Wee JW**, Jeon YW, Eun JY, Kim HJ, Bae SB, Lee KT. Hereditary hemorrhagic telangiectasia treated with low dose intravenous bevacizumab. *Blood Res* 2014; **49**: 192-195 [PMID: 25325040 DOI: 10.5045/br.2014.49.3.192]
- 3 **Thompson AB**, Ross DA, Berard P, Figueroa-Bodine J, Livada N, Richer SL. Very low dose bevacizumab for the treatment of epistaxis in patients with hereditary hemorrhagic telangiectasia. *Allergy Rhinol (Providence)* 2014; **5**: 91-95 [PMID: 25199101 DOI: 10.2500/ar.2014.5.0091]
- 4 **Suppressa P**, Liso A, Sabbà C. Low dose intravenous bevacizumab for the treatment of anaemia in hereditary haemorrhagic telangiectasia. *Br J Haematol* 2011; **152**: 365 [PMID: 21265821 DOI: 10.1111/j.1365-2141.2010.08481.x]
- 5 **Sehl ME**, M Gruber T, McWilliams JP, Marder VJ. Successful management of chronic gastrointestinal hemorrhage using beva-

- cizumab in the setting of hereditary hemorrhagic telangiectasia. *Am J Hematol* 2015; **90**: 561-563 [PMID: 25677911 DOI: 10.1002/ajh.23969]
- 6 **Lazaraki G**, Akriviadis E, Pilpilidis I, Parisi I, Tzilves D, Tarpangos A. Low dose of bevacizumab is safe and effective in preventing bleeding episodes in hereditary hemorrhagic telangiectasia. *Am J Gastroenterol* 2011; **106**: 2204-2206 [PMID: 22138950 DOI: 10.1038/ajg.2011.287]
  - 7 **Kochanowski J**, Sobieszczńska M, Tubek S, Żurek M, Pawelczak J. Successful therapy with bevacizumab in a case of hereditary hemorrhagic telangiectasia. *Hum Vaccin Immunother* 2015; **11**: 680-681 [PMID: 25839219 DOI: 10.1080/21645515.2015.1011960]
  - 8 **Fodstad P**, Dheyauldeen S, Rinde M, Bachmann-Harildstad G. Anti-VEGF with 3-week intervals is effective on anemia in a patient with severe hereditary hemorrhagic telangiectasia. *Ann Hematol* 2011; **90**: 611-612 [PMID: 20824275 DOI: 10.1007/s00277-010-1063-5]
  - 9 **Flieger D**, Hainke S, Fischbach W. Dramatic improvement in hereditary hemorrhagic telangiectasia after treatment with the vascular endothelial growth factor (VEGF) antagonist bevacizumab. *Ann Hematol* 2006; **85**: 631-632 [PMID: 16807748 DOI: 10.1007/s00277-006-0147-8]
  - 10 **Epperla N**, Hocking W. Blessing for the bleeder: bevacizumab in hereditary hemorrhagic telangiectasia. *Clin Med Res* 2015; **13**: 32-35 [PMID: 24667223 DOI: 10.3121/cm.2013.1205]
  - 11 **Brinkerhoff BT**, Poetker DM, Choong NW. Long-term therapy with bevacizumab in hereditary hemorrhagic telangiectasia. *N Engl J Med* 2011; **364**: 688-689 [PMID: 21323562 DOI: 10.1056/NEJMc1012774]
  - 12 **Brinkerhoff BT**, Choong NW, Treisman JS, Poetker DM. Intravenous and topical intranasal bevacizumab (Avastin) in hereditary hemorrhagic telangiectasia. *Am J Otolaryngol* 2012; **33**: 349-351 [PMID: 21917353 DOI: 10.1016/j.amjoto.2011.07.012]
  - 13 **Bose P**, Holter JL, Selby GB. Bevacizumab in hereditary hemorrhagic telangiectasia. *N Engl J Med* 2009; **360**: 2143-2144 [PMID: 19439755 DOI: 10.1056/NEJMc0901421]
  - 14 **Amanzada A**, Töppler GJ, Cameron S, Schwörer H, Ramadori G. A case report of a patient with hereditary hemorrhagic telangiectasia treated successively with thalidomide and bevacizumab. *Case Rep Oncol* 2010; **3**: 463-470 [PMID: 21611144 DOI: 10.1159/000323152]
  - 15 **Lupu A**, Stefanescu C, Treton X, Attar A, Corcos O, Bouhnik Y. Bevacizumab as rescue treatment for severe recurrent gastrointestinal bleeding in hereditary hemorrhagic telangiectasia. *J Clin Gastroenterol* 2013; **47**: 256-257 [PMID: 23164683 DOI: 10.1097/MCG.0b013e3182688d49]
  - 16 **Amann A**, Steiner N, Gunsilius E. Bevacizumab: an option for refractory epistaxis in hereditary haemorrhagic telangiectasia. *Wien Klin Wochenschr* 2015; **127**: 631-634 [PMID: 25986996 DOI: 10.1007/s00508-015-0789-4]
  - 17 **Arizmendez NP**, Rudmik L, Poetker DM. Intravenous bevacizumab for complications of hereditary hemorrhagic telangiectasia: a review of the literature. *Int Forum Allergy Rhinol* 2015; **5**: 1042-1047 [PMID: 26202958 DOI: 10.1002/alr.21587]
  - 18 **Cohen MH**, Gootenberg J, Keegan P, Pazdur R. FDA drug approval summary: bevacizumab (Avastin) plus Carboplatin and Paclitaxel as first-line treatment of advanced/metastatic recurrent nonsquamous non-small cell lung cancer. *Oncologist* 2007; **12**: 713-718 [PMID: 17602060 DOI: 10.1634/theoncologist.12-6-713]
  - 19 **Vlachou PA**, Colak E, Koculym A, Kirpalani A, Kim TK, Hirschfield GM, Faughnan ME. Improvement of ischemic cholangiopathy in three patients with hereditary hemorrhagic telangiectasia following treatment with bevacizumab. *J Hepatol* 2013; **59**: 186-189 [PMID: 23439260 DOI: 10.1016/j.jhep.2013.02.006]
  - 20 **Dupuis-Girod S**, Ginon I, Saurin JC, Marion D, Guillot E, Decullier E, Roux A, Carette MF, Gilbert-Dussardier B, Hatron PY, Lacombe P, Lorcerie B, Rivière S, Corre R, Giraud S, Bailly S, Paintaud G, Ternant D, Valette PJ, Plauchu H, Faure F. Bevacizumab in patients with hereditary hemorrhagic telangiectasia and severe hepatic vascular malformations and high cardiac output. *JAMA* 2012; **307**: 948-955 [PMID: 22396517 DOI: 10.1001/jama.2012.250]
  - 21 **Mitchell A**, Adams LA, MacQuillan G, Tibballs J, vanden Driesen R, Delriviere L. Bevacizumab reverses need for liver transplantation in hereditary hemorrhagic telangiectasia. *Liver Transpl* 2008; **14**: 210-213 [PMID: 18236396 DOI: 10.1002/lt.21417]

P- Reviewer: Field K S- Editor: Qi Y L- Editor: A  
E- Editor: Li D





Published by **Baishideng Publishing Group Inc**

8226 Regency Drive, Pleasanton, CA 94588, USA

Telephone: +1-925-223-8242

Fax: +1-925-223-8243

E-mail: [bpgoffice@wjgnet.com](mailto:bpgoffice@wjgnet.com)

Help Desk: <http://www.wjgnet.com/esps/helpdesk.aspx>

<http://www.wjgnet.com>

