

## Complete response with sorafenib and transcatheter arterial chemoembolization in unresectable hepatocellular carcinoma

Michitoshi Takano, Takashi Kokudo, Yoshihiro Miyazaki, Yumiko Kageyama, Amane Takahashi, Katsumi Amikura, Hirohiko Sakamoto

Michitoshi Takano, Takashi Kokudo, Yoshihiro Miyazaki, Yumiko Kageyama, Amane Takahashi, Katsumi Amikura, Hirohiko Sakamoto, Division of gastroenterological surgery, Saitama Cancer Center, Kitaadachi-gun, Saitama 362-0806, Japan

**Author contributions:** Takano M wrote the original manuscript; all authors participated in drafting and editing the manuscript; all authors read and approved the final manuscript.

**Institutional review board statement:** The study was reviewed and approved by the Saitama Cancer Center Institutional Review Board.

**Informed consent statement:** The patient has provided informed consent for the publication of this case report and accompanying images.

**Conflict-of-interest statement:** The authors declare that they have no competing interests.

**Open-Access:** This article is an open-access article which was selected by an in-house editor and fully peer-reviewed by external reviewers. It is distributed in accordance with the Creative Commons Attribution Non Commercial (CC BY-NC 4.0) license, which permits others to distribute, remix, adapt, build upon this work non-commercially, and license their derivative works on different terms, provided the original work is properly cited and the use is non-commercial. See: <http://creativecommons.org/licenses/by-nc/4.0/>

**Manuscript source:** Unsolicited manuscript

**Correspondence to:** Michitoshi Takano, MD, Division of gastroenterological surgery, Saitama Cancer Center, 780 Komuro, Ina-machi, Kitaadachi-gun, Saitama 362-0806, Japan. [michitaka1983@gmail.com](mailto:michitaka1983@gmail.com)  
Telephone: +81-48-7221111  
Fax: +81-48-7221129

Received: July 20, 2016

Peer-review started: July 22, 2016

First decision: July 21, 2016

Revised: August 11, 2016

Accepted: August 23, 2016

Article in press: August 23, 2016

Published online: November 14, 2016

### Abstract

Patients with advanced hepatocellular carcinoma (HCC) showing portal vein tumor thrombosis (PVTT) have an extremely poor prognosis. According to treatment guidelines, the only option for HCC patients with PVTT is sorafenib chemotherapy. However, in Asia, various treatments have been attempted and possible prolongation of overall survival has been repeatedly reported. We herein report the first case of a patient with an initially unresectable advanced HCC with PVTT who underwent curative hepatectomy after sorafenib and transcatheter arterial chemoembolization (TACE) showing complete histological response. Two months after induction with sorafenib, a significant decrease in serum alpha-fetoprotein level was observed and computed tomography imaging showed a significant decrease in tumor size. Because of remaining PVTT, TACE and curative resection were performed. The combination of sorafenib and TACE may be an effective treatment for HCC patients with PVTT.

**Key words:** Hepatocellular carcinoma; Sorafenib; Complete response; Portal vein tumor thrombosis; Transcatheter arterial chemoembolization

© **The Author(s) 2016.** Published by Baishideng Publishing Group Inc. All rights reserved.

**Core tip:** Patients with advanced hepatocellular carcinoma (HCC) showing portal vein tumor thrombosis (PVTT) have an extremely poor prognosis. The only proposed treatment option for HCC patients with PVTT is sorafenib chemotherapy. However, in Asia, various treatments have been attempted and possible prolongation of overall survival has been repeatedly reported. Here we report the first case of a patient with an initially unresectable advanced HCC and PVTT who underwent curative hepatectomy after sorafenib and transcatheter arterial chemoembolization (TACE) showing complete histological response. The combination of sorafenib and TACE may be an effective treatment for HCC patients with PVTT.

Takano M, Kokudo T, Miyazaki Y, Kageyama Y, Takahashi A, Amikura K, Sakamoto H. Complete response with sorafenib and transcatheter arterial chemoembolization in unresectable hepatocellular carcinoma. *World J Gastroenterol* 2016; 22(42): 9445-9450 Available from: URL: <http://www.wjgnet.com/1007-9327/full/v22/i42/9445.htm> DOI: <http://dx.doi.org/10.3748/wjg.v22.i42.9445>

## INTRODUCTION

Patients with advanced hepatocellular carcinoma (HCC) showing portal vein tumor thrombosis (PVTT) have an extremely poor prognosis<sup>[1,2]</sup>. The median survival of untreated HCC with PVTT has been reported to be 2.7-6 mo<sup>[2,3]</sup>. According to the American Association for the Study of the Liver Disease/Barcelona Clinic for Liver Cancer Staging System and treatment guidelines, the only proposed treatment option for HCC patients with PVTT is sorafenib chemotherapy<sup>[4]</sup>. In Asia, various treatments including hepatectomy and transcatheter arterial chemoembolization (TACE) have been attempted and possible prolongation of overall survival (OS) has been repeatedly reported<sup>[5]</sup>. We herein report the first case of a patient with an initially unresectable advanced HCC with PVTT who underwent curative hepatectomy after sorafenib and TACE, showing complete histological response.

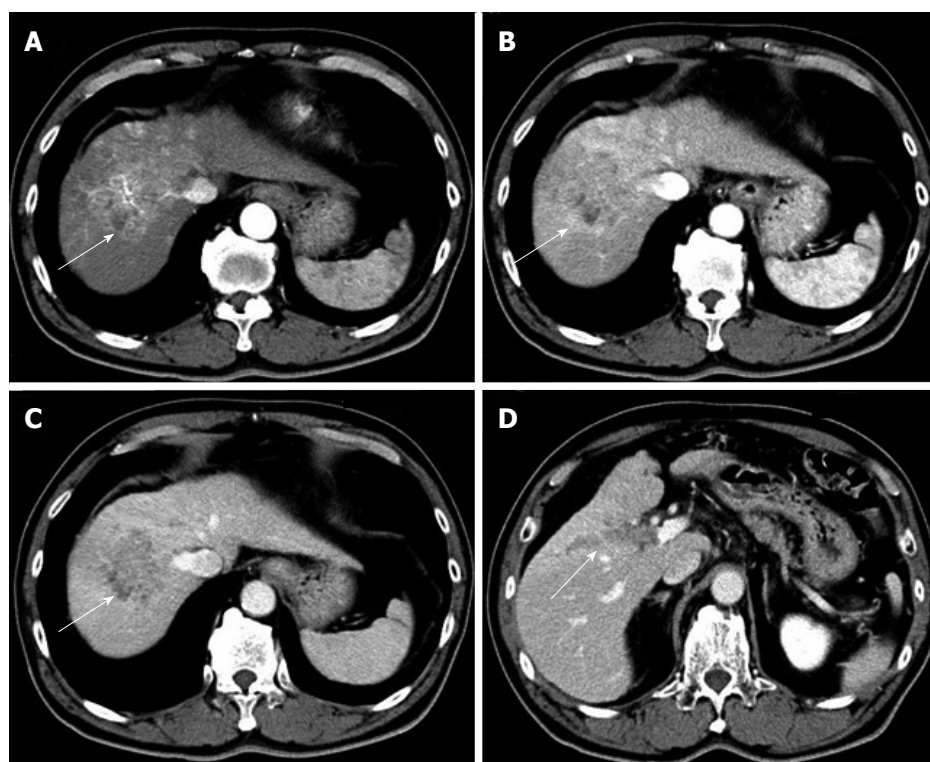
## CASE REPORT

A 67-year-old man was diagnosed with HCC through abdominal ultrasound during examination for elevated liver enzymes by his family doctor and was referred to our hospital. The patient had no history of alcohol abuse, hepatitis B or C infection. Serum  $\alpha$ -fetoprotein (AFP) level and protein induced by vitamin K absence or antagonist-II level were 1736 ng/mL (normal range: < 10 ng/mL) and 15388 mAU/mL (normal range: < 40 mAU/mL), respectively. Contrast-enhanced computed tomography (CT) scan revealed the presence of an 8.7 cm  $\times$  6 cm tumor in the right paramedian sector,

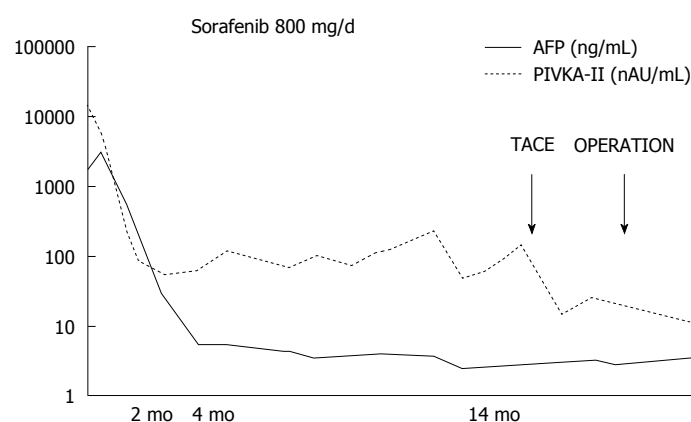
showing early enhancement in the arterial phase and wash-out in the late phase together with PVTT limited to the first-order branch and invading the right portal vein (Figure 1). Right hepatectomy was considered to be necessary for curative resection. Although the patient's liver function was Child-Pugh A, the patient's indocyanine green retention rate at 15 min was 21% (normal range; < 10%) and right hepatectomy was considered to be intolerable according to our institutional criteria<sup>[6]</sup>. Therefore, sorafenib was orally administered twice daily at a dose of 800 mg. During sorafenib treatment, the patient had no adverse event. Two months later, a significant decrease in serum AFP level was observed (195 ng/mL) (Figure 2). The CT scan showed a significant decrease in tumor size (3 cm); however, PVTT remained in the right portal vein (Figure 3). Four months later, serum AFP level decreased to within normal range (4.5 mg/mL), and 14 months later, CT scan revealed the residual PVTT in right portal vein (Figure 4). Portography revealed filling defect in S8 and digital subtraction arteriography showed irregular shaped tumor stain. Thus TACE was performed with 30 mg of miripulatin, 3 mL of lipiodol and gelatin sponge particle (Figure 5), followed by right paramedian sectionectomy. During the operation, neither the main tumor nor the PVTT was identified through intraoperative ultrasound. The operation time was 318 min and the estimated blood loss was 762 mL. The patient's postoperative course was uneventful, and he was discharged from hospital on postoperative day 11. Pathological examination revealed complete necrosis without viable tumor cells both in the scar of PVTT and the main tumor. To date, no recurrence has been observed after 12 mo of follow-up.

## DISCUSSION

Sorafenib has been reported to prolong survival in patients with unresectable or advanced HCC; however, complete response (CR) was not achieved in these reports<sup>[4,7,8]</sup>. In Asian countries, including Japan, liver resection and TACE have been reported to improve the prognosis of patients with HCC with PVTT. In the presence of PVTT, TACE is theoretically contraindicated in Western countries because of the potential risk of hepatic insufficiency that results from ischemia following TACE. However, recent studies demonstrate that TACE can be safely performed in the presence of adequate collateral circulation around the occluded portal vein<sup>[9,10]</sup>. A median OS period after treatment with TACE was reported to be 5.6-16.5 mo in patients with HCC accompanied by PVTT<sup>[11-13]</sup>. A median OS period after treatment with surgery was reported to be 6-19.9 mo<sup>[14-16]</sup>. Furthermore, Minagawa *et al.*<sup>[16]</sup> reported a high survival rate in these patients with the combination of TACE followed by hepatic resection. In the very recent paper, liver resection is associated with prolongation of overall survival of HCC with PVTT<sup>[13]</sup>.



**Figure 1** Contrast-enhanced computed tomography before sorafenib introduction. Heterogeneous hypervascularized tumor (A-C, arrow) in the right paramedian sector, showing early enhancement in the arterial phase and wash-out in the late phase together with portal vein tumor thrombosis (D, arrow) limited to the first-order branch and invading the right portal vein.

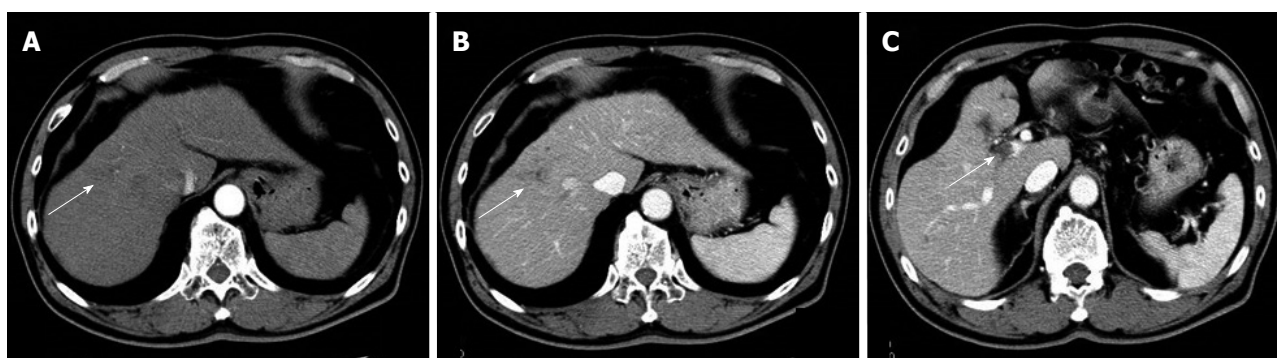


**Figure 2** Clinical course as assessed by tumor markers and therapeutic events. AFP:  $\alpha$ -fetoprotein; PIVKA-II: Vitamin K absence or antagonist-II; TACE: Transcatheter arterial chemoembolization.

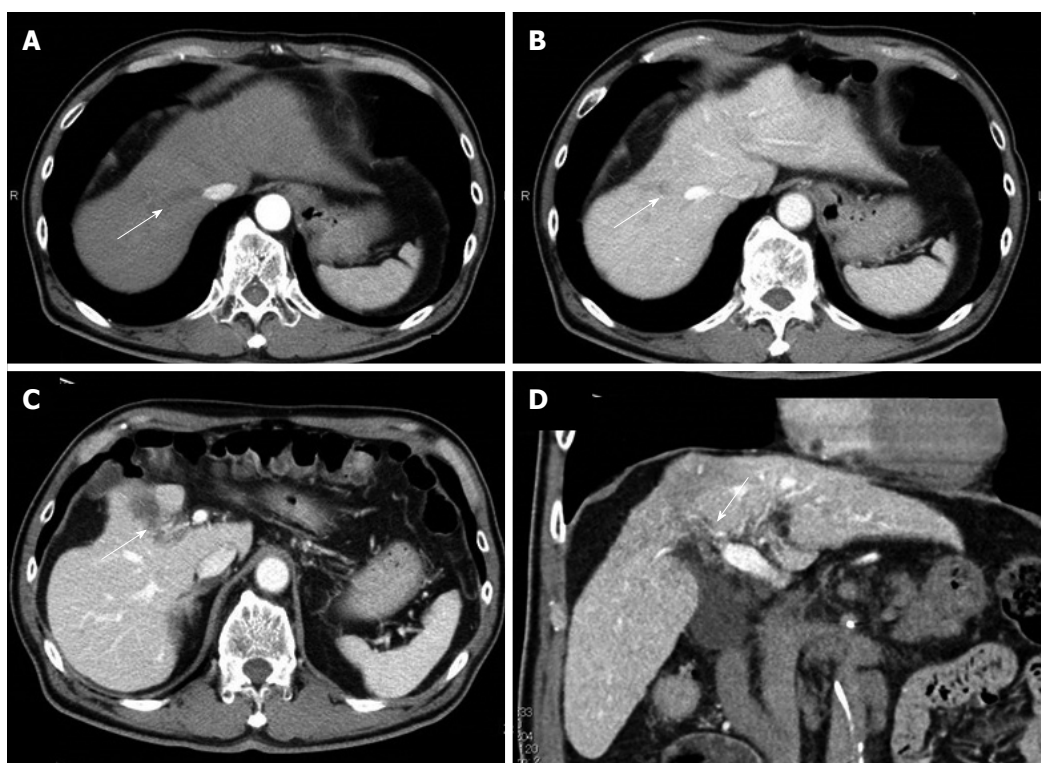
Thus, TACE and surgery are the common choices of the treatment for HCC in Japan. Anticoagulants (e.g., low molecular weight heparin, warfarin and oral anticoagulant) has been reported to be effective for portal vein thrombosis<sup>[17]</sup>. However, evidence is limited concerning the effect of anticoagulants other than anti-cancer treatment for PVTT. After treatment of HCC with PVTT with sorafenib, an OS period of 6.2-12.3 mo has been reported<sup>[13,18]</sup>. Although CR after sorafenib treatment is rare, to the best of our knowledge, 10 cases of HCC patients with PVTT who achieved CR after treatments including sorafenib have been reported

(Table 1)<sup>[19-27]</sup>. Four of the 10 cases underwent hepatectomy and had confirmed histological CR. Five of the 10 cases only underwent sorafenib treatment, and the other cases had other combined treatment modalities. The median time to normalized level of serum AFP was 4.5 mo (range, 2.75-6.5 mo). The median time to CR is 8 mo (range, 6-16.5 mo). All cases including ours, showed disappearance of the main tumor and PVTT. We herein report the first case of histologically confirmed CR of HCC with PVTT after sorafenib and TACE. Combination of sorafenib and TACE may be an effective treatment for HCC patients with PVTT.

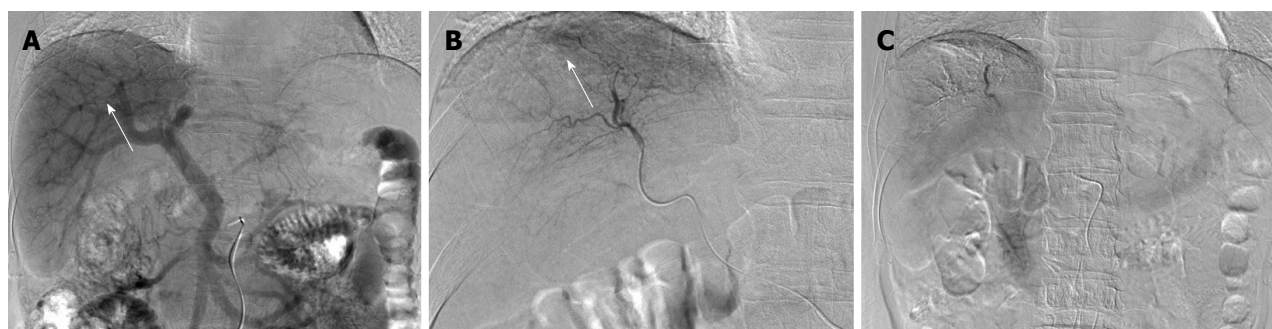



**Figure 3** Two months after sorafenib induction. Computed tomography showed the significantly decrease in size (3 cm) and hypervascularization (A and B, arrow), and portal vein tumor thrombosis remained in the second-order branch of portal vein (C, arrow).



**Figure 4** Fourteen months after sorafenib induction. Computed tomography revealed the tumor disappearance (A and B, arrow) and the residual portal vein tumor thrombosis (C and D, arrow) in the right anterior portal vein.



**Figure 5** Angiography 14 mo after sorafenib induction. A: Portography revealed filling defect in S8 (arrow); B: Digital subtraction arteriography showed irregular shaped tumor stain (arrow); C: Transcatheter arterial chemoembolization was performed with 30 mg of miripulatin, 3 mL of lipiodol and gelatin sponge particle.

**Table 1** Cases of hepatocellular carcinoma patients with portal vein tumor thrombosis who achieved complete response in the literature

Age	Sex	Etiology	Extrahepatic metastasis	Pre-AFP	Post-AFP	Sorafenib dose	Duration (mo)	Time to CR (mo)	Resection	Other therapy	Follow-up period (mo)
54	Male	Hepatitis C	Lung	52347	30.2	800-400	5	5	+	EBRT	14
83	Male	None	Lung	41948	W.N.L.	800-400-200-100	34	8	-	TACE RFA	34
59	Male	Hemochromatosis	Little omentum LN	866	W.N.L.	800	6	6	+	HAI None	16
57	Male	Hepatitis B	None	17000	W.N.L.	800-400	12	12	+	None	12
74	Male	Hepatitis C	ND	3300	W.N.L.	400	8	8	-	None	24
84	ND	Hepatitis C	None	353	W.N.L.	800	12	6	-	None	12
69	Male	Hepatitis C	None	n.d.	ND	800-400-200	62	23	-	None	62
74	Male	None	ND	33058	2	800-400-200	19	19	-	None	19
68	Male	Hepatitis C	Dissemination	4773	45.7	800-400	28	24	+	None	40
48	Male	Hepatitis C	None	135835	W.N.L.	800	9	4	-	None	31
67	Male	None	None	3385	W.N.L.	800	14	14	+	TACE	26

AFP:  $\alpha$ -fetoprotein; CR: Complete response; LN: Lymph node; W.N.L.: Within normal limit; EBRT: External beam radiotherapy; TACE: Transcatheter arterial chemoembolization; RFA: Radiofrequency ablation; HAI: Hepatic arterial infusion chemotherapy; ND: Not described.

## COMMENTS

### Case characteristics

A 67-year-old man had no symptom.

### Clinical diagnosis

On physical examination, he had a palpable mass in right upper quadrant of the abdomen.

### Differential diagnosis

Hepatocellular carcinoma, metastatic liver tumor, intrahepatic cholangiocarcinoma, malignant lymphoma and liver hemangioma.

### Laboratory diagnosis

The patient had elevated hematological value for alkaline phosphatase (316 IU/L), Glutamic-oxaloacetic transaminase (80 IU/L), glutamic pyruvic transaminase (89 IU/L),  $\gamma$ -glutamyltranspeptidase (338 IU/L),  $\alpha$ -fetoprotein (1736.3 ng/mL), protein induced by vitamin K absence or antagonist-II (15388 mAU/mL).

### Imaging diagnosis

Contrast-enhanced computed tomography scan revealed the presence of an 8.7 cm  $\times$  6 cm tumor in the right paramedian sector, showing early enhancement in the arterial phase and wash-out in the late phase together with portal vein tumor thrombosis limited to the first-order branch and invading the right portal vein.

### Pathological diagnosis

Histological examination after sorafenib chemotherapy and transcatheter arterial chemoembolization showed complete necrosis without viable tumor cells both in the scar of portal vein tumor thrombosis and the main tumor.

### Treatment

The patient received a sorafenib chemotherapy and transcatheter arterial chemoembolization.

### Related reports

Sorafenib chemotherapy is associated with prolongation of overall survival of advanced hepatocellular carcinoma (HCC), compared with best supportive care. However, complete response after sorafenib treatment with or without other treatments is very rare.

### Term explanation

Portal vein tumor thrombosis is a form of venous thrombosis affecting the hepatic portal vein, caused by tumor invasion.

### Experiences and lessons

This case report presents a new choice of treatment for advanced hepatocellular carcinoma accompanying with portal vein tumor thrombosis. Combination of sorafenib and transcatheter arterial chemoembolization may be an effective treatment for HCC patients with portal vein tumor thrombosis.

### Peer-review

The authors have described a case of advanced hepatocellular carcinoma with portal vein thrombosis that showed complete response after sorafenib and transcatheter arterial chemoembolization. The article provides another choice of treatment for advanced hepatocellular carcinoma.

## REFERENCES

- Kim JM, Kwon CH, Joh JW, Park JB, Ko JS, Lee JH, Kim SJ, Park CK. The effect of alkaline phosphatase and intrahepatic metastases in large hepatocellular carcinoma. *World J Surg Oncol* 2013; **11**: 40 [PMID: 23432910 DOI: 10.1186/1477-7819-11-40]
- Llovet JM, Bustamante J, Castells A, Vilana R, Ayuso Mdel C, Sala M, Brú C, Rodés J, Bruix J. Natural history of untreated nonsurgical hepatocellular carcinoma: rationale for the design and evaluation of therapeutic trials. *Hepatology* 1999; **29**: 62-67 [PMID: 9862851]
- Villa E, Moles A, Ferretti I, Buttafoco P, Grottola A, Del Buono M, De Santis M, Manenti F. Natural history of inoperable hepatocellular carcinoma: estrogen receptors' status in the tumor is the strongest prognostic factor for survival. *Hepatology* 2000; **32**: 233-238 [PMID: 10915729]
- Forner A, Llovet JM, Bruix J. Hepatocellular carcinoma. *Lancet* 2012; **379**: 1245-1255 [PMID: 22353262 DOI: 10.1016/S0140-6736(11)61347-0]
- Shaohua L, Qiaoxuan W, Peng S, Qing L, Zhongyuan Y, Ming S, Wei W, Rongping G. Surgical Strategy for Hepatocellular Carcinoma Patients with Portal/Hepatic Vein Tumor Thrombosis. *PLoS One* 2015; **10**: e0130021 [PMID: 26076461 DOI: 10.1371/journal.pone.0130021]
- Miyagawa S, Makuuchi M, Kawasaki S, Kakazu T. Criteria for safe hepatic resection. *Am J Surg* 1995; **169**: 589-594 [PMID: 7771622]

- 7 **Llovet JM**, Ricci S, Mazzaferro V, Hilgard P, Gane E, Blanc JF, de Oliveira AC, Santoro A, Raoul JL, Forner A, Schwartz M, Porta C, Zeuzem S, Bolondi L, Greten TF, Galle PR, Seitz JF, Borbath I, Häussinger D, Giannaris T, Shan M, Moscovici M, Voliotis D, Bruix J. Sorafenib in advanced hepatocellular carcinoma. *N Engl J Med* 2008; **359**: 378-390 [PMID: 18650514 DOI: 10.1056/NEJMoa0708857]
- 8 **Cheng AL**, Kang YK, Chen Z, Tsao CJ, Qin S, Kim JS, Luo R, Feng J, Ye S, Yang TS, Xu J, Sun Y, Liang H, Liu J, Wang J, Tak WY, Pan H, Burock K, Zou J, Voliotis D, Guan Z. Efficacy and safety of sorafenib in patients in the Asia-Pacific region with advanced hepatocellular carcinoma: a phase III randomised, double-blind, placebo-controlled trial. *Lancet Oncol* 2009; **10**: 25-34 [PMID: 19095497 DOI: 10.1016/S1470-2045(08)70285-7]
- 9 **Kothary N**, Weintraub JL, Susman J, Rundback JH. Transarterial chemoembolization for primary hepatocellular carcinoma in patients at high risk. *J Vasc Interv Radiol* 2007; **18**: 1517-1526; quiz 1527 [PMID: 18057286 DOI: 10.1016/j.jvir.2007.07.035]
- 10 **Kim JH**, Yoon HK, Kim SY, Kim KM, Ko GY, Gwon DI, Sung KB. Transcatheter arterial chemoembolization vs. chemoinfusion for unresectable hepatocellular carcinoma in patients with major portal vein thrombosis. *Aliment Pharmacol Ther* 2009; **29**: 1291-1298 [PMID: 19392861 DOI: 10.1111/j.1365-2036.2009.04016.x]
- 11 **Luo J**, Guo RP, Lai EC, Zhang YJ, Lau WY, Chen MS, Shi M. Transarterial chemoembolization for unresectable hepatocellular carcinoma with portal vein tumor thrombosis: a prospective comparative study. *Ann Surg Oncol* 2011; **18**: 413-420 [PMID: 20839057 DOI: 10.1245/s10434-010-1321-8]
- 12 **Chung GE**, Lee JH, Kim HY, Hwang SY, Kim JS, Chung JW, Yoon JH, Lee HS, Kim YJ. Transarterial chemoembolization can be safely performed in patients with hepatocellular carcinoma invading the main portal vein and may improve the overall survival. *Radiology* 2011; **258**: 627-634 [PMID: 21273524 DOI: 10.1148/radiol.10101058]
- 13 **Kokudo T**, Hasegawa K, Matsuyama Y, Takayama T, Izumi N, Kadoya M, Kudo M, Ku Y, Sakamoto M, Nakashima O, Kaneko S, Kokudo N; Liver Cancer Study Group of Japan. Survival benefit of liver resection for hepatocellular carcinoma associated with portal vein invasion. *J Hepatol* 2016; Epub ahead of print [PMID: 27266618 DOI: 10.1016/j.jhep.2016.05.044]
- 14 **Lee JM**, Jang BK, Lee YJ, Choi WY, Choi SM, Chung WJ, Hwang JS, Kang KJ, Kim YH, Chauhan AK, Park SY, Tak WY, Kweon YO, Kim BS, Lee CH. Survival outcomes of hepatic resection compared with transarterial chemoembolization or sorafenib for hepatocellular carcinoma with portal vein tumor thrombosis. *Clin Mol Hepatol* 2016; **22**: 160-167 [PMID: 27044767 DOI: 10.3350/cmh.2016.22.1.160]
- 15 **Minagawa M**, Makuuchi M. Treatment of hepatocellular carcinoma accompanied by portal vein tumor thrombus. *World J Gastroenterol* 2006; **12**: 7561-7567 [PMID: 17171782 DOI: 10.3748/wjg.v12.i47.7561]
- 16 **Minagawa M**, Makuuchi M, Takayama T, Ohtomo K. Selection criteria for hepatectomy in patients with hepatocellular carcinoma and portal vein tumor thrombus. *Ann Surg* 2001; **233**: 379-384 [PMID: 11224626]
- 17 **Harding DJ**, Perera MT, Chen F, Olliff S, Tripathi D. Portal vein thrombosis in cirrhosis: Controversies and latest developments. *World J Gastroenterol* 2015; **21**: 6769-6784 [PMID: 26078553 DOI: 10.3748/wjg.v21.i22.6769]
- 18 **Kudo M**, Ikeda M, Takayama T, Numata K, Izumi N, Furuse J, Okusaka T, Kadoya M, Yamashita S, Ito Y, Kokudo N. Safety and efficacy of sorafenib in Japanese patients with hepatocellular carcinoma in clinical practice: a subgroup analysis of GIDEON. *J Gastroenterol* 2016; Epub ahead of print [PMID: 27106231]
- 19 **Kitajima T**, Hatano E, Mitsunori Y, Taura K, Fujimoto Y, Mizumoto M, Okajima H, Kaido T, Minamiguchi S, Uemoto S. Complete pathological response induced by sorafenib for advanced hepatocellular carcinoma with multiple lung metastases and venous tumor thrombosis allowing for curative resection. *Clin J Gastroenterol* 2015; **8**: 300-305 [PMID: 26249525 DOI: 10.1007/s12328-015-0594-7]
- 20 **Shinoda M**, Kishida N, Itano O, Ei S, Ueno A, Kitago M, Abe Y, Hibi T, Yagi H, Masugi Y, Tanabe M, Aiura K, Sakamato M, Tanimoto A, Kitagawa Y. Long-term complete response of advanced hepatocellular carcinoma treated with multidisciplinary therapy including reduced dose of sorafenib: case report and review of the literature. *World J Surg Oncol* 2015; **13**: 144 [PMID: 25889667 DOI: 10.1186/s12957-015-0559-9]
- 21 **Irtan S**, Chopin-Laly X, Ronot M, Faivre S, Paradis V, Belghiti J. Complete regression of locally advanced hepatocellular carcinoma induced by sorafenib allowing curative resection. *Liver Int* 2011; **31**: 740-743 [PMID: 21457447 DOI: 10.1111/j.1478-3231.2010.02441.x]
- 22 **Wang SX**, Byrnes A, Verma S, Pancoast JR, Rixe O. Complete remission of unresectable hepatocellular carcinoma treated with reduced dose of sorafenib: a case report. *Target Oncol* 2010; **5**: 59-63 [PMID: 20309643 DOI: 10.1007/s11523-010-0133-x]
- 23 **Sacco R**, Bargellini I, Gianluigi G, Bertini M, Bozzi E, Altomare E, Battaglia V, Romano A, Bertoni M, Capria A, Bresci G, Bartolozzi C. Complete response for advanced liver cancer during sorafenib therapy: case report. *BMC Gastroenterol* 2011; **11**: 4 [PMID: 21241463 DOI: 10.1186/1471-230X-11-4]
- 24 **Abbadessa G**, Rimassa L, Pressiani T, Carrillo-Infante C, Cucchi E, Santoro A. Optimized management of advanced hepatocellular carcinoma: four long-lasting responses to sorafenib. *World J Gastroenterol* 2011; **17**: 2450-2453 [PMID: 21633647 DOI: 10.3748/wjg.v17.i19.2450]
- 25 **Kee KM**, Hung CH, Wang JH, Lu SN. Serial changes of clinical parameters in a patient with advanced hepatocellular carcinoma with portal vein thrombosis achieving complete response after treatment with sorafenib. *Oncol Targets Ther* 2014; **7**: 829-834 [PMID: 24920924 DOI: 10.2147/OTT.S61740]
- 26 **Shiozawa K**, Watanabe M, Ikehara T, Matsukiyo Y, Kogame M, Kanayama M, Matsui T, Kikuchi Y, Ishii K, Igarashi Y, Sumino Y. Sustained complete response of hepatocellular carcinoma with portal vein tumor thrombus following discontinuation of sorafenib: A case report. *Oncol Lett* 2014; **7**: 50-52 [PMID: 24348819 DOI: 10.3892/ol.2013.1664]
- 27 **Gamstatter T**, Weinmann A, Schadmand-Fischer S, Spies PR, Niederle IM, Schuchmann M, Galle PR, Worns MA. AFP measurement in monitoring treatment response of advanced hepatocellular carcinoma to sorafenib: case report and review of the literature. *Onkologie* 2011; **34**: 538-542 [PMID: 21985853 DOI: 10.1159/000332137]

**P- Reviewer:** Bester L, Gatselis NK, Ji JS, Somma F **S- Editor:** Yu J  
**L- Editor:** A **E- Editor:** Wang CH





Published by **Baishideng Publishing Group Inc**

8226 Regency Drive, Pleasanton, CA 94588, USA

Telephone: +1-925-223-8242

Fax: +1-925-223-8243

E-mail: [bpgoffice@wjgnet.com](mailto:bpgoffice@wjgnet.com)

Help Desk: <http://www.wjgnet.com/esps/helpdesk.aspx>

<http://www.wjgnet.com>



ISSN 1007-9327



9 771007 932045