

World Journal of *Orthopedics*

World J Orthop 2017 May 18; 8(5): 364-440



**MINIREVIEWS**

- 364 Hallux rigidus: How do I approach it?
Lam A, Chan JJ, Surace MF, Vulcano E

ORIGINAL ARTICLE**Basic Study**

- 372 Light and electron microscopic study of the medial collateral ligament epiligament tissue in human knees
Georgiev GP, Iliev A, Kotov G, Kinov P, Slavchev S, Landzhov B

Observational Study

- 379 Technical note: Anterior cruciate ligament reconstruction in the presence of an intramedullary femoral nail using anteromedial drilling
Lacey M, Lamplot J, Walley KC, DeAngelis JP, Ramappa AJ

Prospective Study

- 385 Functional outcome of tibial fracture with acute compartment syndrome and correlation to deep posterior compartment pressure
Goyal S, Naik MA, Tripathy SK, Rao SK

Randomized Clinical Trial

- 394 Frozen shoulder - A prospective randomized clinical trial
Mukherjee RN, Pandey RM, Nag HL, Mittal R

SYSTEMATIC REVIEWS

- 400 Predicting lower limb periprosthetic joint infections: A review of risk factors and their classification
George DA, Drago L, Scarponi S, Gallazzi E, Haddad FS, Romano CL
- 412 Dementia and osteoporosis in a geriatric population: Is there a common link?
Downey CL, Young A, Burton EF, Graham SM, Macfarlane RJ, Tsapakis EM, Tsiridis E
- 424 Surgery for calcifying tendinitis of the shoulder: A systematic review
Verstraeten FU, Fievez E, Janssen L, Morrenhof W
- 431 Effect of lengthening along the anatomical axis of the femur and its clinical impact
Emara KM, Mahmoud AN, Emara AK, Emara MK

CASE REPORT

- 436 Chest pain caused by multiple exostoses of the ribs: A case report and a review of literature
Mazza D, Fabbri M, Calderaro C, Iorio C, Labianca L, Poggi C, Turturro F, Montanaro A, Ferretti A

Contents

World Journal of Orthopedics
Volume 8 Number 5 May 18, 2017

ABOUT COVER

Editorial Board Member of *World Journal of Orthopedics*, Bruce M Rothschild, MD, Professor, Department of Medicine, Northeast Ohio Medical University, Indiana, PA 15701, United States

AIM AND SCOPE

World Journal of Orthopedics (*World J Orthop*, *WJO*, online ISSN 2218-5836, DOI: 10.5312) is a peer-reviewed open access academic journal that aims to guide clinical practice and improve diagnostic and therapeutic skills of clinicians.

WJO covers topics concerning arthroscopy, evidence-based medicine, epidemiology, nursing, sports medicine, therapy of bone and spinal diseases, bone trauma, osteoarthritis, bone tumors and osteoporosis, minimally invasive therapy, diagnostic imaging. Priority publication will be given to articles concerning diagnosis and treatment of orthopedic diseases. The following aspects are covered: Clinical diagnosis, laboratory diagnosis, differential diagnosis, imaging tests, pathological diagnosis, molecular biological diagnosis, immunological diagnosis, genetic diagnosis, functional diagnostics, and physical diagnosis; and comprehensive therapy, drug therapy, surgical therapy, interventional treatment, minimally invasive therapy, and robot-assisted therapy.

We encourage authors to submit their manuscripts to *WJO*. We will give priority to manuscripts that are supported by major national and international foundations and those that are of great basic and clinical significance.

INDEXING/ABSTRACTING

World Journal of Orthopedics is now indexed in Emerging Sources Citation Index (Web of Science), PubMed, PubMed Central and Scopus.

FLYLEAF

I-III Editorial Board

EDITORS FOR THIS ISSUE

Responsible Assistant Editor: *Xiang Li*
Responsible Electronic Editor: *Ya-Jing Lu*
Proofing Editor-in-Chief: *Lian-Sheng Ma*

Responsible Science Editor: *Fang-Fang Ji*
Proofing Editorial Office Director: *Xiu-Xia Song*

NAME OF JOURNAL
World Journal of Orthopedics

ISSN
ISSN 2218-5836 (online)

LAUNCH DATE
November 18, 2010

FREQUENCY
Monthly

EDITORS-IN-CHIEF
Quanjun (Trey) Cui, MD, Professor, Department of Orthopaedic Surgery, School of Medicine, University of Virginia, Charlottesville, VA 22908, United States

Bao-Gan Peng, MD, PhD, Professor, Department of Spinal Surgery, General Hospital of Armed Police Force, Beijing 100039, China

EDITORIAL BOARD MEMBERS
All editorial board members resources online at <http://www.wjgnet.com>

www.wjgnet.com/2218-5836/editorialboard.htm

EDITORIAL OFFICE
Xiu-Xia Song, Director
World Journal of Orthopedics
Baishideng Publishing Group Inc
7901 Stoneridge Drive, Suite 501, Pleasanton, CA 94588, USA
Telephone: +1-925-2238242
Fax: +1-925-2238243
E-mail: editorialoffice@wjgnet.com
Help Desk: <http://www.fgpublishing.com/helpdesk>
<http://www.wjgnet.com>

PUBLISHER
Baishideng Publishing Group Inc
7901 Stoneridge Drive,
Suite 501, Pleasanton, CA 94588, USA
Telephone: +1-925-2238242
Fax: +1-925-2238243
E-mail: bpgoffice@wjgnet.com
Help Desk: <http://www.fgpublishing.com/helpdesk>
<http://www.wjgnet.com>

PUBLICATION DATE
May 18, 2017

COPYRIGHT
© 2017 Baishideng Publishing Group Inc. Articles published by this Open-Access journal are distributed under the terms of the Creative Commons Attribution Non-commercial License, which permits use, distribution, and reproduction in any medium, provided the original work is properly cited, the use is non commercial and is otherwise in compliance with the license.

SPECIAL STATEMENT
All articles published in journals owned by the Baishideng Publishing Group (BPG) represent the views and opinions of their authors, and not the views, opinions or policies of the BPG, except where otherwise explicitly indicated.

INSTRUCTIONS TO AUTHORS
<http://www.wjgnet.com/bpg/gerinfo/204>

ONLINE SUBMISSION
<http://www.fgpublishing.com>

Chest pain caused by multiple exostoses of the ribs: A case report and a review of literature

Daniele Mazza, Mattia Fabbri, Cosma Calderaro, Carlo Iorio, Luca Labianca, Camilla Poggi, Francesco Turturro, Antonello Montanaro, Andrea Ferretti

Daniele Mazza, Mattia Fabbri, Cosma Calderaro, Carlo Iorio, Luca Labianca, Camilla Poggi, Francesco Turturro, Antonello Montanaro, Andrea Ferretti, Orthopedic Division, Sant'Andrea Hospital, La Sapienza University of Rome, 00189 Rome, Italy

Author contributions: All authors contributed to the acquisition of data, writing, and revision of this manuscript.

Institutional review board statement: This case report was approved by the Institution review board.

Informed consent statement: The patient involved in this study gave her written informed consent authorizing use and disclosure of her protected health information.

Conflict-of-interest statement: All the authors have no conflicts of interests to declare.

Open-Access: This article is an open-access article which was selected by an in-house editor and fully peer-reviewed by external reviewers. It is distributed in accordance with the Creative Commons Attribution Non Commercial (CC BY-NC 4.0) license, which permits others to distribute, remix, adapt, build upon this work non-commercially, and license their derivative works on different terms, provided the original work is properly cited and the use is non-commercial. See: <http://creativecommons.org/licenses/by-nc/4.0/>

Manuscript source: Invited manuscript

Correspondence to: Daniele Mazza, MD, Orthopedic Division, Sant'Andrea Hospital, La Sapienza University of Rome, Via di Grottarossa 1035, 00189 Rome, Italy. daniele.mazza@hotmail.it
Telephone: +39-06-33775818
Fax: +39-06-33775918

Received: October 10, 2016

Peer-review started: October 11, 2016

First decision: November 14, 2016

Revised: February 7, 2017

Accepted: February 28, 2017

Article in press: March 2, 2017

Published online: May 18, 2017

Abstract

The aim of this paper is to report an exceptional case of multiple internal exostoses of the ribs in a young patient affected by multiple hereditary exostoses (MHE) coming to our observation for chest pain as the only symptom of an intra-thoracic localization. A 16 years old patient with familiar history of MHE came to our observation complaining a left-sided chest pain. This pain had increased in the last months with no correlation to a traumatic event. The computed tomography (CT) scan revealed the presence of three exostoses located on the left third, fourth and sixth ribs, all protruding into the thoracic cavity, directly in contact with visceral pleura. Moreover, the apex of the one located on the sixth rib revealed to be only 12 mm away from pericardium. Patient underwent video-assisted thoracoscopy with an additional 4-cm mini thoracotomy approach. At the last 1-year follow-up, patient was very satisfied and no signs of recurrence or major complication had occurred. In conclusion, chest pain could be the only symptom of an intra-thoracic exostoses localization, possibly leading to serious complications. Thoracic localization in MHE must be suspected when patients complain chest pain. A chest CT scan is indicated to confirm exostoses and to clarify relationship with surrounding structures. Video-assisted thoracoscopic surgery can be considered a valuable option for exostoses removal, alone or in addition to a mini-thoracotomy approach, in order to reduce thoracotomy morbidity.

Key words: Multiple hereditary exostoses; Thoracoscopy; Ribs exostoses; Chest exostoses; Chest pain

© The Author(s) 2017. Published by Baishideng Publishing Group Inc. All rights reserved.

Core tip: This is a report of an exceptional case of multiple internal exostoses of the ribs in a young patient affected by Multiple hereditary exostoses observed for chest pain as symptom of an intra-thoracic localization. Chest pain could be the only symptom of an intra-thoracic

localization, possibly leading to serious complications. Thoracic localization must be suspected when patients complain chest pain. Computed tomography scan is indicated to confirm exostoses and to clarify relationship with surrounding structures. Video-assisted thoracoscopy surgery can be considered a valuable option for exostoses removal, alone or in addition to a mini-thoracotomy approach, in order to reduce thoracotomy morbidity.

Mazza D, Fabbri M, Calderaro C, Iorio C, Labianca L, Poggi C, Turturro F, Montanaro A, Ferretti A. Chest pain caused by multiple exostoses of the ribs: A case report and a review of literature. *World J Orthop* 2017; 8(5): 436-440 Available from: URL: <http://www.wjgnet.com/2218-5836/full/v8/i5/436.htm> DOI: <http://dx.doi.org/10.5312/wjo.v8.i5.436>

INTRODUCTION

The aim of this paper is to report an exceptional case of multiple internal exostoses of the ribs in a young patient affected by multiple hereditary exostoses (MHE), who came to our observation complaining chest pain as the only symptom of an intra-thoracic localization. MHE is also known as diaphyseal aclasia, Osteochondromatosis or multiple osteochondroma. It is an autosomal dominant disorder with growth plate-like exostoses next to long bones and other skeletal elements.

Usually, all affected individuals are diagnosed by age 12 years, but the median age of diagnosis is three years. The risk for malignant degeneration to osteochondrosarcoma increases with age^[1].

The diagnosis of MHE is based on clinical-radiographic results of multiple exostoses in members of a family. The two genes involved are known to cause MHE are EXT1 and EXT2. Mutations in both EXT1 and EXT2 are detected in 70%-95% of affected individuals^[2]. Exostoses of the rib are extremely rare, contributing to approximately 1% of all exostoses in MHE^[3-5]. We report the case of a patient, complaining only chest pain, affected by MHE with three exostoses protruding directly into the thoracic cavity.

CASE REPORT

A 16 years old patient with familiar history of MHE, came to our observation for a right sided knee-pain caused by an exostoses of the distal femur irritating the surrounding aponeurotic structures. The patient had undergone several surgical procedures for exostoses removal on both femur, tibia and fibula, left radius and fourth finger of the right hand, all performed by our Unit. During physical examination, patient reported even having a left-sided chest pain. This pain had increased in the last months with no correlation to a traumatic event and was exacerbated by physical activity and cough. Palpation didn't reveal any subcutaneous swelling. There was no sign of coughing,

sputum, nausea, tremor or fever and his laboratory values were all normal. The chest x-ray revealed the presence of three exostoses located on the right second and twelfth and on the tenth left ribs, not related to the pain complained by the patient. We therefore performed a computed tomography (CT) (Figure 1) of the chest with 3-dimension reconstruction which even showed the presence of three exostoses on the left third, fourth and sixth ribs. All the three exostoses protruded into the thoracic cavity, directly in contact with visceral pleura. Moreover, the apex of the one located on the sixth rib revealed to be only 12 mm away from pericardium. Because of symptoms complained by the patient and the particular location of exostoses with potential serious complication, we therefore decided for surgical intervention.

Surgical technique

The patient received general anesthesia. Unilateral ventilation with a tidal volume of 300 mL was obtained using a double-lumen endotracheal tube.

A lateral decubitus position was used and a 4-cm long mini-thoracotomy incision was performed at the fifth intercostal space in addition to a standard thoracoscopic portal at the eighth intercostal space in order to completely resect exostoses avoiding recurrence and organ injury.

The surgeon identified by thoracoscopy three significant exostoses originating from the ribs within the left side of the chest (Figure 2); one of them hurt the pericardium during cardiac pulsations, as visualized under unilateral right ventilation after exclusion of the left lung. This scratching caused a thickening of the adjacent pericardium and visceral. Each exostoses were completely resected using a chisel and the specimens obtained were sent to the pathologist. In the apex of the chest cavity a single thoracotomy tube was inserted and positioned.

The incisions were closed and the lung was re-expanded to evaluate correct ventilation. The postoperative course was ordinary, and the patient was discharged on the seventh postoperative day. Pathological examination of the specimens obtained were consistent for exostoses, measuring 2 cm in length and 1 cm in width in the third rib, in the fourth one 2 cm in length and 0.5 cm in width and in the sixth one 2.5 cm in length and 1.5 cm in width (Figure 3). At the last 1-year follow-up, patient was very satisfied and no signs of recurrence or major complication had occurred.

DISCUSSION

The most common localization of exostoses is distal femur, proximal tibia, fibula and humerus, bones that develop from cartilage. Angular deformities, leg-length inequalities and pain resulting from inflammation of skin, tendons or nerves often require surgery.

The flat bones like iliac and scapula are less frequently involved. Rarely ribs, spine, metatarsals, meta-

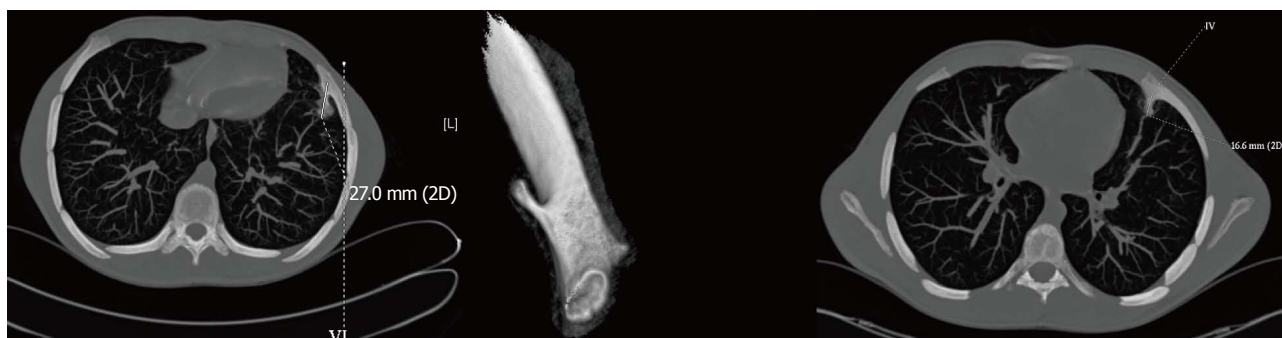

Figure 1 Thoracoscopic findings. Exostosis originating from the costochondral junction of the ribs, with the tip adjacent to the pericardium. The thickening of the pericardium and pleura was caused by scratching with the exostosis during respiratory movements and cardiac pulsations.

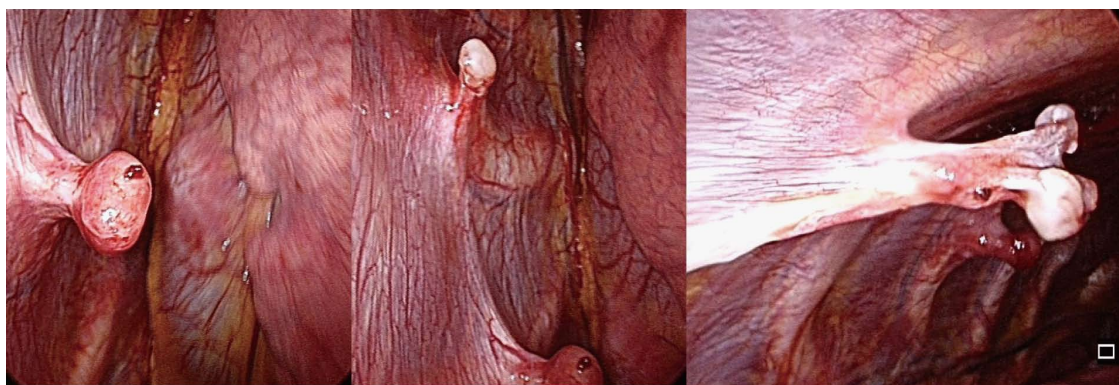


Figure 2 A chest computed tomography scan showing exostoses originating from the left third, fourth and sixth ribs, with a long bony spicule projecting inwards toward the lung.

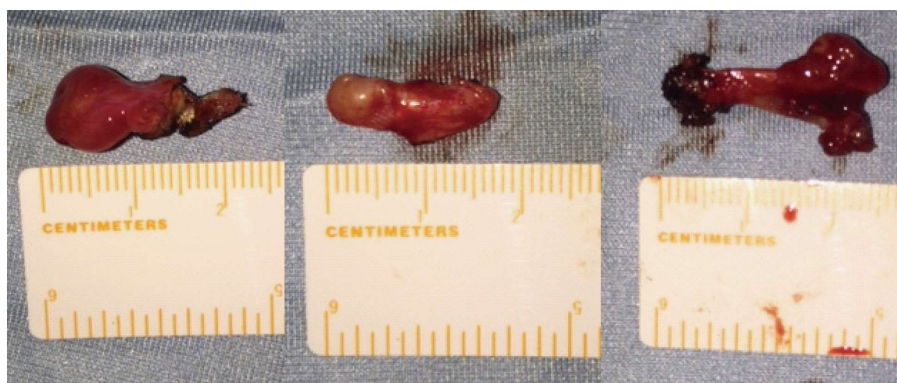

Figure 3 Macroscopic aspect of exostosis.

carpals, phalanges are involved^[1]. Costal exostoses may be difficult to recognize on the chest using only X-ray and the chest CT scan is usually suitable^[3-5]. Malignant transformation is seen in 0.5%-5% cases of MHE. Axial sites as ribs, spine, pelvic hips and shoulder are sites of increased risk of malignant transformation. Average age at malignant transformation in MHE is 25-30. It is rare before 20 years of age.

Generally, exostoses grow and gradually ossify during skeletal growth and stop growing with skeletal maturity. The proportion of individuals with MHE who have clinical symptoms rises from approximately 5% at birth to 96%

at age 12 years^[1].

MHE doesn't require therapy in the absence of clinical symptoms, but it should be recommended in selected patients. Despite several studies exist in literature regarding costal exostoses, only few Authors have reported surgical management and outcomes of intra-thoracic localization (Table 1).

Most of the cases described concern about a single exostoses, alone or associated to MHE, while very few papers report the management of multiple intra-thoracic exostoses^[3,16,19,27,28]. The majority of cases were treated with a thoracotomy approach, with an increase of less

Table 1 Review of surgically treated intra-thoracic exostoses reports

| Ref. | Year | Age | No. of exostoses | Procedure | Outcomes |
|------|------|-----|----------------------------------|------------------------------|----------|
| [6] | 1980 | 9 | 1 | Thoracotomy | Good |
| [7] | 1981 | 20 | 1 | Thoracotomy | Good |
| [8] | 1989 | 7 | 1 | Thoracotomy | Good |
| [9] | 1990 | 14 | 1 | Thoracotomy | Good |
| [10] | 1993 | 19 | 1 | Thoracotomy | Good |
| [11] | 1994 | 36 | 1 | Thoracotomy | Good |
| [12] | 1994 | 3 | 1 | Thoracoscopy | Good |
| [13] | 1997 | 19 | 1 | Thoracotomy | Good |
| [14] | 1998 | 15 | 1 | Thoracotomy | Good |
| [15] | 1997 | 17 | 1 | Thoracoscopy | Good |
| [16] | 2001 | 21 | 1 | Thoracotomy | Good |
| [17] | 2005 | 6 | 3 | Thoracoscopy | Good |
| [4] | 2005 | 15 | 1 | Thoracotomy | Good |
| [18] | 2005 | 11 | 1 | Thoracotomy | Good |
| [19] | 2006 | 14 | 1 | Thoracotomy/ thoracoscopy | Good |
| [20] | 2008 | 17 | 2 | Thoracotomy | Good |
| | | 15 | 1 | Thoracotomy | Good |
| | | 23 | 2 | Thoracotomy | Good |
| | | 12 | 1 | Thoracotomy | Good |
| | | 3 | 1 | Thoracotomy | Good |
| [21] | 2009 | 15 | 1 | Thoracoscopy | Good |
| [22] | 2009 | 16 | 1 | Thoracoscopy | Good |
| [23] | 2010 | 17 | 1 | Thoracoscopy | Good |
| [3] | 2011 | 14 | 2 | Thoracotomy | Good |
| | | 6 | 2 | Thoracotomy | Good |
| [24] | 2012 | 25 | 1 | Thoracotomy/ thoracoscopy | Good |
| [25] | 2013 | 2 | 1 | Thoracotomy | Good |
| [26] | 2013 | 5 | 1 | Thoracoscopy | Good |
| [27] | 2012 | 21 | 1 | Thoracotomy/ thoracoscopy | Good |
| [28] | 2014 | 16 | 2 | Thoracoscopy | Good |
| [29] | 2014 | 15 | 1 | Thoracotomy | Good |
| | | 5 | Multiple intra/ extrathoracic | Thoracotomy | Good |
| [30] | 2015 | 18 | 1 | Thoracoscopy | Good |

invasive surgery such as video-assisted thoracoscopy in the last two decades^[12,15,17,21-23,26,28,30]. However, some Authors have underlined the needs of an additional mini-thoracotomy incision depending on the localization of rib involvement and the dimension of the exostoses^[19,24,27]. Therefore, considering our case, we sought to completely resect exostoses avoiding recurrence and organ injury preferring a 4-cm mini-thoracotomy approach instead of an additional standard thoracoscopic portal.

The outcomes of surgical management were favorable in all previously reported cases with no significant complications, as in our case. Only Cowles *et al.*^[17] reported a persistent post-operative pneumothorax related to a malfunction of chest drainage system, resolved without consequence^[17].

Interestingly, in most of the cases reported the diagnosis was made due to complication, potentially fatal, caused by interference with surrounding structures, as was the choice to surgically treat the exostoses. On the contrary, only two cases are described in literature with pain caused by intra-thoracic localization of exostoses

as the only reason for exostoses removal^[14,29], as in our case.

The patient described in this report revealed only chest pain, but localization and dimension of exostoses could have had a possible risk of dangerous thoracic organ damage or risk of haemothorax due to traumas or vascular wound directly caused by the tip of the exostoses, as widely reported in literature.

Chest pain could be the only symptom of an intra-thoracic exostoses localization, possibly leading to serious complications. Thoracic localization in MHE must be suspected when patients complain chest pain. A chest CT scan is indicated to confirm exostoses and to clarify relationship with surrounding structures. Video-assisted thoracoscopic surgery can be considered a valuable option for exostoses removal, alone or in addition to a mini-thoracotomy approach, in order to reduce thoracotomy morbidity.

COMMENTS

Case characteristics

The patient, a 16 years old Caucasian male, reported having a left-sided chest pain, increased in the last months with no correlation to a traumatic event and was exacerbated by physical activity and cough.

Clinical diagnosis

Palpation don't showed evidence of any subcutaneous swelling and there was no sign of coughing, sputum, vomiting, palpitation or fever.

Differential diagnosis

Neuropathic pain, rib fracture, pneumothorax, haemothorax, pneumonia, pleuritis, chest or pleural or lung neoplastic process were excluded by the clinical and objective sign, laboratory tests and imaging.

Laboratory diagnosis

Hemoglobin level, hematocrit, electrolytes, liver enzymes and coagulation parameters were all normal.

Imaging diagnosis

The chest X-ray and computed tomography (CT) revealed the presence of three exostoses located on the right second and twelfth and on the tenth left ribs, not related to the pain complained and other of the three exostoses on the left third, fourth and sixth ribs.

Pathological diagnosis

The imaging suggested the diagnosis of multiple exostoses of the rib and it was confirmed after the surgical excision by the pathological examination of the specimens.

Treatment

All the exostoses were removed by a thoracoscopy approach with a chisel.

Related reports

Costal exostoses may be difficult to recognize on the chest X-ray. The chest CT scan is usually useful for diagnosis and malignant transformation is seen in 0.5%-5% cases of multiple hereditary exostoses (MHE).

Term explanation

MHE, also known as Multiple Osteochondroma, Osteochondromatosis and Diaphyseal Aclasia, is an autosomal dominant disorder characterized by formation of ectopic, cartilage-capped, growth plate-like exostoses next to long

bones and other skeletal elements.

Experiences and lessons

Thoracic localization in MHE can be suspected when patients complain chest pain and a chest CT scan is indicated to confirm exostoses and to clarify relationship with surrounding structures.

Peer-review

This is an interesting and well presented case report of a rare genetic disease.

REFERENCES

- Bovée JV. Multiple osteochondromas. *Orphanet J Rare Dis* 2008; **3**: 3 [PMID: 18271966 DOI: 10.1186/1750-1172-3-3]
- Zak BM, Schuksz M, Koyama E, Mundy C, Wells DE, Yamaguchi Y, Pacifici M, Esko JD. Compound heterozygous loss of Ext1 and Ext2 is sufficient for formation of multiple exostoses in mouse ribs and long bones. *Bone* 2011; **48**: 979-987 [PMID: 21310272 DOI: 10.1016/j.bone.2011.02.001]
- Assefa D, Murphy RC, Bergman K, Atlas AB. Three faces of costal exostoses: case series and review of literature. *Pediatr Emerg Care* 2011; **27**: 1188-1191 [PMID: 22158283 DOI: 10.1097/PEC.0b013e31823b45ca]
- Pham-Duc ML, Reix P, Mure PY, Pracros JP, Moreux N, Bellon G. Hemothorax: an unusual complication of costal exostosis. *J Pediatr Surg* 2005; **40**: e55-e57 [PMID: 16291144 DOI: 10.1016/j.jpedsurg.2005.07.060]
- Chazono M, Masui F, Kawaguchi Y, Hazama H, Ueda J, Saito S, Ito Y, Kasama K, Liu K, Marumo K. Dumbbell-shaped osteochondroma of the fifth rib causing spinal cord compression. *J Orthop Sci* 2009; **14**: 336-338 [PMID: 19499302 DOI: 10.1007/s00776-008-1323-6]
- Propper RA, Young LW, Wood BP. Hemothorax as a complication of costal cartilaginous exostoses. *Pediatr Radiol* 1980; **9**: 135-137 [PMID: 7393667 DOI: 10.1007/BF01464306]
- Camera A, Potter RT, Siegel M. Hemothorax: unusual complication of hereditary multiple exostosis. *N Y State J Med* 1981; **81**: 243-244 [PMID: 6970353]
- Teijeira FJ, Baril C, Younge D. Spontaneous hemothorax in a patient with hereditary multiple exostoses. *Ann Thorac Surg* 1989; **48**: 717-718 [PMID: 2818067 DOI: 10.1016/0003-4975(89)90802-3]
- Reynolds JR, Morgan E. Haemothorax caused by a solitary costal exostosis. *Thorax* 1990; **45**: 68-69 [PMID: 2321179 DOI: 10.1136/thx.45.1.68]
- Castells L, Comas P, González A, Vargas V, Guardia J, Gifré L. Case report: haemothorax in hereditary multiple exostosis. *Br J Radiol* 1993; **66**: 269-270 [PMID: 8472123 DOI: 10.1259/0007-1285-66-783-269]
- Harrison NK, Wilkinson J, O'Donohue J, Hansell D, Sheppard MN, Goldstraw PG, Davison AG, Newman Taylor AJ. Osteochondroma of the rib: an unusual cause of haemothorax. *Thorax* 1994; **49**: 618-619 [PMID: 8016805 DOI: 10.1136/thx.49.6.618]
- Tomares SM, Jabra AA, Conrad CK, Beauchamp N, Phoon CK, Carroll JL. Hemothorax in a child as a result of costal exostosis. *Pediatrics* 1994; **93**: 523-525 [PMID: 8115223]
- Uchida K, Kurihara Y, Sekiguchi S, Doi Y, Matsuda K, Miyana M, Ikeda Y. Spontaneous haemothorax caused by costal exostosis. *Eur Respir J* 1997; **10**: 735-736 [PMID: 9073015]
- Cottalorda J, Stephan JL, Varlet F, Maatougui K, Chavrier Y. [Intra-thoracic costal sites of osteogenic exostoses in the child]. *Rev Chir Orthop Reparatrice Appar Mot* 1998; **84**: 563-566 [PMID: 9846333]
- Simansky DA, Paley M, Werczberger A, Bar Ziv Y, Yellin A. Exostosis of a rib causing laceration of the diaphragm: diagnosis and management. *Ann Thorac Surg* 1997; **63**: 856-857 [PMID: 9066424 DOI: 10.1016/S0003-4975(96)01269-6]
- Buchan KG, Zamvar V, Mandana KM, Nihal E, Kulatilake P. Juxtacardiac costal osteochondroma presenting as recurrent haemothorax. *Eur J Cardiothorac Surg* 2001; **20**: 208-210 [PMID: 11423301 DOI: 10.1016/S1010-7940(01)00721-7]
- Cowles RA, Rowe DH, Arkovitz MS. Hereditary multiple exostoses of the ribs: an unusual cause of hemothorax and pericardial effusion. *J Pediatr Surg* 2005; **40**: 1197-1200 [PMID: 16034772 DOI: 10.1016/j.jpedsurg.2005.03.064]
- Jin W, Hyun SY, Ryoo E, Lim YS, Kim JK. Costal osteochondroma presenting as haemothorax and diaphragmatic laceration. *Pediatr Radiol* 2005; **35**: 706-709 [PMID: 15806405 DOI: 10.1007/s00247-005-1407-9]
- Abdullah F, Kanard R, Femino D, Ford H, Stein J. Osteochondroma causing diaphragmatic rupture and bowel obstruction in a 14-year-old boy. *Pediatr Surg Int* 2006; **22**: 401-403 [PMID: 16395607 DOI: 10.1007/s00383-005-1622-3]
- Kim S, Lee S, Arsenaault DA, Strijbosch RA, Shamberger RC, Puder M. Pediatric rib lesions: a 13-year experience. *J Pediatr Surg* 2008; **43**: 1781-1785 [PMID: 18926207 DOI: 10.1016/j.jpedsurg.2008.02.061]
- Kuo SM, Chen KC, Diao GY, Hua YM. Dangerous costal exostosis: hemothorax mimicking empyema in a child. *J Pediatr* 2010; **156**: 853, 853.e1 [PMID: 20060125 DOI: 10.1016/j.jpeds.2009.09.053]
- Asmat A, Tam J. Spontaneous haemothorax from an osteochondroma. *Eur J Cardiothorac Surg* 2009; **36**: 394 [PMID: 19482485 DOI: 10.1016/j.ejcts.2009.04.039]
- Khosla A, Parry RL. Costal osteochondroma causing pneumothorax in an adolescent: a case report and review of the literature. *J Pediatr Surg* 2010; **45**: 2250-2253 [PMID: 21034955 DOI: 10.1016/j.jpedsurg.2010.06.045]
- Rolli L, Ampollini L, Carbonegnani P, Rusca M. Intrathoracic costal exostosis. *Eur J Cardiothorac Surg* 2012; **42**: 1051 [PMID: 22659900 DOI: 10.1093/ejcts/ezs327]
- Pelc HJ, Walker J, Davies G. Successful operative management of an asymptomatic chest lesion in hereditary multiple exostosis. *J Pediatr Orthop B* 2013; **22**: 505-508 [PMID: 23907180 DOI: 10.1097/BPB.0b013e31823b5875d2]
- Huang HR, Lin TY, Wong KS. Costal exostosis presenting with hemothorax: report of one case. *Eur J Pediatr* 2006; **165**: 342-343 [PMID: 16435130 DOI: 10.1007/s00431-005-0060-5]
- Nakano T, Endo S, Nokubi M, Tsubochi H. Hemothorax caused by a solitary costal exostosis. *Ann Thorac Surg* 2009; **88**: 306 [PMID: 19559260 DOI: 10.1016/j.athoracsurg.2008.09.063]
- Imai K, Suga Y, Nagatsuka Y, Usuda J, Ohira T, Kato H, Ikeda N. Pneumothorax caused by costal exostosis. *Ann Thorac Cardiovasc Surg* 2014; **20**: 161-164 [PMID: 23269261 DOI: 10.5761/atcs.cr.12.01955]
- Bakhshi H, Kushare I, Murphy MO, Gaynor JW, Dormans JP. Chest wall osteochondroma in children: a case series of surgical management. *J Pediatr Orthop* 2014; **34**: 733-737 [PMID: 25210940 DOI: 10.1097/BPO.0000000000000153]
- Rodrigues JC, Mathias HC, Lyen SM, Mcalindon E, Bucciarelli-Ducci C, Batchelor TJ, Hamilton MC, Manghat NE. A Novel Cause of Acute Coronary Syndrome Due to Dynamic Extrinsic Coronary Artery Compression by a Rib Exostosis: Multimodality Imaging Diagnosis. *Can J Cardiol* 2015; **31**: 1303.e9-1303.e11 [PMID: 26255213 DOI: 10.1016/j.cjca.2015.05.008]

P- Reviewer: Leithner A, Sicari R S- Editor: Ji FF L- Editor: A
E- Editor: Lu YJ





Published by **Baishideng Publishing Group Inc**
7901 Stoneridge Drive, Suite 501, Pleasanton, CA 94588, USA
Telephone: +1-925-223-8242
Fax: +1-925-223-8243
E-mail: bpgoffice@wjgnet.com
Help Desk: <http://www.f6publishing.com/helpdesk>
<http://www.wjgnet.com>

