

## Late-onset severe biliary bleeding after endoscopic pigtail plastic stent insertion

Muneji Yasuda, Hideki Sato, Yuki Koyama, Tomoki Sakakida, Takumi Kawakami, Takeshi Nishimura, Hideki Fujii, Yoshikazu Nakatsugawa, Shinya Yamada, Naoya Tomatsuri, Yusuke Okuyama, Hiroyuki Kimura, Takaaki Ito, Hiroyuki Morishita, Norimasa Yoshida

Muneji Yasuda, Hideki Sato, Yuki Koyama, Tomoki Sakakida, Takumi Kawakami, Takeshi Nishimura, Hideki Fujii, Yoshikazu Nakatsugawa, Shinya Yamada, Naoya Tomatsuri, Yusuke Okuyama, Hiroyuki Kimura, Norimasa Yoshida, Department of Gastroenterology and Hepatology, Japanese Red Cross Kyoto Daiichi Hospital, Kyoto 605-0981, Japan

Takaaki Ito, Hiroyuki Morishita, Department of Radiology, Japanese Red Cross Kyoto Daiichi Hospital, Kyoto 605-0981, Japan

**Author contributions:** Yasuda M, Sato H, Koyama Y, Kawakami T and Yoshida N contributed to the acquisition of data and to the writing and revision of this manuscript; Fujii H performed PTBD; Ito T and Morishita H performed TAE; all other members equally contributed medical treatment.

**Supported by** Japanese Red Cross Kyoto Daiichi Hospital, Kyoto, Japan.

**Institutional review board statement:** This case report was exempt from the Institutional Review Board standards of Japanese Red Cross Kyoto Daiichi Hospital.

**Informed consent statement:** The patient involved in this study gave written informed consent authorizing use and disclosure of her protected health information.

**Conflict-of-interest statement:** All of the authors state that they have no conflicts of interests related to this article.

**Open-Access:** This article is an open-access article which was selected by an in-house editor and fully peer-reviewed by external reviewers. It is distributed in accordance with the Creative Commons Attribution Non Commercial (CC BY-NC 4.0) license, which permits others to distribute, remix, adapt, build upon this work non-commercially, and license their derivative works on different terms, provided the original work is properly cited and the use is non-commercial. See: <http://creativecommons.org/licenses/by-nc/4.0/>

**Manuscript source:** Unsolicited manuscript

**Correspondence to:** Dr. Muneji Yasuda, Department of Gastroenterology and Hepatology, Japanese Red Cross Kyoto Daiichi Hospital, 749 Hon-machi 15, Higashiyama-ward, Kyoto 605-0981, Japan. [muneji0811@yahoo.co.jp](mailto:muneji0811@yahoo.co.jp)  
**Telephone:** +81-75-5611121  
**Fax:** +81-75-5616308

**Received:** October 11, 2016

**Peer-review started:** October 13, 2016

**First decision:** October 28, 2016

**Revised:** November 9, 2016

**Accepted:** November 23, 2016

**Article in press:** November 28, 2016

**Published online:** January 28, 2017

### Abstract

Here, we report our experience with a case of severe biliary bleeding due to a hepatic arterial pseudoaneurysm that had developed 1 year after endoscopic biliary plastic stent insertion. The patient, a 78-year-old woman, presented with hematemesis and obstructive jaundice. Ruptured hepatic arterial pseudoaneurysm was diagnosed, which was suspected to have been caused by long-term placement of an endoscopic retrograde biliary drainage (ERBD) stent. This episode of biliary bleeding was successfully treated by transarterial embolization (TAE). Pseudoaneurysm leading to hemobilia is a rare but potentially fatal complication in patients with long-term placement of ERBD. TAE is a minimally invasive procedure that offers effective treatment for biliary bleeding.

**Key words:** Biliary stent; Plastic stent; Biliary bleeding; Pseudoaneurysm; Pigtail stent

© The Author(s) 2017. Published by Baishideng Publishing Group Inc. All rights reserved.

**Core tip:** Biliary bleeding after endoscopic pigtail plastic stent insertion is a rare but potentially fatal complication. Transarterial embolization (TAE) is a minimally invasive procedure that offers effective treatment for pseudoaneurysm. We report here a case of biliary bleeding caused by long-term placement of a pigtail plastic stent, which was inserted without removal of common bile duct stones due to the patient's age; the TAE treatment was successful. This case report will help similar patients yet to be encountered but likely to increase in number due to ageing of the world's population.

Yasuda M, Sato H, Koyama Y, Sakakida T, Kawakami T, Nishimura T, Fujii H, Nakatsugawa Y, Yamada S, Tomatsuri N, Okuyama Y, Kimura H, Ito T, Morishita H, Yoshida N. Late-onset severe biliary bleeding after endoscopic pigtail plastic stent insertion. *World J Gastroenterol* 2017; 23(4): 735-739 Available from: URL: <http://www.wjgnet.com/1007-9327/full/v23/i4/735.htm> DOI: <http://dx.doi.org/10.3748/wjg.v23.i4.735>

## INTRODUCTION

Biliary bleeding is an uncommon cause of upper gastrointestinal bleeding and biliary tract obstruction. Biliary stent-related biliary bleeding that occurs after an endoscopic procedure has been reported less often than biliary bleeding related to the percutaneous transhepatic procedure; however, its incidence has been increasing due to the general increase in endoscopic interventions. Transarterial embolization (TAE) is an effective treatment for traumatic pseudoaneurysm of visceral arteries. We describe, herein, a patient with gastrointestinal bleeding and biliary tract obstruction due to intrabiliary rupture of hepatic arterial pseudoaneurysm, which was successfully treated by TAE and percutaneous transhepatic biliary drainage (PTBD).

## CASE REPORT

### Patient

A 78-year-old woman.

### Chief complaint

Hematemesis.

### Past related medical history

Thirty years before the current admission, the patient had undergone left hepatectomy, cholecystectomy and choledochectomy for intrahepatic and common bile duct (CBD) stones, in conjunction with Roux-en-Y and biliary reconstruction. At 1 year prior to the current admission, the patient had developed acute obstructive cholangitis due to CBD stones and had subsequently undergone single-balloon endoscopy. During that procedure, a 7 Fr pigtail type plastic biliary stent had been

inserted into the CBD, which was already dilated due to the previous biliary reconstruction. The proximal edge of the plastic stent had been placed, coiled around, in the CBD improperly (Figure 1). After the cholangitis had been resolved, the patient refused removal of her CBD stones, citing age as her reasoning.

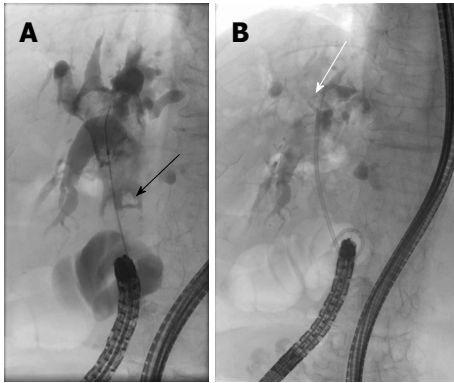
### Family history

We found nothing of significance in the patient's family history.

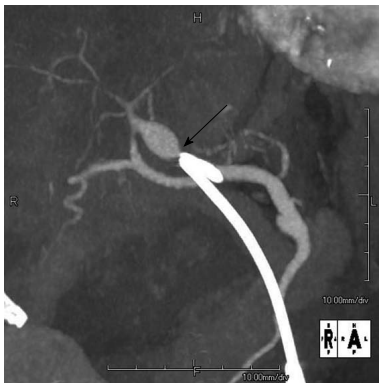### Case presentation

The patient presented to our emergency department with repeated episodes of hematemesis, which had occurred for 6 h. She was not on any medications. On examination, she had pallor of the palpebral conjunctiva, subfebrile temperature (37.3 °C) and tachycardia (heart rate of 99 bpm); her blood pressure was 14.4/5.9 kPa and her respiration rate was 20/min. She had no abdominal pain. Laboratory findings were as follows; hemoglobin of 9.6 g/dL (normal: 11.3-15.2 mg/dL); aspartate aminotransferase/alanine aminotransferase of 155/58 IU/L (normal: 13-33/2-27 IU/L); alkaline phosphatase of 1208 IU/L (normal: 115-359 IU/L); total bilirubin of 1.8 mg/dL (normal: 0.3-1.2 mg/dL); C-reactive protein of 2.6 mg/dL (normal: < 0.3 mg/dL); white blood cell count of 10180/μL (normal: 4000-8000/μL). Non-enhanced computed tomography (CT) revealed dilation of the CBD, as well as high-density masses in the bile duct and in the afferent intestinal loop. Single-balloon endoscopy of the small intestine revealed copious fresh coagulum in the afferent loop, but the site of bleeding was not detected. Contrast-enhanced CT showed 13 mm × 10 mm pseudoaneurysm of the hepatic artery, proximal to the edge of the plastic biliary stent (Figure 2). Abdominal angiography was performed and the pseudoaneurysm was detected close to the stent in the anterior segment artery of the right hepatic artery. N-butyl-2-cyanoacrylate was applied to embolize the pseudoaneurysm (Figure 3), after which a PTBD tube was inserted in the direction from B6 (the inferior branch of right posterior bile duct, corresponding to S6 of the Couinaud classification adopted by Bismuth) to the afferent loop. As a result, the patient's jaundice improved and she was discharged on the 34<sup>th</sup> hospital day.

On the 3<sup>rd</sup> day after discharge, the patient returned to the emergency department with hematemesis, jaundice and shock. Enhanced CT showed extravasation of contrast medium at the site of the pseudoaneurysm, suggesting that the embolic material may have migrated to the jejunum. Emergent abdominal angiography was performed and the digital subtraction angiogram (DSA) revealed an aneurysm at A8 (the anterior arterial branch supplying the superior subsegment) with an arterio-biliary fistula (Figure 4A). Collateral arteries to the anterior segment of the right lobe were also seen. Embolization was performed for



**Figure 1** Endoscopic retrograde cholangiopancreatography image. A: Stones in common bile duct (black arrow); B: The plastic stent had been placed improperly, and the edge was coiled around in the common bile duct (white arrow). There was no sign of collapse or leakage in the biliary tract.



**Figure 2** Abdominal computed tomography angiography. A 13 mm × 10 mm pseudoaneurysm was found at the proximal anterior segment of the right hepatic artery; The hepatic side edge of the plastic stent (black arrow) was close to the pseudoaneurysm.

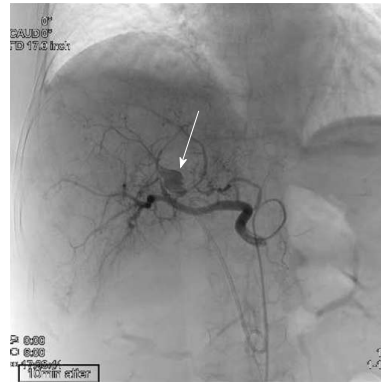
A8, proximal to the pseudoaneurysm (Figure 4B). Subsequently, the patient developed an S8 (Couinaud classification) liver abscess, which was treated successfully by percutaneous transhepatic drainage.

The patient has survived for 1 year since final discharge, without any new health issues.

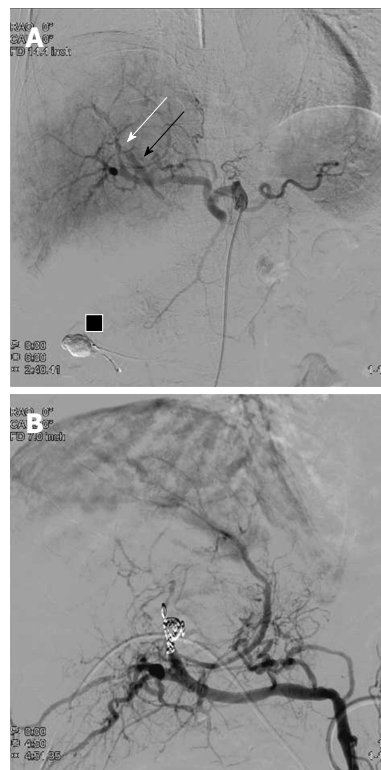## DISCUSSION

Various reports about biliary bleeding have been published. Although biliary hemorrhage is relatively common after surgery, percutaneous transhepatic procedures and placement of the self-expanding metallic biliary stents<sup>[1-5]</sup>, it is rare after insertion of a plastic stent. Likewise, only a few articles have reported on biliary bleeding associated with plastic stents<sup>[6-8]</sup>.

We managed events of both life-threatening bleeding and acute obstructive suppurative cholangitis in a patient with a history of intestinal tract reconstruction. Due to this patient's previous surgery and severe bleeding, endoscopic biliary drainage was relatively difficult, so we chose to perform PTBD for obstructive



**Figure 3** The pseudoaneurysm was detected upon celiac axis injection, with the aneurysmal sac slightly lateral to the edge of the plastic stent (arrow). The sac was no longer seen on a selective digital subtraction angiography image after successful embolization. Blood flow was maintained in the anterior segment of the right hepatic artery.



**Figure 4** The 2<sup>nd</sup> digital subtraction angiography image. A: Selective digital subtraction angiography image of the common hepatic artery showing an arterio-biliary fistula (white arrow) between A8 and the common bile duct (black arrow). Embolic material that migrated into the afferent loop is present (black box); B: Proximal A8 embolization obliterated the pseudoaneurysm. Leakage of contrast medium was completely controlled after embolization.

jaundice. We presume that this hepatic pseudoaneurysm might have formed as a result of traumatic stimulation related to the plastic stent placement because it had been placed improperly, with its tip located at the site of the aneurysm. Yet, this may not be the only cause. The patient's history of cholangitis and CBD stones could have also contributed to the formation of the pseudoaneurysm. In daily clinical

practice, an ERBD stent is usually placed for temporary drainage. However, we sometimes leave biliary stones and the ERBD stent in elderly patients due to their comorbidities, so it is not uncommon for us to see such patients<sup>[9]</sup>.

In the study conducted by Green *et al.*<sup>[10]</sup>, cases of biliary bleeding, including those due to pseudoaneurysm, were mostly treated conservatively (43%) or by TAE (36%), with 20% undergoing surgery. In general, the preferred method to stop life-threatening biliary tract bleeding is TAE because it is less invasive and shows higher efficacy than the surgical approach<sup>[10]</sup>; moreover, TAE has lower reported rates of post-treatment mortality and morbidity than surgery<sup>[11,12]</sup>. However, cases of post-TAE hepatic artery occlusion and other complications, including fatal hepatic necrosis and intrahepatic abscess formation, have been reported<sup>[12-16]</sup>. Selective embolization of the vessel, as close as possible to the pseudoaneurysm, is desirable, both to reduce the risk of recurrent biliary bleeding and decrease the likelihood of hepatic necrosis<sup>[13]</sup>.

For the patient described herein, we initially performed selective embolization and maintained peripheral flow because the pseudoaneurysm sac was detected by the first angiogram. Upon repeat angiography, an arterio-biliary fistula was found, instead of a sac, so we were forced to perform non-selective embolization of the anterior segment of the right hepatic artery. After the second TAE, the patient developed local liver necrosis and an intrahepatic abscess of S8, but she was successfully treated by percutaneous drainage and antibiotics. She has remained well for more than 1 year since final discharge.

In conclusion, hepatic artery pseudoaneurysm is a rare but potentially fatal complication in patients with a long-term placement of ERBD. TAE is a minimally invasive procedure that offers effective treatment for pseudoaneurysm.

## COMMENTS

### Case characteristics

A post-choledochectomy 78-year-old woman, with a pigtail biliary stent and CBD stones left in after previous treatment for cholangitis 1 year prior, presented with hematemesis.

### Clinical diagnosis

Biliary bleeding from a hepatic pseudoaneurysm and obstructive jaundice were detected by imaging examination.

### Differential diagnosis

Combination of peptic ulcer and biliary stent obstruction.

### Laboratory diagnosis

Elevated hepatobiliary system enzyme and C-reactive protein levels and leukocytosis suggestive of obstructive cholangitis. Anemia suggestive of bleeding.

### Imaging diagnosis

Contrast-enhanced computed tomography scan showed a 13 mm × 10 mm

pseudoaneurysm of the hepatic artery, proximal to the edge of the plastic biliary stent.

### Treatment

Transarterial embolization (TAE) and percutaneous transhepatic biliary drainage.

### Related reports

Although biliary hemorrhage is relatively common after surgery, percutaneous transhepatic procedures and placement of self-expanding metallic biliary stents, it is rare after insertion of a plastic stent.

### Term explanation

The Couinaud classification is used to describe functional liver anatomy. It has emerged as the preferred anatomy classification system since it divides the liver into eight independent functional units.

### Experiences and lessons

The pigtail plastic stent is often used for temporary biliary drainage. However, it is important to remember that this stent type can cause fatal bleeding. TAE is a more effective and less invasive treatment for biliary bleeding than surgery.

### Peer-review

Although trauma caused by the proximal tip of the pigtail stent is highly suspicious, the authors explain that there might be other additional factors for the formation of the hepatic pseudoaneurysm.

## REFERENCES

- 1 **Watanabe M**, Shiozawa K, Mimura T, Ito K, Kamata I, Kishimoto Y, Momiyama K, Igarashi Y, Sumino Y. Hepatic artery pseudoaneurysm after endoscopic biliary stenting for bile duct cancer. *World J Radiol* 2012; **4**: 115-120 [PMID: 22468193 DOI: 10.4329/wjrv.v4.i3.115]
- 2 **Hyun D**, Park KB, Hwang JC, Shin BS. Delayed, life-threatening hemorrhage after self-expandable metallic biliary stent placement: clinical manifestations and endovascular treatment. *Acta Radiol* 2013; **54**: 939-943 [PMID: 23761546 DOI: 10.1177/0284185113485501]
- 3 **Nicholson T**, Travis S, Ettles D, Dyet J, Sedman P, Wedgewood K, Royston C. Hepatic artery angiography and embolization for hemobilia following laparoscopic cholecystectomy. *Cardiovasc Intervent Radiol* 1999; **22**: 20-24 [PMID: 9929540 DOI: 10.1007/s002709900323]
- 4 **Walter JF**, Paaso BT, Cannon WB. Successful transcatheter embolic control of massive hemobilia secondary to liver biopsy. *AJR Am J Roentgenol* 1976; **127**: 847-849 [PMID: 973674 DOI: 10.2214/ajr.127.5.847]
- 5 **Kinoshita H**, Imayama H, Hashimoto M, Sato S, Hashino K, Hara M, Yatsugi H, Aoyagi S. Two cases of biliary hemorrhage after percutaneous transhepatic biliary drainage in which transcatheter arterial embolization was effective. *Kurume Med J* 2000; **47**: 183-187 [PMID: 10948659]
- 6 **Wolters F**, Ryan B, Beets-Tan R, Dejong C. Delayed massive hemobilia after biliary stenting. *Endoscopy* 2003; **35**: 976-977 [PMID: 14606026 DOI: 10.1055/s-2003-43480]
- 7 **Conio M**, Caroli-Bosc FX, Buckley M, Chiaramondia M, D'Addazio G, Munizzi F. Massive hemobilia after extraction of plastic biliary endoprosthesis. *J Clin Gastroenterol* 1997; **25**: 706 [PMID: 9451700]
- 8 **Inoue H**, Tano S, Takayama R, Nimomiya K, Nishikawa K, Katurahara M, Horiki N, Takei Y. Right hepatic artery pseudoaneurysm: rare complication of plastic biliary stent insertion. *Endoscopy* 2011; **43** Suppl 2 UCTN: E396 [PMID: 22275018 DOI: 10.1055/s-0030-1256942]
- 9 **Park JY**, Ryu H, Bang S, Song SY, Chung JB. Hepatic artery pseudoaneurysm associated with plastic biliary stent.

- Yonsei Med J* 2007; **48**: 546-548 [PMID: 17594167 DOI: 10.3349/ymj.2007.48.3.546]
- 10 **Green MH**, Duell RM, Johnson CD, Jamieson NV. Haemobilia. *Br J Surg* 2001; **88**: 773-786 [PMID: 11412246 DOI: 10.1046/j.1365-2168.2001.01756]
  - 11 **Lygidakis NJ**, Okazaki M, Damtsios G. Iatrogenic hemobilia: how to approach it. *Hepatogastroenterology* 1991; **38**: 454-457 [PMID: 1765366 DOI: 10.1097/00003072-199411000-00021]
  - 12 **Sarr MG**, Kaufman SL, Zuidema GD, Cameron JL. Management of hemobilia associated with transhepatic internal biliary drainage catheters. *Surgery* 1984; **95**: 603-607 [PMID: 6710356 DOI: 10.1001/archsurg.1980.01380020029007]
  - 13 **Vaughan R**, Rösch J, Keller FS, Antonovic R. Treatment of hemobilia by transcatheter vascular occlusion. *Eur J Radiol* 1984; **4**: 183-189 [PMID: 6468408]
  - 14 **Hoevels J**, Nilsson U. Intrahepatic vascular lesions following nonsurgical percutaneous transhepatic bile duct intubation. *Gastrointest Radiol* 1980; **5**: 127-135 [PMID: 7380153 DOI: 10.1007/bf01888616]
  - 15 **Lucas CE**, Ledgerwood AM. Liver necrosis following hepatic artery transection due to trauma. *Arch Surg* 1978; **113**: 1107 [PMID: 687111 DOI: 10.1001/archsurg.1978.01370210089014]
  - 16 **Trojanowski JQ**, Harrist TJ, Athanasoulis CA, Greenfield AJ. Hepatic and splenic infarctions: complications of therapeutic transcatheter embolization. *Am J Surg* 1980; **139**: 272-277 [PMID: 6965571 DOI: 10.1016/0002-9610(80)90272-x]

**P- Reviewer:** Parsi MAA, Pu LZ, Sofi A **S- Editor:** Yu J

**L- Editor:** A **E- Editor:** Liu WX







Published by **Baishideng Publishing Group Inc**

8226 Regency Drive, Pleasanton, CA 94588, USA

Telephone: +1-925-223-8242

Fax: +1-925-223-8243

E-mail: [bpgoffice@wjgnet.com](mailto:bpgoffice@wjgnet.com)

Help Desk: <http://www.wjgnet.com/esps/helpdesk.aspx>

<http://www.wjgnet.com>



ISSN 1007-9327

