


World Journal of *Clinical Oncology*

World J Clin Oncol 2017 June 10; 8(3): 178-304





REVIEW

- 178 Histone deacetylases, microRNA and leptin crosstalk in pancreatic cancer
Tchio Mantho CI, Harbuzariu A, Gonzalez-Perez RR
- 190 Multidisciplinary approach of colorectal cancer liver metastases
Fiorentini G, Sarti D, Aliberti C, Carandina R, Mambrini A, Guadagni S
- 203 Evolving role of Sorafenib in the management of hepatocellular carcinoma
Ziogas IA, Tsoulfas G
- 214 Magnetic resonance imaging for diagnosis and neoadjuvant treatment evaluation in locally advanced rectal cancer: A pictorial review
Engin G, Sharifov R

MINIREVIEWS

- 230 Immunotherapy in pancreatic cancer: Unleash its potential through novel combinations
Guo S, Contratto M, Miller G, Leichman L, Wu J
- 241 Current state and controversies in fertility preservation in women with breast cancer
Taylan E, Oktay KH
- 249 Biological mesh reconstruction of the pelvic floor following abdominoperineal excision for cancer: A review
Schiltz B, Buchs NC, Penna M, Scarpa CR, Liot E, Morel P, Ris F
- 255 Potential prognostic biomarkers in pancreatic juice of resectable pancreatic ductal adenocarcinoma
Agrawal S

ORIGINAL ARTICLE

Case Control Study

- 261 Levels of neutrophil gelatinase-associated lipocalin in patients with head and neck squamous cell carcinoma in Indian population from Haryana state
Verma M, Dahiya K, Soni A, Dhankhar R, Ghalaat VS, Bansal A, Kaushal V

SYSTEMATIC REVIEWS

- 266 Recurrence-free survival as a putative surrogate for overall survival in phase III trials of curative-intent treatment of colorectal liver metastases: Systematic review
Araujo RLC, Herman P, Riechelmann RP

META-ANALYSIS

- 273** Robot-assisted laparoscopic *vs* open gastrectomy for gastric cancer: Systematic review and meta-analysis
Caruso S, Patriti A, Roviello F, De Franco L, Franceschini F, Ceccarelli G, Coratti A

CASE REPORT

- 285** Bilateral diffuse grade 5 radiation pneumonitis after intensity modulated radiation therapy for localized lung cancer
Osborn VW, Leaf A, Lee A, Garay E, Safdieh J, Schwartz D, Schreiber D
- 289** Prostatic adenocarcinoma, oncocytic variant: Case report and literature review
Klaimont MM, Zafar N
- 293** Pancreatic neuroendocrine tumor Grade 1 patients followed up without surgery: Case series
Sugimoto M, Takagi T, Suzuki R, Konno N, Asama H, Watanabe K, Nakamura J, Kikuchi H, Waragai Y, Takasumi M, Kawana S, Hashimoto Y, Hikichi T, Ohira H
- 300** Target migration from re-inflation of adjacent atelectasis during lung stereotactic body radiotherapy
Mao B, Verma V, Zheng D, Zhu X, Bennion NR, Bhurud AR, Poole MA, Zhen W

Contents

World Journal of Clinical Oncology
Volume 8 Number 3 June 10, 2017

ABOUT COVER

Editorial Board Member of *World Journal of Clinical Oncology*, Bin Wang, PhD, Assistant Professor, Department of Biomedical Engineering, Widener University, Chester, PA 19013, United States

AIM AND SCOPE

World Journal of Clinical Oncology (*World J Clin Oncol*, *WJCO*, online ISSN 2218-4333, DOI: 10.5306) is a peer-reviewed open access academic journal that aims to guide clinical practice and improve diagnostic and therapeutic skills of clinicians.

WJCO covers a variety of clinical medical topics, including etiology, epidemiology, evidence-based medicine, informatics, diagnostic imaging, endoscopy, tumor recurrence and metastasis, tumor stem cells, radiotherapy, chemotherapy, interventional radiology, palliative therapy, clinical chemotherapy, biological therapy, minimally invasive therapy, physiotherapy, psycho-oncology, comprehensive therapy, and oncology-related nursing. Priority publication will be given to articles concerning diagnosis and treatment of oncology diseases. The following aspects are covered: Clinical diagnosis, laboratory diagnosis, differential diagnosis, imaging tests, pathological diagnosis, molecular biological diagnosis, immunological diagnosis, genetic diagnosis, functional diagnostics, and physical diagnosis; and comprehensive therapy, drug therapy, surgical therapy, interventional treatment, minimally invasive therapy, and robot-assisted therapy.

We encourage authors to submit their manuscripts to *WJCO*. We will give priority to manuscripts that are supported by major national and international foundations and those that are of great clinical significance.

INDEXING/ABSTRACTING

World Journal of Clinical Oncology is now indexed in PubMed, PubMed Central and Scopus.

FLYLEAF

I-III Editorial Board

EDITORS FOR THIS ISSUE

Responsible Assistant Editor: *Xiang Li*
Responsible Electronic Editor: *Ya-Jing Lu*
Proofing Editor-in-Chief: *Lian-Sheng Ma*

Responsible Science Editor: *Fang-Fang Ji*
Proofing Editorial Office Director: *Ze-Mao Gong*

NAME OF JOURNAL
World Journal of Clinical Oncology

ISSN
ISSN 2218-4333 (online)

LAUNCH DATE
November 10, 2010

FREQUENCY
Bimonthly

EDITOR-IN-CHIEF
Godefridus J Peters, PhD, Professor, Department of Medical Oncology, Cancer Center Amsterdam, VU University Medical Center, Amsterdam 1081 HV, Netherlands

EDITORIAL BOARD MEMBERS
All editorial board members resources online at <http://www.wjgnet.com/2218-4333/editorialboard.htm>

EDITORIAL OFFICE
Xiu-Xia Song, Director

World Journal of Clinical Oncology
Baishideng Publishing Group Inc
7901 Stoneridge Drive, Suite 501, Pleasanton, CA 94588, USA
Telephone: +1-925-2238242
Fax: +1-925-2238243
E-mail: editorialoffice@wjgnet.com
Help Desk: <http://www.f6publishing.com/helpdesk>
<http://www.wjgnet.com>

PUBLISHER
Baishideng Publishing Group Inc
7901 Stoneridge Drive,
Suite 501, Pleasanton, CA 94588, USA
Telephone: +1-925-2238242
Fax: +1-925-2238243
E-mail: bpgoffice@wjgnet.com
Help Desk: <http://www.f6publishing.com/helpdesk>
<http://www.wjgnet.com>

PUBLICATION DATE
June 10, 2017

COPYRIGHT

© 2017 Baishideng Publishing Group Inc. Articles published by this Open-Access journal are distributed under the terms of the Creative Commons Attribution Non-commercial License, which permits use, distribution, and reproduction in any medium, provided the original work is properly cited, the use is non commercial and is otherwise in compliance with the license.

SPECIAL STATEMENT

All articles published in journals owned by the Baishideng Publishing Group (BPG) represent the views and opinions of their authors, and not the views, opinions or policies of the BPG, except where otherwise explicitly indicated.

INSTRUCTIONS TO AUTHORS

<http://www.wjgnet.com/bpg/gerinfo/204>

ONLINE SUBMISSION

<http://www.f6publishing.com>

Target migration from re-inflation of adjacent atelectasis during lung stereotactic body radiotherapy

Bijing Mao, Vivek Verma, Dandan Zheng, Xiaofeng Zhu, Nathan R Bennion, Abhijeet R Bhirud, Maria A Poole, Weining Zhen

Bijing Mao, Department of Oncology, Guizhou Provincial People's Hospital, Guiyang, Guizhou 550002, China

Vivek Verma, Dandan Zheng, Xiaofeng Zhu, Nathan R Bennion, Abhijeet R Bhirud, Maria A Poole, Weining Zhen, Department of Radiation Oncology, University of Nebraska Medical Center, Omaha, NE 68198, United States

Author contributions: Zhen W conceived of the project; Mao B, Verma V, Zheng D and Poole MA collected data; all authors analyzed data, wrote, and reviewed the paper and provided final approval.

Institutional review board statement: This case report was exempt from the University of Nebraska Medical Center Institutional Review Board and Ethics Committee.

Informed consent statement: Consent to report and publish this case was obtained by the patient's next of kin.

Conflict-of-interest statement: All authors declare that conflicts of interest do not exist.

Open-Access: This article is an open-access article which was selected by an in-house editor and fully peer-reviewed by external reviewers. It is distributed in accordance with the Creative Commons Attribution Non Commercial (CC BY-NC 4.0) license, which permits others to distribute, remix, adapt, build upon this work non-commercially, and license their derivative works on different terms, provided the original work is properly cited and the use is non-commercial. See: <http://creativecommons.org/licenses/by-nc/4.0/>

Manuscript source: Invited manuscript

Correspondence to: Weining Zhen, MD, Department of Radiation Oncology, University of Nebraska Medical Center, Ground Floor, Clarkson Tower, Omaha, NE 68198, United States. wzhen@unmc.edu
Telephone: +1-402-5523844
Fax: +1-402-5523013

Received: December 4, 2016

Peer-review started: December 5, 2016

First decision: February 21, 2017

Revised: March 3, 2017

Accepted: April 18, 2017

Article in press: April 20, 2017

Published online: June 10, 2017

Abstract

Stereotactic body radiotherapy (SBRT) is a widely accepted option for the treatment of medically inoperable early-stage non-small cell lung cancer (NSCLC). Herein, we highlight the importance of interfraction image guidance during SBRT. We describe a case of early-stage NSCLC associated with segmental atelectasis that translocated 15 mm anteroinferiorly due to re-expansion of the adjacent segmental atelectasis following the first fraction. The case exemplifies the importance of cross-sectional image-guided radiotherapy that shows the intended target, as opposed to aligning based on rigid anatomy alone, especially in cases associated with potentially "volatile" anatomic areas.

Key words: Radiation therapy; Stereotactic body radiation therapy; Non-small cell lung cancer; Image-guided radiation therapy; Stereotactic ablative radiation therapy

© **The Author(s) 2017.** Published by Baishideng Publishing Group Inc. All rights reserved.

Core tip: This is a case of early-stage non-small cell lung cancer associated with segmental atelectasis that translocated owing to re-expansion of the adjacent segmental atelectasis following the first fraction. There are image-guidance systems that register solely based on rigid (bony) anatomy and others that also show soft tissue; if the former would have been used, the translocated target would have been missed. The case exemplifies the importance of cross-sectional image-guided radiotherapy that shows the intended target, as opposed to aligning based on rigid anatomy alone, in cases associated with

potentially “volatile” anatomic areas.

Mao B, Verma V, Zheng D, Zhu X, Bennion NR, Bhirud AR, Poole MA, Zhen W. Target migration from re-inflation of adjacent atelectasis during lung stereotactic body radiotherapy. *World J Clin Oncol* 2017; 8(3): 300-304 Available from: URL: <http://www.wjgnet.com/2218-4333/full/v8/i3/300.htm> DOI: <http://dx.doi.org/10.5306/wjco.v8.i3.300>

INTRODUCTION

Among other indications, stereotactic body radiotherapy (SBRT) plays an important role in the treatment of early-stage non-small cell lung cancer (NSCLC), chiefly in medically inoperable candidates, or if patients refuse surgery^[1-7]. It is well-known that target and respiratory motion management is critical, and that spatial uncertainty in SBRT can be caused by both internal motion with respiration and set-up errors. Therefore, image-guided radiotherapy (IGRT) before each treatment is strongly recommended for SBRT; IGRT can confirm that the gross tumor is consistently located within the pre-defined treatment volume.

SBRT may utilize one of two IGRT subtypes: Systems that rely on rigid bony anatomy, and those that provide soft tissue discrimination. For the first type, two in-room systems are specifically designed for stereotactic treatments and are widely used: CyberKnife (Accuray Inc., Sunnyvale, CA, United States) and ExacTrac (BrainLabAG, Feldkirchen, Germany). These systems use orthogonal kilovoltage (kV) electronic 2-D radiographs, generated by X-ray tubes combined with flat panel detectors, to align and verify the patient treatment position - usually according to bony anatomy. Though providing better soft-tissue contrast than its MV counterparts, 2D kV IGRT systems largely consider bony landmarks for registration instead of the internal target alignment, except in cases with bulky thoracic tumors or implanted fiducial markers. For the second type, good soft tissue cross-sectional visibility is provided by 3D images. Some of these systems use kV cone-beam computed tomography (CBCT) generated by linear-accelerator (LINAC)-integrated systems such as On-Board-Imager (Varian Medical Systems, Palo Alto, CA, United States) and X-ray-Volume-Imaging (Elekta Oncology Systems, Crawley, United Kingdom). Alternatively, kV computed tomography (CT) can also be implemented by CT-on-Rails (Siemens, Erlangen, Germany). These systems offer 3D images and soft-tissue-based target verification without fiducials for small lung lesions treated with SBRT^[8]. The most common application of this IGRT scheme is a two-step verification process with an initial bony registration followed by a soft-tissue target alignment^[9,10].

Though most studies report localization accuracy improvements of 3D-vs-2D on the order of a few millimeters for lung SBRT^[11-13], we describe a patient with an

early-stage NSCLC which translocated after the first fraction of SBRT owing to re-expansion of segmental atelectasis. We further discuss the role of IGRT systems that align to bone vs soft-tissue in detection and management of the resulting misalignment.

CASE REPORT

A 72-year-old man presented with a nonproductive cough; computed tomography (CT) scan showed a 2.5-cm right lower lobe nodule. He had a 50-year history of smoking and used 4 L of nighttime oxygen (ECOG performance status 3). On auscultation, he had diminished breath sounds; pulmonary function tests showed an FEV1 (forced expiratory volume, 1 s) 41% of the predicted value and a DLCO (diffusion capacity of carbon-monoxide) 29% of the predicted value. Subsequent positron emission tomography (PET) scan showed no other hypermetabolic foci. Needle biopsy revealed poorly-differentiated lung adenocarcinoma.

He was not a surgical candidate owing to poor pulmonary function, and was appropriate for SBRT. On CT simulation including a four-dimensional (4D) and free-breathing CT, new distal segmental atelectasis was noted near the nodule (Figure 1A). The target was delineated as an internal target volume (ITV) based on maximum intensity projection (MIP) generated by 4DCT simulation, with an additional 5 mm expansion to create the planning target volume (PTV). He then started Volumetric Modulated Arc Therapy to the right lower lobe PTV at a dose of 5000 cGy in 5 daily fractions. Daily kV CBCT was used for IGRT on a TrueBeamSTx LINAC. After the first dose, the tumor was found to have translocated 15mm anteroinferiorly due to re-expansion of segmental atelectasis as demonstrated by the kV CBCT prior to the second fraction. Of note, the movement was significant enough that it was only partially covered by the PTV. He underwent re-simulation, which confirmed the geometric target migration (Figure 1B and C). SBRT was re-adjusted for the new target location after migration. For subsequent fractions, daily kV CBCTs validated tumor position within the ITV; the remainder of therapy was completed uneventfully. Post-treatment CT showed resolution of disease at 4 mo post-SBRT.

DISCUSSION

Although surgery is currently the principal option for early-stage NSCLC patients that are medically operable, stereotactic body radiotherapy (SBRT) has emerged as the option of choice for patients who are medically inoperable. SBRT is a technique that administers high doses of radiation to the target while minimizing the dose to surrounding normal tissues. Reports show high local tumor control rates upwards of 90%, with severe toxicities well under 10%^[14]. This has made it a favorable option for medically inoperable patients with stage I NSCLC, endorsed by both the National Comprehensive Cancer Network (NCCN) Guidelines

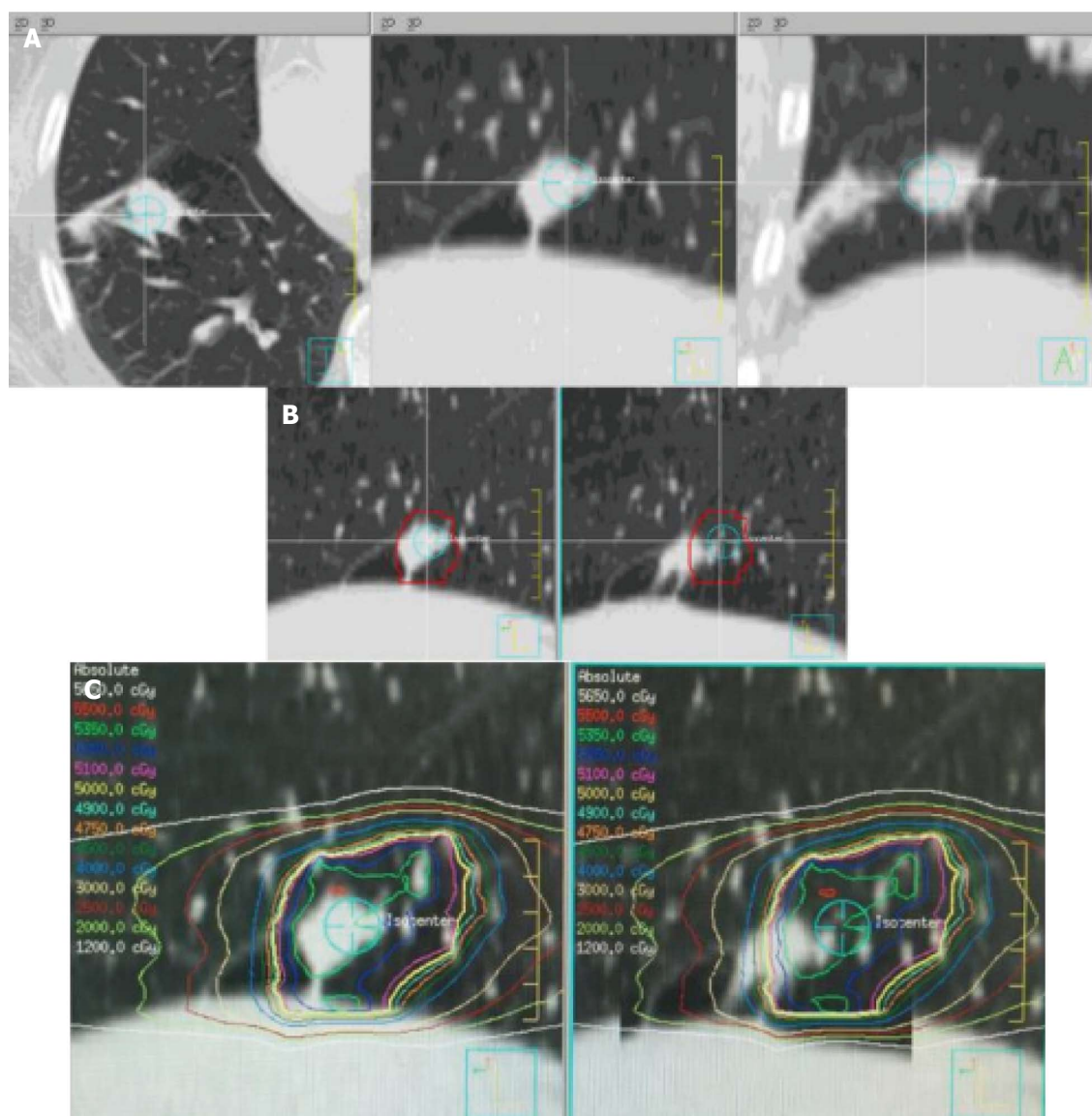


Figure 1 Computed tomography simulation including a four-dimensional and free-breathing computed tomography. A: Computed tomography (CT) images at simulation (left to right; axial, sagittal, and coronal views) showing the tumor, treatment isocenter, and the adjacent segmental atelectasis (best pictured on coronal image, lateral to isocenter); B: Left panel shows the tumor enclosed within the planning target volume (PTV) on the initial simulation CT; right panel demonstrates the translocation as compared with the original PTV on the re-CT after the first fraction. Sagittal views are shown in both panels; C: Dose distribution of initial (left) and translocated (right) tumor with isodose line values provided on left. Sagittal views are shown in both panels.

and the European Society of Medical Oncology (ESMO) Clinical Practice Guidelines^[15].

However, accounting for target and respiratory motion presents a challenge to proper delivery. Hence, in order to verify target location with high accuracy, high-fidelity IGRT is considered essential to SBRT. In our case report, the target translocated 15 mm anteriorly and inferiorly due to re-expansion of adjacent atelectasis after the first fraction. Without soft tissue discrimination in cross-sectional imaging, 2D IGRT based on bony anatomy only would have resulted in systematically missing the tumor in the remaining 4 fractions. These advantages of 3D IGRT are highlighted in anatomic areas liable to changes in morphology.

There have been several studies describing the utility of IGRT in SBRT. A study was carried out to evaluate

the potential of image guidance, gating and real-time tumor tracking to improve accuracy in pulmonary SBRT. It illustrated that CBCT-based IGRT for pre-treatment verification of the target position and online correction of errors reduced safety margins most effectively in pulmonary SBRT^[16]. Another recent study illustrated that application of continuous monitoring and intra-fraction target position correction during treatment improved the target coverage for patients in prostate SBRT. Without these IGRT techniques, intra-fractional motion would have significantly altered coverage in about 10% of patients^[17]. These studies have demonstrated that inter-fractional, and possibly even intra-fractional IGRT, can improve SBRT delivery. We advocate for increased use of cross-sectional imaging IGRT with soft tissue definition, especially in cases of tumors near potentially "anatomically volatile" areas.

While such large translocations such as reported here may be unlikely, intra-fractional real-time tumor tracking may provide additional benefit. An ionization radiation-free system using thoracic transducers and radiofrequency tracking using the Calypso system is under development (Varian Medical Systems, Palo Alto, CA, United States).

In summary, image guidance is a prerequisite for SBRT delivery, but 2D IGRT systems that solely align patients based on rigid bony anatomy may be notably inadequate in some cases. Instead, the use of imaging that provides cross-sectional soft tissue anatomical information to verify the target may prevent systematic misses from changes in target position.

COMMENTS

Case characteristics

A 72-year-old man of stage I non-small cell lung cancer associated with segmental atelectasis that translocated owing to re-expansion of the adjacent segmental atelectasis following the first dose of stereotactic body radiation therapy (SBRT).

Clinical diagnosis

Lung re-expansion of segmental atelectasis.

Differential diagnosis

Diminished breath sounds, pulmonary function, positron emission tomography scan and needle biopsy.

Laboratory diagnosis

The patient was not a surgical candidate owing to poor pulmonary function, and was appropriate for SBRT.

Imaging diagnosis

Re-simulation with high resolution computed tomography (CT) and image comparison using ridged image registration of primary CT simulation images confirmed geographic moves of the tumor due to re-expansion of an adjacent pulmonary atelectasis.

Pathological diagnosis

Needle biopsy showed poorly-differentiated lung adenocarcinoma.

Treatment

Daily kV cone-beam computed tomography was used for IGRT during SBRT.

Related reports

Related reports have demonstrated that inter-fractional, and possibly even intra-fractional IGRT, can improve SBRT delivery.

Term explanation

Non-small cell lung cancer is a deadly disease that may threaten people's life.

Experiences and lessons

Image guidance is extremely important for SBRT delivery.

Peer-review

This is an interesting case report worthy for publication. The authors reported on an early-stage lung tumor undergoing SBRT, translocating outside of the PTV after re-inflation of nearby atelectasis. The case herein presented highlight the risks of relying on IGRT system based on rigid anatomy alone. The manuscript is original, well-written and summarized in very explanatory figures.

REFERENCES

- 1 **Verma V.** Stereotactic Radiotherapy Versus Surgery for Early-Stage Operable Lung Cancer: More Questions Than Answers. *J Natl Compr Canc Netw* 2015; **13**: 1293-1295 [PMID: 26483066]
- 2 **Verma V, Zhen W.** Treatment Costs of Early-Stage Lung Cancers Detected by Low-Dose Computed Tomography Screening. *Int J Radiat Oncol Biol Phys* 2015; **93**: 207-208 [PMID: 26279036 DOI: 10.1016/j.ijrobp.2015.03.036]
- 3 **Verma V, Beriwal S.** Medicare Approves Coverage for Lung Cancer Screening: The Case for Symptomatic Screening. *JAMA Oncol* 2015; **1**: 1027-1028 [PMID: 26226384 DOI: 10.1001/jamaOncol.2015.2165]
- 4 **Verma V.** Lung cancer: Implementing lung-cancer screening--oncological 'grey areas'. *Nat Rev Clin Oncol* 2015; **12**: 256-257 [PMID: 25850551 DOI: 10.1038/nrclinonc.2015.65]
- 5 **Verma V, Shostrom VK, Kumar SS, Zhen W, Hallemeier CL, Braunstein SE, Holland J, Harkenrider MM, S Iskhanian A, Neboori HJ, Jabbour SK, Attia A, Lee P, Alite F, Walker JM, Stahl JM, Wang K, Bingham BS, Hadzitheodorou C, Decker RH, McGarry RC, Simone CB.** Multi-institutional experience of stereotactic body radiotherapy for large (≥ 5 centimeters) non-small cell lung tumors. *Cancer* 2017; **123**: 688-696 [PMID: 27741355 DOI: 10.1002/cncr.30375]
- 6 **Verma V, McMillan MT, Grover S, Simone CB.** Stereotactic Body Radiation Therapy and the Influence of Chemotherapy on Overall Survival for Large (≥ 5 Centimeter) Non-Small Cell Lung Cancer. *Int J Radiat Oncol Biol Phys* 2017; **97**: 146-154 [PMID: 27843029 DOI: 10.1016/j.ijrobp.2016.09.036]
- 7 **Verma V, Shostrom VK, Zhen W, Zhang M, Braunstein SE, Holland J, Hallemeier CL, Harkenrider MM, Iskhanian A, Jabbour SK, Attia A, Lee P, Wang K, Decker RH, McGarry RC, Simone CB.** Influence of Fractionation Scheme and Tumor Location on Toxicities Following Stereotactic Body Radiotherapy for Large (≥ 5 Centimeter) Non-Small Cell Lung Cancer: A Multi-Institutional Analysis. *Int J Radiat Oncol Biol Phys* 2016; **97**: 778-785 [DOI: 10.1016/j.ijrobp.2016.11.049]
- 8 **Chang JY, Dong L, Liu H, Starkschall G, Balter P, Mohan R, Liao Z, Cox JD, Komaki R.** Image-guided radiation therapy for non-small cell lung cancer. *J Thorac Oncol* 2008; **3**: 177-186 [PMID: 18303441 DOI: 10.1097/JTO.0b013e3181622bdd]
- 9 **Dahle M, Pearson S, Purdie T, Bissonnette JP, Franks K, Brade A, Cho J, Sun A, Hope A, Marshall A, Higgins J, Bezjak A.** Practical considerations arising from the implementation of lung stereotactic body radiation therapy (SBRT) at a comprehensive cancer center. *J Thorac Oncol* 2008; **3**: 1332-1341 [PMID: 18978570 DOI: 10.1097/JTO.0b013e31818b1771]
- 10 **Li Q, Mu J, Gu W, Chen Y, Ning Z, Jin J, Pei H.** Frameless stereotactic body radiation therapy for multiple lung metastases. *J Appl Clin Med Phys* 2014; **15**: 4737 [PMID: 25207400 DOI: 10.1120/jacmp.v15i4.4737]
- 11 **Yeung AR, Li JG, Shi W, Newlin HE, Chvetsov A, Liu C, Palta JR, Olivier K.** Tumor localization using cone-beam CT reduces setup margins in conventionally fractionated radiotherapy for lung tumors. *Int J Radiat Oncol Biol Phys* 2009; **74**: 1100-1107 [PMID: 19395197 DOI: 10.1016/j.ijrobp.2008.09.048]
- 12 **Grills IS, Hugo G, Kestin LL, Galerani AP, Chao KK, Wloch J, Yan D.** Image-guided radiotherapy via daily online cone-beam CT substantially reduces margin requirements for stereotactic lung radiotherapy. *Int J Radiat Oncol Biol Phys* 2008; **70**: 1045-1056 [PMID: 18029110 DOI: 10.1016/j.ijrobp.2007.07.2352]
- 13 **Wang Z, Nelson JW, Yoo S, Wu QJ, Kirkpatrick JP, Marks LB, Yin FF.** Refinement of treatment setup and target localization accuracy using three-dimensional cone-beam computed tomography for stereotactic body radiotherapy. *Int J Radiat Oncol Biol Phys* 2009; **73**: 571-577 [PMID: 19147021 DOI: 10.1016/j.ijrobp.2008.09.040]
- 14 **Timmerman R, Paulus R, Galvin J, Michalski J, Straube W, Bradley J, Fakiris A, Bezjak A, Videtic G, Johnstone D, Fowler J, Gore E, Choy H.** Stereotactic body radiation therapy for inoperable early stage lung cancer. *JAMA* 2010; **303**: 1070-1076 [PMID: 20233825 DOI: 10.1001/jama.2010.261]
- 15 **Senan S, Guckenberger M, Ricardi U.** Stage I non-small cell lung

cancer and oligometastatic disease. In: Pass HI, Ball D, Scagliotti GV, editors. IASLC textbook multidisciplinary approach to thoracic oncology textbook. Aurora, CO: International Association for the study of Lung Cancer; 2014

- 16 **Guckenberger M**, Krieger T, Richter A, Baier K, Wilbert J, Sweeney RA, Flentje M. Potential of image-guidance, gating and real-time tracking to improve accuracy in pulmonary stereotactic body

radiotherapy. *Radiother Oncol* 2009; **91**: 288-295 [PMID: 18835650 DOI: 10.1016/j.radonc.2008.08.010]

- 17 **Lovelock DM**, Messineo AP, Cox BW, Kollmeier MA, Zelefsky MJ. Continuous monitoring and intrafraction target position correction during treatment improves target coverage for patients undergoing SBRT prostate therapy. *Int J Radiat Oncol Biol Phys* 2015; **91**: 588-594 [PMID: 25680601 DOI: 10.1016/j.ijrobp.2014.10.049]

P- Reviewer: Arcangeli S, Sugawara I **S- Editor:** Kong JX

L- Editor: A **E- Editor:** Lu YJ





Published by **Baishideng Publishing Group Inc**
7901 Stoneridge Drive, Suite 501, Pleasanton, CA 94588, USA
Telephone: +1-925-223-8242
Fax: +1-925-223-8243
E-mail: bpgoffice@wjgnet.com
Help Desk: <http://www.f6publishing.com/helpdesk>
<http://www.wjgnet.com>

