

# World Journal of *Radiology*

*World J Radiol* 2017 May 28; 9(5): 217-252



**MINIREVIEWS**

- 217 Diffusion weighted imaging for the detection and evaluation of cholesteatoma  
*Henninger B, Kremser C*

**ORIGINAL ARTICLE****Basic Study**

- 223 Correlation of lumbar lateral recess stenosis in magnetic resonance imaging and clinical symptoms  
*Splettstößer A, Khan MF, Zimmermann B, Vogl TJ, Ackermann H, Middendorp M, Maataoui A*
- 230 Cystic lesions of peripheral nerves: Are we missing the diagnosis of the intraneural ganglion cyst?  
*Panwar J, Mathew A, Thomas BP*

**Retrospective Study**

- 245 Transarterial chemoembolization using 40 µm drug eluting beads for hepatocellular carcinoma  
*Greco G, Cascella T, Facciorusso A, Nani R, Lanocita R, Morosi C, Vaiani M, Calareso G, Greco FG, Ragnanese A, Bongini MA, Marchianò AV, Mazzaferro V, Spreafico C*

**ABOUT COVER**

Editorial Board Member of *World Journal of Radiology*, Mohamed F Bazeed, MSc, PhD, Associate Professor, Department of Radiology, Faculty of Medicine, Mansoura University, Mansoura 35111, Egypt

**AIM AND SCOPE**

*World Journal of Radiology* (*World J Radiol*, *WJR*, online ISSN 1949-8470, DOI: 10.4329) is a peer-reviewed open access academic journal that aims to guide clinical practice and improve diagnostic and therapeutic skills of clinicians.

*WJR* covers topics concerning diagnostic radiology, radiation oncology, radiologic physics, neuroradiology, nuclear radiology, pediatric radiology, vascular/interventional radiology, medical imaging achieved by various modalities and related methods analysis. The current columns of *WJR* include editorial, frontier, diagnostic advances, therapeutics advances, field of vision, mini-reviews, review, topic highlight, medical ethics, original articles, case report, clinical case conference (clinicopathological conference), and autobiography.

We encourage authors to submit their manuscripts to *WJR*. We will give priority to manuscripts that are supported by major national and international foundations and those that are of great basic and clinical significance.

**INDEXING/ABSTRACTING**

*World Journal of Radiology* is now indexed in PubMed, PubMed Central, and Emerging Sources Citation Index (Web of Science).

**FLYLEAF**

**I-III Editorial Board**

**EDITORS FOR THIS ISSUE**

**Responsible Assistant Editor:** Xiang Li  
**Responsible Electronic Editor:** Dan Li  
**Proofing Editor-in-Chief:** Lian-Sheng Ma

**Responsible Science Editor:** Jin-Xin Kong  
**Proofing Editorial Office Director:** Xiu-Xia Song

**NAME OF JOURNAL**  
*World Journal of Radiology*

**ISSN**  
ISSN 1949-8470 (online)

**LAUNCH DATE**  
January 31, 2009

**FREQUENCY**  
Monthly

**EDITORS-IN-CHIEF**  
**Kai U Juergens, MD, Associate Professor, MRT** und PET/CT, Nuklearmedizin Bremen Mitte, ZEMODI - Zentrum für morphologische und molekulare Diagnostik, Bremen 28177, Germany

**Edwin JR van Beek, MD, PhD, Professor, Clinical Research Imaging Centre and Department of Medical Radiology, University of Edinburgh, Edinburgh EH16 4TJ, United Kingdom**

**Thomas J Vogl, MD, Professor, Reader in Health Technology Assessment, Department of Diagnostic and Interventional Radiology, Johann Wolfgang Goethe University of Frankfurt, Frankfurt 60590,**

Germany

**EDITORIAL BOARD MEMBERS**  
All editorial board members resources online at <http://www.wjnet.com/1949-8470/editorialboard.htm>

**EDITORIAL OFFICE**  
Xiu-Xia Song, Director  
*World Journal of Radiology*  
Baishideng Publishing Group Inc  
7901 Stoneridge Drive, Suite 501, Pleasanton, CA 94588, USA  
Telephone: +1-925-2238242  
Fax: +1-925-2238243  
E-mail: [editorialoffice@wjnet.com](mailto:editorialoffice@wjnet.com)  
Help Desk: <http://www.f6publishing.com/helpdesk>  
<http://www.wjnet.com>

**PUBLISHER**  
Baishideng Publishing Group Inc  
7901 Stoneridge Drive, Suite 501, Pleasanton, CA 94588, USA  
Telephone: +1-925-2238242  
Fax: +1-925-2238243  
E-mail: [bpgoffice@wjnet.com](mailto:bpgoffice@wjnet.com)  
Help Desk: <http://www.f6publishing.com/helpdesk>  
<http://www.wjnet.com>

**PUBLICATION DATE**  
May 28, 2017

**COPYRIGHT**  
© 2017 Baishideng Publishing Group Inc. Articles published by this Open-Access journal are distributed under the terms of the Creative Commons Attribution Non-commercial License, which permits use, distribution, and reproduction in any medium, provided the original work is properly cited, the use is non commercial and is otherwise in compliance with the license.

**SPECIAL STATEMENT**  
All articles published in journals owned by the Baishideng Publishing Group (BPG) represent the views and opinions of their authors, and not the views, opinions or policies of the BPG, except where otherwise explicitly indicated.

**INSTRUCTIONS TO AUTHORS**  
<http://www.wjnet.com/bpg/gerinfo/204>

**ONLINE SUBMISSION**  
<http://www.f6publishing.com>

Retrospective Study

## Transarterial chemoembolization using 40 $\mu$ m drug eluting beads for hepatocellular carcinoma

Giorgio Greco, Tommaso Cascella, Antonio Facciorusso, Roberto Nani, Rodolfo Lanocita, Carlo Morosi, Marta Vaiani, Giuseppina Calareso, Francesca G Greco, Antonio Ragnanese, Marco A Bongini, Alfonso V Marchianò, Vincenzo Mazzaferro, Carlo Spreafico

Giorgio Greco, Tommaso Cascella, Rodolfo Lanocita, Carlo Morosi, Marta Vaiani, Giuseppina Calareso, Francesca G Greco, Alfonso V Marchianò, Carlo Spreafico, Department of Radiology, Interventional Radiology, Nuclear Medicine and Radiotherapy, National Cancer Institute, 20133 Milan, Italy

Antonio Facciorusso, Gastroenterology Unit, Ospedali Riuniti Foggia, University of Foggia, 71122 Foggia, Italy

Roberto Nani, Antonio Ragnanese, Radiology and Interventional Radiology Unit, Azienda Ospedaliera Giovanni Paolo XXIII, 24128 Bergamo, Italy

Marco A Bongini, Vincenzo Mazzaferro, Hepato-biliary Surgery and Liver Transplantation Unit, National Cancer Institute, 20133 Milan, Italy

**Author contributions:** Greco G collected data, performed the research, wrote the manuscript and made the revision; Greco G, Cascella T, Lanocita R, Morosi C, Marchianò AV, Spreafico C and Nani R performed TACEs and designed the study; Ragnanese A, Calareso G, Vaiani M and Greco FG collected data; Facciorusso A performed statistical analysis; Bongini MA and Mazzaferro V selected the patients, performed clinical support and follow-up, performed liver transplantation; Greco G and Spreafico C evaluated imaging follow-up; Spreafico C supervised the report.

**Institutional review board statement:** The study was reviewed and approved by the Ethics Committee of the National Cancer Institute of Milan.

**Informed consent statement:** Patients were not required to give informed consent to the study because the analysis used anonymous clinical data that were obtained after each patient agreed to treatment by written consent.

**Conflict-of-interest statement:** We have no financial relationships to disclose.

**Data sharing statement:** No additional data are available.

**Open-Access:** This article is an open-access article which was

selected by an in-house editor and fully peer-reviewed by external reviewers. It is distributed in accordance with the Creative Commons Attribution Non Commercial (CC BY-NC 4.0) license, which permits others to distribute, remix, adapt, build upon this work non-commercially, and license their derivative works on different terms, provided the original work is properly cited and the use is non-commercial. See: <http://creativecommons.org/licenses/by-nc/4.0/>

**Manuscript source:** Unsolicited manuscript

**Correspondence to:** Giorgio Greco, MD, Department of Radiology, Interventional Radiology, Nuclear Medicine and Radiotherapy, National Cancer Institute, Via Giacomo Venezian 1, 20133 Milan, Italy. [giorgio.greco@istitutotumori.mi.it](mailto:giorgio.greco@istitutotumori.mi.it)  
Telephone: +39-02-23903384  
Fax: +39-02-23902060

**Received:** December 10, 2016

**Peer-review started:** December 13, 2016

**First decision:** January 16, 2017

**Revised:** February 23, 2017

**Accepted:** March 12, 2017

**Article in press:** March 13, 2017

**Published online:** May 28, 2017

## Abstract

### AIM

To assess the safety and efficacy of transarterial chemoembolization (TACE) of hepatocellular carcinoma (HCC) using a new generation of 40  $\mu$ m drug eluting beads in patients not eligible for curative treatment.

### METHODS

Drug eluting bead TACE (DEB-TACE) using a new generation of microspheres (embosphere tandem, 40  $\mu$ m) preloaded with 100 mg of doxorubicin was performed on 48 early or intermediate HCC patients with compensated



cirrhosis. Response to therapy was assessed with Response Evaluation Criteria in Solid Tumors (RECIST) and modified RECIST (mRECIST) guidelines applied to computed tomography or magnetic resonance imaging. Eleven out of the 48 treated patients treated progressed on to receive liver orthotopic transplantation (OLT). This allowed for histological analysis on the treated explanted nodules.

## RESULTS

DEB-TACE with 40  $\mu$ m showed a good safety profile without major complications or 30-d mortality. The objective response rate of treated tumors was 72.6% and 26.7% according to mRECIST and RECIST respectively. Histological examination in 11 patients assigned to OLT showed a necrosis degree > 90% in 78.6% of cases. The overall time to progression was 13 mo (11-21).

## CONCLUSION

DEB-TACE with 40  $\mu$ m particles is an effective treatment for the treatment of HCC in early-intermediate patients (Barcelona Clinic Liver Cancer stage A/B) with a good safety profile and good results in term of objective response rate and necrosis.

**Key words:** Embozene tandem; Drug eluting beads; Drug eluting bead transarterial chemoembolization; Transarterial chemoembolization; Hepatocellular carcinoma

© The Author(s) 2017. Published by Baishideng Publishing Group Inc. All rights reserved.

**Core tip:** This is the first study exploring the safety and efficacy of 40  $\mu$ m drug eluting bead transarterial chemoembolization for the treatment of hepatocellular carcinoma (HCC) in a series of 48 patients not suitable for ablation or surgical therapies. The use of microspheres smaller than 100  $\mu$ m is not common practice in the western countries due to skepticism and fear of non-target embolization. Our aim is to present our initial experiences when treating with smaller microspheres so we all can test the potential advantages inherent to them and evaluate the effectiveness in the treatment of HCC nodules.

Greco G, Cascella T, Facciorusso A, Nani R, Lanocita R, Morosi C, Vaiani M, Calareso G, Greco FG, Ragnanese A, Bongini MA, Marchianò AV, Mazzaferro V, Spreafico C. Transarterial chemoembolization using 40  $\mu$ m drug eluting beads for hepatocellular carcinoma. *World J Radiol* 2017; 9(5): 245-252 Available from: URL: <http://www.wjgnet.com/1949-8470/full/v9/i5/245.htm> DOI: <http://dx.doi.org/10.4329/wjr.v9.i5.245>

## INTRODUCTION

Transarterial chemoembolization (TACE) is the current standard of care for hepatocellular carcinoma (HCC)

in patients with multinodular disease, classified as intermediate stage (stage B) of the Barcelona Clinic Liver Cancer (BCLC) staging system<sup>[1]</sup>. Furthermore, in clinical practice, a number of patients with early stage (stage A) disease, not eligible for curative treatment (surgery, transplantation or ablation) are commonly treated with TACE<sup>[2,3]</sup>.

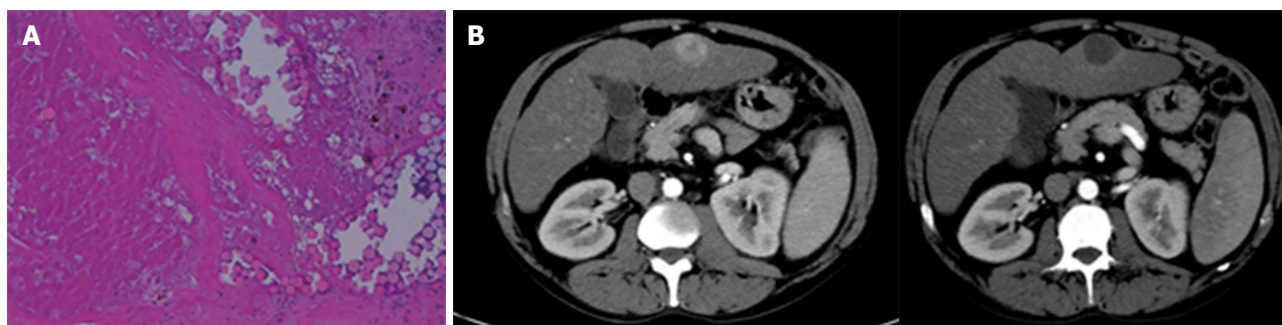
Conventional TACE (c-TACE) has shown superiority over basic supportive care in unresectable HCC in two randomised studies published in the early 2000s<sup>[4,5]</sup> and in a meta-analysis published in 2003<sup>[6]</sup>.

Recently developed drug eluting beads (DEB) have the ability to bind and carry up to double the doxorubicin dose<sup>[7,8]</sup> thus overcoming the common drawbacks of c-TACE such as the release of the chemotherapeutic agent into the systemic circulation.

DEB-TACE superiority over c-TACE or TACE superiority over transarterial embolization has not been proven in recent studies<sup>[9,10]</sup> both in terms of survival and as objective response to treatment. These new microspheres have ensured a reduction in the systemic concentration of the loaded chemotherapeutic agent, with a lower rate of post-procedural toxicity compared to c-TACE<sup>[11-13]</sup>. The first available microspheres had a diameter ranging between 500 and 900  $\mu$ m that has gradually reduced over the years to let DEB penetrate deeper into tumor circulation arterioles. This theory is supported by recently published controlled studies on smaller microspheres that show encouraging preliminary data on the radiological response in terms of extensive intratumoral necrosis<sup>[14,15]</sup>.

Embozene tandem 40  $\mu$ m (Boston Scientific, Minneapolis, MA, United States) are a new size of tightly calibrated spherical drug-eluting beads able to load up 100 mg of doxorubicin in a 2 mL syringe, or 150 mg in a 3 mL syringe. These biocompatible, non-resorbable, hydrogel microspheres are coated with an inorganic perfluorinated polymer (Polyzene®-F). They show a small increase in size (< 5% of the original diameter) during drug loading and storage if compared with similar DEB on the market. Dc-Beads M1 (initial diameter 70-150  $\mu$ m) show a dehydration and loss in size after loading drug; Hepashere (initial diameter 30-60  $\mu$ m), instead, show an increase in size up to 4 times of the initial diameter, resulting in a final diameter between 120-240  $\mu$ m after loading drug. Smaller microspheres theoretically allow for more distal vascular penetration and more homogeneous intratumoral drug distribution, with no meaningful evidence of better results in terms of objective response if compared to 100-300  $\mu$ m particles<sup>[16]</sup>.

The aim of this study was to assess the efficacy and safety of 40  $\mu$ m DEB-TACE in a series of 48 early-intermediate HCC patients complying with eligibility criteria. Primary endpoint was the evaluation of adverse events and complications related to TACE as well as the tumor response rate, considered as best achieved response. Secondary outcomes were the time to progressions (TTP) and time to response (TTR).



**Figure 1** Patient with evidence of a ca. 32 mm tumor with arterial blood flow typical of hepatocellular carcinoma (wash-in phase at the centre of the image) in segment 3 treated with a single cycle of transarterial chemoembolization. A: Corresponding histological image of the tumor after transplantation: Particles can be seen inside the afferent arterioles of the tumor, documenting 100% necrosis; B: The follow-up CT scan after TACE observed complete response according to mRECIST. TACE: Transarterial chemoembolization; mRECIST: Modified Response Evaluation Criteria in Solid Tumors; CT: Computed tomography.

## MATERIALS AND METHODS

### Study population

Data from 48 early-intermediate HCC patients (BCLC stage A/B) referred to our two tertiary centers between May 2013 and May 2015 and treated with DEB-TACE using 40  $\mu$ m microspheres were retrospectively analysed (Table 1). All patients signed a dedicated informed consent form. A multidisciplinary team made up of interventional radiologists, oncologists, hepatologists, pathologists and hepatic surgeons selected candidates for the treatment.

All patients were asymptomatic at enrolment (performance status 0) with cirrhotic disease related to hepatitis C in 56.2% of cases (27/48). Fifty-six point two percent of patients were in BCLC B stage, while 43.8% were in early stage A. All patients presented with a preserved liver function (93.4% Child-Pugh A and 6.6% Child-Pugh B7). Other comorbidities were reported in approximately half of the study population (notably Diabetes, Arterial Hypertension and Chronic Obstructive Pulmonary Disease). No tumors receiving DEB-TACE had been previously treated. The mean number of tumors was 2 (range 1-4) with 30 mm (range 10-96) maximum mean diameter, and the mean sum of all maximum diameters came up to 44 mm (range 13-130).

Patient eligibility was established with the following inclusion criteria: Age > 18 years; HCC diagnosis according to the current guidelines<sup>[1-3]</sup>; Early/intermediate patients not eligible for percutaneous or surgical ablative therapies; well compensated cirrhosis with Child-Pugh Score up to B7; performance status 0 according to the Eastern Cooperative Oncology Group.

Exclusion criteria included bilirubin > 2 mg/dL; principal (main trunk) or segmental portal thrombosis; previous treatments on target tumors (ablation, TACE, Sorafenib); intolerance to doxorubicin (leukocyte count < 3000/mm<sup>3</sup>; cardiac ejection fraction < 50%); aspartate amino transferase and alanine amino transferase levels > 270 IU/mL, and patients receiving angiogenesis agents or affected by uncorrectable coagulation disorders.

### Imaging study protocols

To assess the disease extent in the liver, its vascular

pattern and possible intrahepatic vascular invasions, all patients received pre-treatment abdominal imaging with computed tomography (CT) 128 slices (Somatom Definition Flash, Siemens Healthcare, Erlangen, Germany) or with magnetic resonance imaging (MRI) 1.5 T (Achieva, Philips Healthcare, Best, the Netherlands). In addition to that, they received a CT scan of the chest for a complete staging of the extrahepatic disease.

CT image acquisition technique, before and after treatment, required both a baseline abdominal scan and the arterial, portal and late venous phase study after intravenous administration of a 120-140 mL bolus of iodinated contrast medium (Iopamiro 370 mg/dL, Bracco, Milan, Italy) at an injection flow of 4 mL/s with the Bolus Tracking technique.

The protocol for abdominal MRI required the acquisition of in-phase and out-of-phase T1 weighted sequences, T2 weighted Half-Fourier acquisition Single-shot Turbo-spin Echo (HASTE) and Fat-Saturated (FAT-SAT) sequences, diffusion study and Tissue High Resolution Isotropic Voxel Excitation sequences [T1 weighted FAT-SAT and 3D GRE (3D GradientEcho)] both before and after infusion of Gadolinium-EthOxyBenzyl-Diethylene Triamine Pentaacetic Acid (Gd-EOB-DTPA) 0.025 mmol/mL (Primovist, Bayer, Leverkusen, Germany) with acquisitions up to 20 min during the hepatospecific phase.

### DEB-TACE

TACE was performed using transfemoral arterial access route with a micro-puncture system by placing a 5F vascular introducer (Boston Scientific, Natick, MA, United States). The angiographic study of the superior mesenteric artery and the celiac trunk for the characterisation of hepatic vascular anatomy was performed using an angiography unit (Axiom Angiographic Unit, Siemens Healthcare, Erlanger, Germany), and a 5F catheter (Cobra or Simmons, Boston Scientific, Natick, MA, United States). The angiographic study of extrahepatic pathological branches in some HCC tumors (usually peripheral tumors) was based on a careful study of pre-TACE imaging or on missing parts of the pathological tumor vascularization at the selective angiographic study.

Selective studies of segmental and pathological feeding vessels were also performed using a coaxial

micro catheter (Progreat 2.7F, Terumo, Tokyo, Japan), with a highly selective administration of the treatment.

In cases presenting multifocal disease, the treatment never targeted more than three hepatic segments per session. DEB-TACE was performed using a 2 mL/100 mg of doxorubicin (Adriblastina, Pfizer, New York, NY, United States) loaded dose on embozene tandem 40  $\mu$ m microspheres.

In all performed DEB-TACE treatments embozene tandem 40  $\mu$ m microspheres were diluted in 20-30 mL of iodinated contrast medium (Iopamiro 370 mg/dL), slowly injected manually with a 3 mL syringe, applying gentle pressure, until blood flow stasis was induced<sup>[17]</sup>.

Vasodilator drugs *via* transcatheter intra-arterial were not administered before starting chemoembolization with a view to expand to the maximum the neoplastic vascular network and theoretically increase the penetration of the particles and, accordingly, the potential effectiveness of the treatment as reported by some authors<sup>[18]</sup>. Permanent or temporary embolizing materials were not used to complete DEB-TACE in some tumors of greater dimensions where vascular stasis with only 40  $\mu$ m drug eluting beads was not achieved. In such cases, a second treatment session has been scheduled after performing a CT/MRI investigation to assess that some conditions leading to the impossibility of repeating the treatment, such as the onset of ascites or portal vein thrombosis, had not occurred.

Access haemostasis was achieved by a mechanical system, as Exoseal (Cordis, Miami Lakes, FL, United States), and a subsequent manual compression for about 3-5 min until haemostasis was achieved.

Premedication included 100 mg of paracetamol (Paracetamolo 10 mg/mL S.A.L.F., Bergamo, Italy), 8 mg of ondansetron (Ondansetron 8 mg/4 mL Hikma, Fervença, Portugal) and 50 mg of ranitidine (Ranitidina 50 mg/5 mL, S.A.L.F., Bergamo, Italy). Intravenous antibiotic prophylaxis was administered with 2 g of cefazolin (Cefamizin, Pfizer, New York, NY, United States) consistent with the hospital internal guidelines.

### **Hospitalization, adverse events and toxicity**

Patients were discharged after a brief observation period (48-72 h). Clinical evaluation and assessment of treatment-related toxicity were performed on an outpatient basis with physician's visits and laboratory tests 12, 24 and 48 h after TACE, 4 wk later and every 3 mo thereafter. AE were defined as treatment related if occurred during hospital stay or within 30 d from treatment. Safety parameters were classified according to the Common Terminology Criteria for Adverse Events 4.0<sup>[19]</sup> at each follow-up visit.

### **Imaging evaluation and follow-up**

Two radiologists (Dr. Carlo Spreafico and Dr. Giorgio Greco) both experienced in interventional radiology and interventional hepatic imaging performed all radiological assessments independently.

Tumoral response to treatment was assessed according

to RECIST and mRECIST with a CT scan or MRI investigation performed 4 wk after DEB-TACE and, then, every 3 mo during the follow-up period<sup>[20]</sup>.

A second treatment session, according to the "on demand" policy, was scheduled in case of partial response (PR) or stable disease (SD) after performing blood chemistry tests documenting good preserved hepatic function and continuity in the eligibility criteria for treatment.

In case of repeated DEB-TACE sessions, only the best response was considered for analytical purposes since this has been recently proved a better predictor of survival than the initial response<sup>[21]</sup>. In patients submitted to OLT, the treated tumors were histologically analysed during the months after treatment with targeted definition of necrosis induced by TACE.

### **Statistical analysis**

The descriptive statistical analysis was expressed as median and range in the case of continuous variables and absolute numbers and percentage in the case of categorical ones. Time to best response and TTP were calculated with the Kaplan-Meier method, computed from the time of the first treatment and censored to the day of transplantation in transplant patients. All calculations were obtained with the SPSS software (IBM, Armonk, NY, United States). The statistical review of the study was performed by a biomedical statistician.

## **RESULTS**

### **DEB-TACE and radiological tumor response**

All procedures were performed without technical impediments that would prevent treatment of the target tumor. The two study sites performed an overall number of 73 TACE (47 segmental, 22 bisegmental and 4 trisegmental) on a total number of 128 tumors. 31 patients (64.7%) underwent one treatment cycle, 10 patients (20.8%) to 2 treatment cycles, 6 patients (12.5%) to 3 treatment cycles, and 1 patient to 4 treatment cycles (2%), with a mean number of treatments per patient of 1.45.

Response to treatment was assessed by classifying the tumors into three classes according to dimensional criteria, as specified in Table 2 (according to mRECIST) and Table 3 (according to RECIST). The objective response rate (CR + PR) was 26.8% and 69% for tumors smaller than 3 cm, 32.1% and 85.7% for tumors with diameters between 3 and 5 cm, 10% and 70% for tumors with diameter over 5 cm according to RECIST and mRECIST, respectively.

Considering all the treated tumors, the overall objective response rate (CR + PR) was 26.7% according to RECIST and 72.6% according to mRECIST. These data include all the 48 patients of our series. These results were calculated with RECIST and mRECIST criteria, based on the last available CT scan/MRI, with an overall mean follow-up period of 357 d (range 30-810).

### **Hystological tumor response in transplanted patients**

Eleven patients qualified for OLT after 15 overall cycles of DEB-TACE, with a mean number of treatments per



**Table 1** Demographic characteristics and tumoral parameters of the study population, *n* (%)

Age (yr)	67 (49-95)
Sex	
Male	42 (87.5)
Female	6 (13.5)
Aetiology	
HCV	27 (56.2)
HBV	9 (18.75)
Alcohol	6 (12.5)
Cryptogenetic	3 (6.25)
NASH	3 (6.25)
Child-Pugh	
A	45 (93.4)
B	3 (6.6)
MELD	8 (6-14)
BCLC	
A	21 (43.8)
B	27 (56.2)
ECOG 0	48 (100)
Portal hypertension	
Yes	22 (45.9)
No	26 (54.1)
Tumour extension	
Unilobar	29 (60.4)
Bilobar	19 (39.6)
No. of tumors (target)	
Total	128
Median	2 (1-4)
Max. diameter (mm)	30 (10-96)
Sum of diameters (mm)	44 (13-130)
TACE	
Total cycles	73
Segmental	47 (64.4)
Bisegmental	22 (30.1)
Trisegmental	4 (5.5)

TACE: Transarterial chemoembolization; HBV: Hepatitis B virus; HCV: Hepatitis C virus; NASH: Nonalcoholic steatohepatitis; MELD: Model for end-stage liver disease; BCLC: Barcelona Clinic Liver Cancer; ECOG: Eastern Cooperative Oncology Group.

patient of 1.36. Seven out of 11 patients received 1 treatment, with remaining 4 receiving 2 treatments. Median time elapsed between TACE and OLT was 4.8 mo (95%CI: 2.3-6.5). The histological examination (Table 4) performed on 11 explanted livers reported a total number of 14 tumors of HCC, 10 of which were  $\leq 3$  cm and 4 were between 3 and 5 cm.

Among the tumors smaller than 3 cm, 7 presented 100% necrosis and 3 presented a necrosis rate below 50%. Two out of 4 tumors  $> 3$  cm presented a 100% necrosis rate (Figure 1), while the other 2 were above 90%.

#### DEB-TACE: Adverse events and toxicity

Toxicity data are reported in Table 5. All the observed AE were mild and transient, with no grade 3/4 toxicity reported. There were no cases of post procedure mortality within 30 d.

No major AE were recorded, neither systemically (pulmonary embolism, splenic infarction, gastrointestinal mucosal tumors, acute pancreatitis or cholecystitis,

**Table 2** Target lesions: Modified Response Evaluation Criteria in Solid Tumors response rate

$\varnothing$ nodules	No. of nodules	CR	PR	SD	PD
$\varnothing < 3$ cm	77	47.4%	21.6%	27.8%	3.2%
$3 \leq \varnothing \leq 5$ cm	22	42.8%	42.8%	10.8%	3.6%
$\varnothing > 5$ cm	3	40%	30%	30%	0%
Overall response	102	46%	26.6%	24.4%	3%

CR: Complete response; PR: Partial response; SD: Stable disease; PD: Progressive disease.

**Table 3** Target lesions: Response Evaluation Criteria in Solid Tumors response rate

$\varnothing$ nodules	No. of nodules	CR	PR	SD	PD
$\varnothing < 3$ cm	77	6.2%	20.6%	66%	7.2%
$3 \leq \varnothing \leq 5$ cm	22	3.5%	28.6%	64.4%	3.5%
$\varnothing > 5$ cm	3	0%	10%	90%	0%
Overall response	102	5.2%	21.5%	67.4%	5.9%

CR: Complete response; PR: Partial response; SD: Stable disease; PD: Progressive disease.

**Table 4** Histological response rate of treated nodules in patients submitted to orthotopic transplantation

$\varnothing$ nodules	Degree of necrosis		
	100%	$> 90\%$	$< 50\%$
$\varnothing < 3$ cm	7	-	3
$3 \leq \varnothing \leq 5$ cm	2	2	-
Overall necrosis	9 (64.3%)	2 (14.3%)	3 (21.4%)

spinal cord injury) related to non-target embolization nor locally (hepatic infection or abscesses, ischemic hepatitis and bile duct injuries) due to local toxicity or ischemia<sup>[22]</sup>. Median hospital stay was 2 d (range 2-4). Post-embolization syndrome (PES) occurred in 15% of treatments (11/73). Other common AE were abdominal pain (24.6%) and nausea/vomiting (12.3%), which were treated with analgesic drugs and anti-emetics, and mild ascites (4.1%). Transient post procedure increase in transaminase levels occurred in 13.7% of cases (10/73). Other 1/2 grade laboratory tests alterations included a transient increase in bilirubin levels (6.8%).

#### TTR, TTP and progression free survival

The TTR for all patients was of 4 mo (95%CI: Range 1-4). Overall 24 patients (50%) experienced tumor progression through the study period. One-year progression free survival (PFS) was 64.5% whereas 2-year PFS was 52%. Median TTP was 13 mo (95%CI: Range: 11-21), calculated on mRECIST, as described in Figure 2.

## DISCUSSION

DEB-TACE is the standard of care for HCC intermediate stage patients and a valuable therapeutic option in



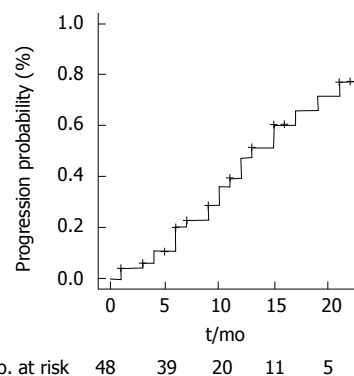
**Table 5** Adverse events

Toxicity	Grade 1/2	Grade 3/4
Clinical findings		
Post embolization syndrome	11/73 (15%)	-
Ascites	3/73 (4.1%)	-
Abdominal pain	18/73 (24.6%)	-
Nausea/vomiting	9/73 (12.3%)	-
Laboratory tests		
Bilirubin	5/73 (6.8%)	-
Transaminase	10/73 (13.7%)	-

BCLC A stage when curative approach is unfeasible<sup>[1,23]</sup>. Several consecutive sessions are usually needed for DEB-TACE to be effective, *i.e.*, the complete tumor response, so that the optimal treatment should lead to higher tumor necrosis rate with the lowest incidence of adverse event. DEB-TACE showed a low incidence of PES<sup>[13]</sup> and systemic toxicity than in previous reports<sup>[8]</sup>, but its superiority over c-TACE is still a matter of debate<sup>[10,24-26]</sup>.

Since the diameter of chemo loaded microspheres seems to be related to their therapeutic action<sup>[17,18]</sup>, studies on pharmacological kinetics have focused on producing smaller particles that could penetrate deeper into the tumor's vascular network. The most distal penetration of these microspheres reduces the phenomenon of hypoxic-ischaemic neoangiogenesis<sup>[27,28]</sup>. However, for embolization not associated with any drug (bland embolization), the use of particles with a diameter < 100  $\mu$ m presented a concerning rate of complications, especially in the treatment of large tumors<sup>[29,30]</sup>. Some complications in this type of procedures are related to the "non-target embolization" that is, the unwanted escape of microspheres outside the optimal area for treatment, which can affect other organs or unwanted areas of the same organ. Acute pancreatitis (0.88%-15.2%), acute cholecystitis (0.2%-5.4%), pulmonary embolism (0.17%-2.7%), splenic infarction (0.08%-1.4%), gastro-intestinal mucosal tumors (0.22%-0.7%), spinal cord injury (0.3%-1.2%) are among the possible extrahepatic complications<sup>[31]</sup>. Unwanted hepatic complications such as ischemic hepatitis (0.26%-15.4%), liver infarction or abscess (0.5%-2.7%) or bile duct injuries<sup>[31]</sup> are connected to local ischemic damages. Some recent studies have proven a very high degree of safety in the use of loadable particles with diameters below 100  $\mu$ m, with good preliminary efficacy results in terms of radiological and histological response to treatment<sup>[14,15,18]</sup>.

A new generation of microspheres (embozene tandem 40  $\mu$ m) has been recently marketed for selective intra-arterial treatment even though data on the efficacy and safety profile of the product is yet to be published. To our knowledge, this is the first report on the safety and efficacy of 40  $\mu$ m particles preloaded with doxorubicin in the treatment of HCC with DEB-TACE. The overall objective response rate (CR + PR) obtained has been of 26.7% to RECIST and 72.6% to mRECIST. This is comparable to the rates according to mRECIST of two recent series carried out with 70-150  $\mu$ m<sup>[14,15]</sup> and 30-60

**Figure 2** Time to progression.

$\mu$ m<sup>[18]</sup> (initial diameters) particles loaded with doxorubicin by Spreafico *et al.*<sup>[14]</sup> and Malagari *et al.*<sup>[18]</sup> respectively.

Cases of failed response to locoregional therapy, defined as progressive disease, were around 5.9% and 3% with RECIST and mRECIST, respectively. Median TTP was 13 mo (11-21), an interesting and slightly better result if compared with previous published trials using other microspheres. Moreover, it is to be considered that we did not restrict progression analysis only to local progression of target tumors, but also distant intrahepatic progressions and/or metastases occurrence were investigated.

In 11 patients out of the recruited 48, DEB-TACE was used as bridging therapy for OLT with a complete pathological response (meant as a 100% necrosis in the histological evaluation) in 64.3% cases (9/14 tumors). Tumors smaller than 3 cm shown a better response in term of histological necrosis (70% complete necrosis), compared to those larger than 3 cm (50% complete necrosis). These histological results are consistent with those reported elsewhere<sup>[32,33]</sup>.

The best radiological response was obtained with a single cycle in 60% of patients, with two cycles in 30% of cases and with three cycles in 10% of patients, with a TTR of about 4 mo (95%CI: Range: 4-6). The effectiveness of HCC treatment using TACE on demand has been proved in our series in the event of detection of SD or PR during the follow-up by CT or MRI, in line with data in the literature. The very low toxicity rates observed in our series are probably a consequence of the high selectivity of the procedure ensured by the use of smaller particles.

The procedures were generally well tolerated. Recorded toxicity levels were lower than recent studies using larger diameter microspheres and consistent with two other studies concerning microspheres with a pre-loading diameter between 70-150  $\mu$ m<sup>[14,15]</sup> and 30-60  $\mu$ m<sup>[18]</sup>.

The incidence of PES was to be lower than the percentages published in other series<sup>[11,12,14,18]</sup> with particles having similar or larger dimensions, most likely due to the selectivity of the procedure and possible sparing of a larger area of peritumoral hepatic parenchyma.

To our knowledge this is the first series regarding the use of 40  $\mu$ m DEB in HCC treatment. This is interesting

for world community and especially for western countries where there is skepticism about using particles smaller than 100  $\mu$ m for DEB-TACE due to the non-target embolization danger. Our preliminary experience shows that 40  $\mu$ m DEB-TACE is a highly effective and safe technique for HCC non suitable to ablation or surgery therapies with a low rate of PES and no major complications, either local or systemic. The results are complete for all the 48 patients and for 11 of them a histologically proven response to DEB-TACE on surgical specimen is available. Objective local response reached 72.6% and 26.7% according to mRECIST and RECIST without damage to adjacent healthy liver as evidenced by imaging, histology and liver biochemistry. The study has some limitations such as the retrospective nature, the single series and the small sample of patients. Further studies with a longer follow-up period and a bigger sample should be planned to confirm our results.

The results of this retrospective study indicate that DEB-TACE with 40  $\mu$ m particles is an effective and safe treatment for early-intermediate HCC patients not eligible for curative treatment with good results in term of objective response rate and necrosis.

## COMMENTS

### Background

Transarterial chemoembolization (TACE) is the current standard of care for hepatocellular carcinoma (HCC) in patients with multinodular disease, classified as intermediate stage (stage B) to Barcelona Clinic Liver Cancer (BCLC) Staging System or in patients in early stage (stage A) not eligible for curative treatment (surgery, liver transplantation or percutaneous ablative treatments). Conventional TACE (c-TACE) has shown superiority over basic supportive care in unresectable HCC in literature since the early 2000s. Actually there is no evidence of superiority of drug eluting bead TACE (DEB-TACE) on c-TACE or transarterial embolization in literature. In the last fifteen years many particles with diameters gradually smaller have been developed for DEB-TACE. These new 40  $\mu$ m diameter drug eluting beads theoretically penetrate deeper into tumor circulation arterioles reducing the phenomenon of hypoxic-ischaemic neoangiogenesis due to transarterial embolization. There is no evidence in literature of DEB-TACE superiority over c-TACE in terms of efficacy. The only demonstrated advantage is the reduced rate of post embolic syndrome.

### Research frontiers

The authors' report on 40  $\mu$ m DEB-TACE for HCC is the first experience in literature. The weakness points are the small sample of patients and the retrospective design of the study but it can represent an interesting report for scientific community as first evaluation of safety and efficacy of this new generation of microparticles. Further studies with a larger number of patients will be needed to confirm data and confirm or deny the theoretical benefits of this new generation of micro-particles in the treatment of HCC.

### Innovations and breakthroughs

The study confirms a degree of objective response to treatment, defined as complete or partial response according to Response Evaluation Criteria in Solid Tumors (RECIST) and modified RECIST applied to computed tomography and magnetic resonance imaging, consistent with that of previous studies in the literature with a slightly higher caliber particles (40-60 and 70-150  $\mu$ m). The data is comforting when you consider the lack of intra or extrahepatic complications due to the phenomenon of non-target embolization, cause for concern in Western countries where the DEBTACE is widespread with larger gauge particles.

### Applications

This study suggests that 40  $\mu$ m DEBTACE is safe and effective in early-

intermediate HCC patients with compensated cirrhosis.

### Terminology

DEB-TACE: Drug eluting bead TACE; Nontarget embolization: Unwanted escape of particles outside the territory seat of treatment.

### Peer-review

This paper presented about the efficacy of TACE using drug eluting beads for HCC patients. This topic could be interesting for readers.

## REFERENCES

- 1 EASL-EORTC clinical practice guidelines: management of hepatocellular carcinoma. *J Hepatol* 2012; **56**: 908-943 [PMID: 22424438 DOI: 10.1016/j.jhep.2011.12.001]
- 2 Llovet JM, Bruix J. Systematic review of randomized trials for unresectable hepatocellular carcinoma: Chemoembolization improves survival. *Hepatology* 2003; **37**: 429-442 [PMID: 12540794 DOI: 10.1053/jhep.2003.50047]
- 3 Bruix J, Sherman M. Management of hepatocellular carcinoma: an update. *Hepatology* 2011; **53**: 1020-1022 [PMID: 21374666 DOI: 10.1002/hep.24199]
- 4 Llovet JM, Real MI, Montaña X, Planas R, Coll S, Aponte J, Ayuso C, Sala M, Muchart J, Solà R, Rodés J, Bruix J. Arterial embolisation or chemoembolisation versus symptomatic treatment in patients with unresectable hepatocellular carcinoma: a randomised controlled trial. *Lancet* 2002; **359**: 1734-1739 [PMID: 12049862 DOI: 10.1016/S0140-6736(02)08649-X]
- 5 Lo CM, Ngan H, Tso WK, Liu CL, Lam CM, Poon RT, Fan ST, Wong J. Randomized controlled trial of transarterial lipiodol chemoembolization for unresectable hepatocellular carcinoma. *Hepatology* 2002; **35**: 1164-1171 [PMID: 11981766 DOI: 10.1053/jhep.2002.33156]
- 6 Llovet JM, Burroughs A, Bruix J. Hepatocellular carcinoma. *Lancet* 2003; **362**: 1907-1917 [PMID: 14667750 DOI: 10.1016/S0140-6736(03)14964-1]
- 7 Poon RT, Tso WK, Pang RW, Ng KK, Woo R, Tai KS, Fan ST. A phase I/II trial of chemoembolization for hepatocellular carcinoma using a novel intra-arterial drug-eluting bead. *Clin Gastroenterol Hepatol* 2007; **5**: 1100-1108 [PMID: 17627902 DOI: 10.1016/j.cgh.2207.04.021]
- 8 Varela M, Real MI, Burrell M, Forner A, Sala M, Brunet M, Ayuso C, Castells L, Montaña X, Llovet JM, Bruix J. Chemoembolization of hepatocellular carcinoma with drug eluting beads: efficacy and doxorubicin pharmacokinetics. *J Hepatol* 2007; **46**: 474-481 [PMID: 17239480 DOI: 10.1016/j.jhep.2006.10.020]
- 9 Brown KT, Do RK, Gonen M, Covey AM, Getrajdman GI, Sofocleous CT, Jarnagin WR, D'Angelica MI, Allen PJ, Erinjeri JP, Brody LA, O'Neill GP, Johnson KN, Garcia AR, Beattie C, Zhao B, Solomon SB, Schwartz LH, DeMatteo R, Abou-Alfa GK. Randomized Trial of Hepatic Artery Embolization for Hepatocellular Carcinoma Using Doxorubicin-Eluting Microspheres Compared With Embolization With Microspheres Alone. *J Clin Oncol* 2016; **34**: 2046-2053 [PMID: 26834067 DOI: 10.1200/JCO.2015.64.0821]
- 10 Sacco R, Bargellini I, Bertini M, Bozzi E, Romano A, Petrucci P, Tumino E, Ginanni B, Federici G, Cioni R, Metrangola S, Bertoni M, Bresci G, Parisi G, Altomare E, Capria A, Bartolozzi C. Conventional versus doxorubicin-eluting bead transarterial chemoembolization for hepatocellular carcinoma. *J Vasc Interv Radiol* 2011; **22**: 1545-1552 [PMID: 21849247 DOI: 10.1016/j.jvir.2011.07.00217]
- 11 Lammer J, Malagari K, Vogl T, Pilleul F, Denys A, Watkinson A, Pitton M, Sergeant G, Pfammatter T, Terraz S, Benhamou Y, Avajon Y, Gruenberger T, Pomoni M, Langenberger H, Schuchmann M, Dumortier J, Mueller C, Chevallier P, Lencioni R. Prospective randomized study of doxorubicin-eluting-bead embolization in the treatment of hepatocellular carcinoma: results of the PRECISION V study. *Cardiovasc Intervent Radiol* 2010; **33**: 41-52 [PMID: 20101010 DOI: 10.1007/s00261-010-0500-0]

- 19908093 DOI: 10.1007/s00270-099-9711-7]
- 12 **Song MJ**, Chun HJ, Song DS, Kim HY, Yoo SH, Park CH, Bae SH, Choi JY, Chang UI, Yang JM, Lee HG, Yoon SK. Comparative study between doxorubicin-eluting beads and conventional transarterial chemoembolization for treatment of hepatocellular carcinoma. *J Hepatol* 2012; **57**: 1244-1250 [PMID: 22824821 DOI: 10.1016/j.jhep.2012.07.017]
- 13 **Facciorusso A**, Di Maso M, Muscatiello N. Drug-eluting beads versus conventional chemoembolization for the treatment of unresectable hepatocellular carcinoma: A meta-analysis. *Dig Liver Dis* 2016; **48**: 571-577 [PMID: 26965785 DOI: 10.1016/j.dld.2016.02.005]
- 14 **Spreafico C**, Cascella T, Facciorusso A, Sposito C, Rodolfo L, Morosi C, Civelli EM, Vaiani M, Bhoori S, Pellegrinelli A, Marchianò A, Mazzaferro V. Transarterial chemoembolization for hepatocellular carcinoma with a new generation of beads: clinical-radiological outcomes and safety profile. *Cardiovasc Intervent Radiol* 2015; **38**: 129-134 [PMID: 24870698 DOI: 10.1007/s00270-014-0907-0]
- 15 **Odísio BC**, Ashton A, Yan Y, Wei W, Kaseb A, Wallace MJ, Vauthey JN, Gupta S, Tam AL. Transarterial hepatic chemoembolization with 70-150  $\mu$ m drug-eluting beads: assessment of clinical safety and liver toxicity profile. *J Vasc Interv Radiol* 2015; **26**: 965-971 [PMID: 25979305 DOI: 10.1016/j.jvir.2015.03.020]
- 16 **Blümmel J**, Reinhardt S, Schäfer M, Gilbert C, Sun L, Ren J. Drug-eluting Beads in the Treatment of Hepatocellular Carcinoma and Colorectal Cancer Metastases to the Liver. *Eur Oncol Haematol* 2012; **8**: 162-166 [DOI: 10.17925/EOH.2012.08.3.162]
- 17 **Lencioni R**, de Baere T, Burrel M, Caridi JG, Lammer J, Malagari K, Martin RC, O'Grady E, Real MI, Vogl TJ, Watkinson A, Geschwind JF. Transcatheter treatment of hepatocellular carcinoma with Doxorubicin-loaded DC Bead (DEBDOX): technical recommendations. *Cardiovasc Intervent Radiol* 2012; **35**: 980-985 [PMID: 22009576 DOI: 10.1007/s00270-011-0287-7]
- 18 **Malagari K**, Pomoni M, Moschouris H, Kelekis A, Charokopakis A, Bouma E, Spyridopoulos T, Chatziioannou A, Sotirchos V, Karampelas T, Tamvakopoulos C, Filippiadis D, Karagiannis E, Marinis A, Koskinas J, Kelekis DA. Chemoembolization of hepatocellular carcinoma with HepaSphere 30-60  $\mu$ m. Safety and efficacy study. *Cardiovasc Intervent Radiol* 2014; **37**: 165-175 [PMID: 24263774 DOI: 10.1007/s00270-013-0777-x]
- 19 **National Cancer Institute**. Common terminology criteria for adverse events v4.0. NCI, NIH, DHHS. May 29, 2009. NIH publication 09-7473. Available from: URL: <http://www.hrc.govt.nz/sites/default/files/CTCAE manual - DMCC.pdf>
- 20 **Lencioni R**, Llovet JM. Modified RECIST (mRECIST) assessment for hepatocellular carcinoma. *Semin Liver Dis* 2010; **30**: 52-60 [PMID: 20175033 DOI: 10.1055/s-0030-1247132]
- 21 **Kim BK**, Kim SU, Kim KA, Chung YE, Kim MJ, Park MS, Park JY, Kim do Y, Ahn SH, Kim MD, Park SI, Won JY, Lee DY, Han KH. Complete response at first chemoembolization is still the most robust predictor for favorable outcome in hepatocellular carcinoma. *J Hepatol* 2015; **62**: 1304-1310 [PMID: 25637785 DOI: 10.1016/j.jhep.2015.01.022]
- 22 **Xia J**, Ren Z, Ye S, Sharma D, Lin Z, Gan Y, Chen Y, Ge N, Ma Z, Wu Z, Fan J, Qin L, Zhou X, Tang Z, Yang B. Study of severe and rare complications of transarterial chemoembolization (TACE) for liver cancer. *Eur J Radiol* 2006; **59**: 407-412 [PMID: 16621394 DOI: 10.1016/j.ejrad.2006.03.002]
- 23 **Malagari K**, Alexopoulou E, Chatzimichail K, Hall B, Koskinas J, Ryan S, Gallardo E, Kelekis A, Gouliamos A, Kelekis D. Transcatheter chemoembolization in the treatment of HCC in patients not eligible for curative treatments: midterm results of doxorubicin-loaded DC bead. *Abdom Imaging* 2008; **33**: 512-519 [PMID: 17938995 DOI: 10.1007/s00261-007-9334-x]
- 24 **Golfieri R**, Giampalma E, Renzulli M, Cioni R, Bargellini I, Bartolozzi C, Breatta AD, Gandini G, Nani R, Gasparini D, Cucchetti A, Bolondi L, Trevisani F. Randomised controlled trial of doxorubicin-eluting beads vs conventional chemoembolisation for hepatocellular carcinoma. *Br J Cancer* 2014; **111**: 255-264 [PMID: 24937669 DOI: 10.1038/bjc.2014.199]
- 25 **Xie ZB**, Wang XB, Peng YC, Zhu SL, Ma L, Xiang BD, Gong WF, Chen J, You XM, Jiang JH, Li LQ, Zhong JH. Systematic review comparing the safety and efficacy of conventional and drug-eluting bead transarterial chemoembolization for inoperable hepatocellular carcinoma. *Hepatol Res* 2015; **45**: 190-200 [PMID: 25388603 DOI: 10.1111/hepr.12450]
- 26 **Facciorusso A**, Mariani L, Sposito C, Spreafico C, Bongini M, Morosi C, Cascella T, Marchianò A, Camerini T, Bhoori S, Brunero F, Barone M, Mazzaferro V. Drug-eluting beads versus conventional chemoembolization for the treatment of unresectable hepatocellular carcinoma. *J Gastroenterol Hepatol* 2016; **31**: 645-653 [PMID: 26331807 DOI: 10.1111/jgh.13147]
- 27 **Wang B**, Xu H, Gao ZQ, Ning HF, Sun YQ, Cao GW. Increased expression of vascular endothelial growth factor in hepatocellular carcinoma after transcatheter arterial chemoembolization. *Acta Radiol* 2008; **49**: 523-529 [PMID: 18568538 DOI: 10.1080/02841850801958890]
- 28 **Kobayashi N**, Ishii M, Ueno Y, Kisara N, Chida N, Iwasaki T, Toyota T. Co-expression of Bcl-2 protein and vascular endothelial growth factor in hepatocellular carcinomas treated by chemoembolization. *Liver* 1999; **19**: 25-31 [PMID: 9928762]
- 29 **Bonomo G**, Pedicini V, Monfardini L, Della Vigna P, Poretti D, Orgera G, Orsi F. Bland embolization in patients with unresectable hepatocellular carcinoma using precise, tightly size-calibrated, anti-inflammatory microparticles: first clinical experience and one-year follow-up. *Cardiovasc Intervent Radiol* 2010; **33**: 552-559 [PMID: 19957182 DOI: 10.1007/s00270-009-9752-y]
- 30 **Maluccio MA**, Covey AM, Porat LB, Schubert J, Brody LA, Sofocleous CT, Getrajdman GI, Jarman W, Dematteo R, Blumgart LH, Fong Y, Brown KT. Transcatheter arterial embolization with only particles for the treatment of unresectable hepatocellular carcinoma. *J Vasc Interv Radiol* 2008; **19**: 862-869 [PMID: 18503900 DOI: 10.1016/j.jvir.2008.02.013]
- 31 **López-Benítez R**, Richter GM, Kauczor HU, Stampfl S, Kladeck J, Radeleff BA, Neukamm M, Hallscheidt PJ. Analysis of nontarget embolization mechanisms during embolization and chemoembolization procedures. *Cardiovasc Intervent Radiol* 2009; **32**: 615-622 [PMID: 19387732 DOI: 10.1007/s00270-009-9568-9]
- 32 **Nicolini A**, Martinetti L, Crespi S, Maggioni M, Sangiovanni A. Transarterial chemoembolization with epirubicin-eluting beads versus transarterial embolization before liver transplantation for hepatocellular carcinoma. *J Vasc Interv Radiol* 2010; **21**: 327-332 [PMID: 20097098 DOI: 10.1016/j.jvir.2009.10.038]
- 33 **Nicolini D**, Svegliati-Baroni G, Candelari R, Mincarelli C, Mandolesi A, Bearzi I, Mocchegiani F, Vecchi A, Montalti R, Benedetti A, Risaliti A, Vivarelli M. Doxorubicin-eluting bead vs conventional transcatheter arterial chemoembolization for hepatocellular carcinoma before liver transplantation. *World J Gastroenterol* 2013; **19**: 5622-5632 [PMID: 24039354 DOI: 10.3748/wjg.v19.i34.5622]

**P- Reviewer:** Edeline J, Jin B, Ohira M **S- Editor:** Ji FF  
**L- Editor:** A **E- Editor:** Li D





Published by **Baishideng Publishing Group Inc**  
7901 Stoneridge Drive, Suite 501, Pleasanton, CA 94588, USA  
Telephone: +1-925-223-8242  
Fax: +1-925-223-8243  
E-mail: [bpgoffice@wjgnet.com](mailto:bpgoffice@wjgnet.com)  
Help Desk: <http://www.f6publishing.com/helpdesk>  
<http://www.wjgnet.com>

