

World Journal of *Orthopedics*

World J Orthop 2017 August 18; 8(8): 606-659



**EDITORIAL**

- 606 Ultrasound diagnosis of fractures in mass casualty incidents
Abu-Zidan FM

MINIREVIEWS

- 612 Postoperative deep shoulder infections following rotator cuff repair
Atesok K, MacDonald P, Leiter J, McRae S, Stranges G, Old J
- 619 Synthesis of evidence for the treatment of intersection syndrome
Balakatounis K, Angoules AG, Angoules NA, Panagiotopoulou K

ORIGINAL ARTICLE**Retrospective Study**

- 624 Ponseti method treatment of neglected idiopathic clubfoot: Preliminary results of a multi-center study in Nigeria
Adegbehingbe OO, Adetiloye AJ, Adewole L, Ajodo DU, Bello N, Esan O, Hoover AC, Ior J, Lasebikan O, Ojo O, Olasinde A, Songden D, Morcuende JA

Observational Study

- 631 Functional outcomes of traumatic and non-traumatic rotator cuff tears after arthroscopic repair
Abechain JJK, Godinho GG, Matsunaga FT, Netto NA, Daou JP, Tamaoki MJS

SYSTEMATIC REVIEWS

- 638 Ipsilateral femur and tibia fractures in pediatric patients: A systematic review
Anari JB, Neuwirth AL, Horn BD, Baldwin KD

META-ANALYSIS

- 644 Femoral positioning influences ipsi-and contralateral anterior cruciate ligament rupture following its reconstruction: Systematic review and meta-analysis
de Campos GC, Teixeira PEP, Castro A, Alves Junior WM

CASE REPORT

- 651 Open wound management of esophagocutaneous fistula in unstable cervical spine after corpectomy and multilevel laminectomy: A case report and review of the literature
Elgafy H, Khan M, Azurdia J, Peters N
- 656 Bennett's fracture associated with fracture of Trapezium - A rare injury of first carpo-metacarpal joint
Goyal T

Contents

World Journal of Orthopedics
Volume 8 Number 8 August 18, 2017

ABOUT COVER

Editorial Board Member of *World Journal of Orthopedics*, Melanie Jane Franklyn, PhD, Academic Fellow, Academic Research, Department of Mechanical Engineering, The University of Melbourne, Melbourne, Victoria 3010, Australia

AIM AND SCOPE

World Journal of Orthopedics (*World J Orthop*, *WJO*, online ISSN 2218-5836, DOI: 10.5312) is a peer-reviewed open access academic journal that aims to guide clinical practice and improve diagnostic and therapeutic skills of clinicians.

WJO covers topics concerning arthroscopy, evidence-based medicine, epidemiology, nursing, sports medicine, therapy of bone and spinal diseases, bone trauma, osteoarthropathy, bone tumors and osteoporosis, minimally invasive therapy, diagnostic imaging. Priority publication will be given to articles concerning diagnosis and treatment of orthopedic diseases. The following aspects are covered: Clinical diagnosis, laboratory diagnosis, differential diagnosis, imaging tests, pathological diagnosis, molecular biological diagnosis, immunological diagnosis, genetic diagnosis, functional diagnostics, and physical diagnosis; and comprehensive therapy, drug therapy, surgical therapy, interventional treatment, minimally invasive therapy, and robot-assisted therapy.

We encourage authors to submit their manuscripts to *WJO*. We will give priority to manuscripts that are supported by major national and international foundations and those that are of great basic and clinical significance.

INDEXING/ABSTRACTING

World Journal of Orthopedics is now indexed in Emerging Sources Citation Index (Web of Science), PubMed, PubMed Central and Scopus.

FLYLEAF

I-III Editorial Board

EDITORS FOR THIS ISSUE

Responsible Assistant Editor: *Xiang Li*
Responsible Electronic Editor: *Ya-Jing Lu*
Proofing Editor-in-Chief: *Lian-Sheng Ma*

Responsible Science Editor: *Fang-Fang Ji*
Proofing Editorial Office Director: *Jin-Lai Wang*

NAME OF JOURNAL
World Journal of Orthopedics

ISSN
ISSN 2218-5836 (online)

LAUNCH DATE
November 18, 2010

FREQUENCY
Monthly

EDITORS-IN-CHIEF
Quanjun (Trey) Cui, MD, Professor, Department of Orthopaedic Surgery, School of Medicine, University of Virginia, Charlottesville, VA 22908, United States

Bao-Gan Peng, MD, PhD, Professor, Department of Spinal Surgery, General Hospital of Armed Police Force, Beijing 100039, China

EDITORIAL BOARD MEMBERS
All editorial board members resources online at <http://www.wjgnet.com>

www.wjgnet.com/2218-5836/editorialboard.htm

EDITORIAL OFFICE
Xiu-Xia Song, Director
World Journal of Orthopedics
Baishideng Publishing Group Inc
7901 Stoneridge Drive, Suite 501, Pleasanton, CA 94588, USA
Telephone: +1-925-2238242
Fax: +1-925-2238243
E-mail: editorialoffice@wjgnet.com
Help Desk: <http://www.fjpublishing.com/helpdesk>
<http://www.wjgnet.com>

PUBLISHER
Baishideng Publishing Group Inc
7901 Stoneridge Drive,
Suite 501, Pleasanton, CA 94588, USA
Telephone: +1-925-2238242
Fax: +1-925-2238243
E-mail: bpgoffice@wjgnet.com
Help Desk: <http://www.fjpublishing.com/helpdesk>
<http://www.wjgnet.com>

PUBLICATION DATE
August 18, 2017

COPYRIGHT
© 2017 Baishideng Publishing Group Inc. Articles published by this Open-Access journal are distributed under the terms of the Creative Commons Attribution Non-commercial License, which permits use, distribution, and reproduction in any medium, provided the original work is properly cited, the use is non commercial and is otherwise in compliance with the license.

SPECIAL STATEMENT
All articles published in journals owned by the Baishideng Publishing Group (BPG) represent the views and opinions of their authors, and not the views, opinions or policies of the BPG, except where otherwise explicitly indicated.

INSTRUCTIONS TO AUTHORS
<http://www.wjgnet.com/bpg/gerinfo/204>

ONLINE SUBMISSION
<http://www.fjpublishing.com>

Postoperative deep shoulder infections following rotator cuff repair

Kivanc Atesok, Peter MacDonald, Jeff Leiter, Sheila McRae, Greg Stranges, Jason Old

Kivanc Atesok, Department of Orthopaedic Surgery, University of Alabama at Birmingham, Birmingham, AL 35294, United States

Peter MacDonald, Jeff Leiter, Sheila McRae, Greg Stranges, Jason Old, Sports Medicine and Upper Extremity Reconstruction Fellowship Program, Pan Am Clinic, Department of Surgery, Section of Orthopaedic Surgery, University of Manitoba, Winnipeg, MB R3M 3E4, Canada

Author contributions: All the authors contributed to this manuscript.

Conflict-of-interest statement: The authors have no conflict of interest related to this manuscript.

Open-Access: This article is an open-access article which was selected by an in-house editor and fully peer-reviewed by external reviewers. It is distributed in accordance with the Creative Commons Attribution Non Commercial (CC BY-NC 4.0) license, which permits others to distribute, remix, adapt, build upon this work non-commercially, and license their derivative works on different terms, provided the original work is properly cited and the use is non-commercial. See: <http://creativecommons.org/licenses/by-nc/4.0/>

Manuscript source: Invited manuscript

Correspondence to: Kivanc Atesok, MD, MSc, Department of Orthopaedic Surgery, University of Alabama at Birmingham, 510 20th Street South, FOT960, Birmingham, AL 35294, United States. kivanc.atesok@utoronto.ca
Telephone: +1-204-9257480
Fax: +1-204-4539032

Received: December 28, 2016

Peer-review started: December 31, 2016

First decision: February 20, 2017

Revised: March 6, 2017

Accepted: May 3, 2017

Article in press: May 5, 2017

Published online: August 18, 2017

Abstract

Rotator cuff repair (RCR) is one of the most commonly

performed surgical procedures in orthopaedic surgery. The reported incidence of deep soft-tissue infections after RCR ranges between 0.3% and 1.9%. Deep shoulder infection after RCR appears uncommon, but the actual incidence may be higher as many cases may go unreported. Clinical presentation may include increasing shoulder pain and stiffness, high temperature, local erythema, swelling, warmth, and fibrinous exudate. Generalized fatigue and signs of sepsis may be present in severe cases. Varying clinical presentation coupled with a low index of suspicion may result in delayed diagnosis. Laboratory findings include high erythrocyte sedimentation rate and C-reactive protein level, and, rarely, abnormal peripheral blood leucocyte count. Aspiration of glenohumeral joint synovial fluid with analysis of cell count, gram staining and culture should be performed in all patients suspected with deep shoulder infection after RCR. The most commonly isolated pathogens are *Propionibacterium acnes*, *Staphylococcus epidermidis*, and *Staphylococcus aureus*. Management of a deep soft-tissue infection of the shoulder after RCR involves surgical debridement with lavage and long-term intravenous antibiotic treatment based on the pathogen identified. Although deep shoulder infection after RCR is usually successfully treated, complications of this condition can be devastating. Prolonged course of intravenous antibiotic treatment, extensive soft-tissue destruction and adhesions may result in substantially diminished functional outcomes.

Key words: Rotator cuff repair; Deep shoulder infection; Shoulder surgery; Postoperative complication

© **The Author(s) 2017.** Published by Baishideng Publishing Group Inc. All rights reserved.

Core tip: Rotator cuff repair (RCR) has become one of the most frequently performed orthopaedic procedures during the last two decades. Paralleling the exponential increase in the number of RCRs, uncommon complications such as postoperative deep shoulder infections may be seen more frequently. Patients who are suspected to have a post-RCR infection require a thorough diagnostic evaluation, including clinical signs and symptoms, laboratory workups

and cultures. Although appropriate management of this condition with surgical debridement and lavage, and long-term IV antibiotics usually results in eradication of the infection, complications can be disabling and functional outcomes poor. The majority of the patients with deep infections after RCR report unsatisfactory outcomes with permanent functional limitations.

Atesok K, MacDonald P, Leiter J, McRae S, Stranges G, Old J. Postoperative deep shoulder infections following rotator cuff repair. *World J Orthop* 2017; 8(8): 612-618 Available from: URL: <http://www.wjgnet.com/2218-5836/full/v8/i8/612.htm> DOI: <http://dx.doi.org/10.5312/wjo.v8.i8.612>

INTRODUCTION

Rotator cuff pathology is one of the most commonly encountered orthopaedic problems, with an estimated prevalence of 17% to 35% including asymptomatic patients^[1]. In symptomatic patients, rotator cuff repair (RCR) usually provides good to excellent clinical outcomes^[1-4]. As a result, RCR has become one of the most frequently performed orthopaedic procedures during the last two decades^[5,6]. Paralleling the exponential increase in the number of RCRs, associated complications such as postoperative deep shoulder infections may be seen more frequently^[7]. Published literature indicates that the incidence of deep shoulder infection after open or mini-open RCR ranges between approximately 0.3% and 1.9%, and the condition is more common in male patients^[7-9]. While the rate of infection is generally thought to be lower after arthroscopic RCR, current high level evidence supporting this assertion is limited. In a recently published retrospective study including 3294 all-arthroscopic RCRs, Pauzenberger *et al*^[10] reported an infection rate of 0.85%. In another retrospective case series, Vopat *et al*^[11] studied the effects of surgical technique on infection rate. Out of 1824 RCRs performed by a single surgeon, 14 had an early deep postoperative shoulder infection that required surgical irrigation and debridement. Of these 14 patients who developed deep infections, primary RCR surgery was performed arthroscopically in only three of them, while 11 patients received open or mini-open repairs. The authors stated that "The most important finding in this study was that patients with non-arthroscopic RCR (open/mini open surgeries) had a greater risk [odds ratio (OR) = 8.63, $P < 0.001$] of infection compared with patients who had an all-arthroscopic RCR". It must be noted that all the available data in the literature consists of retrospective case series and that the patient records were reviewed based on follow-up notes or a re-operation registry for debridement^[7-11]. Hence, the actual incidence of infection may be higher, as many cases may go unreported due to patients choosing to seek treatment

at different institutions than where the primary repair had been performed.

RISK FACTORS

Risk factors for the development of suppurative infections of the shoulder joint can be summarized under three main categories: Anatomic, patient-related, and surgical technique or operating room (OR) environment-related risk factors.

Anatomic risk factors

The axillary area has been shown to provide an enriched colonization environment for various bacteria due to the presence of numerous sebaceous glands and hair follicles^[12-14]. Surgical incisions and entry portals for open, mini-open, and arthroscopic RCR are near the axilla, which may increase the possibility of inadvertent transmission of colonized microorganisms into the joint during surgery. Furthermore, precautions, such as clipping the axillary hair or preparing axillary skin with various solutions have not been proven to be successful in reducing infection rates or bacterial load^[15,16].

Patient-related risk factors

There are various patient characteristics that can adversely affect the body's defense against infections, including diabetes mellitus, immunosuppression, chronic diseases, advanced age, smoking, intravenous drug use, malnutrition, obesity, kidney and/or liver failure, and malignancies^[13,17,18]. In a retrospective comparative study from Chen *et al*^[18], three out of 30 (10%) type I diabetic patients developed infections following RCR. However, no patients in the non-diabetic group had infections after RCR. Pauzenberger *et al*^[10] found that age over 60 was an independent risk factor for post-RCR infections. In addition to systemic conditions, local factors, such as previous shoulder surgery and local corticosteroid injections, may also increase the risk of deep shoulder infection after RCR^[19,20].

Pauzenberger *et al*^[10] indicated that males are more prone to infection after RCR. The authors showed that out of 28 patients with deep infections after arthroscopic RCR, 27 (96.4%) were male and only 1 (3.6%) was female (OR = 21.41, $P = 0.003$). Likewise, Vopat *et al*^[11] reported that 92% of the patients in the infected group after RCR were male, compared to 58% of the control group patients who did not develop infections after RCR (OR = 9.52, $P = 0.042$). Although more male patients undergo RCR than female patients, this difference does not appear to be large enough to explain the significant difference in infection rates between men and women^[5]. Interestingly, there is evidence in the literature showing that *Propionibacterium acnes*' superficial skin colonization rate around arthroscopy portal sites was 81.6% in male patients and 46.1% in female patients^[21]. This colonization rate difference between men and women may be attributed

to the significantly higher serum testosterone levels in the male population vs the female population^[21,22].

Risk factors related to surgical technique and operating room environment

The risk of postoperative deep shoulder infection appears to be higher in open or mini-open RCR techniques compared with arthroscopic techniques^[1,11]. It is conceivable that the likelihood of bacterial contamination increases as the operation time and the size of the surgical incision increases. Another point worth considering is that open or mini-open RCR techniques have been performed much longer than arthroscopic repair techniques, which have only been performed for the last few decades. This fact, along with the improvement in disinfection and OR safety protocols, may have also influenced the decrease in infection rates for arthroscopic techniques^[23,24]. Nonetheless, there can be differences in the incidence of infection between various arthroscopic procedures. Yeranorian *et al.*^[17] reported that out of 165820 arthroscopic shoulder surgeries, 450 required additional surgery due to infections. The authors have noted that the incidence of infection was highest after RCR (0.29%) when compared with other arthroscopic procedures ($P < 0.01$). This finding underlines the significance of RCR as a procedure that increases the risk of infection, even when performed arthroscopically.

DIAGNOSIS

Clinical presentation

At the early stages, patients with deep infections after RCR usually present with increasing shoulder pain, stiffness, and, in some cases, loss of previously achieved postoperative range of motion (ROM)^[1,11,25-27]. There may be noticeable fibrinous exudate or pus drainage from the surgical wound and/or arthroscopy portals, with local swelling, erythema, and warmth around the shoulder joint^[7,8]. However, systemic signs and symptoms, such as fever, chills, low blood pressure, and generalized fatigue, are not common but they may be seen when there is a delay in presentation or when patients have immunosuppressive diseases.

Laboratory findings

Diagnostic lab workups to rule out or confirm deep shoulder infection after RCR include standard peripheral white blood cell (WBC) count with differential, erythrocyte sedimentation rate (ESR), and C-reactive protein (CRP) levels. Peripheral WBC count is usually within normal limits; however, ESR and CRP levels can be elevated. ESR and CRP levels are sensitive but not specific markers for deep shoulder infection. Athwal *et al.*^[8] studied 39 cases of deep shoulder infections after RCR and detected an elevated WBC count in only five patients (approximately 13%); ESR was available for 30 cases and was elevated in 18 cases (60%). The authors

checked CRP levels in 10 cases, and was elevated in five of them (50%). Kwon *et al.*^[7] reported similar results in a study including 14 patients with deep shoulder infections after RCR. In this study, the WBC count was measured in 10 patients, and nine of them had normal levels, averaging $7.6 \times 10^3/\mu\text{L}$ (range, $4.9\text{--}10.8 \times 10^3/\mu\text{L}$). The ESR was measured in eight patients and found to be elevated at least two-fold in seven patients (mean ESR value, $69 \text{ mm/h} \pm 32 \text{ mm/h}$). CRP was measured for two patients, and both were found to be increased, measuring 1.1 mg/dL and 7.7 mg/dL (normal, $< 0.8 \text{ mg/dL}$).

Glenohumeral joint aspiration and analysis with a cell count should be routinely performed in all patients presenting with a suspected deep shoulder infection. Aspirated fluid should also be examined microscopically for crystals, and a gram stain must be performed. As in most cases of septic arthritis, analysis of infected shoulder joint aspiration usually reveals a WBC count above $50000/\mu\text{L}$, with more than 75% polymorphonuclear leukocytes. These values indicate a deep infection of the shoulder, even if the gram stain returns negative and crystals are detected in the joint fluid. Aspiration fluid should be cultured in all cases, regardless of the results of cell count and the microscopic fluid analysis. Even though joint aspiration and synovial fluid analysis should be part of standard diagnostic work up for every case with a suspected joint infection, such data from patients with a reported deep shoulder infection after RCR is lacking in the literature.

Causative microorganisms

The most commonly isolated pathogens are, not surprisingly, the main species in sebaceous areas of normal skin flora, including *Propionibacterium acnes*, coagulase-negative *Staphylococci* (e.g., *Staphylococcus epidermidis*), and *Staphylococcus aureus*^[7-9,13]. However, infections due to various other microorganisms, such as *Corynebacterium* species, *Proteus mirabilis*, *Enterococcus faecalis*, *Peptostreptococcus magnus*, *Bacillus* species, *Streptococcus viridans*, *Actinomyces* species, and poly-microbial culture results, were also reported (Table 1)^[7-10,27].

Shoulder surgeons have recently focused on *Propionibacterium acnes* as a causative agent in many cases of deep shoulder infections after arthroscopic and open shoulder procedures. *P. acnes* is an anaerobic gram-positive bacillus densely colonized in the dermal skin layers around the head and shoulders. Despite routine preoperative antibiotic prophylaxis and skin preparation in shoulder arthroscopy, the rate of surgical site deep tissue inoculation with *P. acnes* can be as high as 19.6%^[21]. Furthermore, these patients were also found to have positive *P. acnes* superficial skin colonization that may indicate contamination by means of surgical instruments^[21]. Interestingly, Pauzenberger *et al.*^[10] reported that although administration of prophylactic antibiotics reduced the rate of infection

Table 1 Summary of reported microorganisms that were isolated from the patients with deep shoulder infections following rotator cuff repair in various retrospective case-series studies

Ref.	Patient No.	No. of isolated organisms	<i>P. acnes</i>	<i>S. aureus</i>	Coagulase-negative Staph ¹	Other microorganisms
Kwon <i>et al</i> ^[7]	14 (11 mono, 3 poly-microbial)	19	7	4	6	2 (<i>Proteus mirabilis</i> and <i>Enterococcus faecalis</i>)
Athwal <i>et al</i> ^[8]	38 (39 shoulders: 33 mono, 6 poly-microbial)	45	20	8	12	5 (<i>Corynebacterium species</i> × 2, <i>Peptostreptococcus magnus</i> , <i>Bacillus species</i> , <i>Streptococcus viridans</i>) 1 (<i>Peptostreptococcus</i>)
Settecerri <i>et al</i> ^[9]	16 (15 mono, 1 poly-microbial)	15	6	4	4	1 (<i>Peptostreptococcus</i>)
Pauzenberger <i>et al</i> ^[10]	28 (mono-microbial isolation in 23 patients)	23	8	2	12	1 (<i>Actinomyces species</i>)
Mirzayan <i>et al</i> ^[27]	13 (7 mono, 3 poly-microbial, 3 no growth)	15	3	5	5	2 (<i>Diphtheroids</i> and <i>Streptococcal species</i>)

¹Coagulase-negative *Staphylococci* include but not limited to *S. epidermitis*, *S. saprophyticus* and *S. hominis* (Courtesy of University of Manitoba, Section of Orthopaedic Surgery, Pan Am Clinic, Winnipeg, Manitoba, Canada).

from 1.54% to 0.28% ($P < 0.001$), there was no significant reduction in the rate of infections due to *P. acnes*. Further research is needed to study the correlation between superficial skin colonization and deep surgical tissue inoculation with *P. acnes* and postoperative deep shoulder infections following RCR.

Imaging

Radiographic evaluation in patients with deep shoulder infections after RCR is rarely necessary and usually reveals normal findings, particularly in acute cases. In subacute or delayed cases, ultrasonography and magnetic resonance imaging (MRI) with an intravenous contrast agent may be valuable to detect abscess formation around the shoulder joint or to identify complications, such as osteomyelitis^[13].

In rare cases, when the joint aspiration and culture results remain negative but the patient has clinical symptoms of infection, an indium 111-labeled WBC scan can be considered. Although this imaging modality might be helpful in localizing inflammation, it does not clearly distinguish between infectious and noninfectious inflammatory processes. Furthermore, reported sensitivity of indium 111-labeled WBC scans for the diagnosis of infectious conditions ranges from 60% to 100%, and specificity ranges from 69% to 92%^[28].

MANAGEMENT

Deep soft-tissue infections of the shoulder after RCR require a thorough and meticulous management that involves surgical debridement with copious lavage and long-term intravenous (IV) antibiotic treatment. Although this approach is universally accepted, the literature mostly provides evidence regarding open debridement due to the fact that the great majority of published studies are retrospective case series including patients who had either open RCRs or arthroscopically-assisted mini-open RCRs^[7-9,11,27]. However, studies indicate that arthroscopic RCRs have increased by

600%, while open repairs have increased by only 34% during the time interval between 1996 and 2006^[5]. It is highly possible that the percentage of arthroscopic RCRs have increased even further since 2006 compared with open repairs, as arthroscopic RCR has become the procedure of choice for the surgical treatment of rotator cuff pathologies. Hence, arthroscopic debridement and lavage needs to be emphasized as the primary surgical procedure to address acute deep shoulder infections after RCR.

Arthroscopic lavage and debridement

Any antibiotic treatment prior to surgery should be discontinued at least five to seven days before surgery. The importance of withholding lavage and IV antibiotics until obtaining cultures from the pus and debrided deep tissues cannot be overemphasized. In general, after the operative site is prepared and draped, incisions along the infected portals are made, and the pus from deeper tissues is drained through these portals. Cultures are then taken from the drained pus, and the swabs are used to obtain deep tissue cultures through the portals (Figure 1). It is advisable to start with a dry arthroscopy of the glenohumeral joint to achieve a better visualization of the infection and to obtain more tissues for culturing before the joint is washed (Figure 2). The glenohumeral joint and the previously repaired rotator cuff is assessed intraoperatively following the initial lavage. Ideally, all the suture material and anchors are removed, and the joint is washed profusely using a minimum of 10 L of fluid, with the last liter containing 100000 units of bacitracin^[27]. Although there could be variations in approach among individual surgeons, a re-repair of the rotator cuff during the same arthroscopic debridement and lavage procedure is not suggested before completing a long-term IV antibiotic therapy and confirming that the infection has been eradicated. In selected patients, based on intraoperative assessment, the sutures and anchors can be retained if the infection is not extensive and there is no loosening of the re-

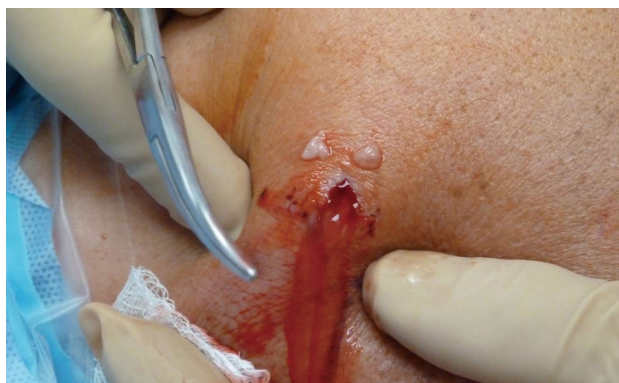

Figure 1 Drainage from an infected arthroscopy portal immediately before the arthroscopic debridement and lavage. After anesthesia the patient is positioned and the shoulder is draped. An incision is made through the infected portal and cultures are taken from the draining pus. Additional deep tissue cultures are sent during the arthroscopic debridement (Courtesy of University of Manitoba, Section of Orthopaedic Surgery, Pan Am Clinic, Winnipeg, Manitoba, Canada).

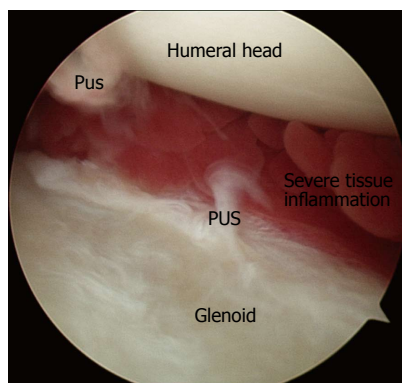


Figure 2 Arthroscopic view of the glenohumeral joint space from a patient with deep shoulder infection after rotator cuff repair. It is possible to visualize the pus and severe tissue inflammation before the irrigation (Courtesy of University of Manitoba, Section of Orthopaedic Surgery, Pan Am Clinic, Winnipeg, Manitoba, Canada).

paired cuff tissue.

Open debridement and lavage

Deep infection usually involves the surgical wound and forms a tract that connects the deep tissues to the superficial layers of the surgical incision. Hence, open surgical debridement and lavage is the mainstay of treatment in patients who had open RCR as the initial procedure. Athwal *et al*^[8] treated 39 patients with post-RCR deep shoulder infections by means of an open irrigation and debridement (30 patients), and a combined arthroscopic and open debridement (nine patients). They reported that a mean of 3.3 surgical debridements were necessary for eradicating the infection. Between surgical debridements, the wound was left open and packed with sterile gauze in 18 shoulders and closed over a drain in 21. They used antibiotic-laden cement beads in five patients. In a series including 16 patients with deep infections after an open RCR, Settecerry *et al*^[9] did an average of 3.5 open debridements (range two to eight debridements), and the wound was left open and packed with sterile gauze between the procedures. Other studies report a similar treatment approach to deep shoulder infection after open RCR^[7,27].

This evidence shows a tendency for multiple open debridement and lavage procedures in patients with deep infections after open RCR. Furthermore, leaving the wound open and packed with sterile gauze between debridements may also mean extended hospital stays for these patients that can negatively influence their quality of life and increase the economic burden on the healthcare system. Of note, patients with deep shoulder infections who underwent arthroscopic RCR as the initial procedure should also be treated with open debridement and lavage if complications such as osteomyelitis, abscess formation, or tissue necrosis exist.

Intravenous antibiotic therapy and infection follow-up

It is imperative to approach post-RCR deep shoulder infection as septic arthritis and to consider IV antibiotic treatment for a minimum of 4 to 6 wk to successfully eradicate the infection and to minimize the risk of complications, such as osteomyelitis, that may occur with a higher incidence due to the suture anchors placed in the humeral head. The antibiotic should be chosen based on the culture and susceptibility results and after a consultation with the infectious disease specialist who will be involved in the patient's management through the course of the initial treatment and the follow-up. A peripherally inserted central catheter must be placed and managed appropriately by regular flushing with normal saline between antibiotic doses to maintain patency. Depending on the causative microorganism and the patient's response to the initial treatment, IV antibiotic treatment can be supplemented or extended by oral antibiotics, as supported in the literature^[7-9].

The assessment of therapeutic response and follow-up of infection is mainly done by clinically evaluating the patient and monitoring infection markers, such as ESR and CRP. The duration of antibiotic treatment and the confirmation of infection eradication requires shared decision making between the orthopaedic surgeon and the infectious disease specialist.

COMPLICATIONS AND OUTCOMES

Deep infections of the shoulder after RCR are usually successfully eradicated with debridement and lavage, and long-term IV antibiotics^[7-9]. Nevertheless, devastating complications, such as osteomyelitis, abscess formation, post-infectious glenohumeral arthritis, and insufficient soft tissue coverage can be encountered, and functional outcomes may be far less than optimal. Kwon *et al*^[7] reported a 67% dissatisfaction rate in a group of 12 patients treated for deep infection after RCR, with a mean UCLA score of 23.6 (excellent and good ≥ 28 , fair and poor ≤ 27). Among these patients,

two needed rotational muscle flaps due to insufficient deltoid tissue after repeated open debridements. Athwal *et al*^[8] reported a complication rate of 32% during the medical and surgical treatment of deep infection after RCR. Their series included one patient who required arthrodesis and two patients who underwent shoulder arthroplasty due to glenohumeral arthrosis within 66 mo of eradicating the deep infection. Mirzayan *et al*^[27] studied 13 patients with chronic deep infections following open RCR. Seven patients had osteomyelitis of the humeral head, two had osteomyelitis of the humeral head and the glenoid, two had osteomyelitis of the clavicle and the acromion, and two had no osteomyelitis but had a subdeltoid abscess. Seven patients required a rotational flap to allow for joint coverage. The results of the Simple Shoulder Test in this study revealed that only three patients could lift a one-pound weight (0.5 kg) and none could lift an eight-pound weight (3.6 kg) to shoulder level without bending the elbow. Eight patients could throw underhand; however, only one could throw overhead.

Although these studies clearly indicate that outcomes after an infected open or mini-open rotator cuff repair can be permanently disabling, no studies to date have reported the effects of deep infections after arthroscopic RCRs on functional outcomes.

CONCLUSION

Deep shoulder infections after rotator cuff repair are not frequently encountered. Patients who are suspected to have a post-RCR infection require a thorough diagnostic evaluation, including clinical signs and symptoms, laboratory workups and cultures. Although appropriate management of this condition with surgical debridement and lavage, and long-term IV antibiotics usually results in eradication of the infection, complications can be disabling and functional outcomes poor. Abscess formation, osteomyelitis, post-infectious glenohumeral arthritis, and loss of the soft tissue envelope are among the most devastating complications resulting from post-RCR deep infections. The majority of the patients with deep infections after RCR report unsatisfactory outcomes with permanent functional limitations.

REFERENCES

- 1 Roberson TA, Azar FM, Miller RH, Smith RA, Throckmorton TW. Predictors of Early Complications After Rotator Cuff Repair. *Tech Should Elb Surg* 2016; **17**: 88-92 [DOI: 10.1097/BTE.0000000000000082]
- 2 Nicholas SJ, Lee SJ, Mullane MJ, Tyler TF, Fukunaga T, Johnson CD, McHugh MP. Functional Outcomes After Double-Row Versus Single-Row Rotator Cuff Repair: A Prospective Randomized Trial. *Orthop J Sports Med* 2016; **4**: 2325967116667398 [PMID: 27757408 DOI: 10.1177/2325967116667398]
- 3 Jung HJ, Sim GB, Bae KH, Kekatpure AL, Chun JM, Jeon IH. Rotator cuff surgery in patients older than 75 years with large and massive tears. *J Shoulder Elbow Surg* 2017; **26**: 265-272 [PMID: 27720414 DOI: 10.1016/j.jse.2016.07.004]
- 4 Antoni M, Klouche S, Mas V, Ferrand M, Bauer T, Hardy P. Return to recreational sport and clinical outcomes with at least 2years follow-up after arthroscopic repair of rotator cuff tears. *Orthop Traumatol Surg Res* 2016; **102**: 563-567 [PMID: 27133977 DOI: 10.1016/j.otsr.2016.02.015]
- 5 Colvin AC, Egorova N, Harrison AK, Moskowitz A, Flatow EL. National trends in rotator cuff repair. *J Bone Joint Surg Am* 2012; **94**: 227-233 [PMID: 22298054 DOI: 10.2106/JBJS.J.00739]
- 6 Paloneva J, Lepola V, Äärämaa V, Joukainen A, Ylinen J, Mattila VM. Increasing incidence of rotator cuff repairs--A nationwide registry study in Finland. *BMC Musculoskelet Disord* 2015; **16**: 189 [PMID: 26265152 DOI: 10.1186/s12891-015-0639-6]
- 7 Kwon YW, Kalainov DM, Rose HA, Bisson LJ, Weiland AJ. Management of early deep infection after rotator cuff repair surgery. *J Shoulder Elbow Surg* 2005; **14**: 1-5 [PMID: 15723006 DOI: 10.1016/j.jse.2004.04.010]
- 8 Athwal GS, Sperling JW, Rispoli DM, Cofield RH. Deep infection after rotator cuff repair. *J Shoulder Elbow Surg* 2007; **16**: 306-311 [PMID: 17321157 DOI: 10.1016/j.jse.2006.05.013]
- 9 Settecce JJ, Pitner MA, Rock MG, Hanssen AD, Cofield RH. Infection after rotator cuff repair. *J Shoulder Elbow Surg* 1999; **8**: 1-5 [PMID: 10077787 DOI: 10.1016/S1058-2746(99)90045-9]
- 10 Pauzenberger L, Grieb A, Hexel M, Laky B, Anderl W, Heuberger P. Infections following arthroscopic rotator cuff repair: incidence, risk factors, and prophylaxis. *Knee Surg Sports Traumatol Arthrosc* 2017; **25**: 595-601 [PMID: 27342982 DOI: 10.1007/s00167-016-4202-2]
- 11 Vopat BG, Lee BJ, DeStefano S, Waryasz GR, Kane PM, Gallacher SE, Fava J, Green AG. Risk Factors for Infection After Rotator Cuff Repair. *Arthroscopy* 2016; **32**: 428-434 [PMID: 26483170 DOI: 10.1016/j.arthro.2015.08.021]
- 12 Yang ES, Tan J, Eells S, Rieg G, Tagudar G, Miller LG. Body site colonization in patients with community-associated methicillin-resistant *Staphylococcus aureus* and other types of *S. aureus* skin infections. *Clin Microbiol Infect* 2010; **16**: 425-431 [PMID: 19689469 DOI: 10.1111/j.1469-0691.2009.02836.x]
- 13 Saltzman MD, Marecek GS, Edwards SL, Kalainov DM. Infection after shoulder surgery. *J Am Acad Orthop Surg* 2011; **19**: 208-218 [PMID: 21464214 DOI: 10.5435/00124635-201104000-00005]
- 14 Crossley KB, Ross J. Colonization of hospitalized patients by *Staphylococcus aureus*, *Staphylococcus epidermidis* and enterococci. *J Hosp Infect* 1985; **6**: 179-186 [PMID: 2862193 DOI: 10.1016/S0195-6701(85)80096-7]
- 15 Marecek GS, Weatherford BM, Fuller EB, Saltzman MD. The effect of axillary hair on surgical antisepsis around the shoulder. *J Shoulder Elbow Surg* 2015; **24**: 804-808 [PMID: 25487899 DOI: 10.1016/j.jse.2014.10.007]
- 16 Boonyasiri A, Thaisiam P, Permpikul C, Judaeng T, Suiwongsa B, Apiradeewajeset N, Fakthongphan T, Suddee S, Laoagtipparos W, Thamlikitkul V. Effectiveness of Chlorhexidine Wipes for the Prevention of Multidrug-Resistant Bacterial Colonization and Hospital-Acquired Infections in Intensive Care Unit Patients: A Randomized Trial in Thailand. *Infect Control Hosp Epidemiol* 2016; **37**: 245-253 [PMID: 26894621 DOI: 10.1017/ice.2015.285]
- 17 Yeranosian MG, Arshi A, Terrell RD, Wang JC, McAllister DR, Petrigliano FA. Incidence of acute postoperative infections requiring reoperation after arthroscopic shoulder surgery. *Am J Sports Med* 2014; **42**: 437-441 [PMID: 24296963 DOI: 10.1177/0363546513510686]
- 18 Chen AL, Shapiro JA, Ahn AK, Zuckerman JD, Cuomo F. Rotator cuff repair in patients with type I diabetes mellitus. *J Shoulder Elbow Surg* 2003; **12**: 416-421 [PMID: 14564259 DOI: 10.1016/S1058-2746(03)00172-1]
- 19 Hiemstra LA, Macdonald PB, Froese W. Subacromial infection following corticosteroid injection. *J Shoulder Elbow Surg* 2003; **12**: 91-93 [PMID: 12610492 DOI: 10.1067/mse.2003.127299]
- 20 Armstrong RW, Bolding F. Septic arthritis after arthroscopy: the contributing roles of intraarticular steroids and environmental factors. *Am J Infect Control* 1994; **22**: 16-18 [PMID: 8172371 DOI: 10.1016/0196-6553(94)90086-8]
- 21 Chuang MJ, Jancosko JJ, Mendoza V, Nottage WM. The Incidence of Propionibacterium acnes in Shoulder Arthroscopy. *Arthroscopy* 2015; **31**: 1702-1707 [PMID: 25823673 DOI: 10.1016/j.arthro.2015.01.029]

- 22 **Király CL**, Alén M, Korvola J, Horsmanheimo M. The effect of testosterone and anabolic steroids on the skin surface lipids and the population of *Propionibacteria* acnes in young postpubertal men. *Acta Derm Venereol* 1988; **68**: 21-26 [PMID: 2449007]
- 23 **Seavey R**. High-level disinfection, sterilization, and antisepsis: current issues in reprocessing medical and surgical instruments. *Am J Infect Control* 2013; **41**: S111-S117 [PMID: 23622741 DOI: 10.1016/j.ajic.2012.09.030]
- 24 **Hackett DJ Jr**, Crosby LA. Infection Prevention in Shoulder Surgery. *Bull Hosp Jt Dis* (2013) 2015; **73** Suppl 1: S140-S144 [PMID: 26631211]
- 25 **Randelli P**, Spennacchio P, Ragone V, Arrigoni P, Casella A, Cabitza P. Complications associated with arthroscopic rotator cuff repair: a literature review. *Musculoskelet Surg* 2012; **96**: 9-16 [PMID: 22205384 DOI: 10.1007/s12306-011-0175-y]
- 26 **Brislin KJ**, Field LD, Savoie FH 3rd. Complications after arthroscopic rotator cuff repair. *Arthroscopy* 2007; **23**: 124-128 [PMID: 17276218 DOI: 10.1016/j.arthro.2006.09.001]
- 27 **Mirzayan R**, Itamura JM, Vangsness CT Jr, Holtom PD, Sherman R, Patzakis MJ. Management of chronic deep infection following rotator cuff repair. *J Bone Joint Surg Am* 2000; **82-A**: 1115-1121 [PMID: 10954101 DOI: 10.2106/00004623-200008000-00008]
- 28 **Lewis SS**, Cox GM, Stout JE. Clinical utility of indium 111-labeled white blood cell scintigraphy for evaluation of suspected infection. *Open Forum Infect Dis* 2014; **1**: ofu089 [PMID: 25734155 DOI: 10.1093/ofid/ofu089]

P- Reviewer: Fukuchi RK, Nikolopoulos D **S- Editor:** Kong JX
L- Editor: A **E- Editor:** Lu YJ





Published by **Baishideng Publishing Group Inc**
7901 Stoneridge Drive, Suite 501, Pleasanton, CA 94588, USA
Telephone: +1-925-223-8242
Fax: +1-925-223-8243
E-mail: bpgoffice@wjgnet.com
Help Desk: <http://www.f6publishing.com/helpdesk>
<http://www.wjgnet.com>

