

# World Journal of *Gastroenterology*

*World J Gastroenterol* 2017 September 7; 23(33): 6009-6196



**EDITORIAL**

- 6009** Helminths as an alternative therapy for intestinal diseases

*Sipahi AM, Baptista DM*

**REVIEW**

- 6016** Dextran sodium sulfate colitis murine model: An indispensable tool for advancing our understanding of inflammatory bowel diseases pathogenesis

*Eichele DD, Kharbanda KK*

- 6030** Autoimmune hepatitis: Standard treatment and systematic review of alternative treatments

*Terziroli Beretta-Piccoli B, Mieli-Vergani G, Vergani D*

**MINIREVIEWS**

- 6049** Colorectal cancer, screening and primary care: A mini literature review

*Hadjipetrou A, Anyfantakis D, Galanakis CG, Kastanakis M, Kastanakis S*

- 6059** Behavioral gastroenterology: An emerging system and new frontier of action

*Jia L, Jiang SM, Liu J*

**ORIGINAL ARTICLE****Basic Study**

- 6065** Pharmacological evaluation of NSAID-induced gastropathy as a "Translatable" model of referred visceral hypersensitivity

*Hummel M, Knappenberger T, Reilly M, Whiteside GT*

- 6077** High yield reproducible rat model recapitulating human Barrett's carcinogenesis

*Matsui D, Omstead AN, Kosovec JE, Komatsu Y, Lloyd EJ, Raphael H, Kelly RJ, Zaidi AH, Jobe BA*

- 6088** Changes in expression of inhibitory substances in the intramural neurons of the stomach following streptozotocin- induced diabetes in the pig

*Bulc M, Palus K, Zielonka L, Gajęcka M, Calka J*

- 6100** HOX transcript antisense intergenic RNA represses E-cadherin expression by binding to EZH2 in gastric cancer

*Chen WM, Chen WD, Jiang XM, Jia XF, Wang HM, Zhang QJ, Shu YQ, Zhao HB*

- 6111**  $\text{Ca}^{2+}$ /calmodulin-dependent protein kinase II regulates colon cancer proliferation and migration *via* ERK1/2 and p38 pathways

*Chen W, An P, Quan XJ, Zhang J, Zhou ZY, Zou LP, Luo HS*

- 6119** Aberrant DNA-PKcs and ERGIC1 expression may be involved in initiation of gastric cancer

*Wang FR, Wei YC, Han ZJ, He WT, Guan XY, Chen H, Li YM*

#### Retrospective Cohort Study

- 6128** Real world treatment patterns of gastrointestinal neuroendocrine tumors: A claims database analysis

*Benson III AB, Broder MS, Cai B, Chang E, Neary MP, Papayan E*

#### Retrospective Study

- 6137** Patients with inflammatory bowel disease have increased risk of autoimmune and inflammatory diseases

*Halling ML, Kjeldsen J, Knudsen T, Nielsen J, Koch-Hansen L*

- 6147** Suspicious brush cytology is an indication for liver transplantation evaluation in primary sclerosing cholangitis

*Boyd S, Vannas M, Jokelainen K, Isoniemi H, Mäkisalo H, Färkkilä MA, Arola J*

- 6155** Management of gastric mucosa-associated lymphoid tissue lymphoma in patients with extra copies of the *MALT1* gene

*Iwamuro M, Takenaka R, Nakagawa M, Moritou Y, Saito S, Hori S, Inaba T, Kawai Y, Toyokawa T, Tanaka T, Yoshino T, Okada H*

- 6164** Ketogenic diet poses a significant effect on imbalanced gut microbiota in infants with refractory epilepsy

*Xie G, Zhou Q, Qiu CZ, Dai WK, Wang HP, Li YH, Liao JX, Lu XG, Lin SF, Ye JH, Ma ZY, Wang WJ*

#### Observational Study

- 6172** Definition of colorectal anastomotic leakage: A consensus survey among Dutch and Chinese colorectal surgeons

*van Rooijen SJ, Jongen ACHM, Wu ZQ, Ji JF, Slooter GD, Roumen RMH, Bouvy ND*

#### CASE REPORT

- 6181** How to treat intestinal obstruction due to malignant recurrence after Whipple's resection for pancreatic head cancer: Description of 2 new endoscopic techniques

*Mouradides C, Taha A, Borbath I, Deprez PH, Moreels TG*

- 6187** Arteriportal shunt incidental to treatment with oxaliplatin that mimics recurrent gastric cancer

*Kim HB, Park SG*

**LETTERS TO THE EDITOR**

- 6194** Comment on "Effect of biofilm formation by clinical isolates of *Helicobacter pylori* on the efflux-mediated resistance to commonly used antibiotics"

*Kazakos EI, Dorrell N, Polyzos SA, Deretzi G, Kountouras J*

ABOUT COVER

Editorial Board Member of World Journal of Gastroenterology, Mostafa Sira, MD, Associate Professor of Pediatric Hepatology, Gastroenterology and Nutrition, National Liver Institute, Menofiya University, Menofiya 32511, Egypt

AIMS AND SCOPE

*World Journal of Gastroenterology* (*World J Gastroenterol*, *WJG*, print ISSN 1007-9327, online ISSN 2219-2840, DOI: 10.3748) is a peer-reviewed open access journal. *WJG* was established on October 1, 1995. It is published weekly on the 7<sup>th</sup>, 14<sup>th</sup>, 21<sup>st</sup>, and 28<sup>th</sup> each month. The *WJG* Editorial Board consists of 1375 experts in gastroenterology and hepatology from 68 countries.

The primary task of *WJG* is to rapidly publish high-quality original articles, reviews, and commentaries in the fields of gastroenterology, hepatology, gastrointestinal endoscopy, gastrointestinal surgery, hepatobiliary surgery, gastrointestinal oncology, gastrointestinal radiation oncology, gastrointestinal imaging, gastrointestinal interventional therapy, gastrointestinal infectious diseases, gastrointestinal pharmacology, gastrointestinal pathophysiology, gastrointestinal pathology, evidence-based medicine in gastroenterology, pancreatology, gastrointestinal laboratory medicine, gastrointestinal molecular biology, gastrointestinal immunology, gastrointestinal microbiology, gastrointestinal genetics, gastrointestinal translational medicine, gastrointestinal diagnostics, and gastrointestinal therapeutics. *WJG* is dedicated to become an influential and prestigious journal in gastroenterology and hepatology, to promote the development of above disciplines, and to improve the diagnostic and therapeutic skill and expertise of clinicians.

INDEXING/ABSTRACTING

*World Journal of Gastroenterology* (*WJG*) is now indexed in Current Contents<sup>®</sup>/Clinical Medicine, Science Citation Index Expanded (also known as SciSearch<sup>®</sup>), Journal Citation Reports<sup>®</sup>, Index Medicus, MEDLINE, PubMed, PubMed Central and Directory of Open Access Journals. The 2017 edition of Journal Citation Reports<sup>®</sup> cites the 2016 impact factor for *WJG* as 3.365 (5-year impact factor: 3.176), ranking *WJG* as 29<sup>th</sup> among 79 journals in gastroenterology and hepatology (quartile in category Q2).

FLYLEAF

I-IX Editorial Board

EDITORS FOR  
THIS ISSUE

Responsible Assistant Editor: *Xiang Li*  
Responsible Electronic Editor: *Yan Huang*  
Proofing Editor-in-Chief: *Lian-Sheng Ma*

Responsible Science Editor: *Li-Juan Wei*  
Proofing Editorial Office Director: *Jin-Lei Wang*

NAME OF JOURNAL  
*World Journal of Gastroenterology*

ISSN  
ISSN 1007-9327 (print)  
ISSN 2219-2840 (online)

LAUNCH DATE  
October 1, 1995

FREQUENCY  
Weekly

EDITORS-IN-CHIEF  
**Damian Garcia-Olmo, MD, PhD, Doctor, Professor, Surgeon**, Department of Surgery, Universidad Autonoma de Madrid; Department of General Surgery, Fundacion Jimenez Diaz University Hospital, Madrid 28040, Spain

**Stephen C Strom, PhD, Professor**, Department of Laboratory Medicine, Division of Pathology, Karolinska Institutet, Stockholm 141-86, Sweden

**Andrzej S Tarnawski, MD, PhD, DSc (Med), Professor of Medicine, Chief Gastroenterology**, VA Long Beach Health Care System, University of California, Irvine, CA, 5901 E. Seventh Str., Long Beach,

CA 90822, United States

EDITORIAL BOARD MEMBERS  
All editorial board members resources online at <http://www.wjgnet.com/1007-9327/editorialboard.htm>

EDITORIAL OFFICE  
Jin-Lei Wang, Director  
Yuan Qi, Vice Director  
Ze-Mao Gong, Vice Director  
*World Journal of Gastroenterology*  
Baishideng Publishing Group Inc  
7901 Stoneridge Drive, Suite 501,  
Pleasanton, CA 94588, USA  
Telephone: +1-925-2238242  
Fax: +1-925-2238243  
E-mail: [editorialoffice@wjgnet.com](mailto:editorialoffice@wjgnet.com)  
Help Desk: <http://www.f6publishing.com/helpdesk>  
<http://www.wjgnet.com>

PUBLISHER  
Baishideng Publishing Group Inc  
7901 Stoneridge Drive, Suite 501,  
Pleasanton, CA 94588, USA  
Telephone: +1-925-2238242  
Fax: +1-925-2238243  
E-mail: [bpoffice@wjgnet.com](mailto:bpoffice@wjgnet.com)  
Help Desk: <http://www.f6publishing.com/helpdesk>

<http://www.wjgnet.com>

PUBLICATION DATE  
September 7, 2017

COPYRIGHT  
© 2017 Baishideng Publishing Group Inc. Articles published by this Open-Access journal are distributed under the terms of the Creative Commons Attribution Non-commercial License, which permits use, distribution, and reproduction in any medium, provided the original work is properly cited, the use is non commercial and is otherwise in compliance with the license.

SPECIAL STATEMENT  
All articles published in journals owned by the Baishideng Publishing Group (BPG) represent the views and opinions of their authors, and not the views, opinions or policies of the BPG, except where otherwise explicitly indicated.

INSTRUCTIONS TO AUTHORS  
Full instructions are available online at <http://www.wjgnet.com/bpg/gerinfo/204>

ONLINE SUBMISSION  
<http://www.f6publishing.com>

## How to treat intestinal obstruction due to malignant recurrence after Whipple's resection for pancreatic head cancer: Description of 2 new endoscopic techniques

Christina Mouradides, Alaa Taha, Ivan Borbath, Pierre H Deprez, Tom G Moreels

Christina Mouradides, Alaa Taha, Ivan Borbath, Pierre H Deprez, Tom G Moreels, Cliniques universitaires Saint-Luc, Hépatogastroentérologie, B-1200 Brussels, Belgium

**Author contributions:** Mouradides C, Taha A, Deprez PH and Moreels TG performed the endoscopic procedures; Borbath I was in charge of the clinical follow-up of the patients; Mouradides C, Taha A and Moreels TG wrote the report; Mouradides C, Taha A, Borbath I, Deprez PH and Moreels TG read and approved the report.

**Institutional review board statement:** All endoscopic procedures were performed according to good clinical practice standards approved by the Institutional Review Board of the Cliniques universitaires Saint-Luc.

**Informed consent statement:** Both patients consented to undergo the endoscopic procedures described in the current manuscript.

**Conflict-of-interest statement:** There is no conflict of interest to be reported for this manuscript.

**Open-Access:** This article is an open-access article which was selected by an in-house editor and fully peer-reviewed by external reviewers. It is distributed in accordance with the Creative Commons Attribution Non Commercial (CC BY-NC 4.0) license, which permits others to distribute, remix, adapt, build upon this work non-commercially, and license their derivative works on different terms, provided the original work is properly cited and the use is non-commercial. See: <http://creativecommons.org/licenses/by-nc/4.0/>

**Manuscript source:** Unsolicited manuscript

**Correspondence to:** Tom G Moreels, MD, PhD, Cliniques Universitaires Saint-Luc, Hépatogastroentérologie, Avenue Hippocrate 10, B-1200 Brussels, Belgium. [tom.moreels@uclouvain.be](mailto:tom.moreels@uclouvain.be)  
Telephone: +32-2-7642892  
Fax: +32-2-7649197

Received: January 7, 2017

Peer-review started: January 10, 2017

First decision: April 21, 2017

Revised: May 23, 2017

Accepted: June 9, 2017

Article in press: June 12, 2017

Published online: September 7, 2017

### Abstract

The prognosis of pancreatic cancer remains poor, even after initial surgical therapy. Local recurrence after Whipple's pancreaticoduodenectomy may lead to intestinal obstruction at the level of the afferent limb or the alimentary limb. Endoscopic insertion of a self-expandable metal stent (SEMS) into the intestinal malignant stricture is the preferred method of choice for palliation. We describe two new endoscopic techniques to treat a malignant intestinal obstruction with the insertion of a SEMS into the afferent limb and the alimentary limb. A case of malignant gastric outlet obstruction after a Whipple's resection was treated by the creation of an endoscopic gastrojejunostomy by the insertion of a lumen apposing HotAxios stent in between the stomach and the alimentary limb under fluoroscopic and endoscopic ultrasound control. Biliary obstruction and jaundice caused by a malignant stricture of the afferent limb after a Roux-en-Y Whipple's resection was treated by the insertion of a SEMS by means of the single-balloon overtube-assisted technique under fluoroscopic control. Feasibility and advantages of both techniques are discussed.

**Key words:** Intestinal obstruction; Self-expandable metal stent; Whipple's pancreaticoduodenectomy

© The Author(s) 2017. Published by Baishideng Publishing



Group Inc. All rights reserved.

**Core tip:** Malignant recurrence after Whipple's pancreatico-duodenectomy is frequent and may lead to intestinal obstruction. Endoscopic palliation of the intestinal obstruction is challenging. We present 2 endoscopic techniques: Endoscopic ultrasound-guided creation of a gastrojejunostomy using a fully covered lumen apposing metal stent, and insertion of a self-expandable metal stent by means of the single-balloon overtube-assisted technique under fluoroscopic control.

Mouradides C, Taha A, Borbath I, Deprez PH, Moreels TG. How to treat intestinal obstruction due to malignant recurrence after Whipple's resection for pancreatic head cancer : Description of 2 new endoscopic techniques. *World J Gastroenterol* 2017; 23(33): 6181-6186 Available from: URL: <http://www.wjgnet.com/1007-9327/full/v23/i33/6181.htm> DOI: <http://dx.doi.org/10.3748/wjg.v23.i33.6181>

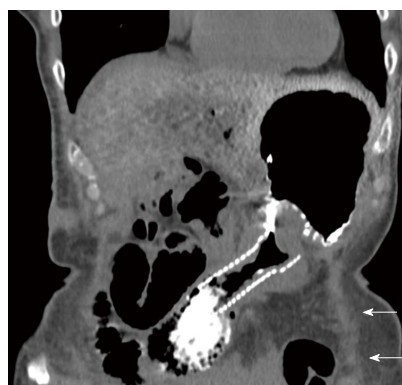## INTRODUCTION

Whipple's pancreatico-duodenectomy was named after Alan Oldfather Whipple who described the technique in 1935<sup>[1]</sup>. It still is the surgical treatment of choice to cure pancreatic head cancer<sup>[2]</sup>. Modifications of the technique have emerged, including pylorus-preserving Whipple's resection and Roux-en-Y intestinal reconstruction<sup>[3]</sup>. After resection of the pancreatic head, both the remnant bile duct and pancreatic duct have to be anastomosed to the afferent limb (hepaticojejunostomy/pancreaticojejunostomy) and food passes through the alimentary limb. Despite the different surgical Whipple's variations, the risk of local tumor recurrence after Whipple's resection for pancreatic head cancer remains more than 50%<sup>[4]</sup>. Few cases present with malignant intestinal obstruction at the level of the afferent or the alimentary limb. Endoscopic palliative therapy by means of insertion of self-expandable metal stents (SEMS) is the preferred method of choice to treat malignant intestinal obstruction in case of pancreatic cancer<sup>[2]</sup>. However, endoscopic SEMS placement in the afferent or the alimentary limb remains a challenging procedure<sup>[5]</sup>. We report on the endoscopic treatment modalities of two cases of malignant intestinal obstruction due to tumor recurrence after Whipple's pancreatico-duodenectomy.

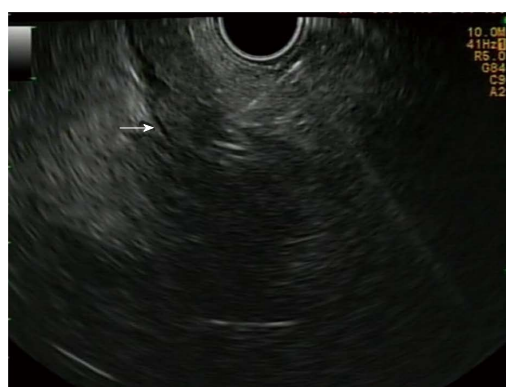## CASE REPORT

### Case 1

A 71 year-old woman was referred with symptoms of upper gastrointestinal obstruction because of local tumor recurrence at the level of the gastrojejunal anastomosis with peritoneal carcinomatosis. She underwent Whipple's resection for pancreatic head

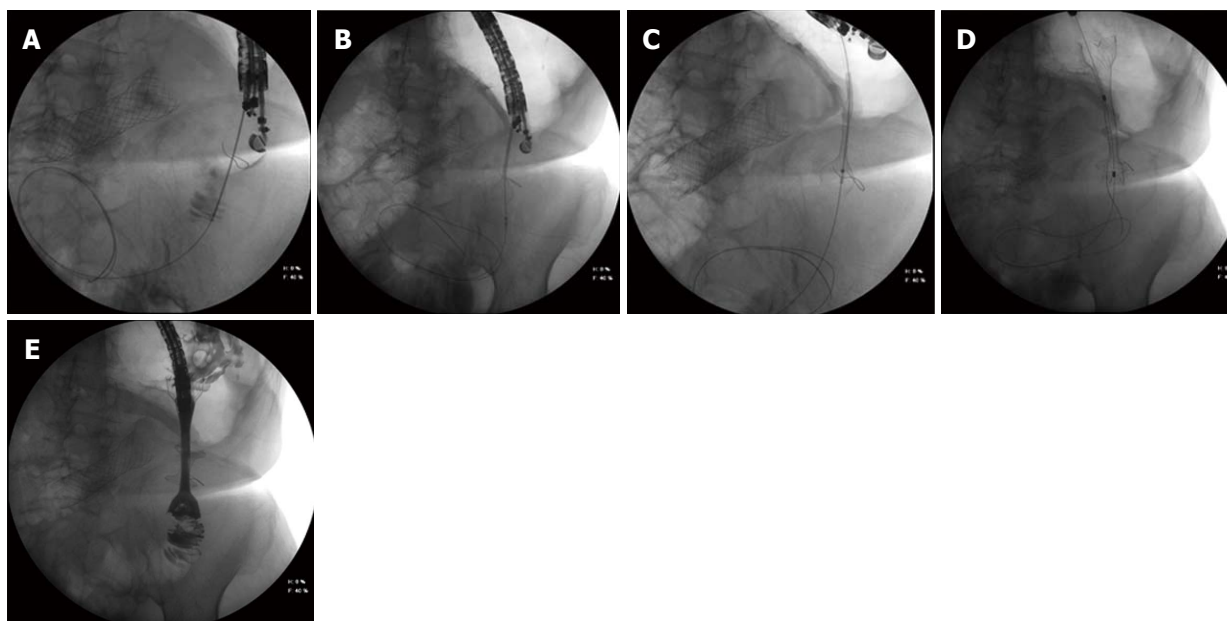


**Figure 1** Coronal computed tomography image of a non-covered metallic stent with peroral contrast in the dilated afferent limb in a patient with classical Whipple's duodenopancreatectomy. Note the obstructed empty alimentary limb underneath the stomach (arrows).



**Figure 2** Linear endoscopic ultrasound image of the transgastric puncture of the obstructed alimentary limb (arrow) with a 19 gauche needle.

cancer two years earlier. Initially, an uncovered enteral SEMS (Wallflex 60 x 22 mm, Boston Scientific) was inserted and ended up in the afferent limb, eventually obstructing the alimentary limb worsening the gastric outlet syndrome. CT scan confirmed the dilated afferent limb towards the hepaticojejunostomy, with food remnants and the empty alimentary limb underneath the stomach (Figure 1). Since the uncovered SEMS could not be removed from the afferent limb because of tumor ingrowth obstructing the entrance to the alimentary limb, we decided to create an endoscopic gastrojejunostomy, using the HotAxios device (XLumina Axios 10 mm x 15 mm, Boston Scientific), under endoscopic ultrasound (EUS) guidance (linear-array echoendoscope GF-UCT 180, Olympus) and fluoroscopy. The HotAxios device is a cystotome catheter with a preloaded covered lumen apposing metal stent. It is developed to drain pancreatic pseudocysts with an all-in-one device<sup>[6]</sup>. Here we used it to create an endoscopic gastrojejunostomy. The empty alimentary limb was identified by transgastric EUS, accessed with a 19 gauche needle (Figure 2), and confirmed fluoroscopically by intraluminal contrast dye injection.



**Figure 3 Fluoroscopic image.** A: The transgastric access of the alimentary limb using a 19 gauge needle. Correct access of the limb was confirmed after injection of contrast dye. A: 0.035 inch guidewire is introduced into the alimentary limb. Note the SEMS in the afferent limb; B: The HotAxios lumen apposing stent deployment between the alimentary limb and the gastric lumen; C: The HotAxios lumen apposing stent migrating outside to stomach. The distal flange is well positioned inside the lumen of the alimentary limb; D: The fully covered oesophageal stent inside the HotAxios lumen apposing stent, creating a gastrojejunostomy; E: Fluoroscopic image confirming the creation of a gastrojejunostomy between the stomach and the alimentary limb using the combination of a HotAxios lumen apposing stent and a fully covered oesophageal stent. Water soluble contrast dye is injected through the oesophageal stent into the alimentary limb. Note the non-covered SEMS in the afferent limb.

Next, a 0.035 inch guidewire was placed (Figure 3A), allowing smooth introduction of the HotAxios stent deployment system into the alimentary limb using electrocautery. The fully covered 10 mm HotAxios lumen apposing stent was deployed under fluoroscopic and endoscopic guidance, with the distal flange in the intestinal lumen, and the proximal flange in the stomach (Figure 3B). However, upon release, it immediately migrated outside the stomach because of the distance between the alimentary limb and the stomach (Figure 3C). A fully covered metal esophageal stent (Taewoong Medical Niti, 80 mm x 22 mm) was introduced over the guidewire and deployed inside the HotAxios stent, with the proximal part protruding into the gastric lumen (Figures 3D and E). After the procedure, the patient quickly resumed oral feeding.

Three months later, she was readmitted for vomiting due to intragastric migration of the esophageal stent. The HotAxios stent was still in place. A fully covered Nagi stent (Taewoong Medical, 20 mm x 16 mm) was placed inside the HotAxios stent, and the patient resumed oral feeding. Seven months after the initial presentation, she died due to malignant progression of the disease.

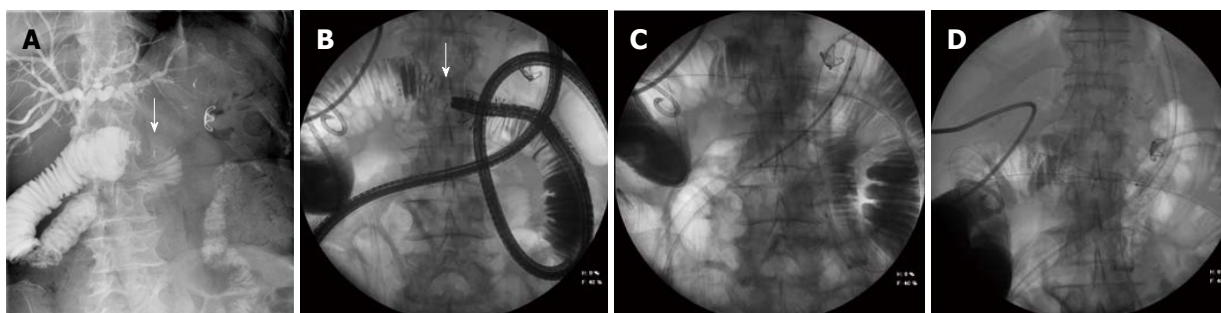
This case illustrates the feasibility of the HotAxios system in creating an EUS-guided gastrojejunostomy to treat malignant gastric outlet syndrome. This technique has recently emerged as an alternative to surgical gastrojejunostomy treating benign and malignant gastric outlet syndrome, with technical success rate

of 92% and 85% clinical success<sup>[7-9]</sup>. Serious adverse events of this endoscopic ultrasound technique were reported in 11.5%, and encompass gastrointestinal perforation, peritonitis and bleeding<sup>[9]</sup>. We encountered another complication. After deployment of the HotAxios lumen apposing stent to create the gastrojejunostomy, the gastric flange migrated outside the stomach without the possibility to reposition it into the stomach. Since the guidewire was still in place, we were able to save the gastrojejunostomy by inserting a second fully covered oesophageal SEMS inside the HotAxios stent.

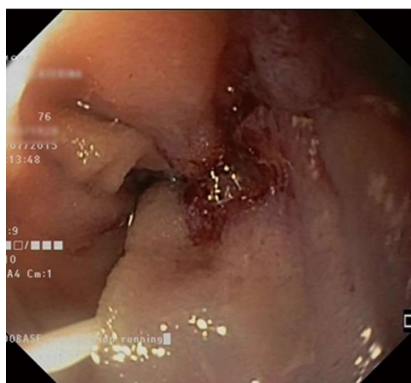
## Case 2

A 76-year-old woman who underwent Roux-en-Y Whipple's resection two years earlier for pancreatic head cancer, was referred because of obstructive jaundice and dilated intrahepatic bile ducts. Percutaneous transhepatic cholangiography and biliary drainage excluded an obstruction at the level of the bilioenteric anastomosis. However, afferent limb syndrome was diagnosed based on the obstruction of the afferent limb 20 cm distally from the hepaticojejunostomy with a dilated intestinal segment between the hepaticojejunostomy and the enteral stricture of the afferent limb (Figure 4A). Next, we performed a single-balloon enteroscopy (SBE) through the Roux-en-Y anastomosis into the afferent limb under fluoroscopic guidance, and reached the jejunal stenosis, with endoscopic characteristics of a malignant stricture (Figure 5). The length of the





**Figure 4 Fluoroscopic image.** A: A percutaneous transhepatic cholangiography confirming patency of the biliary anastomosis. The malignant stricture (arrow) is located at the level of the afferent limb (afferent limb syndrome), leading to dilated intrahepatic bile ducts and a dilatation of the afferent limb. Note the presence of an old Ovesco clip in the stomach. B: The single-balloon enteroscopy up to the level of the malignant stricture in the afferent limb. Contrast injection through the working channel of the enteroscope clearly delineates the length and the malignant aspect of the stricture (arrow). C: The peroral insertion technique of the self-expandable metal stent over a stiff guidewire through the overtube with the balloon inflated to protect the intestinal mucosa and to guide the catheter up to the malignant stricture of the afferent limb. D: The self-expandable metal stent in place in the malignant stricture of the afferent limb. Both the stiff guidewire and the overtube of the single-balloon enteroscope were used to insert the SEMS. SEMS: Self-expandable metal stent.



**Figure 5 Endoscopic image of the malignant stricture of the afferent limb.** Note the guidewire inserted into the stricture.

stricture was estimated by means of the injection of water soluble contrast. A 0.035 inch guidewire was inserted into the stricture under endoscopic and fluoroscopic control, and a CRE dilation balloon (8-10 mm) was inserted over the guide wire to dilate the stricture. Biopsies confirmed the intestinal recurrence of a pancreas adenocarcinoma. After a multidisciplinary oncology discussion, a non-surgical endoscopic approach was suggested. One week later, a second SBE was performed in order to place a SEMS into the malignant stricture. Again, the length of the stricture was estimated by contrast injection under fluoroscopic control (Figure 4B). A 0.035 inch stiff guidewire (VisiGlide 450 cm, Olympus) was inserted into the dilated jejunal segment proximal of the stricture. The overtube of the SBE was anchored as close as possible near the malignant stricture with the balloon inflated. Next, the enteroscope was removed under fluoroscopic guidance, leaving the guidewire and the overtube in place. An uncovered SEMS (Wallflex 60 mm x 22 mm, Boston Scientific) was inserted over the guidewire through the overtube into the stricture, located by means of the previously injected contrast

(Figure 4C). The stent was deployed under fluoroscopic guidance (Figure 4D). Afterwards, the enteroscope was reintroduced through the overtube to control for the correct positioning of the SEMS. The percutaneous biliary drain was removed and the patient was discharged two days later with normal oral food intake. Gemcitabine-based chemotherapy was started.

Three months later, she presented again with obstructive jaundice and afferent limb syndrome suggestive of tumor invasion of the uncovered SEMS. A third SBE procedure was performed, confirming the diagnosis of SEMS obstruction. We used the same single-balloon overtube-assisted technique to insert a new partially covered SEMS (ComVi Enteral Colonic Stent 100 mm x 22 mm, Taewoong) inside the uncovered SEMS. No complications were encountered. Ten months after the second SEMS insertion, she died due to malignant progression of the disease.

This case emphasizes the usefulness, feasibility and reproducibility of the single-balloon overtube-assisted technique for SEMS insertion in malignant strictures of the small intestine, especially in patients with altered anatomy such as Roux-en-Y anastomosis where conventional endoscopes cannot reach. Since the currently available enteral SEMS deployment catheters cannot be used through the working channel (2.8 or 3.2 mm) of the 200 cm long enteroscope, the SEMS is introduced over a long stiff guidewire through the balloon-anchored overtube under fluoroscopic control. This balloon-assisted overtube technique enables to relieve intestinal obstruction without surgical intervention by a combined endoscopic and fluoroscopic approach<sup>[10,11]</sup>.

## DISCUSSION

Malignant recurrence after (modified) Whipple's pancreatico-duodenectomy for pancreatic head adenocarcinoma remains high<sup>[4]</sup>. Sometimes, local

recurrence may lead to the afferent limb syndrome (stricture of the afferent limb) or a gastric outlet-like syndrome (stricture of the alimentary limb) because of intestinal tumor infiltration. In the case of malignant intestinal obstruction following Whipple's resection, palliative surgery is generally indicated to obtain symptom relief (resection of an intestinal segment, enterostomy or intestinal bypass)<sup>[12]</sup>. Case reports have shown that endoscopic enteral SEMS placement has become feasible, either by the creation of an EUS-guided gastrojejunostomy or by insertion of a SEMS by means of the balloon-assisted overtube technique<sup>[7-11]</sup>. We illustrated both procedures in two cases of malignant intestinal obstruction (afferent and alimentary limb obstruction) after Whipple's resection.

## COMMENTS

### Case characteristics

Both patients underwent Whipple's pancreaticoduodenectomy as a curative treatment of pancreatic head cancer. However, local tumor recurrence in the alimentary limb resulted in the gastric outlet syndrome (case 1) and local tumor recurrence in the afferent limb resulted in obstructive jaundice (case 2).

### Clinical diagnosis

The patient with the gastric outlet syndrome presented with recurrent vomiting and weight loss (case 1). The patient with the afferent limb syndrome presented with fever, abdominal pain and jaundice.

### Differential diagnosis

Vomiting may be a side-effect of chemotherapy (gemcitabine) or may be caused by peptic ulcer disease (case 1). Obstructive jaundice may be the clinical sign of a postoperative stricture at the level of the hepaticojejunostomy (case 2).

### Laboratory diagnosis

The patient with the gastric outlet syndrome presented a slight increase in CA19.9 tumor marker (case 1). The patient with the afferent limb syndrome presented with elevated CRP and liver function tests (case 2).

### Imaging diagnosis

Abdominal CT scan of the patient with the gastric outlet syndrome suspected peritoneal carcinomatosis (case 1). MRI-MRPC of the patient with the afferent limb syndrome suspected a postoperative stenosis at the level of the hepaticojejunostomy (case 2).

### Pathological diagnosis

No histological biopsies were taken during the endoscopic ultrasound (EUS)-guided gastrojejunostomy procedure to confirm local tumor recurrence (case 1). During the first single-balloon enteroscopy biopsies were taken at the level of the afferent limb stricture, confirming the presence of a well-differentiated pancreatic adenocarcinoma (case 2).

### Treatment

Both patients were treated endoscopically in a palliative setting. The first patient underwent EUS-guided gastrojejunostomy followed by chemotherapy (Oxaliplatin) (case 1). The second patient underwent self-expandable metal stent (SEMS) insertion into the afferent limb followed by chemotherapy (Gemcitabine) (case 2).

### Related reports

The two endoscopic techniques presented here have been described previously

under the form a case reports.

### Term explanation

Whipple's resection is the surgical curative treatment for pancreatic head cancer, with resection of the pancreatic head and the duodenum and the creation of a hepaticojejunostomy and a pancreaticojejunostomy on to the afferent jejunal limb. The afferent limb syndrome is caused by an obstruction at the level of the afferent limb after Whipple's resection. The gastric outlet syndrome is caused by an obstruction at the level of the alimentary limb after Whipple's resection.

### Experiences and lessons

Local tumor recurrence remains high after initial curative Whipple's pancreaticoduodenectomy for pancreatic head cancer. The clinical presentation as the gastric outlet syndrome or the afferent limb syndrome is rare. New endoscopic techniques may allow to overcome these clinical syndromes by creating an EUS-guided gastrojejunostomy or by SEMS insertion into the afferent limb.

### Peer-review

This is a well-written and illustrated overview of two endoscopic techniques for the palliation of intestinal obstruction due to local tumor recurrence after Whipple's pancreaticoduodenectomy for pancreatic head cancer.

## REFERENCES

- 1 **Haubrich WS.** Whipple of the Whipple operation. *Gastroenterology* 2007; **132**: 1654 [PMID: 17552083 DOI: 10.1053/j.gastro.2007.03.063]
- 2 **Ducieux M,** Cuhna AS, Caramella C, Hollebecque A, Burtin P, Goéré D, Seufferlein T, Haustermans K, Van Laethem JL, Conroy T, Arnold D; ESMO Guidelines Committee. Cancer of the pancreas: ESMO Clinical Practice Guidelines for diagnosis, treatment and follow-up. *Ann Oncol* 2015; **26** Suppl 5: v56-v68 [PMID: 26314780 DOI: 10.1093/annonc/mdv295]
- 3 **Griffin JF,** Poruk KE, Wolfgang CL. Pancreatic cancer surgery: past, present, and future. *Chin J Cancer Res* 2015; **27**: 332-348 [PMID: 26361403 DOI: 10.3978/j.issn.1000-9604.2015.06.07]
- 4 **Mu DQ,** Peng SY, Wang GF. Risk factors influencing recurrence following resection of pancreatic head cancer. *World J Gastroenterol* 2004; **10**: 906-909 [PMID: 15040043 DOI: 10.3748/wjg.v10.i6.906]
- 5 **Johnsson E,** Delle M, Lundell L, Liedman B. Transhepatic placement of an enteral stent to treat jaundice in a tumor recurrence obstructed afferent loop after a whipple procedure. *Dig Surg* 2003; **20**: 329-331 [PMID: 12806200 DOI: 10.1159/000071760]
- 6 **Patil R,** Ona MA, Papafragkakis C, Anand S, Duddempudi S. Endoscopic ultrasound-guided placement of AXIOS stent for drainage of pancreatic fluid collections. *Ann Gastroenterol* 2016; **29**: 168-173 [PMID: 27065729 DOI: 10.20524/aog.2016.0008]
- 7 **Binmoeller KF,** Shah JN. Endoscopic ultrasound-guided gastroenterostomy using novel tools designed for transluminal therapy: a porcine study. *Endoscopy* 2012; **44**: 499-503 [PMID: 22531985 DOI: 10.1055/s-0032-1309382]
- 8 **Shah A,** Khanna L, Sethi A. Treatment of afferent limb syndrome: novel approach with endoscopic ultrasound-guided creation of a gastrojejunostomy fistula and placement of lumen-apposing stent. *Endoscopy* 2015; **47** Suppl 1 UCTN: E309-E310 [PMID: 26115389 DOI: 10.1055/s-0034-1392210]
- 9 **Tyberg A,** Perez-Miranda M, Sanchez-Ocaña R, Peñas I, de la Serna C, Shah J, Binmoeller K, Gaidhane M, Grimm I, Baron T, Kahaleh M. Endoscopic ultrasound-guided gastrojejunostomy with a lumen-apposing metal stent: a multicenter, international experience. *Endosc Int Open* 2016; **4**: E276-E281 [PMID: 27004243 DOI: 10.1055/s-0042-101789]
- 10 **Popa D,** Ramesh J, Peter S, Wilcox CM, Mönkemüller K. Small Bowel Stent-in-Stent Placement for Malignant Small Bowel Obstruction Using a Balloon-Assisted Overtube Technique. *Clin*

*Endosc* 2014; **47**: 108-111 [PMID: 24570892 DOI: 10.5946/ce.2014.47.1.108]

- 11 **Nakahara K**, Okuse C, Matsumoto N, Suetani K, Morita R, Michikawa Y, Ozawa S, Hosoya K, Kobayashi S, Otsubo T, Itoh F. Enteral metallic stenting by balloon enteroscopy for obstruction of surgically reconstructed intestine. *World J Gastroenterol* 2015; **21**:

7589-7593 [PMID: 26140008 DOI: 10.3748/wjg.v21.i24.7589]

- 12 **Kofokotsios A**, Papazisis K, Andronikidis I, Ntinas A, Kardassis D, Vrochides D. Palliation With Endoscopic Metal Stents May Be Preferable to Surgical Intervention for Patients With Obstructive Pancreatic Head Adenocarcinoma. *Int Surg* 2015; **100**: 1104-1110 [PMID: 26414833 DOI: 10.9738/INTSURG-D-14-00274.1]

**P- Reviewer:** Przemioslo R **S- Editor:** Gong ZM **L- Editor:** A  
**E- Editor:** Huang Y





Published by **Baishideng Publishing Group Inc**  
7901 Stoneridge Drive, Suite 501, Pleasanton, CA 94588, USA  
Telephone: +1-925-223-8242  
Fax: +1-925-223-8243  
E-mail: [bpgoffice@wjgnet.com](mailto:bpgoffice@wjgnet.com)  
Help Desk: <http://www.f6publishing.com/helpdesk>  
<http://www.wjgnet.com>



ISSN 1007-9327

