

World Journal of *Methodology*

World J Methodol 2017 December 26; 7(4): 112-150





EDITORIAL

- 112 Predictive power of statistical significance
Heston TF, King JM

REVIEW

- 117 Shortness of breath in clinical practice: A case for left atrial function and exercise stress testing for a comprehensive diastolic heart failure workup
Iyngkaran P, Anavekar NS, Neil C, Thomas L, Hare DL
- 129 Is forced oscillation technique the next respiratory function test of choice in childhood asthma
Alblooshi A, Alkalbani A, Albadi G, Narchi H, Hall G

ORIGINAL ARTICLE

Basic Study

- 139 Quantitative comparison of cranial approaches in the anatomy laboratory: A neuronavigation based research method
Doglietto F, Qiu J, Ravichandiran M, Radovanovic I, Belotti F, Agur A, Zadeh G, Fontanella MM, Kucharczyk W, Gentili F

CASE REPORT

- 148 Laparoscopic-extracorporeal surgery performed with a fixation device for adnexal masses complicating pregnancy: Report of two cases
Kasahara H, Kikuchi I, Otsuka A, Tsuzuki Y, Nojima M, Yoshida K

ABOUT COVER

Editorial Board Member of *World Journal of Methodology*, Yong Q Chen, PhD, Professor, Department of Cancer Biology, Urology, Cancer Genomics and Translational Science, Wake Forest University School of Medicine, Winston-Salem, NC 27157, United States

AIM AND SCOPE

World Journal of Methodology (*World J Methodol*, *WJM*, online ISSN 2222-0682, DOI: 10.5662) is a peer-reviewed open access academic journal that aims to guide clinical practice and improve diagnostic and therapeutic skills of clinicians.

The primary task of *WJM* is to rapidly publish high-quality original articles, reviews, and commentaries that deal with the methodology to develop, validate, modify and promote diagnostic and therapeutic modalities and techniques in preclinical and clinical applications. *WJM* covers topics concerning the subspecialties including but not exclusively anesthesiology, cardiac medicine, clinical genetics, clinical neurology, critical care, dentistry, dermatology, emergency medicine, endocrinology, family medicine, gastroenterology and hepatology, geriatrics and gerontology, hematology, immunology, infectious diseases, internal medicine, obstetrics and gynecology, oncology, ophthalmology, orthopedics, otolaryngology, radiology, serology, pathology, pediatrics, peripheral vascular disease, psychiatry, radiology, rehabilitation, respiratory medicine, rheumatology, surgery, toxicology, transplantation, and urology and nephrology.

INDEXING/ABSTRACTING

World Journal of Methodology is now indexed in PubMed, PubMed Central.

FLYLEAF

I-V Editorial Board

EDITORS FOR THIS ISSUE

Responsible Assistant Editor: *Xiang Li*
Responsible Electronic Editor: *Ya-jing Lu*
Proofing Editor-in-Chief: *Lian-Sheng Ma*

Responsible Science Editor: *Li-Jun Cai*
Proofing Editorial Office Director: *Xiu-Xia Song*

NAME OF JOURNAL
World Journal of Methodology

ISSN
ISSN 2222-0682 (online)

LAUNCH DATE
September 26, 2011

FREQUENCY
Quarterly

EDITOR-IN-CHIEF
Yicheng Ni, MD, PhD, Professor, Department of Radiology, University Hospitals, KU Leuven, Herestraat 49, B-3000, Leuven, Belgium

EDITORIAL BOARD MEMBERS
All editorial board members resources online at <http://www.wjgnet.com/2222-0682/editorialboard.htm>

EDITORIAL OFFICE
Xiu-Xia Song, Director
World Journal of Methodology
Baishideng Publishing Group Inc
7901 Stoneridge Drive, Suite 501, Pleasanton, CA 94588, USA
Telephone: +1-925-2238242
Fax: +1-925-2238243
E-mail: editorialoffice@wjgnet.com
Help Desk: <http://www.f6publishing.com/helpdesk>
<http://www.wjgnet.com>

PUBLISHER
Baishideng Publishing Group Inc
7901 Stoneridge Drive,
Suite 501, Pleasanton, CA 94588, USA
Telephone: +1-925-2238242
Fax: +1-925-2238243
E-mail: bpgoffice@wjgnet.com
Help Desk: <http://www.f6publishing.com/helpdesk>
<http://www.wjgnet.com>

PUBLICATION DATE
December 26, 2017

COPYRIGHT
© 2016 Baishideng Publishing Group Inc. Articles published by this Open-Access journal are distributed under the terms of the Creative Commons Attribution Non-commercial License, which permits use, distribution, and reproduction in any medium, provided the original work is properly cited, the use is non commercial and is otherwise in compliance with the license.

SPECIAL STATEMENT
All articles published in journals owned by the Baishideng Publishing Group (BPG) represent the views and opinions of their authors, and not the views, opinions or policies of the BPG, except where otherwise explicitly indicated.

INSTRUCTIONS TO AUTHORS
<http://www.wjgnet.com/bpg/gerinfo/204>

ONLINE SUBMISSION
<http://www.f6publishing.com>

Laparoscopic-extracorporeal surgery performed with a fixation device for adnexal masses complicating pregnancy: Report of two cases

Hanako Kasahara, Iwaho Kikuchi, Aya Otsuka, Yoko Tsuzuki, Michio Nojima, Koyo Yoshida

Hanako Kasahara, Iwaho Kikuchi, Aya Otsuka, Yoko Tsuzuki, Michio Nojima, Koyo Yoshida, Department of Obstetrics and Gynecology, Juntendo University Urayasu Hospital, Chiba 279-0021, Japan

Author contributions: Kasahara H and Kikuchi I contributed equally to this work; Kasahara H, Kikuchi I, Otsuka A and Tsuzuki Y performed the research; Kikuchi I designed the research; Nojima M and Yoshida K conducted the research; Kasahara H wrote the paper.

Informed consent statement: Because the patients have moved, we could not contact them. Before the operation, we have got comprehensive agreement, so the IRB approved.

Conflict-of-interest statement: None.

Open-Access: This article is an open-access article which was selected by an in-house editor and fully peer-reviewed by external reviewers. It is distributed in accordance with the Creative Commons Attribution Non Commercial (CC BY-NC 4.0) license, which permits others to distribute, remix, adapt, build upon this work non-commercially, and license their derivative works on different terms, provided the original work is properly cited and the use is non-commercial. See: <http://creativecommons.org/licenses/by-nc/4.0/>

Manuscript source: Invited manuscript

Correspondence to: Iwaho Kikuchi, MD, PhD, Department of Obstetrics and Gynecology, Juntendo University Urayasu Hospital, Tomioka 2-1-1, Urayasu City, Chiba 279-0021, Japan. kikuchi@juntendo.ac.jp
Telephone: +81-47-3533111
Fax: +81-47-3520187

Received: January 16, 2017

Peer-review started: January 18, 2017

First decision: March 27, 2017

Revised: November 18, 2017

Accepted: December 1, 2017

Article in press: December 1, 2017

Published online: December 26, 2017

Abstract

The potential complications associated with an adnexal mass discovered during early pregnancy call for surgical treatment. Ideally, surgery is performed after gestational week 12, but uterine expansion after the first trimester makes surgery difficult. We report two pregnancies complicated by adnexal masses for which we used an organ fixation device for safe performance of single-site umbilical laparoscopic surgery. Pelvic magnetic resonance imaging depicted a dichorionic, diamniotic twin pregnancy and 60-mm right adnexal mass in the first patient and bilateral adnexae in the second. All three masses were suspected mature cystic teratomas. Both patients underwent laparoscopic surgery during gestational week 14. With use of an organ fixation device, traction was applied until the mass reached the umbilicus; tumor resection was performed extracorporeally. In the second patient, the second mass was simply aspirated because adhesions were encountered. Our single-site laparoscopic-extracorporeal technique proved to be a safe approach to an otherwise high-risk situation.

Key words: Laparoscopic surgery; Pregnant complication; Ovarian mass; Fixation device; Extracorporeal

© The Author(s) 2017. Published by Baishideng Publishing Group Inc. All rights reserved.

Core tip: The new device, "Ova-Lead" has a 20-mm-diameter tip that is made of silicone and shaped like a suction cup. It fixes to the organ through the application of negative pressure, by using this device the surgeon manipulates the organ. We reported two cases of adnexal mass discovered during pregnant that this device seemed useful.

Kasahara H, Kikuchi I, Otsuka A, Tsuzuki Y, Nojima M, Yoshida K. Laparoscopic-extracorporeal surgery performed with a fixation

device for adnexal masses complicating pregnancy: Report of two cases. *World J Methodol* 2017; 7(4): 148-150 Available from: URL: <http://www.wjgnet.com/2222-0682/full/v7/i4/148.htm> DOI: <http://dx.doi.org/10.5662/wjm.v7.i4.148>

INTRODUCTION

One or more adnexal masses are discovered in a reported 0.01%-1% of all pregnancies^[1]. The majority resolve spontaneously, but in some cases, torsion or rupture necessitates emergency surgery. Ideally, surgery is performed after gestational week 12, but expansion of the uterus after the first trimester makes surgical manipulation difficult. We report adnexal masses complicating 2 pregnancies for which we used an organ fixation device for safe performance of single-site umbilical laparoscopic surgery.

CASE REPORT

Case 1

The patient was a 29-year-old woman, gravida 0 para 0. An early-stage dichorionic, diamniotic twin pregnancy was confirmed simultaneously with a right-sided adnexal mass. Pelvic magnetic resonance imaging (MRI) revealed a 60-mm mass that appeared to be a mature cystic teratoma, so laparoscopic surgery was scheduled and performed during gestational week 14. We placed Lap Protector and EZ Access (Hakko Corporation Tokyo Japan) as a wound retractor in the umbilicus, and we used an organ fixation device called "Ova-Lead" (Fuji Systems corporation, Tokyo Japan) to apply traction to the adnexa to bring the mass up to the umbilicus (Figure 1). We resected the mass extracorporeally (Figure 2). She was followed up at our hospital until 22 wk then moved overseas.

Case 2

The patient was a 38-year-old woman, gravida 0 para 0. Bilateral adnexal masses were identified during the early stage of pregnancy. Pelvic MRI revealed a 70-mm left adnexal mass and a 50-mm right adnexal mass. Both were thought to be mature cystic teratomas, so laparoscopic surgery was scheduled and performed during gestational week 14. We placed a RapidPort EZ Access Port in the umbilicus. We encountered extensive adhesions within the peritoneal cavity. Traction was applied to the left adnexa by means of an organ fixation device, "Ova-Lead" until the mass reached the umbilicus, and the mass was resected extracorporeally. Applying traction to the right adnexa proved difficult due to the adhesions, so we simply performed paracentesis. The fluid contained hemorrhagic components, so we suspected an endometrioma. The left adnexal mass was diagnosed histologically as a mixed cystic teratoma and endometrioma. No recurrence of the right mass was noted during the remaining course of the pregnancy.

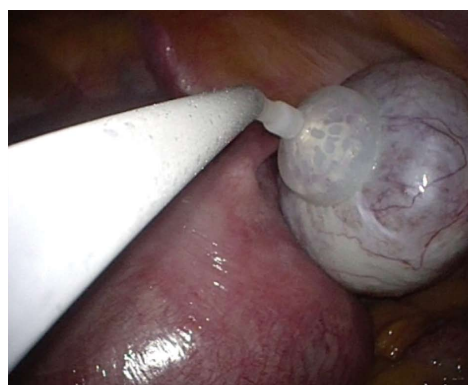

Figure 1 By using "Ova-Lead", aspirate sucking and fix the ovaries to the cup.

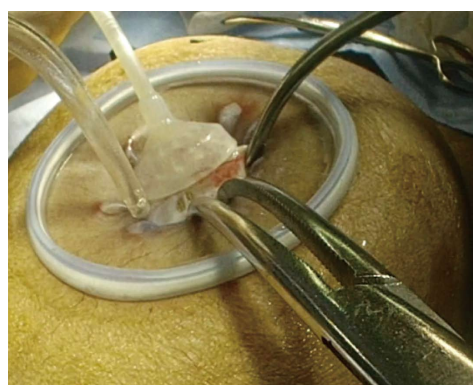


Figure 2 Ovarian cystectomy was performed extracorporeally after pulling out the whole ovary from the abdominal cavity.

She was followed up at our hospital, and at 36 wk, premature rupture of membrane occurred to her, then she was delivered vaginally.

DISCUSSION

The "Ova-Lead" has a 20-mm-diameter tip that is made of silicone and shaped like a suction cup. It fixes to the organ through the application of negative pressure (30 mmHg). The surgeon manipulates the device by a metal handle, and use of the device eases performance of the operation. At our hospital, we attach and fix the device to the adnexal mass and then apply traction to the mass to draw it up to the umbilicus. This allows us to resect the organ extracorporeally, and by using this single-port technique, the operation time is shortened, and surgery can be performed with as little leakage of tumor contents into the peritoneal cavity as possible.

Adnexal masses occurring during pregnancy are of various tissue types. The most common are mature cystic teratomas, representing 40% of adnexal masses. These are followed in order by serous cystadenomas at 20%, mucinous cystadenomas at 10%, endometriomas at 5%, and malignant tumors at 3%^[1]. The contents of a mature cystic teratoma can easily leak into the peritoneal cavity. This has been found to result in

chemical peritonitis. Therefore, at our hospital, we use an extracorporeal technique to resect the mass.

Extracorporeal resection generally reduces the overall operation time, thus shortening the pneumoperitoneum time. Jansen *et al.*^[2] verified that increases in intrauterine pressure can result in fetal hypoxia. Hunter *et al.*^[3] verified in an animal model that carbon dioxide (gas) pneumoperitoneum can cause fetal acidosis and noted that changes were greatest at pressures of 15 mmHg or more. We believe that laparoscopic-extracorporeal resection, in comparison to total intracorporeal laparoscopic resection, allows us to better shorten the duration of both the surgery and the pneumoperitoneum, helping us prevent this complication.

Adverse events can occur in pregnant women with an adnexal mass. There is potential for pedicle torsion (1%-22%), rupture (9%), miscarriage or premature labor (5%-15%), or infection (1.2%-2.4%)^[4]. The risk of such complications increases when the mass is greater than 6 cm^[4]. We recommend surgery for masses greater than 6 cm that we encounter at our hospital.

Our gynecology department guidelines recommend performing surgery after gestational week 12, after the period of organogenesis has passed. The Japan College of Radiology imaging guidelines recommend use of MRI after gestational week 14. Surgery becomes increasingly difficult with each passing gestational week, so at our hospital, we perform surgical treatment as close to gestational week 14 as possible if a diagnosis has been made by then.

In conclusion, we treated two cases of adnexal masses complicating pregnancy by performing single-port umbilical laparoscopic surgery, using an organ fixation device, and resecting the masses extracorporeally. There are risks associated with surgery performed during pregnancy, but the potential complications associated with the simultaneous presence of an adnexal mass outweigh the risks of surgery. We have found that our technique prevents the complications associated with such surgery and facilitates safe surgical treatment even when the surgical field is difficult to secure and the uterus

is especially enlarged, as in the case of a twin pregnancy. And also, even in the case of a large ovarian tumor, this method was suggested to be useful.

ARTICLE HIGHLIGHTS

Clinical diagnosis

Ovarian cyst (benign).

Differential diagnosis

Ovarian carcinoma, *etc.*

Imaging diagnosis

Magnetic resonance imaging findings as follows: Case 1: Mature cystic teratoma; Case 2: Endometrioma.

Pathological diagnosis

Case 1: Mature cystic teratoma; Case 2: Endometrioma.

Treatment

Surgical treatment.

Related reports

This manuscript was the first report about this device.

Experiences and lessons

In the case of a large ovarian tumor, this "ova-lead" was suggested to be useful.

REFERENCES

- 1 Hoover K, Jenkins TR. Evaluation and management of adnexal mass in pregnancy. *Am J Obstet Gynecol* 2011; **205**: 97-102 [PMID: 21571247 DOI: 10.1016/j.ajog.2011.01.050]
- 2 Jansen CA, Krane EJ, Thomas AL, Beck NF, Lowe KC, Joyce P, Parr M, Nathanielsz PW. Continuous variability of fetal PO₂ in the chronically catheterized fetal sheep. *Am J Obstet Gynecol* 1979; **134**: 776-783 [PMID: 463979 DOI: 10.1016/0002-9378(79)90947-5]
- 3 Hunter JG, Swanstrom L, Thornburg K. Carbon dioxide pneumoperitoneum induces fetal acidosis in a pregnant ewe model. *Surg Endosc* 1995; **9**: 272-277; discussion 277-279 [PMID: 7597597 DOI: 10.1007/BF00187767]
- 4 Guariglia L, Conte M, Are P, Rosati P. Ultrasound-guided fine needle aspiration of ovarian cysts during pregnancy. *Eur J Obstet Gynecol Reprod Biol* 1999; **82**: 5-9 [PMID: 10192476 DOI: 10.1016/S0301-2115(98)00164-X]

P- Reviewer: Tu H, Zafrafas M S- Editor: Ji FF L- Editor: A
E- Editor: Lu YJ





Published by **Baishideng Publishing Group Inc**
7901 Stoneridge Drive, Suite 501, Pleasanton, CA 94588, USA
Telephone: +1-925-223-8242
Fax: +1-925-223-8243
E-mail: bpgoffice@wjgnet.com
Help Desk: <http://www.f6publishing.com/helpdesk>
<http://www.wjgnet.com>

