

World Journal of *Gastrointestinal Endoscopy*

World J Gastrointest Endosc 2017 June 16; 9(6): 243-295



REVIEW

- 243 Endoscopic ultrasound in oncology: An update of clinical applications in the gastrointestinal tract
Valero M, Robles-Medrand C

MINIREVIEWS

- 255 Endoscopic recommendations for colorectal cancer screening and surveillance in patients with inflammatory bowel disease: Review of general recommendations
Huguet JM, Suárez P, Ferrer-Barceló L, Ruiz L, Monzó A, Durá AB, Sempere J

ORIGINAL ARTICLE

Retrospective cohort study

- 263 Endoscopic resolution and recurrence of gastric antral vascular ectasia after serial treatment with argon plasma coagulation
Garg S, Aslam B, Nickl N

Observational Study

- 267 Utility of the balloon-overtube-assisted modified over-the-wire stenting technique to treat post-sleeve gastrectomy complications
Ponte A, Pinho R, Proença L, Silva J, Rodrigues J, Sousa M, Silva JC, Carvalho J

Randomized Controlled Trial

- 273 Multicenter randomised controlled trial comparing the high definition white light endoscopy and the bright narrow band imaging for colon polyps
Singh R, Cheong KL, Zorron Cheng Tao Pu L, Mangira D, Koay DSC, Kee C, Ng SC, Rerknimitr R, Aniwani S, Ang TL, Goh LK, Ho SH, Lau JYW

CASE REPORT

- 282 Bladder urothelial carcinoma extending to rectal mucosa and presenting with rectal bleeding
Aneese AM, Manuballa V, Amin M, Cappell MS

Contents

World Journal of Gastrointestinal Endoscopy
Volume 9 Number 6 June 16, 2017

ABOUT COVER

Editorial Board Member of *World Journal of Gastrointestinal Endoscopy*, Alexander Klaus, MD, MHSc, Associate Professor, Chief Doctor, Department of Surgery, Sisters of Charity Hospital Vienna, Vienna, Vienna 1060, Austria

AIM AND SCOPE

World Journal of Gastrointestinal Endoscopy (*World J Gastrointest Endosc*, *WJGE*, online ISSN 1948-5190, DOI: 10.4253) is a peer-reviewed open access (OA) academic journal that aims to guide clinical practice and improve diagnostic and therapeutic skills of clinicians.

WJGE covers topics concerning gastroscopy, intestinal endoscopy, colonoscopy, capsule endoscopy, laparoscopy, interventional diagnosis and therapy, as well as advances in technology. Emphasis is placed on the clinical practice of treating gastrointestinal diseases with or under endoscopy.

We encourage authors to submit their manuscripts to *WJGE*. We will give priority to manuscripts that are supported by major national and international foundations and those that are of great clinical significance.

INDEXING/ABSTRACTING

World Journal of Gastrointestinal Endoscopy is now indexed in Emerging Sources Citation Index (Web of Science), PubMed, and PubMed Central.

FLYLEAF

I-III Editorial Board

EDITORS FOR THIS ISSUE

Responsible Assistant Editor: *Xiang Li*
Responsible Electronic Editor: *Huan-Liang Wu*
Proofing Editor-in-Chief: *Lian-Sheng Ma*

Responsible Science Editor: *Jin-Xin Kong*
Proofing Editorial Office Director: *Jin-Lai Wang*

NAME OF JOURNAL
World Journal of Gastrointestinal Endoscopy

ISSN
ISSN 1948-5190 (online)

LAUNCH DATE
October 15, 2009

FREQUENCY
Monthly

EDITORS-IN-CHIEF
Atsushi Imagawa, PhD, Director, Doctor, Department of Gastroenterology, Mitoyo General Hospital, Kan-onji, Kagawa 769-1695, Japan

Juan Manuel Herrerias Gutierrez, PhD, Academic Fellow, Chief Doctor, Professor, Unidad de Gestión Clínica de Aparato Digestivo, Hospital Universitario Virgen Macarena, Sevilla 41009, Sevilla, Spain

EDITORIAL BOARD MEMBERS
All editorial board members resources online at <http://www.wjgnet.com>

www.wjgnet.com/1948-5190/editorialboard.htm

EDITORIAL OFFICE
Xiu-Xia Song, Director
World Journal of Gastrointestinal Endoscopy
Baishideng Publishing Group Inc
7901 Stoneridge Drive, Suite 501, Pleasanton, CA 94588, USA
Telephone: +1-925-2238242
Fax: +1-925-2238243
E-mail: editorialoffice@wjgnet.com
Help Desk: <http://www.fjgpublishing.com/helpdesk>
<http://www.wjgnet.com>

PUBLISHER
Baishideng Publishing Group Inc
7901 Stoneridge Drive, Suite 501, Pleasanton, CA 94588, USA
Telephone: +1-925-2238242
Fax: +1-925-2238243
E-mail: bpgoffice@wjgnet.com
Help Desk: <http://www.fjgpublishing.com/helpdesk>
<http://www.wjgnet.com>

PUBLICATION DATE
June 16, 2017

COPYRIGHT
© 2017 Baishideng Publishing Group Inc. Articles published by this Open-Access journal are distributed under the terms of the Creative Commons Attribution Non-commercial License, which permits use, distribution, and reproduction in any medium, provided the original work is properly cited, the use is non commercial and is otherwise in compliance with the license.

SPECIAL STATEMENT
All articles published in journals owned by the Baishideng Publishing Group (BPG) represent the views and opinions of their authors, and not the views, opinions or policies of the BPG, except where otherwise explicitly indicated.

INSTRUCTIONS TO AUTHORS
<http://www.wjgnet.com/bpg/gerinfo/204>

ONLINE SUBMISSION
<http://www.fjgpublishing.com>

Randomized Controlled Trial

Multicenter randomised controlled trial comparing the high definition white light endoscopy and the bright narrow band imaging for colon polyps

Rajvinder Singh, Kuan Loong Cheong, Leonardo Zorron Cheng Tao Pu, Dileep Mangira, Doreen Siew Ching Koay, Carmen Kee, Siew Chien Ng, Rungsun Rerknimitr, Satimai Aniwani, Tiing-Leong Ang, Khean-Lee Goh, Shiaw Hooi Ho, James Yun-Wong Lau

Rajvinder Singh, Kuan Loong Cheong, Leonardo Zorron Cheng Tao Pu, Doreen Siew Ching Koay, Gastroenterology Department, Lyell McEwin Hospital (NALHN), SA 5112, Australia

Rajvinder Singh, Leonardo Zorron Cheng Tao Pu, School of Medicine, the University of Adelaide, SA 5000, Australia

Dileep Mangira, Flinders Medical Centre, South Australia, Australia, SA 5042, Australia

Carmen Kee, Siew Chien Ng, James Yun-Wong Lau, Prince of Wales Hospital, Shatin, New Territories, Hong Kong

Rungsun Rerknimitr, Satimai Aniwani, Chulalongkorn University, Bangkok 10330, Thailand

Tiing-Leong Ang, Changi General Hospital, Singapore 529889, Singapore

Khean-Lee Goh, Shiaw Hooi Ho, University of Malaya Medical Centre, Kuala Lumpur 59100, Malaysia

Author contributions: Singh R and Lau JYW conceptualized and designed this study; Singh R, Cheong KL, Mangira D, Koay DSC, Ng SC, Rerknimitr R, Aniwani S, Ang TL, Goh LK, Ho SH and Lau JYW recruited the patients involved in this study; Singh R, Cheong KL, Zorron Cheng Tao Pu L, Kee C and Lau JYW interpreted the data, performed statistical analyses, and edited the manuscript into its final version to be published.

Institutional review board statement: Institutional medical and ethics committees of each participating hospital approved the study protocol.

Clinical trial registration statement: This study is registered at <https://clinicaltrials.gov>. The registration identification number is NCT01422577.

Informed consent statement: All study participants, or their

legal guardian, provided informed written consent prior to study enrollment.

Conflict-of-interest statement: The authors declared no conflicting interests (including, but not limited to, commercial, personal, political, intellectual, or religious interests) related to the manuscript submitted for consideration of publication.

Data sharing statement: Technical appendix and dataset available from the corresponding author at rajvinder.singh@sa.gov.au. Participants gave informed consent for data sharing.

Open-Access: This article is an open-access article which was selected by an in-house editor and fully peer-reviewed by external reviewers. It is distributed in accordance with the Creative Commons Attribution Non Commercial (CC BY-NC 4.0) license, which permits others to distribute, remix, adapt, build upon this work non-commercially, and license their derivative works on different terms, provided the original work is properly cited and the use is non-commercial. See: <http://creativecommons.org/licenses/by-nc/4.0/>

Manuscript source: Invited manuscript

Correspondence to: Dr. Rajvinder Singh, Professor of Medicine, Director of Gastroenterology, Gastroenterology Department, Lyell McEwin Hospital (NALHN), Haydown Road, Elizabeth Vale, SA 5112 Australia. rajvinder.singh@sa.gov.au
Telephone: +61-8-81829909
Fax: +61-8-81829837

Received: January 17, 2017

Peer-review started: January 19, 2017

First decision: March 13, 2017

Revised: April 4, 2017

Accepted: May 18, 2017

Article in press: May 19, 2017

Published online: June 16, 2017

Abstract

AIM

To compare high definition white light endoscopy and bright narrow band imaging for colon polyps' detection rates.

METHODS

Patients were randomised to high definition white light endoscopy (HD-WLE) or the bright narrow band imaging (bNBI) during withdrawal of the colonoscope. Polyps identified in either mode were characterised using bNBI with dual focus (bNBI-DF) according to the Sano's classification. The primary outcome was to compare adenoma detection rates (ADRs) between the two arms. The secondary outcome was to assess the negative predictive value (NPV) in differentiating adenomas from hyperplastic polyps for diminutive rectosigmoid lesions.

RESULTS

A total of 1006 patients were randomised to HD-WLE ($n = 511$) or bNBI ($n = 495$). The mean of adenoma per patient was 1.62 and 1.84, respectively. The ADRs in bNBI and HD-WLE group were 37.4% and 39.3%, respectively. When adjusted for withdrawal time (OR = 1.19, 95%CI: 1.15-1.24, $P < 0.001$), the use of bNBI was associated with a reduced ADR (OR = 0.69, 95%CI: 0.52-0.92). Nine hundred and thirty three polyps (86%) in both arms were predicted with high confidence. The sensitivity (Sn), specificity (Sp), positive predictive value and NPV in differentiating adenomatous from non-adenomatous polyps of all sizes were 95.9%, 87.2%, 94.0% and 91.1% respectively. The NPV in differentiating an adenoma from hyperplastic polyp using bNBI-DF for diminutive rectal polyps was 91.0%.

CONCLUSION

ADRs did not differ between bNBI and HD-WLE, however HD-WLE had higher ADR after adjustment of withdrawal time. bNBI surpassed the PIVI threshold for diminutive polyps.

Key words: Narrow band imaging; Dual focus; High definition; White light endoscopy; Colon; Polyps; Randomised controlled trial

© The Author(s) 2017. Published by Baishideng Publishing Group Inc. All rights reserved.

Core tip: Adenoma detection rate (ADR) is one of the most important quality measures in colonoscopy and bright narrow band imaging (bNBI) can theoretically improve imaging and thus reconnaissance of colorectal polyps. In addition, the magnification using bNBI with dual focus (bNBI-DF) allows the prediction of the polyp's histology. This multicenter randomised controlled trial was conceived to compare the ADR of high definition white light endoscopy (HD-WLE) vs bNBI during withdrawal of screening colonoscopies. No difference was found in ADR between HD-WLE and bNBI. The

prediction of diminutive distal polyps with bNBI-DF was satisfactory according to the American Society for Gastrointestinal Endoscopy's threshold.

Singh R, Cheong KL, Zorron Cheng Tao Pu L, Mangira D, Koay DSC, Kee C, Ng SC, Rerknimitr R, Aniwani S, Ang TL, Goh LK, Ho SH, Lau JYW. Multicenter randomised controlled trial comparing the high definition white light endoscopy and the bright narrow band imaging for colon polyps. *World J Gastrointest Endosc* 2017; 9(6): 273-281 Available from: URL: <http://www.wjgnet.com/1948-5190/full/v9/i6/273.htm> DOI: <http://dx.doi.org/10.4253/wjge.v9.i6.273>

INTRODUCTION

Colorectal cancer is a leading cause of morbidity and mortality worldwide^[1]. Its incidence in Asia-Pacific region has been rising at an alarming rate^[2,3]. Screening colonoscopy and polypectomy have been shown to reduce the mortality related to colorectal cancer^[4]. Despite its effectiveness, the potential to miss polyps can range between 15% to 30% with screening colonoscopy^[5]. Current guidelines recommend removal of all visible polyps (except benign diminutive distal polyps) and subsection to histological assessment, irrespective of their endoscopic morphological features. This could make colonoscopy a less cost effective screening strategy^[6]. Novel image enhanced endoscopic technologies have the potential to overcome some of the limitations of standard white light endoscopy (WLE) by increasing the detection rate of polyps/neoplasms and providing real-time histological diagnosis.

Narrow band imaging (NBI) is one of the most widely available and convenient to use technologies developed. Narrowed bandwidth light is used to visualize superficial vasculature and mucosal pit patterns in real-time^[7,8]. The light penetrates the mucosa and submucosa and is absorbed by hemoglobin in surface microvessels, which appear as linear darker structures^[9]. This enables the endoscopist to differentiate thicker and more irregular vascular landmarks. Multiple classification systems based on surface pit-pattern and vascular pattern have been developed and validated to differentiate hyperplastic polyps from adenomatous polyps^[10,11]. This real-time differentiation has been proposed as a part of "resect and discard" strategy in which diminutive polyps (measuring < 5 mm) are resected without histological assessment and hyperplastic polyps in rectosigmoid region are left *in situ*^[12]. This approach could confer substantial cost savings by avoiding unwarranted histological evaluation^[13] and may avoid complications related to polypectomy^[14]. Few published studies showed no significant difference in adenoma detection rates (ADRs) between NBI and WLE^[15-18]. Only one meta-analysis demonstrated an increased accuracy of NBI over WLE in characterising colonic polyps with hierarchical summary receiver-operating characteristic

curves exceeding 0.90^[19]. Dimmer images compared to WLE^[20], type of endoscopes and monitors used (high vs low resolution), inconsistent color enhancement settings and endoscopists' experience have been proposed as potential reasons for the unimpressive performance of NBI.

Recently, a newer generation NBI system has been introduced. The system appears to provide brighter NBI (bNBI) images (by 2 fold) in a high-definition (HD) mode and has the option of further magnifying a particular target with the dual focus (DF) magnification function, up to 65 times. These provide an in-depth view of desired areas of the mucosa with clear and crisp images, which potentially may improve polyp detection as well as characterisation.

In this study we hypothesized that, when compared to high definition white light endoscopy (HD-WLE), the newer generation colonoscopes with the brighter NBI capability and the bNBI with dual focus (bNBI-DF) magnification mode could improve ADR and accurately predict polyp histology.

MATERIALS AND METHODS

Study design

We performed a prospective multicenter randomised controlled trial across four centers in the Asia Pacific region (The Prince of Wales Hospital, Hong Kong; The King Chulalongkorn Memorial Hospital, Thailand; Changi General Hospital, Singapore and The Lyell McEwin Hospital, Australia) from October 2010 to April 2012. Institutional medical and ethics committees of each participating hospital approved the study protocol. The study was registered with clinicaltrials.gov (NCT 01422577).

Study population

We recruited subjects who were referred for outpatient screening colonoscopy across four centers during the study period. All patients were 40 years and older with no significant medical comorbidities and met the criteria for average risk for the colorectal cancer with no previous colonoscopies in the last five years. Patients were excluded if they were on anti-platelets or anticoagulants, had any colorectal surgical resection, inflammatory bowel disease, familial colorectal cancer syndromes (familial adenomatous polyposis and hereditary non-polyposis colorectal cancer), were unable to provide written informed consent or had poor bowel preparation.

All participating subjects were informed about the study and written informed consent was obtained before initiation of the procedure. Participants were allowed to have clear fluids on the day before the procedure and were given four liters of polyethyleneglycol as bowel preparation followed by a 6-h fast (previous day preparation). Appropriate doses of conscious sedation (Fentanyl and Midazolam \pm Propofol) were given prior to and during the procedure.

Eleven endoscopists participated in the study. Each of the endoscopists had extensive experience with the use of NBI in colonoscopy having performed more than 2000 procedures each using the earlier generation colonoscopes with NBI. The CF-HQ 190 or 290 series colonoscopes with the DF mode for magnification (Olympus, Tokyo Co. Ltd) were used for all patients. The colonoscope was connected to a CLV video processor with images transmitted to HD monitors (1280 \times 1024 pixels). All participating endoscopists were consultants who had experience with an earlier generation of NBI scopes.

Randomisation

Subjects were randomised to receive the examination during withdrawal either in the HD-WLE or in the bNBI mode, followed by bNBI-DF to characterise each polyp that was identified in both arms (Figure 1). The colonoscope was inserted using HD-WLE until caecum was reached, in all subjects. Randomisation took place once the caecum or appendiceal orifice was identified and adequacy of bowel preparation was established as per the modified Aronchick scale^[21]. Subjects with suboptimal bowel preparation were excluded. Patients were randomised according to a computer-generated randomisation scheme in blocks of twenty. Allocation to HD-WLE or bNBI mode of withdrawal was kept in a concealed envelope and revealed by a research assistant to the endoscopist just before withdrawal was initiated. A dedicated nurse assistant monitored both insertion (time to reach caecum from insertion) and withdrawal (time of scope removal from initiation of withdrawal) times with a stopwatch. During insertion, the stopwatch was paused during patient position change or while exerting abdominal pressure to facilitate colonoscope advancement. Similarly, the stopwatch was paused during withdrawal when biopsies or polypectomies were performed. The withdrawal time was set to a minimum of 6 min in both bNBI and HD-WLE arms and endoscopists were deliberately reminded of the time during the withdrawal phase.

Data collection

Colonoscopy withdrawal commenced from the caecum with the patient in the left lateral position and was carried out according to randomisation. Location of each polyp was identified using anatomical landmarks and categorised into either the right or left side of the colon. The size of each polyp was assessed using diameter of the opened biopsy forceps (7.5 mm) or the diameter of the snare used. Identified polyps were characterised by using bNBI-DF mode in both arms.

Characterisation of polyps was made by bNBI-DF using Sano's classification, which has been found to be valid tool for predicting polyp histology^[11]. The classification was based on vascular pattern on the surface of the polyp. Characterisation of polyps was made with high confidence if the polyp demonstrated endoscopic features, which were strongly suggestive of

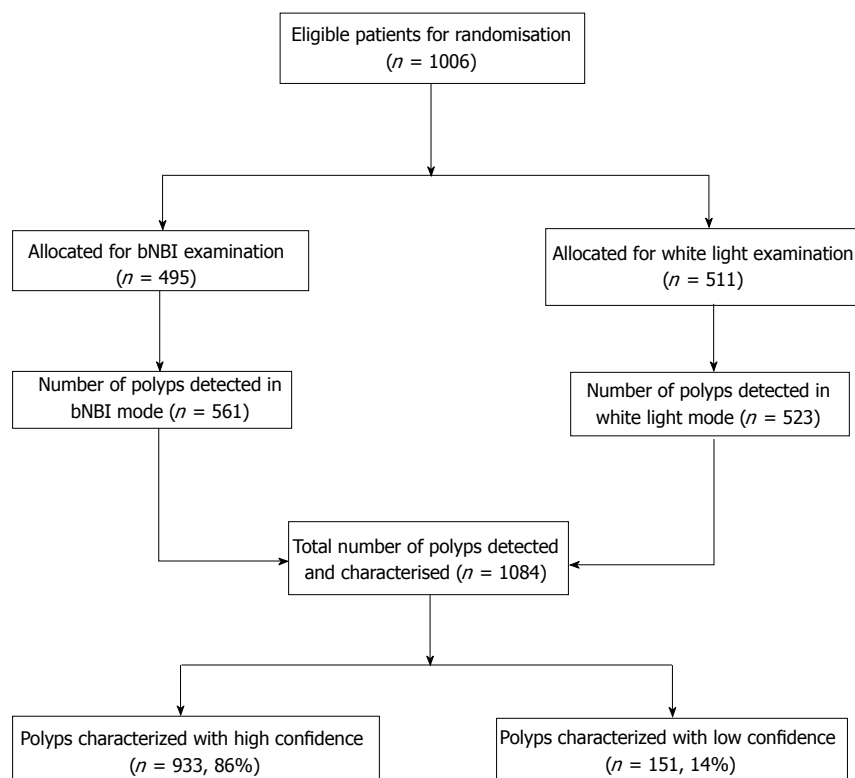


Figure 1 Study flow chart. bNBI: Bright narrow band imaging.

its pathology according to Sano's classification. Polyps were characterised with low confidence if exposure was limited secondary to non-removable debris, inadequate focus or if the polyp demonstrated features of more than one Sano's class.

The preferred mode of polypectomy was left to the endoscopists' discretion. Once the polypectomy was performed, mucosal viewing was switched back to respective mode as per randomisation. Each identified polyp was resected and retrieved into an individual container for pathologic examination. Pathologists with experience in gastrointestinal tract, who were blinded for the endoscopic mode of the examination, evaluated all resected polyps.

Outcomes

The primary outcome of the study was to compare the ADR, defined as percentage of patients with one or more adenomatous polyp detected, between the two arms (HD-WLE vs bNBI). The secondary outcome was to assess if bNBI-DF could meet the American Society for Gastrointestinal Endoscopy (ASGE)'s Preservation and Incorporation of Valuable Endoscopic Innovation (PIVI) threshold in predicting histopathology of colon polyps^[22]. We only assessed the second criteria from the PIVI guideline [where the technology, when used with high confidence, should provide > 90% negative predictive value (NPV) for adenomatous histology in diminutive rectosigmoid polyps] as we believed that this strategy would be more practical and generalizable.

Sample size

We previously conducted a colonoscopy screening study amongst average risk Hong Kong Chinese subjects older than 50 years of age and found an ADR of 30%^[23]. The prevalence of colon adenomas in asymptomatic subjects in Asia is unknown and is likely to vary across different ethnic groups. The sample size evaluation was based on assumption that improved optics and bNBI is superior to the HD-WLE mode in detection of colon polyps. We thus hypothesized that bNBI would be able to detect more adenomas than HD-WLE. A sample size of 500 per group was required to detect a relative risk of 1.28 (*i.e.*, a difference of 38.4% vs 30%) with a power of 80% and a type 1 two-sided error of 0.05.

Statistical analysis

Continuous variables were compared using the *t*-test if normally distributed. Categorical variables were compared using the χ^2 test or Fisher's exact test when appropriate. The Mann-Whitney's *U* test was used for skewed variables. To compare the detection of all adenomas and hyperplastic polyps (per-polyp analysis), the Poisson regression model or negative binomial regression model was used. The accuracy of bNBI-DF in examining early colorectal lesions was evaluated using Sano's classification compared to the final histopathology and measures of sensitivity (Sn), specificity (Sp), positive predictive value (PPV), and NPV; and their correspondent 95% CIs were performed. These diagnostic tests were calculated by means of

Table 1 Characteristics of patients and colonoscopy performance in both groups *n* (%)

Parameters	bNBI (<i>n</i> = 495)	WLE (<i>n</i> = 511)	<i>P</i> value
Patients			
Men	210 (42.43)	237 (46.38)	0.207
Age, mean ± SD	58.31 ± 6.17	58.36 ± 6.13	0.904
BMI, mean ± SD	23.75 ± 3.29	23.74 ± 2.99	0.942
Current smoker	24 (4.9)	29 (5.7)	0.536
Current drinker	38 (7.7)	44 (8.7)	0.815
Current use of NSAID	6 (1.2)	9 (1.8)	0.705
Current use of aspirin	13 (2.6)	22 (4.3)	0.345
Current use of warfarin	0	2 (0.4)	0.232
Comorbidities			
Hypertension	123 (24.8)	131 (25.6)	0.774
Diabetes	56 (11.3)	32 (6.3)	0.005
Ischemic heart disease	10 (2.0)	10 (2.0)	0.943
Chronic obstructive airway disease	2 (0.4)	0	0.15
Previous stroke	1 (0.2)	2 (0.4)	0.582
Cirrhosis	1 (0.2)	1 (0.2)	0.982
Gastro-esophageal reflux	10 (2)	8 (1.6)	0.587
Dyslipidemia	31 (6.3)	29 (5.7)	0.694
History of cancer	19 (3.8)	12 (2.3)	0.172
Examination time (min), mean ± SD			
Time to cecum	6.66 ± 4.56	7.06 ± 4.94	0.183
Time for withdrawal	11.23 ± 6.36	9.84 ± 5.03	< 0.0001

bNBI: Bright narrow band imaging; WLE: White light endoscopy.

the generalized estimating equations to account for the clustering of polyps within patients.

In addition, we performed statistical analysis to examine the effect of the withdrawal time, entered as a covariate, on the ADR on a per-patient level. Specifically, a multiple logistic regression was used to estimate adjusted odds ratio (OR) and its 95%CI with all variables (see Table 1) excluding time taken to reach cecum, entered as covariates. The presence or absence of one or more adenomas was considered a response variable. Mode of withdrawal (HD-WLE or bNBI) was forced to remain into all regression models. Two-tailed *P* value lower than 0.05 was considered statistically significant. Multiple outcomes were tested without adjusting for the type I error rate. Statistical tests were performed with the use of SPSS software (version 19.0, SPSS, Chicago, IL, United States).

RESULTS

A total of 1006 patients were enrolled during the 17-mo study period (October 2010 to April 2012), of which 44.4% were men and the mean age was 58 years. Four hundred and ninety-five participants were randomised to the bNBI arm and 511 participants to the HD-WLE arm. Table 1 demonstrates the demographics of the study population in the two arms by age, gender, body mass index (BMI), social habits, medical comorbidities and mean insertion and withdrawal times. There were no significant differences in baseline characteristics in both arms except for the prevalence of diabetes, which was seen more frequently in bNBI arm (bNBI, *n* = 56

Table 2 Pathologic diagnosis in both bright narrow band imaging and high definition white light endoscopy *n* (%)

	bNBI (<i>n</i> = 495)	HD-WLE (<i>n</i> = 511)	<i>P</i> value
Adenomas	341	326	0.425
Subjects with adenomas ² (ADR)	185 (37.4)	201 (39.3)	0.523
Adenomas per adenoma carrier ¹	1.84	1.62	0.129
Size			
Subjects with 0-5 mm adenomas ²	149 (30.1)	162 (31.2)	0.583
Subjects with 6-9 mm adenomas ²	52 (10.5)	52 (10.2)	0.864
Subjects with ≥ 10 mm adenomas ²	31 (6.3)	31 (6.1)	0.897
Adenomas < 10 mm	306	290	0.283
Adenomas 0-5 mm	241	229	0.334
Adenomas 6-9 mm	65	61	0.896
Adenomas ≥ 10 mm	35	36	0.837
Location			
Right-sided adenomas	157	155	0.400
Left-sided adenomas	168	159	0.797
Histopathology			
Carcinomas	3	5	0.418
Tubular	315	304	0.343
Tubulovillous	10	12	0.689
Villous	2	0	NA
Adenomas with high grade dysplasia	6	7	0.992
Hyperplastic polyps	178	136	0.020
Hyperplastic polyps < 10 mm	176	135	0.020
SSA/Ps	13	7	0.257
Subjects with SSA/P, <i>n</i> (SSA/P-detection rate in %)	13 (2.6)	6 (1.2)	0.091
Inflammatory polyps	12	14	0.572
Indeterminate or non-significant	16	15	0.987
Not submitted for histologic examinations	13	31	0.010
Xanthoma	1	1	0.961

¹Mann-Whitney's *U* test used; ² χ^2 test or Fisher's exact test used as appropriate. HD-WLE: High definition white light endoscopy; bNBI: Bright narrow band imaging.

(11.3%) vs HD-WLE, *n* = 32 (5.3%). The mean time to reach caecum was similar in both arms; however, the mean withdrawal time was 1.39 min longer in the bNBI arm (*P* < 0.05).

Adenoma detection rates

A total of 1084 polyps were detected in both arms. The overall mean polyp detection rate per colonoscopy in the bNBI arm was 1.13 and in the HD-WLE arm was 1.02 (*P* = 0.093). Two hundred and sixty subjects in the bNBI arm (52.53%) and 257 in the HD-WLE group (50.29%) had one or more polyp (*P* = 0.479). About two thirds (*n* = 638) of polyps were identified on left side of the colon and 92.8 % (*n* = 1005) of polyps were less than 10mm in size.

The ADR in the bNBI group and HD-WLE group was 37.4% and 39.3% respectively (185 of 495 subjects and 201 of 511 subjects had at least one adenoma) (Table 2). Table 2 demonstrates the pathological diagnosis of polyps detected in both arms. Sixty one percent (341/561) of polyps in bNBI arm and 62% (326/523) in HD-WLE arm were adenomatous (*P* = 0.425) in nature. ADRs were directly related to withdrawal time in both arms, as shown in Figure 2, ADR progressively

Table 3 Polyp categorization according to Sano's classification - Hyperplastic/SSA/P vs adenoma/cancer

	Pathology		Total
	Hyperplastic/SSA/P	Adenoma/cancer	
Sano's classification			
I	245	24	269
II, IIIa, IIIb	36	555	591
Total	281	579	

Sensitivity of predicting adenoma = 95.7% (93.4% to 97.2%); Specificity of predicting adenoma = 86.5% (81.7% to 90.2%); PPV of predicting adenoma = 93.9% (91.7% to 95.6%); NPV of predicting adenoma = 91.0% (86.4% to 94.0%).

increased with increasing withdrawal time. A higher number of hyperplastic polyps were identified in bNBI arm than in HD-WLE arm (bNBI, $n = 178$ vs HD-WLE, $n = 136$), which was statistically significant ($P = 0.021$). According to logistic regression analysis, withdrawal time (OR = 1.19, 95%CI: 1.15-1.24, $P < 0.001$), age (OR = 1.03, 95%CI: 1.00-1.05, $P = 0.032$) and male sex (OR = 1.49, 95%CI: 1.11-2.00, $P = 0.008$) were independently associated with an improved ADR when adjusted for differences in baseline variables. When we adjusted for withdrawal time (OR = 1.19, 95%CI: 1.15-1.24, $P < 0.001$), the use of bNBI was associated with a reduced ADR (OR = 0.69, 95%CI: 0.52-0.92).

Polyp characterisation

Nine hundred and thirty-three polyps (86%) from both arms were categorized into various classes with high confidence according to Sano's classification. The other 13.9% ($n = 151$) were classified with low confidence. Among the high confidence polyps, 308 (33%) polyps were Sano type I; 598 (64%) were type II; 20 (2.1%) were type IIIA and 7 (0.75%) were type IIIB.

The Sn, Sp, PPV and NPV in differentiating adenomatous from non-adenomatous polyps of all sizes were 95.7%, 86.5%, 93.9% and 91.0% respectively (Table 3). The Sn, Sp, PPV and NPV in differentiating an adenoma from cancer were 87.5%, 100%, 100%, and 99.8% respectively (Table 4). The Sn, Sp, PPV and NPV of bNBI-DF in the characterisation of polyps with 5mm or less in the rectosigmoid region were 94.5%, 95.4%, 94.8% and 93.7% respectively (Table 5).

DISCUSSION

This prospective multicenter randomised study compared two different modalities: HD-WLE and bNBI to assess if there was a difference in ADRs. In addition, bNBI-DF was used to characterise polyps using the Sano's classification. We did not find a statistically significant improvement in ADR with bNBI when compared to HD-WLE. Polyp characterisation was effective with bNBI-DF in differentiating adenomas from hyperplastic polyps in diminutive distal polyps, meeting the second PIVI standard.

Table 4 Polyp characterisation according to Sano's classification - Adenoma vs cancer

	Pathology		Total
	Adenoma	Cancer	
Sano's classification			
II, IIIa	547	1	548
IIIB	0	7	7
Total	547	8	

Sensitivity of predicting cancer = 87.5% (47.4% to 99.7%); Specificity of predicting cancer = 100% (99.3% to 100%); PPV of predicting cancer = 100% (59.0% to 100%); NPV of predicting cancer = 99.8% (98.7% to 100%).

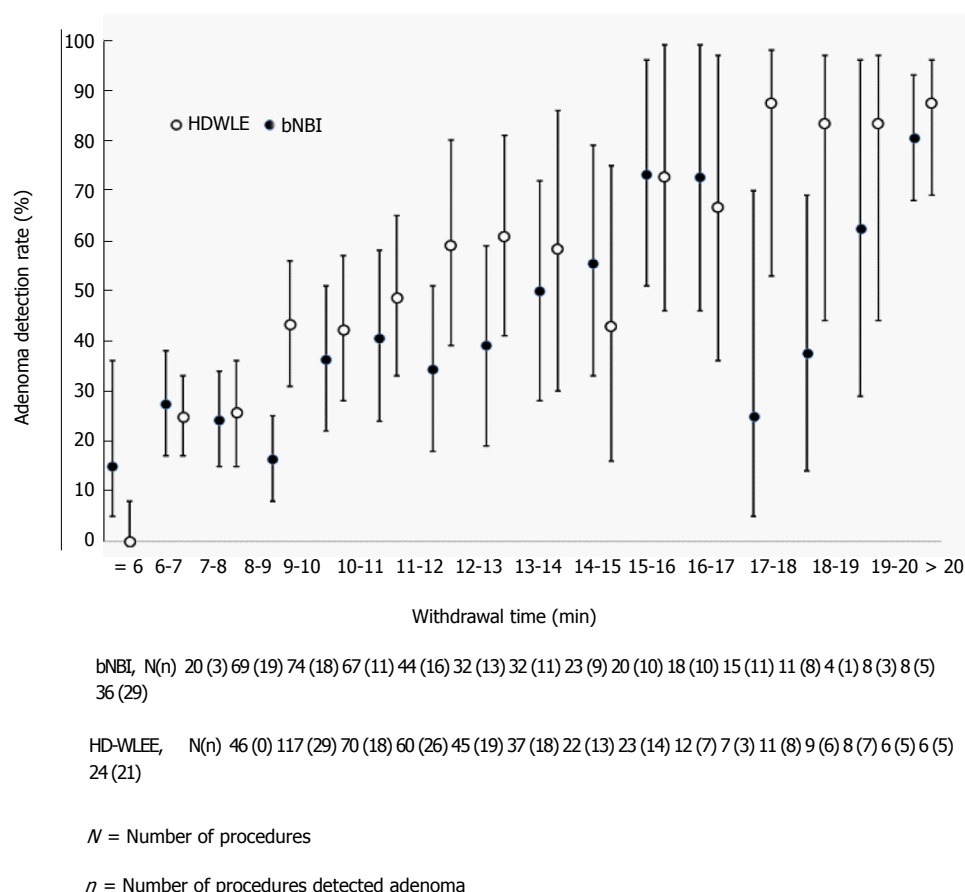
Table 5 Polyp characterisation based on Sano's classification for polyps in the rectosigmoid region (5 mm or less in size)

	Pathology		Total
	Hyperplastic	Adenoma/cancer	
Sano's classification			
I	146	10	156
II, IIIa, IIIb	7	130	137
Total	153	140	

Sensitivity of predicting adenoma = 94.5% (89.1% to 97.3%); Specificity of predicting adenoma = 95.4% (90.6% to 97.8%); PPV of predicting adenoma = 94.8% (89.5% to 97.5%); NPV of predicting adenoma = 93.7% (87.7% to 96.9%).

The study design was similar to that of Rex and Helbig, who evaluated an earlier version of NBI^[24]. Their study represented a single operator experience, in contrast to this study, which involved several academic centers. In a recent tandem study, Leung *et al*^[25] compared bNBI to HD-WLE in colonoscopy. Subjects were submitted to bNBI first and followed by HD-WLE or *vice versa*. The use of bNBI was associated with a higher ADR with a higher number of polyps detected per subject. However, for the HD-WLE group, the older generation 260 series colonoscopes were used. Illumination with 260 series colonoscopes is considerably less sharp when compared to the 190/290 series colonoscopes. Hence, one cannot be certain if the superiority of bNBI in finding adenomas was not a result of a "brighter processor". In another study by Wallace *et al*^[26], average risk subjects presenting for screening were randomised to receive the examination by a standard colonoscope (H180) or a dual focus colonoscope (HQ-190). ADR were similar between both groups (52% vs 50%). The NPV for diminutive rectosigmoid polyps were 96 and 97% respectively, which was not too dissimilar to our study.

Multiple randomised studies and a meta-analysis compared ADRs of NBI with conventional colonoscopy. The results have thus far been mixed with very few studies^[27,28] demonstrating improved ADRs with NBI. Despite having endoscopists with considerable experience in using NBI and a large sample size, we were unable to demonstrate a statistically significant improvement in ADR. Actually, this study suggests that NBI could actually decrease the ADR if used exclusively for



The figure represents the adenoma detection rate (%) and error bars indicate 95%CI

Figure 2 Adenoma detection rate vs withdrawal time. HD-WLE: High definition white light endoscopy; bNBI: Bright narrow band imaging.

overview of the whole colon during withdrawal. The similar ADRs achieved in this study may be attributed to the fact that improved resolution could be achieved using the same high definition processor for both bNBI and HD-WLE. These findings are not too dissimilar to studies conducted in the past with older generation systems^[29-31].

Previous studies conducted using bNBI to differentiate adenomatous from non-adenomatous lesions demonstrated accuracies ranging from 77% to 93%^[8,32-36]. Sessile serrated adenomas/polyps (SSA/Ps), which endoscopically may resemble hyperplastic polyps but have malignant potential, were detected in 1.8% of all polyps. Previous studies have shown the prevalence of SSAs ranging from 1% to 7%^[37], but a more recent study shows that the reported prevalence of SSA/Ps is raising with the years and it can get up to 15.8%^[38]. This difference may be due in part to the different prevalence rate in the studied population, which included predominantly a younger Asian cohort. These polyps unfortunately do not fit into any of the available classifications at the time the study was performed.

This study adds strength to the usefulness of bNBI in characterising colonic lesions in real-time. This "endopathology" concept supports the "resect and discard" approach that carries many practical

advantages. In a simulation model by Hassan *et al*^[6], this strategy resulted in a substantial economic benefit without any impact on efficacy. Kessler *et al*^[13] demonstrated that endoscopic diagnosis of polyp histology during colonoscopy and forgoing pathologic examination would result in substantial up-front cost savings whilst the downstream consequences of the resulting incorrect surveillance intervals appear to be negligible. bNBI-DF used in this study not only successfully met the second PIVI threshold established by the ASGE but also demonstrated the highest accuracy so far in differentiating adenomas from hyperplastic polyps^[6]. More than 85% of polyps were characterised with high confidence and the overall sensitivity and specificity demonstrated was significantly higher than in other studies^[18].

This study has some limitations. First, the mean withdrawal time was prolonged in both arms, but particularly in the bNBI's arm (11.23 min vs 9.84 min). In a multiple regression model, examination of the colon in the HD-WLE mode was associated with a better ADR. Similar to this study, longer withdrawal times with bNBI were also noted in a meta-analysis by Jin *et al*^[39] as well as by Rex *et al*^[24]. This could be potentially explained by the lack of confidence in assessing the mucosa in an overview mode with bNBI, although endoscopists were

experienced with previous versions of the modality. The ADRs in both arms of the study were higher than the target ADR set by the United States Multi-Society Task Force (men > 25% and women > 15%)^[40]. Longer withdrawal times and high-definition imaging are the possible reasons for the overall higher adenoma detection rates.

In conclusion, ADR was not different between bNBI and HD-WLE. Male sex, larger withdrawal time and older age were positively correlated with ADR. When adjusted for withdrawal time, HD-WLE had higher ADR. With bNBI-DF, 85% of the polyps could be characterised with high confidence, of which more than 95% of them were predicted accurately. The most worthwhile strategy to reduce the risks associated with unwarranted polypectomies and save costs incurred with pathological assessment of polyps could be a "combination strategy" where withdrawal is performed using HD-WLE and polyp characterisation with bNBI-DF.

COMMENTS

Background

Colorectal polyps are the precursors of colorectal cancer and their removal through colonoscopy is effective in preventing colorectal cancer. New technologies continuously improve the imaging ability of the colonoscopes. Whether these new technologies effectively differ from each other for detection of polyps is debatable.

Research frontiers

The development of state-of-the-art endoscopes are not always associated with better results. Technologies that enhance imaging supposedly could improve the detection of polyps. So far, the use of light filters to improve adenoma detection rate (ADR) is not recommended.

Innovations and breakthrough

Improvement in ADR is important as it is inversely correlated with colorectal cancer risk. The improvement of old technologies has been shown beneficial for detection of polyps (*i.e.*, HD vs non-HD imaging). However, comparison between new technologies is less studied. The authors therefore evaluated the use of two cutting-edge technologies [high definition white light endoscopy (HD-WLE) and bright narrow band imaging (bNBI)] to detect colorectal polyps.

Applications

Although virtual chromoendoscopy is useful for characterising polyps, its use for detecting them did not differ from HD-WLE in this study. Therefore, even though there is improvement in the brightness with the new light filter, it is still not recommended as standard of care for screening purposes.

Terminology

Adenoma detection rate is defined as the percentage of patients that were submitted to colonoscopy and had at least one adenomatous polyp. Narrow band imaging is an optical image-enhanced technology based on specific light wavelengths, which allows enhanced visualisation of vasculature and superficial mucosal surface.

Peer-review

The authors compared ADR of two different modalities. They found that HD-WLE had higher ADR after adjustment of withdrawal time. bNBI had satisfactory negative predictive value in differentiating adenomatous from non-adenomatous histology in diminutive polyps, which was above the preservation and incorporation of valuable endoscopic innovation threshold. The paper is well written.

REFERENCES

- 1 Winawer SJ, Zauber AG, Ho MN, O'Brien MJ, Gottlieb LS, Sternberg SS, Wayne JD, Schapiro M, Bond JH, Panish JF. Prevention of colorectal cancer by colonoscopic polypectomy. The National Polyp Study Workgroup. *N Engl J Med* 1993; **329**: 1977-1981 [PMID: 8247072 DOI: 10.1056/NEJM199312303292701]
- 2 Sung JJ, Lau JY, Goh KL, Leung WK. Increasing incidence of colorectal cancer in Asia: implications for screening. *Lancet Oncol* 2005; **6**: 871-876 [PMID: 16257795 DOI: 10.1016/S1470-2045(05)70422-8]
- 3 Muto T, Kotake K, Koyama Y. Colorectal cancer statistics in Japan: data from JSCCR registration, 1974-1993. *Int J Clin Oncol* 2001; **6**: 171-176 [PMID: 11706554]
- 4 Nishihara R, Wu K, Lochhead P, Morikawa T, Liao X, Qian ZR, Inamura K, Kim SA, Kuchiba A, Yamauchi M, Imamura Y, Willett WC, Rosner BA, Fuchs CS, Giovannucci E, Ogino S, Chan AT. Long-term colorectal-cancer incidence and mortality after lower endoscopy. *N Engl J Med* 2013; **369**: 1095-1105 [PMID: 24047059 DOI: 10.1056/NEJMoa1301969]
- 5 van Rijn JC, Reitsma JB, Stoker J, Bossuyt PM, van Deventer SJ, Dekker E. Polyp miss rate determined by tandem colonoscopy: a systematic review. *Am J Gastroenterol* 2006; **101**: 343-350 [PMID: 16454841 DOI: 10.1111/j.1572-0241.2006.00390.x]
- 6 Hassan C, Pickhardt PJ, Rex DK. A resect and discard strategy would improve cost-effectiveness of colorectal cancer screening. *Clin Gastroenterol Hepatol* 2010; **8**: 865-869, 869.e1-3 [PMID: 20621680 DOI: 10.1016/j.cgh.2010.05.018]
- 7 Gono K, Yamazaki K, Doguchi N, Nonami T, Obi T, Yamaguchi M, Ohyama N, Machida H, Sano Y, Yoshida S, Hamamoto Y, Endo T. Endoscopic observation of tissue by narrow band illumination. *Opt Rev* 2003; **10**: 211-215 [DOI: 10.1007/s10043-003-0211-8]
- 8 Machida H, Sano Y, Hamamoto Y, Muto M, Koza T, Tajiri H, Yoshida S. Narrow-band imaging in the diagnosis of colorectal mucosal lesions: a pilot study. *Endoscopy* 2004; **36**: 1094-1098 [PMID: 15578301 DOI: 10.1055/s-2004-826040]
- 9 Postic G, Lewin D, Bickerstaff C, Wallace MB. Colonoscopic miss rates determined by direct comparison of colonoscopy with colon resection specimens. *Am J Gastroenterol* 2002; **97**: 3182-3185 [PMID: 12492208 DOI: 10.1111/j.1572-0241.2002.07128.x]
- 10 Oba S, Tanaka S, Sano Y, Oka S, Chayama K. Current status of narrow-band imaging magnifying colonoscopy for colorectal neoplasia in Japan. *Digestion* 2011; **83**: 167-172 [PMID: 21266811 DOI: 10.1159/000321807]
- 11 Uraoka T, Saito Y, Ikematsu H, Yamamoto K, Sano Y. Sano's capillary pattern classification for narrow-band imaging of early colorectal lesions. *Dig Endosc* 2011; **23** Suppl 1: 112-115 [PMID: 21535215 DOI: 10.1111/j.1443-1661.2011.01118.x]
- 12 Rex DK. Reducing costs of colon polyp management. *Lancet Oncol* 2009; **10**: 1135-1136 [PMID: 19910251 DOI: 10.1016/S1470-2045(09)70342-0]
- 13 Kessler WR, Imperiale TF, Klein RW, Wielage RC, Rex DK. A quantitative assessment of the risks and cost savings of forgoing histologic examination of diminutive polyps. *Endoscopy* 2011; **43**: 683-691 [PMID: 21623556 DOI: 10.1055/s-0030-1256381]
- 14 Levin TR, Zhao W, Conell C, Seff LC, Manninen DL, Shapiro JA, Schulman J. Complications of colonoscopy in an integrated health care delivery system. *Ann Intern Med* 2006; **145**: 880-886 [PMID: 17179057 DOI: 10.7326/0003-4819-145-12-200612190-00004]
- 15 Dinesen L, Chua TJ, Kaffes AJ. Meta-analysis of narrow-band imaging versus conventional colonoscopy for adenoma detection. *Gastrointest Endosc* 2012; **75**: 604-611 [PMID: 22341105 DOI: 10.1016/j.gie.2011.10.017]
- 16 Nagorni A, Bjelakovic G, Petrovic B. Narrow band imaging versus conventional white light colonoscopy for the detection of colorectal polyps. *Cochrane Database Syst Rev* 2012; **1**: CD008361 [PMID: 22258983 DOI: 10.1002/14651858.CD008361.pub2]
- 17 Pasha SF, Leighton JA, Das A, Harrison ME, Gurudu SR, Ramirez FC, Fleischer DE, Sharma VK. Comparison of the yield and

- miss rate of narrow band imaging and white light endoscopy in patients undergoing screening or surveillance colonoscopy: a meta-analysis. *Am J Gastroenterol* 2012; **107**: 363-370; quiz 371 [PMID: 22186978 DOI: 10.1038/ajg.2011.436]
- 18 **van den Broek FJ**, Reitsma JB, Curvers WL, Fockens P, Dekker E. Systematic review of narrow-band imaging for the detection and differentiation of neoplastic and nonneoplastic lesions in the colon (with videos). *Gastrointest Endosc* 2009; **69**: 124-135 [PMID: 19111693 DOI: 10.1016/j.gie.2008.09.040]
 - 19 **McGill SK**, Evangelou E, Ioannidis JP, Soetikno RM, Kaltenbach T. Narrow band imaging to differentiate neoplastic and non-neoplastic colorectal polyps in real time: a meta-analysis of diagnostic operating characteristics. *Gut* 2013; **62**: 1704-1713 [PMID: 23300139 DOI: 10.1136/gutjnl-2012-303965]
 - 20 **Dekker E**, van den Broek FJ, Reitsma JB, Hardwick JC, Offerhaus GJ, van Deventer SJ, Hommes DW, Fockens P. Narrow-band imaging compared with conventional colonoscopy for the detection of dysplasia in patients with longstanding ulcerative colitis. *Endoscopy* 2007; **39**: 216-221 [PMID: 17385106 DOI: 10.1055/s-2007-966214]
 - 21 **Aronchick CA**, Lipshutz WH, Wright SH, DuFrane F, Bergman G. Validation of an instrument to assess colon cleansing. *Am J Gastroenterol* 1999; **94**: 2667
 - 22 **Rex DK**, Kahi C, O'Brien M, Levin TR, Pohl H, Rastogi A, Burgart L, Imperiale T, Ladabaum U, Cohen J, Lieberman DA. The American Society for Gastrointestinal Endoscopy PIVI (Preservation and Incorporation of Valuable Endoscopic Innovations) on real-time endoscopic assessment of the histology of diminutive colorectal polyps. *Gastrointest Endosc* 2011; **73**: 419-422 [PMID: 21353837 DOI: 10.1016/j.gie.2011.01.023]
 - 23 **Sung JJ**, Chan FK, Leung WK, Wu JC, Lau JY, Ching J, To KF, Lee YT, Luk YW, Kung NN, Kwok SP, Li MK, Chung SC. Screening for colorectal cancer in Chinese: comparison of fecal occult blood test, flexible sigmoidoscopy, and colonoscopy. *Gastroenterology* 2003; **124**: 608-614 [PMID: 12612899 DOI: 10.1053/gast.2003.50090]
 - 24 **Rex DK**, Helbig CC. High yields of small and flat adenomas with high-definition colonoscopes using either white light or narrow band imaging. *Gastroenterology* 2007; **133**: 42-47 [PMID: 17631129 DOI: 10.1053/j.gastro.2007.04.029]
 - 25 **Leung WK**, Lo OS, Liu KS, Tong T, But DY, Lam FY, Hsu AS, Wong SY, Seto WK, Hung IF, Law WL. Detection of colorectal adenoma by narrow band imaging (HQ190) vs. high-definition white light colonoscopy: a randomized controlled trial. *Am J Gastroenterol* 2014; **109**: 855-863 [PMID: 24751581 DOI: 10.1038/ajg.2014.83]
 - 26 **Wallace MB**, Crook JE, Coe S, Ussui V, Staggs E, Almansa C, Patel MK, Bouras E, Cangemi J, Keaveny A, Picco M, Riegert-Johnson D. Accuracy of in vivo colorectal polyp discrimination by using dual-focus high-definition narrow-band imaging colonoscopy. *Gastrointest Endosc* 2014; **80**: 1072-1087 [PMID: 24973171 DOI: 10.1016/j.gie.2014.05.305]
 - 27 **Kaltenbach T**, Friedland S, Soetikno R. A randomised tandem colonoscopy trial of narrow band imaging versus white light examination to compare neoplasia miss rates. *Gut* 2008; **57**: 1406-1412 [PMID: 18523025 DOI: 10.1136/gut.2007.137984]
 - 28 **Inoue T**, Murano M, Murano N, Kuramoto T, Kawakami K, Abe Y, Morita E, Toshina K, Hoshiro H, Egashira Y, Umegaki E, Higuchi K. Comparative study of conventional colonoscopy and pan-colonic narrow-band imaging system in the detection of neoplastic colonic polyps: a randomized, controlled trial. *J Gastroenterol* 2008; **43**: 45-50 [PMID: 18297435 DOI: 10.1007/s00535-007-2125-x]
 - 29 **Paggi S**, Radaelli F, Amato A, Meucci G, Mandelli G, Imperiali G, Spinzi G, Terreni N, Lenoci N, Terruzzi V. The impact of narrow band imaging in screening colonoscopy: a randomized controlled trial. *Clin Gastroenterol Hepatol* 2009; **7**: 1049-1054 [PMID: 19577008 DOI: 10.1016/j.cgh.2009.06.028]
 - 30 **Sabbagh LC**, Reveiz L, Aponte D, de Aguiar S. Narrow-band imaging does not improve detection of colorectal polyps when compared to conventional colonoscopy: a randomized controlled trial and meta-analysis of published studies. *BMC Gastroenterol* 2011; **11**: 100 [PMID: 21943365 DOI: 10.1186/1471-230X-11-100]
 - 31 **Chung SJ**, Kim D, Song JH, Kang HY, Chung GE, Choi J, Kim YS, Park MJ, Kim JS. Comparison of detection and miss rates of narrow band imaging, flexible spectral imaging chromoendoscopy and white light at screening colonoscopy: a randomised controlled back-to-back study. *Gut* 2014; **63**: 785-791 [PMID: 23853211 DOI: 10.1136/gutjnl-2013-304578]
 - 32 **Su MY**, Hsu CM, Ho YP, Chen PC, Lin CJ, Chiu CT. Comparative study of conventional colonoscopy, chromoendoscopy, and narrow-band imaging systems in differential diagnosis of neoplastic and nonneoplastic colonic polyps. *Am J Gastroenterol* 2006; **101**: 2711-2716 [PMID: 17227517 DOI: 10.1111/j.1572-0241.2006.00932.x]
 - 33 **Chiu HM**, Chang CY, Chen CC, Lee YC, Wu MS, Lin JT, Shun CT, Wang HP. A prospective comparative study of narrow-band imaging, chromoendoscopy, and conventional colonoscopy in the diagnosis of colorectal neoplasia. *Gut* 2007; **56**: 373-379 [PMID: 17005766 DOI: 10.1136/gut.2006.099614]
 - 34 **East JE**, Suzuki N, Saunders BP. Comparison of magnified pit pattern interpretation with narrow band imaging versus chromoendoscopy for diminutive colonic polyps: a pilot study. *Gastrointest Endosc* 2007; **66**: 310-316 [PMID: 17643705 DOI: 10.1016/j.gie.2007.02.026]
 - 35 **Rastogi A**, Bansal A, Wani S, Callahan P, McGregor DH, Cherian R, Sharma P. Narrow-band imaging colonoscopy—a pilot feasibility study for the detection of polyps and correlation of surface patterns with polyp histologic diagnosis. *Gastrointest Endosc* 2008; **67**: 280-286 [PMID: 18155210 DOI: 10.1016/j.gie.2007.07.036]
 - 36 **Tischendorf JJ**, Wasmuth HE, Koch A, Hecker H, Trautwein C, Winograd R. Value of magnifying chromoendoscopy and narrow band imaging (NBI) in classifying colorectal polyps: a prospective controlled study. *Endoscopy* 2007; **39**: 1092-1096 [PMID: 18072061 DOI: 10.1055/s-2007-966781]
 - 37 **Simmons DT**, Harewood GC, Baron TH, Petersen BT, Wang KK, Boyd-Enders F, Ott BJ. Impact of endoscopist withdrawal speed on polyp yield: implications for optimal colonoscopy withdrawal time. *Aliment Pharmacol Ther* 2006; **24**: 965-971 [PMID: 16948808 DOI: 10.1111/j.1365-2036.2006.03080.x]
 - 38 **Abdeljawad K**, Vemulapalli KC, Kahi CJ, Cummings OW, Snover DC, Rex DK. Sessile serrated polyp prevalence determined by a colonoscopist with a high lesion detection rate and an experienced pathologist. *Gastrointest Endosc* 2015; **81**: 517-524 [PMID: 24998465 DOI: 10.1016/j.gie.2014.04.064]
 - 39 **Jin XF**, Chai TH, Shi JW, Yang XC, Sun QY. Meta-analysis for evaluating the accuracy of endoscopy with narrow band imaging in detecting colorectal adenomas. *J Gastroenterol Hepatol* 2012; **27**: 882-887 [PMID: 22098192 DOI: 10.1111/j.1440-1746.2011.06987.x]
 - 40 **Rex DK**, Bond JH, Winawer S, Levin TR, Burt RW, Johnson DA, Kirk LM, Litlin S, Lieberman DA, Waye JD, Church J, Marshall JB, Riddell RH. Quality in the technical performance of colonoscopy and the continuous quality improvement process for colonoscopy: recommendations of the U.S. Multi-Society Task Force on Colorectal Cancer. *Am J Gastroenterol* 2002; **97**: 1296-1308 [PMID: 12094842 DOI: 10.1111/j.1572-0241.2002.05812.x]

P- Reviewer: Koksas AS, Lee YT S- Editor: Gong ZM

L- Editor: A E- Editor: Wu HL





Published by **Baishideng Publishing Group Inc**
7901 Stoneridge Drive, Suite 501, Pleasanton, CA 94588, USA
Telephone: +1-925-223-8242
Fax: +1-925-223-8243
E-mail: bpgoffice@wjgnet.com
Help Desk: <http://www.f6publishing.com/helpdesk>
<http://www.wjgnet.com>

