


# World Journal of *Gastrointestinal Endoscopy*

*World J Gastrointest Endosc* 2017 August 16; 9(8): 346-427



### REVIEW

- 346 Terahertz endoscopic imaging for colorectal cancer detection: Current status and future perspectives  
*Doradla P, Joseph C, Giles RH*

### MINIREVIEWS

- 359 Use and barriers to chromoendoscopy for dysplasia surveillance in inflammatory bowel disease  
*Shukla R, Salem M, Hou JK*
- 368 Evolution of stereoscopic imaging in surgery and recent advances  
*Schwab K, Smith R, Brown V, Whyte M, Jourdan I*
- 378 Endoscopic ultrasonography - emerging applications in hepatology  
*Magalhães J, Monteiro S, Xavier S, Leite S, de Castro FD, Cotter J*

### ORIGINAL ARTICLE

#### Retrospective Cohort Study

- 389 Clinical impact of confocal laser endomicroscopy in the management of gastrointestinal lesions with an uncertain diagnosis  
*Robles-Medrand C, Vargas M, Ospina J, Puga-Tejada M, Valero M, Soria M, Bravo G, Robles-Jara C, Lukashok HP*
- 396 Impact of laparoscopic liver resection on bleeding complications in patients receiving antithrombotics  
*Fujikawa T, Kawamoto H, Kawamura Y, Emoto N, Sakamoto Y, Tanaka A*

#### Retrospective Study

- 405 Correlation of abnormal histology with endoscopic findings among mycophenolate mofetil treated patients  
*Izower MA, Rahman M, Molmenti EP, Bhaskaran MC, Amin VG, Khan S, Sultan K*
- 411 Usefulness of the Hook knife in flexible endoscopic myotomy for Zenker's diverticulum  
*Rouquette O, Abergel A, Mulliez A, Poincloux L*

### CASE REPORT

- 417 Russell body gastritis with Dutcher bodies evaluated using magnification endoscopy  
*Yorita K, Iwasaki T, Uchita K, Kuroda N, Kojima K, Iwamura S, Tsutsumi Y, Ohno A, Kataoka H*
- 425 Simultaneous Courvoisier's and double duct signs  
*Agrawal S, Vohra S*

## Contents

*World Journal of Gastrointestinal Endoscopy*  
Volume 9 Number 8 August 16, 2017

### ABOUT COVER

Editorial Board Member of *World Journal of Gastrointestinal Endoscopy*, Jorg G Albert, MD, PhD, Associate Professor, Department of Internal Medicine I, Johann Wolfgang Goethe-University Hospital, D-60590 Frankfurt, Germany

### AIM AND SCOPE

*World Journal of Gastrointestinal Endoscopy* (*World J Gastrointest Endosc*, *WJGE*, online ISSN 1948-5190, DOI: 10.4253) is a peer-reviewed open access (OA) academic journal that aims to guide clinical practice and improve diagnostic and therapeutic skills of clinicians.

*WJGE* covers topics concerning gastroscopy, intestinal endoscopy, colonoscopy, capsule endoscopy, laparoscopy, interventional diagnosis and therapy, as well as advances in technology. Emphasis is placed on the clinical practice of treating gastrointestinal diseases with or under endoscopy.

We encourage authors to submit their manuscripts to *WJGE*. We will give priority to manuscripts that are supported by major national and international foundations and those that are of great clinical significance.

### INDEXING/ABSTRACTING

*World Journal of Gastrointestinal Endoscopy* is now indexed in Emerging Sources Citation Index (Web of Science), PubMed, and PubMed Central.

### FLYLEAF

#### I-III Editorial Board

### EDITORS FOR THIS ISSUE

Responsible Assistant Editor: *Xiang Li*  
Responsible Electronic Editor: *Ya-Jing Lu*  
Proofing Editor-in-Chief: *Lian-Sheng Ma*

Responsible Science Editor: *Fang-Fang Ji*  
Proofing Editorial Office Director: *Jin-Lai Wang*

NAME OF JOURNAL  
*World Journal of Gastrointestinal Endoscopy*

ISSN  
ISSN 1948-5190 (online)

LAUNCH DATE  
October 15, 2009

FREQUENCY  
Monthly

EDITORS-IN-CHIEF  
**Atsushi Imagawa, PhD, Director, Doctor**, Department of Gastroenterology, Mitoyo General Hospital, Kan-onji, Kagawa 769-1695, Japan

**Juan Manuel Herrerias Gutierrez, PhD, Academic Fellow, Chief Doctor, Professor**, Unidad de Gestión Clínica de Aparato Digestivo, Hospital Universitario Virgen Macarena, Sevilla 41009, Spain

EDITORIAL BOARD MEMBERS  
All editorial board members resources online at <http://www.wjnet.com>

[www.wjnet.com/1948-5190/editorialboard.htm](http://www.wjnet.com/1948-5190/editorialboard.htm)

EDITORIAL OFFICE  
Xiu-Xia Song, Director  
*World Journal of Gastrointestinal Endoscopy*  
Baishideng Publishing Group Inc  
7901 Stoneridge Drive, Suite 501, Pleasanton, CA 94588, USA  
Telephone: +1-925-2238242  
Fax: +1-925-2238243  
E-mail: [editorialoffice@wjnet.com](mailto:editorialoffice@wjnet.com)  
Help Desk: <http://www.fjgpublishing.com/helpdesk>  
<http://www.wjnet.com>

PUBLISHER  
Baishideng Publishing Group Inc  
7901 Stoneridge Drive, Suite 501,  
Pleasanton, CA 94588, USA  
Telephone: +1-925-2238242  
Fax: +1-925-2238243  
E-mail: [bpgoffice@wjnet.com](mailto:bpgoffice@wjnet.com)  
Help Desk: <http://www.fjgpublishing.com/helpdesk>  
<http://www.wjnet.com>

PUBLICATION DATE  
August 16, 2017

COPYRIGHT  
© 2017 Baishideng Publishing Group Inc. Articles published by this Open-Access journal are distributed under the terms of the Creative Commons Attribution Non-commercial License, which permits use, distribution, and reproduction in any medium, provided the original work is properly cited, the use is non commercial and is otherwise in compliance with the license.

SPECIAL STATEMENT  
All articles published in journals owned by the Baishideng Publishing Group (BPG) represent the views and opinions of their authors, and not the views, opinions or policies of the BPG, except where otherwise explicitly indicated.

INSTRUCTIONS TO AUTHORS  
<http://www.wjnet.com/bpg/gerinfo/204>

ONLINE SUBMISSION  
<http://www.fjgpublishing.com>

## Retrospective Study

# Correlation of abnormal histology with endoscopic findings among mycophenolate mofetil treated patients

Mitchell A Izower, Merajur Rahman, Ernesto P Molmenti, Madhu C Bhaskaran, Viren G Amin, Sundas Khan, Keith Sultan

Mitchell A Izower, Viren G Amin, Department of Medicine, North Shore University Hospital, Manhasset, NY 11030, United States

Merajur Rahman, Keith Sultan, Division of Gastroenterology, Department of Medicine, North Shore University Hospital, Manhasset, NY 11030, United States

Ernesto P Molmenti, Department of Surgery, North Shore University Hospital, Manhasset, NY 11030, United States

Madhu C Bhaskaran, Division of Nephrology, Department of Medicine, North Shore University Hospital, Manhasset, NY 11030, United States

Sundas Khan, the Feinstein Institute for Biomedical Research, Manhasset, NY 11030, United States

**Author contributions:** Izower MA, Rahman M, Molmenti EP, Bhaskaran MC, Amin VG and Sultan K involvement in conception or design, contributions to critical aspects of the research, drafting and revising the article; Khan S data analysis of the research.

**Institutional review board statement:** The study was reviewed and approved by the North Shore-Long Island Jewish Institutional Review Board.

**Informed consent statement:** Waiver of informed consent was requested and granted by the North Shore-Long Island Jewish Institutional Review board because information recorded by the investigators in such a manner that the subjects cannot be identified, directly or through identifiers linked to the subjects.

**Conflict-of-interest statement:** All authors have no financial relationships to disclose.

**Data sharing statement:** No additional data are available.

**Open-Access:** This article is an open-access article which was selected by an in-house editor and fully peer-reviewed by external reviewers. It is distributed in accordance with the Creative Commons Attribution Non Commercial (CC BY-NC 4.0) license, which permits others to distribute, remix, adapt, build upon this

work non-commercially, and license their derivative works on different terms, provided the original work is properly cited and the use is non-commercial. See: <http://creativecommons.org/licenses/by-nc/4.0/>

**Manuscript source:** Invited manuscript

**Correspondence to:** Merajur Rahman, MD, Division of Gastroenterology, Department of Medicine, North Shore University Hospital, 300 Community Drive, Manhasset, NY 11030, United States. [rmerajur@nshs.edu](mailto:rmerajur@nshs.edu)  
**Telephone:** +1-516-3873990  
**Fax:** +1-516-5623555

**Received:** January 22, 2017

**Peer-review started:** January 22, 2017

**First decision:** March 28, 2017

**Revised:** April 23, 2017

**Accepted:** May 22, 2017

**Article in press:** May 24, 2017

**Published online:** August 16, 2017

## Abstract

### AIM

To describe all abnormal histological findings and their associated endoscopic presentation in patients using mycophenolate mofetil (MMF).

### METHODS

A retrospective review of all individuals prescribed MMF within 6 mo of a colonoscopy or flexible sigmoidoscopy between 07/2009 and 09/2015 was performed within Northwell Health system. Records were analyzed for age, gender, procedure indication, MMF indication, and both gross and microscopic findings. Only reports with abnormal histology were included.

### RESULTS

One hundred and eighty-four procedures from 170



patients were found, of which 39 met inclusion criteria. Fifty-one point three percent were female. MMF was used for solid organ transplant in 71.8%. Diarrhea was the indication for 71.8% of colonoscopies. Fifty-nine percent of reports revealed gross and microscopic abnormalities while 41.0% had only microscopic findings. Only 11 patients' reports (28.2%) indicated a specific histopathology of MMF colitis. Among the entire group, only 23.1% of abnormal histology was isolated proximal to the splenic flexure.

## CONCLUSION

Our results demonstrate a high rate of left sided disease and microscopic findings without gross mucosal abnormalities among patients using MMF. Also, a broader definition of MMF-colonopathy may be appropriate, with a majority of our abnormal histology falling outside of the more narrowly defined MMF-colitis category. Given the high frequency of isolated microscopic abnormalities and distal disease, sigmoidoscopy with random biopsies may be an appropriate, less invasive initial endoscopic examination in selected MMF patients.

**Key words:** Mycophenolate mofetil; Colitis; Colonoscopy; Diarrhea

© **The Author(s) 2017.** Published by Baishideng Publishing Group Inc. All rights reserved.

**Core tip:** Gastrointestinal complaints are common among patients using mycophenolate mofetil (MMF). Little information exists to guide an effective endoscopic workup in this population. A retrospective review of all patients prescribed mycophenolate within 6 mo of an endoscopic procedure was performed. Our results demonstrate a high rate of left sided disease and microscopic findings without gross mucosal abnormalities among patients using mycophenolate. A broader definition of MMF-colonopathy may be appropriate, with a majority of our abnormal histology falling outside of the more narrowly defined MMF-colitis category. Our findings suggest sigmoidoscopy with random biopsies may be an appropriate initial evaluation.

Izower MA, Rahman M, Molmenti EP, Bhaskaran MC, Amin VG, Khan S, Sultan K. Correlation of abnormal histology with endoscopic findings among mycophenolate mofetil treated patients. *World J Gastrointest Endosc* 2017; 9(8): 405-410 Available from: URL: <http://www.wjgnet.com/1948-5190/full/v9/i8/405.htm> DOI: <http://dx.doi.org/10.4253/wjge.v9.i8.405>

## INTRODUCTION

Mycophenolate mofetil (MMF) is an immunosuppressive agent that is used mainly for the prevention of organ transplant rejection, but is increasingly used for autoimmune and hematologic disorders<sup>[1,2]</sup>. Mycophenolic acid (MPA) is the active metabolite of MMF. MPA prevents the proliferation of lymphocytes by inhibiting

inosine monophosphate dehydrogenase, an enzyme in the *de novo* pathway of purine synthesis<sup>[3]</sup>. Other mechanisms of MPA immunosuppression have been reported, including apoptosis of activated T-lymphocytes, decreased recruitment of lymphocytes to sites of inflammation, and decreased nitric oxide-mediated tissue damage<sup>[4]</sup>. Enterocytes are also dependent on the *de novo* pathway of purine synthesis and become potential targets for MPA<sup>[1,4]</sup>. This can lead to gastrointestinal toxicity, which typically manifests as diarrhea, and can occur in up to 36% of patients<sup>[1]</sup>.

For many patients using MMF who develop diarrhea, the severity of complaints may prompt a formal workup. In cases with negative stool studies for infectious causes, endoscopic examination either with flexible sigmoidoscopy or colonoscopy may be performed<sup>[5]</sup>. In those individuals with abnormal histology, it is then critical to differentiate MMF-related colitis from colitis of other etiologies such as new onset inflammatory bowel disease (IBD) or atypical infection. Accurate diagnosis is critical to proper use of MMF, as dose modification and/or discontinuation of MMF risks organ rejection or reactivation of autoimmune disease<sup>[2,6]</sup>.

Prototypical histopathology of MMF colitis has been described as "prominent crypt cell apoptosis and reactive/reparative changes including enterocyte cytologic atypia, increased neuroendocrine cells, and glandular architectural distortion"<sup>[7]</sup>. While a pathologist informed of MMF usage may identify a typical pattern of MMF related injury<sup>[1,2,4]</sup>, and specify a finding as "MMF colitis", a broader spectrum of abnormal histology associated with MMF appears to exist<sup>[2]</sup>. In addition, the endoscopic findings related to MMF colitis, and other MMF associated abnormal histology, are not well described - including the gross nature of lesions and typical distribution within the colon. Most prior studies have been limited to case reports and retrospective studies and have focused on abnormal histopathology associated with MMF usage without addressing the endoscopic appearance or patterns of distribution within the GI tract<sup>[4]</sup>.

As with other disorders such as Crohn's disease and microscopic colitis, knowledge of anatomic disease distribution and associated presence or absence of gross mucosal abnormalities are critical to guide an effective work up. Our aim was to describe all abnormal histological findings and their associated endoscopic presentation in all patients undergoing colonoscopy while using MMF.

## MATERIALS AND METHODS

We conducted a retrospective review of all patients who were 18 years of age and older and had documented use of MMF within 6 mo of undergoing a colonoscopy or flexible sigmoidoscopy from July 2009 to September 2015. The study was conducted within the North Shore-LIJ Health System (now Northwell Health) after obtaining institutional review board approval. Only

**Table 1** Demographic of mycophenolate mofetil treated patients and procedures (170 patients, 184 procedures) (%)

Characteristic	
mean age	57.05
Female	89 (48.4)
Indication for procedure <sup>2</sup>	
Screening	72 (39.1)
Diarrhea	51 (27.7)
Bleeding	24 (13.0)
Anemia	20 (10.9)
Abdominal pain	14 (7.7)
Constipation	3 (1.6)
Weight loss	3 (1.6)
Abnormal imaging	3 (1.6)
Bloating	1 (0.52)
Other (history of IBD, amyloid, stricture)	9 (4.9)
Indication for MMF	
Organ transplant (kidney, liver, lung)	116
Autoimmune	35
Blood disorder	7
Unknown indication	26
Abnormal mucosa (gross)	40
With normal biopsies	10
With abnormal biopsies	25 (2 duplicates)
Without biopsies <sup>1</sup>	5
Normal mucosa (gross)	144
With normal biopsies	44 (normal biopsy or polypectomy, 1 for mass)
With abnormal biopsies	17 (1 duplicate)
Without biopsies <sup>1</sup>	83

<sup>1</sup>Without biopsies done or with reports unavailable; <sup>2</sup>Some procedures with multiple indications documented. MMF: Mycophenolate mofetil; IBD: Inflammatory bowel disease.

sigmoidoscopy or colonoscopy reports with abnormal histology described on the official pathology report were included in the review. Sigmoidoscopy or colonoscopy reports with normal pathology or missing pathology report were excluded. In patients with multiple eligible colonoscopies or sigmoidoscopies, the procedure report nearest to the date of MMF prescribing was the one included in the analysis. If a patient had both an eligible colonoscopy and flexible sigmoidoscopy, the colonoscopy report was used.

Demographic information, indication for colonoscopy, indication for MMF, gross and histological findings were recorded. All pathology samples were evaluated by experienced gastrointestinal pathologists. Only pathology reports specifically citing MMF use as the likely etiology were classified as "MMF-colitis". All remaining abnormal findings were broadly classified as "other" abnormal findings, and sub-categorized according to their description in the pathology report. Abnormal histology findings proximal to the splenic flexure were defined as right colonic; findings distal to the splenic flexure were defined as left colonic. Abnormal findings occurring both proximal and distal to the splenic flexure were defined as pancolonic. Location and description of abnormal gross findings on colonoscopy/sigmoidoscopy examination also corresponded to the official procedure report. Our goals

were to describe abnormal histological findings, their location within the colon, and the presence or absence of associated gross endoscopic findings.

## RESULTS

A total of 184 colonoscopies and sigmoidoscopies from 170 patients were reviewed during the study period. Overall, screening was the most common indication for a procedure, with organ transplant as the most common indication for MMF use (Table 1). Of these, 34 colonoscopies and 5 sigmoidoscopies from 39 individual patients met inclusion criteria. Fifty-one point three percent were female. Average age at time of procedure was 51.44 years old. For this group with abnormal histology, diarrhea was the most common indication, accounting for 71.8% of the combined sigmoidoscopies and colonoscopies. Two patients had procedures for history of inflammatory bowel disease. Indications for MMF therapy were: Solid organ transplant (71.8%), hematologic disorders (17.9%) and autoimmune disease (10.3%). Of the 28 solid organ transplant patients, 27 were from renal transplants and 1 was from a lung transplant. Demographics of colitis among MMF treated patients (Table 2).

Of the 39 patient reports meeting inclusion criteria, only 11 patient pathology reports (28.2%) indicated a specific histopathology of MMF colitis. Notably, only 9 of 39 (23.1%) specimen request forms sent to pathology provided history of MMF use. Non-specific colitis was identified in 30.8% of the reports. Four reports indicated graft vs host disease (GVHD), and all were from patients who were on MMF for leukemia or lymphoma and underwent stem cell transplant. The remaining twelve cases are included in Table 3.

Overall 23 (59.0%) of abnormal histology corresponded to a reported gross endoscopic abnormality, while 16 (41.0%) demonstrated abnormal histology without a gross abnormality. Of the 28 procedures performed for an indication of diarrhea, 13 (46.4%) of abnormal histology corresponded to a gross endoscopic abnormality, while 15 (53.6%) demonstrated abnormal histology without a gross abnormality. Among the entire 39 cases reviewed only 23.1% of abnormal histology was isolated to the right colon. Among the subgroup of 11 MMF-colitis cases, only one (9.1%) was isolated to the right colon, Figure 1.

## DISCUSSION

In our study out of 184 procedures performed on 170 patients using MMF, only 39 colonoscopies/sigmoidoscopies had abnormal pathology. Of these, only 28.2% demonstrated a specific histopathology of MMF colitis. Endoscopic and histological evidence of colitis in patients who developed diarrhea while using MMF have been previously studied<sup>[4]</sup>. Those reports, which evaluated the histopathological findings of this MMF-colitis, have shown a variety of features including

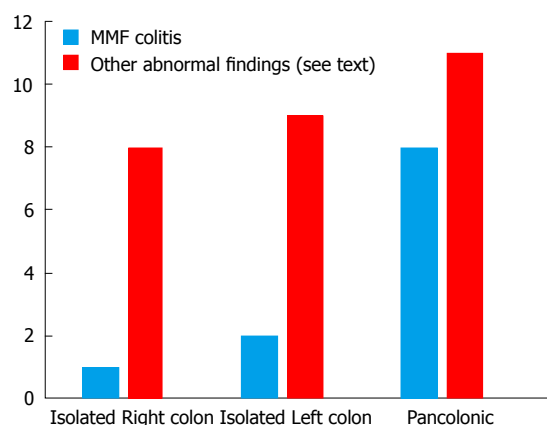
**Table 2** Demographic of colitis among mycophenolate mofetil treated patients *n* (%)

Characteristic	
<i>n</i>	39
mean age	51.44
Female	20 (51.3)
Indication for procedure	
Diarrhea	28 (71.8)
Bleeding	2 (5.1)
Anemia	1 (2.6)
Screening	4 (10.3)
Abnormal imaging	2 (5.1)
Other (history of IBD)	2 (5.1)
Indication for MMF	
Organ transplant	28 (71.8)
Autoimmune	4 (10.3)
Blood disorder	7 (17.9)

MMF: Mycophenolate mofetil; IBD: Inflammatory bowel disease.

prominent crypt cell apoptosis and reactive/reparative changes including enterocyte cytologic atypia, lamina propria inflammation, and crypt architectural disarray<sup>[8]</sup>. In our study, similar findings were described for MMF-colitis, with the most common feature being cell apoptosis. While the presence of apoptosis is regarded as more typical of a true MMF-related colitis<sup>[8]</sup>, there is no consensus regarding the spectrum of abnormal histology related to MMF use. Our findings of frequent nonspecific colitis and other histological abnormalities suggests that a broader definition of MMF-colonopathy may be required, with a majority of our abnormal histology falling outside of the more narrowly defined MMF-colitis category.

Prior case series and reports were able to categorize abnormal histological findings in patients on MMF into IBD-like, GVHD-like, ischemic-like, acute colitis, or non-specific colitis<sup>[2,9]</sup>. In our study, 30.8% of the reports indicated non-specific colitis. This high frequency of non-specific colitis was also found by de Andrade *et al*<sup>[9]</sup>. In addition to non-specific colitis, there were 4 reported cases of GVHD in our study, all in patients with hematologic disease and a history of bone marrow transplant. This suggests that the transplant itself is the cause of the abnormal findings rather than the MMF, although previous studies have described GVHD-like pathology in patients on MMF following solid organ transplant<sup>[1,2,4]</sup>. Additionally, it can be difficult to histologically differential between GVHD and MMF colitis. Star *et al*<sup>[10]</sup> have found that high eosinophilic count, absence of neuroendocrine cell clusters and apoptotic microabscess are more suggestive of MMF colitis over GVHD. Ischemic-like pathology can also be found in patients on MMF. Johal *et al*<sup>[8]</sup> described MMF-induced segmental colitis mimicking ischemic colitis. There was one case of ischemic-like pathology found in our study, however, given lack of multiple biopsies, it is unknown if this patient had segmental colitis. Regardless of the pathology, most of these patients underwent col-

**Figure 1** Distribution of histopathology in confirmed mycophenolate mofetil colitis and other abnormal findings.

onoscopy due to diarrhea.

Gastrointestinal toxicity, usually manifested as diarrhea, is the most common side effect of MMF<sup>[8]</sup>. The reported incidence of diarrhea is variable and can range from 13% to 64%<sup>[4]</sup>. Diarrhea was the most common indication for colonoscopy in our study population (71.8%). Even though the exact mechanism of MMF induced diarrhea is unknown, different etiologies have been proposed<sup>[4]</sup>. In addition to the impact on the quality of life, diarrhea can lead to non-compliance, weight loss, and physician-directed MMF dose reduction<sup>[1]</sup>.

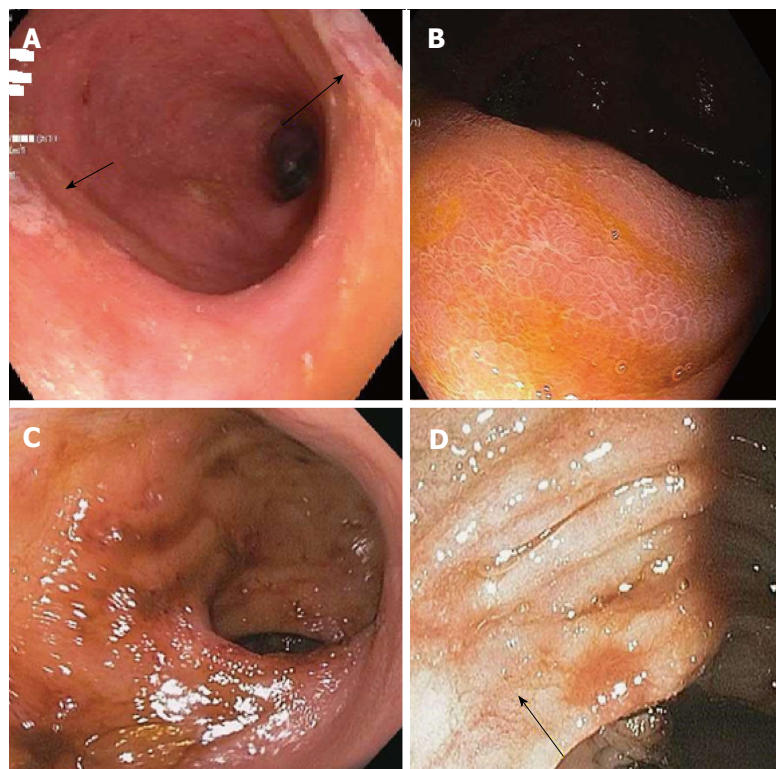
Data describing the presence of macroscopic abnormalities and distribution of findings associated with MMF-related colitis is limited. Calmet *et al*<sup>[4]</sup> found macroscopic findings ranging from erythema to erosions and ulcers. About half of the patients they studied had normal macroscopic findings, similar to our findings of abnormal histology without endoscopic mucosal changes in 41% patients, with others demonstrating erythema, friability, granularity, loss of vascularity, and ulcerations. These findings were found across MMF-related colitis including GVHD, AML, and MMF colitis as shown in Figure 2. Along with Calmet *et al*<sup>[4]</sup>, our results showing such a high rate of isolated microscopic abnormalities strongly support a diagnostic protocol including random biopsies of normal appearing mucosa in patients on MMF with colitis-like complaints.

Our patients also demonstrated a low frequency of abnormal histology (23.1%) limited to the right colon, proximal to the splenic flexures. This finding was even more pronounced for the subgroup of MMF-colitis, of which only one case was isolated proximal to the splenic flexure. This appears similar to the findings of Calmet *et al*<sup>[4]</sup>. In a smaller sample of 20 patients they found that 25% of MMF related colitis was found in the right colon, though "right colon" was not explicitly defined<sup>[4]</sup>. Our findings suggest that a viable strategy for evaluation in this patient population could be to initially perform by a sigmoidoscopy, moving on to full colonoscopy only if distal findings are negative. While sigmoidoscopy is

**Table 3** Abnormal histological findings by mycophenolate mofetil indication

	Solid organ transplant (n)	Autoimmune (n)	Blood disorder (n)	Total (n)
MMF colitis	10	1	0	11
Graft <i>vs</i> host disease	0	0	4	4
Nonspecific colitis	11	0	1	12
Other	3 (hyperplastic), 1 (lymphoid aggregate), 1 (kayexalate), 1 (ischemic), 1 (amyloid)	1 (IBD), 1 (lymphoid aggregate), 1 (hyperplastic)	1 (AML), 1 (reactive)	12

MMF: Mycophenolate mofetil; IBD: Inflammatory bowel disease.



**Figure 2** These findings were found across mycophenolate mofetil-related colitis. A: Mycophenolate mofetil (MMF) colitis: erythematous hyperemic mucosa (sigmoid colon); B: MMF colitis: coarse appearing colonic mucosa (ascending colon); C: AML: multiple small ulcers and erosion (rectum); D: GVHD: patchy areas of mucosa (transverse colon).

no longer commonly used for colon cancer screening purposes, it remains a valuable tool for the evaluation of other gastrointestinal conditions. Notably, it may be used for the diagnosis and monitoring of response to therapy in ulcerative colitis due to the near universal involvement of the rectum and left-colon typical of the disorder. Our findings suggest a similar role for sigmoidoscopy for the workup of lower gastrointestinal complaints in patients using MMF. Significant advantages to sigmoidoscopy compared to colonoscopy include avoidance of sedation and lower risk of perforation. Also, since so many of these patients have a history of renal transplantation, the avoidance of a full bowel preparation, required by colonoscopy but unnecessary for sigmoidoscopy, lowers the risk of renal compromise, which has been associated with certain colonoscopy preparations<sup>[11]</sup>.

In our current series we found a relatively small number of abnormal histology reported with a diagnosis specific for MMF colitis. Notably, a similarly small number of samples that were sent to pathology directly specified usage of MMF. This implies that

some pathologists, if they are not aware of MMF use, or are less familiar with MMF-related colitis, may not consider the diagnosis of MMF-related colitis, leading to decreased specificity of findings and lingering diagnostic uncertainty. It would likely be of value to pathologists to make them aware of MMF usage, so as to improve the rate at which MMF-related colitis is appreciated in pathology samples. Alternatively, as discussed, a more broadly defined MMF-colonopathy may need to be considered when evaluating and managing patients with any abnormal histology using MMF.

Our study had some limitations. The total number of patients we analyzed for abnormal histological findings, while large by comparison to other case series, was still small in absolute numbers due to the rareness of MMF use and occurrence of these findings. Also, though the electronic medical record (EMR) allowed us to track MMF prescribing, we could not confirm patient compliance. In addition, though we did analyze a significant amount of demographic information, there were limits to the EMR, such as our inability to consider patient race/ethnicity as part of our analysis.



In summary, ours is the largest study correlating all abnormal pathology associated with MMF use with both gross endoscopic findings and disease distribution. Our findings reinforce the importance of random biopsies of grossly normal appearing colonic mucosa towards making an accurate diagnosis. Importantly, our findings also support a first line diagnostic approach using a less invasive, lower risk sigmoidoscopy coupled with routine biopsy in selected MMF patients with appropriate complaints. Moving forward, valuable avenues of research would include outcomes analysis of patients diagnosed with MMF-related colonic abnormalities after intervention, whether that be *via* dose modification or discontinuation of MMF or other means of treatment. This would be valuable in further confirming the clinical significance of these findings, as well as the therapeutic benefit of accurately confirming such a diagnosis

## COMMENTS

### Background

Gastrointestinal complaints are common among patients using mycophenolate mofetil (MMF). Abnormal biopsy findings have been described in this population, but little information exists to guide an effective endoscopic workup of those on MMF such as the presence or absence of gross endoscopic findings and their anatomic distribution.

### Research frontiers

Abnormal biopsy findings have been described in patients treated with MMF. The current research focus is to evaluate the endoscopic findings and the proper endoscopic workup in patients with gastrointestinal complaints on MMF.

### Innovations and breakthroughs

Prior studies have only described the histology in a limited number of patient on MMF. Most of these studies were limited to renal transplant patients. The authors looked at all patients treated with MMF for a variety of illnesses. Also, there is very limited information describing gross mucosal findings and anatomic distribution of abnormal findings within the MMF population. The authors results demonstrate a high rate of left sided disease and microscopic findings without gross mucosal abnormalities among patients using MMF.

### Applications

A broader definition of MMF-colonopathy may be appropriate, with a majority of the authors' abnormal histology falling outside of the more narrowly defined MMF-colitis category. The authors findings support sigmoidoscopy with random biopsies may be an appropriate initial endoscopic evaluation in patients with bowel complaints using MMF.

### Terminology

MMF is an immunosuppressive agent that is used mainly for the prevention of organ transplant rejection. This can lead to gastrointestinal toxicity, which typically manifests as diarrhea. Right colonic findings were defined as abnormal

histology findings proximal to the splenic flexure. Left colonic findings were defined as abnormal histology findings distal to the splenic flexure.

### Peer-review

This paper study the correlation of abnormal histology with endoscopic findings among Mycophenolate Mofetil treated patients, the sample is large.

## REFERENCES

- 1 Lee S, de Boer WB, Subramaniam K, Kumarasinghe MP. Pointers and pitfalls of mycophenolate-associated colitis. *J Clin Pathol* 2013; **66**: 8-11 [PMID: 23038687 DOI: 10.1136/jclinpath-2012-200888]
- 2 Selbst MK, Ahrens WA, Robert ME, Friedman A, Proctor DD, Jain D. Spectrum of histologic changes in colonic biopsies in patients treated with mycophenolate mofetil. *Mod Pathol* 2009; **22**: 737-743 [PMID: 19329937 DOI: 10.1038/modpathol.2009.44]
- 3 Ransom JT. Mechanism of action of mycophenolate mofetil. *Ther Drug Monit* 1995; **17**: 681-684 [PMID: 8588241]
- 4 Calmet FH, Yarur AJ, Pukazhendhi G, Ahmad J, Bhamidimarri KR. Endoscopic and histological features of mycophenolate mofetil colitis in patients after solid organ transplantation. *Ann Gastroenterol* 2015; **28**: 366-373 [PMID: 26126799]
- 5 Behrend M. Adverse gastrointestinal effects of mycophenolate mofetil: aetiology, incidence and management. *Drug Saf* 2001; **24**: 645-663 [PMID: 11522119]
- 6 Al-Absi AI, Cooke CR, Wall BM, Sylvestre P, Ismail MK, Mya M. Patterns of injury in mycophenolate mofetil-related colitis. *Transplant Proc* 2010; **42**: 3591-3593 [PMID: 21094821 DOI: 10.1016/j.transproceed.2010.08.066]
- 7 Papadimitriou JC, Cangro CB, Lustberg A, Khaled A, Nogueira J, Wiland A, Ramos E, Klassen DK, Drachenberg CB. Histologic features of mycophenolate mofetil-related colitis: a graft-versus-host disease-like pattern. *Int J Surg Pathol* 2003; **11**: 295-302 [PMID: 14615824]
- 8 Johal K, Ratnapli SK, Lam-Himlin DM, Gurudu SR. Mycophenolate mofetil-induced segmental colitis mimicking ischemic colitis. *Case Rep Gastroenterol* 2014; **8**: 95-100 [PMID: 24803893 DOI: 10.1159/000360847]
- 9 de Andrade LG, Rodrigues MA, Romeiro FG, Garcia PD, Contti MM, de Carvalho MF. Clinicopathologic features and outcome of mycophenolate-induced colitis in renal transplant recipients. *Clin Transplant* 2014; **28**: 1244-1248 [PMID: 25142167 DOI: 10.1111/ctr.12452]
- 10 Star KV, Ho VT, Wang HH, Odze RD. Histologic features in colon biopsies can discriminate mycophenolate from GVHD-induced colitis. *Am J Surg Pathol* 2013; **37**: 1319-1328 [PMID: 24076772 DOI: 10.1097/PAS.0b013e31829ab1ef]
- 11 Wexner SD, Beck DE, Baron TH, Fanelli RD, Hyman N, Shen B, Wasco KE; American Society of Colon and Rectal Surgeons; American Society for Gastrointestinal Endoscopy; Society of American Gastrointestinal and Endoscopic Surgeons. A consensus document on bowel preparation before colonoscopy: prepared by a task force from the American Society of Colon and Rectal Surgeons (ASCRS), the American Society for Gastrointestinal Endoscopy (ASGE), and the Society of American Gastrointestinal and Endoscopic Surgeons (SAGES). *Gastrointest Endosc* 2006; **63**: 894-909 [PMID: 16733101 DOI: 10.1016/j.gie.2006.03.918]

P- Reviewer: Cui J S- Editor: Qi Y L- Editor: A  
E- Editor: Lu YJ





Published by **Baishideng Publishing Group Inc**  
7901 Stoneridge Drive, Suite 501, Pleasanton, CA 94588, USA  
Telephone: +1-925-223-8242  
Fax: +1-925-223-8243  
E-mail: [bpgoffice@wjgnet.com](mailto:bpgoffice@wjgnet.com)  
Help Desk: <http://www.f6publishing.com/helpdesk>  
<http://www.wjgnet.com>

