


World Journal of *Clinical Oncology*

World J Clin Oncol 2017 June 10; 8(3): 178-304





REVIEW

- 178 Histone deacetylases, microRNA and leptin crosstalk in pancreatic cancer
Tchio Mantho CI, Harbuzariu A, Gonzalez-Perez RR
- 190 Multidisciplinary approach of colorectal cancer liver metastases
Fiorentini G, Sarti D, Aliberti C, Carandina R, Mambrini A, Guadagni S
- 203 Evolving role of Sorafenib in the management of hepatocellular carcinoma
Ziogas IA, Tsoulfas G
- 214 Magnetic resonance imaging for diagnosis and neoadjuvant treatment evaluation in locally advanced rectal cancer: A pictorial review
Engin G, Sharifov R

MINIREVIEWS

- 230 Immunotherapy in pancreatic cancer: Unleash its potential through novel combinations
Guo S, Contratto M, Miller G, Leichman L, Wu J
- 241 Current state and controversies in fertility preservation in women with breast cancer
Taylan E, Oktay KH
- 249 Biological mesh reconstruction of the pelvic floor following abdominoperineal excision for cancer: A review
Schiltz B, Buchs NC, Penna M, Scarpa CR, Liot E, Morel P, Ris F
- 255 Potential prognostic biomarkers in pancreatic juice of resectable pancreatic ductal adenocarcinoma
Agrawal S

ORIGINAL ARTICLE

Case Control Study

- 261 Levels of neutrophil gelatinase-associated lipocalin in patients with head and neck squamous cell carcinoma in Indian population from Haryana state
Verma M, Dahiya K, Soni A, Dhankhar R, Ghalaat VS, Bansal A, Kaushal V

SYSTEMATIC REVIEWS

- 266 Recurrence-free survival as a putative surrogate for overall survival in phase III trials of curative-intent treatment of colorectal liver metastases: Systematic review
Araujo RLC, Herman P, Riechelmann RP

META-ANALYSIS

- 273** Robot-assisted laparoscopic *vs* open gastrectomy for gastric cancer: Systematic review and meta-analysis
Caruso S, Patriti A, Roviello F, De Franco L, Franceschini F, Ceccarelli G, Coratti A

CASE REPORT

- 285** Bilateral diffuse grade 5 radiation pneumonitis after intensity modulated radiation therapy for localized lung cancer
Osborn VW, Leaf A, Lee A, Garay E, Safdieh J, Schwartz D, Schreiber D
- 289** Prostatic adenocarcinoma, oncocytic variant: Case report and literature review
Klaimont MM, Zafar N
- 293** Pancreatic neuroendocrine tumor Grade 1 patients followed up without surgery: Case series
Sugimoto M, Takagi T, Suzuki R, Konno N, Asama H, Watanabe K, Nakamura J, Kikuchi H, Waragai Y, Takasumi M, Kawana S, Hashimoto Y, Hikichi T, Ohira H
- 300** Target migration from re-inflation of adjacent atelectasis during lung stereotactic body radiotherapy
Mao B, Verma V, Zheng D, Zhu X, Bennion NR, Bhurud AR, Poole MA, Zhen W

Contents

World Journal of Clinical Oncology
Volume 8 Number 3 June 10, 2017

ABOUT COVER

Editorial Board Member of *World Journal of Clinical Oncology*, Bin Wang, PhD, Assistant Professor, Department of Biomedical Engineering, Widener University, Chester, PA 19013, United States

AIM AND SCOPE

World Journal of Clinical Oncology (*World J Clin Oncol*, *WJCO*, online ISSN 2218-4333, DOI: 10.5306) is a peer-reviewed open access academic journal that aims to guide clinical practice and improve diagnostic and therapeutic skills of clinicians.

WJCO covers a variety of clinical medical topics, including etiology, epidemiology, evidence-based medicine, informatics, diagnostic imaging, endoscopy, tumor recurrence and metastasis, tumor stem cells, radiotherapy, chemotherapy, interventional radiology, palliative therapy, clinical chemotherapy, biological therapy, minimally invasive therapy, physiotherapy, psycho-oncology, comprehensive therapy, and oncology-related nursing. Priority publication will be given to articles concerning diagnosis and treatment of oncology diseases. The following aspects are covered: Clinical diagnosis, laboratory diagnosis, differential diagnosis, imaging tests, pathological diagnosis, molecular biological diagnosis, immunological diagnosis, genetic diagnosis, functional diagnostics, and physical diagnosis; and comprehensive therapy, drug therapy, surgical therapy, interventional treatment, minimally invasive therapy, and robot-assisted therapy.

We encourage authors to submit their manuscripts to *WJCO*. We will give priority to manuscripts that are supported by major national and international foundations and those that are of great clinical significance.

INDEXING/ABSTRACTING

World Journal of Clinical Oncology is now indexed in PubMed, PubMed Central and Scopus.

FLYLEAF

I-III Editorial Board

EDITORS FOR THIS ISSUE

Responsible Assistant Editor: *Xiang Li*
Responsible Electronic Editor: *Ya-Jing Lu*
Proofing Editor-in-Chief: *Lian-Sheng Ma*

Responsible Science Editor: *Fang-Fang Ji*
Proofing Editorial Office Director: *Ze-Mao Gong*

NAME OF JOURNAL
World Journal of Clinical Oncology

ISSN
ISSN 2218-4333 (online)

LAUNCH DATE
November 10, 2010

FREQUENCY
Bimonthly

EDITOR-IN-CHIEF
Godefridus J Peters, PhD, Professor, Department of Medical Oncology, Cancer Center Amsterdam, VU University Medical Center, Amsterdam 1081 HV, Netherlands

EDITORIAL BOARD MEMBERS
All editorial board members resources online at <http://www.wjgnet.com/2218-4333/editorialboard.htm>

EDITORIAL OFFICE
Xiu-Xia Song, Director

World Journal of Clinical Oncology
Baishideng Publishing Group Inc
7901 Stoneridge Drive, Suite 501, Pleasanton, CA 94588, USA
Telephone: +1-925-2238242
Fax: +1-925-2238243
E-mail: editorialoffice@wjgnet.com
Help Desk: <http://www.f6publishing.com/helpdesk>
<http://www.wjgnet.com>

PUBLISHER
Baishideng Publishing Group Inc
7901 Stoneridge Drive,
Suite 501, Pleasanton, CA 94588, USA
Telephone: +1-925-2238242
Fax: +1-925-2238243
E-mail: bpgoffice@wjgnet.com
Help Desk: <http://www.f6publishing.com/helpdesk>
<http://www.wjgnet.com>

PUBLICATION DATE
June 10, 2017

COPYRIGHT

© 2017 Baishideng Publishing Group Inc. Articles published by this Open-Access journal are distributed under the terms of the Creative Commons Attribution Non-commercial License, which permits use, distribution, and reproduction in any medium, provided the original work is properly cited, the use is non commercial and is otherwise in compliance with the license.

SPECIAL STATEMENT

All articles published in journals owned by the Baishideng Publishing Group (BPG) represent the views and opinions of their authors, and not the views, opinions or policies of the BPG, except where otherwise explicitly indicated.

INSTRUCTIONS TO AUTHORS

<http://www.wjgnet.com/bpg/gerinfo/204>

ONLINE SUBMISSION

<http://www.f6publishing.com>

Prostatic adenocarcinoma oncocytic variant: Case report and literature review

Matthew M Klairmont, Nadeem Zafar

Matthew M Klairmont, Nadeem Zafar, Department of Pathology, University of Tennessee Health Science Center, Memphis, TN 38163, United States

Author contributions: All authors contributed to the acquisition of data, writing, and revision of this manuscript.

Institutional review board statement: This case report was exempt from the Institutional Review Board standards at University of Tennessee Health Science Center at Memphis.

Informed consent statement: The patient reported in this study gave verbal informed consent authorizing use and disclosure of his protected health information.

Conflict-of-interest statement: There are no conflicts of interest to report for any author.

Open-Access: This article is an open-access article which was selected by an in-house editor and fully peer-reviewed by external reviewers. It is distributed in accordance with the Creative Commons Attribution Non Commercial (CC BY-NC 4.0) license, which permits others to distribute, remix, adapt, build upon this work non-commercially, and license their derivative works on different terms, provided the original work is properly cited and the use is non-commercial. See: <http://creativecommons.org/licenses/by-nc/4.0/>

Manuscript source: Invited manuscript

Correspondence to: Nadeem Zafar, MD, Associate Professor, Department of Pathology, University of Tennessee Health Science Center, 930 Madison 5th Floor, Memphis, TN 38163, United States. nzafar@uthsc.edu
Telephone: +1-901-4486436
Fax: +1-901-4486979

Received: January 29, 2017

Peer-review started: February 12, 2017

First decision: March 8, 2017

Revised: March 29, 2017

Accepted: April 23, 2017

Article in press: April 24, 2017

Published online: June 10, 2017

Abstract

The oncocytic variant of prostatic adenocarcinoma is exceptionally rare with only 4 cases reported in the English literature. Little is known about the clinical behavior of this variant of prostatic adenocarcinoma, because of the exceptionally low number of reported cases. The 2016 World Health Organization Classification of Tumors of Prostate does not recognize the oncocytic variant, again likely related to the exceptional paucity of reported cases. Here, we report the fifth case of the oncocytic variant of acinar type prostatic adenocarcinoma in an asymptomatic 64-year-old Caucasian American male with elevated serum prostate specific antigen (7.33 ng/mL; normal range 0-4.00 ng/mL) during routine blood screening for diabetes mellitus. At subsequent transrectal prostate biopsy, the right side of prostate was infiltrated by adenocarcinoma with tumor cells forming variably differentiated glands, including some poorly differentiated. Tumor cell nuclear: cytoplasmic ratio was low, with small to intermediate sized vesicular nuclei and only rare discernable small nucleoli. Cellular cytoplasm was characteristically granular pink with sharply defined cell membranes. Positive AMACR (P504S) epithelial immunohistochemical staining and absence of staining for prostatic basal cells confirmed the tumor to be primary prostatic adenocarcinoma. AMACR immunohistochemical staining was also helpful with accurate grading of the tumor due to the difficulty of differentiating tumor cells from residual prostate myocytes at routine hematoxylin and eosin (HE) staining. This new case adds to the exceptionally small number of previously reported cases of the oncocytic variant of primary prostatic adenocarcinoma. It also highlights the difficulty associated with Gleason scoring of the oncocytic variant by routine HE evaluation and the usefulness of AMACR (P504S) immunostaining for accurate grading of prostatic adenocarcinoma in the oncocytic variant.

Key words: Prostate; Adenocarcinoma; Clinical behavior; Oncocytic; Gleason; Prognosis

© The Author(s) 2017. Published by Baishideng Publishing Group Inc. All rights reserved.

Core tip: The oncocytic variant of prostatic adenocarcinoma is exceptionally rare with only 4 cases reported so far. Through reporting this new case, the oncocytic variant is being highlighted and challenges associated with its accurate diagnosis and staging discussed. The use of immunohistochemistry to confirm prostatic origin of this tumor for accurate grading of this lesion is also highlighted. It is also postulated that the tumor cells may be difficult to locate for their presence and organization at hematoxylin and eosin evaluation, potentially resulting in inaccurate grading of the tumor, the tumor likely behaves no different from the usual/typical variant of acinar-type adenocarcinoma if appropriately graded.

Klaimont MM, Zafar N. Prostatic adenocarcinoma, oncocytic variant: Case report and literature review. *World J Clin Oncol* 2017; 8(3): 289-292 Available from: URL: <http://www.wjgnet.com/2218-4333/full/v8/i3/289.htm> DOI: <http://dx.doi.org/10.5306/wjco.v8.i3.289>

INTRODUCTION

Prostatic adenocarcinoma is a common malignancy, however, the 2016 World Health Organization (WHO) Classification of Prostatic Tumors^[1] does not mention the oncocytic variant of acinar-type adenocarcinoma, likely due to the very small number of reported cases in the literature. There is a paucity of data concerning the clinical behavior of this variant compared to the traditionally established varieties of acinar-type prostate adenocarcinoma. Accordingly, there is a critical need for more cases of the oncocytic variant to be reported, for it to be added to a future WHO classification, and to identify a variable clinical behavior from the usual variant, if that is indeed the case.

CASE REPORT

The 64-year-old Caucasian male with past medical history of hypertension, hyperlipidemia, type-2 diabetes, and otherwise asymptomatic, was also found at routine screening to have an elevated total serum prostate-specific antigen (PSA) of 7.33 ng/mL (range 0-4.0 ng/mL). Review of systems was unremarkable. He denied tobacco use and reported occasional alcohol use. Family history was unremarkable for genitourinary malignancy. Digital rectal exam indicated irregular prostate borders with a single indurated nodule on the right. The patient subsequently underwent transrectal prostate biopsy which revealed a right-sided prostate adenocarcinoma, the left-side being unremarkable. Patient was discharged after biopsy and elected to undergo targeted cryoablation of the prostate at an outside institution.

Histology

At routine hematoxylin and eosin (HE) histology, the right side of the prostate contained a poorly delineated malignancy with tumor cells arranged in vague glandular forms, as well as apparent cords, and possibly some single cells (Figure 1A). The cells had a low nuclear:cytoplasmic ratio, small to intermediate sized vesicular nuclei with only very rare prominent nucleoli, granular amphophilic to acidophilic cytoplasm, and sharp cell membranes (Figure 1B). It was difficult to reliably differentiate tumor cells from residual prostatic myocytes because of overlapping cytomorphology and staining quality (Figure 1B). Routine ABC immunohistochemistry with AMACR (P504S) and prostate basal cell markers (PIN4) was very helpful to confirm this cancer to be primary to prostate, and for accurate Gleason scoring of the tumor, as it clearly demonstrated the absence of single tumor cells and extensive gland formation, mostly discrete, with some tumor cells merging into more solid structures (1C and 1D). The tumor was assigned Gleason score 3 + 4 (20%) = 7, present in all 6/6 cores, 25% of total biopsy, with perineural invasion, but no vascular invasion. Biopsies of the left prostate were negative for malignancy.

DISCUSSION

Oncocytic tumors of prostate are exceedingly rare. The first reported case was an oncocytoma in an 87-year-old man who underwent transurethral resection for prostatic hypertrophy^[2]. While the tumor cells were immunoreactive with cytochrome-oxidase, they were not reactive with PSA.

In 1992, Ordóñez *et al*^[3] reported the first case of prostatic carcinoma with oncocytic features in a 63-year-old patient who presented with inguinal lymph node metastasis and an unknown primary, with a normal serum PSA. The tumor cells had finely granular cytoplasm, which ultrastructural examination showed to contain numerous mitochondria. The cells were immunoreactive with PSA and prostatic acid phosphatase. Subsequent prostatectomy confirmed primary oncocytic adenocarcinoma of the prostate. The authors postulated that the reason for oncocytic transformation may involve possible mitochondrial dysfunction in the cancer cell of origin, resulting in the proliferation of an oncocytic cancer cell type.

Pinto *et al*^[4] reported the 2nd case of primary carcinoma of prostate with diffuse oncocytic changes in a 66-year-old patient, who presented with a retro-ocular tumor and a PSA level of 100 ng/mL. Digital rectal exam indicated prostatic enlargement, which was subsequently biopsied, and the retro-ocular metastasis was also resected. Both the tumor sites contained identical poorly differentiated oncocytic tumor cells with strong immunoreactivity for PSA. This patient also had hyperdense metastatic lesions in various bony sites. The authors postulated that the prognosis of these very rare oncocytic tumors is no different from the usual prostatic acinar carcinoma and is more related to the tumor differentiation (Gleason

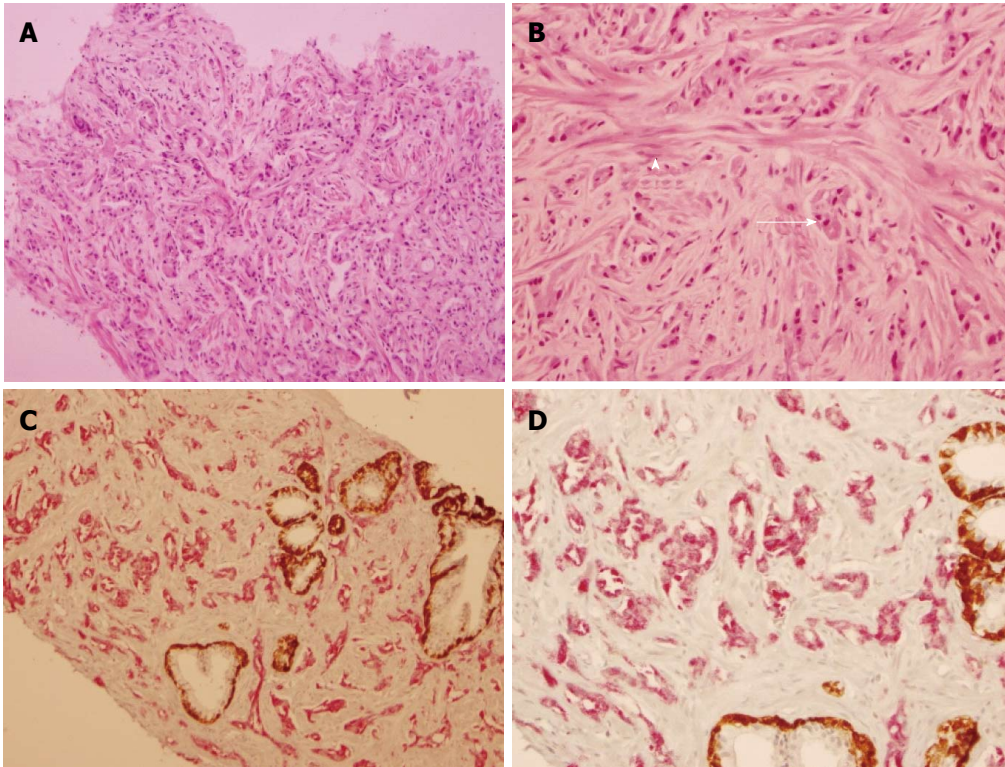


Figure 1 Oncocytic variant of prostatic adenocarcinoma: Hematoxylin and eosin and Immunohistochemical evaluation. A: Low power view of tumor, showing the tumor cells arranged in glandular and loose epithelial clusters (100 \times); B: High power view of tumor in glandular formations (arrow) and spindled residual prostate myocytes (arrowhead) (200 \times); C: PIN4 immunohistochemical staining identifies tumor (in red) and benign prostatic glands with residual basal cells (in brown) (100 \times); D: PIN4 immunohistochemical staining high power (200 \times) view with tumor (in red) and benign prostatic glands with residual basal cells (in brown).

scoring). We agree with this opinion, though we feel this is still anecdotal because of insufficient experience with this tumor variant.

Fiandrino *et al*^[5] reported the third case of prostatic adenocarcinoma with oncocytic features in a 72-year-old patient who presented with dysuria and prostate enlargement. The patient underwent prostatectomy which revealed prostatic adenocarcinoma with oncocytic features involving the entire tumor mass. Capsular infiltration and perineural invasion were also present. Based on extensive gland fusion, it was assigned a Gleason score of 8 (4 + 4) involving 60% of the prostate (both lobes). At immunohistochemistry, the oncocytic tumor cells were strongly positive for PSA and prostatic acid phosphatase (PSAP). Cells also stained positive for antimitochondrial antibody which demonstrated granular cytoplasmic reactivity in tumor cells but not normal glands. Ultrastructural evaluation was performed and similarly demonstrated a high mitochondrial density in tumor cells compared to the adjacent parenchyma.

Khadim *et al*^[6] reported the most recent case of oncocytic variant of prostatic adenocarcinoma in a 57-year-old, who presented with urinary urgency, hesitancy, increased frequency, poor stream, enlarged firm prostate at digital rectal examination and a markedly elevated PSA level of 40 ng/mL. At transurethral resection, the entire prostatic tumor comprised of oncocytic cells, arranged in solid sheets, with round to ovoid hyperchromatic nuclei and granular eosinophilic cytoplasm and PSA immunoreactivity. Gleason

score of 5 + 4 = 9 was assigned, involving 80% of the tissue sampled and without perineural or lymphovascular invasion. No follow-up was provided.

Gilloteaux *et al*^[7] have reported a peculiar, rare oncocyte-like cell in prostatic carcinoma (DU145) cell line, with a small nucleus and with cytoplasm almost entirely filled with often distorted mitochondria. It is enticing to speculate if this might be the cell-type which gives rise to the oncocytic variant of prostatic adenocarcinoma.

In summary, the reasons for presenting this case are multiple, foremost to add to the very limited literature on this variant of prostatic adenocarcinoma and to highlight the challenge of optimal Gleason scoring at HE assessment only. Our calculated Gleason score prior to AMACR (P504) staining was 4 + 5 = 9 because of the presence of poorly differentiated glands and perceived numerous single eosinophilic cells, with only rare well-formed glands. Our final Gleason score was 3 + 4 (20%) = 7, as AMACR (P504S) staining confirmed the absence of single tumor cells in the biopsy and the presence of numerous glands, mostly well-formed, with rare additional distorted and merged tumor glands. We believe the overestimation of Gleason score at HE is related to the difficulty of differentiating residual benign myocytes from tumor cells because of the overlapping cytomorphology and staining characteristics. We feel that AMACR (P504S) staining is critically important for optimal assessment of tumor differentiation and Gleason scoring of the oncocytic variant of prostatic adenocarcinoma. The non-recognition

of this cancer variant in the 2016 WHO classification of tumors of prostate, among other known variants of classic acinar type prostatic adenocarcinoma^[8], is likely related to the exceptionally low number of reported cases, most likely related to very low incidence. Variants of conventional prostate cancer (pseudohyperplastic, foamy gland, hypernephroid, atrophic, microcystic, with Paneth cell-like changes, with collagenous micronodules, with glomeruloid formations, and oncocytic) do not have any known prognostic significance and are graded according to the Gleason system. The prognosis and clinical behavior of the oncocytic variant, therefore, is also likely to be related to the degree of tumor differentiation and clinical staging, and not morphologic variation.

COMMENTS

Case characteristics

A 64-year-old Caucasian male with a serum prostate-specific antigen level of 7.33 ng/mL (range 0-4.0 ng/mL).

Clinical diagnosis

Prostatic enlargement.

Differential diagnosis

Prostatic carcinoma, prostatitis, prostatic hypertrophy.

Pathologic diagnosis

Primary adenocarcinoma of prostate, oncocytic variant, Gleason score 3 + 4 (20%) = 7, 6/6 cores, 20% of total tissue involved on the right, with peri-neural invasion.

Treatment

The patient opted for cryoablation of the prostate at another facility. No further follow-up is available at this point.

Peer-review

This is an interesting case report of a very rare tumor.

REFERENCES

- 1 **Humphrey PA**, Moch H, Cubilla AL, Ulbright TM, Reuter VE. The 2016 WHO Classification of Tumours of the Urinary System and Male Genital Organs-Part B: Prostate and Bladder Tumours. *Eur Urol* 2016; **70**: 106-119 [PMID: 26996659 DOI: 10.1016/j.eururo.2016.02.028]
- 2 **Beer M**, Occhionero F, Welsch U. Oncocytoma of the prostate: a case report with ultrastructural and immunohistochemical evaluation. *Histopathology* 1990; **17**: 370-372 [PMID: 2175296]
- 3 **Ordóñez NG**, Ro JY, Ayala AG. Metastatic prostatic carcinoma presenting as an oncocytic tumor. *Am J Surg Pathol* 1992; **16**: 1007-1012 [PMID: 1384366]
- 4 **Pinto JA**, González JE, Granadillo MA. Primary carcinoma of the prostate with diffuse oncocytic changes. *Histopathology* 1994; **25**: 286-288 [PMID: 7821900]
- 5 **Fiandrino G**, Lucioni M, Filippin F, Viglio A, Nicola M, Molo S, Necchi V, Zmerly H, Ravasi S, Paulli M. Prostatic adenocarcinoma with oncocytic features. *J Clin Pathol* 2011; **64**: 177-178 [PMID: 21131313 DOI: 10.1136/jcp.2010.085720]
- 6 **Khadim MT**, Hassan U, Ejaz A, Mamoon N. Oncocytic variant of prostatic adenocarcinoma- A case report. *Pak Armed Forces Med J* 2012; **62**
- 7 **Gilloteaux J**, Eze N, Jamison JM, McGuire K, Summers JL. A rare, human prostate oncocyte cell originates from the prostatic carcinoma (DU145) cell line. *Ultrastruct Pathol* 2013; **37**: 440-448 [PMID: 23957452 DOI: 10.3109/01913123.2013.814739]
- 8 **Mikuz G**. Histologic classification of prostate cancer. *Anal Quant Cytopathol Histopathol* 2015; **37**: 39-47 [PMID: 26072633]

P- Reviewer: Naspro R, Russo MA **S- Editor:** Song XX
L- Editor: A **E- Editor:** Lu YJ





Published by **Baishideng Publishing Group Inc**
7901 Stoneridge Drive, Suite 501, Pleasanton, CA 94588, USA
Telephone: +1-925-223-8242
Fax: +1-925-223-8243
E-mail: bpgoffice@wjgnet.com
Help Desk: <http://www.f6publishing.com/helpdesk>
<http://www.wjgnet.com>

