

# World Journal of *Gastroenterology*

*World J Gastroenterol* 2017 July 14; 23(26): 4661-4846



### EDITORIAL

- 4661 Can a fibrotic liver afford epithelial-mesenchymal transition?

*Munker S, Wu YL, Ding HG, Liebe R, Weng HL*

- 4669 Impact of hepatitis C oral therapy in portal hypertension

*Libânio D, Marinho RT*

### REVIEW

- 4675 Present and future of metastatic colorectal cancer treatment: A review of new candidate targets

*Martini G, Troiani T, Cardone C, Vitiello P, Sforza V, Ciardiello D, Napolitano S, Della Corte CM, Morgillo F, Raucci A, Cuomo A, Selvaggi F, Ciardiello F, Martinelli E*

- 4689 Diarrhea after bariatric procedures: Diagnosis and therapy

*Borbély YM, Osterwalder A, Kröll D, Nett PC, Inglin RA*

### ORIGINAL ARTICLE

#### Basic Study

- 4701 Fibrinogen deficiency suppresses the development of early and delayed radiation enteropathy

*Wang J, Pathak R, Garg S, Hauer-Jensen M*

- 4712 *Helicobacter pylori* vacA genotype is a predominant determinant of immune response to *Helicobacter pylori* CagA

*Link A, Langner C, Schirrmeister W, Habendorf W, Weigt J, Venerito M, Tammer I, Schlüter D, Schlaermann P, Meyer TF, Wex T, Malfertheiner P*

- 4724 Jianpi Qingchang decoction regulates intestinal motility of dextran sulfate sodium-induced colitis through reducing autophagy of interstitial cells of Cajal

*Dai YC, Zheng L, Zhang YL, Chen X, Chen DL, Wang LJ, Tang ZP*

- 4735 *Lactobacillus acidophilus* alleviates pouchitis after ileal pouch-anal anastomosis in rats

*Xu YY, Zhang YY, He AQ, Li KY, Gao SY, Liu G*

- 4744 Effect of EPEC endotoxin and bifidobacteria on intestinal barrier function through modulation of toll-like receptor 2 and toll-like receptor 4 expression in intestinal epithelial cell-18

*Yang X, Gao XC, Liu J, Ren HY*

**Retrospective Cohort Study**

- 4752 Hospital costs, length of stay and prevalence of hip and knee arthroplasty in patients with inflammatory bowel disease  
*Ehrenpreis ED, Zhou Y*

**Retrospective Study**

- 4759 Eight-week ledipasvir/sofosbuvir in non-cirrhotic, treatment-naïve hepatitis C genotype-1 patients with hepatitis C virus-RNA < 6 million IU/mL: Single center, real world effectiveness and safety  
*Latt NL, Yanny BT, Gharibian D, Gevorkyan R, Sahota AK*
- 4767 Early radiological assessment of locally advanced pancreatic cancer treated with electrochemotherapy  
*Granata V, Fusco R, Setola SV, Piccirillo M, Leongito M, Palaia R, Granata F, Lastoria S, Izzo F, Petrillo A*
- 4779 Effect of initial stent position on patency of transjugular intrahepatic portosystemic shunt  
*Luo SH, Chu JG, Huang H, Yao KC*

**Observational Study**

- 4788 Endoscopy is of low yield in the identification of gastrointestinal neoplasia in patients with dermatomyositis: A cross-sectional study  
*Kidambi TD, Schmajuk G, Gross AJ, Ostroff JW, Terdiman JP, Lee JK*
- 4796 Levels and activities of von Willebrand factor and metalloproteinase with thrombospondin type-1 motif, number 13 in inflammatory bowel diseases  
*Cibor D, Owczarek D, Butenas S, Salapa K, Mach T, Undas A*
- 4806 Predictors of esophageal varices and first variceal bleeding in liver cirrhosis patients  
*Kraja B, Mone I, Akshija I, Koçollari A, Prifti S, Burazeri G*
- 4815 Extreme liver resections with preservation of segment 4 only  
*Balzan SMP, Gava VG, Magalhães MA, Dotto ML*
- 4823 Predictive factors for body weight loss and its impact on quality of life following gastrectomy  
*Tanabe K, Takahashi M, Urushihara T, Nakamura Y, Yamada M, Lee SW, Tanaka S, Miki A, Ikeda M, Nakada K*

**Prospective Study**

- 4831 Divergent expression of bacterial wall sensing toll-like receptors 2 and 4 in colorectal cancer  
*Paarnio K, Väyrynen S, Klintrup K, Ohtonen P, Mäkinen MJ, Mäkelä J, Karttunen TJ*
- 4839 Non-invasive assessment of liver fibrosis using two-dimensional shear wave elastography in patients with autoimmune liver diseases  
*Zeng J, Huang ZP, Zheng J, Wu T, Zheng RQ*

## Contents

*World Journal of Gastroenterology*  
Volume 23 Number 26 July 14, 2017

### ABOUT COVER

Editorial board member of *World Journal of Gastroenterology*, Seung-Wan Ryu, MD, PhD, Associate Professor, Division of Gastrointestinal Surgery, Department of Surgery, Keimyung university, Sch Med, Daegu 700-712, South Korea

### AIMS AND SCOPE

*World Journal of Gastroenterology* (*World J Gastroenterol*, *WJG*, print ISSN 1007-9327, online ISSN 2219-2840, DOI: 10.3748) is a peer-reviewed open access journal. *WJG* was established on October 1, 1995. It is published weekly on the 7<sup>th</sup>, 14<sup>th</sup>, 21<sup>st</sup>, and 28<sup>th</sup> each month. The *WJG* Editorial Board consists of 1375 experts in gastroenterology and hepatology from 68 countries.

The primary task of *WJG* is to rapidly publish high-quality original articles, reviews, and commentaries in the fields of gastroenterology, hepatology, gastrointestinal endoscopy, gastrointestinal surgery, hepatobiliary surgery, gastrointestinal oncology, gastrointestinal radiation oncology, gastrointestinal imaging, gastrointestinal interventional therapy, gastrointestinal infectious diseases, gastrointestinal pharmacology, gastrointestinal pathophysiology, gastrointestinal pathology, evidence-based medicine in gastroenterology, pancreatology, gastrointestinal laboratory medicine, gastrointestinal molecular biology, gastrointestinal immunology, gastrointestinal microbiology, gastrointestinal genetics, gastrointestinal translational medicine, gastrointestinal diagnostics, and gastrointestinal therapeutics. *WJG* is dedicated to become an influential and prestigious journal in gastroenterology and hepatology, to promote the development of above disciplines, and to improve the diagnostic and therapeutic skill and expertise of clinicians.

### INDEXING/ABSTRACTING

*World Journal of Gastroenterology* (*WJG*) is now indexed in Current Contents<sup>®</sup>/Clinical Medicine, Science Citation Index Expanded (also known as SciSearch<sup>®</sup>), Journal Citation Reports<sup>®</sup>, Index Medicus, MEDLINE, PubMed, PubMed Central and Directory of Open Access Journals. The 2017 edition of Journal Citation Reports<sup>®</sup> cites the 2016 impact factor for *WJG* as 3.365 (5-year impact factor: 3.176), ranking *WJG* as 29<sup>th</sup> among 79 journals in gastroenterology and hepatology (quartile in category Q2).

### FLYLEAF

#### I-IX Editorial Board

### EDITORS FOR THIS ISSUE

Responsible Assistant Editor: *Xiang Li*  
Responsible Electronic Editor: *Dan Li*  
Proofing Editor-in-Chief: *Lian-Sheng Ma*

Responsible Science Editor: *Yuan Qi*  
Proofing Editorial Office Director: *Jin-Lei Wang*

NAME OF JOURNAL  
*World Journal of Gastroenterology*

ISSN  
ISSN 1007-9327 (print)  
ISSN 2219-2840 (online)

LAUNCH DATE  
October 1, 1995

FREQUENCY  
Weekly

#### EDITORS-IN-CHIEF

**Damian Garcia-Olmo, MD, PhD, Doctor, Professor, Surgeon**, Department of Surgery, Universidad Autonoma de Madrid; Department of General Surgery, Fundacion Jimenez Diaz University Hospital, Madrid 28040, Spain

**Stephen C Strom, PhD, Professor**, Department of Laboratory Medicine, Division of Pathology, Karolinska Institutet, Stockholm 141-86, Sweden

**Andrzej S Tarnawski, MD, PhD, DSc (Med), Professor of Medicine, Chief Gastroenterology**, VA Long Beach Health Care System, University of California, Irvine, CA, 5901 E. Seventh Str., Long Beach,

CA 90822, United States

#### EDITORIAL BOARD MEMBERS

All editorial board members resources online at <http://www.wjgnet.com/1007-9327/editorialboard.htm>

#### EDITORIAL OFFICE

Jin-Lei Wang, Director  
Yuan Qi, Vice Director  
Ze-Mao Gong, Vice Director  
*World Journal of Gastroenterology*  
Baishideng Publishing Group Inc  
7901 Stoneridge Drive, Suite 501,  
Pleasanton, CA 94588, USA  
Telephone: +1-925-2238242  
Fax: +1-925-2238243  
E-mail: [editorialoffice@wjgnet.com](mailto:editorialoffice@wjgnet.com)  
Help Desk: <http://www.f6publishing.com/helpdesk>  
<http://www.wjgnet.com>

#### PUBLISHER

Baishideng Publishing Group Inc  
7901 Stoneridge Drive, Suite 501,  
Pleasanton, CA 94588, USA  
Telephone: +1-925-2238242  
Fax: +1-925-2238243  
E-mail: [bpgoffice@wjgnet.com](mailto:bpgoffice@wjgnet.com)  
Help Desk: <http://www.f6publishing.com/helpdesk>

<http://www.wjgnet.com>

PUBLICATION DATE  
July 14, 2017

#### COPYRIGHT

© 2017 Baishideng Publishing Group Inc. Articles published by this Open-Access journal are distributed under the terms of the Creative Commons Attribution Non-commercial License, which permits use, distribution, and reproduction in any medium, provided the original work is properly cited, the use is non commercial and is otherwise in compliance with the license.

#### SPECIAL STATEMENT

All articles published in journals owned by the Baishideng Publishing Group (BPG) represent the views and opinions of their authors, and not the views, opinions or policies of the BPG, except where otherwise explicitly indicated.

#### INSTRUCTIONS TO AUTHORS

Full instructions are available online at <http://www.wjgnet.com/bpg/gerinfo/204>

ONLINE SUBMISSION  
<http://www.f6publishing.com>

## Observational Study

# Extreme liver resections with preservation of segment 4 only

Silvio Marcio Pegoraro Balzan, Vinícius Grando Gava, Marcelo Arbo Magalhães, Marcelo Luiz Dotto

Silvio Marcio Pegoraro Balzan, Marcelo Arbo Magalhães, Marcelo Luiz Dotto, Department of Pharmacy and Biology, University of Santa Cruz do Sul, 96810-110 Santa Cruz do Sul, Brazil

Silvio Marcio Pegoraro Balzan, Vinícius Grando Gava, Department of Surgery, Hospital Moinhos de Vento, 90035 Porto Alegre, Brazil

**Author contributions:** Balzan SMP, Gava VG and Magalhães MA designed the research, treated the patients, collected and analyzed the data, and wrote the paper; Dotto ML treated the patients and wrote the paper; all authors read and approved the final version for publication.

**Institutional review board statement:** The study was reviewed and approved by the Institutional Review Board of Hospital Ana Nery.

**Conflict-of-interest statement:** All authors declare no conflict of interest in relation to this study or its publication.

**Data sharing statement:** Technical appendix, statistical code and dataset are available from the corresponding author at [sbalzan@hotmail.com](mailto:sbalzan@hotmail.com). The data were anonymized and, thus, informed consent was not required from the participants.

**Open-Access:** This article is an open-access article which was selected by an in-house editor and fully peer-reviewed by external reviewers. It is distributed in accordance with the Creative Commons Attribution Non Commercial (CC BY-NC 4.0) license, which permits others to distribute, remix, adapt, build upon this work non-commercially, and license their derivative works on different terms, provided the original work is properly cited and the use is non-commercial. See: <http://creativecommons.org/licenses/by-nc/4.0/>

**Manuscript source:** Invited manuscript

**Correspondence to:** Silvio Marcio Pegoraro Balzan, PhD, Department of Pharmacy and Biology, University of Santa Cruz do Sul, Rua Marechal Deodoro, 1139, 96810-110 Santa Cruz do Sul, Brazil. [silviobalzan@unisc.br](mailto:silviobalzan@unisc.br)  
Telephone: +55-51-37152824  
Fax: +55-51-37152824

Received: January 29, 2017

Peer-review started: February 8, 2017

First decision: March 16, 2017

Revised: May 3, 2017

Accepted: June 9, 2017

Article in press: June 12, 2017

Published online: July 14, 2017

## Abstract

### AIM

To evaluate safety and outcomes of a new technique for extreme hepatic resections with preservation of segment 4 only.

### METHODS

The new method of extreme liver resection consists of a two-stage hepatectomy. The first stage involves a right hepatectomy with middle hepatic vein preservation and induction of left lobe congestion; the second stage involves a left lobectomy. Thus, the remnant liver is represented by the segment 4 only (with or without segment 1,  $\pm$  S1). Five patients underwent the new two-stage hepatectomy (congestion group). Data from volumetric assessment made before the second stage was compared with that of 10 matched patients (comparison group) that underwent a single-stage right hepatectomy with middle hepatic vein preservation.

### RESULTS

The two stages of the procedure were successfully carried out on all 5 patients. For the congestion group, the overall volume of the left hemiliver had increased 103% (mean increase from 438 mL to 890 mL) at 4 wk after the first stage of the procedure. Hypertrophy of the future liver remnant (*i.e.*, segment 4  $\pm$  S1) was higher than that of segments 2 and 3 (144% *vs* 54%, respectively,  $P < 0.05$ ). The median remnant liver volume-to-body weight ratio was 0.3 (range, 0.28-0.40).



before the first stage and 0.8 (range, 0.45-0.97) before the second stage. For the comparison group, the rate of hypertrophy of the left liver after right hepatectomy with middle hepatic vein preservation was  $116\% \pm 34\%$ . Hypertrophy rates of segments 2 and 3 ( $123\% \pm 47\%$ ) and of segment 4 ( $108\% \pm 60\%$ ,  $P > 0.05$ ) were proportional. The mean preoperative volume of segments 2 and 3 was  $256 \pm 64$  cc and increased to  $572 \pm 257$  cc after right hepatectomy. Mean preoperative volume of segment 4 increased from  $211 \pm 75$  cc to  $439 \pm 180$  cc after surgery.

## CONCLUSION

The proposed method for extreme hepatectomy with preservation of segment 4 only represents a technique that could allow complete resection of multiple bilateral liver metastases.

**Key words:** Hepatectomy; Colorectal liver metastases; Hepatic congestion; Liver regeneration; Liver resection; Liver failure

© The Author(s) 2017. Published by Baishideng Publishing Group Inc. All rights reserved.

**Core tip:** Extreme hepatic resections with preservation of one segment only may be required for complete resection of multiple bilobar liver metastases. We evaluated a new technique of two-stage hepatectomy with preservation of segment 4 only. Stage one involves a right hepatectomy with middle hepatic vein preservation and associated left lobe congestion through reduction of the left hepatic vein diameter. This combination optimizes segment 4 regeneration while allowing the left lobe (to be resected) to maintain function with reduced hypertrophy. Stage two involves a left lobectomy. Hypertrophy rates of non-congested segment 4 were significantly greater than in congested left lobe.

Balzan SMP, Gava VG, Magalhães MA, Dotto ML. Extreme liver resections with preservation of segment 4 only. *World J Gastroenterol* 2017; 23(26): 4815-4822 Available from: URL: <http://www.wjgnet.com/1007-9327/full/v23/i26/4815.htm> DOI: <http://dx.doi.org/10.3748/wjg.v23.i26.4815>

## INTRODUCTION

Complete surgical resection of colorectal liver metastases (CLM) leads to long-term survival for selected patients with isolated hepatic disease or resectable associated extrahepatic disease<sup>[1-5]</sup>. Technical improvements, mainly in blood flow modulation (such as portal vein embolization, portal vein ligation, associating liver partition and portal vein ligation (ALPPS), and simultaneous portal and hepatic vein embolization), have extended the limits of resection

for CLM<sup>[6-8]</sup>. Stimulation of hepatic regeneration has also made liver resection feasible in patients who would otherwise have a small future liver remnant (FLR). However, these methods are not adequate for cases requiring bilateral anatomical liver resection with preservation of only a small central liver segment, as they cannot provide sufficient selective FLR hypertrophy.

Extensive bilateral hepatic involvement by CLM that requires complete resection of the right hemiliver and of the left lateral section, but which shows minimal or no involvement of segment 4, is an unusual as well as challenging clinical situation. Usually, the volume of liver segment 4 is insufficient to meet the minimal requirements for safe resection of all other segments. Additionally, the commonly applied methods for stimulating liver regeneration were designed to induce hypertrophy in lateral segments of the liver. Deprivation of portal flow to the entire right liver plus to the left lateral section has not yet been reported but would be expected to lead to liver failure if the FLR was very small.

Right portal vein embolization (with or without hepatic vein deprivation) induces parenchymal hypertrophy of both FLR (segment 4) and the left lateral section<sup>[9-12]</sup>. The ALPPS method was developed to induce hypertrophy of the left lateral section, in particular<sup>[13,14]</sup>. Recently, our group published a technical alternative option that optimizes hypertrophy of segment 4, while avoiding hypertrophy of the left lateral section and maintaining its function<sup>[15]</sup>. In this study, we aimed to target hypertrophy to segment 4 by generating a congestion of segments 2 and 3 after performance of a right hepatectomy. The safety and efficacy outcomes of this method are presented herein.

## MATERIALS AND METHODS

### Study design and patients

From January 2013 to December 2015, patients (Table 1) with multiple bilateral CLM who underwent a two-stage hepatectomy with preservation of segment 4 [ $\pm$  segment 1 (S1)] only, using a technique previously described by our team<sup>[15]</sup>, were selected for study inclusion and designated as the "congestion group". For comparative analysis, patients that underwent right hepatectomy were selected to fit a 2: 1 case-matched proportion and included as the "comparison group". Inter-group comparisons were made for the hypertrophy rates of each left side hepatic segment after a right hepatectomy only (in the comparison group) and after a right hepatectomy associated with left lobe congestion (*i.e.*, the first-stage procedure in the congestion group). Pre- and postoperative hepatic triple-phase contrast-enhanced computed tomography (CT) images were used for comparative volumetric assessment of all patients.

**Table 1 Patient characteristics of the congestion group**

|           | Sex    | Age, yr | Weight, kg | Preoperative chemotherapy | Comorbidities | CLM          |
|-----------|--------|---------|------------|---------------------------|---------------|--------------|
| Patient 1 | Female | 52      | 55         | Oxaliplatin               | None          | Metachronous |
| Patient 2 | Female | 61      | 63         | Oxaliplatin               | SAH           | Metachronous |
| Patient 3 | Female | 39      | 98         | Oxaliplatin + bevacizumab | None          | Synchronous  |
| Patient 4 | Female | 54      | 66         | Oxaliplatin               | None          | Metachronous |
| Patient 5 | Female | 65      | 46         | Oxaliplatin               | DM, SAH       | Metachronous |

CLM: Colorectal liver metastases; DM: Diabetes mellitus; SAH: Systemic arterial hypertension.

### Congestion group

The congestion group included 5 patients with multiple bilateral CLM who had been selected for resection according to fulfillment of the following criteria: (1) hepatic segment 4 ( $\pm$  S1) without lesions or with only superficial lesions appropriate for atypical resection; (2) right hemiliver and left lateral sector both considered ineligible for surgical preservation due to the presence of multiple deep and/or sectorial or segmental hepatic pedicle tumor involvement; and (3) absence of detectable extrahepatic metastases (Table 1).

Abdominal and thoracic contrast-enhanced CT, abdominal magnetic resonance imaging (MRI), and positron emission tomography (PET)-CT were used to detect hepatic and extrahepatic disease. Hepatic metastases were defined as metachronous if they were diagnosed at least 6 mo after colorectal tumor resection. All patients received chemotherapy with oxaliplatin-based standard protocols and showed no hepatic disease progression prior to the surgical resection.

At the time of presentation of the metastatic liver disease, none of the patients were considered candidates for surgery as their FRLs were too small. Individual case discussion was carried out by the multidisciplinary tumor board, with alternatives for ensuring achievement of complete hepatic resection of the metastatic disease being considered. In this scenario, simultaneous embolization of the right portal vein and left lateral sector portal branches was deemed to be too risky because of the very small FLR (segment 4  $\pm$  S1). Of note, the left lateral lobe was evaluated for preservation but complete cleanup was deemed impossible, even with application of local ablation methods.

### Comparison group

The comparison group consisted of 10 patients that had been randomly selected from a large database so that each patient was matched according to the following criteria: age (classified according to decades), sex, American Society of Anesthesiologists (commonly known as ASA) score, CLM diagnoses, preoperative chemotherapy (chemotherapeutic agents and duration), and type of resection (right hepatectomy with middle hepatic vein preservation).

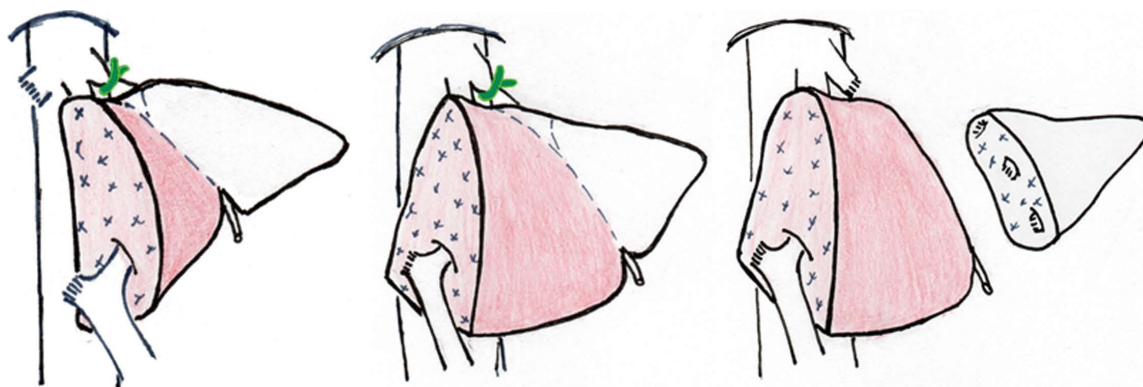
### Rationale for segmental congestion and technical aspects

Extended hepatic resection with preservation of segment 4 only represents a significant clinical challenge. The usual options for resection in patients with multiple bilateral metastases include methods of portal vein privation with or without local ablation techniques. However, when segment 4 is the only one to be preserved, performance of isolated right portal vein embolization (or even in conjunction with right hepatic vein occlusion) induces hypertrophy of both segment 4 and the left lateral sector, namely of both the segments to be preserved and the segments to be resected. Thus, the increase of segment 4 is not optimal, and it might not be sufficient for successful outcome. On the other hand, coincident embolization of the left lateral sector portal branches (in addition to the right portal vein embolization) is a risky procedure since the non-embolized segment is too small.

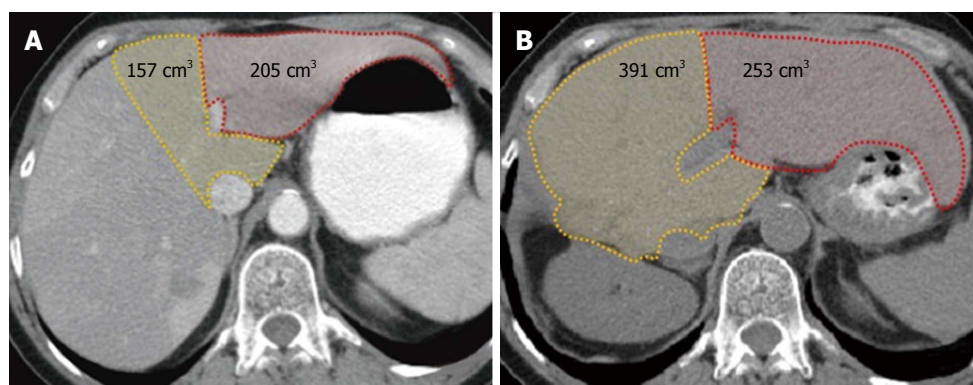
Thus, to optimize hypertrophy of the FLR (*i.e.*, segment 4), our team conceived of a two-stage procedure (Figure 1) in which the initial surgery consists of a right hepatectomy with middle hepatic vein preservation and induction of congestion of the left lobe, and the second stage is a left lateral sectionectomy.

Since parenchymal resection provides the highest expected rate of remnant liver hypertrophy, a major hepatic resection (right hepatectomy) is performed in the first stage. Additionally, to promote future hypertrophy of segment 4 and to avoid hypertrophy of the left lateral sector, congestion of left lobe is induced. To induce the desired segmental congestion, a silicone tube is wrapped around the left hepatic vein, outside of the liver. The diameter of the looping silicone is progressively diminished around the vein. When macroscopic signs of congestion become evident in segments 2 and 3, a Doppler study is performed to ensure that hepatopetal flow is still present in these segments. Finally, the silicone tube is tied-off in order to maintain the diameter of the vessel according to the size of the loop. The loop is left *in situ* until the second stage is performed. It is important to ensure the hepatopetal flow despite congestion, as this will help maintain the function of the congested segments but will limit their hypertrophy rates.

At 4 wk after the first stage, a CT with volumetric assessment is performed to evaluate parenchymal



**Figure 1** Schematic representation of two-stage hepatectomy with preservation of segment 4 only using outflow modulation. A: During the first stage, a right hepatectomy with middle hepatic vein is performed along with an associated induction of congestion in the left lobe; B: Redistribution of portal flow (increased inflow to segment 4 after territorial congestion of segments 2/3) optimizes hypertrophy of segment 4 and avoids hypertrophy of segment 2 and 3; C: The second stage of procedure, a left lobectomy, is performed.



**Figure 2** Computed tomography-based volumetry. A: Before the first stage of liver resection; B: Before the second stage of the procedure. Modulated congestion of the left lobe associated with right hepatectomy led to a significant hypertrophy rate of segments 4 and 1 (156%) but only a modest hypertrophy rate of segments 2 and 3 (24%). Modified from Balzan *et al.*<sup>[15]</sup>.

hypertrophy (Figure 2), after which a left lateral sectionectomy is performed if the FLR is considered sufficient. When lesions are also present on segments 4 and/or 1, the tumors are resected during the first stage, thereby “cleaning” the FLR for the subsequent procedure.

Both the first and second stages were performed with a J-shaped incision. Intraoperative ultrasound was used to verify the transection plane and assure preservation and permeability of the middle hepatic vein. The left hepatic vein was dissected and encircled by the standard technique. Parenchymal transection was performed using a saline-irrigated bipolar device, and all vascular and biliary structures sized  $\geq 3$  mm were divided between ligatures. Intermittent Pringle maneuver (15 min of clamping with 5 min intervals) was used as needed.

#### Measurement of liver volumetry

Volumetry of segments 4 and 1 (or of only segment 4 if S1 should be resected) and of segments 2 and 3 (left lobe) was performed preoperatively and at 4 wk after the right hepatectomy (Figure 2). The regeneration rate (percent hypertrophy) was calculated with the

following formula:  $[(\text{segmental volume after surgery} - \text{segmental volume before surgery}) \times 100] / \text{segmental volume before surgery}$ . Volumetries were determined by contrast-enhanced CT acquisitions and by use of the Osirix for IOS medical imaging viewer software (Pixmeo SARL, Bernex, Switzerland, 2012).

#### Statistical analysis

Data are expressed as mean  $\pm$  SE of the mean or median. A *t*-test was used to compare means. *P* value  $< 0.05$  indicated statistical significance. All statistical analyses were performed by the SPSS statistical software package, version 10.1 (SPSS Inc, Chicago, IL, United States).

## RESULTS

#### Liver regeneration in the congestion group

The overall left liver increased by 103% (mean increase from 438 mL to 890 mL) in the 4 wk after performance of the first stage of the procedure. Hypertrophy of the FLR (*i.e.*, segment 4  $\pm$  S1) was greater than that of segments 2 and 3 (144% vs 54%, respectively, *P*  $< 0.05$ ). Table 2 shows the individual volumes



**Table 2** Hypertrophy rate of congested and non-congested segments

|               | Segments 2/3                 |                              |                  | Segment 4 ( $\pm$ S1)        |                              |                  | P value |
|---------------|------------------------------|------------------------------|------------------|------------------------------|------------------------------|------------------|---------|
|               | 1 <sup>st</sup> stage, in cc | 2 <sup>nd</sup> stage, in cc | Hypertrophy rate | 1 <sup>st</sup> stage, in cc | 2 <sup>nd</sup> stage, in cc | Hypertrophy rate |         |
| Case 1        | 205                          | 253                          | 24%              | 157                          | 391                          | 149%             |         |
| Case 2        | 228                          | 331                          | 45%              | 192                          | 505                          | 163%             |         |
| Case 3        | 309                          | 679                          | 120%             | 272                          | 823                          | 203%             |         |
| Case 4        | 248                          | 407                          | 64%              | 225                          | 641                          | 185%             |         |
| Case 5        | 186                          | 214                          | 15%              | 167                          | 206                          | 23%              |         |
| mean $\pm$ SD | 235 $\pm$ 42                 | 377 $\pm$ 165                | 54 $\pm$ 37      | 203 $\pm$ 42                 | 513 $\pm$ 211                | 144 $\pm$ 63     | < 0.05  |

1<sup>st</sup> stage: Volumetry before 1<sup>st</sup> stage; 2<sup>nd</sup> stage: Volumetry before second stage (after right hepatectomy and segments 2 and 3 congestion).

and hypertrophy rates for each patient. The median remnant liver volume-to-body weight ratio was 0.3 (range, 0.28-0.40) before the first stage and 0.8 (range, 0.45-0.97) before the second stage.

### Liver regeneration in the comparison group

The overall hypertrophy rate of the left liver at 4-6 wk after right hepatectomy with middle hepatic vein preservation in this group was 116%  $\pm$  34%. The hypertrophy rates were proportional for segments 2 and 3 and segment 4 (123%  $\pm$  47% vs 108%  $\pm$  60%,  $P$  > 0.05). The mean preoperative volume of segments 2 and 3 was 256  $\pm$  64 cc, which increased to 572  $\pm$  257 cc after the right hepatectomy. The mean preoperative volume of segment 4 increased from 211  $\pm$  75 cc to 439  $\pm$  180 cc after the surgery.

### Morbidity and mortality rates

Both of the two stages of the novel procedure were successfully completed in all 5 patients. One patient (case #3) developed postoperative ascites after the first stage, requiring prolonged hospital stay. Another patient (case 5, a 65-year-old female) died at 30 d after the second stage, due to liver failure that likely resulted from small-for-size syndrome. In this patient, ascites and jaundice developed on postoperative day 7 and increased progressively with no evidence of biliary obstruction. She had been receiving systemic oxaliplatin-based chemotherapy for 8 mo prior to performance of the first stage. Her hypertrophy rate at 4 wk after the first stage was below expected, for both congested and non-congested segments (15% and 23%, respectively).

All other patients experienced uneventful postoperative recovery (*i.e.*, no Dindo-Clavien complication of grade 2 or more) after the first and second stages.

## DISCUSSION

The present study demonstrates that modulation of outflow allows for targeted liver regeneration. The method reported is particularly useful for patients in whom only segment 4 ( $\pm$  S1) can be preserved. In such cases, as described herein, the hypertrophy rate of segment 4 ( $\pm$  S1) after right hepatectomy was optimized when partial outflow deprivation of

segments 2/3 was employed.

The classical paradigm of liver resectability comprises the preservation of at least two contiguous functional liver segments, with appropriate portal and arterial inflow, as well as venous outflow and biliary drainage. Right and left trisectionectomies are the most extensive liver resections routinely performed<sup>[16]</sup>. Moreover, two-stage hepatectomy for bilateral CLM may provide long-term outcomes that are comparable to those in patients treated with a planned single-stage hepatectomy<sup>[16-20]</sup>. However, extreme resections with preservation of only a single liver segment have been reported rarely<sup>[21-23]</sup>. Two cases of hepatic resection with only segment 4 preservation were reported by Adam *et al.*<sup>[21]</sup>, and both used staged procedures. For these, the first stage involved a major hepatectomy (right hepatectomy) in one of the patients and a minor hepatectomy (left lobectomy) in the other one. Schadde *et al.*<sup>[19]</sup> reported 6 cases with left lobectomy performed during the first stage, in the context of ALPPS, followed by right hepatectomy in the second stage.

Our technique comprises a right hepatectomy (with or without wedge resections on segment 4) during the first stage of the procedure and a left lobectomy as the second stage. The potential disadvantages of performing a major liver resection first include: (1) submitting the patient to a higher-risk procedure initially, although this is offset by the chance that the patient may eventually not be a candidate for the second stage due to disease progression; and (2) subjecting the surgeon of the second stage to a procedure with increased technical difficulty if adhesions involving the diaphragm have formed. However, other positive aspects should be considered: (1) a major resection performed as the initial procedure induces a greater extent of hepatic regeneration than a minor hepatectomy; (2) anatomical right hepatectomy is a standardized procedure with acceptable morbidity; and (3) lysis of adhesions from the diaphragm to the cut section of the liver is not routinely required to perform the second stage procedure (left lobectomy). Besides these, no oncological benefit has been demonstrated for one strategy over another.

Extensive parenchymal resection results in the highest rate of regeneration of the remaining liver, as

compared to other reported methods that induce FLR hypertrophy. In our study, the overall volume increase of the left liver after the first stage was 103%, and the FLR (*i.e.*, segment 4) increased 144% before the second stage. In ALPPS, the reported hypertrophy rates of FLR before the second stage have ranged from 47% to 110%<sup>[13,24-26]</sup>. Likewise, in portal vein embolization or ligation alone, or when associated with ipsilateral hepatic vein occlusion, even more modest rates of hypertrophy have been reported (from as low as 8.2% and up to 46%)<sup>[27-31]</sup>.

Hypertrophy of the remaining liver after major parenchymal hepatic resection is fast and powerful, and involves a complex process of signaling pathways<sup>[32]</sup>. The role of portal flow in the process of regeneration after major hepatectomy is unclear, but induction of regeneration seems to occur due to: (1) the increase of portal flow per unit mass itself; and (2) the large incoming amounts (per hepatocyte) of signaling molecules usually present in portal blood<sup>[33]</sup>. According to these concepts, the temporary increase of portal flow to some hepatic territories would strongly stimulate the regenerative process of these hepatocytes, while the maintenance of a usual portal flow would prevent regeneration.

This phenomenon explains the disproportional rate of hypertrophy that is seen between the left lobe and segment 4 after right hepatectomy, with or without preservation of the middle hepatic vein. It is known that after right hepatectomy with middle hepatic vein resection, the rate of regeneration of segment 4 is lower than that of segments 2 and 3. On the other hand, after right hepatectomy with middle hepatic vein preservation, all remnant segments show a similar hypertrophy<sup>[33-35]</sup>. In our technique, this knowledge was applied in a reverse manner, specifically a reduction of outflow from the left lobe after the right hepatectomy with preservation of middle hepatic vein. In fact, the induced congestion of the left lobe prevents the expected increase of portal flow to this hepatic area, maintaining its function while avoiding hypertrophy. In the meantime, the portal flow is redirected to non-congested segments (segments 4 and 1), *i.e.*, the FLR, optimizing its regeneration.

Thus, induced congestion of the left lobe (which is to be resected) during the first stage of the procedure aims to prevent its hypertrophy while optimizing that of segment 4 (which is to be preserved). Our results confirm a significant disproportional hypertrophy rate of the congested left lobe (54%) compared to the non-congested segment 4 (144%), allowing for safe resection of the left lobe in the second stage of the procedure. The consistency of this strategy is evidenced by the hypertrophy rate of the matched comparison group of patients that underwent a right hepatectomy with middle hepatic vein preservation. In this comparison group, in the context of single-stage hepatectomy for CLM, a proportional hypertrophy rate

was observed for left lobe and segment 4.

The interval between performance of the first and second stages ranged from 6 wk to 8 wk, and all patients underwent the second stage of the procedure. One patient died following the second stage. This patient presented an unexpected low rate of hypertrophy after the first stage (15% for the left lobe and 23% for segment 4) and underwent the second stage with a FRL of 206 cc (0.45% of the body weight). The restricted rate of hypertrophy could have been related to the long period of preoperative chemotherapy (8 mo) that the patient had undergone. The postoperative clinical findings were compatible with small-for-size syndrome and started to develop after postoperative day 7, with progressive hyperbilirubinemia and voluminous ascites. The patient died of liver failure on postoperative day 30.

Future studies should take into account both the expected rate of hypertrophy and the kinetic rate of hypertrophy. These rates should probably be considered as contraindications for the second procedure, as in other strategies used to induce liver hypertrophy. Also, the ideal interval between the two stages remains to be determined, as well as the benefit of chemotherapy during the interval period. To evaluate the viability of performing the second stage early, our group recently initiated a prospective protocol that includes volumetric assessment on day 7 after performance of the first stage.

In summary, this novel method for extreme hepatectomy with preservation of only segment 4 represents a new understanding of the clinical treatment that could refine the assignment of patients with multiple bilateral liver metastases to achieve a complete resection.

## COMMENTS

### Background

Complete resection is the only potential curative treatment for colorectal liver metastases (CLM). Resection of multiple bilateral lesions represents a technical challenge and a real risk of postoperative hepatic failure when segment 4 is the only hepatic segment to be preserved.

### Research frontiers

The usual technical options for resection of multiple bilateral CLM are preoperative portal vein embolization, associating liver partition and portal vein ligation, and two-stage hepatectomy. Unfortunately, these are rarely useful for extreme resection with preservation of segment 4 only, due to the common very-small future liver remnant. Thus, a method allowing safe hepatic resection with preservation of only segment 4 will benefit a significant number of patients.

### Innovations and breakthroughs

A two-stage procedure that can overcome the risk of postoperative hepatic failure among patients with preservation of segment 4 only is presented. The first stage involves a right hepatectomy (to accomplish the higher expected hypertrophy rate) and a reduction of the left hepatic vein diameter (venous congestion to preclude proper hypertrophy). This strategy allows for an extraordinary hypertrophy rate of segment 4 (future liver remnant), while the left lobe maintains its function with a much less extent of increase in size. Then, the second stage can be safely accomplished through a left lobectomy. Compared to conventional right hepatectomy, the use of outflow modulation optimizes the

hypertrophy rate of the target area.

## Applications

This surgical technique represents a useful and safe method to perform extreme resections when the only hepatic segment to be preserved is segment 4.

## Peer-review

This is a retrospective study, limited by the small number of patients. However, the use of this innovative technique allows extensive liver resection in patients with multiple bilateral liver metastases in a scenario that cannot be treated by conventional approaches. The comparison group in this paper clearly shows that venous congestion is a useful tool to optimize liver hypertrophy of the future liver remnant. The spreading of such technique should encourage other centers to perform it. Its benefit in a larger number of patients shall become apparent with further series.

## REFERENCES

- 1 Abbas S, Lam V, Hollands M. Ten-year survival after liver resection for colorectal metastases: systematic review and meta-analysis. *ISRN Oncol* 2011; **2011**: 763245 [PMID: 22091431 DOI: 10.5402/2011/763245]
- 2 Marudanayagam R, Ramkumar K, Shanmugam V, Langman G, Rajesh P, Coldham C, Bramhall SR, Mayer D, Buckels J, Mirza DF. Long-term outcome after sequential resections of liver and lung metastases from colorectal carcinoma. *HPB (Oxford)* 2009; **11**: 671-676 [PMID: 20495635 DOI: 10.1111/j.1477-2574.2009.00115.x]
- 3 Sakamoto Y, Sakaguchi Y, Oki E, Minami K, Toh Y, Okamura T. Surgical outcomes after resection of both hepatic and pulmonary metastases from colorectal cancer. *World J Surg* 2012; **36**: 2708-2713 [PMID: 22782440 DOI: 10.1007/s00268-012-1708-8]
- 4 McNally SJ, Parks RW. Surgery for colorectal liver metastases. *Dig Surg* 2013; **30**: 337-347 [PMID: 24051581 DOI: 10.1159/000351442]
- 5 Leung U, Gönen M, Allen PJ, Kingham TP, DeMatteo RP, Jarnagin WR, D'Angelica MI. Colorectal Cancer Liver Metastases and Concurrent Extrahepatic Disease Treated With Resection. *Ann Surg* 2017; **265**: 158-165 [PMID: 28009741 DOI: 10.1097/SLA.0000000000001624]
- 6 May BJ, Talenfeld AD, Madoff DC. Update on portal vein embolization: evidence-based outcomes, controversies, and novel strategies. *J Vasc Interv Radiol* 2013; **24**: 241-254 [PMID: 23369559 DOI: 10.1016/j.jvir.2012.10.017]
- 7 Spelt L, Sparrelid E, Isaksson B, Andersson RG, Stureson C. Tumour growth after portal vein embolization with pre-procedural chemotherapy for colorectal liver metastases. *HPB (Oxford)* 2015; **17**: 529-535 [PMID: 25726854 DOI: 10.1111/hpb.12397]
- 8 Guiu B, Chevallier P, Denys A, Delhom E, Pierredon-Foulongne MA, Rouanet P, Fabre JM, Quenet F, Herrero A, Panaro F, Baudin G, Ramos J. Simultaneous trans-hepatic portal and hepatic vein embolization before major hepatectomy: the liver venous deprivation technique. *Eur Radiol* 2016; **26**: 4259-4267 [PMID: 27090112 DOI: 10.1007/s00330-016-4291-9]
- 9 Abdalla EK. Portal vein embolization (prior to major hepatectomy) effects on regeneration, resectability, and outcome. *J Surg Oncol* 2010; **102**: 960-967 [PMID: 21165999 DOI: 10.1002/jso.21654]
- 10 Farges O, Belghiti J, Kianmanesh R, Regimbeau JM, Santoro R, Vilgrain V, Denys A, Sauvanet A. Portal vein embolization before right hepatectomy: prospective clinical trial. *Ann Surg* 2003; **237**: 208-217 [PMID: 12560779 DOI: 10.1097/01.SLA.0000048447.16651.7B]
- 11 Hwang S, Lee SG, Ko GY, Kim BS, Sung KB, Kim MH, Lee SK, Hong HN. Sequential preoperative ipsilateral hepatic vein embolization after portal vein embolization to induce further liver regeneration in patients with hepatobiliary malignancy. *Ann Surg* 2009; **249**: 608-616 [PMID: 19300228 DOI: 10.1097/SLA.0b013e31819ecc5c]
- 12 Donati M, Stavrou GA, Oldhafer KJ. Current position of ALPPS in the surgical landscape of CRLM treatment proposals. *World J Gastroenterol* 2013; **19**: 6548-6554 [PMID: 24151380 DOI: 10.3748/wjg.v19.i39.6548]
- 13 Schadde E, Ardiles V, Robles-Campos R, Malago M, Machado M, Hernandez-Alejandro R, Soubrane O, Schnitzbauer AA, Raptis D, Tschuor C, Petrowsky H, De Santibanes E, Clavien PA; ALPPS Registry Group. Early survival and safety of ALPPS: first report of the International ALPPS Registry. *Ann Surg* 2014; **260**: 829-836; discussion 836-838 [PMID: 25379854 DOI: 10.1097/SLA.0000000000000947]
- 14 Hasselgren K, Malagò M, Vyas S, Campos RR, Brusadin R, Linecker M, Petrowsky H, Clavien PA, Machado MA, Hernandez-Alejandro R, Wanis K, Valter L, Sandström P, Björnsson B. Neoadjuvant chemotherapy does not affect future liver remnant growth and outcomes of associating liver partition and portal vein ligation for staged hepatectomy. *Surgery* 2017; **161**: 1255-1265 [PMID: 28081953 DOI: 10.1016/j.surg.2016.11.033]
- 15 Balzan SM, Gava VG, Magalhaes MA, Dotto ML. Outflow modulation to target liver regeneration: something old, something new. *Eur J Surg Oncol* 2014; **40**: 140-143 [PMID: 24075823 DOI: 10.1016/j.ejso.2013.08.012]
- 16 Jaeck D, Oussoultzoglou E, Rosso E, Greget M, Weber JC, Bachellier P. A two-stage hepatectomy procedure combined with portal vein embolization to achieve curative resection for initially unresectable multiple and bilobar colorectal liver metastases. *Ann Surg* 2004; **240**: 1037-1049; discussion 1049-1051 [PMID: 15570209 DOI: 10.1097/01.sla.0000145965.86383.89]
- 17 Tsai S, Marques HP, de Jong MC, Mira P, Ribeiro V, Choti MA, Schulick RD, Barroso E, Pawlik TM. Two-stage strategy for patients with extensive bilateral colorectal liver metastases. *HPB (Oxford)* 2010; **12**: 262-269 [PMID: 20590896 DOI: 10.1111/j.1477-2574.2010.00161.x]
- 18 Tsim N, Healey AJ, Frampton AE, Habib NA, Bansil DS, Wasan H, Cleator SJ, Stebbing J, Lowdell CP, Jackson JE, Tait P, Jiao LR. Two-stage resection for bilobar colorectal liver metastases: R0 resection is the key. *Ann Surg Oncol* 2011; **18**: 1939-1946 [PMID: 21298352 DOI: 10.1245/s10434-010-1533-y]
- 19 Schadde E, Malagò M, Hernandez-Alejandro R, Li J, Abdalla E, Ardiles V, Lurje G, Vyas S, Machado MA, de Santibanes E. Monosegment ALPPS hepatectomy: extending resectability by rapid hypertrophy. *Surgery* 2015; **157**: 676-689 [PMID: 25712199 DOI: 10.1016/j.surg.2014.11.015]
- 20 Makuuchi M, Hasegawa H, Yamazaki S, Takayasu K. Four new hepatectomy procedures for resection of the right hepatic vein and preservation of the inferior right hepatic vein. *Surg Gynecol Obstet* 1987; **164**: 68-72 [PMID: 3026059]
- 21 Adam R, Laurent A, Azoulay D, Castaing D, Bismuth H. Two-stage hepatectomy: A planned strategy to treat irresectable liver tumors. *Ann Surg* 2000; **232**: 777-785 [PMID: 11088072 DOI: 10.1097/0000658-200012000-00006]
- 22 Lau WY, Lai EC, Lau SH. Associating liver partition and portal vein ligation for staged hepatectomy: the current role and development. *Hepatobiliary Pancreat Dis Int* 2017; **16**: 17-26 [PMID: 28119254 DOI: 10.1016/S1499-3872(16)60174-1]
- 23 Edmondson MJ, Sodergren MH, Pucher PH, Darzi A, Li J, Petrowsky H, Campos RR, Serrablo A, Jiao LR. Variations and adaptations of associated liver partition and portal vein ligation for staged hepatectomy (ALPPS): Many routes to the summit. *Surgery* 2016; **159**: 1058-1072 [PMID: 26747229 DOI: 10.1016/j.surg.2015.11.013]
- 24 Tanaka K, Matsuo K, Murakami T, Kawaguchi D, Hiroshima Y, Koda K, Endo I, Ichikawa Y, Taguri M, Tanabe M. Associating liver partition and portal vein ligation for staged hepatectomy (ALPPS): short-term outcome, functional changes in the future liver remnant, and tumor growth activity. *Eur J Surg Oncol* 2015; **41**: 506-512 [PMID: 25704556 DOI: 10.1016/j.ejso.2015.01.031]
- 25 Mise Y, Passot G, Wang X, Chen HC, Wei S, Brudevick KW, Aloia TA, Conrad C, Huang SY, Vauthey JN. A Nomogram to Predict Hypertrophy of Liver Segments 2 and 3 After Right Portal Vein Embolization. *J Gastrointest Surg* 2016; **20**: 1317-1323 [PMID: 26747229 DOI: 10.1016/j.surg.2015.11.013]

- 27073080 DOI: 10.1007/s11605-016-3145-8]
- 26 **Pandanaboyana S**, Bell R, Hidalgo E, Toogood G, Prasad KR, Bartlett A, Lodge JP. A systematic review and meta-analysis of portal vein ligation versus portal vein embolization for elective liver resection. *Surgery* 2015; **157**: 690-698 [PMID: 25704417 DOI: 10.1016/j.surg.2014.12.009]
  - 27 **Zeile M**, Bakal A, Volkmer JE, Stavrou GA, Dautel P, Hoeltje J, Stang A, Oldhafer KJ, Brünig R. Identification of cofactors influencing hypertrophy of the future liver remnant after portal vein embolization-the effect of collaterals on embolized liver volume. *Br J Radiol* 2016; **89**: 20160306 [PMID: 27730840 DOI: 10.1259/bjr.20160306]
  - 28 **Abulkhir A**, Limongelli P, Healey AJ, Damrah O, Tait P, Jackson J, Habib N, Jiao LR. Preoperative portal vein embolization for major liver resection: a meta-analysis. *Ann Surg* 2008; **247**: 49-57 [PMID: 18156923 DOI: 10.1097/SLA.0b013e31815f6e5b]
  - 29 **Hwang S**, Ha TY, Ko GY, Kwon DI, Song GW, Jung DH, Kim MH, Lee SK, Lee SG. Preoperative Sequential Portal and Hepatic Vein Embolization in Patients with Hepatobiliary Malignancy. *World J Surg* 2015; **39**: 2990-2998 [PMID: 26304608 DOI: 10.1007/s00268-015-3194-2]
  - 30 **Michalopoulos GK**. Liver regeneration after partial hepatectomy: critical analysis of mechanistic dilemmas. *Am J Pathol* 2010; **176**: 2-13 [PMID: 20019184 DOI: 10.2353/ajpath.2010.090675]
  - 31 **Hata S**, Sugawara Y, Kishi Y, Niiya T, Kaneko J, Sano K, Imamura H, Kokudo N, Makuuchi M. Volume regeneration after right liver donation. *Liver Transpl* 2004; **10**: 65-70 [PMID: 14755780 DOI: 10.1002/lt.20006]
  - 32 **Zappa M**, Dondero F, Sibert A, Vullierme MP, Belghiti J, Vilgrain V. Liver regeneration at day 7 after right hepatectomy: global and segmental volumetric analysis by using CT. *Radiology* 2009; **252**: 426-432 [PMID: 19703882 DOI: 10.1148/radiol.2523080922]
  - 33 **Scatton O**, Plasse M, Dondero F, Vilgrain V, Sauvanet A, Belghiti J. Impact of localized congestion related to venous deprivation after hepatectomy. *Surgery* 2008; **143**: 483-489 [PMID: 18374045 DOI: 10.1016/j.surg.2007.11.002]
  - 34 **Wicherts DA**, Miller R, de Haas RJ, Bitsakou G, Vibert E, Veilhan LA, Azoulay D, Bismuth H, Castaing D, Adam R. Long-term results of two-stage hepatectomy for irresectable colorectal cancer liver metastases. *Ann Surg* 2008; **248**: 994-1005 [PMID: 19092344 DOI: 10.1097/SLA.0b013e3181907fd9]
  - 35 **Viganò L**, Torzilli G, Cimino M, Imai K, Vibert E, Donadon M, Castaing D, Adam R. Drop-out between the two liver resections of two-stage hepatectomy. Patient selection or loss of chance? *Eur J Surg Oncol* 2016; **42**: 1385-1393 [PMID: 27316601 DOI: 10.1016/j.ejso.2016.03.020]

**P- Reviewer:** Rezaee-Zavareh MS, Zhu X **S- Editor:** Qi Y

**L- Editor:** A **E- Editor:** Zhang FF







Published by **Baishideng Publishing Group Inc**  
7901 Stoneridge Drive, Suite 501, Pleasanton, CA 94588, USA  
Telephone: +1-925-223-8242  
Fax: +1-925-223-8243  
E-mail: [bpgoffice@wjgnet.com](mailto:bpgoffice@wjgnet.com)  
Help Desk: <http://www.f6publishing.com/helpdesk>  
<http://www.wjgnet.com>



ISSN 1007-9327



9 771007 932045