

World Journal of *Gastrointestinal Endoscopy*

World J Gastrointest Endosc 2017 October 16; 9(10): 499-539



MINIREVIEWS

- 499 Endoscopic ultrasound: Current roles and future directions
Friedberg SR, Lachter J
- 506 Endoscopic ultrasound elastography for solid pancreatic lesions
Chantarojanasiri T, Kongkam P

ORIGINAL ARTICLE

Retrospective Study

- 514 Oral esomeprazole vs injectable omeprazole for the prevention of hemorrhage after endoscopic submucosal dissection
Uchiyama T, Higurashi T, Kuriyama H, Kondo Y, Hata Y, Nakajima A

CASE REPORT

- 521 Two case reports of acute upper gastrointestinal bleeding from duodenal ulcers after Roux-en-Y gastric bypass surgery: Endoscopic diagnosis and therapy by single balloon or push enteroscopy after missed diagnosis by standard esophagogastroduodenoscopy
Hakim S, Reddy SRR, Batke M, Polidori G, Cappell MS
- 529 Cap polyposis refractory to *Helicobacter pylori* eradication treated with endoscopic submucosal dissection
Murata M, Sugimoto M, Ban H, Otsuka T, Nakata T, Fukuda M, Inatomi O, Bamba S, Kushima R, Andoh A
- 535 Endoscopic ultrasound-guided pancreaticogastrostomy for symptomatic pancreatic duct obstruction caused by migrated pancreatic stent
Lu L, Jin HB, Yang JF, Zhang XF

Contents

World Journal of Gastrointestinal Endoscopy
Volume 9 Number 10 October 16, 2017

ABOUT COVER

Editorial Board Member of *World Journal of Gastrointestinal Endoscopy*, Dr. Stepan Suchanek, MD, PhD, Chief Doctor, Department of Internal Medicine, 1st Faculty of Medicine of the Charles University, Prague CZ16902, Czech Republic

AIM AND SCOPE

World Journal of Gastrointestinal Endoscopy (*World J Gastrointest Endosc*, *WJGE*, online ISSN 1948-5190, DOI: 10.4253) is a peer-reviewed open access (OA) academic journal that aims to guide clinical practice and improve diagnostic and therapeutic skills of clinicians.

WJGE covers topics concerning gastroscopy, intestinal endoscopy, colonoscopy, capsule endoscopy, laparoscopy, interventional diagnosis and therapy, as well as advances in technology. Emphasis is placed on the clinical practice of treating gastrointestinal diseases with or under endoscopy.

We encourage authors to submit their manuscripts to *WJGE*. We will give priority to manuscripts that are supported by major national and international foundations and those that are of great clinical significance.

INDEXING/ABSTRACTING

World Journal of Gastrointestinal Endoscopy is now indexed in Emerging Sources Citation Index (Web of Science), PubMed, and PubMed Central.

FLYLEAF

I-III Editorial Board

EDITORS FOR THIS ISSUE

Responsible Assistant Editor: *Xiang Li*
Responsible Electronic Editor: *Ya-Jing Lu*
Proofing Editor-in-Chief: *Lian-Sheng Ma*

Responsible Science Editor: *Fang-Fang Ji*
Proofing Editorial Office Director: *Xiu-Xia Song*

NAME OF JOURNAL
World Journal of Gastrointestinal Endoscopy

ISSN
ISSN 1948-5190 (online)

LAUNCH DATE
October 15, 2009

FREQUENCY
Monthly

EDITORS-IN-CHIEF
Atsushi Imagawa, PhD, Director, Doctor, Department of Gastroenterology, Mitoyo General Hospital, Kan-onji, Kagawa 769-1695, Japan
Juan Manuel Herrerias Gutierrez, PhD, Academic Fellow, Chief Doctor, Professor, Unidad de Gestión Clínica de Aparato Digestivo, Hospital Universitario Virgen Macarena, Sevilla 41009, Spain

EDITORIAL BOARD MEMBERS
All editorial board members resources online at <http://www.wjnet.com>

www.wjnet.com/1948-5190/editorialboard.htm

EDITORIAL OFFICE
Xiu-Xia Song, Director
World Journal of Gastrointestinal Endoscopy
Baishideng Publishing Group Inc
7901 Stoneridge Drive, Suite 501, Pleasanton, CA 94588, USA
Telephone: +1-925-2238242
Fax: +1-925-2238243
E-mail: editorialoffice@wjnet.com
Help Desk: <http://www.fjgpublishing.com/helpdesk>
<http://www.wjnet.com>

PUBLISHER
Baishideng Publishing Group Inc
7901 Stoneridge Drive, Suite 501, Pleasanton, CA 94588, USA
Telephone: +1-925-2238242
Fax: +1-925-2238243
E-mail: bpgoffice@wjnet.com
Help Desk: <http://www.fjgpublishing.com/helpdesk>
<http://www.wjnet.com>

PUBLICATION DATE
October 16, 2017

COPYRIGHT
© 2017 Baishideng Publishing Group Inc. Articles published by this Open-Access journal are distributed under the terms of the Creative Commons Attribution Non-commercial License, which permits use, distribution, and reproduction in any medium, provided the original work is properly cited, the use is non commercial and is otherwise in compliance with the license.

SPECIAL STATEMENT
All articles published in journals owned by the Baishideng Publishing Group (BPG) represent the views and opinions of their authors, and not the views, opinions or policies of the BPG, except where otherwise explicitly indicated.

INSTRUCTIONS TO AUTHORS
<http://www.wjnet.com/bpg/gerinfo/204>

ONLINE SUBMISSION
<http://www.fjgpublishing.com>

Endoscopic ultrasound elastography for solid pancreatic lesions

Tanyaporn Chantarojanasiri, Pradermchai Kongkam

Tanyaporn Chantarojanasiri, Department of Medicine, Police General Hospital, Patumwan, Bangkok 10400, Thailand

Pradermchai Kongkam, Gastrointestinal Endoscopy Excellent Center, Department of Medicine, Faculty of Medicine, Chulalongkorn University and King Chulalongkorn Memorial Hospital, Thai Red Cross Society, Bangkok 10330, Thailand

Author contributions: Both authors contributed to this paper.

Conflict-of-interest statement: The authors revealed no conflict of interest in relation to this review.

Open-Access: This article is an open-access article which was selected by an in-house editor and fully peer-reviewed by external reviewers. It is distributed in accordance with the Creative Commons Attribution Non Commercial (CC BY-NC 4.0) license, which permits others to distribute, remix, adapt, build upon this work non-commercially, and license their derivative works on different terms, provided the original work is properly cited and the use is non-commercial. See: <http://creativecommons.org/licenses/by-nc/4.0/>

Manuscript source: Invited manuscript

Correspondence to: Pradermchai Kongkam, MD, Gastrointestinal Endoscopy Excellent Center, Department of Medicine, Faculty of Medicine, Chulalongkorn University and King Chulalongkorn Memorial Hospital, Thai Red Cross Society, 1873, Rama 4 Road, Patumwan, Bangkok 10330, Thailand. pradermchai.k@chula.ac.th
Telephone: +66-2-2564356
Fax: +66-2-6524219

Received: January 30, 2017

Peer-review started: February 12, 2017

First decision: March 27, 2017

Revised: August 28, 2017

Accepted: September 4, 2017

Article in press: September 5, 2017

Published online: October 16, 2017

solid pancreatic lesions (SPL). This technology has been previously used for measuring the stiffness of various organs based on a principle of "harder the lesions, higher chance for malignancy". Two elastography techniques; strain and shear wave elastography, are available. For endoscopic ultrasound (EUS), only the former is existing. To interpret results of EUS elastography for SPL, 3 methods are used: (1) pattern recognition; (2) strain ratio; and (3) strain histogram. Based on results of existing studies, these 3 techniques provide high sensitivity but low to moderate specificity and accuracy rate. This review will summarize all available information in order to update current situation of using elastography for an evaluation of SPLs to readers.

Key words: Elastography; Endoscopic ultrasound; Solid pancreatic lesions; Pancreatic cancer; Chronic pancreatitis

© **The Author(s) 2017.** Published by Baishideng Publishing Group Inc. All rights reserved.

Core tip: Elastography is a technology that can measure tissue stiffness. Endoscopic ultrasound (EUS) elastography has been increasingly used for an evaluation of solid pancreatic lesions (SPL). Several interpretation methods of EUS elastography for this purpose have been described in many previous studies. This review focuses on how to read and interpret findings of EUS elastography obtained from SPL. Readers should be competent for applying EUS elastography for diagnosing SPL after finishing reading the review.

Chantarojanasiri T, Kongkam P. Endoscopic ultrasound elastography for solid pancreatic lesions. *World J Gastrointest Endosc* 2017; 9(10): 506-513 Available from: URL: <http://www.wjgnet.com/1948-5190/full/v9/i10/506.htm> DOI: <http://dx.doi.org/10.4253/wjge.v9.i10.506>

Abstract

Elastography is one of technologies assisting diagnosis of

INTRODUCTION

The diagnosis of solid pancreatic lesions (SPL) is a

challenging clinical problem. Endoscopic ultrasound-guided fine needle aspiration (EUS-FNA) is the most commonly used diagnostic method. It has high specificity but moderate sensitivity. Due to the aggressiveness and poor outcomes of pancreatic cancer, several methods such as elastography or contrast enhancement have then been developed to assist in the diagnosis of SPL. Certainly, these software technologies cannot replace EUS-FNA because they are not pathological diagnostic tools, but they can help clinicians in many clinical scenarios such as in lesions with remarkably low EUS-FNA diagnostic yield including mass-forming chronic pancreatitis. Several previous studies have shown various efficacy values for these adjunctive technologies in their results. Elastography is one of these current assisting technologies diagnosing SPL. This technology measures the stiffness of the target lesion. In this review, the results of EUS elastography in the evaluation of SPL will be summarized.

This review summarizes characteristic findings of each SPL by EUS elastography. We searched the PubMed database for English-language journals with human studies published between 1988 and 2016. The following keywords were used in combination with EUS: Elastography, pancreas, and solid lesions. References to those identified articles were also examined for potentially relevant studies.

HISTORY OF ELASTOGRAPHY

Since 1988, the concepts of tissue deformability and elasticity of solid tumor has been described^[1]. In 1991, tissue elasticity measurements were made by evaluation of the elastic modulus after applying a pressure (Figure 1); hence, the term "elastography" was first reported^[2]. This led to the development of real-time imaging and the combination of elastography imaging with B mode imaging using a combined autocorrelation method in 2001^[3]. Since then, elastography has been applied to the diagnosis of solid tumors of various organs such as breast, thyroids, lymph nodes and liver. In 2006, elastography for SPL was firstly reported^[4]. The interpretation of elastography findings from SPL have been developed and applied to clinical management.

TYPES OF ELASTOGRAPHY

Elastography is classified into two categories based on different mechanical properties: Strain and shear wave elastography. The former evaluates tissue stiffness by measuring tissue distortion after applying pressure and the latter assess tissue stiffness by measuring tissue distortion after applying the acoustic radial force impulse^[5]. However, only strain elastography is available for EUS.

STRAIN ELASTOGRAPHY MEASUREMENT METHODS

Strain elastography evaluates tissue stiffness *via*

the displacement caused by manual compression or cardiovascular pulsation^[6]. Larger strain or tissue displacement values represent softer tissue (Figure 2). The degree of strain-the relative indicator-can be displayed *via* three methods^[6].

Pattern recognition

This method is to display as colors, with the green color as the mean stiffness, blue color represents harder tissue and red color represents softer tissue. This is the only method considered qualitative method whereas following methods are quantitative ones.

Strain ratio

This method is to display as gray scale image and compare strain ratio (SR) of area of interest with reference area.

Strain histogram

Pattern recognition: Color pattern analysis of elastography was first described in transcutaneous ultrasound elastography of the breast^[7]. The EUS elastography pattern in pancreatic lesion was first described by Giovannini (Figure 3)^[4] with 100% sensitivity but only 67% specificity in differential diagnosis of benign and malignant SPL. The same author later classified the previous 5-scale elastic score into 3 scores: A, B and C, representing benign, indeterminate, and malignant lesions, respectively^[8]. This classification has 92.3% sensitivity and 80% specificity in differential diagnosis between benign and malignant SPL. Reports of different pattern analyses results in different clinical efficacy have been published. Another report by Janssen *et al*^[9] classified color patterns into 3 types: Type 1 with homogeneous pattern, type 2 with 2 or 3 colors, and type 3 with a honeycomb pattern. In this report, however, the use of elastography in differential diagnosis between benign and malignant lesions was disappointing. Another study done by Iglesias-Garcia^[10], classified the elastography into 4 patterns with 100% sensitivity and 85.5% specificity in the diagnosis of malignant SPL. The comparison of each report as well as sensitivity and specificity is shown in Table 1.

SR: SR compares the strain between the target area and other reference areas to provide more objective qualitative data^[11]. In breast lesions, the strain of the lesion is compared to the strain of the surrounding fat tissue. Many studies use SR to differentially diagnose pancreatic carcinoma and chronic pancreatitis^[11-14]. In some studies, the strain of the area surrounding the pancreas was used as the baseline compared with the strain of the lesion^[11,15]. The peripancreatic surrounding the soft tissue was used as the baseline in other studies^[12,13]. Moreover, according to the phantom study, the depth of the reference area has a significant impact on the evaluation of the SR^[16]. The area of selection and cut-off point in each study are demonstrated in Table 2. Studies have correlated SR and chronic pancreatitis.

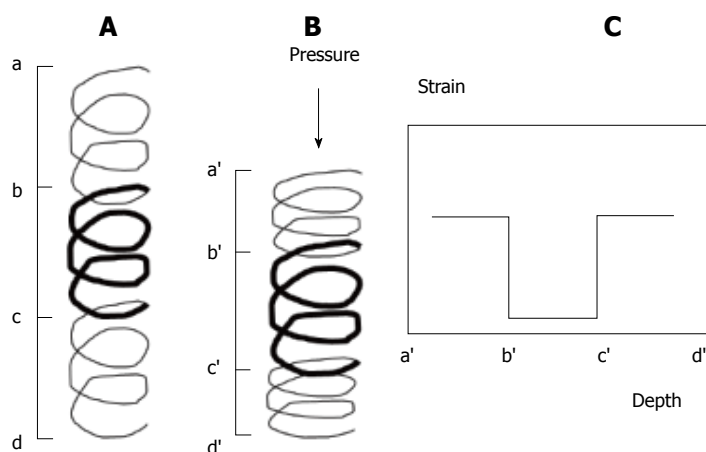


Figure 1 The principle of strain elastography is illustrated by coil spring appearance. A: After applying pressure, more deformation is demonstrated in tissue with higher elasticity; B: The strain on each tissue depends on the tissue stiffness; C: Higher strain is seen in softer tissue after compression (Adapted from Ophir^[2]).

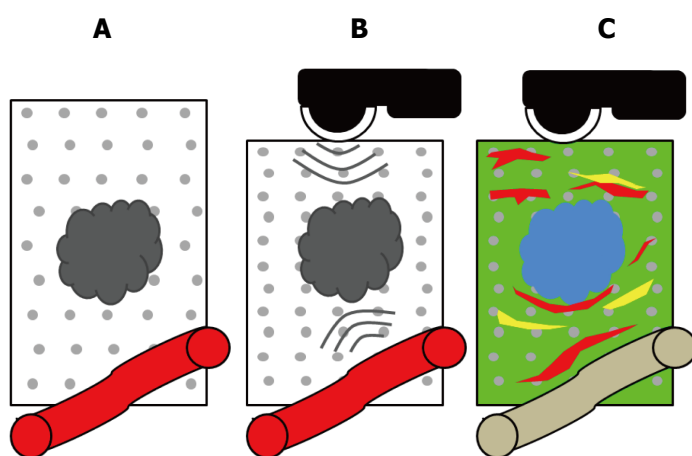


Figure 2 The principle of endoscopic ultrasound elastography for solid pancreatic lesions. A: Pancreatic carcinoma has more stiffness than normal pancreas; B: The strain elastography measured the degree of displacement after applying manual pressure or vascular pulsation; C: The degree of displacement is represented as colors: Green is the average stiffness, blue is stiffer tissue, and red is softer tissue.

Table 1 Results of 4 large studies using pattern recognition of elastography for diagnosis of solid pancreatic lesions

Author	Giovannini <i>et al</i> ^[4] , 2006		Giovannini <i>et al</i> ^[8] , 2009		Janssen <i>et al</i> ^[9] , 2007			Iglesias-Garcia <i>et al</i> ^[10] , 2009	
	Elastic score /pattern	Interpretation	Score	Interpretation	Type	Color	Interpretation	Pattern	Interpretation
Score and interpretation	Distortion for entire low echo area	Normal pancreas	A (elastic score 1 and 2)	Benign	Homogeneous	A = blue	B = normal pancreas	Homogeneous green	Normal pancreas
	No distortion on low echo area even for a part	Fibrosis, chronic pancreatitis						Heterogenous green	Inflammatory pancreas
	Distortion at the edge of low echo area, even for a part	Small adenocarcinoma	B (elastic score 3)	Indeterminate	2 or 3 colors	B = green/yellow		Homogeneous blue	Ductal pancreatic adenocarcinoma
	No distortion for entire low echo area	Endocrine tumor	C (elastic score 4 and 5)	Malignant	Heterogeneous	C = red	A/B = chronic pancreatitis and neoplasia	Heterogeneous blue	Neuroendocrine tumor
	No distortion on low echo area and surrounding	Advanced adenocarcinoma							
Sensitivity	100		92.3		65.9 (chronic pancreatitis), 93.8 (neoplasia)			100	
Specificity	67		80		56.9 (chronic pancreatitis), 65.4 (neoplasia)			85.5	
Accuracy	NA		89.2		60.2 (chronic pancreatitis), 73.5 (neoplasia)			94	

NA: Not available.



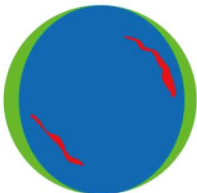


Elastic score	Elastography	Pattern	Condition
1		Distortion for entire low echo area	Normal pancreas
2		No distortion on low echo area even for a part	Fibrosis, chronic pancreatitis
3		Distortion at the edge of low echo area, even for a part	Small adenocarcinoma
4		No distortion for entire low echo area	Endocrine tumor
5		No distortion on low echo area and surrounding	Advanced adenocarcinoma

Figure 3 Classification of elastography findings proposed by Giovannini^[4].

Iglesias-Garcia reported a cut-off of 2.25 for the diagnosis of chronic pancreatitis with a sensitivity of 91.2% and a specificity of 91% using the surrounding soft tissue as a reference^[17]. Another study reported the correlation of SR and the presence of pancreatic exocrine insufficiency (PEI) with 87.0% probability of PEI in those with SR higher than 4.5 compared with 16.3% probability of PEI in those with SR lower than 4.5^[18]. In this study, the normal surrounding gut wall was used as the reference. Iglesias-Garcias reported the mean elastic value to be 0.47%, 0.23%, 0.02% and 0.01% for normal pancreas, chronic pancreatitis, pancreatic cancer, and endocrine tumor, respectively^[14]. Another report from South Korea demonstrated a mean elastic value of 0.53% for the normal pancreas and 0.02% for pancreatic cancer^[19].

Many studies are based on the SR method, but there is no standardization for the reference area yet^[5]. Moreover, the distance of the reference area from the ultrasound probe significantly impacted the SR measurements^[16]. These two factors significantly

impacted the reliability of the SR methods as a diagnostic test for SPL.

Strain histogram

The strain histogram is another type of the quantitative image analysis. To analyze the strain histogram, the color image of the elastography is converted into the gray scale (value) of 256 tones. It ranged from 0 to 255 with 0 representing the blue area (hard) and 255 representing the red area (soft) (Figure 4). The distribution of the gray scale is then calculated into various parameters as shown (Table 3). In some reports, the histograms were performed separately from the individual red/green/blue color^[20]. The correlations of the parameters with the degree of pancreatic fibrosis have been published^[21]. With increasing fibrosis, the mean and standard deviation decrease, while skewness and kurtosis increase. On the other hand, the histogram could be analyzed using the neural network analysis. The correlation between a cut-off mean level > 175 in pancreatic carcinoma

Table 2 Results of studies using strain ratio of elastography for an evaluation of solid pancreatic lesions

Ref.	Diseases of comparison (n)	Reference area	Cut off point	Sensitivity	Specificity
Iglesia-Garcia <i>et al</i> ^[14]	PC (49) vs CP (27) PC (49) vs PNET (6)	Soft tissue	6.04 26.63	100 100	96.3 87.8
Itokawa <i>et al</i> ^[11]	PC (72), PNET (9), CP (20), normal pancreas (8)	Normal pancreas	23.66 in MFP vs 39.08 in PC		
Dawwas <i>et al</i> ^[12]	Malignant (87): (PC, PNET, metastatic cancer) And benign (17) (pancreatitis)	Soft tissue	4.65	100	16.7
Kongkam <i>et al</i> ^[13]	PC (23), PNET (5), Meatastasis (1), CP (2), AIP (3), other (4)	Soft tissue	3.17 6.04	86.2 75.9	66.7 77.8

PC: Pancreatic cancer; PNET: Pancreatic neuroendocrine tumor; CP: Chronic pancreatitis; AIP: Autoimmune pancreatitis.

Table 3 The histogram parameters^[5,21,45]

Images	Parameters	Information	Interpretation
Gray scale images	Mean	Mean of the gray levels	Higher mean value indicates softer tissue
	Standard deviation	Standard deviation of the gray levels	Higher value indicating heterogeneous hardness
	ASM	Measure of the homogeneity on the gray scale image	
	Contrast	Measure of local gray level variation on the gray scale image	
	Correlation	Measure of gray level linear dependence on the gray scale image	
	Entropy	Measure of the randomness of gray level distribution	
	IDM	Measure of the homogeneity on the gray scale image	
	Skewness	Measure of the asymmetry of the gray level distribution	Higher value indicating higher or lower hardness
	Kurtosis	Measure of the “peakedness” of the gray level distribution	Higher value indicating concentration of a specific hardness
Black and white image	% area	Percentage of the white area (= hard area)	
	Mean of	Complex ratio of the shape of the white area (= hard area) and	
	Complexity	is calculated as periphery ² /area of the white area	

had a sensitivity of 91.4%-93.4% and a specificity of 66%-87.9%^[22,23]. Another report analyzed the histogram by comparing the histogram of the tumor over the adjacent part of the pancreas^[24]. The strain histogram's ratio with cut-off value of 1.15 indicated pancreatic malignancy with 98% sensitivity, 58% specificity, and 69% accuracy.

CLINICAL IMPLICATIONS

Pancreatic adenocarcinoma vs mass-forming chronic pancreatitis

Pancreatic adenocarcinoma is the most common type of pancreatic tumor, and it is characterized by many desmoplastic reactions^[25]. Increased amounts of extracellular matrix including type I and type V collagen and fibronectin are found similar to those found in alcoholic chronic pancreatitis and tumor-induced chronic pancreatitis^[26]. The differential diagnosis between pancreatic adenocarcinoma and mass-forming pancreatitis-especially on the background of chronic pancreatitis-remains a challenging problem. It is well known that the incidence of pancreatic adenocarcinoma is higher in patients with chronic pancreatitis^[27]. Moreover, some features of chronic pancreatitis, such as calcification, may hinder the detection of pancreatic cancer^[28]. Moreover, EUS-FNA of the pancreatic cancer (standard method for tissue acquisition from SPL) results in only 50%-73.9%

sensitivity but with 73.7%-100% specificity in the presence of chronic pancreatitis^[29-31]. In elastography, pancreatic adenocarcinoma usually manifests as a hard tumor with a predominate blue color pattern (Table 1 and Figure 5). It has a higher SR than mass-forming chronic pancreatitis. Another single report compared pancreatic adenocarcinoma and autoimmune pancreatitis. This demonstrated that in autoimmune pancreatitis the stiffness area not only forms the mass area but also the surrounding pancreatic tissue^[32].

Pancreatic neuroendocrine tumor

Pancreatic neuroendocrine tumors (PNETs) are a rare type of solid pancreatic tumor that are characterized histologically by tumor cells arranged in solid nest, trabecular, or gland like formation surrounded by thin vascular stroma^[33]. The elastography pattern of PNET was described as homogeneous blue and heterogeneous blue by Giovannini^[4] and Iglesias-Garcia^[10], respectively. In one prospective study that included 6 patients with PNET, the SR of PNET is 56.73-higher than the 17.41 SR seen in pancreatic adenocarcinoma^[17].

Solid pseudopapillary neoplasm

Elastography studies in solid pseudopapillary neoplasm (SPN) are rare. Only one study with 1 SPN case was found. It had a SR near 15^[17].

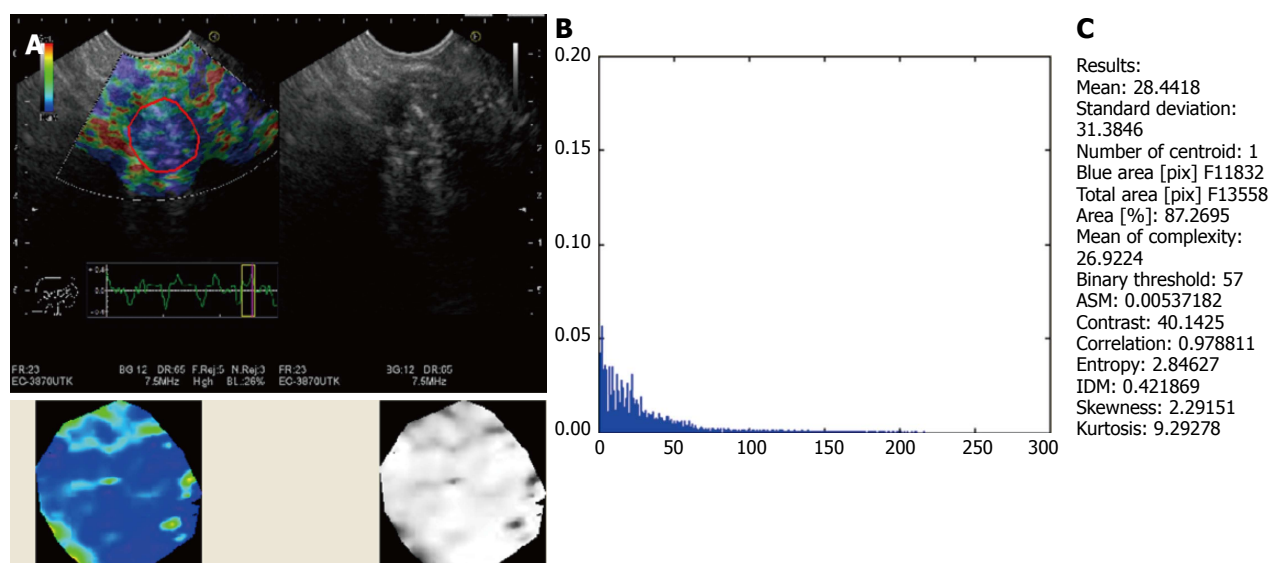


Figure 4 Histogram analysis using MATLABver 1.6.7. A and B: The color image of the elastography is converted into the gray scale (value) of 256 tones ranging from 0 to 255: 0 represents the blue area (hard) and 255 represents the red area (soft); C: The distribution of the gray scale is presented as a histogram from which the parameters are calculated.

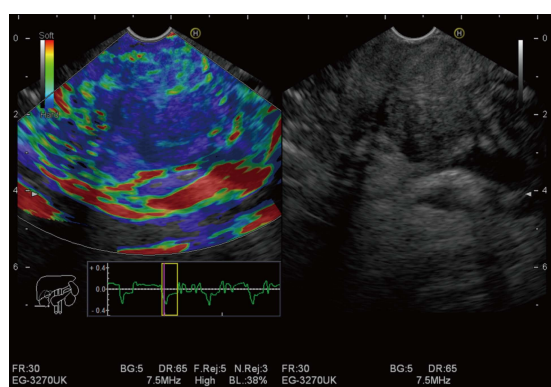


Figure 5 Endoscopic ultrasound elastography of pancreatic adenocarcinoma. The color pattern showed predominant blue color pattern without distortion of surrounding area.

OTHER UNCOMMON TUMORS

For pancreatic acinar cell carcinoma, there are limited reports of EUS elastography. Only one report of elastography in pancreatic acinar cell carcinoma has been published^[34]. In this report, there was no specific pattern of elastography, and the pattern varied according to the acinar cell tumor pathologic phenotype. The data for more uncommon types of pancreatic cancers such as anaplastic cell carcinoma and adenosquamous cell carcinoma have not yet been reported.

Chronic pancreatitis

Elastography has been used in both the diagnosis of chronic pancreatitis and as a predictor of post-operative pancreatic fistula. Despite the usefulness of EUS in the diagnosis of pancreatic lesions, there are only limited data in EUS elastography studies in chronic pancreatitis. Many studies of elastography in chronic pancreatitis

using transabdominal ultrasound with shear wave elastography for the detection of pancreatic fibrosis both in chronic pancreatitis and tumor-related fibrosis have been reported^[35-38]. Apart from the transabdominal ultrasonography, intraoperative ultrasound elastography has been published. This demonstrated correlation between “soft pancreas” and the development of a post-operative pancreatic fistula^[39,40].

In EUS studies, one prospective study demonstrated a higher SR in chronic pancreatitis with 91.2% sensitivity, 91.0% specificity, and 91.1% accuracy with a cut-off point of 2.25^[17]. In this study, the SR also varied across groups according to Rosemond criteria for the diagnosis of chronic pancreatitis with a higher SR up to 8.12 in cases that fulfilled all criteria of chronic pancreatitis. Moreover, in patients with chronic pancreatitis, elastography with higher SR was seen in those with evidence of pancreatic enzyme insufficiency (SR 4.89 vs 2.99)^[18]. This finding was consistent with another study demonstrating higher stiffness in more advanced pancreatic fibrosis using EUS elastography with histogram analysis^[21]. A retrospective study of EUS elastography using histograms for analysis also demonstrate the correlation of mean value with the stage of chronic pancreatitis *via* the Rosemont criteria. This used cutoffs of 90.1 ± 19.3 , 73.2 ± 10.6 , 63.7 ± 14.2 , and 56.1 ± 13.6 , in normal pancreas, indeterminate for chronic pancreatitis, suggestive of chronic pancreatitis, and consistent with chronic pancreatitis, respectively^[41].

Aging can cause several changes similar to early chronic pancreatitis^[42]. A study using EUS also demonstrated abnormalities similar to chronic pancreatitis in elderly subjects without clinical chronic pancreatitis—particularly after the age of 60^[43]. Elastography studies in aging populations also showed increased pancreatic stiffness with age demonstrated by both EUS^[44] and transabdominal ultrasonography^[45]. These changes

become significant after age 40 to 60^[44,45]. In one study, the mean histogram below 50 was more suggestive of chronic pancreatitis than usual aging changes^[44].

COULD EUS ELASTOGRAPHY REPLACED TISSUE DIAGNOSIS?

While many studies have demonstrated excellent efficacy of elastography in the diagnosis of SPL, the value of elastography in cases with negative EUS FNA remains inconsistently demonstrated in all studies. Moreover, the method of image analysis is not yet standardized. Most reports demonstrated high sensitivity but low specificity, and the interpretation was performed by a center with many experienced elastographers. Hence, elastography cannot replace EUS-FNA for diagnosis^[46].

CONCLUSION

In summary, EUS elastography is an improvement in the differential diagnosis between benign and malignant SPL in many studies. The main role of elastography in SPL is as an adjunct with other modalities in making diagnoses. Especially in chronic pancreatitis, EUS still has a promising role in both the diagnosis of early chronic pancreatitis and the prediction of complication. However, the overlapping of early chronic pancreatitis and aging changes makes the decision more difficult.

REFERENCES

- 1 Ueno E, Tohno E, Soeda S, Asaoka Y, Itoh K, Bamber JC, Blaszczyk M, Davey J, Mckinna JA. Dynamic tests in real-time breast echography. *Ultrasound Med Biol* 1988; **14** Suppl 1: 53-57 [PMID: 3055603]
- 2 Ophir J, Céspedes I, Ponnekanti H, Yazdi Y, Li X. Elastography: a quantitative method for imaging the elasticity of biological tissues. *Ultrasound Imaging* 1991; **13**: 111-134 [PMID: 1858217]
- 3 Shiina T, Nitta N, Ueno E, Bamber JC. Real time tissue elasticity imaging using the combined autocorrelation method. *J Med Ultrason* (2001) 2002; **29**: 119-128 [PMID: 27277886 DOI: 10.1007/BF02481234]
- 4 Giovannini M, Hookey LC, Bories E, Pesenti C, Monges G, Delpero JR. Endoscopic ultrasound elastography: the first step towards virtual biopsy? Preliminary results in 49 patients. *Endoscopy* 2006; **38**: 344-348 [PMID: 16680632 DOI: 10.1055/s-2006-925158]
- 5 Hirooka Y, Kuwahara T, Irisawa A, Itokawa F, Uchida H, Sasahira N, Kawada N, Itoh Y, Shiina T. JSUM ultrasound elastography practice guidelines: pancreas. *J Med Ultrason* (2001) 2015; **42**: 151-174 [PMID: 26576568 DOI: 10.1007/s10396-014-0571-7]
- 6 Shiina T. JSUM ultrasound elastography practice guidelines: basics and terminology. *J Med Ultrason* (2001) 2013; **40**: 309-323 [PMID: 27277449 DOI: 10.1007/s10396-013-0490-z]
- 7 Itoh A, Ueno E, Tohno E, Kamma H, Takahashi H, Shiina T, Yamakawa M, Matsumura T. Breast disease: clinical application of US elastography for diagnosis. *Radiology* 2006; **239**: 341-350 [PMID: 16484352 DOI: 10.1148/radiol.2391041676]
- 8 Giovannini M, Thomas B, Erwan B, Christian P, Fabrice C, Benjamin E, Geneviève M, Paolo A, Pierre D, Robert Y, Walter S, Hanz S, Carl S, Christoph D, Pierre E, Jean-Luc VL, Jacques D, Peter Y, Andrian S. Endoscopic ultrasound elastography for evaluation of lymph nodes and pancreatic masses: a multicenter study. *World J Gastroenterol* 2009; **15**: 1587-1593 [PMID: 19340900 DOI: 10.3748/wjg.v15.i13.1587]
- 9 Janssen J, Schlörer E, Greiner L. EUS elastography of the pancreas: feasibility and pattern description of the normal pancreas, chronic pancreatitis, and focal pancreatic lesions. *Gastrointest Endosc* 2007; **65**: 971-978 [PMID: 17531630 DOI: 10.1016/j.gie.2006.12.057]
- 10 Iglesias-Garcia J, Larino-Noia J, Abdulkader I, Forteza J, Dominguez-Munoz JE. EUS elastography for the characterization of solid pancreatic masses. *Gastrointest Endosc* 2009; **70**: 1101-1108 [PMID: 19647248 DOI: 10.1016/j.gie.2009.05.011]
- 11 Itokawa F, Itoi T, Sofuni A, Kurihara T, Tsuchiya T, Ishii K, Tsuji S, Ikeuchi N, Umeda J, Tanaka R, Yokoyama N, Moriyasu F, Kasuya K, Nagao T, Kamisawa T, Tsuchida A. EUS elastography combined with the strain ratio of tissue elasticity for diagnosis of solid pancreatic masses. *J Gastroenterol* 2011; **46**: 843-853 [PMID: 21505859 DOI: 10.1007/s00535-011-0399-5]
- 12 Dawwas MF, Taha H, Leeds JS, Nayar MK, Oppong KW. Diagnostic accuracy of quantitative EUS elastography for discriminating malignant from benign solid pancreatic masses: a prospective, single-center study. *Gastrointest Endosc* 2012; **76**: 953-961 [PMID: 22854060 DOI: 10.1016/j.gie.2012.05.034]
- 13 Kongkam P, Lakananurak N, Navichare P, Chantarojanasiri T, Aye K, Rittitid W, Kritisin K, Angsuwatcharakon P, Aniw S, Pittayanon R, Sampatanukul P, Treeprasertsuk S, Kullavanijaya P, Rerknimitr R. Combination of EUS-FNA and elastography (strain ratio) to exclude malignant solid pancreatic lesions: A prospective single-blinded study. *J Gastroenterol Hepatol* 2015; **30**: 1683-1689 [PMID: 26238152 DOI: 10.1111/jgh.13067]
- 14 Iglesias-Garcia J, Larino-Noia J, Abdulkader I, Forteza J, Dominguez-Munoz JE. Quantitative endoscopic ultrasound elastography: an accurate method for the differentiation of solid pancreatic masses. *Gastroenterology* 2010; **139**: 1172-1180 [PMID: 20600020 DOI: 10.1053/j.gastro.2010.06.059]
- 15 Kawada N, Tanaka S, Uehara H, Takakura R, Katayama K, Fukuda J, Matsuno N, Takenaka A, Ishikawa O. Feasibility of second-generation transabdominal ultrasound-elastography to evaluate solid pancreatic tumors: preliminary report of 36 cases. *Pancreas* 2012; **41**: 978-980 [PMID: 22781915 DOI: 10.1097/MPA.0b013e3182499b84]
- 16 Havre RF, Waage JR, Gilja OH, Odegaard S, Nesje LB. Real-Time Elastography: Strain Ratio Measurements Are Influenced by the Position of the Reference Area. *Ultraschall Med* 2011; Epub ahead of print [PMID: 21667433 DOI: 10.1055/s-0031-1273247]
- 17 Iglesias-Garcia J, Domínguez-Muñoz JE, Castiñeira-Alvarinho M, Luaces-Regueira M, Lariño-Noia J. Quantitative elastography associated with endoscopic ultrasound for the diagnosis of chronic pancreatitis. *Endoscopy* 2013; **45**: 781-788 [PMID: 24019131 DOI: 10.1055/s-0033-1344614]
- 18 Domínguez-Muñoz JE, Iglesias-Garcia J, Castiñeira Alvarinho M, Luaces Regueira M, Lariño-Noia J. EUS elastography to predict pancreatic exocrine insufficiency in patients with chronic pancreatitis. *Gastrointest Endosc* 2015; **81**: 136-142 [PMID: 25088920 DOI: 10.1016/j.gie.2014.06.040]
- 19 Lee TH, Cho YD, Cha SW, Cho JY, Jang JY, Jeong SW, Choi HJ, Moon JH. Endoscopic ultrasound elastography for the pancreas in Korea: a preliminary single center study. *Clin Endosc* 2013; **46**: 172-177 [PMID: 23614128 DOI: 10.5946/ce.2013.46.2.172]
- 20 Schrader H, Wiese M, Ellrichmann M, Belyaev O, Uhl W, Tannapfel A, Schmidt W, Meier J. Diagnostic value of quantitative EUS elastography for malignant pancreatic tumors: relationship with pancreatic fibrosis. *Ultraschall Med* 2012; **33**: E196-E201 [PMID: 21630184 DOI: 10.1055/s-0031-1273256]
- 21 Itoh Y, Itoh A, Kawashima H, Ohno E, Nakamura Y, Hiramatsu T, Sugimoto H, Sumi H, Hayashi D, Kuwahara T, Morishima T, Funasaka K, Nakamura M, Miyahara R, Ohmiya N, Katano Y, Ishigami M, Goto H, Hirooka Y. Quantitative analysis of diagnosing pancreatic fibrosis using EUS-elastography (comparison with surgical specimens). *J Gastroenterol* 2014; **49**: 1183-1192 [PMID: 24026103 DOI: 10.1007/s00535-013-0880-4]
- 22 Săftoiu A, Vilmann P, Gorunescu F, Gheonea DI, Gorunescu M, Ciurea T, Popescu GL, Iordache A, Hassan H, Iordache S. Neural network analysis of dynamic sequences of EUS elastography used for

- the differential diagnosis of chronic pancreatitis and pancreatic cancer. *Gastrointest Endosc* 2008; **68**: 1086-1094 [PMID: 18656186 DOI: 10.1016/j.gie.2008.04.031]
- 23 **Săftoiu A**, Vilman P, Gorunescu F, Janssen J, Hocke M, Larsen M, Iglesias-Garcia J, Arcidiacono P, Will U, Giovannini M, Dietrich C, Havre R, Gheorghe C, McKay C, Gheonea DI, Ciurea T; European EUS Elastography Multicentric Study Group. Accuracy of endoscopic ultrasound elastography used for differential diagnosis of focal pancreatic masses: a multicenter study. *Endoscopy* 2011; **43**: 596-603 [PMID: 21437851 DOI: 10.1055/s-0030-1256314]
 - 24 **Opačić D**, Rustemović N, Kalauz M, Markoš P, Ostojić Z, Majerović M, Ledinsky I, Višnjić A, Krznarić J, Opačić M. Endoscopic ultrasound elastography strain histograms in the evaluation of patients with pancreatic masses. *World J Gastroenterol* 2015; **21**: 4014-4019 [PMID: 25852289 DOI: 10.3748/wjg.v21.i13.4014]
 - 25 **Pandol S**, Edderkaoui M, Gukovsky I, Lugea A, Gukovskaya A. Desmoplasia of pancreatic ductal adenocarcinoma. *Clin Gastroenterol Hepatol* 2009; **7**: S44-S47 [PMID: 19896098 DOI: 10.1016/j.cgh.2009.07.039]
 - 26 **Imamura T**, Iguchi H, Manabe T, Ohshio G, Yoshimura T, Wang ZH, Suwa H, Ishigami S, Imamura M. Quantitative analysis of collagen and collagen subtypes I, III, and V in human pancreatic cancer, tumor-associated chronic pancreatitis, and alcoholic chronic pancreatitis. *Pancreas* 1995; **11**: 357-364 [PMID: 8532652]
 - 27 **Raimondi S**, Lowenfels AB, Morselli-Labate AM, Maisonneuve P, Pezzilli R. Pancreatic cancer in chronic pancreatitis; aetiology, incidence, and early detection. *Best Pract Res Clin Gastroenterol* 2010; **24**: 349-358 [PMID: 20510834 DOI: 10.1016/j.bpg.2010.02.007]
 - 28 **Bang JY**, Varadarajulu S. Neoplasia in chronic pancreatitis: how to maximize the yield of endoscopic ultrasound-guided fine needle aspiration. *Clin Endosc* 2014; **47**: 420-424 [PMID: 25325001 DOI: 10.5946/ce.2014.47.5.420]
 - 29 **Varadarajulu S**, Tamhane A, Eloubeidi MA. Yield of EUS-guided FNA of pancreatic masses in the presence or the absence of chronic pancreatitis. *Gastrointest Endosc* 2005; **62**: 728-736; quiz 751, 753 [PMID: 16246688 DOI: 10.1016/j.gie.2005.06.051]
 - 30 **Iordache S**, Săftoiu A, Cazacu S, Gheonea DI, Dumitrescu D, Popescu C, Ciurea T. Endoscopic ultrasound approach of pancreatic cancer in chronic pancreatitis patients in a tertiary referral centre. *J Gastrointest Liver Dis* 2008; **17**: 279-284 [PMID: 18836620]
 - 31 **Fritscher-Ravens A**, Brand L, Knöfel WT, Bobrowski C, Topalidis T, Thonke F, de Werth A, Soehendra N. Comparison of endoscopic ultrasound-guided fine needle aspiration for focal pancreatic lesions in patients with normal parenchyma and chronic pancreatitis. *Am J Gastroenterol* 2002; **97**: 2768-2775 [PMID: 12425546 DOI: 10.1111/j.1572-0241.2002.07020.x]
 - 32 **Dietrich CF**, Hirche TO, Ott M, Ignee A. Real-time tissue elastography in the diagnosis of autoimmune pancreatitis. *Endoscopy* 2009; **41**: 718-720 [PMID: 19618344 DOI: 10.1055/s-0029-1214866]
 - 33 **Kasajima A**, Yazdani S, Sasano H. Pathology diagnosis of pancreatic neuroendocrine tumors. *J Hepatobiliary Pancreat Sci* 2015; **22**: 586-593 [PMID: 25641911 DOI: 10.1002/jhbp.208]
 - 34 **Chantarojanasiri T**, Hirooka Y, Kawashima H, Ohno E, Yamamura T, Funasaka K, Nakamura M, Miyahara R, Ishigami M, Watanabe O, Nakaguro M, Shimoyama Y, Nakamura S, Goto H. Endoscopic ultrasound in the diagnosis of acinar cell carcinoma of the pancreas: contrast-enhanced endoscopic ultrasound, endoscopic ultrasound elastography, and pathological correlation. *Endosc Int Open* 2016; **4**: E1223-E1226 [PMID: 27853750 DOI: 10.1055/s-0042-110096]
 - 35 **Yashima Y**, Sasahira N, Isayama H, Kogure H, Ikeda H, Hirano K, Mizuno S, Yagioka H, Kawakubo K, Sasaki T, Nakai Y, Tada M, Yoshida H, Omata M, Koike K. Acoustic radiation force impulse elastography for noninvasive assessment of chronic pancreatitis. *J Gastroenterol* 2012; **47**: 427-432 [PMID: 22065162 DOI: 10.1007/s00535-011-0491-x]
 - 36 **Kuwahara T**, Hirooka Y, Kawashima H, Ohno E, Sugimoto H, Hayashi D, Morishima T, Kawai M, Suhara H, Takeyama T, Yamamura T, Funasaka K, Nakamura M, Miyahara R, Watanabe O, Ishigami M, Shimoyama Y, Nakamura S, Hashimoto S, Goto H. Quantitative evaluation of pancreatic tumor fibrosis using shear wave elastography. *Pancreatol* 2016; **16**: 1063-1068 [PMID: 27692969 DOI: 10.1016/j.pan.2016.09.012]
 - 37 **Llamoza-Torres CJ**, Fuentes-Pardo M, Álvarez-Higueras FJ, Alberca-de-Las-Parras F, Carballo-Álvarez F. Usefulness of percutaneous elastography by acoustic radiation force impulse for the non-invasive diagnosis of chronic pancreatitis. *Rev Esp Enferm Dig* 2016; **108**: 450-456 [PMID: 27459032 DOI: 10.17235/reed.2016.4103/2015]
 - 38 **Goertz RS**, Schuderer J, Strobel D, Pfeifer L, Neurath MF, Wildner D. Acoustic radiation force impulse shear wave elastography (ARFI) of acute and chronic pancreatitis and pancreatic tumor. *Eur J Radiol* 2016; **85**: 2211-2216 [PMID: 27842669 DOI: 10.1016/j.ejrad.2016.10.019]
 - 39 **Hatano M**, Watanabe J, Kushiata F, Tohyama T, Kuroda T, Koizumi M, Kumagi T, Hisano Y, Sugita A, Takada Y. Quantification of pancreatic stiffness on intraoperative ultrasound elastography and evaluation of its relationship with postoperative pancreatic fistula. *Int Surg* 2015; **100**: 497-502 [PMID: 25785334 DOI: 10.9738/INTSURG-D-14-00040.1]
 - 40 **Harada N**, Ishizawa T, Inoue Y, Aoki T, Sakamoto Y, Hasegawa K, Sugawara Y, Tanaka M, Fukayama M, Kokudo N. Acoustic radiation force impulse imaging of the pancreas for estimation of pathologic fibrosis and risk of postoperative pancreatic fistula. *J Am Coll Surg* 2014; **219**: 887-894.e5 [PMID: 25262282 DOI: 10.1016/j.jamcollsurg.2014.07.940]
 - 41 **Kuwahara T**, Hirooka Y, Kawashima H, Ohno E, Ishikawa T, Kawai M, Suhara H, Takeyama T, Hashizume K, Koya T, Tanaka H, Sakai D, Yamamura T, Furukawa K, Funasaka K, Nakamura M, Miyahara R, Watanabe O, Ishigami M, Hashimoto S, Goto H. Quantitative diagnosis of chronic pancreatitis using EUS elastography. *J Gastroenterol* 2017; **52**: 868-874 [PMID: 27995327 DOI: 10.1007/s00535-016-1296-8]
 - 42 **Chantarojanasiri T**, Hirooka Y, Ratanachu-Ek T, Kawashima H, Ohno E, Goto H. Evolution of pancreas in aging: degenerative variation or early changes of disease? *J Med Ultrason* (2001) 2015; **42**: 177-183 [PMID: 26576570 DOI: 10.1007/s10396-014-0576-2]
 - 43 **Rajan E**, Clain JE, Levy MJ, Norton ID, Wang KK, Wiersma MJ, Vazquez-Sequeiros E, Nelson BJ, Jondal ML, Kendall RK, Harmsen WS, Zinsmeister AR. Age-related changes in the pancreas identified by EUS: a prospective evaluation. *Gastrointest Endosc* 2005; **61**: 401-406 [PMID: 15758911]
 - 44 **Janssen J**, Papavassiliou I. Effect of aging and diffuse chronic pancreatitis on pancreas elasticity evaluated using semiquantitative EUS elastography. *Ultraschall Med* 2014; **35**: 253-258 [PMID: 24327468 DOI: 10.1055/s-0033-1355767]
 - 45 **Chantarojanasiri T**, Hirooka Y, Kawashima H, Ohno E, Sugimoto H, Hayashi D, Kuwahara T, Yamamura T, Funasaka K, Nakamura M, Miyahara R, Ishigami M, Watanabe O, Hashimoto S, Goto H. Age-related changes in pancreatic elasticity: When should we be concerned about their effect on strain elastography? *Ultrasonics* 2016; **69**: 90-96 [PMID: 27070288 DOI: 10.1016/j.ultras.2016.03.018]
 - 46 **Deprez PH**. EUS elastography: is it replacing or supplementing tissue acquisition? *Gastrointest Endosc* 2013; **77**: 590-592 [PMID: 23498142 DOI: 10.1016/j.gie.2012.11.040]

P- Reviewer: Gilbert JL, Hu H, Zhu YL **S- Editor:** Ji FF
L- Editor: A **E- Editor:** Lu YJ





Published by **Baishideng Publishing Group Inc**
7901 Stoneridge Drive, Suite 501, Pleasanton, CA 94588, USA
Telephone: +1-925-223-8242
Fax: +1-925-223-8243
E-mail: bpgoffice@wjgnet.com
Help Desk: <http://www.f6publishing.com/helpdesk>
<http://www.wjgnet.com>

