

World Journal of *Gastroenterology*

World J Gastroenterol 2017 May 28; 23(20): 3569-3760



**EDITORIAL**

- 3569 Hepatitis C in injection drug users: It is time to treat

Grassi A, Ballardini G

- 3572 Cyclooxygenase 2 in liver dysfunction and carcinogenesis: Facts and perspectives

Martín-Sanz P, Casado M, Boscá L

REVIEW

- 3581 First quarter century of laparoscopic liver resection

Morise Z, Wakabayashi G

- 3589 Hepatitis A virus infection and hepatitis A vaccination in human immunodeficiency virus-positive patients: A review

Lin KY, Chen GJ, Lee YL, Huang YC, Cheng A, Sun HY, Chang SY, Liu CE, Hung CC

- 3607 Brain changes detected by functional magnetic resonance imaging and spectroscopy in patients with Crohn's disease

Lv K, Fan YH, Xu L, Xu MS

- 3615 Perspectives of traditional Chinese medicine in pancreas protection for acute pancreatitis

Li J, Zhang S, Zhou R, Zhang J, Li ZF

MINIREVIEWS

- 3624 Transition of pediatric to adult care in inflammatory bowel disease: Is it as easy as 1, 2, 3?

Afzali A, Wahbeh G

- 3632 Colorectal cancer population screening programs worldwide in 2016: An update

Navarro M, Nicolas A, Ferrandez A, Lanás A

ORIGINAL ARTICLE**Basic Study**

- 3643 Urinary metabolic insights into host-gut microbial interactions in healthy and IBD children

Martin FP, Su MM, Xie GX, Guiraud SP, Kussmann M, Godin JP, Jia W, Nydegger A

- 3655 M2-like Kupffer cells in fibrotic liver may protect against acute insult

Zheng QF, Bai L, Duan ZP, Han YP, Zheng SJ, Chen Y, Li JS

- 3664 Sonographic appearance of anal cushions of hemorrhoids

Aimaiti A, A Ba Bai Ke Re MMTJ, Ibrahim I, Chen H, Tuerdi M, Mayinuer

- 3675 Effect of NDC80 in human hepatocellular carcinoma

Ju LL, Chen L, Li JH, Wang YF, Lu RJ, Bian ZL, Shao JG

- 3684 Animal experimental studies using small intestine endoscope

Liu JH, Liu DY, Wang L, Han LP, Qi ZY, Ren HJ, Feng Y, Luan FM, Mi LT, Shan SM

Retrospective Cohort Study

- 3690 Radiological response and inflammation scores predict tumour recurrence in patients treated with transarterial chemoembolization before liver transplantation

Nicolini D, Agostini A, Montalti R, Mocchegiani F, Mincarelli C, Mandolesi A, Robertson NL, Candelari R, Giovagnoni A, Vivarelli M

Retrospective Study

- 3702 Surgical management of liver diseases invading the hepatocaval confluence based on IH classification: The surgical guideline in our center

Li W, Han J, Wu ZP, Wu H

Observational Study

- 3713 Study on the value of serum miR-106b for the early diagnosis of hepatocellular carcinoma

Shi BM, Lu W, Ji K, Wang YF, Xiao S, Wang XY

Prospective Study

- 3721 Clinical significance of expression of proliferating cell nuclear antigen and E-cadherin in gastric carcinoma

Hu L, Li HL, Li WF, Chen JM, Yang JT, Gu JJ, Xin L

META-ANALYSIS

- 3730 Different techniques for harvesting grafts for living donor liver transplantation: A systematic review and meta-analysis

Li H, Zhang JB, Chen XL, Fan L, Wang L, Li SH, Zheng QL, Wang XM, Yang Y, Chen GH, Wang GS

CASE REPORT

- 3744 Successful treatment of a pancreatic schwannoma by spleen-preserving distal pancreatectomy

Xu SY, Wu YS, Li JH, Sun K, Hu ZH, Zheng SS, Wang WL

- 3752 Preoperative detection and localization of small bowel hemangioma: Two case reports

Takase N, Fukui K, Tani T, Nishimura T, Tanaka T, Harada N, Ueno K, Takamatsu M, Nishizawa A, Okamura A, Kaneda K

LETTERS TO THE EDITOR

- 3758** Non-invasive stimulation techniques to relieve abdominal/pelvic pain: Is more always better?

Harvey MP, Watier A, Dufort Rouleau É, Léonard G

ABOUT COVER

Editorial board member of *World Journal of Gastroenterology*, Jia Liu, MD, Associate Professor, Department of Infectious Diseases, Institution of Infection and Immunology, Union Hospital, Tongji Medical College, Huazhong University of Science and Technology, Wuhan 430022, Hubei Province, China

AIMS AND SCOPE

World Journal of Gastroenterology (*World J Gastroenterol*, *WJG*, print ISSN 1007-9327, online ISSN 2219-2840, DOI: 10.3748) is a peer-reviewed open access journal. *WJG* was established on October 1, 1995. It is published weekly on the 7th, 14th, 21st, and 28th each month. The *WJG* Editorial Board consists of 1375 experts in gastroenterology and hepatology from 68 countries.

The primary task of *WJG* is to rapidly publish high-quality original articles, reviews, and commentaries in the fields of gastroenterology, hepatology, gastrointestinal endoscopy, gastrointestinal surgery, hepatobiliary surgery, gastrointestinal oncology, gastrointestinal radiation oncology, gastrointestinal imaging, gastrointestinal interventional therapy, gastrointestinal infectious diseases, gastrointestinal pharmacology, gastrointestinal pathophysiology, gastrointestinal pathology, evidence-based medicine in gastroenterology, pancreatology, gastrointestinal laboratory medicine, gastrointestinal molecular biology, gastrointestinal immunology, gastrointestinal microbiology, gastrointestinal genetics, gastrointestinal translational medicine, gastrointestinal diagnostics, and gastrointestinal therapeutics. *WJG* is dedicated to become an influential and prestigious journal in gastroenterology and hepatology, to promote the development of above disciplines, and to improve the diagnostic and therapeutic skill and expertise of clinicians.

INDEXING/ABSTRACTING

World Journal of Gastroenterology (*WJG*) is now indexed in Current Contents[®]/Clinical Medicine, Science Citation Index Expanded (also known as SciSearch[®]), Journal Citation Reports[®], Index Medicus, MEDLINE, PubMed, PubMed Central, Digital Object Identifier, and Directory of Open Access Journals. The 2015 edition of Journal Citation Reports[®] released by Thomson Reuters (ISI) cites the 2015 impact factor for *WJG* as 2.787 (5-year impact factor: 2.848), ranking *WJG* as 38 among 78 journals in gastroenterology and hepatology (quartile in category Q2).

FLYLEAF

I-IX Editorial Board

EDITORS FOR THIS ISSUE

Responsible Assistant Editor: *Xiang Li*
Responsible Electronic Editor: *Cai-Hong Wang*
Proofing Editor-in-Chief: *Lian-Sheng Ma*

Responsible Science Editor: *Yuan Qi*
Proofing Editorial Office Director: *Jin-Lei Wang*

NAME OF JOURNAL
World Journal of Gastroenterology

ISSN
ISSN 1007-9327 (print)
ISSN 2219-2840 (online)

LAUNCH DATE
October 1, 1995

FREQUENCY
Weekly

EDITORS-IN-CHIEF
Damian Garcia-Olmo, MD, PhD, Doctor, Professor, Surgeon, Department of Surgery, Universidad Autonoma de Madrid; Department of General Surgery, Fundacion Jimenez Diaz University Hospital, Madrid 28040, Spain

Stephen C Strom, PhD, Professor, Department of Laboratory Medicine, Division of Pathology, Karolinska Institutet, Stockholm 141-86, Sweden

Andrzej S Tarnawski, MD, PhD, DSc (Med), Professor of Medicine, Chief Gastroenterology, VA Long Beach Health Care System, University of California, Irvine, CA, 5901 E. Seventh Str., Long Beach,

CA 90822, United States

EDITORIAL BOARD MEMBERS
All editorial board members resources online at <http://www.wjgnet.com/1007-9327/editorialboard.htm>

EDITORIAL OFFICE
Jin-Lei Wang, Director
Yuan Qi, Vice Director
Ze-Mao Gong, Vice Director
World Journal of Gastroenterology
Baishideng Publishing Group Inc
7901 Stoneridge Drive, Suite 501,
Pleasanton, CA 94588, USA
Telephone: +1-925-2238242
Fax: +1-925-2238243
E-mail: editorialoffice@wjgnet.com
Help Desk: <http://www.f6publishing.com/helpdesk>
<http://www.wjgnet.com>

PUBLISHER
Baishideng Publishing Group Inc
7901 Stoneridge Drive, Suite 501,
Pleasanton, CA 94588, USA
Telephone: +1-925-2238242
Fax: +1-925-2238243
E-mail: bpgoffice@wjgnet.com
Help Desk: <http://www.f6publishing.com/helpdesk>

<http://www.wjgnet.com>

PUBLICATION DATE
May 28, 2017

COPYRIGHT
© 2017 Baishideng Publishing Group Inc. Articles published by this Open-Access journal are distributed under the terms of the Creative Commons Attribution Non-commercial License, which permits use, distribution, and reproduction in any medium, provided the original work is properly cited, the use is non commercial and is otherwise in compliance with the license.

SPECIAL STATEMENT
All articles published in journals owned by the Baishideng Publishing Group (BPG) represent the views and opinions of their authors, and not the views, opinions or policies of the BPG, except where otherwise explicitly indicated.

INSTRUCTIONS TO AUTHORS
Full instructions are available online at <http://www.wjgnet.com/bpg/gerinfo/204>

ONLINE SUBMISSION
<http://www.f6publishing.com>

Preoperative detection and localization of small bowel hemangioma: Two case reports

Nobuhisa Takase, Keisuke Fukui, Takafumi Tani, Tohru Nishimura, Tomohiro Tanaka, Naoki Harada, Kimihiko Ueno, Manabu Takamatsu, Akihiko Nishizawa, Akiharu Okamura, Kunihiro Kaneda

Nobuhisa Takase, Keisuke Fukui, Takafumi Tani, Tohru Nishimura, Tomohiro Tanaka, Naoki Harada, Kimihiko Ueno, Manabu Takamatsu, Kunihiro Kaneda, Department of Surgery, Kakogawa Central City Hospital, Kakogawa 675-8611, Japan

Akihiko Nishizawa, Department of Internal Medicine, Kakogawa Central City Hospital, Kakogawa 675-8611, Japan

Akiharu Okamura, Department of Diagnostic Pathology, Kakogawa Central City Hospital, Kakogawa 675-8611, Japan

Author contributions: Harada N and Nishizawa A operated on the patient and designed the report; Fukui K, Tani T, Nishimura T, Tanaka T, Ueno K, Takamatsu M and Okamura A drafted the paper; Kaneda K critically revised the paper with an important conceptual and editorial input; and all authors contributed to this manuscript.

Institutional review board statement: This case report was exempt from the Institutional Review Board standards at Kakogawa Central City Hospital, Kakogawa, Japan.

Informed consent statement: The patients participating in the study provided informed written consent.

Conflict-of-interest statement: The authors declare no conflict of interest associated with this manuscript.

Open-Access: This article is an open-access article which was selected by an in-house editor and fully peer-reviewed by external reviewers. It is distributed in accordance with the Creative Commons Attribution Non Commercial (CC BY-NC 4.0) license, which permits others to distribute, remix, adapt, build upon this work non-commercially, and license their derivative works on different terms, provided the original work is properly cited and the use is non-commercial. See: <http://creativecommons.org/licenses/by-nc/4.0/>

Manuscript source: Unsolicited manuscript

Correspondence to: Kunihiro Kaneda, MD, PhD, Department of Surgery, Kakogawa Central City Hospital, 439, Honmachi, Kakogawa-cho, Kakogawa 675-8611,

Japan. k-kaneda@kakohp.jp
Telephone: +81-79-4515500
Fax: +81-79-4515548

Received: February 16, 2017

Peer-review started: February 17, 2017

First decision: March 3, 2017

Revised: March 17, 2017

Accepted: April 12, 2017

Article in press: April 12, 2017

Published online: May 28, 2017

Abstract

Among the various diagnostic modalities for small bowel hemangioma, video capsule endoscopy (VCE) and double-balloon enteroscopy (DBE) can be recommended as part of the work-up in patients with obscure gastrointestinal bleeding (OGIB). DBE is superior to VCE in the accuracy of diagnosis and therapeutic potential, while in most cases total enteroscopy cannot be achieved through only the antegrade or retrograde DBE procedures. As treatment for small bowel bleeding, especially spout bleeding, localization of the lesion for the decision of DBE insertion facilitates early treatment, such as endoscopic hemostatic clipping, allowing patients to avoid useless transfusion and the worsening of their disease into life-threatening status. Applying endoscopic India ink marking prior to laparoscopic surgical resection is a particularly useful technique for more minimally invasive treatment. We report two cases of small bowel hemangioma found in examinations for OGIB that were treated with combination of laparoscopic and endoscopic modalities.

Key words: Laparoscopic surgery; India ink marking; Small bowel hemangioma; Obscure gastrointestinal bleeding; Minimally invasive

© The Author(s) 2017. Published by Baishideng Publishing Group Inc. All rights reserved.

Core tip: Small bowel hemangioma is a relatively rare small bowel tumor and can cause gastrointestinal bleeding, which often results in a diagnostic dilemma. video capsule endoscopy (VCE) and double-balloon enteroscopy are both useful modalities for the diagnosis of small bowel disease with obscure gastrointestinal bleeding including hemangioma, and preceding observation by VCE can result in a synergistic treatment effect. Furthermore, applying endoscopic India ink marking prior to laparoscopic surgical resection is a useful technique for achieving minimally invasive treatment.

Takase N, Fukui K, Tani T, Nishimura T, Tanaka T, Harada N, Ueno K, Takamatsu M, Nishizawa A, Okamura A, Kaneda K. Preoperative detection and localization of small bowel hemangioma: Two case reports. *World J Gastroenterol* 2017; 23(20): 3752-3757 Available from: URL: <http://www.wjgnet.com/1007-9327/full/v23/i20/3752.htm> DOI: <http://dx.doi.org/10.3748/wjg.v23.i20.3752>

INTRODUCTION

The detection of small bowel bleeding using conventional endoscopy is difficult because of the anatomical features of the small intestine. The current clinical guideline including diagnosis and management for patients with suspected small bowel bleeding is provided by American College of Gastroenterology^[1]. Among the diagnostic modalities, such as video capsule endoscopy (VCE), double-balloon enteroscopy (DBE), computed tomography (CT), magnetic resonance, enterography, angiography and scintigraphy, VCE and DBE show the greatest impact on the diagnosis and treatment of small-bowel disease^[2-4]. We herein report two cases of small bowel hemangioma found in examinations for obscure gastrointestinal bleeding.

CASE REPORT

Case 1

A 62-year-old Japanese female who had been admitted to another facility presented with black (tar) colored stools and general malaise as her chief complaints. There was no past medical problem. Though she had a severe iron-deficiency anemia, general gastrointestinal examinations including upper endoscopy and total colonoscopy to the terminal ileum were normal. She was referred to our hospital for a detailed examination of obscure gastrointestinal bleeding (OGIB). Although she had received repeated transfusions of red blood cells with one as recent as one week prior, her initial hemoglobin level was 3.8 g/dL. Her coagulating system and tumor markers including carcinoembryonic

antigen (CEA) and carbohydrate antigen 19-9 (CA19-9) were normal. VCE revealed the exact location of the lesion (Figure 1A), and DBE revealed spout bleeding in the upper jejunum (Figure 1B). The DBE showed a raised lesion (15 mm) with smooth surface in the upper jejunum site of approximately 60 cm (Figure 1B and C). We suspected the lesion as small intestinal hemangioma or arteriovenous malformation. We performed endoscopic hemostatic clipping of the lesion (Figure 1D), and during the endoscopic procedure, applied a visualization technique for tumor localization using India ink tattooing. Finally, we performed a video-assisted single-port laparoscopic enterectomy (Figure 2A). The resected specimen contained a depressed lesion with necrosis-related slough of endoscopic clipping lesion (Figure 2B). Histological findings revealed a cavernous hemangioma without atypia mainly composed of submucosa (Figure 2C). She was dismissed from the hospital 8 d after undergoing surgery.

Case 2

A 52-year-old Japanese male visiting his family doctor presented with black (tar) colored stools for 3 mo as his chief complaint. He had hypertension, hyperlipidemia and type 2 diabetes mellitus without complications. Though he was diagnosed with only mild iron-deficiency anemia, his hemoglobin level had decreased by approximately 35% in 6 mo. Therefore, a general gastrointestinal examination was performed. When upper endoscopy and total colonoscopy showed almost normal results, he was referred to our hospital for a detailed examination of OGIB. His initial hemoglobin level was 11.3 g/dL. Early-phase contrast-enhanced computed tomography (CECT) showed a small nodule enhancement in the ileum (Figure 3A). VCE revealed the precise location of the lesion (Figure 3B), and DBE revealed submucosal tumor-like (SMT) raised lesion (10 mm) with central erosion in the lower ileum (Figure 3C); still, histological findings from the endoscopic biopsy showed nonspecific changes. We preoperatively diagnosed the lesion as hemangioma, and performed a video-assisted laparoscopic enterectomy using preoperative endoscopic India ink tattooing (Figure 3D). Histological findings revealed a capillary hemangioma without atypia from the muscle layer to the mucosal layer (Figure 3E). The patient was dismissed from the hospital 8 days after surgery.

DISCUSSION

Intraluminal gastrointestinal bleeding can be a life-threatening condition. In case of OGIB this is rarely the case when esophagogastroduodenoscopy and colonoscopy with adequate preparation have been performed^[5,6], which often results in a diagnostic dilemma. In 75% of OGIB patients, the lesion is ultimately found in the small intestine, and occasionally

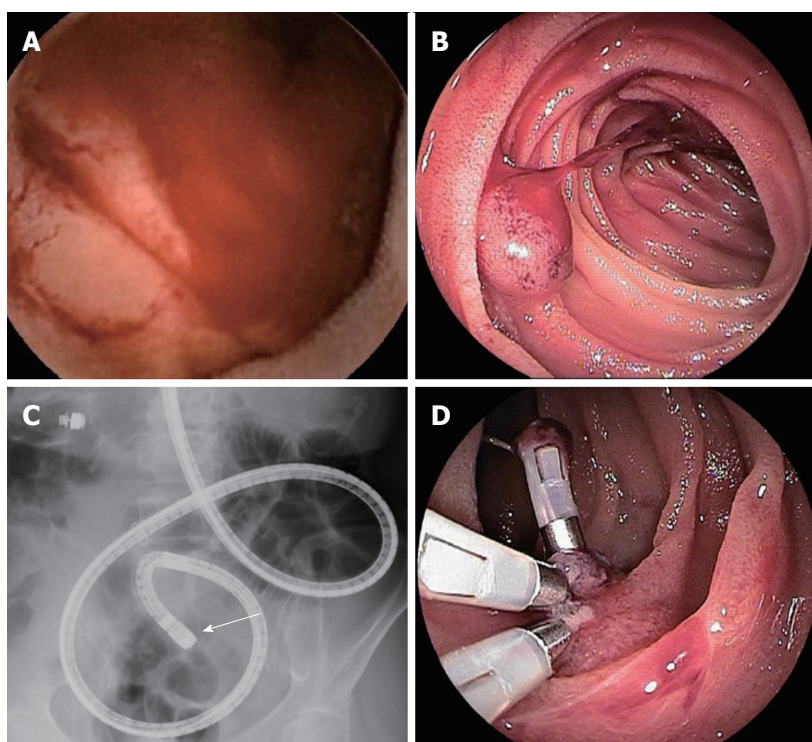


Figure 1 Evaluation of endoscopic findings (case 1). Video capsule endoscopy (A) and double-enteroscopy (B and C) show a raised lesion with smooth surface in the upper jejunum, and double-balloon enteroscopy showed spout bleeding of the lesion. The lesion in the jejunum was disclosed 29 min after capsule ingestion (pylorus passage at 16 min) (A). Detailed localization of the target lesion using fluoroscopy is shown by the end of endoscopic insertion (arrow) (C). The lesion underwent endoscopic hemostatic clipping (D).

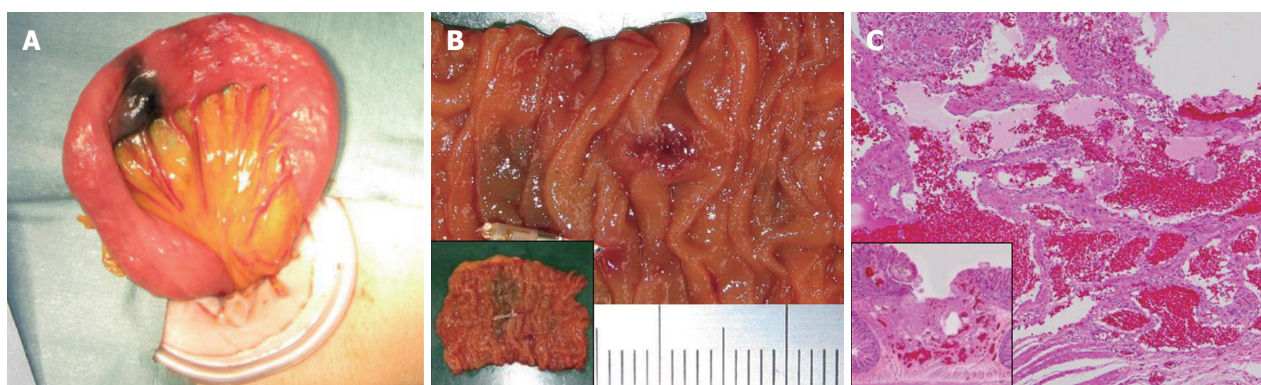


Figure 2 Surgical and pathological finding (case 1). The surgical finding on single port laparoscopic survey shows an objective site with India link tattooing (A). Surgical specimen from the small intestine. Including the lesion indicated with India link shows a whole view of the resected lesion (B). Histological (h-e stain) in the resected specimen show different-sized blood vessels circumferentially proliferated from the mucosa to submucosa. Inset shows different-sized distended blood vessels circumferentially proliferated from the mucosa to submucosa. Inset shows a low-power field view (C).

causes recurrent or persistent bleeding^[6].

Small bowel bleeding is relatively rare, comprising only about 5% of gastrointestinal bleeding^[1,7]. Concerning the common causes of small bowel bleeding, the causative disease varies by age. In patients under 40 years of age, inflammatory bowel disease, the most common cause, is followed by Dieulafoy's lesions, neoplasms, Meckel's disease and Polyps. In those over 40, angioectasia including arteriovenous malformation and hemangioma is followed by Dieulafoy's lesions, neoplasms and NSAIDs ulcers^[1]. In addition, Yamamoto *et al.*^[8]

reported that the frequency of angioectasia-related bleeding among small bowel bleeding cases was 20%.

Of all primary small bowel tumor cases, 47% are benign^[9]. Among them, small bowel hemangioma is a relatively rare primary small bowel tumor, histologically defined as a benign tumor. Wilson *et al.*^[10] reported that hemangioma constitutes approximately 10% of benign small bowel tumors and that most reported cases have occurred in the jejunum and ileum. Concerning the initial common symptoms of small bowel hemangioma, the occurrence frequency of iron-deficiency anemia, pain and intussusception are 41%, 31% and 13%,

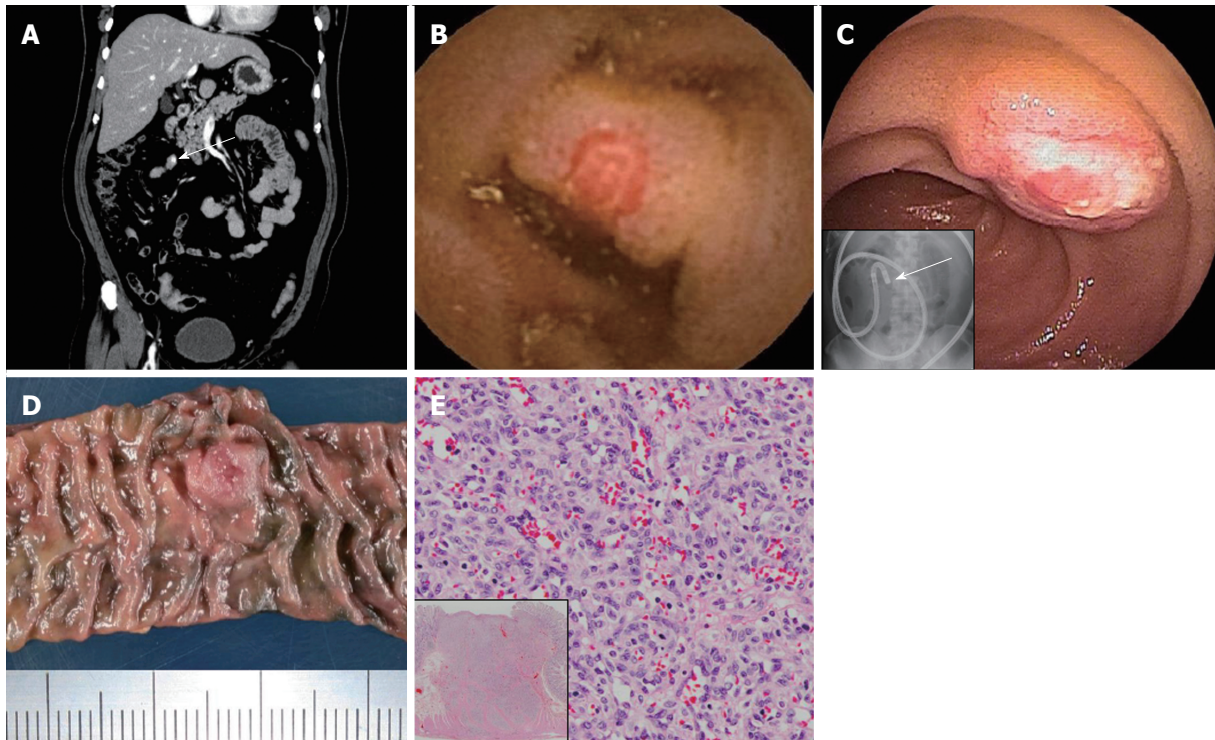


Figure 3 Evaluation of clinical finding (case 2). Early-phase contrast-enhanced computed tomography reveals small nodule enhancement in the ileum (arrow) (A). Video capsule endoscopy (B) and double-balloon enteroscopy (C) show a submucosal tumor-like raised lesion with central erosion in the lower ileum. The lesion in the jejunum was disclosed 145 min after capsule ingestion (pylorus passage at 140 min) (B), inset indicates fluoroscopic localization of target at the end of the endoscope insertion (arrow) (C). Surgical specimen from the small intestine, including the indicated lesion with India ink tattooing (D). Histological finding (H-E stain) in the resected specimen show circumferential capillary growth without atypia from the mucosa to the muscle. Inset shows a low-power field view (E).

respectively^[10]. Macroscopically, Chen *et al.*^[11] summarized previous endoscopy reports of intestinal hemangiomas describing the lesions as typically submucosal, purple to red, soft and pedunculated. Histologically, hemangiomas can be broadly classified in capillary, cavernous and mixed type, with the cavernous type being the most common^[12]. They generally consist of numerous dilated, irregular blood-filled spaces or sinuses lined by layers of endothelial cells^[13].

Recent advances in endoscopic technique including VCE and DBE have allowed preoperative diagnosis of small bowel hemangioma^[11]. VCE can be recommended as part of the routine work-up in patients with obscure bleeding^[14], and it is not contraindicated except in patients with stenosis of the intestine. Compared with VCE, DBE has the advantage of biopsy and therapeutic potential, such as preoperative localization, coagulation and hemostasis by clipping^[15], whereas Xin indicated that successful total enteroscopy is achieved in only 1.6% of patients through the antegrade procedure^[16].

In recent years, the therapeutic options including minimally invasive laparoscopic surgery represented by our cases and even non-surgical endoscopic approaches for small bowel hemangioma have been proposed. The laparoscopic approach to gastro-intestinal diseases is now widely accepted, but it is generally difficult to locate the lesion by palpation, especially in the jejunum and ileum. A previous

study reported on colonic tattooing in animal model with various agents, such as methylene blue, indigo carmine, toluidine blue, lymphazurine, hematoxylin, eosin, indocyanine green (ICG) and India ink^[17]. Only ICG and India ink tattoos persisted for more than 48 h, while ICG was associated with allergic reactions and systemic toxicity^[17]. Therefore, endoscopic marking with India ink is used widely as a visualization technique for colorectal cancer, to define the operative location. India ink tattooing has a low incidence of complications (0.22%), and remains for a prolonged duration^[17,18]. In the present case, we selected this visualization technique for video-assisted single-port laparoscopic enterectomy, expecting a minimally invasive effect. Concerning non-surgical endoscopic approaches, several clinical studies have reported that endoscopic mucosal resection can be a useful tool for small bowel hemangioma^[19-21]. However, in addition to the common endoscopic complications including intestinal perforation and lesion persistence, the endoscopic approach for small bowel hemangioma with rich vascularity has the potential for flooding, given the potential for misconception of the lesion depth. Chen *et al.*^[11] also recommended careful consideration of the indications for endoscopic surgery. As one of the methods to overcome these potential risks, laparoscopic and endoscopic cooperative surgery (LECS) has been suggested as a new concept for tumor dissection^[22]. In recent years, Kanaji *et al.*^[23]

demonstrated safe and total laparoscopic resection of hemangiomas in the third portion of the duodenum using the LECS technique. Therefore, LECS may become a useful therapeutic option for small bowel hemangioma.

In conclusion, we have documented two cases of small bowel hemangioma found in examinations for OGIB. The preceding implementation of VCE made the selective decision of DBE insertion easy, and the endoscopic process facilitated early treatment, resulting in avoidance of progression to life-threatening status. In the present case report (*Case 2*), CECT showed small nodule enhancement in the lesion. Therefore, the preceding CECT with a characteristic of rapid and minimally invasive technique may omit VCE, making it a useful algorithm for further early treatment. These findings imply that various preoperative endoscopic contrivances may result in safer, more minimally invasive treatment.

COMMENTS

Case characteristics

Two cases of small bowel hemangioma found in examinations for obscure gastrointestinal bleeding (OGIB) were treated with combination of laparoscopic and endoscopic modalities.

Clinical diagnosis

Preoperative enteroscopy and imaging tests in each case suggested that the lesion was a small intestinal hemangioma or arteriovenous malformation.

Differential diagnosis

Arteriovenous malformation.

Laboratory diagnosis

Iron-deficiency anemia was diagnosed, with one case showing severe anemia.

Imaging diagnosis

Video capsule endoscopy (VCE) showed the precise location of the lesion, and double-balloon enteroscopy (DBE) revealed raised lesions with or without spout bleeding in the small intestine.

Pathological diagnosis

They diagnosed Case 1 and Case 2 as cavernous hemangioma and capillary hemangioma, respectively.

Treatment

The patients were treated with combination of laparoscopic and endoscopic modalities.

Related reports

There are few reports on treatments combining VCE, DBE on fluoroscopy, preoperative endoscopic marking, and single-port laparoscopic surgery.

Term explanation

There are no uncommon terms used in this manuscript.

Experiences and lessons

The authors share this case as important knowledge for the appropriate treatment process for small bowel hemangioma.

Peer-review

These two case reports demonstrate that small bowel hemangioma found as an examination for OGIB were successfully treated with combination of laparoscopic and endoscopic modalities.

REFERENCES

- 1 **Gerson LB**, Fidler JL, Cave DR, Leighton JA. ACG Clinical Guideline: Diagnosis and Management of Small Bowel Bleeding. *Am J Gastroenterol* 2015; **110**: 1265-1287; quiz 1288 [PMID: 26303132 DOI: 10.1038/ajg.2015.246]
- 2 **Tanabe S**. Diagnosis of Obscure Gastrointestinal Bleeding. *Clin Endosc* 2016; **49**: 539-541 [PMID: 26879551 DOI: 10.5946/ce.2016.004]
- 3 **Iddan G**, Meron G, Glukhovskiy A, Swain P. Wireless capsule endoscopy. *Nature* 2000; **405**: 417 [PMID: 10839527 DOI: 10.1038/35013140]
- 4 **Yamamoto H**, Sekine Y, Sato Y, Higashizawa T, Miyata T, Iino S, Ido K, Sugano K. Total enteroscopy with a nonsurgical steerable double-balloon method. *Gastrointest Endosc* 2001; **53**: 216-220 [PMID: 11174299]
- 5 **Raju GS**, Gerson L, Das A, Lewis B. American Gastroenterological Association (AGA) Institute technical review on obscure gastrointestinal bleeding. *Gastroenterology* 2007; **133**: 1697-1717 [PMID: 17983812 DOI: 10.1053/j.gastro.2007.06.007]
- 6 **Pasha SF**, Hara AK, Leighton JA. Diagnostic evaluation and management of obscure gastrointestinal bleeding: a changing paradigm. *Gastroenterol Hepatol* (N Y) 2009; **5**: 839-850 [PMID: 20567529]
- 7 **Briley CA**, Jackson DC, Johnsrude IS, Mills SR. Acute gastrointestinal hemorrhage of small-bowel origin. *Radiology* 1980; **136**: 317-319 [PMID: 6967614 DOI: 10.1148/radiology.136.2.6967614]
- 8 **Yamamoto H**, Kita H, Sunada K, Hayashi Y, Sato H, Yano T, Iwamoto M, Sekine Y, Miyata T, Kuno A, Ajibe H, Ido K, Sugano K. Clinical outcomes of double-balloon endoscopy for the diagnosis and treatment of small-intestinal diseases. *Clin Gastroenterol Hepatol* 2004; **2**: 1010-1016 [PMID: 15551254]
- 9 **Eckel JH**. Primary tumors of the jejunum and ileum. *Surgery* 1948; **23**: 467-475 [PMID: 18906031]
- 10 **Wilson JM**, Melvin DB, Gray G, Thorbjarnarson B. Benign small bowel tumor. *Ann Surg* 1975; **181**: 247-250 [PMID: 1078626]
- 11 **Chen HH**, Tu CH, Lee PC, Chiu HM, Wu MS, Wang HP. Endoscopically diagnosed cavernous hemangioma in the deep small intestine: A case report. *Adv Dig Med* 2015; **2**: 74-78 [DOI: 10.1016/j.aidm.2014.03.009]
- 12 **Ramanujam PS**, Venkatesh KS, Bettinger L, Hayashi JT, Rothman MC, Fietz MJ. Hemangioma of the small intestine: case report and literature review. *Am J Gastroenterol* 1995; **90**: 2063-2064 [PMID: 7485031]
- 13 **Pera M**, Márquez L, Dedeu JM, Sánchez J, García M, Ramón JM, Puigvehí M. Solitary cavernous hemangioma of the small intestine as the cause of long-standing iron deficiency anemia. *J Gastrointest Surg* 2012; **16**: 2288-2290 [PMID: 22875598 DOI: 10.1007/s11605-012-1991-6]
- 14 **Maieron A**, Hubner D, Blaha B, Deutsch C, Schickmair T, Ziachehabi A, Kerstan E, Knoflach P, Schoefl R. Multicenter retrospective evaluation of capsule endoscopy in clinical routine. *Endoscopy* 2004; **36**: 864-868 [PMID: 15452781 DOI: 10.1055/s-2004-825852]
- 15 **Chen WG**, Shan GD, Zhang H, Li L, Yue M, Xiang Z, Cheng Y, Wu CJ, Fang Y, Chen LH. Double-balloon enteroscopy in small bowel tumors: a Chinese single-center study. *World J Gastroenterol* 2013; **19**: 3665-3671 [PMID: 23801870 DOI: 10.3748/wjg.v19.i23.3665]
- 16 **Xin L**, Liao Z, Jiang YP, Li ZS. Indications, detectability, positive findings, total enteroscopy, and complications of diagnostic double-balloon endoscopy: a systematic review of data over the first decade of use. *Gastrointest Endosc* 2011; **74**: 563-570 [PMID: 21620401 DOI: 10.1016/j.gie.2011.03.1239]

- 17 **Nizam R**, Siddiqi N, Landas SK, Kaplan DS, Holtzaple PG. Colonic tattooing with India ink: benefits, risks, and alternatives. *Am J Gastroenterol* 1996; **91**: 1804-1808 [PMID: 8792702]
- 18 **Kim BK**, Song MH, Yang HJ, Kim DS, Lee NK, Jeon YS. Use of cystoscopic tattooing in laparoscopic partial cystectomy. *Korean J Urol* 2012; **53**: 401-404 [PMID: 22741048 DOI: 10.4111/kju.2012.53.6.401]
- 19 **Willert RP**, Chong AK. Multiple cavernous hemangiomas with iron deficiency anemia successfully treated with double-balloon enteroscopy. *Gastrointest Endosc* 2008; **67**: 765-767 [PMID: 18155208 DOI: 10.1016/j.gie.2007.07.044]
- 20 **Shibuya T**, Osada T, Mitomi H, Takeda T, Nomura O, Nakayama H, Hidaka Y, Mori H, Beppu K, Sakamoto N, Nagahara A, Otaka M, Ogihara T, Yao T, Watanabe S. Jejunal capillary hemangioma treated by using double-balloon endoscopy (with video). *Gastrointest Endosc* 2010; **72**: 660-661 [PMID: 20546731 DOI: 10.1016/j.gie.2009.12.051]
- 21 **Pinho R**, Rodrigues A, Proença L, Silva AP, Fernandes S, Leite S, Amaral I, de Sousa P, Fraga J. Solitary hemangioma of the small bowel disclosed by wireless capsule endoscopy. *Gastroenterol Clin Biol* 2008; **32**: 15-18 [PMID: 18405648 DOI: 10.1016/j.gcb.2007.11.004]
- 22 **Hiki N**, Yamamoto Y, Fukunaga T, Yamaguchi T, Nunobe S, Tokunaga M, Miki A, Ohyama S, Seto Y. Laparoscopic and endoscopic cooperative surgery for gastrointestinal stromal tumor dissection. *Surg Endosc* 2008; **22**: 1729-1735 [PMID: 18074180 DOI: 10.1007/s00464-007-9696-8]
- 23 **Kanaji S**, Nakamura T, Nishi M, Yamamoto M, Kanemitsu K, Yamashita K, Imanishi T, Sumi Y, Suzuki S, Tanaka K, Kakeji Y. Laparoscopic partial resection for hemangioma in the third portion of the duodenum. *World J Gastroenterol* 2014; **20**: 12341-12345 [PMID: 25232270 DOI: 10.3748/wjg.v20.i34.12341]

P- Reviewer: Nickel F, Noviello C, Venskutonis D **S- Editor:** Qi Y
L- Editor: A **E- Editor:** Zhang FF





Published by **Baishideng Publishing Group Inc**
7901 Stoneridge Drive, Suite 501, Pleasanton, CA 94588, USA
Telephone: +1-925-223-8242
Fax: +1-925-223-8243
E-mail: bpgoffice@wjgnet.com
Help Desk: <http://www.f6publishing.com/helpdesk>
<http://www.wjgnet.com>



ISSN 1007-9327

