

World Journal of *Gastroenterology*

World J Gastroenterol 2017 August 14; 23(30): 5451-5644



**EDITORIAL**

- 5451** Wilson's disease: Prospective developments towards new therapies

Ranucci G, Polishchuck R, Iorio R

- 5457** Are our endoscopy patients at risk for pyogenic liver abscess?

Cerwenka H, Schemmer P

REVIEW

- 5460** Pancreatitis: Preventing catastrophic haemorrhage

Evans RPT, Mourad MM, Pall G, Fisher SG, Bramhall SR

MINIREVIEWS

- 5469** Treating children with inflammatory bowel disease: Current and new perspectives

Guariso G, Gasparetto M

- 5486** Influence of gut microbiota on neuropsychiatric disorders

Cenit MC, Sanz Y, Codoñer-Franch P

ORIGINAL ARTICLE**Basic Study**

- 5499** Everolimus halts hepatic cystogenesis in a rodent model of polycystic-liver-disease

Temmerman F, Chen F, Libbrecht L, Vander Elst I, Windmolders P, Feng Y, Ni Y, De Smedt H, Nevens F, van Pelt J

- 5508** MicroRNA profile in neosquamous esophageal mucosa following ablation of Barrett's esophagus

Sreedharan L, Mayne GC, Watson DI, Bright T, Lord RV, Ansar A, Wang T, Kist J, Astill DS, Hussey DJ

- 5519** Expression of Interleukin-26 is upregulated in inflammatory bowel disease

Fujii M, Nishida A, Imaeda H, Ohno M, Nishino K, Sakai S, Inatomi O, Bamba S, Kawahara M, Shimizu T, Andoh A

- 5530** Autophagic cell death induced by reactive oxygen species is involved in hyperthermic sensitization to ionizing radiation in human hepatocellular carcinoma cells

Yuan GJ, Deng JJ, Cao DD, Shi L, Chen X, Lei JJ, Xu XM

- 5538** Yangzheng Sanjie decoction regulates proliferation and apoptosis of gastric cancer cells by enhancing let-7a expression

Deng HX, Yu YY, Zhou AQ, Zhu JL, Luo LN, Chen WQ, Hu L, Chen GX

Case Control Study

- 5549 Crohn's disease environmental factors in the developing world: A case-control study in a statewide catchment area in Brazil

Salgado VCL, Luiz RR, Boechat N, Schorr BC, Leão IS, Nunes T, Zaltman C

Retrospective Cohort Study

- 5557 Postoperative bleeding in patients on antithrombotic therapy after gastric endoscopic submucosal dissection

Sato C, Hirasawa K, Koh R, Ikeda R, Fukuchi T, Kobayashi R, Kaneko H, Makazu M, Maeda S

Retrospective Study

- 5567 Serous pancreatic neoplasia, data and review

Dietrich CF, Dong Y, Jenssen C, Ciaravino V, Hocke M, Wang WP, Burmester E, Möller K, Atkinson NSS, Capelli P, D'Onofrio M

- 5579 Pancreaticoduodenectomy for duodenal papilla carcinoma: A single-centre 9-year retrospective study of 112 patients with long-term follow-up

Lian PL, Chang Y, Xu XC, Zhao Z, Wang XQ, Xu KS

Clinical Trials Study

- 5589 Efficacy and safety of Xiangsha Liujunzi granules for functional dyspepsia: A multi-center randomized double-blind placebo-controlled clinical study

Lv L, Wang FY, Ma XX, Li ZH, Huang SP, Shi ZH, Ji HJ, Bian LQ, Zhang BH, Chen T, Yin XL, Tang XD

Observational Study

- 5602 Combination of acoustic radiation force impulse imaging, serological indexes and contrast-enhanced ultrasound for diagnosis of liver lesions

Sun XL, Yao H, Men Q, Hou KZ, Chen Z, Xu CQ, Liang LW

Prospective Study

- 5610 Incidents and adverse events of endoscopic ultrasound-guided fine-needle aspiration for pancreatic cystic lesions

Du C, Chai NL, Linghu EQ, Li HK, Sun YF, Xu W, Wang XD, Tang P, Yang J

SYSTEMATIC REVIEWS

- 5619 Systematic review of giant gastric lipomas reported since 1980 and report of two new cases in a review of 117110 esophagogastroduodenoscopies

Cappell MS, Stevens CE, Amin M

- 5634 Acute colonic pseudo-obstruction: A systematic review of aetiology and mechanisms

Wells CI, O'Grady G, Bissett IP

ABOUT COVER

Editorial board member of *World Journal of Gastroenterology*, Piero Luigi Almasio, MD, Associate Professor, Biomedical Department of Internal and Specialist Medicine, University of Palermo, 90127 Palermo, Italy

AIMS AND SCOPE

World Journal of Gastroenterology (*World J Gastroenterol*, *WJG*, print ISSN 1007-9327, online ISSN 2219-2840, DOI: 10.3748) is a peer-reviewed open access journal. *WJG* was established on October 1, 1995. It is published weekly on the 7th, 14th, 21st, and 28th each month. The *WJG* Editorial Board consists of 1375 experts in gastroenterology and hepatology from 68 countries.

The primary task of *WJG* is to rapidly publish high-quality original articles, reviews, and commentaries in the fields of gastroenterology, hepatology, gastrointestinal endoscopy, gastrointestinal surgery, hepatobiliary surgery, gastrointestinal oncology, gastrointestinal radiation oncology, gastrointestinal imaging, gastrointestinal interventional therapy, gastrointestinal infectious diseases, gastrointestinal pharmacology, gastrointestinal pathophysiology, gastrointestinal pathology, evidence-based medicine in gastroenterology, pancreatology, gastrointestinal laboratory medicine, gastrointestinal molecular biology, gastrointestinal immunology, gastrointestinal microbiology, gastrointestinal genetics, gastrointestinal translational medicine, gastrointestinal diagnostics, and gastrointestinal therapeutics. *WJG* is dedicated to become an influential and prestigious journal in gastroenterology and hepatology, to promote the development of above disciplines, and to improve the diagnostic and therapeutic skill and expertise of clinicians.

INDEXING/ABSTRACTING

World Journal of Gastroenterology (*WJG*) is now indexed in Current Contents[®]/Clinical Medicine, Science Citation Index Expanded (also known as SciSearch[®]), Journal Citation Reports[®], Index Medicus, MEDLINE, PubMed, PubMed Central and Directory of Open Access Journals. The 2017 edition of Journal Citation Reports[®] cites the 2016 impact factor for *WJG* as 3.365 (5-year impact factor: 3.176), ranking *WJG* as 29th among 79 journals in gastroenterology and hepatology (quartile in category Q2).

FLYLEAF

I-IX Editorial Board

EDITORS FOR THIS ISSUE

Responsible Assistant Editor: *Xiang Li*
Responsible Electronic Editor: *Fen-Fen Zhang*
Proofing Editor-in-Chief: *Lian-Sheng Ma*

Responsible Science Editor: *Yuan Qi*
Proofing Editorial Office Director: *Jin-Lei Wang*

NAME OF JOURNAL
World Journal of Gastroenterology

ISSN
ISSN 1007-9327 (print)
ISSN 2219-2840 (online)

LAUNCH DATE
October 1, 1995

FREQUENCY
Weekly

EDITORS-IN-CHIEF
Damian Garcia-Olmo, MD, PhD, Doctor, Professor, Surgeon, Department of Surgery, Universidad Autonoma de Madrid; Department of General Surgery, Fundacion Jimenez Diaz University Hospital, Madrid 28040, Spain

Stephen C Strom, PhD, Professor, Department of Laboratory Medicine, Division of Pathology, Karolinska Institutet, Stockholm 141-86, Sweden

Andrzej S Tarnawski, MD, PhD, DSc (Med), Professor of Medicine, Chief Gastroenterology, VA Long Beach Health Care System, University of California, Irvine, CA, 5901 E. Seventh Str., Long Beach,

CA 90822, United States

EDITORIAL BOARD MEMBERS
All editorial board members resources online at <http://www.wjgnet.com/1007-9327/editorialboard.htm>

EDITORIAL OFFICE
Jin-Lei Wang, Director
Yuan Qi, Vice Director
Ze-Mao Gong, Vice Director
World Journal of Gastroenterology
Baishideng Publishing Group Inc
7901 Stoneridge Drive, Suite 501,
Pleasanton, CA 94588, USA
Telephone: +1-925-2238242
Fax: +1-925-2238243
E-mail: editorialoffice@wjgnet.com
Help Desk: <http://www.f6publishing.com/helpdesk>
<http://www.wjgnet.com>

PUBLISHER
Baishideng Publishing Group Inc
7901 Stoneridge Drive, Suite 501,
Pleasanton, CA 94588, USA
Telephone: +1-925-2238242
Fax: +1-925-2238243
E-mail: bpoffice@wjgnet.com
Help Desk: <http://www.f6publishing.com/helpdesk>

<http://www.wjgnet.com>

PUBLICATION DATE
August 14, 2017

COPYRIGHT
© 2017 Baishideng Publishing Group Inc. Articles published by this Open-Access journal are distributed under the terms of the Creative Commons Attribution Non-commercial License, which permits use, distribution, and reproduction in any medium, provided the original work is properly cited, the use is non commercial and is otherwise in compliance with the license.

SPECIAL STATEMENT
All articles published in journals owned by the Baishideng Publishing Group (BPG) represent the views and opinions of their authors, and not the views, opinions or policies of the BPG, except where otherwise explicitly indicated.

INSTRUCTIONS TO AUTHORS
Full instructions are available online at <http://www.wjgnet.com/bpg/getinfo/204>

ONLINE SUBMISSION
<http://www.f6publishing.com>

Observational Study

Combination of acoustic radiation force impulse imaging, serological indexes and contrast-enhanced ultrasound for diagnosis of liver lesions

Xiao-Lan Sun, Hui Yao, Qiong Men, Ke-Zhu Hou, Zhen Chen, Chang-Qing Xu, Li-Wei Liang

Xiao-Lan Sun, Department of Ultrasound, Shanghai Yangpu District East Hospital, Shanghai 200433, China

Hui Yao, Department of Radiotherapy, Shanghai Yangpu District East Hospital, Shanghai 200433, China

Qiong Men, Department of Oncology, Shanghai Yangpu District East Hospital, Shanghai 200433, China

Ke-Zhu Hou, Department of Surgery, Shanghai Yangpu District East Hospital, Shanghai 200433, China

Zhen Chen, Department of Pathology, Shanghai Yangpu District East Hospital, Shanghai 200433, China

Chang-Qing Xu, Department of Radiography, Shanghai Yangpu District East Hospital, Shanghai 200433, China

Li-Wei Liang, Department of Gastroenterology, Shanghai Yangpu District East Hospital, Shanghai 200433, China

Author contributions: Sun XL and Liang LW designed the research; Sun XL, Yao H, Men Q, Hou KZ and Liang LW performed the research; Sun XL, Yao H, Men Q, Hou KZ, Chen Z, Xu CQ and Liang LW contributed new reagents or analytic tools; Sun XL, Hou KZ, Chen Z, Xu CQ and Liang LW analyzed the data; Sun XL and Liang LW wrote the paper.

Supported by Yangpu District Health and Family Planning Commission, Yangpu District Science and Technology Commission, No. YP15M18; Research Project of Shanghai Municipal Commission of Health and Family Planning, No. 201540032.

Institutional review board statement: This study was approved by Shanghai Yangpu District East Hospital Institutional Review Board.

Informed consent statement: All study participants, or their legal guardian, provided informed written consent prior to study enrollment.

Conflict-of-interest statement: No potential conflicts of interest

relevant to this article are reported.

Data sharing statement: No additional data are available.

Open-Access: This article is an open-access article which was selected by an in-house editor and fully peer-reviewed by external reviewers. It is distributed in accordance with the Creative Commons Attribution Non Commercial (CC BY-NC 4.0) license, which permits others to distribute, remix, adapt, build upon this work non-commercially, and license their derivative works on different terms, provided the original work is properly cited and the use is non-commercial. See: <http://creativecommons.org/licenses/by-nc/4.0/>

Manuscript source: Unsolicited manuscript

Correspondence to: Dr. Li-Wei Liang, Attending Physician, Department of Gastroenterology, Shanghai Yangpu District East Hospital, No. 999 Shiguang Road, Yangpu District, Shanghai 200433, China. ypsdkjk@163.com
Telephone: +86-21-65881977

Received: March 27, 2017

Peer-review started: March 29, 2017

First decision: April 11, 2017

Revised: April 24, 2017

Accepted: May 9, 2017

Article in press: May 9, 2017

Published online: August 14, 2017

Abstract

AIM

To assess the value of combined acoustic radiation force impulse (ARFI) imaging, serological indexes and contrast-enhanced ultrasound (CEUS) in distinguishing between benign and malignant liver lesions.

METHODS

Patients with liver lesions treated at our hospital were

included in this study. The lesions were divided into either a malignant tumor group or a benign tumor group according to pathological or radiological findings. ARFI quantitative detection, serological testing and CEUS quantitative detection were performed and compared. A comparative analysis of the measured indexes was performed between these groups. Receiver operating characteristic (ROC) curves were constructed to compare the diagnostic accuracy of ARFI imaging, serological indexes and CEUS, alone or in different combinations, in identifying benign and malignant liver lesions.

RESULTS

A total of 112 liver lesions in 43 patients were included, of which 78 were malignant and 34 were benign. Shear wave velocity (SWV) value, serum alpha-fetoprotein (AFP) content and enhancement rate were significantly higher in the malignant tumor group than in the benign tumor group (2.39 ± 1.20 m/s *vs* 1.50 ± 0.49 m/s, 18.02 ± 5.01 ng/mL *vs* 15.96 ± 4.33 ng/mL, 2.14 ± 0.21 dB/s *vs* 2.01 ± 0.31 dB/s; $P < 0.05$). The ROC curve analysis revealed that the areas under the curves (AUCs) of SWV value alone, AFP content alone, enhancement rate alone, SWV value + AFP content, SWV value + enhancement rate, AFP content + enhancement rate and SWV value + AFP content + enhancement rate were 85.1%, 72.1%, 74.5%, 88.3%, 90.4%, 82.0% and 92.3%, respectively. The AUC of SWV value + AFP content + enhancement rate was higher than those of SWV value + AFP content and SWV value + enhancement rate, and significantly higher than those of any single parameter or the combination of any two of parameters.

CONCLUSION

The combination of SWV, AFP and enhancement rate had better diagnostic performance in distinguishing between benign and malignant liver lesions than the use of any single parameter or the combination of any two of parameters. It is expected that this would provide a tool for the differential diagnosis of benign and malignant liver lesions.

Key words: Combined diagnosis; Liver lesions; Benign; Malignant; Differentiation

© **The Author(s) 2017.** Published by Baishideng Publishing Group Inc. All rights reserved.

Core tip: This study investigated the diagnostic value of combined acoustic radiation force impulse (ARFI) imaging, serological indicators and contrast-enhanced ultrasound in differentiating between benign and malignant liver lesions. The results showed that the diagnostic performance of combined ARFI, alpha-fetoprotein (AFP) and contrast-enhanced ultrasound in distinguishing between benign and malignant liver lesions was higher than the use of any single parameter or the combination of any two of parameters. It is expected that this would provide a tool for the differential diagnosis of benign and malignant liver

lesions.

Sun XL, Yao H, Men Q, Hou KZ, Chen Z, Xu CQ, Liang LW. Combination of acoustic radiation force impulse imaging, serological indexes and contrast-enhanced ultrasound for diagnosis of liver lesions. *World J Gastroenterol* 2017; 23(30): 5602-5609 Available from: URL: <http://www.wjgnet.com/1007-9327/full/v23/i30/5602.htm> DOI: <http://dx.doi.org/10.3748/wjg.v23.i30.5602>

INTRODUCTION

The gold standard for diagnosis of benign and malignant liver lesions is pathological examination. However, due to its invasive nature and the potential presence of infection, bleeding and other risks, pathological examination is only conducted in patients highly suspected of having malignant liver tumors. In addition, pathological diagnosis has many contraindications and is applicable in only a narrow range of patients. Thus, it is difficult to implement pathological diagnosis as a routine examination. For both benign and malignant liver lesions, detection of serological indicators and contrast-enhanced ultrasonography (CEUS) are routinely performed. Serological indicators alone often have a lower sensitivity and specificity than CEUS and acoustic radiation force impulse (ARFI) imaging. However, for small hepatocellular carcinoma, alpha-fetoprotein (AFP) is the most sensitive indicator^[1,2]. Although CEUS is a mature examination method, its diagnostic accuracy may be affected by lesion depth, blood flow velocity and respiratory movement, which makes it not suitable for some lesions and patients^[3-9]. ARFI imaging is simple and highly accepted by patients, and it can quantitatively assess the change in tissue hardness. However, it is vulnerable to biliary and intrahepatic vascular effects^[10-17]. Although these three kinds of examinations have certain value in identifying benign and malignant lesions, each has its limitations. At present, the diagnostic accuracy of the combination of these three kinds of examinations in identifying benign and malignant liver lesions remains unknown, although the combined diagnosis has been widely used for other diseases. In the present study, by constructing receiver operating characteristic (ROC) curves, we compared the diagnostic accuracy of ARFI imaging, serological indexes and CEUS, alone or in different combinations, in identifying benign and malignant liver lesions, with an aim to provide a reliable tool for the differential diagnosis of benign and malignant liver lesions.

MATERIALS AND METHODS

Study subjects

A total of 43 patients with 112 liver lesions treated

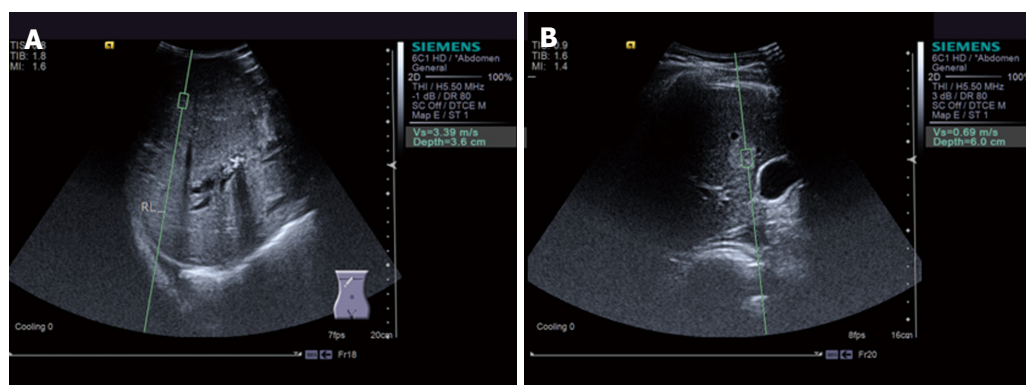


Figure 1 Acoustic radiation force impulse imaging of a liver tumor. A: Acoustic radiation force impulse (ARFI) detection of a malignant liver tumor [shear wave velocity (SWV) = 3.39 m/s]; B: ARFI detection of a benign liver tumor (SWV = 0.69 m/s).

at our hospital from May 2016 to February 2017 were included in this study. Among these patients, 21 were male and 22 were female. The lesion size ranged from 8 mm × 7 mm to 123 mm × 100 mm. The exclusion criteria were: (1) patients in whom shear wave velocity (SWV) values could not be acquired during ARFI imaging; (2) patients who could not tolerate the ultrasound contrast agent or critically ill patients; (3) patients with completely liquefied cystic tumors; and (4) patients with contraindications to liver puncture biopsy. The study was approved by the Ethics Committee of Shanghai Yangpu District East Hospital, and informed consent was obtained from all patients.

Instruments and methods

ARFI imaging: A Siemens Acuson S3000 color Doppler ultrasound system with a 6C-1HD convex array probe (center frequency, 4.0 MHz) was used. First, a whole liver scan was performed using conventional ultrasound to observe the nature of the lesion. Then, this was switched to ARFI mode to avoid biliary ducts within the liver, blood vessels and liquid necrosis. Patients were instructed to completely hold their breath during the examination. Then, SWV measurement was initiated while keeping the probe stationary. This was repeated for 3 to 6 times at the lesion center, and repeated for 3 to 5 times at the periphery of the lesion, with average SWV value calculated.

CEUS: CEUS was performed with the same system for ARFI imaging in the contrast mode, with the mechanical index adjusted to the appropriate state. SonoVue suspension (2.0 mL) was administered by bolus injection *via* the elbow vein, followed by rapid injection of 5 mL of normal saline. The patient was breathing steadily throughout the procedure. After imaging, the records were exported. Then, analysis software was used to plot the time intensity curve of the lesion and obtain the initial time, peak time, initial strength, peak intensity and 180-s echo intensity of the lesion. Subsequently, peak acceleration time, intensity increment, enhancement rate, and 180-s

dissipation rate were calculated.

Serological examination: An automatic biochemical analyzer was used for the quantitative analysis of the following serological indicators: AFP, serum fucosidase (AFU), alanine aminotransferase (ALT), aspartate aminotransferase (AST), γ -glutamyltranspeptidase (GGT), and alkaline phosphatase (ALP).

Statistical analysis

SPSS 17.0 statistical software was used for statistical analyses. Measurement data are presented as mean \pm SD. Comparison of data between groups was performed using two independent samples *t*-test. Indicators with statistically significant differences were used to construct the ROC curves to calculate the area under the curve (AUC), in order to investigate the diagnostic accuracy. Diagnostic accuracy was compared between different combinations to determine the value of combined diagnosis in identifying benign and malignant liver lesions.

RESULTS

Pathological results

Pathological or radiological diagnosis confirmed 78 cases of malignant tumors and 34 cases of benign tumors. Among these cases, 18 were primary liver cancer, 60 were metastatic cancer, 16 were hemangiomas, 11 were liver cysts, 5 were adenomas, and 2 were focal nodular hyperplasia.

Comparison of SWV values between malignant and benign tumor groups

SWV values were significantly higher in the malignant tumor group (2.39 ± 1.20 m/s, a typical image is shown in Figure 1A) than in the benign tumor group (1.50 ± 0.49 m/s, a typical image is shown in Figure 1B) ($P < 0.05$; Figure 2).

Comparison of serological indicators between malignant and benign tumor groups

AFP level was significantly higher in the malignant

Table 1 Comparison of serological indicators between the malignant and benign tumor groups

	AFP (ng/mL)	AFU (U/L)	ALT (U/L)	AST (U/L)	GGT (U/L)	ALP (U/L)
Malignant tumor group	18.02 ± 5.01	29.74 ± 14.22	39.01 ± 3.60	46.92 ± 12.11	62.40 ± 27.30	139.40 ± 85.90
Benign tumor group	15.96 ± 4.33	25.61 ± 13.11	37.90 ± 4.33	44.40 ± 11.60	54.90 ± 22.30	117.99 ± 57.30
<i>t</i> -value	2.081	1.446	1.705	1.409	1.409	1.328
<i>P</i> value	0.04	0.151	0.09	0.162	0.162	0.187

AFP: Alpha-fetoprotein; AFU: Serum fucosidase; ALT: Alanine aminotransferase; AST: Aspartate aminotransferase; ALP: Alkaline phosphatase; GGT: Glutamyltranspeptidase.

Table 2 Comparison of contrast-enhanced ultrasound parameters in the malignant and benign tumor groups

	Start time (s)	Initial strength (dB)	Peak time (s)	Peak intensity (dB)	120s Echo intensity (dB)	Peak acceleration time (s)	Intensity increment (dB)	Enhancement rate (dB/s)	Extinction rate (dB/s)
Malignant tumor group	11.98 ± 2.95	8.35 ± 6.03	30.22 ± 9.65	39.27 ± 6.32	27.33 ± 17.86	17.94 ± 4.64	30.99 ± 6.67	2.24 ± 0.21	0.08 ± 0.07
Benign tumor group	13.01 ± 3.92	6.57 ± 5.66	33.33 ± 11.96	37.77 ± 7.30	32.01 ± 11.96	20.10 ± 10.32	31.22 ± 7.12	2.01 ± 0.31	0.06 ± 0.06
<i>t</i> -value	-1.532	1.463	-1.456	1.101	-1.396	-1.533	-0.164	2.589	1.449
<i>P</i> value	0.128	0.146	0.148	0.273	0.166	0.128	0.870	0.011	0.150

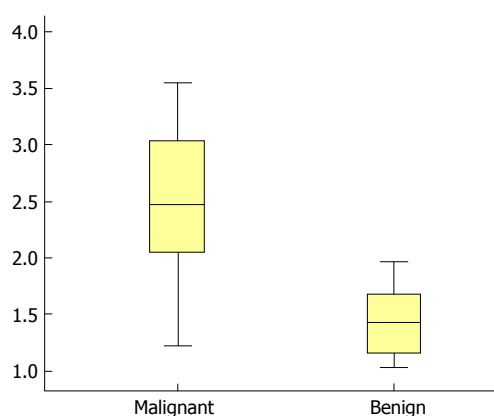


Figure 2 Shear wave velocity values of the malignant and benign tumor groups. The shear wave velocity of malignant tumors was 2.39 ± 1.20 m/s, while that of benign tumors was 1.50 ± 0.49 m/s.

tumor group than in the benign tumor group ($P < 0.05$), while the differences in AFU, ALT, AST, GGT and ALP levels were not statistically significant ($P > 0.05$) (Table 1).

Comparison of CEUS indicators between malignant and benign tumor groups

CEUS enhancement rate was significantly higher in the malignant tumor group than in the benign tumor group (a typical image is shown in Figure 3A and B) ($P < 0.05$), while the differences in start time, initial strength, peak time, peak intensity, 180-second echo intensity, peak acceleration time, strength increment, and rate of regression were not statistically significant ($P > 0.05$) (Table 2).

Diagnostic accuracy of different combinations of SWV value, AFP content and enhancement rate

SWV value, AFP content and enhancement rate were combined in the following different ways: SWV value

+ AFP content, SWV value + enhancement rate, AFP content + enhancement rate, and SWV value + AFP content + enhancement rate. Then, the ROC curves were constructed to calculate the AUCs. The AUCs of SWV value alone, AFP content alone, enhancement rate alone, SWV value + AFP content, SWV value + enhancement rate, AFP content + enhancement rate and SWV value + AFP content + enhancement rate were 85.1%, 72.1%, 74.5%, 88.3%, 90.4%, 82.0% and 92.3%, respectively. Taking the maximum value of the Youden index, SWV = 1.60 m/s, AFP = 18.68 ng/mL, and enhancement rate = 2.21 dB/s were determined as the best cut-off values for the diagnosis of benign and malignant liver lesions (Figures 4 and 5). When the cut-off value for the regression coefficient of the SWV value, AFP content and enhancement rate was 0.8711451, it was found that 23 cases were false-negative lesions, which included 11 cases of liver metastases derived from the digestive tract and 12 cases of hepatocellular carcinoma; and there were no false-positive lesions.

DISCUSSION

Pathological examination is the gold standard for diagnosing liver lesions. However, patient acceptance is low due to the invasiveness of the examination. Furthermore, pathological examination cannot be routinely used for screening of benign and malignant liver lesions. Serological indicators and CEUS are commonly used noninvasive examinations in clinical practice. However, serological indicators alone have a low sensitivity and specificity, and the CEUS examination process is complex and requires some skills^[18-21]. ARFI imaging is simple and can quantitatively reflect changes in tissue hardness. Studies have shown that ARFI can be used to diagnose benign and malignant

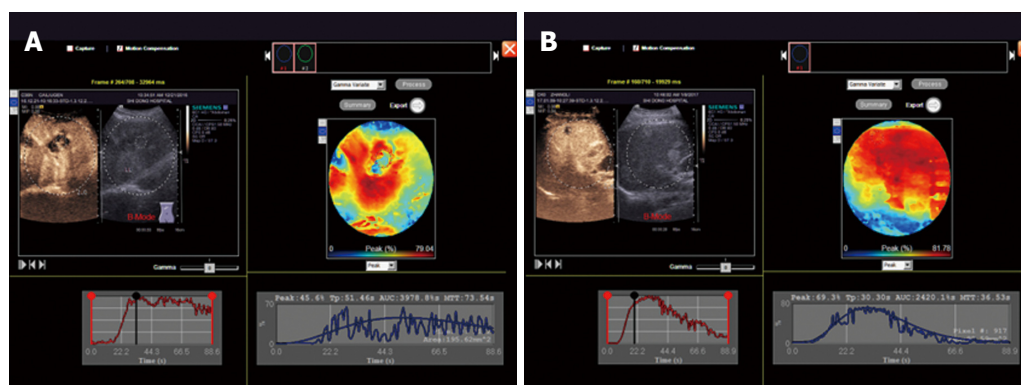


Figure 3 Contrast-enhanced ultrasound TIC curves used to detect benign and malignant liver tumors. A: TIC curve for the detection of malignant liver tumors; B: TIC curve for the detection of benign liver tumors.

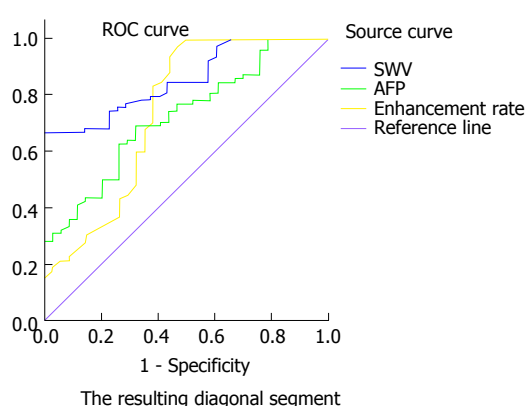


Figure 4 Comparison of the receiver operating characteristic curves of shear wave velocity, alpha-fetoprotein and enhancement rate for the identification of benign and malignant liver tumors.

liver tumors, but it is easily affected by bile ducts and large blood vessels^[22-29]. Thus, each of these three types of detection methods has its own advantages and disadvantages. Since the combined diagnosis has been widely used for other diseases at present, we hypothesized that the combination of these three kinds of examinations might have better accuracy in identifying benign and malignant liver lesions. Therefore, we constructed ROC curves to compare the diagnostic efficacy of ARFI imaging, serological indexes and CEUS, alone or in different combinations, in the present study.

Comparison of ARFI, serological parameters, CEUS indicators between malignant and benign tumor groups

Our results revealed that SWV value, AFP content and CEUS enhancement rate were significantly higher in the malignant tumor group than in the benign tumor group, suggesting that the use of these parameters is feasible for the differential diagnosis of benign and malignant liver lesions. Increased SWV value may indicate increased tumor hardness. This may be due to the richness of the liver cancer substance in tumor cells that sustains growth and promotes the invasion of capillaries, and the chaotic arrangement

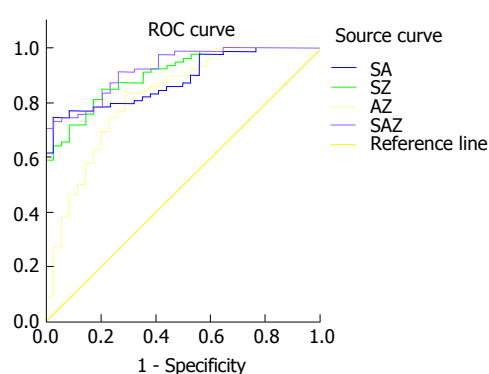


Figure 5 Comparison of the receiver operating characteristic curves of the combination of shear wave velocity value, alpha-fetoprotein content and enhancement rate for identifying benign and malignant liver tumors. SA = SWV value + AFP content; SZ = SWV value + enhancement rate; AZ = AFP content + enhancement rate; SAZ = SWV value + AFP content + enhancement rate.

of tissues that show invasive growth. Hence, activity in the surrounding tissue is limited, because the hardness of malignant liver tumors is greater than that of benign liver tumors. Elevated AFP content may be due to malignant liver cells, in which the AFP gene is re-expressed and AFP is released to blood. CEUS enhancement rate represents the rich blood supply of the tumor, because the number of microvessels per unit volume of malignant tumors is more than that of benign tumors, and the unit time into the malignant tumor contrast agent also increases. Hence, the enhancement rate is higher^[3,4,30-42]. The difference in AFP and CEUS enhancement rate between benign and malignant liver tumors can be expected, and the difference in SWV value between the two groups suggests that ARFI can also be used for the analysis of benign and malignant liver lesions.

Diagnostic accuracy of SWV value, AFP content and enhancement rate, alone or in different combinations, in distinguishing between malignant and benign tumors

The results of this study showed that the AUC of SWV value was slightly higher than that of CEUS enhancement rate and significantly higher than that of

AFP content. This finding suggests that the diagnostic value of ARFI is higher than that of CEUS enhancement rate and AFP content and the diagnostic value of ARFI is higher than that of AFP. This might be because the change in the texture of liver lesions is more sensitive than that of AFP content. The diagnostic value of CEUS is less than that of ARFI, and the reason may be that CEUS reflects the hemodynamics of liver lesions, while ARFI reflects changes in tissue hardness. Tissue hardness reflects not only the vascular composition of tissue, but also the interstitial fiber composition of tissue, cell arrangement and other factors. Hence, compared to CEUS, ARFI is more comprehensive and intuitive.

The results of this study showed that the diagnostic accuracy of combined SWV value, AFP content and enhancement rate was slightly higher than that of SWV value plus AFP content and SWV value plus enhancement rate, and significantly higher than that of AFP content plus enhancement rate and any one of the three parameters. When the cut-off value for the regression coefficient of the SWV value, AFP content and enhancement rate was 0.8711451, the best diagnostic performance was achieved. With this cut-off value, the results of this study revealed that nine cases of hepatocellular carcinoma were false-negative lesions, which may have been transformed through liver cirrhosis to stage I liver cancer, in which the tumor composition was less obvious. Furthermore, SWV value and AFP content were low, which may be related to the partial necrosis in the tumor component. These led to the low SWV value, AFP content and enhancement rate regression coefficient, and then the false negative results were obtained. Meanwhile, studies have shown that the stiffness of hepatocellular carcinoma and cholangiocarcinoma is greater than that of liver metastases. Furthermore, metastatic carcinoma derived from the digestive tract has lower hardness, and AFP content is lower than the content of liver parenchyma. This led to low SWV value, AFP content and enhancement rate of regression coefficient, and then false negative results were obtained^[43-51].

The results of this study were based on data from a small sample and did not cover all types of malignant and benign liver tumors. Therefore, the results of this study should be explained with caution, especially in clinical settings. However, the clinical pathological types of liver lesions studied in this study are common and have certain representative significance. Multi-center studies with a larger sample should be performed to verify our findings.

In summary, the diagnostic performance of combined ARFI, AFP and contrast-enhanced ultrasound in distinguishing between benign and malignant liver lesions was higher than the use of any single parameter or the combination of any two of parameters. It is expected that this would provide a tool for the differential diagnosis of benign and malignant liver lesions.

COMMENTS

Background

The gold standard for identifying benign and malignant liver lesions is pathological diagnosis. However, due to its invasiveness, the presence of infection, bleeding and other risks, pathological examination may cause body damage. Hence, pathological examination is only suitable for patients with suspected liver malignancy. In addition, pathological diagnosis has many contraindications and is applicable in only a narrow range of patients. Thus, it is difficult to implement pathological diagnosis as a routine examination.

Research frontiers

Serological indicators and contrast-enhanced ultrasound (CEUS) are noninvasive routine examinations for both benign and malignant liver lesions. Serological indicators alone have a low specificity and sensitivity. CEUS is a well-established examination method; however, it is relatively complex to operate and has high technical requirements, and some patients cannot tolerate the contrast agent. Acoustic radiation force impulse (ARFI) imaging is simple to operate, has high patient acceptance, and can quantitatively reflect the change in tissue hardness; however, it is easily affected by bile ducts and large blood vessels. The diagnostic value of the combined of ARFI imaging, serological indicators, and CEUS remains unclear.

Innovations and breakthroughs

Although ARFI imaging, serological indexes and CEUS have certain value in identifying benign and malignant lesions, each has its limitations. At present, the diagnostic accuracy of the combination of these three kinds of examinations in identifying benign and malignant liver lesions remains unknown, although the combined diagnosis has been widely used for other diseases. The results of this study showed that the diagnostic performance of combined ARFI, serum alpha-fetoprotein (AFP) and contrast-enhanced ultrasound in distinguishing between benign and malignant liver lesions was higher than the use of any single parameter or the combination of any two of parameters.

Applications

It is expected that the combination of ARFI imaging, serological indicators and CEUS would provide a tool for the differential diagnosis of benign and malignant liver lesions.

Peer-review

The combination of acoustic radiation force impulse imaging, serological indicators, and contrast-enhanced ultrasound has high accuracy in identifying benign and malignant liver lesions. This result should be confirmed by large multi-center studies, in order to better promote its clinical use.

REFERENCES

- 1 **Park SJ**, Jang JY, Jeong SW, Cho YK, Lee SH, Kim SG, Cha SW, Kim YS, Cho YD, Kim HS, Kim BS, Park S, Bang HI. Usefulness of AFP, AFP-L3, and PIVKA-II, and their combinations in diagnosing hepatocellular carcinoma. *Medicine* (Baltimore) 2017; **96**: e5811 [PMID: 28296720 DOI: 10.1097/md.00000000000005811]
- 2 **Best J**, Bilgi H, Heider D, Schotten C, Manka P, Bedreli S, Gorray M, Ertle J, van Grunsven LA, Dechêne A. The GALAD scoring algorithm based on AFP, AFP-L3, and DCP significantly improves detection of BCLC early stage hepatocellular carcinoma. *Z Gastroenterol* 2016; **54**: 1296-1305 [PMID: 27936479 DOI: 10.1055/s-0042-119529]
- 3 **D'Onofrio M**, Romanini L, Serra C, Magnolfi F, Bertolotto M, Quaia E, Puntel G, Colleoni A, Fiorini E, Cenci C, Santi E, Ciaravino V, Laffranchi F, Catalano O, Cantisani V, Calliada F, Derchi L. Contrast enhancement ultrasound application in focal liver lesions characterization: a retrospective study about guidelines application (SOCEUS-CEUS survey). *J Ultrasound* 2015; **19**: 99-106 [PMID: 27298641 DOI: 10.1007/s40477-015-0185-y]
- 4 **Iwamoto T**, Imai Y, Kogita S, Igura T, Sawai Y, Fukuda K, Yamaguchi Y, Matsumoto Y, Nakahara M, Morimoto O, Seki Y, Ohashi H, Fujita N, Kudo M, Takehara T. Comparison of

- Contrast-Enhanced Ultrasound and Gadolinium-Ethoxybenzyl-Diethylenetriamine Pentaacetic Acid-Enhanced MRI for the Diagnosis of Macroscopic Type of Hepatocellular Carcinoma. *Dig Dis* 2016; **34**: 679-686 [PMID: 27750237 DOI: 10.1159/000448855]
- 5 **Kondo S**, Takagi K, Nishida M, Iwai T, Kudo Y, Ogawa K, Kamiyama T, Shibuya H, Kahata K, Shimizu C. Computer-Aided Diagnosis of Focal Liver Lesions Using Contrast-Enhanced Ultrasonography with Perflubutane Microbubbles. *IEEE Trans Med Imaging* 2017; **36**: 1427-1437 [PMID: 28141517 DOI: 10.1109/TMI.2017.2659734]
- 6 **Loria F**, Loria G, Basile S, Crea G, Frosina L, Di Carlo I. Contrast-enhanced ultrasound appearances of enhancement patterns of intrahepatic cholangiocarcinoma: correlation with pathological findings. *Updates Surg* 2014; **66**: 135-143 [PMID: 24802031 DOI: 10.1007/s13304-014-0251-6]
- 7 **Roche V**, Pigneur F, Tselikas L, Roux M, Baranes L, Djabbari M, Costentin C, Calderaro J, Laurent A, Rahmouni A, Luciani A. Differentiation of focal nodular hyperplasia from hepatocellular adenomas with low-mechanical-index contrast-enhanced sonography (CEUS): effect of size on diagnostic confidence. *Eur Radiol* 2015; **25**: 186-195 [PMID: 25120205 DOI: 10.1007/s00330-014-3363-y]
- 8 **Sparchez Z**, Mocan T, Radu P, Anton O, Bolog N. Contrast enhanced ultrasonography in assessing the treatment response to transarterial chemoembolization in patients with hepatocellular carcinoma. *Med Ultrason* 2016; **18**: 96-102 [PMID: 26962561 DOI: 10.11152/mu.2013.2066.181.scz]
- 9 **Tselikas L**, Pigneur F, Roux M, Baranes L, Costentin C, Roche V, Calderaro J, Herin E, Laurent A, Zafrani E, Azoulay D, Mallat A, Rahmouni A, Luciani A. Impact of hepatobiliary phase liver MRI versus Contrast-Enhanced Ultrasound after an inconclusive extracellular gadolinium-based contrast-enhanced MRI for the diagnosis of benign hepatocellular tumors. *Abdom Radiol (NY)* 2017; **42**: 825-832 [PMID: 27704147 DOI: 10.1007/s00261-016-0921-6]
- 10 **Bao Z**, Gu L, Liu J, Wei L, Ye Z. [Clinical value of acoustic radiation force impulse elastography in differential diagnosis of focal liver lesions]. *Zhonghua Ganzangbing Zazhi* 2016; **24**: 123-126 [PMID: 26983480]
- 11 **Cho SH**, Lee JY, Han JK, Choi BI. Acoustic radiation force impulse elastography for the evaluation of focal solid hepatic lesions: preliminary findings. *Ultrasound Med Biol* 2010; **36**: 202-208 [PMID: 20018432 DOI: 10.1016/j.ultrasmedbio.2009.10.009]
- 12 **Davies G**, Koenen M. Acoustic radiation force impulse elastography in distinguishing hepatic haemangiomas from metastases: preliminary observations. *Br J Radiol* 2011; **84**: 939-943 [PMID: 21385910 DOI: 10.1259/bjr/97637841]
- 13 **Fahey BJ**, Nelson RC, Hsu SJ, Bradway DP, Dumont DM, Trahey GE. In vivo guidance and assessment of liver radio-frequency ablation with acoustic radiation force elastography. *Ultrasound Med Biol* 2008; **34**: 1590-1603 [PMID: 18471954 DOI: 10.1016/j.ultrasmedbio.2008.03.006]
- 14 **Frulio N**, Laumonier H, Carteret T, Laurent C, Maire F, Balabaud C, Bioulac-Sage P, Trillaud H. Evaluation of liver tumors using acoustic radiation force impulse elastography and correlation with histologic data. *J Ultrasound Med* 2013; **32**: 121-130 [PMID: 23269717]
- 15 **Gallotti A**, D'Onofrio M, Romanini L, Cantisani V, Pozzi Mucelli R. Acoustic Radiation Force Impulse (ARFI) ultrasound imaging of solid focal liver lesions. *Eur J Radiol* 2012; **81**: 451-455 [PMID: 21330078 DOI: 10.1016/j.ejrad.2010.12.071]
- 16 **Goya C**, Hamidi C, Yavuz A, Hattapoglu S, Uslukaya O, Cetinckmak MG, Teke M, Urakci Z. The Role of Acoustic Radiation Force Impulse Elastography in the Differentiation of Infectious and Neoplastic Liver Lesions. *Ultrason Imaging* 2015; **37**: 312-322 [PMID: 25568051 DOI: 10.1177/0161734614566697]
- 17 **Heide R**, Strobel D, Bernatik T, Goertz RS. Characterization of focal liver lesions (FLL) with acoustic radiation force impulse (ARFI) elastometry. *Ultraschall Med* 2010; **31**: 405-409 [PMID: 20652853 DOI: 10.1055/s-0029-1245565]
- 18 **Chen L**, Chu F, Cao Y, Shao J, Wang F. Serum miR-182 and miR-331-3p as diagnostic and prognostic markers in patients with hepatocellular carcinoma. *Tumour Biol* 2015; **36**: 7439-7447 [PMID: 25903466 DOI: 10.1007/s13277-015-3430-2]
- 19 **Chen QW**, Cheng CS, Chen H, Ning ZY, Tang SF, Zhang X, Zhu XY, Vargulick S, Shen YH, Hua YQ, Xie J, Shi WD, Gao HF, Xu LT, Feng LY, Lin JH, Chen Z, Liu LM, Ping B, Meng ZQ. Effectiveness and complications of ultrasound guided fine needle aspiration for primary liver cancer in a Chinese population with serum α -fetoprotein levels ≤ 200 ng/ml--a study based on 4,312 patients. *PLoS One* 2014; **9**: e101536 [PMID: 25170868 DOI: 10.1371/journal.pone.0101536]
- 20 **Cui Z**, Yu X, Guo L, Wei Y, Zheng S, Li W, Chen P, Zhu J, Peng J. Combined analysis of serum alpha-fetoprotein and MAGE-A3-specific cytotoxic T lymphocytes in peripheral blood for diagnosis of hepatocellular carcinoma. *Dis Markers* 2013; **35**: 915-923 [PMID: 24427779]
- 21 **Song P**, Feng X, Inagaki Y, Song T, Zhang K, Wang Z, Zheng S, Ma K, Li Q, Kong D, Wu Q, Zhang T, Zhao X, Hasegawa K, Sugawara Y, Kokudo N, Tang W; Japan-China Joint Team for Medical Research and Cooperation on HCC. Clinical utility of simultaneous measurement of alpha-fetoprotein and des- γ -carboxy prothrombin for diagnosis of patients with hepatocellular carcinoma in China: A multi-center case-controlled study of 1,153 subjects. *Biosci Trends* 2014; **8**: 266-273 [PMID: 25382443]
- 22 **Kim JE**, Lee JY, Bae KS, Han JK, Choi BI. Acoustic radiation force impulse elastography for focal hepatic tumors: usefulness for differentiating hemangiomas from malignant tumors. *Korean J Radiol* 2013; **14**: 743-753 [PMID: 24043967 DOI: 10.3348/kjr.2013.14.5.743]
- 23 **Kwon HJ**, Kang MJ, Cho JH, Oh JY, Nam KJ, Han SY, Lee SW. Acoustic radiation force impulse elastography for hepatocellular carcinoma-associated radiofrequency ablation. *World J Gastroenterol* 2011; **17**: 1874-1878 [PMID: 21528062 DOI: 10.3748/wjg.v17.i14.1874]
- 24 **Mărginean CO**, Brănzaniuc K, Mărginean C, Azamfirei L, Pitea AM. Elastography, progression factor in liver ultrasound. *Rev Med Chir Soc Med Nat Iasi* 2010; **114**: 764-770 [PMID: 21235119]
- 25 **Rizzo L**, Nunnari G, Berretta M, Cacopardo B. Acoustic Radial Force Impulse as an effective tool for a prompt and reliable diagnosis of hepatocellular carcinoma - preliminary data. *Eur Rev Med Pharmacol Sci* 2012; **16**: 1596-1598 [PMID: 23111977]
- 26 **Shuang-Ming T**, Ping Z, Ying Q, Li-Rong C, Ping Z, Rui-Zhen L. Usefulness of acoustic radiation force impulse imaging in the differential diagnosis of benign and malignant liver lesions. *Acad Radiol* 2011; **18**: 810-815 [PMID: 21419668 DOI: 10.1016/j.acra.2011.01.026]
- 27 **Vermehren J**, Polta A, Zimmermann O, Herrmann E, Poynard T, Hofmann WP, Bojunga J, Sarrazin C, Zeuzem S, Friedrich-Rust M. Comparison of acoustic radiation force impulse imaging with transient elastography for the detection of complications in patients with cirrhosis. *Liver Int* 2012; **32**: 852-858 [PMID: 22222050 DOI: 10.1111/j.1478-3231.2011.02736.x]
- 28 **Ying L**, Lin X, Xie ZL, Tang FY, Hu YP, Shi KQ. Clinical utility of acoustic radiation force impulse imaging for identification of malignant liver lesions: a meta-analysis. *Eur Radiol* 2012; **22**: 2798-2805 [PMID: 22772145 DOI: 10.1007/s00330-012-2540-0]
- 29 **Yu H**, Wilson SR. Differentiation of benign from malignant liver masses with Acoustic Radiation Force Impulse technique. *Ultrasound Q* 2011; **27**: 217-223 [PMID: 22124386 DOI: 10.1097/RUQ.0b013e318239422e]
- 30 **Dong Y**, Wang WP, Mao F, Ji ZB, Huang BJ. Application of imaging fusion combining contrast-enhanced ultrasound and magnetic resonance imaging in detection of hepatic cellular carcinomas undetectable by conventional ultrasound. *J Gastroenterol Hepatol* 2016; **31**: 822-828 [PMID: 26480287 DOI: 10.1111/jgh.13202]
- 31 **Dong Y**, Zhu Z, Wang WP, Mao F, Ji ZB. Ultrasound features of hepatocellular adenoma and the additional value of contrast-enhanced ultrasound. *Hepatobiliary Pancreat Dis Int* 2016; **15**: 48-54 [PMID: 26818543]

- 32 **Kong WT**, Ji ZB, Wang WP, Cai H, Huang BJ, Ding H. Evaluation of Liver Metastases Using Contrast-Enhanced Ultrasound: Enhancement Patterns and Influencing Factors. *Gut Liver* 2016; **10**: 283-287 [PMID: 26586554 DOI: 10.5009/gnl14324]
- 33 **Li R**, Tang CL, Cai P, Ma KS, Zhang XH, Ding SY, Zhang Y, Guo DY, Yan XC. Comparison of CT and contrast-enhanced ultrasound findings in hepatic angiomyolipoma with pathological correlations. *Abdom Radiol (NY)* 2016; **41**: 248-256 [PMID: 26867906 DOI: 10.1007/s00261-015-0571-0]
- 34 **Liang X**, Lin L, Cao Q, Huang R, Wang Y. Recognizing Focal Liver Lesions in CEUS With Dynamically Trained Latent Structured Models. *IEEE Trans Med Imaging* 2016; **35**: 713-727 [PMID: 26513779 DOI: 10.1109/tmi.2015.2492618]
- 35 **Liu JJ**, Li HX, Chen ZB, Yang WP, Zhao SF, Chen J, Bai T, Li H, Li LQ. Consistency analysis of contrast-enhanced ultrasound and contrast-enhanced CT in diagnosis of small hepatocellular carcinoma. *Int J Clin Exp Med* 2015; **8**: 21466-21471 [PMID: 26885093]
- 36 **Menozi G**, Maccabruni V, Marini G, Froio E, Garlassi E. Contrast-enhanced ultrasound (CEUS) appearance of hepatic myelolipoma. *J Ultrasound* 2014; **19**: 61-65 [PMID: 26941876 DOI: 10.1007/s40477-014-0137-y]
- 37 **Seitz K**, Strobel D. A Milestone: Approval of CEUS for Diagnostic Liver Imaging in Adults and Children in the USA. *Ultraschall Med* 2016; **37**: 229-232 [PMID: 27276056 DOI: 10.1055/s-0042-107411]
- 38 **Shiozawa K**, Watanabe M, Ikehara T, Matsukiyo Y, Kogame M, Shinohara M, Kikuchi Y, Shinohara M, Igarashi Y, Sumino Y. [Evaluation of Sorafenib for Hepatocellular Carcinoma with Low α -Fetoprotein by Arrival Time Parametric Imaging Using Contrast-Enhanced Ultrasonography with Sonazoid]. *Gan To Kagaku Ryoho* 2016; **43**: 215-218 [PMID: 27067685]
- 39 **Sirli R**, Sporea I, Săndulescu DL, Popescu A, Dănilă M, Săftoiu A, Spârchez Z, Badea R. Contrast enhanced ultrasound for the diagnosis of liver hemangiomas - results of a Romanian multicentre study. *Med Ultrason* 2015; **17**: 444-450 [PMID: 26649337 DOI: 10.11152/mu.2013.2066.174.csu]
- 40 **Spârchez Z**, Radu P, Kacso G, Spârchez M, Zaharia T, Al Hajjar N. Prospective comparison between real time contrast enhanced and conventional ultrasound guidance in percutaneous biopsies of liver tumors. *Med Ultrason* 2015; **17**: 456-463 [PMID: 26649339 DOI: 10.11152/mu.2013.2066.174.deu]
- 41 **Sugimori K**, Numata K, Okada M, Nihonmatsu H, Takebayashi S, Maeda S, Nakano M, Tanaka K. Central vascular structures as a characteristic finding of regenerative nodules using hepatobiliary phase gadolinium ethoxybenzyl diethylenetriaminepentaacetic acid-enhanced MRI and arterial dominant phase contrast-enhanced US. *J Med Ultrason* (2001) 2017; **44**: 89-100 [PMID: 27771842 DOI: 10.1007/s10396-016-0750-9]
- 42 **Yang W**, Yan K, Wang S, Dai Y, Wu W, Yin SS, Chen MH. Differential Diagnosis of Arterial Phase Enhanced Hepatic Inflammatory Lesions and Hepatocellular Carcinomas with Contrast-enhanced Ultrasound. *Ultrasound Med Biol* 2016; **42**: 82-91 [PMID: 26456578 DOI: 10.1016/j.ultrasmedbio.2015.07.014]
- 43 **Beyer LP**, Pregler B, Wiesinger I, Stroszczynski C, Wiggermann P, Jung EM. Continuous dynamic registration of microvascularization of liver tumors with contrast-enhanced ultrasound. *Radiol Res Pract* 2014; **2014**: 347416 [PMID: 24991432 DOI: 10.1155/2014/347416]
- 44 **Corvino A**, Catalano O, Setola SV, Sandomenico F, Corvino F, Petrillo A. Contrast-enhanced ultrasound in the characterization of complex cystic focal liver lesions. *Ultrasound Med Biol* 2015; **41**: 1301-1310 [PMID: 25666723 DOI: 10.1016/j.ultrasmedbio.2014.12.667]
- 45 **Gatos I**, Tsantis S, Spiliopoulos S, Skouroliaou A, Theotokas I, Zoumpoulis P, Hazle JD, Kagadis GC. A new automated quantification algorithm for the detection and evaluation of focal liver lesions with contrast-enhanced ultrasound. *Med Phys* 2015; **42**: 3948-3959 [PMID: 26133595 DOI: 10.1118/1.4921753]
- 46 **Liu J**, Wang D, Li H, Li H, Zhou T, Zhao S, Ding Z. Clinical Value of Contrast-Enhanced Ultrasound in Diagnosis of Hyperechoic Liver Lesions. *Med Sci Monit* 2015; **21**: 2845-2850 [PMID: 26394170 DOI: 10.12659/msm.894115]
- 47 **Lyu P**, Li S, Xu H, Xu L, Lyu J, Shou J, Zhao B. [Application value of contrast-enhanced ultrasonography for assessing the high-risk population of hepatic malignant tumor]. *Zhonghua Zhongliu Zazhi* 2015; **37**: 545-548 [PMID: 26463334]
- 48 **Pschierer K**, Grothues D, Rennert J, da Silva NP, Schreyer AG, Melter M, Stroszczynski C, Jung EM. Evaluation of the diagnostic accuracy of CEUS in children with benign and malignant liver lesions and portal vein anomalies. *Clin Hemorheol Microcirc* 2015; **61**: 333-345 [PMID: 26444615 DOI: 10.3233/ch-152003]
- 49 **Sporea I**, Martie A, Bota S, Sirli R, Popescu A, Dănilă M. Characterization of focal liver lesions using contrast enhanced ultrasound as a first line method: a large monocentric experience. *J Gastrointest Liver Dis* 2014; **23**: 57-63 [PMID: 24689098 DOI: 10.3748/wjg.v20.i13.3590]
- 50 **Tarantino L**, Ambrosino P, Di Minno MN. Contrast-enhanced ultrasound in differentiating malignant from benign portal vein thrombosis in hepatocellular carcinoma. *World J Gastroenterol* 2015; **21**: 9457-9460 [PMID: 26327753 DOI: 10.3748/wjg.v21.i32.9457]
- 51 **Kim TK**, Jang HJ. Contrast-enhanced ultrasound in the diagnosis of nodules in liver cirrhosis. *World J Gastroenterol* 2014; **20**: 3590-3596 [PMID: 24707142 DOI: 10.3748/wjg.v20.i13.3590]

P- Reviewer: Hoetker MS, Meropol NJ **S- Editor:** Qi Y
L- Editor: Wang TQ **E- Editor:** Li D





Published by **Baishideng Publishing Group Inc**
7901 Stoneridge Drive, Suite 501, Pleasanton, CA 94588, USA
Telephone: +1-925-223-8242
Fax: +1-925-223-8243
E-mail: bpgoffice@wjgnet.com
Help Desk: <http://www.f6publishing.com/helpdesk>
<http://www.wjgnet.com>



ISSN 1007-9327

