

World Journal of *Gastroenterology*

World J Gastroenterol 2017 November 28; 23(44): 7813-7944



**EDITORIAL**

- 7813 Advances in endoscopic balloon therapy for weight loss and its limitations

Vyas D, Deshpande K, Pandya Y

ORIGINAL ARTICLE**Basic Study**

- 7818 Prediction of early-stage hepatocellular carcinoma using OncoScan chromosomal copy number aberration data

Yu MC, Lee CW, Lee YS, Lian JH, Tsai CL, Liu YP, Wu CH, Tsai CN

- 7830 Composition and immuno-stimulatory properties of extracellular DNA from mouse gut flora

Qi C, Li Y, Yu RQ, Zhou SL, Wang XG, Le GW, Jin QZ, Xiao H, Sun J

Case Control Study

- 7840 Transmitted cardiovascular pulsations on high resolution esophageal impedance manometry, and their significance in dysphagia

Chaudhry NA, Zahid K, Keihanian S, Dai Y, Zhang Q

- 7849 Intestinal parameters of oxidative imbalance in celiac adults with extraintestinal manifestations

Piatek-Guziewicz A, Ptak-Belowska A, Przybylska-Felus M, Pasko P, Zagrodzki P, Brzozowski T, Mach T, Zwolinska-Wcislo M

Retrospective Study

- 7863 Prediction of hepatocellular carcinoma development by aminotransferase to platelet ratio index in primary biliary cholangitis

Cheung KS, Seto WK, Fung J, Mak LY, Lai CL, Yuen MF

Clinical Trials Study

- 7875 Role of combined propofol and sufentanil anesthesia in endoscopic injection sclerotherapy for esophageal varices

Yu Y, Qi SL, Zhang Y

Observational Study

- 7881 Health disparities are associated with gastric cancer mortality-to-incidence ratios in 57 countries

Tsai MC, Wang CC, Lee HL, Peng CM, Yang TW, Chen HY, Sung WW, Lin CC

- 7888 Circulating miR-125a but not miR-125b is decreased in active disease status and negatively correlates with disease severity as well as inflammatory cytokines in patients with Crohn's disease

Sun CM, Wu J, Zhang H, Shi G, Chen ZT

Prospective Study

- 7899 Dramatic response of hepatitis C patients chronically infected with hepatitis C virus genotype 3 to sofosbuvir-based therapies in Punjab, Pakistan: A prospective study

Iqbal S, Yousuf MH, Yousaf MI

META-ANALYSIS

- 7906 Short-term clinical outcomes of laparoscopic vs open rectal excision for rectal cancer: A systematic review and meta-analysis

Martínez-Pérez A, Carra MC, Brunetti F, de'Angelis N

- 7917 Anterior vs conventional approach right hepatic resection for large hepatocellular carcinoma: A systematic review and meta-analysis

Tang JX, Li JJ, Weng RH, Liang ZM, Jiang N

CASE REPORT

- 7930 Metabolically based liver damage pathophysiology in patients with urea cycle disorders - A new hypothesis

Ivanovski I, Ješić M, Ivanovski A, Garavelli L, Ivanovski P

- 7939 First case of cross-auxiliary double domino donor liver transplantation

Zhu ZJ, Wei L, Qu W, Sun LY, Liu Y, Zeng ZG, Zhang L, He EH, Zhang HM, Jia JD, Zhang ZT

ABOUT COVER

Editorial board member of *World Journal of Gastroenterology*, Vitaly Skoropad, DSc, MD, PhD, Associate Professor, Department of Abdominal Oncology, Federal State Institution "Medical Radiological Research Center" of the Russian Ministry of Health, Obninsk 249036, Kaluga region, Russia

AIMS AND SCOPE

World Journal of Gastroenterology (*World J Gastroenterol*, *WJG*, print ISSN 1007-9327, online ISSN 2219-2840, DOI: 10.3748) is a peer-reviewed open access journal. *WJG* was established on October 1, 1995. It is published weekly on the 7th, 14th, 21st, and 28th each month. The *WJG* Editorial Board consists of 1375 experts in gastroenterology and hepatology from 68 countries.

The primary task of *WJG* is to rapidly publish high-quality original articles, reviews, and commentaries in the fields of gastroenterology, hepatology, gastrointestinal endoscopy, gastrointestinal surgery, hepatobiliary surgery, gastrointestinal oncology, gastrointestinal radiation oncology, gastrointestinal imaging, gastrointestinal interventional therapy, gastrointestinal infectious diseases, gastrointestinal pharmacology, gastrointestinal pathophysiology, gastrointestinal pathology, evidence-based medicine in gastroenterology, pancreatology, gastrointestinal laboratory medicine, gastrointestinal molecular biology, gastrointestinal immunology, gastrointestinal microbiology, gastrointestinal genetics, gastrointestinal translational medicine, gastrointestinal diagnostics, and gastrointestinal therapeutics. *WJG* is dedicated to become an influential and prestigious journal in gastroenterology and hepatology, to promote the development of above disciplines, and to improve the diagnostic and therapeutic skill and expertise of clinicians.

INDEXING/ABSTRACTING

World Journal of Gastroenterology (*WJG*) is now indexed in Current Contents[®]/Clinical Medicine, Science Citation Index Expanded (also known as SciSearch[®]), Journal Citation Reports[®], Index Medicus, MEDLINE, PubMed, PubMed Central and Directory of Open Access Journals. The 2017 edition of Journal Citation Reports[®] cites the 2016 impact factor for *WJG* as 3.365 (5-year impact factor: 3.176), ranking *WJG* as 29th among 79 journals in gastroenterology and hepatology (quartile in category Q2).

FLYLEAF

I-IX Editorial Board

EDITORS FOR THIS ISSUE

Responsible Assistant Editor: Xiang Li
Responsible Electronic Editor: Yin-Jie Ma
Proofing Editor-in-Chief: Lian-Sheng Ma

Responsible Science Editor: Ze-Mao Gong
Proofing Editorial Office Director: Jin-Lei Wang

NAME OF JOURNAL
World Journal of Gastroenterology

ISSN
ISSN 1007-9327 (print)
ISSN 2219-2840 (online)

LAUNCH DATE
October 1, 1995

FREQUENCY
Weekly

EDITORS-IN-CHIEF
Damian Garcia-Olmo, MD, PhD, Doctor, Professor, Surgeon, Department of Surgery, Universidad Autonoma de Madrid; Department of General Surgery, Fundacion Jimenez Diaz University Hospital, Madrid 28040, Spain

Stephen C Strom, PhD, Professor, Department of Laboratory Medicine, Division of Pathology, Karolinska Institutet, Stockholm 141-86, Sweden

Andrzej S Tarnawski, MD, PhD, DSc (Med), Professor of Medicine, Chief Gastroenterology, VA Long Beach Health Care System, University of California, Irvine, CA, 5901 E. Seventh Str., Long Beach,

CA 90822, United States

EDITORIAL BOARD MEMBERS
All editorial board members resources online at <http://www.wjgnet.com/1007-9327/editorialboard.htm>

EDITORIAL OFFICE
Jin-Lei Wang, Director
Ze-Mao Gong, Vice Director
World Journal of Gastroenterology
Baishideng Publishing Group Inc
7901 Stoneridge Drive, Suite 501,
Pleasanton, CA 94588, USA
Telephone: +1-925-2238242
Fax: +1-925-2238243
E-mail: editorialoffice@wjgnet.com
Help Desk: <http://www.f6publishing.com/helpdesk>
<http://www.wjgnet.com>

PUBLISHER
Baishideng Publishing Group Inc
7901 Stoneridge Drive, Suite 501,
Pleasanton, CA 94588, USA
Telephone: +1-925-2238242
Fax: +1-925-2238243
E-mail: bpgoffice@wjgnet.com
Help Desk: <http://www.f6publishing.com/helpdesk>
<http://www.wjgnet.com>

PUBLICATION DATE
November 28, 2017

COPYRIGHT
© 2017 Baishideng Publishing Group Inc. Articles published by this Open-Access journal are distributed under the terms of the Creative Commons Attribution Non-commercial License, which permits use, distribution, and reproduction in any medium, provided the original work is properly cited, the use is non commercial and is otherwise in compliance with the license.

SPECIAL STATEMENT
All articles published in journals owned by the Baishideng Publishing Group (BPG) represent the views and opinions of their authors, and not the views, opinions or policies of the BPG, except where otherwise explicitly indicated.

INSTRUCTIONS TO AUTHORS
Full instructions are available online at <http://www.wjgnet.com/bpg/gerinfo/204>

ONLINE SUBMISSION
<http://www.f6publishing.com>

Case Control Study

Transmitted cardiovascular pulsations on high resolution esophageal impedance manometry, and their significance in dysphagia

Naeen A Chaudhry, Kamran Zahid, Sara Keihanian, Yunfeng Dai, Qing Zhang

Naeen A Chaudhry, Sara Keihanian, Qing Zhang, Department of Medicine, Division of Gastroenterology, University of Florida, Gainesville, FL 32610, United States

Kamran Zahid, Department of Medicine, Division of Hospital Medicine, University of Florida, Gainesville, FL 32610, United States

Yunfeng Dai, Department of Biostatistics, University of Florida, Gainesville, FL 32610, United States

ORCID number: Naeen A Chaudhry (0000-0001-6662-8181); Kamran Zahid (0000-0002-1288-4072); Sara Keihanian (0000-0002-9933-0274); Yunfeng Dai (0000-0003-3961-4766); Qing Zhang (0000-0001-9688-8910).

Author contributions: Chaudhry NA was responsible for study planning and design, collecting and compiling, and also did preliminary statistical analysis. She also compiled the manuscript, tables and images; Zahid K assisted in data collection, and manuscript compilation; Keihanian S provided feedback during manuscript compilation and also was part of the final approval of the manuscript; Dai Y was responsible for the final data analysis and review; Zhang Q was responsible for study planning and design, review of analytical process, feedback during manuscript compilation, and approval of the final manuscript.

Institutional review board statement: The study was approved by the Institutional Review Board of the University of Florida.

Informed consent statement: The informed consent was waived by the IRB due to the retrospective nature of the study.

Conflict-of-interest statement: No potential conflicts of interest relevant to this article were reported.

Data sharing statement: Statistical code and anonymized data set available from the corresponding author at naeen.chaudhry@medicine.ufl.edu. The stipulation for informed consent was waived by IRB due to the retrospective design of the study. No other data besides the one included in the manuscript are

available.

Open-Access: This article is an open-access article which was selected by an in-house editor and fully peer-reviewed by external reviewers. It is distributed in accordance with the Creative Commons Attribution Non Commercial (CC BY-NC 4.0) license, which permits others to distribute, remix, adapt, build upon this work non-commercially, and license their derivative works on different terms, provided the original work is properly cited and the use is non-commercial. See: <http://creativecommons.org/licenses/by-nc/4.0/>

Manuscript source: Unsolicited manuscript

Correspondence to: Naeen A Chaudhry, Post-Doctoral Fellow, University of Florida, Gainesville, FL 32610, United States. naeen.chaudhry@medicine.ufl.edu
Telephone: +1-609-7513330
Fax: +1-352-6279002

Received: May 12, 2017

Peer-review started: May 16, 2017

First decision: July 27, 2017

Revised: August 8, 2017

Accepted: September 13, 2017

Article in press: September 13, 2017

Published online: November 28, 2017

Abstract

AIM

To investigate the behavior of pulsatile pressure zones (PPZ's) as noted on high resolution esophageal impedance manometry (HREIM), and determine their association with dysphagia.

METHODS

Retrospective, single center case control design scr-

eenening HREIM studies for cases (dysphagia) and controls (no dysphagia). Thoracic radiology studies were reviewed further in cases for (thoracic cardiovascular) thoracic cardiovascular (TCV) structures in esophageal proximity to compare with HREIM findings. Manometric data was collected for number, location, axial length, PPZ pressure and esophageal clearance function (impedance).

RESULTS

Among 317 screened patients, 56% cases and 64% controls had PPZ's. Fifty cases had an available thoracic radiology comparison. The distribution of PPZ's in these 50 cases and 59 controls was similar (average 1.4 PPZ/patient). Controls (mean 31.2 \pm SD 12 years) were a significantly younger population than cases (mean 67.3 \pm SD 14.9 years) with $P < 0.0001$. The upright posture PPZ pressure was higher in controls (15.7 \pm 10.0 mmHg) than cases (10.8 \pm 9.7 mmHg). Although statistically significant ($P = 0.005$), it was a weak predictor using logistic regression and ROC model (AUC = 0.65). Three dysphagia patients had partial compression from external TCV on radiology (1 aberrant subclavian artery, 2 dilated left atrium). The posture (supine vs upright) with more prominent PPZ's impaired bolus clearance in 9 additional cases by > 20%.

CONCLUSION

Transmitted TCV pulsations observed in HREIM bear no significant impact on swallowing. However, in older adults with dysphagia, evidence of impaired bolus clearance on impedance should be evaluated for external TCV compression. These associations have never been explored previously in literature, and are novel.

Key words: High resolution esophageal manometry; Dysphagia; Dysphagia lusoria; Dysphagia cardia; Esophageal motility; Thoracic cardiovascular structures; Esophageal disorders

© The Author(s) 2017. Published by Baishideng Publishing Group Inc. All rights reserved.

Core tip: Transmitted pulsations from thoracic cardiovascular structures are frequently observed on HREIM, and usually bear no significant impact on swallowing. However, in older adults with dysphagia, evidence of impaired bolus clearance on impedance should be further reviewed using clinical data and functional esophageal swallow studies in order to assess the possibility of external compression from cardiovascular structures.

Chaudhry NA, Zahid K, Keihanian S, Dai Y, Zhang Q. Transmitted cardiovascular pulsations on high resolution esophageal impedance manometry, and their significance in dysphagia. *World J Gastroenterol* 2017; 23(44): 7840-7848

Available from: URL: <http://www.wjgnet.com/1007-9327/full/v23/i44/7840.htm> DOI: <http://dx.doi.org/10.3748/wjg.v23.i44.7840>

INTRODUCTION

The esophagus has a close correlation with several thoracic cardiovascular (TCV) landmarks along its course. Prominent arterial structures include ascending aorta, arch of the aorta, left atrium and descending aorta. Cases of TCV compression on the esophagus have been classically associated with congenital anomalies, *e.g.*, dysphagia lusoria (aberrant subclavian artery causing esophageal compression)^[1]. It has also been proposed that the esophagus can be potentially compressed between the left atrium and descending aorta^[2] if it takes a left course on transition from thorax to abdomen. There are case reports of previously asymptomatic patients diagnosed with external cardiovascular compression on esophagus when they presented with pill induced esophagitis^[3] or pill related dysphagia^[4]. Initial clinical suspicion of TCV compression on esophagus is never paramount in dysphagia. However in older patients with an established history of atherosclerosis, cardiomegaly, or left atrial dilatation^[5], there can be a suspicion due to secondary causes^[6], *e.g.*, atrial fibrillation, mitral valve regurgitation or stenosis. There are reports of Ortner's syndrome (Cardiovocal syndrome) which is hoarseness caused by cardiopulmonary disease compressing the left recurrent laryngeal nerve^[7]. This interplay of the physiologic dynamics resulting from the anatomical proximity of these structures needs to be studied further. High Resolution Esophageal Impedance Manometry (HREIM) can provide an interesting insight on the significance and diagnosis of these cases. Effect of TCV pulsations, or pulsatile pressure zones (PPZ's), on the esophagus can be noted on HREIM^[8]. They present as a steady pulsation that remains unaffected with the stage of swallowing, and have been reported in previous literature as a high pressure barrier^[9]. Their characteristics and role in patients with or without dysphagia remain uninvestigated. Our aim with this study is to investigate the characteristics and significance of transmitted TCV pulsations on the esophagus as noted on HREIM, especially in terms of dysphagia.

MATERIALS AND METHODS

This is a retrospective single center case control study using HREIM studies of 317 patients conducted at a tertiary care center with institutional IRB approval.

Selection of cases

Studies of 250 patients undergoing HREIM for dysph-

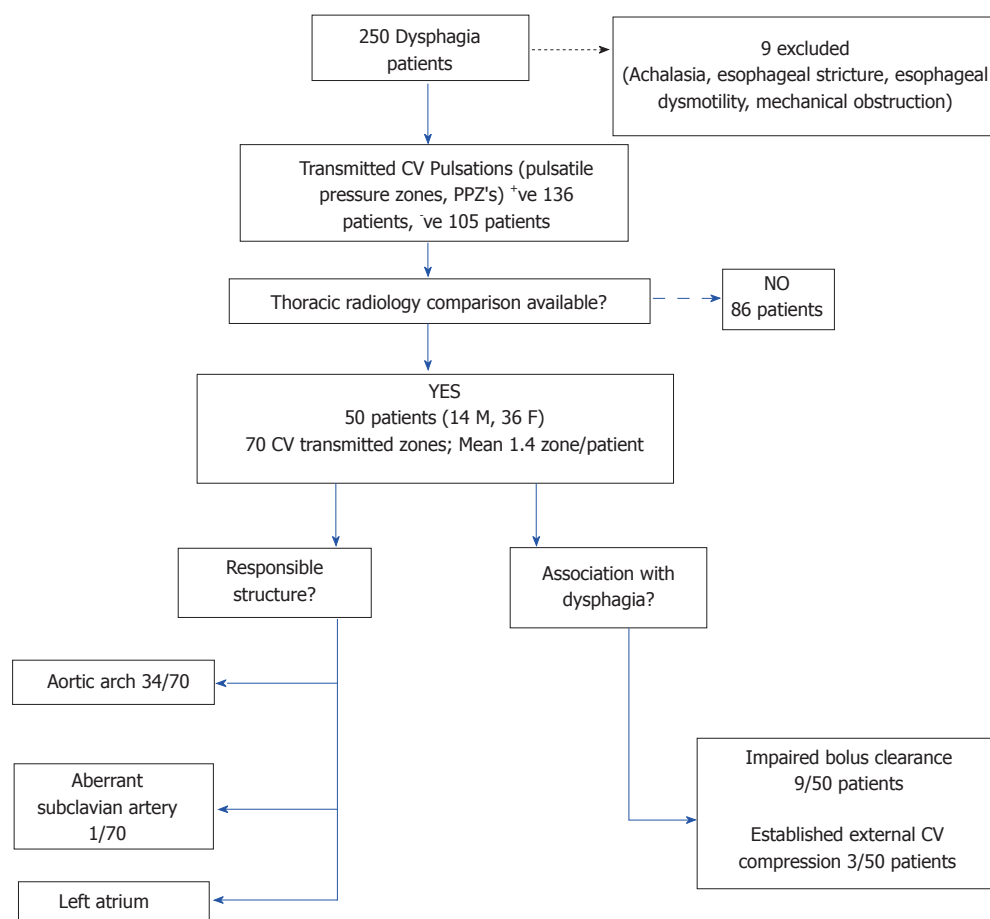


Figure 1 Selection of cases (dysphagia patients) with transmitted cardiovascular pulsations as noted on high resolution esophageal impedance manometry. CV: Cardiovascular.

agia from July 2012 to January 2014 were screened. Nine patients were eliminated on basis of achalasia, stricture, poor esophageal motility or mechanical obstruction. Cases were selected based on findings of PPZ's noted on HREIM, which were independent from the swallows, and hence representative of transmitted TCV pulsations on the esophagus. In these patients further electronic medical record was searched for available thoracic imaging, showing TCV structures likely responsible due to their anatomical proximity to esophagus. Fifty dysphagia patients with available radiology (CT/MR chest, esophagogram) were identified (Figure 1) and their data was used for statistical analysis.

Selection of controls

HREIM studies of 67 patients without dysphagia (per chart review) were screened as controls. Eight were eliminated due to presence of artifacts on study and catheter malfunction. The remaining 59 were reviewed for presence or absence of PPZ. In subjects with PPZ's data were collected regarding number and location of PPZ, axial length, PPZ pressure in upright posture, postural effect and impedance. Comparative thoracic

radiology was not available for the controls hence only their HREIM data was included for analysis.

Procedure and analysis

As per the institutional HREIM protocol (modified from Chicago protocol^[10]), patients received 10 swallows each in the supine and then in the upright position using 5 mL Gatorade™. Some patients had also received additional 10 mL swallows but these were excluded from the results analysis. A 4.2 mm outer diameter solid-state combined manometry and impedance recording catheter assembly incorporating 36 circumferential pressure sensors spaced at 1-cm intervals and 18 impedance segments spaced at 2-cm intervals were used (ManoScan™ Eso, Given Imaging Yogneam, Israel). The catheter was calibrated prior to each procedure and was inserted transnasally and positioned to record from the hypopharynx to the stomach with a goal of three intragastric sensor recording loci. Data were analyzed using ManoView ESO 3.0 analysis software (Given Imaging). Failed peristalsis was defined as no peristaltic contraction following a swallow. PPZ was included if pressure across it was > 5 mmHg. Pressure was determined

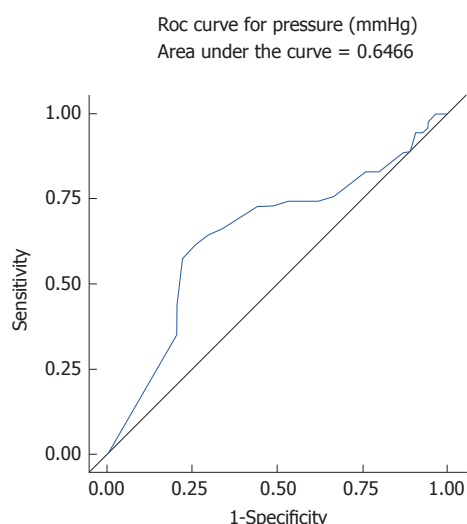


Figure 2 The receiver operator curve for pressure across pulsatile pressure zone with dysphagia shows area under the curve 0.65 demonstrating weak significance. Hence even though pressure was a statistically significant variable on Wilcoxon Rank Sum analysis, it is a poor predictor of dysphagia caused by transmitted cardiovascular pulsations on esophagus by this model.

using the isobar contour and measured in mmHg.

Data were collected from HREIM studies of selected patients regarding number of PPZ's present, axial length, PPZ pressures in upright posture, postural effect, location along esophagus (upper, middle or lower third) and impedance. The esophagus was divided into upper, middle and lower thirds. For our study, we only recorded pressures in the upright posture since prior research has demonstrated decreased integrated relaxation pressure, distal contractile integers, and elimination of vascular artifacts in a sitting posture^[11]. Since we were interested in measuring the impact of transmitted pulsations on dysphagia, we considered the physiological posture (upright) of swallowing more appropriate for pressure measurement. Even though some PPZ's were observed with the patient both in upright and supine posture, there were instances when it appeared more prominent in one posture as compared to the other. This was considered as a *dominant posture* for the PPZ. For PPZ's present only in one posture, this was documented as its dominant posture. Available radiology images were reviewed by the investigators for correlating TCV structures, and where possible it was also assessed if the patients had a noticeable left turn of esophagus on transition from thorax to abdomen.

The data was tabulated in descriptive format and statistical analysis was done using SAS 9.4 (Copyright © 2013, SAS Institute Inc., Cary, NC, United States). Characteristics of age, sex, anatomical location of PPZ (upper, middle or lower esophagus), PPZ pressure and axial length were analyzed using Wilcoxon rank sum analysis and logistic regression was performed for

marginally significant variables. A *P*-value of < 0.05 was considered statistically significant for the purposes of our study. We performed logistic regression analysis using the disease status (dysphagia vs. no dysphagia) as the response variable and gender, location, axial length, pressure and posture as explanatory variables. A backward selection procedure at the 0.2 significance level identified that pressure was the only explanatory variable significantly associated with dysphagia. We decided to assess the strength of the association by using pressure as a predictor for dysphagia.

RESULTS

In 241 patients with dysphagia (cases), 136 (56.4%) had PPZ's in either supine or upright posture on HREIM, in comparison to 38 (64.4%) in non-dysphagia group (controls). Since some patients had more than one independently behaving pulsatile zone, 70 PPZ's were noted in these 50 patients (Average 1.4 PPZ per patient). This was similar in prevalence to the 38 controls with PPZ's, 54 PPZ's were observed with an average 1.4 per patient. Demographic and clinical characteristics are presented in Table 1. The prevalence of PPZ's, was similar in both the cases and controls. The cases were markedly older (67.3 ± 14.9 , median 70 years) than controls (31.2 ± 12.2 , median 27 years) with $P < 0.0001$.

Average pressure of PPZ's (upright postures) in cases was 10.8 ± 9.7 mmHg, which was significantly lower than controls 15.7 ± 10.0 mmHg ($P < 0.01$). However, since rising external pressure does not correlate with resolution of dysphagia physiologically, we evaluated its strength as a predictor (see methods). The prediction model had an associated receiver operating characteristic (ROC) curve (Figure 2) with the area under the ROC curve (AUC) of 0.65 (weak significance). Hence, even though low PPZ pressure was significantly associated with dysphagia, the quality of predicting dysphagia by pressure was low; AUC, sensitivity and specificity were quite low.

Some patients had impairment in bolus clearance with regards to dominant posture, but there was no clear association between PPZ pressure and Impedance. (Impairment was considered to be $> 20\%$ change in bolus clearance on Impedance.) Impaired bolus clearance was observed in 12/50 (24%) dysphagia patients and was associated with the PPZ becoming more prominent. Bolus clearance in these patients decreased by $> 20\%$ if PPZ was dominant regardless of upright or supine posture, hence showing no relation to posture itself. Only 3 of these 12 patients had clear evidence of partial compression from external TCV structures on radiology (1 from aberrant subclavian artery with dysphagia lusoria, 2 from dilated left atrium). In the patient with dysphagia lusoria, bolus clearance was 10% in supine swallows

Table 1 Demographic and morphologic characteristics of transmitted cardiovascular pulsations, or pulsatile pressure zones, on High Resolution Esophageal Impedance Manometry *n* (%)

Variable		Dysphagia (<i>n</i> = 50)	No dysphagia (<i>n</i> = 38)	<i>P</i> value
Age, yr	mean ± SD	67.3 ± 14.9	31.2 ± 12.2	< 0.0001
	Median (min, max)	70 (24, 89)	27 (19, 61)	
Gender	Male	14 (28)	18 (47)	0.097
	Female	36 (72)	20 (53)	
Number of pulsatile zones	Total (% prevalence overall)	70 (56.4)	54 (64.4)	-
	Average per patient	1.4	1.4	-
Location of pulsatile zone in esophagus	Upper third	12 (17)	7 (13)	0.769
	Middle third	24 (34)	21 (39)	
	Lower third	34 (49)	26 (48)	
Axial length of pulsatile zone (cm)	mean ± SD	2.2 ± 1.4	2.4 ± 1.2	0.258
	Median (min, max)	2 (0.5, 6)	2 (0.5, 5)	
	Avg upper third (min, max)	1 (0.5-2)	1 (0.5-2)	
	Avg middle third (min, max)	0.7 (0.5-2.5)	2.2 (0.5-4)	
	Avg lower third (min, max)	3.3 (0.5-6)	2.3 (1.5-5)	
PPZ	mean ± SD	10.8 ± 9.7	15.7 ± 10.0	< 0.01
Pressure (mmHg)	Median (min, max)	10 (0, 35)	17 (0, 45)	
	Avg upper third	9.8	16.7	
	Avg middle third	5.9	13.3	
	Avg lower third	14.3	16.9	
Dominant posture for pulsatile zone	Supine	21 (30)	10 (18.5)	0.282
	Upright	10 (14.3)	6 (11.1)	
	Both postures	39 (55.7)	38 (70.4)	

This table shows a comparison between patients with dysphagia (cases) and without dysphagia (controls).

and 90% upright swallows (Figure 3). In one of the patients with enlarged left atrium, bolus clearance was 80% in supine swallows and 10 % upright (Figure 4). No impedance data was available for the third patient. PPZ pressure (upright) in these 3 patients ranged from 25 to 35 mmHg. There was no radiological evidence of obstruction caused by TCV structures in the remaining 47/50 patients. Figure 5 shows PPZ's observed in non-dysphagia patients.

The behavior of PPZ's was observed with regards to change in posture. In cases, majority (39/70, 56%) of the PPZ's were observed in both upright and supine postures, 10 in upright, and 21 in supine posture only. Similarly in controls, the majority (38/54, 70%) of them were noted in both upright and supine postures. Hence, this presentation was more common in controls. The average axial length of the PPZ in cases was 2.2 ± 1.4 cm, which was comparable to controls 2.4 ± 1.2 cm.

The aortic arch was related to 34 PPZ's, 11 of which were in upper and 23 in the middle third. One remaining PPZ in the upper third was due to an aberrant subclavian artery (dysphagia lusoria). The left atrium was related to 35 PPZ's including all 34 PPZ's in the lower third and one in the middle third. Hence the characteristics described for the lower PPZ's in Table 1 can be attributed to the left atrium.

Among the 50 patients with dysphagia, 20 had dysphagia to solids, 4 to both solids and liquids whereas 26 were unspecified per chart review. Esophageal orientation on lower thoracic cavity could

be ascertained in 27 patients, 24 of them had a left turn of esophagus causing it to be situated between the descending thoracic aorta and left atrium. This finding was present in all patients with PPZ's causing bolus impairment on impedance in lower third of esophagus.

DISCUSSION

Per our results, transmitted cardiovascular pulsations were seen with a comparable frequency in patients with and without dysphagia. However the older age of the dysphagia population indicates that advancing age and/or development of atherosclerosis and valvular heart disease could be a risk factor. The most common causes for a pulsatile pressure zone were the left atrium and the aortic arch likely because they are most closely related CV structures to the esophagus during its thoracic course. Prior studies have reported dysphagia aortica seen in elderly patients especially women with a history of hypertension and kyphosis^[12,13]. Even though a majority of the PPZ's were present in both upright and supine posture, it was apparent that most of these had a more prominent appearance in one posture than the other. We called this the "dominant posture" for the PPZ, and noted that this had some relation with impaired bolus clearance in the dysphagia group. Pressure, likely by itself is not a key determinant of bolus impairment unless there are other factors at play. We opted to measure pressure only in the upright posture (rather

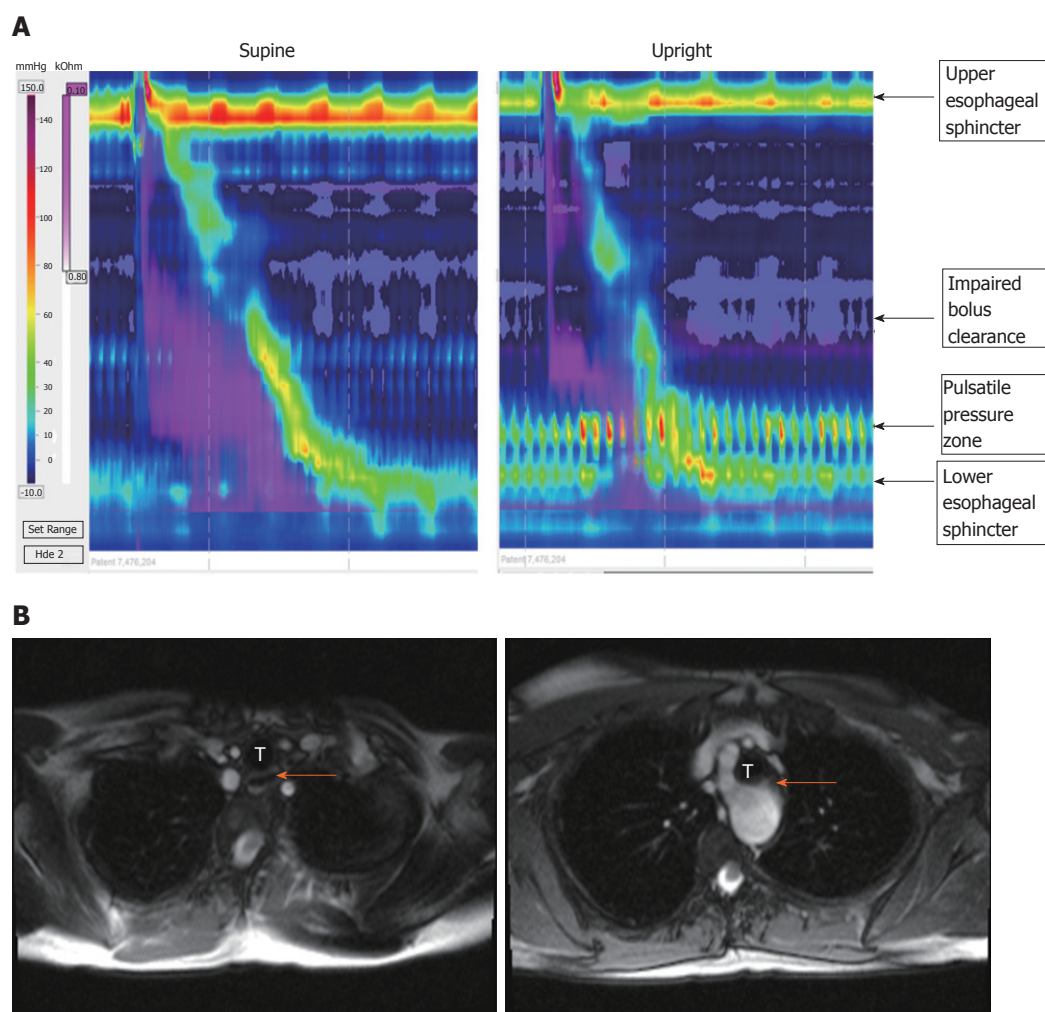


Figure 3 In the patient with dysphagia lusoria, bolus clearance was 10% in supine swallows and 90% upright swallows. A: Pulsatile pressure zones (PPZ) on HREIM due to transmitted pulsations of aberrant subclavian artery and aortic arch in a patient with dysphagia lusoria, with impaired bolus clearance; B: Magnetic Resonance Angiogram of patient with dysphagia lusoria; *LEFT* patent esophagus (arrow) *RIGHT* esophageal compression secondary to aberrant subclavian artery (dysphagia lusoria); T: Trachea.

than the dominant posture) since it is the physiological posture of swallowing. Hence, pressure from a vascular source of dysphagia would be more relevant if the PPZ was observed in the upright posture. Similar PPZ pressures in non-dysphagia patients had no impact on impedance, whereas they did in some dysphagia patients. More research needs to be done regarding dysphagia in the elderly in correlation with the history of atherosclerosis and cardiomegaly.

HREIM has evolved into quite an important field over the past couple of decades, and has established itself in the research and clinical arena. It provides us with a wealth of information in the realm of esophageal functional disorders and their diagnostics^[14]. Transmitted cardiovascular pulsations are commonly encountered by the observing gastroenterologist, however there is still a lack of knowledge regarding their impact in patients with dysphagia. Our results demonstrate that even though there were a few cases of dysphagia secondary to TCV structures, these can only be diagnosed with confidence with the combined

evidence of impedance and fluoroscopic studies such as barium swallow^[15]. HREIM also does not fully account for patients with dysphagia to solids, which was the case in most of our patients when type of dysphagia was specified.

In elderly patients with dysphagia, the differential diagnosis usually focuses on swallowing difficulties secondary to advancing age or dementia, or intra-esophageal pathology, *e.g.*, strictures, rings. External compression by cardiovascular landmarks can be another possible, yet uncommon, cause of dysphagia in this population. It can cause considerable frustration for both the physician and the patient when an extensive work up is unsuccessful in yielding answers as to the cause of the symptoms. As per literature review an esophagus lying to the left of the vertebral column in the lower thorax has greater chances of being compressed between the left atrium and descending thoracic aorta^[2] (two dominant vascular structures). We also identified this trend in our data, however it's difficult to establish a clear correlation

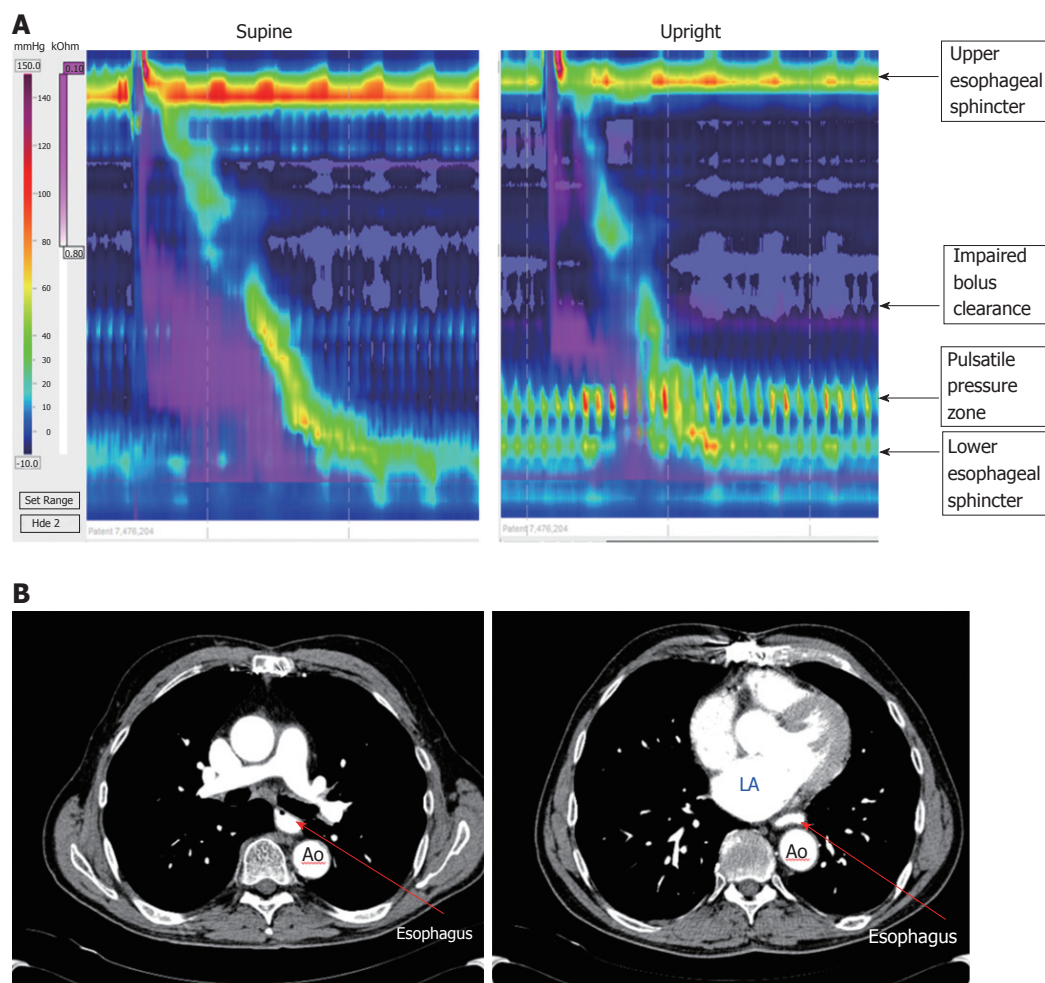


Figure 4 In one of the patients with enlarged left atrium, bolus clearance was 80% in supine swallows and 10% upright. A: Pulsatile pressure zone with impaired bolus clearance easily visible in a dysphagia patient in upright posture due to left atrial enlargement; B: Corresponding CT Scan Images of the same patient (Left) Esophagus patent in upper thorax (Right) Esophagus compressed between dilated left atrium (LA) and descending aorta (Ao).

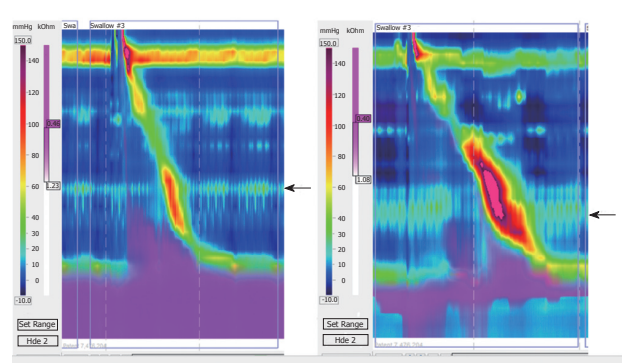


Figure 5 Pulsatile pressure zones observed in patients without dysphagia (see arrows).

given that this is the pre-dominant anatomical location for the esophagus, and no statistical evidence was determined to the effect.

It is interesting though, how a PPZ caused by the same cardiovascular structure, behaves differently in presentation across the subjects. It has previously been proposed that some patients have an underlying

pre-disposition for dysphagia due to CVS causes which becomes manifest with super-imposed factors (pill-induced esophagitis^[3], gastritis, atherosclerosis^[16], aortic aneurysm^[17,18]). No clear association was observed between any specific CV structure with properties of its esophageal transmitted pulsations, e.g., appearance in upright vs supine posture, axial length, PPZ pressure, or presence or absence of impaired bolus clearance. The only obvious anatomical association was the presence of Aortic arch in the middle third of the esophagus on HREIM and the left atrium in the lower third.

When there is pre-existing history of mitral valve stenosis/regurgitation, atrial fibrillation or cardiomegaly^[4,6] in a dysphagia patient, a dilated left atrium compressing the esophagus can be the culprit. Cardiac dysphagia was the cause in two of our 3 pts in which we could determine clear association between dysphagia and pressure caused by a cardiovascular structure. The third patient was of dysphagia lusoria due to an aberrant subclavian artery. Treatment of cardiovascular associated dysphagia is initially always

dietary modification^[13], however some cases have described endovascular stenting^[16] as well as surgical options^[2] in advanced cases.

The limitations of our study include a smaller control group as compared to cases, which could not be matched on basis of age. Since our study was retrospective and most HREIM's are performed on patients with dysphagia, we were unable to compensate for this size difference and our control group was limited. Thoracic radiology was also not available for the control group. We were also unable to incorporate the pulse rate and blood pressure of the subjects in the analysis due to the retrospective design. The dysphagia status of the patient was also determined from chart review rather than a standardized patient reported measure. Future research can focus on older populations with underlying cardiovascular disease in the presence of noticeable transmitted CV pulsations on the esophagus and their association with dysphagia.

In conclusion transmitted pulsations from TCV structures are frequently observed on HREIM usually having no significant impact on swallowing. However, evidence of impaired bolus clearance on impedance can be correlated with clinical data and functional esophageal swallow studies in older adults with dysphagia to assess for external compression from cardiovascular structures.

COMMENTS

Background

Transmitted pulsations of thoracic cardiovascular (TCV) structures are often visible on high resolution esophageal impedance manometry (HREIM) as pulsatile pressure zones (PPZ's). However, their significance has never been established especially in light of dysphagia. This study investigated the characteristics of these common observations, to determine their impact on swallowing and dysphagia.

Research frontiers

The field of HREIM has shown rapid development in the past decade and its diagnostic importance, especially for swallowing disorders, is without question. There is a close anatomical relationship between thoracic cardiovascular structures and the esophagus, and the advent of HREIM enables us to study their physiological relationship in better detail.

Innovations and breakthroughs

This study investigates a commonly observed, but poorly understood, phenomenon on HREIM and seeks better comprehension of its relevance. This study is one such step in this direction, and seeks to answer questions about transmitted cardiovascular pulsations and dysphagia. This findings point towards an age-related association with dysphagia which is novel.

Applications

This study was retrospective in nature, and was carried out with liquid swallows. Future studies, with more control data and a prospective design, can be designed to study the impact of transmitted pulsations on a solid bolus, barium pill, or the impact of posture.

Terminology

TCV structures: describes the heart and the major vessels. In our study,

reference is mostly to arterial structures due to the transmission of pulses across to the esophagus. HREIM and PPZ's are the representative areas of transmitted arterial pulsations to the esophagus on HREIM.

Peer-review

This is a well written article. It is an interesting topic. High resolution manometry is still evolving and there are various features in it that are not very clear.

REFERENCES

- 1 Levitt B, Richter JE. Dysphagia Lusoria: a comprehensive review. *Dis Esophagus* 2007; **20**: 455-460 [PMID: 17958718 DOI: 10.1111/j.1442-2050.2007.00787.x]
- 2 Mittal RK, Siskind BN, Hongo M, Flye MW, McCallum RW. Dysphagia aortica. Clinical, radiological and manometric findings. *Dig Dis Sci* 1986; **31**: 379-384 [PMID: 3956334]
- 3 Malhotra A, Kottam RD, Spira RS. Dysphagia Lusoria presenting with pill induced oesophagitis- a case report with review of literature. *BJMP* 2010; **3**: 312
- 4 Whitney B, Croxon R. Dysphagia caused by cardiac enlargement. *Clin Radiol* 1972; **23**: 147-152 [PMID: 4263165]
- 5 Raffa GM, Cappai A, Tarelli G. Giant left atrium Syndrome. *J Cardiovasc Med (Hagerstown)* 2011; **12**: 745-746 [PMID: 21881448 DOI: 10.2459/JCM.0b013e32834a65b1]
- 6 Monkemuller K, Feldman K, Ulbright L. Cardiac Dysphagia. *Clinical Gastroenterology and Hepatology* 2010; **8**: e41-e42 [DOI: 10.1016/j.cgh.2009.12.014]
- 7 Arifputera A, Loo G, Chang P, Kojodjojo P. An unusual case of dysphonia and dysphagia. *Singapore Med J* 2014; **55**: e31-e33 [PMID: 24154555 DOI: 10.1162/smmedj.2013212]
- 8 Babaei R, Mittal K. Cardiovascular compression of the esophagus and spread of gastro-esophageal reflux. *Neurogastroenterol Motil* 2011; **23**: 45-51 [PMID: 20939848 DOI: 10.1111/j.1365-2982.2010.01606.x]
- 9 Wilkinson JM, Euinton HA, Smith LF, Bull MJ, Thorpe JA. Diagnostic dilemmas in dysphagia aortica. *Eur J Cardiothorac Surg* 1997; **11**: 222-227 [PMID: 9080147]
- 10 Kahrilas PJ, Bredenoord AJ, Fox M, Gyawali CP, Roman S, Smout AJ, Pandolfino JE; International High Resolution Manometry Working Group. The Chicago Classification of esophageal motility disorders, v3.0. *Neurogastroenterol Motil* 2015; **27**: 160-174 [PMID: 25469569 DOI: 10.1111/nmo.12477]
- 11 Xiao Y, Read A, Nicodème F, Roman S, Kahrilas PJ, Pandolfino JE. The effect of a sitting vs supine posture on normative esophageal pressure topography metrics and Chicago Classification diagnosis of esophageal motility disorders. *Neurogastroenterol Motil* 2012; **24**: e509-e516 [PMID: 22897486 DOI: 10.1111/j.1365-2982.2012.02001.x]
- 12 Hilliard AA, Murali N, Keller AS. Dysphagia aortica. *Ann Intern Med* 2005; **142**: 230-231 [PMID: 15684224]
- 13 Karavelioglu Y, Kalçik M, Yetim M, Sarak T, Bekar L, Doğan T. A Rare Cause of Dysphagia and Weight Loss in a Nonagenarian with Hypertension: Dysphagia Aortica. *J Am Geriatr Soc* 2015; **63**: 1488-1489 [PMID: 26189863 DOI: 10.1111/jgs.13544]
- 14 Carlson DA, Ravi K, Kahrilas PJ, Gyawali CP, Bredenoord AJ, Castell DO, Spechler SJ, Halland M, Kanuri N, Katzka DA, Leggett CL, Roman S, Saenz JB, Sayuk GS, Wong AC, Yadlapati R, Ciolino JD, Fox MR, Pandolfino JE. Diagnosis of Esophageal Motility Disorders: Esophageal Pressure Topography vs. Conventional Line Tracing. *Am J Gastroenterol* 2015; **110**: 967-977; quiz 978 [PMID: 26032151 DOI: 10.1038/ajg.2015.159]
- 15 Scharitzer M, Pokieser P, Schober E, Schima W, Eisenhuber E, Stadler A, Memarsadeghi M, Partik B, Lechner G, Ekberg O. Morphological findings in dynamic swallowing studies of symptomatic patients. *Eur Radiol* 2002; **12**: 1139-1144 [PMID: 11976859 DOI: 10.1007/s00330-001-1202-4]
- 16 Kische S, Werner D, Ince H. A neglected symptom of contained

Aortic Laceration- Dysphagia Aortica successfully treated by endovascular stent grafting. *Catheter Cardiovasc Interv* 2012; **80**: 1052-1055

17 **Wang WP**, Yan XL, Ni YF, Zhang T, Han Y, Li XF, Lu Q. An

unusual cause of dysphagia: thoracic aorta aneurysm. *J Thorac Dis* 2013; **5**: E224-E226 [PMID: 24416520 DOI: 10.3978/j.issn.2072-1439.2013.11.15]

18 **Antón E**. Dysphagia aortica: a diagnostic challenge in the elderly. *Rev Esp Enferm Dig* 2007; **99**: 362-364 [PMID: 17883304]

P- Reviewer: Garcia-Olmo D, Jain M, Saligram S **S- Editor:** Qi Y
L- Editor: A **E- Editor:** Huang Y





Published by **Baishideng Publishing Group Inc**
7901 Stoneridge Drive, Suite 501, Pleasanton, CA 94588, USA
Telephone: +1-925-223-8242
Fax: +1-925-223-8243
E-mail: bpgoffice@wjgnet.com
Help Desk: <http://www.f6publishing.com/helpdesk>
<http://www.wjgnet.com>



ISSN 1007-9327



9 771007 932045