


World Journal of *Gastroenterology*

World J Gastroenterol 2017 November 21; 23(43): 7653-7812



**EDITORIAL**

- 7653 Noncoding RNAs as drivers of the phenotypic plasticity of oesophageal mucosa

Fassan M, Facchin S, Munari G, Fanelli GN, Lorenzon G, Savarino E

MINIREVIEWS

- 7657 Functional interaction of endoplasmic reticulum stress and hepatitis B virus in the pathogenesis of liver diseases

Kim SY, Kyaw YY, Cheong J

- 7666 Pathological process of liver sinusoidal endothelial cells in liver diseases

Ni Y, Li JM, Liu MK, Zhang TT, Wang DP, Zhou WH, Hu LZ, Lv WL

ORIGINAL ARTICLE**Basic Study**

- 7678 Resveratrol modifies biliary secretion of cholephilic compounds in sham-operated and cholestatic rats

Dolezelova E, Prasnicka A, Cermanova J, Carazo A, Hyrsova L, Hroch M, Mokry J, Adamcova M, Mrkvicova A, Pavek P, Micuda S

- 7693 Chitinase 3-like 1 secreted by peritumoral macrophages in esophageal squamous cell carcinoma is a favorable prognostic factor for survival

Xing S, Zheng X, Zeng T, Zeng MS, Zhong Q, Cao YS, Pan KL, Wei C, Hou F, Liu WL

- 7705 Palmitate induces fat accumulation by activating C/EBP β -mediated G0S2 expression in HepG2 cells

Zhao NQ, Li XY, Wang L, Feng ZL, Li XF, Wen YF, Han JX

Retrospective Cohort Study

- 7716 Epidemiology and natural history of Wilson's disease in the Chinese: A territory-based study in Hong Kong between 2000 and 2016

Cheung KS, Seto WK, Fung J, Mak LY, Lai CL, Yuen MF

Retrospective Study

- 7727 Efficacy of thalidomide therapy in pediatric Crohn's disease with evidence of tuberculosis

Wang L, Hong Y, Wu J, Leung YK, Huang Y

- 7735 Combined endovascular brachytherapy, sorafenib, and transarterial chemobolization therapy for hepatocellular carcinoma patients with portal vein tumor thrombus

Zhang ZH, Liu QX, Zhang W, Ma JQ, Wang JH, Luo JJ, Liu LX, Yan ZP

- 7746** Procedure-related complications in gastric variceal obturation with tissue glue

Guo YE, Miao HB, Wen ZF, Xuan JY, Zhou HX

- 7756** Gastric xanthelasma and metabolic disorders: A large retrospective study among Chinese population

Chen Y, He XJ, Zhou MJ, Li YM

Clinical Trials Study

- 7765** Application of superb microvascular imaging in focal liver lesions

He MN, Lv K, Jiang YX, Jiang TA

Observational Study

- 7776** Chronic liver disease is universal in children with biliary atresia living with native liver

Lee WS, Ong SY, Foo HW, Wong SY, Kong CX, Seah RB, Ng RT

Prospective Study

- 7785** How severe is moderately severe acute pancreatitis? Clinical validation of revised 2012 Atlanta Classification

Ignatavicius P, Gulla A, Cernauskis K, Barauskas G, Dambrauskas Z

META-ANALYSIS

- 7791** Laparoscopic vs open hepatectomy for hepatolithiasis: An updated systematic review and meta-analysis

Li H, Zhang J, Cai JY, Li SH, Zhang JB, Wang XM, Chen GH, Yang Y, Wang GS

CASE REPORT

- 7807** Fatal gastrointestinal histoplasmosis 15 years after orthotopic liver transplantation

Agrawal N, Jones DEJ, Dyson JK, Hoare T, Melmore SA, Needham S, Thompson NP

ABOUT COVER

Editorial board member of *World Journal of Gastroenterology*, kenshi Matsumoto, MD, PhD, Associate Professor, Department of Gastroenterology, Juntendo University, Tokyo 113-8421, Japan

AIMS AND SCOPE

World Journal of Gastroenterology (*World J Gastroenterol*, *WJG*, print ISSN 1007-9327, online ISSN 2219-2840, DOI: 10.3748) is a peer-reviewed open access journal. *WJG* was established on October 1, 1995. It is published weekly on the 7th, 14th, 21st, and 28th each month. The *WJG* Editorial Board consists of 1375 experts in gastroenterology and hepatology from 68 countries.

The primary task of *WJG* is to rapidly publish high-quality original articles, reviews, and commentaries in the fields of gastroenterology, hepatology, gastrointestinal endoscopy, gastrointestinal surgery, hepatobiliary surgery, gastrointestinal oncology, gastrointestinal radiation oncology, gastrointestinal imaging, gastrointestinal interventional therapy, gastrointestinal infectious diseases, gastrointestinal pharmacology, gastrointestinal pathophysiology, gastrointestinal pathology, evidence-based medicine in gastroenterology, pancreatology, gastrointestinal laboratory medicine, gastrointestinal molecular biology, gastrointestinal immunology, gastrointestinal microbiology, gastrointestinal genetics, gastrointestinal translational medicine, gastrointestinal diagnostics, and gastrointestinal therapeutics. *WJG* is dedicated to become an influential and prestigious journal in gastroenterology and hepatology, to promote the development of above disciplines, and to improve the diagnostic and therapeutic skill and expertise of clinicians.

INDEXING/ABSTRACTING

World Journal of Gastroenterology (*WJG*) is now indexed in Current Contents[®]/Clinical Medicine, Science Citation Index Expanded (also known as SciSearch[®]), Journal Citation Reports[®], Index Medicus, MEDLINE, PubMed, PubMed Central and Directory of Open Access Journals. The 2017 edition of Journal Citation Reports[®] cites the 2016 impact factor for *WJG* as 3.365 (5-year impact factor: 3.176), ranking *WJG* as 29th among 79 journals in gastroenterology and hepatology (quartile in category Q2).

FLYLEAF

I-IX Editorial Board

EDITORS FOR THIS ISSUE

Responsible Assistant Editor: Xiang Li
Responsible Electronic Editor: Yan Huang
Proofing Editor-in-Chief: Lian-Sheng Ma

Responsible Science Editor: Ke Chen
Proofing Editorial Office Director: Jin-Lei Wang

NAME OF JOURNAL
World Journal of Gastroenterology

ISSN
ISSN 1007-9327 (print)
ISSN 2219-2840 (online)

LAUNCH DATE
October 1, 1995

FREQUENCY
Weekly

EDITORS-IN-CHIEF
Damian Garcia-Olmo, MD, PhD, Doctor, Professor, Surgeon, Department of Surgery, Universidad Autonoma de Madrid; Department of General Surgery, Fundacion Jimenez Diaz University Hospital, Madrid 28040, Spain

Stephen C Strom, PhD, Professor, Department of Laboratory Medicine, Division of Pathology, Karolinska Institutet, Stockholm 141-86, Sweden

Andrzej S Tarnawski, MD, PhD, DSc (Med), Professor of Medicine, Chief Gastroenterology, VA Long Beach Health Care System, University of California, Irvine, CA, 5901 E. Seventh Str., Long Beach,

CA 90822, United States

EDITORIAL BOARD MEMBERS
All editorial board members resources online at <http://www.wjgnet.com/1007-9327/editorialboard.htm>

EDITORIAL OFFICE
Jin-Lei Wang, Director
Ze-Mao Gong, Vice Director
World Journal of Gastroenterology
Baishideng Publishing Group Inc
7901 Stoneridge Drive, Suite 501,
Pleasanton, CA 94588, USA
Telephone: +1-925-2238242
Fax: +1-925-2238243
E-mail: editorialoffice@wjgnet.com
Help Desk: <http://www.wjgnet.com/helpdesk>
<http://www.wjgnet.com>

PUBLISHER
Baishideng Publishing Group Inc
7901 Stoneridge Drive, Suite 501,
Pleasanton, CA 94588, USA
Telephone: +1-925-2238242
Fax: +1-925-2238243
E-mail: bpgoffice@wjgnet.com
Help Desk: <http://www.wjgnet.com/helpdesk>

<http://www.wjgnet.com>

PUBLICATION DATE
November 21, 2017

COPYRIGHT
© 2017 Baishideng Publishing Group Inc. Articles published by this Open-Access journal are distributed under the terms of the Creative Commons Attribution Non-commercial License, which permits use, distribution, and reproduction in any medium, provided the original work is properly cited, the use is non commercial and is otherwise in compliance with the license.

SPECIAL STATEMENT
All articles published in journals owned by the Baishideng Publishing Group (BPG) represent the views and opinions of their authors, and not the views, opinions or policies of the BPG, except where otherwise explicitly indicated.

INSTRUCTIONS TO AUTHORS
Full instructions are available online at <http://www.wjgnet.com/bpg/gerinfo/204>

ONLINE SUBMISSION
<http://www.wjgnet.com>

Retrospective Study

Gastric xanthelasma and metabolic disorders: A large retrospective study among Chinese population

Yi Chen, Xin-Jue He, Min-Jian Zhou, You-Ming Li

Yi Chen, Xin-Jue He, Min-Jian Zhou, You-Ming Li, Department of Gastroenterology, the First Affiliated Hospital, College of Medicine, Zhejiang University, Hangzhou 310003, Zhejiang Province, China

ORCID number: Yi Chen (0000-0003-0230-1467); Xin-Jue He (0000-0003-4785-9018); Min-Jian Zhou (0000-0001-7232-5582); You-Ming Li (0000-0002-5532-6062).

Author contributions: Chen Y and He XJ contributed equally to this work; Chen Y and Zhou MJ designed the research; Chen Y and He XJ performed the research; Chen Y and He XJ analyzed data; Chen Y and Li YM wrote the paper.

Supported by Science Foundation of Health Bureau of Zhejiang Province, No. 2017183691 (to Chen Y).

Institutional review board statement: This manuscript was approved Department of Gastroenterology, the First Affiliated Hospital, College of Medicine, Zhejiang University for its conduction.

Informed consent statement: All study participants, or their legal guardian, provided informed written consent prior to study enrollment.

Conflict-of-interest statement: All authors have no any conflict of interest to declare.

Data sharing statement: All data of this study was shown and available in manuscript.

Open-Access: This article is an open-access article which was selected by an in-house editor and fully peer-reviewed by external reviewers. It is distributed in accordance with the Creative Commons Attribution Non Commercial (CC BY-NC 4.0) license, which permits others to distribute, remix, adapt, build upon this work non-commercially, and license their derivative works on different terms, provided the original work is properly cited and the use is non-commercial. See: <http://creativecommons.org/licenses/by-nc/4.0/>

Manuscript source: Unsolicited manuscript

Correspondence to: You-Ming Li, Professor, Department

of Gastroenterology, The First Affiliated Hospital, College of Medicine, Zhejiang University, 866 Yuhangtang Road, Hangzhou 310003, Zhejiang Province, China. zlym@zju.edu.cn
Telephone: +86-571-87235632
Fax: +86-571-87235632

Received: July 3, 2017

Peer-review started: July 3, 2017

First decision: August 10, 2017

Revised: August 25, 2017

Accepted: September 13, 2017

Article in press: September 13, 2017

Published online: November 21, 2017

Abstract

AIM

To gain knowledge of xanthelasma, a large population-based study was conducted.

METHODS

Patients who underwent upper gastrointestinal endoscopy at the First Affiliated Hospital, College of Medicine, Zhejiang University, Hangzhou, China during Jan 2009 to Nov 2016 were included. General characteristics as well as clinical data were collected, including blood routine, serum biochemical analysis, endoscopic findings, histological evaluation and comorbidity. Statistical analyses was performed using SPSS 20.0 software for Windows (IBM Inc., Chicago, IL, United States) using Student's *t*-test, Mann-Whitney *U* test, χ^2 test, univariable and multivariable logistic analysis. 2-tailed *P* value less than 0.05 was considered to be statistically significant.

RESULTS

A total of 176006 endoscopies were retrieved and we included 1370 xanthelasma participants (703 men, 667 women) in this study. Prevalence of xanthelasma was 0.78% with average age of 56.6 ± 11.2 years. Chief complaint of xanthelasma consisted abdominal pain

(24.2%), up-abdominal discomfort (14.1%), abdominal distention (10.1%), dyspepsia (9.1%), *et al.* Most xanthelasma occurred as single lesion in gastric antrum. Xanthelasma patients witnessed higher *Helicobacter pylori* (*H. pylori*) infection rate, more of other gastric lesions including atrophy, intestinal metaplasia and dysplasia ($P < 0.01$). In xanthelasma patients, serum carcinoembryonic antigen, triglyceride, fasting glucose, neutrophil, neutrophil-to-lymphocyte ratio were significantly higher, and high density lipoprotein-cholesterol, lymphocyte was lower ($P < 0.05$). Xanthelasma accompanied with more fatty liver disease and hepatic cyst, but fewer gallbladder polyp ($P < 0.05$). In logistic regression, it revealed that fasting plasma glucose (OR = 3.347, 1.170-9.575, $P < 0.05$), neutrophil (OR = 1.617, 1.003-2.605, $P < 0.05$), and carcinoembryonic antigen (OR = 2.011, 1.236-3.271, $P < 0.01$) were all independent risk factors in xanthelasma.

CONCLUSION

Current study described a large xanthelasma cohort in Chinese population, revealed its relationship with *H. pylori* infection, carcinogenesis, metabolic dysfunction and inflammation as well.

Key words: Gastric xanthelasma; *Helicobacter pylori* infection; Gastric dysplasia; Metabolic disorder

© The Author(s) 2017. Published by Baishideng Publishing Group Inc. All rights reserved.

Core tip: Xanthelasma was a relatively rare endoscopic finding, characterized by accumulation of lipid in histiocytic foam cells in mucosa. Current study described a large xanthelasma cohort in Chinese population and revealed its relationship with *Helicobacter pylori* infection, atrophy, intestinal metaplasia, dysplasia, and metabolic disorder, indicating role of xanthelasma in both carcinogenesis and metabolic dysfunction.

Chen Y, He XJ, Zhou MJ, Li YM. Gastric xanthelasma and metabolic disorders: A large retrospective study among Chinese population. *World J Gastroenterol* 2017; 23(43): 7756-7764 Available from: URL: <http://www.wjgnet.com/1007-9327/full/v23/i43/7756.htm> DOI: <http://dx.doi.org/10.3748/wjg.v23.i43.7756>

INTRODUCTION

Gastric xanthelasma, characterized by lipid accumulation in histiocytic foam cells, was a relatively scarce endoscopic finding, with prevalence varied from 0.8% to 7% in different study population^[1-3]. As is frequently observed in the gastric mucosa of patients with early gastric cancer, xanthelasma was assumed to be a predictive biomarker or pre-tumorigenesis change of gastric adenocarcinoma^[1,4]. But there is no large descriptonal study among Chinese population.

Mechanism of xanthelasma was unknown. Early

small sample studies have showed relationship between xanthelasma and *Helicobacter pylori* (*H. pylori*) infection^[5,6]. Later on, a Korean cohort further supported this finding, indicating a role of *H. pylori* as well as inflammation in xanthelasma^[2]. As these countries were high *H. pylori* prevalent places, till now, whether *H. pylori* infection was result of or just casual finding in xanthelasma was not clear, neither was the association between chronic inflammation and xanthelasma.

As xanthelasma was defined as lipid deposit in stomach, its relevance to metabolic disorders was of great interest. Etiologically, these conditions may be associated with a primary dyslipoproteinemic state, such as diabetes, nephrosis, obesity or cholestasis. In two Korean studies, dyslipidemia, representative of lower mean high density lipoprotein (HDL)-cholesterol and higher mean triglyceride levels was found in gastric xanthelasma subjects in comparison with the controls, accompanied with higher body mass index (BMI)^[2,7]. But, there were no reports regarding xanthelasma and metabolic factors in Chinese population yet.

So, herein, we conducted a large retrospective study in China. General aspects of xanthelasma were described, including clinical aspect, endoscopic and histological findings. Furthermore, we focused on relationship between xanthelasma and metabolic disorders, as well as inflammation property.

MATERIALS AND METHODS

Study population

This study was performed among adults who underwent upper gastrointestinal endoscopy at the First Affiliated Hospital, College of Medicine, Zhejiang University, Hangzhou, China during Jan., 2009 to Nov., 2016. Endoscopic xanthelasma group was defined as patients with xanthelasma as one of their endoscopic findings. Biopsy-proven xanthelasma were those who did biopsy at suspicious xanthelasma lesion and histological staining showed typical foam cells which supported diagnosis of xanthelasma.

The study protocol was approved by the Hospital Ethics Committee and performed in accordance with Declaration of Helsinki. All persons gave their informed consent prior to their inclusion. Patients with history of gastric cancer, gastrectomy, proton pump inhibitor use within the last 2 wk, antibiotics use within the last 4 wk, poor general condition not suitable for prolonged procedure time, and surveillance or inability to give informed consent were excluded.

Clinical evaluations

Clinical evaluations were performed according to procedures as previously described^[8]. In brief, demographic data, health habits and outpatient records (chief complaint, medical history, home medications, *et al*) were collected by trained physicians. Standing height and body weight without shoes and with light clothes

were measured using standard procedures. BMI was calculated as body weight (kg) divided by square of height (m). Waist circumference was measured at the level of the narrowest point between iliac crest and rib cage using a non-stretchable tape. Systolic and diastolic blood pressures were measured using an automated sphygmomanometer, with participants in sitting position. Overnight fasting blood samples were obtained. Blood routine, as well as biochemical factors, including liver enzymes, serum lipids, glucose, and uric acid, was measured as previously described^[9,10]. Carbohydrate antigen 199 (CA199) level and carcinoembryonic antigen (CEA) was measured by ECLIA on a Modular Analytics E module (Roche Diagnostics Co., Tokyo, Japan).

Endoscopy procedure

Procedure of upper gastrointestinal endoscopy was described in previous study^[11]. Two endoscopists worked together on each patient during the whole procedure including biopsy. For controversial or non-classifiable cases, consensus was reached by discussion with one or more senior endoscopists. Gastric antrum was routine biopsies site. Additional biopsy were collected where lesion was found. The biopsy samples were fixed in formalin and sent to pathology laboratory in two separate vials, labeled according to their demographic data and anatomic sites.

Endoscopic xanthelasma diagnosis was based on observation of typical lesions appearing as a yellow-white nodule or plaque. Anatomic location and size of all xanthelasma lesion were recorded during procedure. Size was estimated by comparing it with open biopsy forceps^[12]. Non-gastric gastrointestinal xanthelasma refers to xanthelasma within GI tract, but not located in stomach; extra-gastrointestinal xanthelasma refers to xanthelasma other than GI tract, such as skin xanthelasma or eye xanthelasma.

Histologic evaluation

Histology of each specimen was determined by two experienced pathologists independently, who were blinded to endoscopic findings. Procedures and definitions of different lesion were described in previous reports^[11,12].

H. pylori status was evaluated by modified Giemsa staining. Dysplasia refers to phenotypically neoplastic epithelium confined to glandular structures inside the basement membrane^[13]. Atrophy of gastric mucosa indicates that the gastric glands proper in the gastric mucosa become sparse.

Foamy cells were typical histological findings and diagnostic prior criteria of xanthelasma^[2]. The histologic appearance of lipid islands was described as lamina propria occupied by large ovoid to polygonal histiocytes with an abundant, finely vacuolated (foamy) cytoplasm staining lightly with eosin. Nuclei of foam cell were regular, round to ovoid, and occupied a small portion

of cell area. Intestinal metaplasia was characterized by presence of histologically typical goblet cells. Grade of intestinal metaplasia was classified according to goblet cell density (low for 1-10, medium for 10-50 and high as > 50 goblet cells per low power field). If any inconsistency of two pathologists, the biopsy specimens were assessed by a third experienced pathologist, and the final diagnosis was based on diagnosis of the majority.

Statistical analysis

Statistical analyses was performed using SPSS 20.0 software for Windows (IBM Inc., Chicago, IL, United States). Continuous variables were shown as mean and standard deviation and compared using Student's *t*-test or Mann-Whitney *U* test. Categorical variables were analyzed using χ^2 test. Univariable and multivariable logistic analysis were adopted in constructing a predicting model of xanthelasma. 2-tailed *P* value less than 0.05 was considered as statistically significant.

RESULTS

General aspect of gastric xanthelasma among study population

From 2009 to 2016, a total of 176006 endoscopies was retrieved in the First Affiliated Hospital. Among them, 1370 xanthelasma were identified, with prevalence being 0.78%. Proportion of female and male was almost equivalent (667 vs 703). Xanthelasma was seen in a relative elderly group, with average age of 56.6 ± 11.2 years (57.2 ± 11.5 for male and 55.9 ± 10.9 for female).

Among all patients with xanthelasma, 24.2% complained of abdominal pain, 9.1% visited hospital for dyspepsia, 10.1% came with abdominal distention, and 14.1% for up-abdominal discomfort. Other symptoms like constipation, regurgitation, and diarrhea were seen in minority.

Xanthelasma appeared in most cases as single lesion, 6.1% were found as double or multiple. Average size of xanthelasma was 0.40 ± 0.24 cm. Most common site of xanthelasma was antrum (as high as 70.7%), corpus being the second (15.2%), and angulus xanthelasma accounted for 10.1% patients. None was seen in the fundus. Among all antrum xanthelasma, 35.7% were found in greater curvature, 26.3% in less curvature, 11.1% in the frontier wall and the rest in the posterior. No non-gastric gastrointestinal xanthelasma or extra-gastrointestinal xanthelasma was identified in current study.

Gastric xanthelasma, atrophy, *H. pylori* infection, intestinal metaplasia and dysplasia

In order to investigate relationship between xanthelasma and other gastric lesion (such as atrophy, *H. pylori* infection, intestinal metaplasia and dysplasia), 207 patients without biopsy were excluded in current

Table 1 χ^2 analysis of *Helicobacter pylori*, atrophy, infection, intestinal metaplasia and dysplasia rate in xanthelasma and non-xanthelasma group *n* (%)

Variables	Xanthelasma	Non-xanthelasma	χ^2	P
<i>n</i> (male/female)	1163 (602/561)	1163 (602/561)	-	1
Age (yr)	57 ± 11	56 ± 13	-	0.619
<i>Helicobacter pylori</i> infection	358 (30.8)	341 (29.4)	0.269	0.603
Atrophy	155 (13.3)	58 (4.9)	13.1	< 0.01
Intestinal metaplasia	576 (49.5)	166 (14.3)	44.6	< 0.001
Low grade	331 (28.5)	119 (10.3)	15.6	< 0.001
Medium grade	199 (17.1)	43 (3.7)	27.1	< 0.001
High grade	46 (4.0)	4 (0.3)	13.7	< 0.001
dysplasia	24 (2.1)	36 (3.1)	14.3	< 0.01

Table 2 Metabolic factors in xanthelasma and non-xanthelasma groups

Variables	Non-xanthelasma	Xanthelasma	P
<i>n</i> (male/female)	99 (41/58)	99 (41/58)	1.000
Age (yr)	55 ± 13	56 ± 11	0.537
Body mass index (kg/m ²)	22.1 ± 2.3	23.2 ± 2.3	0.288
Systolic blood pressure	119 ± 16	117 ± 13	0.818
Diastolic blood pressure	73 ± 10	73 ± 13	0.785
Alanine aminotransferase	20 ± 13	20 ± 9	0.953
Aspartate aminotransferase (U/L)	21 ± 6	21 ± 4	0.669
Alkaline phosphatase (U/L)	67 ± 18	72 ± 21	0.202
γ -Glutamyltransferase (U/L)	23 ± 18	27 ± 32	0.327
Total bilirubin (μ mol/L)	12.2 ± 3.8	13.4 ± 8.5	0.246
Triglyceride (mmol/L)	1.07 ± 0.55	1.33 ± 0.63	< 0.05
Albumin (g/L)	47.5 ± 3.2	46.2 ± 3.8	0.063
Total cholesterol (mmol/L)	4.51 ± 0.77	4.59 ± 0.78	0.614
HDL-cholesterol (mmol/L)	1.45 ± 0.35	1.26 ± 0.33	< 0.01
LDL cholesterol (mmol/L)	2.42 ± 0.61	2.56 ± 0.52	0.259
Fasting plasma glucose (mmol/L)	4.71 ± 0.50	5.08 ± 0.58	< 0.001
Hb1Ac (%)	5.49 ± 1.19	5.5 ± 0.17	0.984
Serum uric acid (μ mol/L)	303 ± 79	328 ± 91	0.119
CEA (ng/mL)	1.8 ± 1.2	2.8 ± 1.6	< 0.001
CA199 (U/mL)	8.3 ± 9.5	9.4 ± 12	0.780

HDL-cholesterol: High density lipoprotein cholesterol; LDL-cholesterol: Low density lipoprotein cholesterol; CA199: Carbohydrate antigen 199; CEA: Carcinoembryonic antigen.

analysis (Table 1). Among all 1163 xanthelasma, *H. pylori* infection rate was 30.8%. In 13.3% xanthelasma patients, atrophy was identified. Prevalence of dysplasia was 2.1%. To look deep into transition from gastritis to dysplasia, intestinal metaplasia was investigated. Pathological evaluation of intestinal metaplasia was conducted and sorted into three degrees, and it showed that high, medium and low grade intestinal metaplasia was found in 28.5%, 17.1% and 4.0% xanthelasma population, respectively.

To dig deep into relationship of these findings with xanthelasma, 1163 patients without endoscopic xanthelasma were also included among people who underwent endoscopy in our hospital (Table 1). Comparing with control group, patients with xanthelasma showed a slightly higher rate of *H. pylori* infection but not

significant. Atrophy was more prevalent in xanthelasma (13.3% vs 4.9% in control group, $P < 0.01$). Similarly, all three grades of intestinal metaplasia was seen more common in xanthelasma. Prevalence of dysplasia was not seven-fold higher in xanthelasma than non-xanthelasma group (2.1% vs 0.3% in control group, $P < 0.001$).

Association between gastric xanthelasma and metabolic disorders

Among 1370 endoscopic diagnosed xanthelasma, 99 were biopsy-proven, which were included in further analysis, with 41 being male and 58 female (Table 2, Figure 1). 99 healthy controls were collected from annual health examination who underwent endoscopy with negative finding of xanthelasma. Mean age in xanthelasma was 56 ± 11 years, and 55 ± 13 in non-xanthelasma. Body mass index was similar in these two group (23.2 ± 2.3 in xanthelasma vs 22.1 ± 2.3 in non-xanthelasma), as well as blood pressure (systolic 117 ± 13 and diastolic 73 ± 13 in xanthelasma vs systolic 119 ± 16 and diastolic 73 ± 10 in non-xanthelasma).

Serum lipid profile was found distinct between two groups (Figure 1). Xanthelasma patients showed significant higher TG (1.33 ± 0.63 vs 1.07 ± 0.55 in non-xanthelasma, $P < 0.05$) and lower HDL-cholesterol (1.45 ± 0.35 vs 1.26 ± 0.33 in non-xanthelasma, $P < 0.01$), but no difference in LDL-cholesterol or total cholesterol. As for glucose metabolism, serum fasting glucose was increased in xanthelasma (5.08 ± 0.58 vs 4.71 ± 0.49 in non-xanthelasma, $P < 0.001$), but Hb1Ac was similar.

Tumor marker CEA was higher in xanthelasma group (2.8 ± 1.6 vs 1.8 ± 1.2 in non-xanthelasma, $P < 0.001$), but CA199 was similar in two groups (9.4 ± 12 vs 8.7 ± 9.5 in non-xanthelasma).

No significant disparity was seen in liver enzyme, including ALT, AST, ALP and GGT. Other factors, such as total bilirubin, albumin and serum uric acid were not different in two groups.

Metabolic comorbidities in xanthelasma

Data of metabolic comorbidities were collected in xanthelasma and non-xanthelasma group (Table 3). In xanthelasma, fatty liver was more prevalent than non-

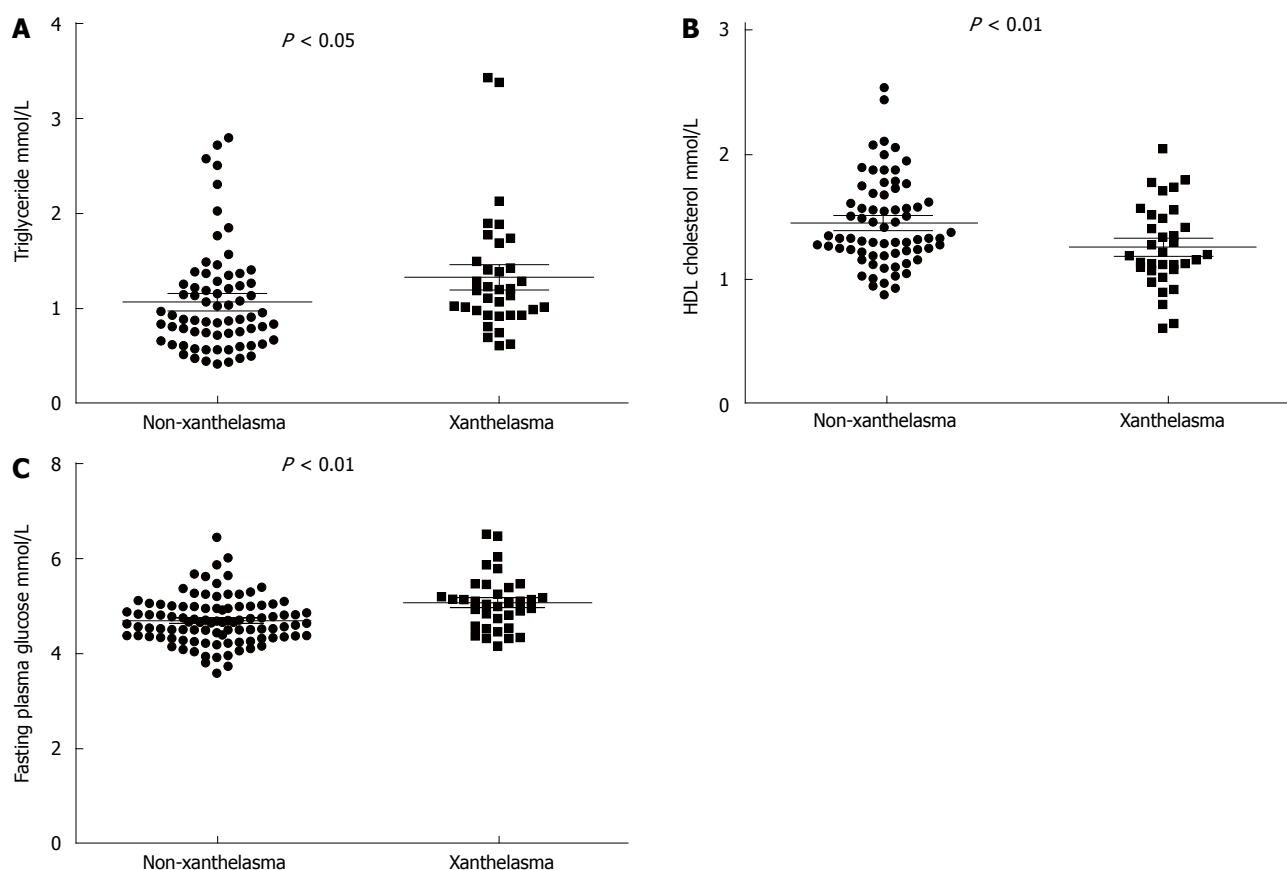


Figure 1 Metabolic changes in xanthelasma. A: TG; B: HDL-cholesterol; C: Fasting plasma glucose. HDL-cholesterol: High density lipoprotein cholesterol.

Table 3 Metabolic comorbidities in xanthelasma and non-xanthelasma group *n* (%)

Metabolic comorbidity	Non-xanthelasma	Xanthelasma	<i>P</i>
Biliary and liver diseases			
Chronic liver disease	2 (2.0)	4 (8.9)	0.911
Fatty liver	15 (15.2)	13 (28.9)	< 0.05
Hemangioma	1 (1.9)	1 (2.1)	0.568
Cyst	10 (10.1)	8 (17.0)	< 0.05
Post-cholecystectomy	2 (2.0)	4 (8.5)	0.911
Gallstone	4 (4.0)	3 (6.8)	0.132
Gallbladder polyp	9 (9.1)	3 (6.8)	< 0.01
Cardio-cerebral-vascular disease			
Coronary artery disease	1 (1.0)	2 (4.9)	0.877
Atrial fibrillation	0 (0)	1 (2.4)	0.522
Carotid atherosclerosis	5 (5.1)	6 (14.6)	0.223
Stroke	0 (0)	1 (2.4)	0.522
Thyroid disease	4 (4.0)	4 (9.8)	0.187
Diabetes mellitus	1 (1.0)	2 (4.9)	0.877

xanthelasma (28.9% vs 15.2% in non-xanthelasma). Liver cyst was found more frequent in xanthelasma (10.1% vs 17% in non-xanthelasma) and fewer gallbladder polyp was discovered in xanthelasma (9.1% vs 6.8% in xanthelasma). Prevalence of other diseases, including chronic liver disease, hemangioma, gallstone coronary artery disease, atrial fibrillation, carotid atherosclerosis, stroke, thyroid disease and diabetes mellitus were similar in two groups.

Difference in serum inflammatory markers in gastric xanthelasma

Inflammation markers were analyzed in our study as well (Table 4, Figure 2). In xanthelasma group, neutrophil was higher (3.4 ± 1.3 vs 4.0 ± 1.3 in non-xanthelasma, $P < 0.05$), lymphocyte was lower (2.1 ± 0.5 vs 1.8 ± 0.8 in non-xanthelasma, $P < 0.05$), newly developed inflammation related index NLR (Neutrophil-to-lymphocyte ratio) was significantly increased (1.74 ± 0.74 vs 2.62 ± 1.92 in non-xanthelasma, $P < 0.001$), but C-reactive protein (CRP) was similar (2.4 ± 4.6 vs 2.4 ± 2.8 in non-xanthelasma, $P = 0.124$).

Independent risk factors in gastric xanthelasma

In order to investigate diagnostic and predictive role of metabolic and inflammatory factors in xanthelasma, univariable logistic analysis was adopted. It turned out that fasting plasma glucose (OR = 3.740, 95%CI: 1.721-8.129, $P < 0.01$), neutrophil (OR = 1.329, 95%CI: 1.004-1.758, $P < 0.05$), NLR (OR = 2.097, 95%CI: 1.234-3.564, $P < 0.01$), and CEA (OR = 1.882, 95%CI: 1.195-2.964, $P < 0.01$) were significantly associated with gastric xanthelasma (Table 5).

To gain more specific knowledge of whether these four factors are independent, multivariable logistic regression was used. As NLR was a calculated index from neutrophil, we herein included fasting plasma glucose, neutrophil, and CEA in further analysis to

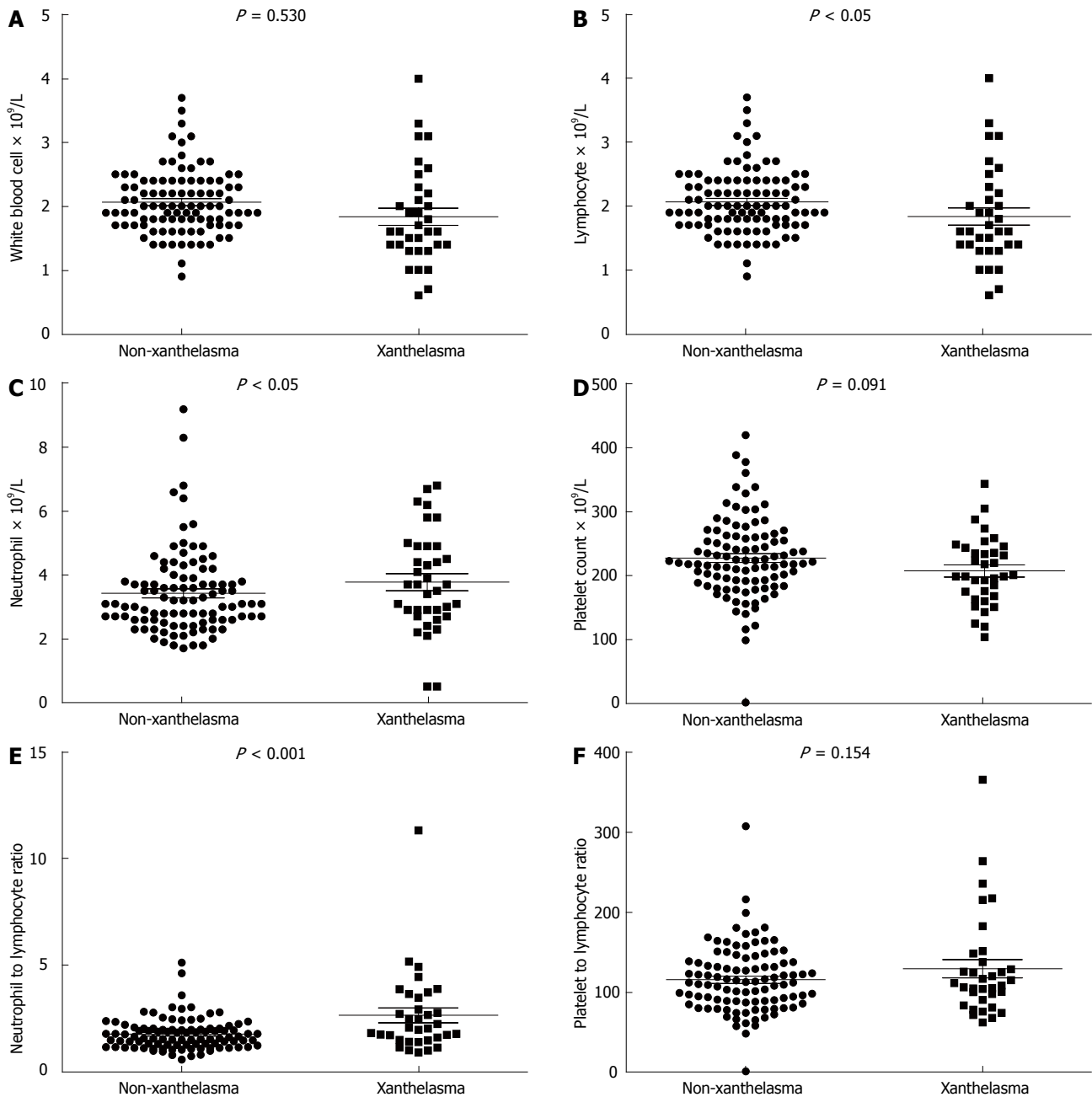


Figure 2 Blood routine changes in xanthelasma. A: WBC; B: Lymphocyte; C: Neutrophil; D: Platelet count; E: NLR; F: PLR; NLR: Neutrophil-to-lymphocyte ratio; PLR: Platelet-to-lymphocyte ratio.

avoid potential confounding. It manifested that fasting plasma glucose (OR = 3.347, 95%CI: 1.170-9.575, $P < 0.05$), neutrophil (OR = 1.617, 95%CI: 1.003-2.605, $P < 0.05$), and CEA (OR = 2.011, 95%CI: 1.236-3.271, $P < 0.01$) were all independent risk factors in xanthelasma (Table 6).

DISCUSSION

Current study was the first populational based cohort of xanthelasma in China. This retrospective study collected a large xanthelasma group in Chinese population. Prevalence of endoscopic xanthelasma was 0.78% in our cohort with average age of 56.6 ± 11.2 . Reasons of

hospital visiting included abdominal pain (24.2%), up-abdominal discomfort (14.1%), abdominal distention (10.1%), and dyspepsia (9.1%), *et al.* Xanthelasma was most frequently seen in antrum as a single lesion. Chi-square analysis revealed positive relationship between prevalence of xanthelasma and *H. pylori* infection rate, more atrophy, intestinal metaplasia, dysplasia respectively. Metabolic and inflammatory factors were found associated with xanthelasma, as with higher CEA, TG, fasting glucose, neutrophil, NLR index, fatty liver comorbidity and lower HDL-cholesterol, lymphocyte. Among all these factors, fasting plasma glucose, neutrophil, and CEA were proved to be independent factors in xanthelasma.

Table 4 Serum inflammatory markers in xanthelasma and non-xanthelasma groups

Variables	Non-xanthelasma	Xanthelasma	P
White blood cell ($\times 10^9/L$)	6.0 \pm 1.5	5.8 \pm 1.6	0.530
Neutrophil ($\times 10^9/L$)	3.4 \pm 1.3	4.0 \pm 1.3	< 0.05
Lymphocyte ($\times 10^9/L$)	2.1 \pm 0.5	1.8 \pm 0.8	< 0.05
Hemoglobin (g/L)	141 \pm 15	141 \pm 17	0.950
Platelet count ($\times 10^9/L$)	228 \pm 63	208 \pm 53	0.091
NLR	1.74 \pm 0.74	2.62 \pm 1.92	< 0.001
PLR	116 \pm 41	129 \pm 65	0.154
CRP (mg/L)	2.4 \pm 4.6	2.4 \pm 2.8	0.124

NLR: Neutrophil-to-lymphocyte ratio; PLR: Platelet-to-lymphocyte ratio; CRP: C-reactive protein.

Table 5 Univariable logistic regression of xanthelasma-related factors

Variables	OR	95%CI	P
n (male/female)	1.006	0.571-1.773	0.983
Age (yr)	1.007	0.984-1.131	0.535
Body mass index (kg/m ²)	1.188	0.866-1.629	0.286
Systolic blood pressure	0.972	0.904-1.045	0.437
Diastolic blood pressure	1.045	0.938-1.163	0.425
Alanine aminotransferase	1.051	0.975-1.131	0.192
Aspartate aminotransferase (U/L)	0.911	0.801-1.037	0.159
Alkaline phosphatase (U/L)	1.011	0.986-1.036	0.393
γ -Glutamyltransferase (U/L)	0.992	0.961-1.024	0.623
Total bilirubin (μ mol/L)	1.071	0.971-1.180	0.171
Triglyceride (mmol/L)	1.145	0.361-3.632	0.818
Albumin (g/L)	0.902	0.805-1.009	0.072
Total cholesterol (mmol/L)	0.178	0.010-3.133	0.238
HDL-cholesterol (mmol/L)	9.130	0.448-185.8	0.150
LDL-cholesterol (mmol/L)	4.764	0.183-123.9	0.348
Fasting plasma glucose (mmol/L)	3.740	1.721-8.129	< 0.01
Hb1Ac (%)	1.011	0.350-2.924	0.983
Serum uric acid (μ mol/L)	1.006	0.999-1.012	0.088
White blood cell ($\times 10^9/L$)	0.919	0.708-1.194	0.527
Neutrophil ($\times 10^9/L$)	1.329	1.004-1.758	< 0.05
Lymphocyte ($\times 10^9/L$)	0.471	0.222-1.000	0.050
Hemoglobin (g/L)	1.012	0.955-1.072	0.695
Platelet count ($\times 10^9/L$)	0.971	0.927-1.016	0.200
NLR	2.097	1.234-3.564	< 0.01
PLR	1.071	0.995-1.152	0.069
CRP (mg/L)	0.998	0.838-1.188	0.980
CEA (ng/mL)	1.882	1.195-2.964	< 0.01
CA199 (U/mL)	1.007	0.961-1.054	0.777

HDL-cholesterol: High density lipoprotein cholesterol; LDL-cholesterol: Low density lipoprotein cholesterol; CA199: Carbohydrate antigen 199; CEA: Carcinoembryonic antigen; NLR: Neutrophil-to-lymphocyte ratio; PLR: Platelet-to-lymphocyte ratio; CRP: C-reactive protein.

Current analysis revealed co-existence of atrophy, intestinal metaplasia and dysplasia in xanthelasma, indicating a potential pro-tumorigenesis role in gastric pathology. In previous prospective study, age/sex/atrophy-matched control analysis demonstrated that the presence of gastric xanthelasma was significantly associated with the presence of gastric cancer, indicating that xanthelasma could serve as a warning sign of gastric cancer^[4]. Furthermore, in a Japanese cohort,

Table 6 Multivariable logistic regression of xanthelasma-related factors

Variables	OR	95%CI	P
Fasting plasma glucose (mmol/L)	3.347	1.170-9.575	< 0.05
Neutrophil ($\times 10^9/L$)	1.617	1.003-2.605	< 0.05
CEA (ng/mL)	2.011	1.236-3.271	< 0.01

CEA: Carcinoembryonic antigen.

with follow-up being more than three years, gastric xanthelasma was shown to be a useful marker for gastric cancer development^[11]. Other than endoscopic diagnosis of gastric cancer, serum CEA level in xanthelasma group was significantly elevated. The exact mechanism behind this remained unknown. But it was speculated that reactive oxygen species (ROS) might be the mediator. First, increased release of ROS may be involved in accumulation of oxidized LDL cholesterol and development of gastric xanthelasma^[14]. On this basis, ROS can cause DNA damage and associated oncogenic changes, thus lead to tumorigenesis^[15,16]. However, molecular and cell biology experiments were needed to support the idea.

This study identified a slightly higher *H. pylori* infection rate in gastric xanthelasma. Recent years witnessed rapid increase rate in infection, especially in China^[17]. As high as 57.6% people in population carried *H. pylori*^[18]. *H. pylori* is a well-known cause of various gastrointestinal issues, such as peptic ulcer disease, gastroesophageal reflux disease and chronic active gastritis as well^[19]. Chronic gastritis is thought to be involved in gastric glandular atrophy and intestinal metaplasia, which is considered as a precursor of gastric tumorigenesis^[20]. In consistent with our findings, Hori and Tsutsumi first reported that *H. pylori* infection was seen on the surface of foveolar cells in 48% of biopsy samples of xanthelasma in 1996^[5]. To further support that, Isomoto, in 1999, also reported a close relationship among *H. pylori* infection, xanthelasma, and atrophic gastritis^[6]. Similarly, a large cohort in Korea also identified this association and proposed that xanthelasma may be provoked by *H. Pylori* infection^[2].

In order to better understand role of chronic inflammation and xanthelasma, this study also investigated relationship between serum inflammatory biomarkers and xanthelasma, which revealed an increasing trend of neutrophil and a decrease in lymphocyte with negative relationship of CRP, an acute phase protein. Moreover, NLR index, defined as neutrophil counts divided by lymphocyte counts, was introduced. In most cases, lymphopenia well reflects impaired cell-mediated immunity, while neutrophilia represents a response to systematic inflammation, so high NLR represents systemic and local inflammatory state^[21]. Emerging evidences have shown an important role of NLR in different cancer types and metabolic disease such as cardiovascular disease as well^[22,23]. These results further

supported an inflamed environment in xanthelasma.

Xanthelasma was characterized by deposit of lipid in gastrointestinal tract. In this study, we found a positive association between xanthelasma and serum TG level accompanied by decreased HDL cholesterol. As a major component in metabolic syndrome, fatty liver was seen more frequent in xanthelasma patients. Glucose metabolism was also impaired in xanthelasma, supported by significantly higher fasting plasma glucose. However, Hb1Ac did not differ between groups. This indicated a scenario of slight fasting glucose intolerance, rather than well-established diabetes. Moreover, the amount of epicardial adipose tissue found in subjects with xanthelasma was higher and, the presence of xanthelasma was independently associated with supra-median epicardial fat thickness^[24]. Whether these were random findings or potential causal relationship in pathogenesis still need further studies.

However, this study has several limitations. Firstly, with the nature of retrospective case-control study, no causal relationship can be identified between either xanthelasma and other gastric pathology or xanthelasma with metabolic disorders. Further prospective studies are needed in this concern and in other groups to improve generalizability. Secondly, as was a retrospective study, no standard procedure of xanthelasma treatment was set. Difference might existed among endoscopists. Rate of xanthelasma biopsy would be underestimated.

Current study described a large xanthelasma cohort in Chinese population, and revealed its positive relationship with *H. pylori* infection, atrophy, intestinal metaplasia, dysplasia, and metabolic disorder as well, indicating an important role of xanthelasma in both carcinogenesis and metabolic dysfunction. Logistic regression revealed role of fasting plasma glucose, neutrophil, and CEA as independent risk factors in xanthelasma.

COMMENTS

Background

Xanthelasma was a relatively rare endoscopic finding, characterized by accumulation of lipid in histiocytic foam cells in mucosa. To gain knowledge of xanthelasma, a large population-based study was conducted.

Research frontiers

As xanthelasma was defined as lipid deposit in stomach, its relevance to metabolic disorders was of great interest. Dyslipidemia, representative of lower mean high density lipoprotein-cholesterol and higher mean triglyceride levels was found in two Korean studies, accompanied with higher body mass index in gastric xanthelasma subjects in comparison with the controls. But, there were no reports in this concern in Chinese population yet.

Innovations and breakthroughs

Current study described a large xanthelasma cohort in Chinese population, revealed its positive relationship with *H. pylori* infection, atrophy, intestinal metaplasia, dysplasia, and metabolic disorder as well, indicating an important role of xanthelasma in both carcinogenesis and metabolic dysfunction.

Applications

With better understanding of xanthelasma pathogenesis and its relationship with

metabolic, immunogenic and carcinogenic factors, clinical value of xanthelasma as predicting factor will be envisaged.

Peer-review

The authors studied the relationship between gastric xanthelasma and metabolic disorders in Chinese patients. They collected patient information from endoscopy archives and analysis the relationship of xanthelasma with several biochemical, metabolic and tumor markers.

REFERENCES

- 1 **Sekikawa A**, Fukui H, Sada R, Fukuhara M, Marui S, Tanke G, Endo M, Ohara Y, Matsuda F, Nakajima J, Henmi S, Saito S, Tsumura T, Maruo T, Kimura T, Osaki Y. Gastric atrophy and xanthelasma are markers for predicting the development of early gastric cancer. *J Gastroenterol* 2016; **51**: 35-42 [PMID: 25904098 DOI: 10.1007/s00535-015-1081-0]
- 2 **Yi SY**. Dyslipidemia and *H. pylori* in gastric xanthomatosis. *World J Gastroenterol* 2007; **13**: 4598-4601 [PMID: 17729413 DOI: 10.3748/wjg.v13.i34.4598]
- 3 **Dhakal M**, Dhakal OP, Bhandari D, Gupta A. Gastric xanthelasma: an unusual endoscopic finding. *BMJ Case Rep* 2013; **2013**: bcr2013201017 [PMID: 24165503 DOI: 10.1136/bcr-2013-201017]
- 4 **Sekikawa A**, Fukui H, Maruo T, Tsumura T, Kanesaka T, Okabe Y, Osaki Y. Gastric xanthelasma may be a warning sign for the presence of early gastric cancer. *J Gastroenterol Hepatol* 2014; **29**: 951-956 [PMID: 24372908 DOI: 10.1111/jgh.12512]
- 5 **Hori S**, Tsutsumi Y. Helicobacter pylori infection in gastric xanthomas: immunohistochemical analysis of 145 lesions. *Pathol Int* 1996; **46**: 589-593 [PMID: 8893228]
- 6 **Isomoto H**, Mizuta Y, Inoue K, Matsuo T, Hayakawa T, Miyazaki M, Onita K, Takeshima F, Murase K, Shimokawa I, Kohno S. A close relationship between Helicobacter pylori infection and gastric xanthoma. *Scand J Gastroenterol* 1999; **34**: 346-352 [PMID: 10365893]
- 7 **Chang FY**, Shih CY, Lee SD. Abnormal serum lipid levels in subjects with gastric xanthoma. *Clin Chim Acta* 1993; **217**: 233-235 [PMID: 8261635]
- 8 **Xu C**, Chen Y, Xu L, Miao M, Li Y, Yu C. Serum complement C3 levels are associated with nonalcoholic fatty liver disease independently of metabolic features in Chinese population. *Sci Rep* 2016; **6**: 23279 [PMID: 27029598 DOI: 10.1038/srep23279]
- 9 **Wang J**, Xu C, Xun Y, Lu Z, Shi J, Yu C, Li Y. ZJU index: a novel model for predicting nonalcoholic fatty liver disease in a Chinese population. *Sci Rep* 2015; **5**: 16494 [PMID: 26568423 DOI: 10.1038/srep16494]
- 10 **Wang J**, Zhu W, Huang S, Xu L, Miao M, Wu C, Yu C, Li Y, Xu C. Serum apoB levels independently predict the development of non-alcoholic fatty liver disease: A 7-year prospective study. *Liver Int* 2017; **37**: 1202-1208 [PMID: 28106941 DOI: 10.1111/liv.13363]
- 11 **Du Y**, Bai Y, Xie P, Fang J, Wang X, Hou X, Tian D, Wang C, Liu Y, Sha W, Wang B, Li Y, Zhang G, Li Y, Shi R, Xu J, Li Y, Huang M, Han S, Liu J, Ren X, Xie P, Wang Z, Cui L, Sheng J, Luo H, Wang Z, Zhao X, Dai N, Nie Y, Zou Y, Xia B, Fan Z, Chen Z, Lin S, Li ZS; Chinese Chronic Gastritis Research group. Chronic gastritis in China: a national multi-center survey. *BMC Gastroenterol* 2014; **14**: 21 [PMID: 24502423 DOI: 10.1186/1471-230X-14-21]
- 12 **Köksal AS**, Suna N, Kalkan İH, Eminler AT, Sakaogulları ŞZ, Turhan N, Saygılı F, Kuzu UB, Öztas E, Parlak E. Is Gastric Xanthelasma an Alarming Endoscopic Marker for Advanced Atrophic Gastritis and Intestinal Metaplasia? *Dig Dis Sci* 2016; **61**: 2949-2955 [PMID: 27250981 DOI: 10.1007/s10620-016-4210-6]
- 13 **Rugge M**, Correa P, Dixon MF, Hattori T, Leandro G, Lewin K, Riddell RH, Sipponen P, Watanabe H. Gastric dysplasia: the Padova international classification. *Am J Surg Pathol* 2000; **24**: 167-176 [PMID: 10680883]
- 14 **Kaiserling E**, Heinle H, Itabe H, Takano T, Remmele W. Lipid islands in human gastric mucosa: morphological and immunohistochemical findings. *Gastroenterology* 1996; **110**: 369-374 [PMID: 8566582]
- 15 **Ding Y**, Wang H, Niu J, Luo M, Gou Y, Miao L, Zou Z, Cheng Y.

- Induction of ROS Overload by Alantolactone Prompts Oxidative DNA Damage and Apoptosis in Colorectal Cancer Cells. *Int J Mol Sci* 2016; **17**: 558 [PMID: 27089328 DOI: 10.3390/ijms17040558]
- 16 **Sridharan DM**, Asaithamby A, Bailey SM, Costes SV, Doetsch PW, Dynan WS, Kronenberg A, Rithidech KN, Saha J, Snijders AM, Werner E, Wiese C, Cucinotta FA, Pluth JM. Understanding cancer development processes after HZE-particle exposure: roles of ROS, DNA damage repair and inflammation. *Radiat Res* 2015; **183**: 1-26 [PMID: 25564719 DOI: 10.1667/RR13804.1]
- 17 **Leja M**, Axon A, Brenner H. Epidemiology of *Helicobacter pylori* infection. *Helicobacter* 2016; **21** Suppl 1: 3-7 [PMID: 27531531 DOI: 10.1111/hel.12332]
- 18 **Pan KF**, Zhang L, Gerhard M, Ma JL, Liu WD, Ulm K, Wang JX, Zhang L, Zhang Y, Bajbouj M, Zhang LF, Li M, Vieth M, Liu RY, Quante M, Wang LH, Suchanek S, Zhou T, Guan WX, Schmid R, Classen M, You WC. A large randomised controlled intervention trial to prevent gastric cancer by eradication of *Helicobacter pylori* in Linq County, China: baseline results and factors affecting the eradication. *Gut* 2016; **65**: 9-18 [PMID: 25986943 DOI: 10.1136/gutjnl-2015-309197]
- 19 **Tsukanov VV**, Kasparov EV, Tonkikh JL, Shtygasheva OV, Butorin NN, Amelchugova OS, Vasyutin AV, Bronnikova EP, Fassan M, Rugge M. Peptic Ulcer Disease and *Helicobacter pylori* Infection in Different Siberian Ethnicities. *Helicobacter* 2017; **22**: Epub 2016 Jun 6 [PMID: 27265879 DOI: 10.1111/hel.12322]
- 20 **Sokic-Milutinovic A**, Alempijevic T, Milosavljevic T. Role of *Helicobacter pylori* infection in gastric carcinogenesis: Current knowledge and future directions. *World J Gastroenterol* 2015; **21**: 11654-11672 [PMID: 26556993 DOI: 10.3748/wjg.v21.i41.11654]
- 21 **Grivennikov SI**, Greten FR, Karin M. Immunity, inflammation, and cancer. *Cell* 2010; **140**: 883-899 [PMID: 20303878 DOI: 10.1016/j.cell.2010.01.025]
- 22 **Xue J**, Huang W, Chen X, Li Q, Cai Z, Yu T, Shao B. Neutrophil-to-Lymphocyte Ratio Is a Prognostic Marker in Acute Ischemic Stroke. *J Stroke Cerebrovasc Dis* 2017; **26**: 650-657 [PMID: 27955949 DOI: 10.1016/j.jstrokecerebrovasdis.2016.11.010]
- 23 **Hu K**, Lou L, Ye J, Zhang S. Prognostic role of the neutrophil-lymphocyte ratio in renal cell carcinoma: a meta-analysis. *BMJ Open* 2015; **5**: e006404 [PMID: 25854964 DOI: 10.1136/bmjopen-2014-006404]
- 24 **Akyüz AR**, Ağaç MT, Turan T, Şahin S, Kul S, Korkmaz L, Erkuş ME, Erkan H, Çelik Ş. Xanthelasma Is Associated with an Increased Amount of Epicardial Adipose Tissue. *Med Princ Pract* 2016; **25**: 187-190 [PMID: 26488592 DOI: 10.1159/000441846]

P- Reviewer: Ding SZ, Lankarani KB, Lee CL **S- Editor:** Ma YJ
L- Editor: A **E- Editor:** Lu YJ





Published by **Baishideng Publishing Group Inc**
7901 Stoneridge Drive, Suite 501, Pleasanton, CA 94588, USA
Telephone: +1-925-223-8242
Fax: +1-925-223-8243
E-mail: bpgoffice@wjgnet.com
Help Desk: <http://www.f6publishing.com/helpdesk>
<http://www.wjgnet.com>



ISSN 1007-9327

