

# World Journal of *Gastroenterology*

*World J Gastroenterol* 2018 January 7; 24(1): 1-160



**EDITORIAL**

- 1 Estrogen, estrogen receptors, and hepatocellular carcinoma: Are we there yet?  
*Sukocheva OA*

**REVIEW**

- 5 Relationship between intestinal microbiota and ulcerative colitis: Mechanisms and clinical application of probiotics and fecal microbiota transplantation  
*Shen ZH, Zhu CX, Quan YS, Yang ZY, Wu S, Luo WW, Tan B, Wang XY*

**MINIREVIEWS**

- 15 Updated review on immune factors in pathogenesis of Crohn's disease  
*Li N, Shi RH*

**ORIGINAL ARTICLE****Basic Study**

- 23 Construction of an oesophageal cancer-specific ceRNA network based on miRNA, lncRNA, and mRNA expression data  
*Xue WH, Fan ZR, Li LF, Lu JL, Ma BJ, Kan QC, Zhao J*

- 35 Emodin and baicalein inhibit sodium taurocholate-induced vacuole formation in pancreatic acinar cells  
*Li J, Zhou R, Bie BB, Huang N, Guo Y, Chen HY, Shi MJ, Yang J, Zhang J, Li ZF*

**Case Control Study**

- 46 Increased intestinal mucosal leptin levels in patients with diarrhea-predominant irritable bowel syndrome  
*Liu DR, Xu XJ, Yao SK*

**Retrospective Cohort Study**

- 58 Correlation between smoking habit and surgical outcomes on viral-associated hepatocellular carcinomas  
*Kai K, Komukai S, Koga H, Yamaji K, Ide T, Kawaguchi A, Aishima S, Noshiro H*

**Retrospective Study**

- 69 Safety and efficacy of metallic stent for unresectable distal malignant biliary obstruction in elderly patients  
*Sakai Y, Iwai T, Shimura K, Gon K, Koizumi K, Ijima M, Chiba K, Nakatani S, Sugiyama H, Tsuyuguchi T, Kamisawa T, Maetani I, Kida M*
- 76 Short- and long-term outcomes following laparoscopic vs open surgery for pathological T4 colorectal cancer: 10 years of experience in a single center  
*Yang ZF, Wu DQ, Wang JJ, Lv ZJ, Li Y*

- 87** Differential analysis of lymph node metastasis in histological mixed-type early gastric carcinoma in the mucosa and submucosa  
*Zhong Q, Sun Q, Xu GF, Fan XQ, Xu YY, Liu F, Song SY, Peng CY, Wang L*

**Observational Study**

- 96** HLA-DQ: Celiac disease vs inflammatory bowel disease  
*Bosca-Watts MM, Minguez M, Planelles D, Navarro S, Rodriguez A, Santiago J, Tosca J, Mora F*

- 104** Surgical specimen extraction *via* a prophylactic ileostomy procedure: A minimally invasive technique for laparoscopic rectal cancer surgery  
*Wang P, Liang JW, Zhou HT, Wang Z, Zhou ZX*

**Prospective Study**

- 112** Characterization of biofilms in biliary stents and potential factors involved in occlusion  
*Vaishnavi C, Samanta J, Kochhar R*

**SYSTEMATIC REVIEWS**

- 124** Systematic review of colorectal cancer screening guidelines for average-risk adults: Summarizing the current global recommendations  
*Bénard F, Barkun AN, Martel M, von Renteln D*

**META-ANALYSIS**

- 139** Probiotic monotherapy and *Helicobacter pylori* eradication: A systematic review with pooled-data analysis  
*Losurdo G, Cubisino R, Barone M, Principi M, Leandro G, Ierardi E, Di Leo A*

**CASE REPORT**

- 150** Long-term survival after gastrectomy and metastasectomy for gastric cancer with synchronous bone metastasis  
*Choi YJ, Kim DH, Han HS, Han JH, Son SM, Kim DS, Yun HY*
- 157** Emergent single-balloon enteroscopy for overt bleeding of small intestinal vascular malformation  
*Chung CS, Chen KC, Chou YH, Chen KH*

## ABOUT COVER

Editorial board member of *World Journal of Gastroenterology*, Alexander Link, MD, PhD, Academic Research, Associate Professor, Department of Gastroenterology, Hepatology and Infectious Diseases, Otto-von-Guericke University Hospital Magdeburg, Magdeburg 39120, Germany

## AIMS AND SCOPE

*World Journal of Gastroenterology* (*World J Gastroenterol*, *WJG*, print ISSN 1007-9327, online ISSN 2219-2840, DOI: 10.3748) is a peer-reviewed open access journal. *WJG* was established on October 1, 1995. It is published weekly on the 7<sup>th</sup>, 14<sup>th</sup>, 21<sup>st</sup>, and 28<sup>th</sup> each month. The *WJG* Editorial Board consists of 642 experts in gastroenterology and hepatology from 59 countries.

The primary task of *WJG* is to rapidly publish high-quality original articles, reviews, and commentaries in the fields of gastroenterology, hepatology, gastrointestinal endoscopy, gastrointestinal surgery, hepatobiliary surgery, gastrointestinal oncology, gastrointestinal radiation oncology, gastrointestinal imaging, gastrointestinal interventional therapy, gastrointestinal infectious diseases, gastrointestinal pharmacology, gastrointestinal pathophysiology, gastrointestinal pathology, evidence-based medicine in gastroenterology, pancreatology, gastrointestinal laboratory medicine, gastrointestinal molecular biology, gastrointestinal immunology, gastrointestinal microbiology, gastrointestinal genetics, gastrointestinal translational medicine, gastrointestinal diagnostics, and gastrointestinal therapeutics. *WJG* is dedicated to become an influential and prestigious journal in gastroenterology and hepatology, to promote the development of above disciplines, and to improve the diagnostic and therapeutic skill and expertise of clinicians.

## INDEXING/ABSTRACTING

*World Journal of Gastroenterology* (*WJG*) is now indexed in Current Contents<sup>®</sup>/Clinical Medicine, Science Citation Index Expanded (also known as SciSearch<sup>®</sup>), Journal Citation Reports<sup>®</sup>, Index Medicus, MEDLINE, PubMed, PubMed Central and Directory of Open Access Journals. The 2017 edition of Journal Citation Reports<sup>®</sup> cites the 2016 impact factor for *WJG* as 3.365 (5-year impact factor: 3.176), ranking *WJG* as 29<sup>th</sup> among 79 journals in gastroenterology and hepatology (quartile in category Q2).

## EDITORS FOR THIS ISSUE

Responsible Assistant Editor: Xiang Li  
Responsible Electronic Editor: Yan Huang  
Proofing Editor-in-Chief: Lian-Sheng Ma

Responsible Science Editor: Ze-Mao Gong  
Proofing Editorial Office Director: Jin-Lei Wang

NAME OF JOURNAL  
*World Journal of Gastroenterology*

ISSN  
ISSN 1007-9327 (print)  
ISSN 2219-2840 (online)

LAUNCH DATE  
October 1, 1995

FREQUENCY  
Weekly

EDITORS-IN-CHIEF  
**Damian Garcia-Olmo, MD, PhD, Doctor, Professor, Surgeon**, Department of Surgery, Universidad Autonoma de Madrid; Department of General Surgery, Fundacion Jimenez Diaz University Hospital, Madrid 28040, Spain

**Stephen C Strom, PhD, Professor**, Department of Laboratory Medicine, Division of Pathology, Karolinska Institutet, Stockholm 141-86, Sweden

**Andrzej S Tarnawski, MD, PhD, DSc (Med), Professor of Medicine, Chief Gastroenterology**, VA Long Beach Health Care System, University of California, Irvine, CA, 5901 E. Seventh Str., Long Beach,

CA 90822, United States

EDITORIAL BOARD MEMBERS  
All editorial board members resources online at <http://www.wjgnet.com/1007-9327/editorialboard.htm>

EDITORIAL OFFICE  
Ze-Mao Gong, Director  
*World Journal of Gastroenterology*  
Baishideng Publishing Group Inc  
7901 Stoneridge Drive, Suite 501,  
Pleasanton, CA 94588, USA  
Telephone: +1-925-2238242  
Fax: +1-925-2238243  
E-mail: [editorialoffice@wjgnet.com](mailto:editorialoffice@wjgnet.com)  
Help Desk: <http://www.f6publishing.com/helpdesk>  
<http://www.wjgnet.com>

PUBLISHER  
Baishideng Publishing Group Inc  
7901 Stoneridge Drive, Suite 501,  
Pleasanton, CA 94588, USA  
Telephone: +1-925-2238242  
Fax: +1-925-2238243  
E-mail: [bpgoffice@wjgnet.com](mailto:bpgoffice@wjgnet.com)  
Help Desk: <http://www.f6publishing.com/helpdesk>  
<http://www.wjgnet.com>

PUBLICATION DATE  
January 7, 2018

COPYRIGHT  
© 2018 Baishideng Publishing Group Inc. Articles published by this Open-Access journal are distributed under the terms of the Creative Commons Attribution Non-commercial License, which permits use, distribution, and reproduction in any medium, provided the original work is properly cited, the use is non commercial and is otherwise in compliance with the license.

SPECIAL STATEMENT  
All articles published in journals owned by the Baishideng Publishing Group (BPG) represent the views and opinions of their authors, and not the views, opinions or policies of the BPG, except where otherwise explicitly indicated.

INSTRUCTIONS TO AUTHORS  
Full instructions are available online at <http://www.wjgnet.com/bpg/gerinfo/204>

ONLINE SUBMISSION  
<http://www.f6publishing.com>

## Retrospective Study

# Differential analysis of lymph node metastasis in histological mixed-type early gastric carcinoma in the mucosa and submucosa

Qian Zhong, Qi Sun, Gui-Fang Xu, Xiu-Qin Fan, Yuan-Yuan Xu, Fei Liu, Shi-Yi Song, Chun-Yan Peng, Lei Wang

Qian Zhong, Gui-Fang Xu, Xiu-Qin Fan, Yuan-Yuan Xu, Fei Liu, Shi-Yi Song, Chun-Yan Peng, Lei Wang, Department of Gastroenterology, the Affiliated Drum Tower Hospital of Nanjing University Medical School, Nanjing 210008, Jiangsu Province, China

Qi Sun, Department of Pathology, the Affiliated Drum Tower Hospital of Nanjing University Medical School, Nanjing 210008, Jiangsu Province, China

ORCID number: Qian Zhong (0000-0002-9713-7649); Qi Sun (0000-0001-8276-0027); Gui-Fang Xu (0000-0001-9949-3658); Xiu-Qin Fan (0000-0002-5306-6885); Yuan-Yuan Xu (0000-0002-8272-6504); Fei Liu (0000-0003-3949-5832); Shi-Yi Song (0000-0003-3053-820X); Chun-Yan Peng (0000-0002-0589-0159); Lei Wang (0000-0003-0178-5930)

**Author contributions:** Zhong Q and Sun Q contributed equally to this work; Zhong Q and Wang L designed the research; Zhong Q and Sun Q contributed to the analysis and interpretation of the data; Xu GF, Fan XQ, Xu YY, Liu F, Song SY and Peng CY contributed to the acquisition of the data; Zhong Q, Wang L and Sun Q wrote the paper; all authors have read and approved the final version of the manuscript for publication.

**Supported by** Medical Science and Technology Development Foundation of Nanjing Department of Health, No. 201402032.

**Institutional review board statement:** The study was reviewed and approved by the Ethics Committee of The Affiliated Drum Tower Hospital of Nanjing University Medical School.

**Informed consent statement:** Patients were not required to give informed consent to the study because the analysis used anonymized clinical data that were obtained after each patient agreed by written consent to undergo curative gastrectomy with lymph node dissection.

**Conflict-of-interest statement:** The authors have no conflicts of interest to disclose.

**Data sharing statement:** No additional data are available.

**Open-Access:** This article is an open-access article which was selected by an in-house editor and fully peer-reviewed by external reviewers. It is distributed in accordance with the Creative Commons Attribution Non Commercial (CC BY-NC 4.0) license, which permits others to distribute, remix, adapt, build upon this work non-commercially, and license their derivative works on different terms, provided the original work is properly cited and the use is non-commercial. See: <http://creativecommons.org/licenses/by-nc/4.0/>

**Manuscript source:** Unsolicited manuscript

**Correspondence to:** Lei Wang, MD, Department of Gastroenterology, the Affiliated Drum Tower Hospital of Nanjing University Medical School, No. 321, Zhongshan Road, Gulou District, Nanjing 210008, Jiangsu Province, China. 867152094@qq.com  
Telephone: +86-25-83304616  
Fax: +86-25-83304616

**Received:** October 5, 2017

**Peer-review started:** October 6, 2017

**First decision:** October 31, 2017

**Revised:** November 11, 2017

**Accepted:** November 27, 2017

**Article in press:** November 27, 2017

**Published online:** January 7, 2018

## Abstract

### AIM

To investigate the relationship between histological mixed-type of early gastric cancer (EGC) in the mucosa and submucosa and lymph node metastasis (LNM).

### METHODS

This study included 298 patients who underwent gastrectomy for EGC between 2005 and 2012. Enrolled lesions were divided into groups of pure differentiated (pure D), pure undifferentiated (pure U), and mixed-



type according to the proportion of the differentiated and undifferentiated components observed under a microscope. We reviewed the clinicopathological features, including age, sex, location, size, gross type, lymphovascular invasion, ulceration, and LNM, among the three groups. Furthermore, we evaluated the predictors of LNM in the mucosa-confined EGC.

## RESULTS

Of the 298 patients, 165 (55.4%) had mucosa-confined EGC and 133 (44.6%) had submucosa-invasive EGC. Only 13 (7.9%) cases of mucosa-confined EGC and 30 (22.6%) cases of submucosa-invasive EGC were observed to have LNM. The submucosal invasion (OR = 4.58, 95%CI: 1.23-16.97,  $P = 0.023$ ), pure U type (OR = 4.97, 95%CI: 1.21-20.39,  $P = 0.026$ ), and mixed-type (OR = 5.84, 95%CI: 1.05-32.61,  $P = 0.044$ ) were independent risk factors for LNM in EGC. The rate of LNM in mucosa-confined EGC was higher in the mixed-type group ( $P = 0.012$ ) and pure U group ( $P = 0.010$ ) than in the pure D group, but no significant difference was found between the mixed-type group and pure U group ( $P = 0.739$ ). Similarly, the rate of LNM in the submucosa-invasive EGC was higher in the mixed-type ( $P = 0.012$ ) and pure U group ( $P = 0.009$ ) than in the pure D group but was not significantly different between the mixed-type and pure U group ( $P = 0.375$ ). Multivariate logistic analysis showed that only female sex (OR = 5.83, 95%CI: 1.64-20.70,  $P = 0.028$ ) and presence of lymphovascular invasion (OR = 13.18, 95%CI: 1.39-125.30,  $P = 0.020$ ) were independent risk factors for LNM in mucosa-confined EGC, while histological type was not an independent risk factor for LNM in mucosa-confined EGC ( $P = 0.106$ ).

## CONCLUSION

For mucosal EGC, histological mixed-type is not an independent risk factor for LNM and could be managed in the same way as the undifferentiated type.

**Key words:** Early gastric carcinoma; Mixed-type; Lymph node metastasis; Mucosa; Lymphovascular invasion

© The Author(s) 2018. Published by Baishideng Publishing Group Inc. All rights reserved.

**Core tip:** This retrospective study investigated the relationship between the histological mixed-type of early gastric carcinoma (EGC) in the mucosa and submucosa and lymph node metastasis (LNM). We found that the rates of LNM in the histological mixed-type and the pure undifferentiated type were not significantly different in the mucosal or submucosal EGC. Furthermore, histological type was not an independent risk factor for LNM in mucosa-confined EGC. Hence, according to WHO classification, histological mixed-type and pure undifferentiated EGC could be managed in the same way, and curative endoscopic submucosal dissection is feasible for patients with histological mixed-type mucosa-confined EGC.

Zhong Q, Sun Q, Xu GF, Fan XQ, Xu YY, Liu F, Song SY, Peng CY, Wang L. Differential analysis of lymph node metastasis in histological mixed-type early gastric carcinoma in the mucosa and submucosa. *World J Gastroenterol* 2018; 24(1): 87-95 Available from: URL: <http://www.wjgnet.com/1007-9327/full/v24/i1/87.htm> DOI: <http://dx.doi.org/10.3748/wjg.v24.i1.87>

## INTRODUCTION

Gastric carcinoma is the second leading cause of cancer-related death behind lung carcinoma, despite a worldwide decline in both its incidence and mortality since the late half of the twentieth century<sup>[1]</sup>. Endoscopic resection can be curative for selected cases of early gastric cancer (EGC)<sup>[2]</sup>. Endoscopic submucosal dissection (ESD), a recently developed technique, is a widely accepted treatment modality for EGC, including undifferentiated-type EGC within the expanded criteria (mucosal cancer measuring less than 2 cm without ulceration or lymphovascular tumor emboli). Some studies have shown that there is no risk of lymph node metastasis (LNM) in undifferentiated-type EGC, conforming to the expanded criteria for endoscopic resection<sup>[3-5]</sup>. The incidence of LNM is the most important factor when deciding on endoscopic resection in EGC<sup>[6]</sup>. Therefore, the criteria for ESD consist of factors related to the risk of LNM, including histological differentiation and tumor size.

The prognosis of EGC is mainly dependent on histological differentiation, which determines the extent of LNM and can potentially assist in selecting the most suitable treatment strategy<sup>[7-9]</sup>. However, gastric cancer tissues often present histological heterogeneity and comprise a mixture of several different cell types. Before a treatment has been selected, it is difficult for pathologists to accurately diagnose the histological type of the cancer tissue based on the histological differentiation state definitions as defined by the 14<sup>th</sup> Japanese classification of gastric carcinoma<sup>[10]</sup> or the 7<sup>th</sup> tumor-node-metastasis classification<sup>[11]</sup>. This is especially the case in mixed-type gastric cancer from several biopsy specimens. Approximately 5%-25% of gastric cancers are classified as having a histological mixed-type in previous studies<sup>[12,13]</sup>, consisting of undifferentiated and differentiated components.

Recently, several studies have reported that mixed-type EGC was associated with aggressive clinical features as well as poor outcomes<sup>[12,14]</sup>. However, these studies did not consider the different biological behaviors of the mucosal mixed-type EGC and submucosal mixed-type EGC, although patients with submucosal EGC would undoubtedly be at a higher risk of LNM and poor prognosis than those with mucosal EGC. Therefore, the biological behavior of the histological mixed-type in mucosal EGC remains undetermined. In this study, we aimed to clarify the relationship of histological mixed-type EGC and the rate of LNM, and the feasibility of

endoscopic resection for patients with mixed-type EGC in the mucosa.

## MATERIALS AND METHODS

### Patients

A consecutive series of 298 patients diagnosed with EGC were examined. All patients, including 165 patients with EGC in the mucosa and 133 patients with EGC in the submucosa, underwent curative gastrectomy with lymph node dissection at the Department of Surgery at Nanjing Drum Tower Hospital from January 2005 to January 2012. Patients who were treated with chemotherapy before surgery were excluded from this study. Histopathological examination was performed by expert pathologists. Data on the clinicopathological factors, including age, sex, tumor location, macroscopic appearance, size, presence of stomach ulcer, infection with *Helicobacter pylori* (*H. pylori*), lymphovascular invasion, and presence of LNM, were obtained. After surgery, patients were told to visit our outpatient department for esophagogastroduodenoscopy and abdominal pelvic computed tomography, which were performed at 3- and 6-mo intervals during the first year and then annually thereafter. This study was approved by the Institutional Review Board of Nanjing Drum Tower Hospital.

### Subgroups based on the histological differentiation state

Patients were divided into three subgroups according to the histological features of their tumors: (1) a pure differentiated component with no undifferentiated component (pure D group); (2) a pure undifferentiated component with no differentiated component (pure U group); and (3) a histological mixed-type that consisted of both differentiated and undifferentiated components (mixed-type group). The histological mixed-type includes the differentiated-predominant mixed-type with undifferentiated component making up less 50% (D > U group) and the undifferentiated-predominant mixed-type with undifferentiated component making up more than 50% (U > D group). According to the Japanese classification of gastric carcinoma, the pure D and D > U groups were classified as the differentiated type of gastric cancer, whereas the U > D and pure U groups were classified as the undifferentiated type. On the other hand, according to the tumor-node-metastasis classification, only the pure D group was classified as the differentiated type, and the remaining three groups were classified as the undifferentiated type. The Japanese classification of gastric carcinoma<sup>[6]</sup> was used to classify the macroscopic type of the tumors as follows: elevated (I, IIa, I and IIa, IIa and IIb), flat (IIb), and depressed (IIc, IIc and III, III). According to the different histological classifications, the cases of EGC in the mucosa and submucosa are shown in Figure 1.

### Statistical analysis

Analysis of variance was used to compare the mean values of the continuous variables among the three different histological subgroups, and the  $\chi^2$  test was performed on the categorical variables. Bonferroni correction for multiple comparisons suggested differences between two of the three histological subgroups. Multivariate logistic regression analysis was performed to determine the predictors of LNM. The significant difference was set at an alpha level of 0.05. When the Bonferroni correction was applied, the significant difference was set at an alpha level of 0.017, which was 0.05/number of tests<sup>[15]</sup>. All statistical analyses were performed using SPSS software, version 22.0 (SPSS Inc., Chicago, IL, United States).

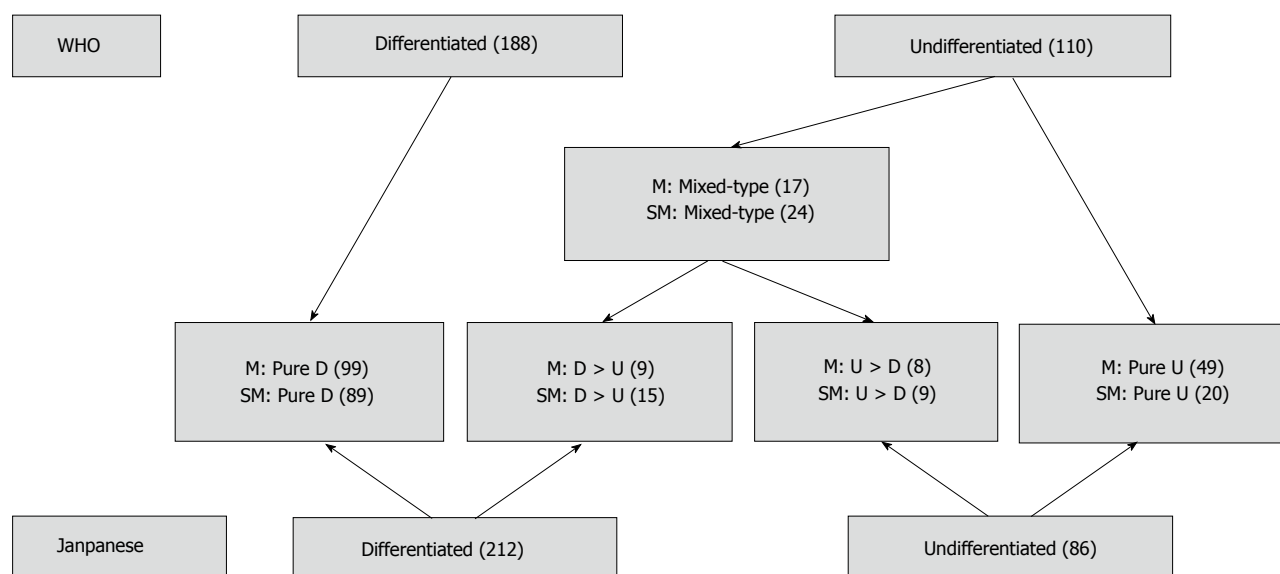
## RESULTS

### Clinicopathological characteristics of patients with EGC

The study group consisted of 206 male patients and 92 female patients with a median age of 59.5 years (range, 18-86 years). Seventy-one patients had tumors in the upper third of the stomach and 227 in the middle or lower third. One hundred and six patients had an elevated gross type and 192 patients had a flat or depressed gross type. There were 165 patients with EGC in the mucosa and 133 patients with EGC in the submucosa. Histologically, patients were divided into the following four groups: 188 (63.1%) patients with the pure D histological type, 24 (7.0%) with the D > U histological type, 17 (5.7%) with the U > D histological type, and 69 (23.2%) with the pure U histological type. The overall prevalence of the histological mixed-type, including the D > U and U > D histological types, was 12.7% (41/298) in EGC. The overall incidence of LNM was 14.4% in EGC (Table 1). In a univariate analysis of EGC, LNM was associated with younger age ( $P = 0.005$ ), female sex ( $P = 0.044$ ), tumor size ( $P = 0.022$ ), middle/lower location ( $P = 0.010$ ), lymphovascular invasion ( $P = 0.013$ ), flat/depressed gross type ( $P = 0.034$ ), depth of submucosal invasion ( $P = 0.001$ ), pure U type ( $P = 0.005$ ), and mixed-type ( $P = 0.001$ ). Given that the criteria for ESD treatment of EGC consist of the invasion depth, histological type, tumor size, and ulceration, it is reasonable and meaningful to take these four covariates into a multivariate analysis to assess their main effect on the rate of LNM. The multivariate analysis showed that submucosal invasion (OR = 4.58, 95%CI: 1.23-16.97,  $P = 0.023$ ), pure U type (OR = 4.97, 95%CI: 1.21-20.39,  $P = 0.026$ ), and mixed-type (OR = 5.84, 95%CI: 1.05-32.61,  $P = 0.044$ ) were independent risk factors for LNM in EGC. There was no interaction effect between the invasion depth and histological type ( $P = 0.822$ ) (Table 2).

### Clinicopathologic features among the histological mixed-type, pure undifferentiated, and pure differentiated EGC in the mucosa and submucosa

Table 3 shows the relationship between the clinico-



**Figure 1** The relationship among the histological classifications of early gastric cancer in the mucosa and submucosa. Of the 298 cases, there were 212 with differentiated type gastric cancer and 86 with undifferentiated type gastric cancer based on the Japanese classification currently used as the endoscopic resection criteria. In accordance with the WHO classification, there were 188 patients with differentiated type and 110 patients with undifferentiated type gastric cancer. According to the histological differentiation and undifferentiation components, 41 patients were reclassified as mixed-type. For mucosal early gastric cancer (EGC), there were 99 patients in the pure differentiated (pure D) group, 9 in the differentiated > undifferentiated (D > U) group, 8 in the undifferentiated > differentiated (U > D) group, and 49 in the pure undifferentiated (pure U) group. For submucosal EGC, there were 89 in the pure D group, 15 in the D > U group, 9 in the U > D group, and 20 in the pure U group. Among the 41 patients with mixed-type EGC, there were 17 in the mucosa and 24 in the submucosa. D: Differentiated; M: Mucosa; SM: Submucosa; U: Undifferentiated.

**Table 1** Clinicopathological characteristics of patients with early gastric cancer *n* (%)

Variable	Value
Age (yr), median ± SD (range)	59.5 ± 12.1 (18-86)
Gender	
Male	206 (69.1)
Female	92 (30.9)
Tumor size (cm), median ± SD (range)	2.2 ± 1.2 (0.5-6.0)
Location	
U	71 (23.8)
M/L	227 (76.2)
Gross type	
Elevated	106 (35.6)
Flat/depressed	192 (64.4)
Depth of invasion	
M	165 (55.4)
SM	133 (44.6)
Histological type	
Pure D	188 (63.1)
D > U	24 (7.0)
U > D	17 (5.7)
Pure U	69 (23.2)
Lymph node metastasis	
Present	43 (14.4)
Absent	255 (85.6)

SD: Standard deviation; U: Upper; M/L: Middle/lower; M: Mucosa; SM: Submucosa; Pure D: Pure differentiated; D: Differentiated components; U: Undifferentiated components; Pure U: Pure undifferentiated.

pathological factors and histological types, which included the mixed-type, pure undifferentiated type, and pure differentiated type, in mucosal EGC. The distribution of age ( $P = 0.028$ ), gender ( $P = 0.004$ ),

tumor location ( $P = 0.003$ ), gross type ( $P < 0.001$ ), ulceration ( $P = 0.015$ ), *H. pylori* ( $P = 0.025$ ), and LNM ( $P = 0.016$ ) significantly differed among the three histological subgroups, while tumor size ( $P = 0.802$ ) and lymphovascular invasion ( $P = 0.589$ ) were similarly distributed among the three histological subgroups. Patients in the mixed-type group were more likely to have *H. pylori* infection than those in the pure U group ( $P = 0.015$ ). Besides tumor size and lymphovascular invasion, age ( $P = 0.525$ ), gender ( $P = 0.151$ ), tumor location ( $P = 0.759$ ), gross type ( $P = 0.507$ ), and ulceration ( $P = 0.490$ ) were similarly distributed between the mixed-type group and pure U group. Of note, the rate of LNM was similar between the mixed-type group and the pure U group ( $P = 0.739$ ), although it was significantly higher in the mixed-type group ( $P = 0.012$ ) and pure U group ( $P = 0.010$ ) than in the pure D group. These data suggested that mixed-type group showed similar clinicopathologic features and aggressive behavior compared with the pure U group in mucosal EGC.

Table 4 shows the relationship between the clinicopathological factors and histological types, which included the mixed type, pure undifferentiated type, and pure differentiated type in submucosal EGC. Distribution of age ( $P = 0.008$ ), gender ( $P < 0.001$ ), tumor location ( $P = 0.019$ ), gross type ( $P = 0.028$ ), and LNM ( $P = 0.008$ ) significantly differed among the three histological subgroups, while tumor size ( $P = 0.166$ ), ulceration ( $P = 0.369$ ), *H. pylori* infection ( $P = 0.997$ ), and lymphovascular invasion ( $P = 0.325$ )



**Table 2 Risk factors for lymph node metastasis in early gastric carcinoma**

Variable	Univariate analysis			Multivariate analysis		
	OR	95%CI	P value	OR	95%CI	P value
Age (yr)			0.005			
≤ 60	1.00					
> 60	0.37	0.18-0.74				
Gender			0.044			
Male	1.00					
Female	1.97	1.02-3.82				
Size (cm)	1.33	1.04-1.71	0.022			0.154
Location			0.010			
U	1.00					
M/L	4.85	1.45-16.19				
LV invasion			< 0.001			
Absent	1.00					
Present	18.4	8.31-40.72				
Gross type			0.034			
Elevated	1.00					
Flat/depressed	2.32	1.07-5.04				
Ulcer			0.031			0.256
Absent	1.00					
Present	2.15	1.07-4.31				
<i>H. pylori</i> infection			0.346			
Absent	1.00					
Present	1.46	0.67-3.19				
Depth of invasion			0.001			0.023
Mucosa	1.00			4.58	1.23-16.97	
Submucosa	3.41	1.70-6.83				
Histological type			0.001			0.054
Pure D	1.00					
Pure U	2.99	1.39-6.44	0.005	4.97	1.21-20.39	0.026
Mixed-type	4.45	1.91-10.36	0.001	5.84	1.05-32.61	0.044
Depth of invasion/histological type						0.822

MT: Mixed-type; PU: Pure undifferentiated; PD: Pure differentiated; U: Upper; M/L: Middle/lower; LV: Lymphovascular; LNM: Lymph node metastasis.

**Table 3 Clinicopathologic features of mucosa-confined early gastric carcinoma according to histological type *n* (%)**

Variable	MT, <i>n</i> = 17	Pure U, <i>n</i> = 49	Pure D, <i>n</i> = 99	P value	P (Bonferroni corrected)
Age (yr)				0.028	MT vs PU, 0.525
≤ 60	10 (58.8)	33 (67.3)	44 (44.4)		MT vs PD, 0.272
> 60	7 (41.2)	16 (32.7)	55 (55.6)		PU vs PD, 0.009
Gender				0.004	MT vs PU, 0.151
Male	7 (41.2)	30 (61.2)	77 (77.8)		MT vs PD, 0.002
Female	10 (58.8)	19 (38.8)	22 (22.2)		PU vs PD, 0.034
Tumor size (cm)	2.1 ± 1.1	1.9 ± 1.2	1.9 ± 1.2	0.802	
Location				0.003	MT vs PU, 0.759
U	1 (5.9)	4 (8.2)	29 (29.3)		MT vs PD, 0.042
M/L	16 (94.1)	45 (91.8)	70 (70.7)		PU vs PD, 0.004
Gross type				< 0.001	MT vs PU, 0.507
Elevated	4 (23.5)	8 (16.3)	51 (51.5)		MT vs PD, 0.033
Flat/depressed	13 (76.5)	41 (83.7)	48 (48.5)		PU vs PD, < 0.001
Ulcer				0.015	MT vs PU, 0.490
Absent	6 (35.3)	22 (44.9)	64 (64.6)		MT vs PD, 0.022
Present	11 (64.7)	27 (55.1)	35 (35.4)		PU vs PD, 0.022
<i>H. pylori</i> infection				0.025	MT vs PU, 0.015
Absent	1 (5.9)	18 (36.7)	22 (22.2)		MT vs PD, 0.119
Present	16 (94.1)	31 (63.3)	77 (77.8)		PU vs PD, 0.061
LV invasion				0.589	
Absent	17 (100.0)	47 (95.9)	97 (98.0)		
Present	0 (0)	2 (4.1)	2 (2.0)		
LNM				0.016	MT vs PU, 0.739
Absent	14 (82.4)	42 (85.7)	96 (97.0)		MT vs PD, 0.012
Present	3 (17.6)	7 (14.3)	3 (3.0)		PU vs PD, 0.010

MT: Mixed-type; PU: Pure undifferentiated; PD: Pure differentiated; U: Upper; M/L: Middle/lower; LV: Lymphovascular; LNM: Lymph node metastasis.

**Table 4** Clinicopathologic features of submucosa-invasive early gastric carcinoma according to histological type *n* (%)

Variable	MT, <i>n</i> = 24	Pure U, <i>n</i> = 20	Pure D, <i>n</i> = 89	<i>P</i> value	<i>P</i> (Bonferroni corrected)
Age (yr)				0.008	MT vs PU, 0.423
≤ 60	14 (58.3)	14 (70.0)	32 (36.0)		MT vs PD, 0.048
> 60	10 (41.7)	6 (30.0)	57 (64.0)		PU vs PD, 0.005
Gender				< 0.001	MT vs PU, 0.069
Male	15 (62.5)	7 (35.0)	70 (78.7)		MT vs PD, 0.104
Female	9 (37.5)	13 (65.0)	19 (21.3)		PU vs PD, < 0.001
Size (cm)	2.6 ± 1.3	2.8 ± 1.4	2.3 ± 1.1	0.166	
Location				0.019	MT vs PU, 0.128
U	5 (20.8)	1 (5.0)	31 (34.8)		MT vs PD, 0.191
M/L	19 (79.2)	19 (95.0)	58 (65.2)		PU vs PD, 0.008
Gross type				0.028	MT vs PU, 0.199
Elevated	6 (25.0)	2 (10.0)	35 (39.3)		MT vs PD, 0.195
Flat/depressed	18 (75.0)	18 (90.0)	54 (60.7)		PU vs PD, 0.012
Ulcer				0.369	
Absent	5 (20.8)	7 (35.0)	32 (36.0)		
Present	19 (79.2)	13 (65.0)	57 (64.0)		
<i>H. pylori</i> infection				0.997	
Absent	7 (29.2)	6 (30.0)	26 (29.2)		
Present	17 (70.8)	14 (70.0)	63 (70.8)		
LV invasion				0.325	
Absent	15 (62.5)	15 (75.0)	69 (77.5)		
Present	9 (37.5)	5 (25.0)	20 (22.5)		
LNM				0.008	MT vs PU, 0.375
Absent	15 (62.5)	12 (60.0)	76 (85.4)		MT vs PD, 0.012
Present	9 (37.5)	8 (40.0)	13 (14.6)		PU vs PD, 0.009

MT: Mixed-type; PU: Pure undifferentiated; PD: Pure differentiated; U: Upper; M/L: Middle/lower; LV: Lymphovascular; LNM: Lymph node metastasis.

were similarly distributed among the three histological subgroups. Besides tumor size, ulceration, *H. pylori* infection, and lymphovascular invasion, age ( $P = 0.423$ ), gender ( $P = 0.069$ ), tumor location ( $P = 0.128$ ), and gross type ( $P = 0.199$ ) were similarly distributed between the mixed-type group and pure U group. The rate of LNM was higher in the mixed-type group ( $P = 0.012$ ) and pure U group ( $P = 0.009$ ) than in the pure D group, but was not significantly different between the mixed-type and pure U group ( $P = 0.375$ ). These data suggested that the mixed-type group showed similar clinicopathologic features and aggressive behavior compared with the pure U group in submucosal EGC.

#### Risk factors for LNM in EGC in the mucosa

In a univariate analysis of mucosa-confined EGC, LNM was associated with pure undifferentiated type ( $P = 0.019$ ), mixed-type ( $P = 0.026$ ), female sex ( $P = 0.005$ ), and presence of lymphovascular invasion ( $P = 0.013$ ). However, in a multivariate analysis, only female sex (OR = 5.83, 95%CI: 1.64-20.70,  $P = 0.028$ ) and presence of lymphovascular invasion (OR = 13.18, 95%CI: 1.39-125.30,  $P = 0.020$ ) were independent risk factors for LNM of mucosa-confined EGC, while histological type was not an independent risk factor for LNM of mucosa-confined EGC ( $P = 0.106$ ) (Table 5).

## DISCUSSION

Endoscopic resection is a curative modality for EGC and its indications have been expanded<sup>[16,17]</sup>. However,

histological mixed-type is not categorized in the present criteria for ESD. In this study, we found that submucosal invasion, pure U type, and mixed-type were independent risk factors for LNM in EGC. However, the distribution of tumor size, location, gross type, ulceration, lymphovascular invasion, and LNM rate were similar between the mixed-type group and pure U group in mucosa-confined EGC, and histological mixed-type was not an independent risk factor for LNM in mucosal EGC.

EGC generally shows greater histological diversity than other types of cancer. Even tumors confined to the mucosa show histologic diversity, which tends to increase with deeper invasion and increased tumor diameter<sup>[18]</sup>. In addition, histological mixed-type has been reported to have a higher LNM rate and more aggressive behavior than other histological types<sup>[19]</sup>. New difficulties in determining the appropriate management for histological mixed-type EGC arose as a result of improvements in ESD, which allows *en bloc* resection of large superficial gastric lesions and precise histopathological evaluation<sup>[20]</sup>. In fact, there are two distinct groups of differentiated and undifferentiated mixed-type EGC. The first group shows both differentiated and undifferentiated histological components in the mucosa. The second group shows differentiated components confined in the mucosa and undifferentiated components confined in the submucosa. We hypothesized that these two groups had different prognoses and should be evaluated and managed independently. In our study, we found

**Table 5 Risk factors for lymph node metastasis in mucosa-confined early gastric carcinoma**

Variable	Univariate analysis			Multivariate analysis		
	OR	95%CI	P value	OR	95%CI	P value
Age (yr)			0.082			
≤ 60	1.00					
> 60	0.31	0.08-1.16				
Size (cm)	1.36	0.90-2.06	0.145			
Gender			0.005			0.028
Male	1.00			1.00		
Female	5.89	1.72-20.17		5.83	1.64-20.70	
Location			0.630			
U	1.00					
M/L	1.47	0.31-6.95				
LV invasion			0.013			0.020
Absent	1.00			1.00		
Present	13.64	1.75-106.28		13.18	1.39-125.30	
Gross type			0.253			
Elevated	1.00					
Flat/depressed	2.17	0.58-8.22				
Ulcer			0.199			
Absent	1.00					
Present	2.14	0.67-6.85				
<i>H. pylori</i> infection			0.244			
Absent	1.00					
Present	0.50	0.15-1.61				
Histological type			0.035			0.106
Pure D	1.00					
Pure U	5.33	1.32-21.63	0.019	4.46	0.99-20.00	0.051
Mixed-type	6.86	1.26-37.77	0.026	5.31	0.86-33.01	0.073

PD: Pure differentiated; PU: Pure undifferentiated; U: Upper; M/L: Middle/lower; LV: Lymphovascular.

that submucosal invasion, pure U type, and mixed-type were independent risk factors for LNM in EGC. We next analyzed the clinicopathologic features of mucosal and submucosal EGC according to the histological type. The mixed-type group and pure U group showed similar clinicopathologic features and aggressive behavior in mucosal EGC, including the distribution of age, gender, tumor size, location, gross type, ulceration, lymphovascular invasion, and LNM rate. Furthermore, we validated that histological type was not an independent risk factor for LNM in mucosal EGC. Given the mucosal undifferentiated EGC has been included in the expanded criteria for ESD, we recommended that mucosal mixed-type EGC could be treated with ESD. For submucosal EGC, the mixed-type group also showed similar clinicopathologic features and aggressive behavior compared with the pure U group. Submucosal undifferentiated EGC has not been included in the criteria for ESD, due to the high frequency of LNM. Several studies have shown that mixed-type EGC with submucosal invasion carries a high risk of LNM, and endoscopic surgery should be limited to the differentiated type of invasive submucosal EGC without histological heterogeneity<sup>[20,21]</sup>. Our data supported that the LNM rate of submucosal EGC was significantly higher in the mixed-type group (9/24) and pure U group (8/20) than in the pure D group (13/89). In accordance with the 7<sup>th</sup> tumor-node-metastasis classification, the mixed-type group and pure U group, including undifferentiated components, were all

undifferentiated EGC<sup>[22]</sup>. Hence, the decision criterion of histological mixed-type in tumor-node-metastasis classification is better than Japanese classification<sup>[23]</sup>.

A study from Shimizu *et al.*<sup>[23]</sup> showed that there was no significant difference in the clinicopathological factors between the D > U and U > D groups<sup>[23]</sup>. This means that the mixture of differentiated and undifferentiated components contributes to a worse prognosis, no matter the ratio of undifferentiated components to differentiated components. Actually, the pathogenesis and aggressiveness of mixed histology are unclear. Zheng *et al.*<sup>[24]</sup> suggested that the mixed-type components might originate from stem cells with similar genetic traits, but follow different histogenic pathways. Park *et al.*<sup>[25]</sup> found that mixed-type gastric carcinoma frequently showed an enhanced CpG island hypermethylation status, implicating enhanced CpG island promoter hypermethylation in the histogenesis of mixed-type carcinoma. Studies of the mucin phenotype have reported that some cases of differentiated gastric cancer with a gastric phenotype are transformed into undifferentiated gastric cancer during tumor growth and development, increasing the risk of LNM<sup>[26]</sup>. Although mixed-type carcinomas are thought to be more aggressive in some studies according to the Lauren classification<sup>[24,27]</sup>, a recent study reported that mixed histology, according to WHO classification, showed no LNM within the criteria for endoscopic resection<sup>[13]</sup>. Our data supported that the rate of LNM was not significantly different in the mixed-type and

pure undifferentiated EGC confined in the mucosa. Limited by the small sample sizes, our data showed considerably wide confidence interval of the OR ratio of lymphovascular invasion, in the univariate and multivariate analyses of mucosal EGC. Although similar data were reported in some studies<sup>[28,29]</sup>, it should be confirmed by additional clinical research with larger sample sizes.

In conclusion, our results demonstrated that the histological mixed-type showed a similar low rate of LNM compared with the pure undifferentiated type in mucosa-confined EGC, and histological type was not an independent risk factor for LNM in mucosa-confined EGC. According to the tumor-node-metastasis classification, mucosal histological mixed-type and undifferentiated EGC could be managed in the same way, and curative ESD is feasible for patients with histological mixed-type EGC confined in the mucosa.

## ARTICLE HIGHLIGHTS

### Research background

Endoscopic submucosal dissection (ESD) is a curative modality for mucosal-confined early gastric cancer (EGC) and its indications have been expanded. However, EGC tissues often present histological heterogeneity and comprise a mixture of several different cell types. The present criteria for ESD does not take consideration of the histological mixed-type EGC. The rate of lymph node metastasis (LNM) is the most important factor when deciding on endoscopic resection in EGC. Therefore, there is a current pressing need to clarify the relationship of histological mixed-type and the rate of LNM, and the feasibility of endoscopic resection for patients with histological mixed-type EGC confined in the mucosa.

### Research motivation

According to the latest research, histological mixed-type EGC was associated with aggressive clinical features as well as poor outcomes, but these studies did not consider the different biological behaviors of the mucosal mixed-type EGC and submucosal mixed-type EGC. Given the mucosal undifferentiated EGC measuring less than 2 cm without ulceration has been included in the expanded criteria for ESD treatment, it is necessary to assess the feasibility of endoscopic resection for patients with histological mixed-type EGC confined in the mucosa.

### Research objectives

In this study, we investigated the clinicopathologic features of EGC according to histological type classification to evaluate the biological behavior of mixed-type EGC and the predictive value of histological type on the rate of LNM in mucosa-confined EGC.

### Research methods

This study included 298 patients who underwent gastrectomy for EGC between 2005 and 2012. Enrolled lesions were divided into groups of pure differentiated (pure D), pure undifferentiated (pure U), and mixed-type according to the proportion of the differentiated and undifferentiated components observed under a microscope. We reviewed the clinicopathological features, including age, sex, location, size, gross type, lymphovascular invasion, ulceration, and LNM, among the three groups. Furthermore, we evaluated the risk factors for LNM in mucosal EGC.

### Research results

Submucosal invasion, pure U type, and mixed-type were independent risk factors for LNM in EGC. The rate of LNM in mucosa-confined EGC was higher in the mixed-type group and pure U group than in the pure D group, but no significant difference was found between the mixed-type group and pure U group. Similarly, the rate of LNM in the submucosa-invasive EGC was higher

in the mixed-type and pure U group than in the pure D group, but was not significantly different between the mixed-type and pure U group. Multivariate logistic analysis showed that histological type was not an independent risk factor for LNM in mucosa-confined EGC.

### Research conclusions

The distribution of tumor size, location, gross type, ulceration, lymphovascular invasion, and LNM rate were similar between the mixed-type group and pure undifferentiated group in mucosa-confined EGC, and the histological mixed-type was not an independent predictor of LNM in mucosa-confined EGC. According to the tumor-node-metastasis classification, the histological mixed-type and undifferentiated EGC could be managed in the same way, and curative ESD was feasible for patients with mucosal histological mixed-type EGC.

### Research perspectives

Endoscopic resection is a curative modality for EGC and its indications have been expanded. Our study indicated that the mucosal histological mixed-type EGC could be managed with curative ESD. With the gradual understanding of the pathogenesis and biological behavior of mixed-type EGC, more patients with mixed-type EGC would benefit from the ESD treatment.

## REFERENCES

- 1 Kelley JR, Duggan JM. Gastric cancer epidemiology and risk factors. *J Clin Epidemiol* 2003; **56**: 1-9 [PMID: 12589864 DOI: 10.1016/S0895-4356(02)00534-6]
- 2 Goto O, Fujishiro M, Kodashima S, Ono S, Omata M. Outcomes of endoscopic submucosal dissection for early gastric cancer with special reference to validation for curability criteria. *Endoscopy* 2009; **41**: 118-122 [PMID: 19214889 DOI: 10.1055/s-0028-1119452]
- 3 Shim CN, Lee SK. Endoscopic submucosal dissection for undifferentiated-type early gastric cancer: do we have enough data to support this? *World J Gastroenterol* 2014; **20**: 3938-3949 [PMID: 24744583 DOI: 10.3748/wjg.v20.i14.3938]
- 4 Gotoda T, Yamamoto H, Soetikno RM. Endoscopic submucosal dissection of early gastric cancer. *J Gastroenterol* 2006; **41**: 929-942 [PMID: 17096062 DOI: 10.1007/s00535-006-1954-3]
- 5 Lee S, Choi KD, Han M, Na HK, Ahn JY, Jung KW, Lee JH, Kim DH, Song HJ, Lee GH, Yook JH, Kim BS, Jung HY. Long-term outcomes of endoscopic submucosal dissection versus surgery in early gastric cancer meeting expanded indication including undifferentiated-type tumors: a criteria-based analysis. *Gastric Cancer* 2017; Epub ahead of print [PMID: 29052052 DOI: 10.1007/s10120-017-0772-z]
- 6 Hirasawa T, Gotoda T, Miyata S, Kato Y, Shimoda T, Taniguchi H, Fujisaki J, Sano T, Yamaguchi T. Incidence of lymph node metastasis and the feasibility of endoscopic resection for undifferentiated-type early gastric cancer. *Gastric Cancer* 2009; **12**: 148-152 [PMID: 19890694 DOI: 10.1007/s10120-009-0515-x]
- 7 Komatsu S, Ichikawa D, Miyamae M, Shimizu H, Konishi H, Shiozaki A, Fujiwara H, Okamoto K, Kishimoto M, Otsuji E. Histological mixed-type as an independent prognostic factor in stage I gastric carcinoma. *World J Gastroenterol* 2015; **21**: 549-555 [PMID: 25593472 DOI: 10.3748/wjg.v21.i2.541]
- 8 Pyo JH, Lee H, Min BH, Lee JH, Choi MG, Lee JH, Sohn TS, Bae JM, Kim KM, Ahn JH, Carriere KC, Kim JJ, Kim S. Long-Term Outcome of Endoscopic Resection vs. Surgery for Early Gastric Cancer: A Non-inferiority-Matched Cohort Study. *Am J Gastroenterol* 2016; **111**: 240-249 [PMID: 26782817 DOI: 10.1038/ajg.2015.427]
- 9 Zheng H, Takahashi H, Murai Y, Cui Z, Nomoto K, Miwa S, Tsuneyama K, Takano Y. Pathobiological characteristics of intestinal and diffuse-type gastric carcinoma in Japan: an immunostaining study on the tissue microarray. *J Clin Pathol* 2007; **60**: 273-277 [PMID: 16714395 DOI: 10.1136/jcp.2006.038778]
- 10 Japanese Gastric Cancer Association. Japanese classification of gastric carcinoma: 3rd English edition. *Gastric Cancer* 2011; **14**: 101-112 [PMID: 21573743 DOI: 10.1007/s10120-011-0041-5]



- 11 **Rice TW**, Blackstone EH, Rusch VW. 7th edition of the AJCC Cancer Staging Manual: esophagus and esophagogastric junction. *Ann Surg Oncol* 2010; **17**: 1721-1724 [PMID: 20369299 DOI: 10.1245/s10434-010-1024-1]
- 12 **Miyamae M**, Komatsu S, Ichikawa D, Kosuga T, Kubota T, Okamoto K, Konishi H, Shiozaki A, Fujiwara H, Kishimoto M, Otsuji E. Histological mixed-type as an independent risk factor for nodal metastasis in submucosal gastric cancer. *Tumour Biol* 2016; **37**: 709-714 [PMID: 26242270 DOI: 10.1007/s13277-015-3864-6]
- 13 **Yoon HJ**, Kim YH, Kim JH, Kim H, Kim H, Park JJ, Youn YH, Park H, Kim JW, Hyung WJ, Noh SH, Choi SH. Are new criteria for mixed histology necessary for endoscopic resection in early gastric cancer? *Pathol Res Pract* 2016; **212**: 410-414 [PMID: 26907784 DOI: 10.1016/j.prp.2016.02.013]
- 14 **Hwang CS**, Ahn S, Lee BE, Lee SJ, Kim A, Choi CI, Kim DH, Jeon TY, Kim GH, Song GA, Park DY. Risk of lymph node metastasis in mixed-type early gastric cancer determined by the extent of the poorly differentiated component. *World J Gastroenterol* 2016; **22**: 4020-4026 [PMID: 27099445 DOI: 10.3748/wjg.v22.i15.4020]
- 15 **Blankenburg M**, Boekens H, Hechler T, Maier C, Krumova E, Scherens A, Magerl W, Aksu F, Zernikow B. Reference values for quantitative sensory testing in children and adolescents: developmental and gender differences of somatosensory perception. *Pain* 2010; **149**: 76-88 [PMID: 20138430 DOI: 10.1016/j.pain.2010.01.011]
- 16 **Ahn JY**, Jung HY, Choi KD, Choi JY, Kim MY, Lee JH, Choi KS, Kim DH, Song HJ, Lee GH, Kim JH, Park YS. Endoscopic and oncologic outcomes after endoscopic resection for early gastric cancer: 1370 cases of absolute and extended indications. *Gastrointest Endosc* 2011; **74**: 485-493 [PMID: 21741645 DOI: 10.1016/j.gie.2011.04.038]
- 17 **Jeon HK**, Lee SJ, Kim GH, Park DY, Lee BE, Song GA. Endoscopic submucosal dissection for undifferentiated-type early gastric cancer: short- and long-term outcomes. *Surg Endosc* 2017; Epub ahead of print [PMID: 29046960 DOI: 10.1007/s00464-017-5892-3]
- 18 **Luinetti O**, Fiocca R, Villani L, Alberizzi P, Ranzani GN, Solcia E. Genetic pattern, histological structure, and cellular phenotype in early and advanced gastric cancers: evidence for structure-related genetic subsets and for loss of glandular structure during progression of some tumors. *Hum Pathol* 1998; **29**: 702-709 [PMID: 9670827]
- 19 **Takizawa K**, Ono H, Kakushima N, Tanaka M, Hasuie N, Matsubayashi H, Yamaguchi Y, Bando E, Terashima M, Kusafuka K, Nakajima T. Risk of lymph node metastases from intramucosal gastric cancer in relation to histological types: how to manage the mixed histological type for endoscopic submucosal dissection. *Gastric Cancer* 2013; **16**: 531-536 [PMID: 23192620 DOI: 10.1007/s10120-012-0220-z]
- 20 **Hanaoka N**, Tanabe S, Mikami T, Okayasu I, Saigenji K. Mixed-histologic-type submucosal invasive gastric cancer as a risk factor for lymph node metastasis: feasibility of endoscopic submucosal dissection. *Endoscopy* 2009; **41**: 427-432 [PMID: 19418397 DOI: 10.1055/s-0029-1214495]
- 21 **Mita T**, Shimoda T. Risk factors for lymph node metastasis of submucosal invasive differentiated type gastric carcinoma: clinical significance of histological heterogeneity. *J Gastroenterol* 2001; **36**: 661-668 [PMID: 11686475]
- 22 **Wittekind C**. [2010 TNM system: on the 7th edition of TNM classification of malignant tumors]. *Pathologe* 2010; **31**: 331-332 [PMID: 20703480 DOI: 10.1007/s00292-010-1349-3]
- 23 **Shimizu H**, Ichikawa D, Komatsu S, Okamoto K, Shiozaki A, Fujiwara H, Murayama Y, Kuriu Y, Ikoma H, Nakanishi M, Ochiai T, Kokuba Y, Kishimoto M, Yanagisawa A, Otsuji E. The decision criterion of histological mixed type in "T1/T2" gastric carcinoma--comparison between TNM classification and Japanese Classification of Gastric Cancer. *J Surg Oncol* 2012; **105**: 800-804 [PMID: 22189799 DOI: 10.1002/jso.23010]
- 24 **Zheng HC**, Li XH, Hara T, Masuda S, Yang XH, Guan YF, Takano Y. Mixed-type gastric carcinomas exhibit more aggressive features and indicate the histogenesis of carcinomas. *Virchows Arch* 2008; **452**: 525-534 [PMID: 18266006 DOI: 10.1007/s00428-007-0572-7]
- 25 **Sark SY**, Kook MC, Kim YW, Cho NY, Kim TY, Kang GH. Mixed-type gastric cancer and its association with high-frequency CpG island hypermethylation. *Virchows Arch* 2010; **456**: 625-633 [PMID: 20422213 DOI: 10.1007/s00428-010-0916-6]
- 26 **Saito A**, Shimoda T, Nakanishi Y, Ochiai A, Toda G. Histologic heterogeneity and mucin phenotypic expression in early gastric cancer. *Pathol Int* 2001; **51**: 165-171 [PMID: 11328531 DOI: 10.1046/j.1440-1827.2001.01179.x]
- 27 **Pyo JH**, Lee H, Min BH, Lee JH, Choi MG, Lee JH, Sohn TS, Bae JM, Kim KM, Yeon S, Jung SH, Kim JJ, Kim S. Early gastric cancer with a mixed-type Lauren classification is more aggressive and exhibits greater lymph node metastasis. *J Gastroenterol* 2017; **52**: 594-601 [PMID: 27590416 DOI: 10.1007/s00535-016-1254-5]
- 28 **Lee JH**, Choi IJ, Han HS, Kim YW, Ryu KW, Yoon HM, Eom BW, Kim CG, Lee JY, Cho SJ, Kim YI, Nam BH, Kook MC. Risk of lymph node metastasis in differentiated type mucosal early gastric cancer mixed with minor undifferentiated type histology. *Ann Surg Oncol* 2015; **22**: 1813-1819 [PMID: 25344305 DOI: 10.1245/s10434-014-4167-7]
- 29 **Huo ZB**, Chen SB, Zhang J, Li H, Wu DC, Zhai TS, Luan SF. Risk clinicopathological factors for lymph node metastasis in poorly differentiated early gastric cancer and their impact on laparoscopic wedge resection. *World J Gastroenterol* 2012; **18**: 6489-6493 [PMID: 23197896 DOI: 10.3748/wjg.v18.i44.6489]

**P- Reviewer:** Goral V, Vinh-Hung V, Vorobjova T

**S- Editor:** Gong ZM **L- Editor:** Wang TQ **E- Editor:** Li D





Published by **Baishideng Publishing Group Inc**  
7901 Stoneridge Drive, Suite 501, Pleasanton, CA 94588, USA  
Telephone: +1-925-223-8242  
Fax: +1-925-223-8243  
E-mail: [bpgooffice@wjgnet.com](mailto:bpgooffice@wjgnet.com)  
Help Desk: <http://www.f6publishing.com/helpdesk>  
<http://www.wjgnet.com>



ISSN 1007-9327

