

World Journal of *Gastroenterology*

World J Gastroenterol 2018 February 14; 24(6): 657-766



ORIGINAL ARTICLE

Basic Study

- 657** Role of *PTPN22* polymorphisms in pathophysiology of Crohn's disease
Sharp RC, Beg SA, Naser SA
- 671** Health-related quality of life, anxiety, depression and impulsivity in patients with advanced gastroenteropancreatic neuroendocrine tumours
Lewis AR, Wang X, Magdalani L, D'Arienzo P, Bashir C, Mansoor W, Hubner R, Valle JW, McNamara MG
- 680** Analysis of hepatitis B virus preS1 variability and prevalence of the rs2296651 polymorphism in a Spanish population
Casillas R, Tabernero D, Gregori J, Belmonte I, Cortese MF, González C, Riveiro-Barciela M, López RM, Quer J, Esteban R, Buti M, Rodríguez-Frías F
- 693** Inhibitory effects of patchouli alcohol on stress-induced diarrhea-predominant irritable bowel syndrome
Zhou TR, Huang JJ, Huang ZT, Cao HY, Tan B
- 706** Recombinant expressed vasoactive intestinal peptide analogue ameliorates TNBS-induced colitis in rats
Xu CL, Guo Y, Qiao L, Ma L, Cheng YY

Retrospective Study

- 716** Split-dose bowel preparation improves adequacy of bowel preparation and gastroenterologists' adherence to National Colorectal Cancer Screening and Surveillance Guidelines
Menees SB, Kim HM, Schoenfeld P
- 725** Clinical utility of hepatitis B surface antigen kinetics in treatment-naïve chronic hepatitis B patients during long-term entecavir therapy
Lin TC, Chiu YC, Chiu HC, Liu WC, Cheng PN, Chen CY, Chang TT, Wu IC
- 737** Performance of transient elastography in assessing liver fibrosis in patients with autoimmune hepatitis-primary biliary cholangitis overlap syndrome
Wu HM, Sheng L, Wang Q, Bao H, Miao Q, Xiao X, Guo CJ, Li H, Ma X, Qiu DK, Hua J

Clinical Practice Study

- 744 Value of contrast-enhanced ultrasound in the differential diagnosis of gallbladder lesion

Zhang HP, Bai M, Gu JY, He YQ, Qiao XH, Du LF

Observational Study

- 752 High prevalence of hepatitis B-antibody loss and a case report of *de novo* hepatitis B virus infection in a child after living-donor liver transplantation

Sintusek P, Posuwan N, Wanawongsawad P, Jitraruch S, Poovorawan Y, Chongsrisawat V

CASE REPORT

- 763 Gastroenteritis in an adult female revealing hemolytic uremic syndrome: Case report

Chinchilla-López P, Cruz-Ramón V, Ramírez-Pérez O, Méndez-Sánchez N

Contents

World Journal of Gastroenterology
Volume 24 Number 6 February 14, 2018

ABOUT COVER

Editorial board member of *World Journal of Gastroenterology*, Yoshiaki Iwasaki, MD, PhD, Professor, Health Service Center, Okayama University, Okayama 700-8530, Japan

AIMS AND SCOPE

World Journal of Gastroenterology (*World J Gastroenterol*, *WJG*, print ISSN 1007-9327, online ISSN 2219-2840, DOI: 10.3748) is a peer-reviewed open access journal. *WJG* was established on October 1, 1995. It is published weekly on the 7th, 14th, 21st, and 28th each month. The *WJG* Editorial Board consists of 642 experts in gastroenterology and hepatology from 59 countries.

The primary task of *WJG* is to rapidly publish high-quality original articles, reviews, and commentaries in the fields of gastroenterology, hepatology, gastrointestinal endoscopy, gastrointestinal surgery, hepatobiliary surgery, gastrointestinal oncology, gastrointestinal radiation oncology, gastrointestinal imaging, gastrointestinal interventional therapy, gastrointestinal infectious diseases, gastrointestinal pharmacology, gastrointestinal pathophysiology, gastrointestinal pathology, evidence-based medicine in gastroenterology, pancreatology, gastrointestinal laboratory medicine, gastrointestinal molecular biology, gastrointestinal immunology, gastrointestinal microbiology, gastrointestinal genetics, gastrointestinal translational medicine, gastrointestinal diagnostics, and gastrointestinal therapeutics. *WJG* is dedicated to become an influential and prestigious journal in gastroenterology and hepatology, to promote the development of above disciplines, and to improve the diagnostic and therapeutic skill and expertise of clinicians.

INDEXING/ABSTRACTING

World Journal of Gastroenterology (*WJG*) is now indexed in Current Contents[®]/Clinical Medicine, Science Citation Index Expanded (also known as SciSearch[®]), Journal Citation Reports[®], Index Medicus, MEDLINE, PubMed, PubMed Central and Directory of Open Access Journals. The 2018 edition of Journal Citation Reports[®] cites the 2016 impact factor for *WJG* as 3.365 (5-year impact factor: 3.176), ranking *WJG* as 29th among 79 journals in gastroenterology and hepatology (quartile in category Q2).

EDITORS FOR THIS ISSUE

Responsible Assistant Editor: *Xiang Li*
Responsible Electronic Editor: *Yu-Jie Ma*
Proofing Editor-in-Chief: *Lian-Sheng Ma*

Responsible Science Editor: *Xue-Jiao Wang*
Proofing Editorial Office Director: *Ze-Mao Gong*

NAME OF JOURNAL
World Journal of Gastroenterology

ISSN
ISSN 1007-9327 (print)
ISSN 2219-2840 (online)

LAUNCH DATE
October 1, 1995

FREQUENCY
Weekly

EDITORS-IN-CHIEF
Damian Garcia-Olmo, MD, PhD, Doctor, Professor, Surgeon, Department of Surgery, Universidad Autonoma de Madrid; Department of General Surgery, Fundacion Jimenez Diaz University Hospital, Madrid 28040, Spain

Stephen C Strom, PhD, Professor, Department of Laboratory Medicine, Division of Pathology, Karolinska Institutet, Stockholm 141-86, Sweden

Andrzej S Tarnawski, MD, PhD, DSc (Med), Professor of Medicine, Chief Gastroenterology, VA Long Beach Health Care System, University of California, Irvine, CA, 5901 E. Seventh Str., Long Beach,

CA 90822, United States

EDITORIAL BOARD MEMBERS
All editorial board members resources online at <http://www.wjgnet.com/1007-9327/editorialboard.htm>

EDITORIAL OFFICE
Ze-Mao Gong, Director
World Journal of Gastroenterology
Baishideng Publishing Group Inc
7901 Stoneridge Drive, Suite 501,
Pleasanton, CA 94588, USA
Telephone: +1-925-2238242
Fax: +1-925-2238243
E-mail: editorialoffice@wjgnet.com
Help Desk: <http://www.f0publishing.com/helpdesk>
<http://www.wjgnet.com>

PUBLISHER
Baishideng Publishing Group Inc
7901 Stoneridge Drive, Suite 501,
Pleasanton, CA 94588, USA
Telephone: +1-925-2238242
Fax: +1-925-2238243
E-mail: bpoffice@wjgnet.com
Help Desk: <http://www.f0publishing.com/helpdesk>
<http://www.wjgnet.com>

PUBLICATION DATE
February 14, 2018

COPYRIGHT
© 2018 Baishideng Publishing Group Inc. Articles published by this Open-Access journal are distributed under the terms of the Creative Commons Attribution Non-commercial License, which permits use, distribution, and reproduction in any medium, provided the original work is properly cited, the use is non commercial and is otherwise in compliance with the license.

SPECIAL STATEMENT
All articles published in journals owned by the Baishideng Publishing Group (BPG) represent the views and opinions of their authors, and not the views, opinions or policies of the BPG, except where otherwise explicitly indicated.

INSTRUCTIONS TO AUTHORS
Full instructions are available online at <http://www.wjgnet.com/bpg/gerinfo/204>

ONLINE SUBMISSION
<http://www.f0publishing.com>

Retrospective Study

Performance of transient elastography in assessing liver fibrosis in patients with autoimmune hepatitis-primary biliary cholangitis overlap syndrome

Hui-Min Wu, Li Sheng, Qi Wang, Han Bao, Qi Miao, Xiao Xiao, Can-Jie Guo, Hai Li, Xiong Ma, De-Kai Qiu, Jing Hua

Hui-Min Wu, Li Sheng, Qi Wang, Han Bao, Qi Miao, Xiao Xiao, Can-Jie Guo, Hai Li, Xiong Ma, De-Kai Qiu, Jing Hua, Division of Gastroenterology and Hepatology, Renji Hospital, Shanghai 200127, China

Hui-Min Wu, Li Sheng, Qi Wang, Han Bao, Qi Miao, Xiao Xiao, Can-Jie Guo, Hai Li, Xiong Ma, De-Kai Qiu, Jing Hua, School of Medicine, Shanghai Jiao Tong University, Shanghai 200127, China

Hui-Min Wu, Li Sheng, Qi Wang, Han Bao, Qi Miao, Xiao Xiao, Can-Jie Guo, Hai Li, Xiong Ma, De-Kai Qiu, Jing Hua, Shanghai Institute of Digestive Disease, Key Laboratory of Gastroenterology and Hepatology, Ministry of Health, Shanghai 200127, China

ORCID number: Hui-Min Wu (0000-0002-3991-3857); Li Sheng (0000-0002-3641-5211); Qi Wang (0000-0002-6937-8306); Han Bao (0000-0003-2934-3990); Qi Miao (0000-0003-3370-9692); Xiao Xiao (0000-0002-7936-336X); Can-Jie Guo (0000-0001-5951-299X); Hai Li (0000-0001-9937-8852); Xiong Ma (0000-0002-7047-1962); De-Kai Qiu (0000-0002-6312-1702); Jing Hua (0000-0002-6100-9477).

Author contributions: Wu HM and Li S contributed equally to this work and collected and analyzed the data; Wang Q coordinated the research; Bao H and Xiao X performed the transient elastography and coordinated liver biopsy; Miao Q contributed to histological examination; Qiu DK, Ma X, Hua J, Li H, and Guo CJ analyzed the data; Hua J designed the study; Wu HM, Li S and Hua J wrote the paper.

Supported by the National Natural Science Foundation of China, No. 81470842 and No. 81770572 to Hua J.

Institutional review board statement: The study received a waiver of the approval requirement from the ethics committee.

Informed consent statement: All patients signed an informed consent form for liver biopsy.

Conflict-of-interest statement: We declare that there is no conflict of interest to disclose.

Data sharing statement: No additional data are available.

Open-Access: This article is an open-access article which was selected by an in-house editor and fully peer-reviewed by external reviewers. It is distributed in accordance with the Creative Commons Attribution Non Commercial (CC BY-NC 4.0) license, which permits others to distribute, remix, adapt, build upon this work non-commercially, and license their derivative works on different terms, provided the original work is properly cited and the use is non-commercial. See: <http://creativecommons.org/licenses/by-nc/4.0/>

Manuscript source: Unsolicited manuscript.

Correspondence to: Jing Hua, MD, PhD, Professor, Division of Gastroenterology and Hepatology, Renji Hospital, School of Medicine, Shanghai Jiao Tong University, Shanghai Institute of Digestive Disease, No. 160, Pujian Road, Shanghai 200127, China. hua-jing88@hotmail.com
Telephone: +86-21-68383113
Fax: +86-21-63200874

Received: November 7, 2017

Peer-review started: November 8, 2017

First decision: November 21, 2017

Revised: December 5, 2017

Accepted: January 1, 2018

Article in press: January 1, 2018

Published online: February 14, 2018

Abstract

AIM

To investigate the performance of transient elastography (TE) for diagnosis of fibrosis in patients with

autoimmune hepatitis-primary biliary cholangitis (AIH-PBC) overlap syndrome.

<http://www.wjgnet.com/1007-9327/full/v24/i6/737.htm> DOI: <http://dx.doi.org/10.3748/wjg.v24.i6.737>

METHODS

A total of 70 patients with biopsy-proven AIH-PBC overlap syndrome were included. Spearman correlation test was used to analyze the correlation of liver stiffness measurement (LSM) and fibrosis stage. Independent samples Student's *t*-test or one-way analysis of variance was used to compare quantitative variables. Receiver operating characteristics (ROC) curve was used to calculate the optimal cut-off values of LSM for predicting individual fibrosis stages. A comparison on the diagnostic accuracy for severe fibrosis was made between LSM and other serological scores.

RESULTS

Patients with AIH-PBC overlap syndrome had higher median LSM than healthy controls (11.3 ± 6.4 kPa *vs* 4.3 ± 1.4 kPa, $P < 0.01$). LSM was significantly correlated with fibrosis stage ($r = 0.756$, $P < 0.01$). LSM values increased gradually with an increased fibrosis stage. The areas under the ROC curves of LSM for stages $F \geq 2$, $F \geq 3$, and $F4$ were 0.837 (95%CI: 0.729-0.914), 0.910 (0.817-0.965), and 0.966 (0.893-0.995), respectively. The optimal cut-off values of LSM for fibrosis stages $F \geq 2$, $F \geq 3$, and $F4$ were 6.55, 10.50, and 14.45 kPa, respectively. LSM was significantly superior to fibrosis-4, glutamyl-transferase/platelet ratio, and aspartate aminotransferase-to-platelet ratio index scores in detecting severe fibrosis ($F \geq 3$) (0.910 *vs* 0.715, $P < 0.01$; 0.910 *vs* 0.649, $P < 0.01$; 0.910 *vs* 0.616, $P < 0.01$, respectively).

CONCLUSION

TE can accurately detect hepatic fibrosis as a non-invasive method in patients with AIH-PBC overlap syndrome.

Key words: Liver stiffness measurement; Transient elastography; Liver fibrosis; Autoimmune hepatitis; Primary biliary cholangitis; Overlap syndrome

© The Author(s) 2018. Published by Baishideng Publishing Group Inc. All rights reserved.

Core tip: Our research determined that transient elastography can accurately detect hepatic fibrosis as a non-invasive method in patients with autoimmune hepatitis-primary biliary cholangitis overlap syndrome. Liver stiffness measurements were significantly superior to fibrosis-4, glutamyl-transferase/platelet ratio, and aspartate aminotransferase-to-platelet ratio index scores for detecting severe fibrosis.

Wu HM, Sheng L, Wang Q, Bao H, Miao Q, Xiao X, Guo CJ, Li H, Ma X, Qiu DK, Hua J. Performance of transient elastography in assessing liver fibrosis in patients with autoimmune hepatitis-primary biliary cholangitis overlap syndrome. *World J Gastroenterol* 2018; 24(6): 737-743 Available from: URL:

INTRODUCTION

Liver fibrosis, characterized by the accumulation of the extracellular matrix, has been considered a common progressive stage and predictor of undesirable prognosis in various chronic liver diseases^[1]. The evaluation of fibrosis is crucial in the assessment of chronic liver diseases. Liver biopsy remains the gold standard for evaluating fibrosis but has some drawbacks, which has led to the development of non-invasive methods.

Transient elastography (TE) by FibroScan based on ultrasound can noninvasively evaluate liver fibrosis via liver stiffness measurement (LSM)^[2]. It has been introduced as a non-invasive surrogate to liver biopsy for detection of hepatic fibrosis in patients with various chronic liver diseases^[3-6]. Numerous studies have shown that LSM values have a good correlation with histological fibrosis stages. Furthermore, compared to other serum biomarkers, such as aspartate aminotransferase (AST)-to-platelet ratio index (APRI), and fibrosis-4 (FIB-4) scores, LSM is probably the most validated non-invasive method to assess the stage of fibrosis with better diagnostic accuracy^[3,7,8].

Autoimmune hepatitis (AIH) and primary biliary cholangitis (PBC) are two immune-mediated chronic liver diseases targeting hepatocytes and biliary epithelial cells, respectively^[9]. The overlap syndrome of AIH-PBC shares clinical, biochemical, serological, and histological features of patients with AIH and PBC^[10]. AIH is usually a chronic and long-term disease, and approximately 25% of patients with AIH progress to hepatic fibrosis or cirrhosis despite immunosuppression intervention^[11]. Recently, studies reported that patients with AIH-PBC overlap syndrome exhibited a lower response rate to ursodeoxycholic acid and steroid combination therapy while having a more severe clinical prognosis compared with AIH patients^[12]. Therefore, accurately assessing hepatic fibrosis and initiating anti-fibrotic intervention are essential for some AIH-PBC overlap syndrome patients with rapid disease progression. Our recent study revealed that TE can reliably stage liver fibrosis in AIH patients^[13]. However, the evaluation of TE in assessing liver fibrosis in patients with AIH-PBC overlap syndrome remains limited.

In the current study, we assessed the diagnostic performance of TE in evaluating liver fibrosis in biopsy-proven AIH-PBC overlap syndrome patients and made a comparison with other non-invasive methods.

MATERIALS AND METHODS

Patients

Patients who were suspected to have AIH-PBC overlap syndrome and eventually underwent liver biopsy at

Renji Hospital (Shanghai, China) from September 2014 to July 2017 were recruited in this retrospective study. Ultimately, a total of 70 patients met the Paris AIH-PBC overlap syndrome criteria^[10]. Briefly, the requirement of at least two out of three specific criteria in each condition was met. The PBC criteria included: (1) alkaline phosphatase (ALP) levels at least twice the upper limit of normal (ULN) or gamma glutamyltransferase (GGT) levels at least five times the ULN; (2) anti-mitochondrial antibody (AMA) positivity; and (3) florid bile duct lesion in liver biopsy. The AIH criteria comprised of: (1) alanine aminotransferase (ALT) levels at least five times the ULN; (2) IgG levels at least twice the ULN or anti-smooth muscle antibody (ASMA) positivity; and (3) moderate to severe periportal or periseptal lymphocytic piecemeal necrosis in histological examination. All patients received no immunosuppressive therapy before liver biopsy.

The exclusion criteria included chronic infection with hepatic virus B or C, primary sclerosing cholangitis (PSC), PBC, AIH, drug-induced liver disease, alcoholic or non-alcoholic fatty liver disease, hereditary metabolic liver disease, hepatobiliary parasitic infection, and severe systemic disease. Patients with acute severe attack with markedly elevated serum aminotransferase levels (ALT > 1000 U/L) and severe jaundice were excluded. Decompensated cirrhosis with ascites, hepatic encephalopathy, gastrointestinal bleeding, and hepatic carcinoma were excluded. Each participant of this study provided written informed consent.

Histological examination

Percutaneous liver biopsy guided by ultrasound was performed in all patients under local anesthesia using a 16G disposable needle. Liver specimens at least 1 cm in length with eight complete portal tracts were included. The specimens were fixed in 10% neutral formalin immediately and embedded in paraffin. Hematoxylin and eosin staining was used to observe the morphology of the liver, and Masson's trichrome and reticulin staining was performed to detect fibrosis. Liver fibrosis and necroinflammatory activity were evaluated by a single experienced pathologist who was blinded to the patients' clinical data. A METAVIR-derived scoring system was used for evaluating liver fibrosis and inflammation by a single senior pathologist^[14]. In brief, the fibrosis stage description was F0, no fibrosis; F1, portal fibrosis without septa; F2, portal and periportal fibrosis with few septa; F3, portal and periportal fibrosis with numerous septa without cirrhosis; and F4, cirrhosis. Hepatic inflammatory activity was graded as follows: A0, none; A1, mild; A2, moderate; and A3, severe.

Clinical measurements

Medical records of all patients diagnosed with AIH-PBC overlap syndrome were reviewed, and clinical data and laboratory findings were collected and analyzed. Laboratory evaluations included liver biochemistry

[i.e., ALT, AST, ALP, GGT, total bilirubin, direct bilirubin, globulin, and albumin], serum immunoglobulins (IgG, IgM, and IgA), routine blood test (white blood cell count and platelet count), and prothrombin time. APRI score was calculated by using the formula of Wai *et al*^[15] [(AST/ULN considered as 40 IU/L)/platelet count $\times 10^9$ /L]. FIB-4 score was calculated by using the formula of Sterling *et al*^[16] [(age \times AST)/(platelet count \times ALT^{1/2})]. GGT/platelet ratio (GPR) was calculated by using the formula of Lemoine *et al* (GGT/platelet count $\times 10^9$ /L)^[17]. The serum autoantibodies, including anti-nuclear antibody (ANA), AMA, and ASMA were detected by indirect immunofluorescence (Euroimmun AG, Hangzhou, China).

LSM by TE

TE measured with a FibroScan device and an M probe ultrasound transducer (both from Echosens, Paris, France) was performed in all patients who underwent liver biopsy on the same day. According to the ultrasonography images, we selected an appropriate area for detection that contained at least 6-cm-thick liver parenchyma with absence of main blood vessels and the gallbladder. We obtained 10 valid LSMs from each participant and considered LSM with an interquartile range $\leq 30\%$ and a success rate $\geq 60\%$ as reliable. The median value represented the value of LSM expressed in kilopascals (kPa). All the measurements were performed following the manufacturer's instructions. LSM assessment of 25 healthy people as normal controls was also performed.

Statistical analysis

Data were analyzed using SPSS software version 22.0 (SPSS Inc, Chicago, IL, United States). Normally distributed continuous variables are expressed as the mean \pm SD. Quantitative variables were compared using independent samples Student's *t*-test or one-way analysis of variance when appropriate. The Spearman's rank correlation test was used to explore the correlation between the LSM and fibrosis grade. The diagnostic accuracy of LSM for the prediction of fibrosis stages was calculated using a receiver operator characteristic (ROC) curve. Optimal LSM cut-off values for F2-4 fibrosis were determined based on the highest combined sensitivity and specificity (Youden index). The performance characteristics of each cut-off value in terms of sensitivity and specificity were calculated. The areas under the ROC curves (AUROCs) were calculated to compare the diagnostic efficiency of each noninvasive predictor for severe fibrosis. A *P*-value < 0.05 was considered statistically significant.

RESULTS

Characteristics of the patients

A total of 70 biopsy-proven AIH-PBC overlap syndrome patients were included, with a mean age of 46.6 \pm 10.2, and 84.3% of patients were female. In all

Table 1 Baseline characteristics of the patients with autoimmune hepatitis- primary biliary cholangitis overlap syndrome *n* (%)

Characteristic	<i>n</i> = 70
Age	46.6 ± 10.2
Gender	
Male	11 (15.7)
Female	59 (84.3)
Autoantibody positive rate	94.3
Liver function test (mean ± SD)	
ALT (U/L)	185.6 ± 238.9
AST (U/L)	166.6 ± 190.7
GGT (U/L)	363.2 ± 393.3
ALP (U/L)	318.7 ± 245.9
Total bilirubin (μmol/L)	32.3 ± 33.9
Albumin (g/L)	40.1 ± 8.0
Serum IgG level (g/L)	17.0 ± 5.1
Serum IgM level (g/L)	4.2 ± 6.9
Biochemical score (mean ± SD)	
APRI	2.47 ± 3.85
FIB-4	3.22 ± 3.53
GPR	1.93 ± 2.28
Liver biopsy	
Fibrosis stage	
0	0 (0)
1	9 (12.9)
2	29 (41.4)
3	25 (35.7)
4	7 (10.0)
Hepatic inflammatory activity	
0	0 (0)
1	1 (1.4)
2	30 (42.3)
3	39 (55.7)
LSM value (kPa, mean ± SD)	11.3 ± 6.4

AST: Aspartate aminotransferase; ALP: Alkaline phosphatase; APRI: Aspartate aminotransferase-to-platelet ratio index; FIB-4: Fibrosis-4; GGT: Gamma glutamyltransferase; GPR: Gamma glutamyltransferase/platelet ratio; LSM: Liver stiffness measurement.

patients, the prevalence of autoantibodies, including ANA, AMA, and ASMA, was 94.3%. AIH-PBC overlap syndrome was diagnosed based on the Paris criteria. The general characteristics of the patients are shown in Table 1.

Relationship between LSM and histological fibrosis stage

LSM was successfully performed in all patients. The mean LSM value of all AIH-PBC overlap syndrome patients was clearly higher than that of healthy normal controls (11.3 ± 6.4 kPa vs 4.3 ± 1.4 kPa, $P < 0.01$). LSM values for fibrosis stages F1, F2, F3, and F4 were 6.9 ± 3.4 kPa, 8.3 ± 2.0 kPa, 13.3 ± 5.5 kPa, and 22.8 ± 8.3 kPa, respectively. LSM was closely correlated with fibrosis stage ($r = 0.756$, $P < 0.01$). Patients with higher fibrosis stages usually had higher LSM values (Figure 1).

Diagnostic accuracy of LSM

The AUROC values of LSM in detecting significant fibrosis ($F \geq 2$), severe fibrosis ($F \geq 3$), and cirrhosis (F4) were 0.837, 0.910, and 0.966, respectively (Figure

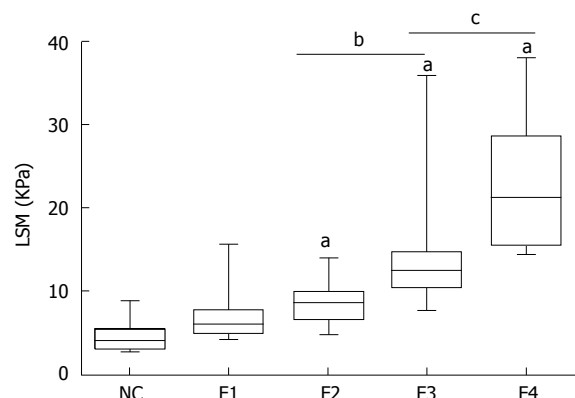


Figure 1 Correlation between liver stiffness measurement and histological fibrosis stage. LSM values were assessed by TE in healthy normal controls and AIH-PBC overlap syndrome patients with different liver fibrosis stages based on the results of liver biopsy (F0–F4). ^a $P < 0.01$, F2, 3, and 4 vs NC; ^b $P < 0.01$, F3 vs F2; ^c $P < 0.01$, F4 vs F3. LSM: Liver stiffness measurement; NC: Normal controls; AIH-PBC: Autoimmune hepatitis-primary biliary cholangitis; TE: Transient elastography.

2). The optimal cut-off values of LSM for fibrosis stages were 6.55 kPa for $F \geq 2$, 10.50 kPa for $F \geq 3$, and 14.45 kPa for F4 with the highest combined sensitivity and specificity (Table 2).

Comparison of the diagnostic accuracy of LSM for severe fibrosis with other serological scores

The biochemical scores FIB-4, GPR, and APRI were calculated for all patients based on their laboratory parameters. AUROCs of FIB-4, APRI, and GPR for detecting severe fibrosis ($F \geq 3$) were 0.715 (95%CI: 0.594–0.816), 0.649 (0.525–0.759), and 0.616 (0.492–0.730), respectively. LSM was superior to FIB-4, GPR, and APRI in detecting severe fibrosis ($F \geq 3$) by AUROC values (0.910 vs 0.715, $P < 0.01$; 0.910 vs 0.649, $P < 0.01$; 0.910 vs 0.616, $P < 0.01$, respectively) (Figure 3).

DISCUSSION

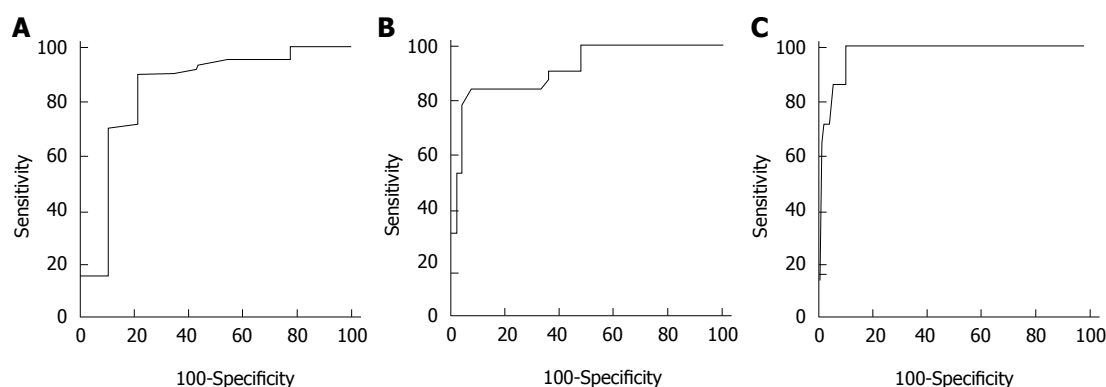
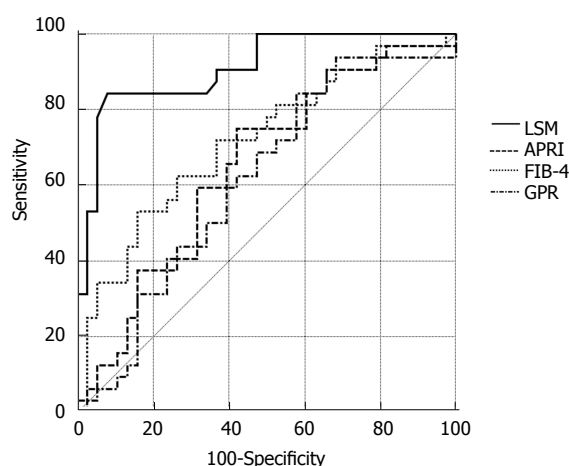
Timely and accurate assessment of the degree of liver fibrosis is crucial to the evaluation of disease progression and decision of therapeutic schedule in various chronic liver diseases^[18]. LSM assessed by TE was introduced and widely used as an effective and promising non-invasive tool for assessment of liver fibrosis in patients with chronic hepatitis B and C, as well as non-alcoholic fatty liver diseases^[19–21]. In the current study, we found that LSM had a strong correlation with histological fibrosis stage in patients with AIH-PBC overlap syndrome, while it was significantly superior to FIB-4, GPR, and APRI scores in detecting severe fibrosis.

Our study illustrated a favorable diagnostic performance of LSM for assessing different fibrosis stages in AIH-PBC overlap syndrome. The AUROCs of LSM in detecting significant fibrosis ($F \geq 2$), severe fibrosis ($F \geq 3$), and cirrhosis (F4) were 0.837, 0.910, and 0.966, respectively. The cut-off values for predicting

Table 2 Diagnostic accuracy of liver stiffness measurement in detecting liver fibrosis in patients with autoimmune hepatitis-primary biliary cholangitis overlap syndrome

stage	AUROC (95%CI)	Cut-off (kPa)	Sensitivity	Specificity	PPV	NPV	+LR	-LR
F \geq 2	0.837 (0.729-0.914)	6.55	0.902	0.778	0.965	0.538	4.06	0.13
F \geq 3	0.910 (0.817-0.965)	10.50	0.844	0.921	0.900	0.875	10.69	0.17
F = 4	0.966 (0.893-0.995)	14.45	1.000	0.889	0.500	1.000	9.00	0.00

AUROC: Areas under the receiver operator characteristic; PPV: Positive predictive value; NPV: Negative predictive value; +LR: Positive likelihood ratio; -LR: Negative likelihood ratio.

**Figure 2** The receiver operator characteristic curve of liver stiffness measurement for the diagnosis of liver fibrosis stage. A: Significant fibrosis (F \geq 2); B: Severe fibrosis (F \geq 3); C: Cirrhosis (F4).**Figure 3** The receiver operator characteristic curves of liver stiffness measurement, fibrosis-4, aspartate aminotransferase-to-platelet ratio index, and GRP for the detection of severe fibrosis (F \geq 3). LSM: liver stiffness measurement; GPR: GGT/platelet ratio; FIB-4: Fibrosis-4; APRI: Amino-transferase -to-platelet ratio index.

F \geq 2, F \geq 3, and F4 were 6.55, 10.50, and 14.45 kPa, respectively. Compared with the cut-off values reported in our recent study in patients with AIH alone, in which the optimal LSM cut-off values for predicting significant fibrosis, severe fibrosis, and cirrhosis were 6.45, 8.75, and 12.5 kPa^[13], respectively, the LSM cut-off values in AIH-PBC overlap syndrome were slightly higher, especially in severe fibrosis and cirrhosis. Another study reported that the optimal LSM cut-off values for significant fibrosis, severe fibrosis, and cirrhosis were

7.3 kPa, 9.8 kPa, and 17.3 kPa, respectively, in PBC and PSC patients^[22]. It seemed that the patients with AIH-PBC overlap syndrome or PBC had relatively higher LSM values than AIH patients. The major reason is probably that AIH-PBC overlap syndrome patients have a poor treatment response and rapid disease progression. However, in a meta-analysis comprised of 22 studies and 4430 patients with different etiologies of liver disease, the estimated LSM cut-off values were 7.71 kPa for F \geq 2 and 15.08 kPa for F4^[23]. Our findings are similar to these results, indicating that etiology of liver disease has no significant effect on LSM assessment.

LSM by TE had a favorable diagnostic performance in evaluating liver fibrosis as a non-invasive method. Compared with APRI and FIB-4, which are widely used as non-invasive serologic methods, LSM showed better accuracy in detecting liver fibrosis^[6,24]. In the current study, we also found that LSM was significantly superior to FIB-4 and APRI in detecting severe fibrosis in AIH-PBC overlap syndrome patients, which is consistent with our previous result. In a recent study, GPR had exhibited a better accuracy than APRI and FIB-4 in detecting liver fibrosis in CHB patients^[17]. Here, we found that GPR had a similar diagnostic performance for detecting severe fibrosis to APRI and FIB-4 scores but was inferior to LSM.

The major limitation of our study was the small patient sample size due to the low prevalence of AIH-PBC overlap syndrome. Larger studies are needed to confirm these results.

In conclusion, LSM by TE is an accurate and reliable

non-invasive method in evaluating liver fibrosis in patients with AIH-PBC overlap syndrome. LSM is significantly superior to APRI, GPR, and FIB-4 scores for detecting severe fibrosis.

ARTICLE HIGHLIGHTS

Research background

Transient elastography (TE) can reliably stage liver fibrosis via liver stiffness measurement (LSM) in chronic liver disease. However, the accuracy of TE for assessment of liver fibrosis in patients with autoimmune hepatitis-primary biliary cholangitis (AIH-PBC) overlap syndrome is still unclear.

Research motivation

It is important to identify non-invasive markers of liver fibrosis to predict disease progression.

Research objectives

We evaluated the performance and usefulness of TE for detection of fibrosis in these patients and compared TE with other non-invasive diagnostic tools.

Research methods

The diagnostic accuracy of LSM for the prediction of fibrosis stages was calculated using a receiver operator characteristic (ROC) curve. Optimal LSM cut-off values for F2-4 fibrosis were determined based on the highest combined sensitivity and specificity.

Research results

TE can accurately detect hepatic fibrosis as a non-invasive method in patients with AIH-PBC overlap syndrome.

Research conclusions

For the first time, the current study evaluated TE as a non-invasive assessment of liver fibrosis in patients with AIH-PBC overlap syndrome and demonstrated that it was a reliable tool that was superior to serum biomarker scores for predicting severe fibrosis.

Research perspectives

The impact of hepatic inflammation on LSM values was not analyzed due to the relatively small number of patients in each subgroup. Larger studies are needed to confirm these results.

REFERENCES

- 1 Lee YA, Wallace MC, Friedman SL. Pathobiology of liver fibrosis: a translational success story. *Gut* 2015; **64**: 830-841 [PMID: 25681399 DOI: 10.1136/gutjnl-2014-306842]
- 2 Alvarez F, Berg PA, Bianchi FB, Bianchi L, Burroughs AK, Cancado EL, Chapman RW, Cooksley WG, Czaja AJ, Desmet VJ, Donaldson PT, Eddleston AL, Fainboim L, Heathcote J, Homberg JC, Hoofnagle JH, Kakumu S, Krawitt EL, Mackay IR, MacSween RN, Maddrey WC, Manns MP, McFarlane IG, Meyer zum Büschenfelde KH, Zeniya M. International Autoimmune Hepatitis Group Report: review of criteria for diagnosis of autoimmune hepatitis. *J Hepatol* 1999; **31**: 929-938 [PMID: 10580593 DOI: 10.1016/S0168-8278(99)80297-9]
- 3 Vierling JM. Autoimmune Hepatitis and Overlap Syndromes: Diagnosis and Management. *Clin Gastroenterol Hepatol* 2015; **13**: 2088-2108 [PMID: 26284592 DOI: 10.1016/j.cgh.2015.08.012]
- 4 Manns MP, Lohse AW, Vergani D. Autoimmune hepatitis—Update 2015. *J Hepatol* 2015; **62**: S100-S111 [PMID: 25920079 DOI: 10.1016/j.jhep.2015.03.005]
- 5 European Association for the Study of the Liver. European Association for the Study of the Liver. EASL Clinical Practice Guidelines: The diagnosis and management of patients with primary biliary cholangitis. *J Hepatol* 2017; **67**: 145-172 [PMID: 28427765 DOI: 10.1016/j.jhep.2017.03.022]
- 6 Castéra L, Vergniol J, Foucher J, Le Bail B, Chanteloup E, Haaser M, Darriet M, Couzigou P, De Lédinghen V. Prospective comparison of transient elastography, Fibrotest, APRI, and liver biopsy for the assessment of fibrosis in chronic hepatitis C. *Gastroenterology* 2005; **128**: 343-350 [PMID: 15685546 DOI: 10.1053/j.gastro.2004.11.018]
- 7 Rockey DC, Caldwell SH, Goodman ZD, Nelson RC, Smith AD; American Association for the Study of Liver Diseases. Liver biopsy. *Hepatology* 2009; **49**: 1017-1044 [PMID: 19243014 DOI: 10.1002/hep.22742]
- 8 Sandrin L, Fourquet B, Hasquenoph JM, Yon S, Fournier C, Mal F, Christidis C, Ziol M, Poulet B, Kazemi F, Beaugrand M, Palau R. Transient elastography: a new noninvasive method for assessment of hepatic fibrosis. *Ultrasound Med Biol* 2003; **29**: 1705-1713 [PMID: 14698338 DOI: 10.1016/j.ultrasmedbio.2003.07.001]
- 9 Wang Q, Selmi C, Zhou X, Qiu D, Li Z, Miao Q, Chen X, Wang J, Krawitt EL, Gershwin ME, Han Y, Ma X. Epigenetic considerations and the clinical reevaluation of the overlap syndrome between primary biliary cirrhosis and autoimmune hepatitis. *J Autoimmun* 2013; **41**: 140-145 [PMID: 23187010 DOI: 10.1016/j.jaut.2012.10.004]
- 10 Chazouillères O, Wendum D, Serfaty L, Montebault S, Rosmorduc O, Poupon R. Primary biliary cirrhosis-autoimmune hepatitis overlap syndrome: clinical features and response to therapy. *Hepatology* 1998; **28**: 296-301 [PMID: 9695990 DOI: 10.1002/hep.510280203]
- 11 Montano-Loza AJ, Thandassery RB, Czaja AJ. Targeting Hepatic Fibrosis in Autoimmune Hepatitis. *Dig Dis Sci* 2016; **61**: 3118-3139 [PMID: 27435327 DOI: 10.1007/s10620-016-4254-7]
- 12 Park Y, Cho Y, Cho EJ, Kim YJ. Retrospective analysis of autoimmune hepatitis-primary biliary cirrhosis overlap syndrome in Korea: characteristics, treatments, and outcomes. *Clin Mol Hepatol* 2015; **21**: 150-157 [PMID: 26157752 DOI: 10.3350/cmh.2015.21.2.150]
- 13 Xu Q, Sheng L, Bao H, Chen X, Guo C, Li H, Ma X, Qiu D, Hua J. Evaluation of transient elastography in assessing liver fibrosis in patients with autoimmune hepatitis. *J Gastroenterol Hepatol* 2017; **32**: 639-644 [PMID: 27505153 DOI: 10.1111/jgh.13508]
- 14 Bedossa P, Poynard T. An algorithm for the grading of activity in chronic hepatitis C. The METAVIR Cooperative Study Group. *Hepatology* 1996; **24**: 289-293 [PMID: 8690394 DOI: 10.1002/hep.510240201]
- 15 Wai CT, Greenson JK, Fontana RJ, Kalbfleisch JD, Marrero JA, Conjeevaram HS, Lok AS. A simple noninvasive index can predict both significant fibrosis and cirrhosis in patients with chronic hepatitis C. *Hepatology* 2003; **38**: 518-526 [PMID: 12883497 DOI: 10.1053/jhep.2003.50346]
- 16 Sterling RK, Lissen E, Clumeck N, Sola R, Correa MC, Montaner J, Sulkowski M, Torriani FJ, Dieterich DT, Thomas DL, Messinger D, Nelson M; APRICOT Clinical Investigators. Development of a simple noninvasive index to predict significant fibrosis in patients with HIV/HCV coinfection. *Hepatology* 2006; **43**: 1317-1325 [PMID: 16729309 DOI: 10.1002/hep.21178]
- 17 Lemoine M, Shimakawa Y, Nayagam S, Khalil M, Suso P, Lloyd J, Goldin R, Njai HF, Ndow G, Taal M, Cooke G, D'Alessandro U, Vray M, Mbaye PS, Njie R, Mallet V, Thursz M. The gamma-glutamyl transpeptidase to platelet ratio (GPR) predicts significant liver fibrosis and cirrhosis in patients with chronic HBV infection in West Africa. *Gut* 2016; **65**: 1369-1376 [PMID: 26109530 DOI: 10.1136/gutjnl-2015-309260]
- 18 Trautwein C, Friedman SL, Schuppan D, Pinzani M. Hepatic fibrosis: Concept to treatment. *J Hepatol* 2015; **62**: S15-S24 [PMID: 25920084 DOI: 10.1016/j.jhep.2015.02.039]
- 19 Jia J, Hou J, Ding H, Chen G, Xie Q, Wang Y, Zeng M, Zhao J, Wang T, Hu X, Schuppan D. Transient elastography compared to serum markers to predict liver fibrosis in a cohort of Chinese patients with chronic hepatitis B. *J Gastroenterol Hepatol* 2015; **30**: 756-762 [PMID: 25353058 DOI: 10.1111/jgh.12840]
- 20 Ziol M, Handra-Luca A, Kettaneh A, Christidis C, Mal F, Kazemi F,

- de Lédinghen V, Marcellin P, Dhumeaux D, Trinchet JC, Beaugrand M. Noninvasive assessment of liver fibrosis by measurement of stiffness in patients with chronic hepatitis C. *Hepatology* 2005; **41**: 48-54 [PMID: 15690481 DOI: 10.1002/hep.20506]
- 21 **Yoneda M**, Yoneda M, Fujita K, Inamori M, Tamano M, Hiriishi H, Nakajima A. Transient elastography in patients with non-alcoholic fatty liver disease (NAFLD). *Gut* 2007; **56**: 1330-1331 [PMID: 17470477 DOI: 10.1136/gut.2007.126417]
- 22 **Corpechot C**, El Naggar A, Poujol-Robert A, Ziol M, Wendum D, Chazouillères O, de Lédinghen V, Dhumeaux D, Marcellin P, Beaugrand M, Poupon R. Assessment of biliary fibrosis by transient elastography in patients with PBC and PSC. *Hepatology* 2006; **43**: 1118-1124 [PMID: 16628644 DOI: 10.1002/hep.21151]
- 23 **Stebbing J**, Farouk L, Panos G, Anderson M, Jiao LR, Mandalia S, Bower M, Gazzard B, Nelson M. A meta-analysis of transient elastography for the detection of hepatic fibrosis. *J Clin Gastroenterol* 2010; **44**: 214-219 [PMID: 19745758 DOI: 10.1097/MCG.0b013e3181b4af1f]
- 24 **E Anastasiou O**, Büchter M, A Baba H, Korth J, Canbay A, Gerken G, Kahraman A. Performance and Utility of Transient Elastography and Non-Invasive Markers of Liver Fibrosis in Patients with Autoimmune Hepatitis: A Single Centre Experience. *Hepat Mon* 2016; **16**: e40737 [PMID: 28070199 DOI: 10.5812/hepatmon.40737]

P- Reviewer: Saez-Royuela F **S- Editor:** Gong ZM
L- Editor: Wang TQ **E- Editor:** Ma YJ





Published by **Baishideng Publishing Group Inc**
7901 Stoneridge Drive, Suite 501, Pleasanton, CA 94588, USA
Telephone: +1-925-223-8242
Fax: +1-925-223-8243
E-mail: bpgoffice@wjgnet.com
Help Desk: <http://www.f6publishing.com/helpdesk>
<http://www.wjgnet.com>



ISSN 1007-9327

