

World Journal of *Gastrointestinal Surgery*

World J Gastrointest Surg 2018 February 27; 10(2): 6-27



**MINIREVIEWS**

- 6 Dolichocolon revisited: An inborn anatomic variant with redundancies causing constipation and volvulus
Raahave D

ORIGINAL ARTICLE**Clinical Trials Study**

- 13 Transcutaneous electroacupuncture alleviates postoperative ileus after gastrectomy: A randomized clinical trial
Chen KB, Lu YQ, Chen JD, Shi DK, Huang ZH, Zheng YX, Jin XL, Wang ZF, Zhang WD, Huang Y, Wu ZW, Zhang GP, Zhang H, Jiang YH, Chen L

Observational Study

- 21 Perioperative liver and spleen elastography in patients without chronic liver disease
Eriksson S, Borsiin H, Öberg CF, Brange H, Mijovic Z, Stureson C

Contents

World Journal of Gastrointestinal Surgery
Volume 10 Number 2 February 27, 2018

ABOUT COVER

Editorial Board Member of *World Journal of Gastrointestinal Surgery*, Hans G Beger, MD, Professor, Department of Visceralchirurgie, University of Ulm, Ulm 89075, Germany

AIM AND SCOPE

World Journal of Gastrointestinal Surgery (*World J Gastrointest Surg*, *WJGS*, online ISSN 1948-9366, DOI: 10.4240) is a peer-reviewed open access academic journal that aims to guide clinical practice and improve diagnostic and therapeutic skills of clinicians.

WJGS covers topics concerning micro-invasive surgery; laparoscopy; hepatic, biliary, pancreatic and splenic surgery; surgical nutrition; portal hypertension, as well as associated subjects. The current columns of *WJGS* include editorial, frontier, diagnostic advances, therapeutics advances, field of vision, mini-reviews, review, topic highlight, medical ethics, original articles, case report, clinical case conference (Clinicopathological conference), and autobiography. Priority publication will be given to articles concerning diagnosis and treatment of gastrointestinal surgery diseases. The following aspects are covered: Clinical diagnosis, laboratory diagnosis, differential diagnosis, imaging tests, pathological diagnosis, molecular biological diagnosis, immunological diagnosis, genetic diagnosis, functional diagnostics, and physical diagnosis; and comprehensive therapy, drug therapy, surgical therapy, interventional treatment, minimally invasive therapy, and robot-assisted therapy.

We encourage authors to submit their manuscripts to *WJGS*. We will give priority to manuscripts that are supported by major national and international foundations and those that are of great basic and clinical significance.

INDEXING/ABSTRACTING

World Journal of Gastrointestinal Surgery is now indexed in Emerging Sources Citation Index (Web of Science), PubMed, and PubMed Central.

EDITORS FOR THIS ISSUE

Responsible Assistant Editor: *Xiang Li*
Responsible Electronic Editor: *Jin-Li Yan*
Proofing Editor-in-Chief: *Lian-Sheng Ma*

Responsible Science Editor: *Li-Jun Cui*
Proofing Editorial Office Director: *Xin-Xia Song*

NAME OF JOURNAL

World Journal of Gastrointestinal Surgery

ISSN

ISSN 1948-9366 (online)

LAUNCH DATE

November 30, 2009

FREQUENCY

Monthly

EDITOR-IN-CHIEF

Timothy M Pawlik, MD, Director, Professor, Department of Surgery, Johns Hopkins University, School of Medical, Baltimore, MD 21287, United States

EDITORIAL BOARD MEMBERS

All editorial board members resources online at <http://www.wjgnet.com/1948-9366/editorialboard.htm>

EDITORIAL OFFICE

Xiu-Xia Song, Director

World Journal of Gastrointestinal Surgery

Baishideng Publishing Group Inc
8226 Regency Drive, Pleasanton, CA 94588, USA
Telephone: +1-925-2238242

Fax: +1-925-2238243

E-mail: editorialoffice@wjgnet.com

Help Desk: <http://www.wjgnet.com/esps/helpdesk.aspx>

<http://www.wjgnet.com>

PUBLISHER

Baishideng Publishing Group Inc

8226 Regency Drive,

Pleasanton, CA 94588, USA

Telephone: +1-925-2238242

Fax: +1-925-2238243

E-mail: bpgoffice@wjgnet.com

Help Desk: <http://www.wjgnet.com/esps/helpdesk.aspx>

<http://www.wjgnet.com>

PUBLICATION DATE

February 27, 2018

COPYRIGHT

© 2018 Baishideng Publishing Group Inc. Articles published by this Open-Access journal are distributed under the terms of the Creative Commons Attribution Non-commercial License, which permits use, distribution, and reproduction in any medium, provided the original work is properly cited, the use is non commercial and is otherwise in compliance with the license.

SPECIAL STATEMENT

All articles published in journals owned by the Baishideng Publishing Group (BPG) represent the views and opinions of their authors, and not the views, opinions or policies of the BPG, except where otherwise explicitly indicated.

INSTRUCTIONS TO AUTHORS

<http://www.wjgnet.com/bpg/gerinfo/204>

ONLINE SUBMISSION

<http://www.wjgnet.com/esps/>

Dolichocolon revisited: An inborn anatomic variant with redundancies causing constipation and volvulus

Dennis Raahave

Dennis Raahave, Department of Surgery, Copenhagen University North Sealand Hospital, Hilleroed 3400, Denmark

Author contributions: Raahave D wrote the paper.

Conflict-of-interest statement: The author declares no conflict of interest.

Open-Access: This article is an open-access article which was selected by an in-house editor and fully peer-reviewed by external reviewers. It is distributed in accordance with the Creative Commons Attribution Non Commercial (CC BY-NC 4.0) license, which permits others to distribute, remix, adapt, build upon this work non-commercially, and license their derivative works on different terms, provided the original work is properly cited and the use is non-commercial. See: <http://creativecommons.org/licenses/by-nc/4.0/>

Manuscript source: Invited manuscript

Correspondence to: Dennis Raahave, MD, PhD, DMSci, Consultant Surgeon, Senior Researcher, Department of Surgery, Copenhagen University North Sealand Hospital, Dyrehavevej 29, Hilleroed 3400, Denmark. dr.dr@dadlnet.dk
Telephone: +45-40-258626

Received: November 2, 2017

Peer-review started: November 2, 2017

First decision: November 28, 2017

Revised: January 25, 2018

Accepted: January 29, 2018

Article in press: January 29, 2018

Published online: February 27, 2018

Abstract

The objective of this review is to examine whether a redundant colon gives rise to symptoms like constipation and volvulus. In 1820, Monterossi made drawings of colons with displacements and elongation of the colon found during autopsy. In 1912, Kienböck first visualized a redundant colon using bismuth, and Lardennois and Auborg named the anatomic variant dolichocolon in

1914. The criteria were later: A sigmoid loop rising over the line between the iliac crests, a transverse colon below the same line and extra loops at the flexures. The incidence of dolichocolon is 1.9%-28.5%. Dolichocolon seems to be congenital, as fetuses, newborns, and infants exhibit colonic redundancies. Studies have identified a triade of constipation, abdominal pain, and distension. Colon transit time was recently shown to increase significantly with increased number of redundancies, which increases abdominal pain, bloating and infrequent defecation. The diagnosis of dolichocolon is established by barium enema or CT-colonography. Treatment is conservative, or surgical in case of volvulus or refractory constipation.

Key words: Dolichocolon; Colon elongatum; Functional gastrointestinal disorders; Constipation; Volvulus

© **The Author(s) 2018.** Published by Baishideng Publishing Group Inc. All rights reserved.

Core tip: Dolichocolon is an inborn anatomic variant, where redundancies may be located in the right, middle and left part of the colon and at the flexures. This review investigated the literature on dolichocolon. The prevalence is not known. The incidence is 1.9%-28.5% in patient series. The dominating symptoms of dolichocolon are constipation, abdominal pain and volvulus. Colon transit time is prolonged and increases significantly with increased number of redundancies, which increases abdominal pain, bloating and infrequent defecation. The diagnosis is established by a barium enema or CT-colonography. Treatment is conservative, or surgical in case of volvulus or refractory constipation.

Raahave D. Dolichocolon revisited: An inborn anatomic variant with redundancies causing constipation and volvulus. *World J Gastrointest Surg* 2018; 10(2): 6-12 Available from: URL: <http://www.wjgnet.com/1948-9366/full/v10/i2/6.htm> DOI: <http://dx.doi.org/10.4240/wjgs.v10.i2.6>

INTRODUCTION

The redundant colon represents an unusually lengthened large bowel folded up upon itself, forming extra loops, tortuosities and kinks. The redundancy may involve the entire colon or it may be limited to certain areas as the hepatic flexure, transverse colon, splenic flexure, but the distal colon especially the region of the sigmoid is the most commonly affected. There has long been a debate about whether a redundant colon gives rise to symptoms like constipation and volvulus. The objective of this review is to critically examine this issue.

Embryological development of the colon

The development of the midgut in the embryo is characterized by a rapid elongation of the gut and its mesentery, resulting in formation of the primary intestinal loop. The cephalic limb of the loop develops into the distal part of the duodenum, the jejunum, and part of the ileum. The caudal limb becomes the lower portion of the ileum, the caecum, the appendix, the ascending colon and the proximal two-thirds of the transverse colon. In adults, the junction of the cranial and caudal limb can only be recognized if a portion of the vitelline duct persists as a Meckel's diverticulum^[1]. Coinciding with the growth in length, the primitive intestinal loop rotates around an axis formed by the superior mesenteric artery. Subsequently, elongation of the small intestinal loop continues, forming coiled loops. Similarly, the large intestine grows considerably in length, but fails to participate in the coiling phenomenon. At the end of the third month, the intestinal loops return to the abdominal cavity from the extra-embryonic coelom. The caecal bud is temporarily located in the right upper quadrant below the liver before it descends into the right iliac fossa, thereby forming the ascending colon and hepatic flexure. The distal end of the caecal swelling forms a narrow diverticulum, the appendix. As the intestine returns to the abdominal cavity, their mesenteries are pressed against the posterior abdominal wall where they fuse with the parietal peritoneum, fixing the right and left colon. The colon is now as it is in the adult.

ANCIENT ANATOMIC OBSERVATIONS OF THE COLON

In 1820, Monterossi^[2] noted from autopsies an increased length of the colon, which was depicted in handmade drawings showing sigmoid loops and duplication of the right and left colonic flexure (Figure 1). Treves^[3] dissected the bodies of patients who died from reasons other than abdominal diseases. He was convinced that the length of the bowel was independent of age, height, and weight. In the full-term fetus, he found that the length of the intestine, and especially the colon, was significantly constant. Shober^[4] reported 18 cases selected from different investigators between 1826 and

1896 in which the sigmoid flexure was found on the right side of the pelvis. Various other abnormalities were reported, including a caecum in the right hypochondriac region with extensive mesentery. It seems that the colon was likely to vary in length and in mode of disposition more than any other part of the intestinal canal^[5]. This was further demonstrated by Black^[6] in a series of drawings from textbooks and journal papers between 1836 and 1911, showing a multitude of displacement and elongation of the left colon. The hepatic and splenic flexures were permanently in place.

Bryant^[7] measured the intestines after removed from the body. His data showed that Treves^[3] was incorrect in stating that all children start life with practically the same length of intestine. He found great variations in the small intestine and colon before the fifth month of fetal life. At the age of 10 years, the child has a length of colon considered normal for the adult. He also found that the colon varied in length from 1.25 to 2.00 m, with an average length of 1.52 m. Furthermore, he reported that the length of the colon increased about 20 cm between 20 and 80 years of age.

NEWER OBSERVATIONS OF COLON LENGTH

Phillips *et al*^[8] reported colon length from several studies of cadavers, using laparotomy, barium enema or CT-colonography, between 1955 and 2015. The mean length of the colon varied between 109.0 cm and 169.0 cm. A redundant colon with loops was not mentioned. In their own study, they found a significant proportion of colons had mobility of the ascending and descending segments, with the length of the latter being highly variable. This may indicate loose redundancies.

RADIOLOGY OF DOLICHOCOLON

By combining a bismuth meal and a bismuth clysm, Kienböck^[9] was the first to visualize a redundant colon. An extremely long mobile descending colon and sigmoid ran from the left flexure through the abdomen up under the liver and then distally superimposed to the ascending colon and caecum, before joining the rectum. A few years later, Lardennois and Aubourg^[10] using the same technique demonstrated various redundancies in all parts of the colon, in both adults and children. These investigators named the anatomic variant dolichocolon (dolicho-, Greek: long). During the following years, many case-series with all positions of colonic redundancies were published, using this new X-ray technique^[11-14]. The colon length or that of the redundancies was not measured. Years later, the redundant colon was characterized by the following criteria: a sigmoid loop rising over the line between the iliac crests, a transverse colon below the same line and extra loops at the hepatic and splenic flexure. A fully developed dolichocolon occurs when all redundancies

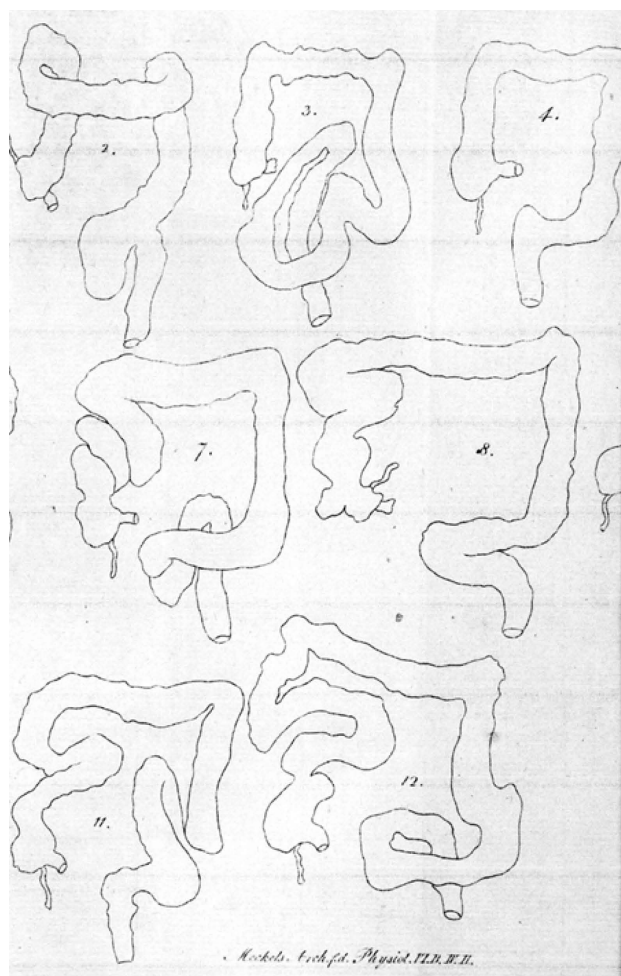


Figure 1 Handmade drawings of dolichocolon forming tortuosities, loops and kinks. From Monterossi^[2], 1820.

are present simultaneously^[15-17] (Figures 2 and 3).

A long colon may result in an incomplete colonoscopy, as demonstrated in a study in which the colorectal length was 45 cm longer than the length in a group who underwent complete colonoscopy^[18].

ETIOLOGY OF DOLICHOCOLON

Redundancy of the colon is a far from seldom variant. In 1934, Kantor^[19] reported 258 cases from 1614 patients who underwent roentgenography, an incidence of 16.0%. However, Moeller^[13] found redundant colon in 18 out of 744 cases, an incidence of 2.4%. A high incidence of 28.5% was found among 562 cases reported by Larimore^[12], and in 116 newborn infants, he found redundancy with the same frequency and variation as in adults. In cadavers, Bryant^[7] reported an incidence of 14% among 242 subjects. Thus, redundancy seems to occur at any age, in either sex, and without special preference to any habitus^[20].

For the next half century, the interest in redundant colon seemed to wane. The prevalence of dolichocolon in a population is not known, because healthy people have not been investigated for that purpose. The closest

to such an evaluation is a study by Brumer^[21] in which 53 patients had a barium enema for reasons other than constipation; one patient (1.9%) had a redundant colon. In 2009, Raahave *et al*^[17] published a study of 236 patients with constipation disorders, finding high frequencies of colonic redundancies.

The question for many authors has been whether dolichocolon is a congenital anatomic variant, an abnormal growth, or pathological stretching. Treves^[3] and Bryant^[7] assumed that colon growth is associated with activity and function depending on the diet. Very recently, the large bowel was shown in mice to undergo substantial changes in length, as it fills with fecal matter, and that the stretching of longitudinal muscles results in slow colonic transit^[22]. However, using barium enema, several authors have shown that fetuses, newborns, and infants exhibit colonic redundancies^[10,12,23]. Recently, colonic elongation has been shown in children by nuclear transit scintigraphy^[24]. A familiar occurrence of dolichocolon has also been observed^[25]. In general, there are great variations in the frequency and positions of redundancies. Most investigators have found them to occur in the middle and left side of the colon^[11,12,17,23].

Thus, dolichocolon is mainly congenital, but function and fecal transport may also promote some changes.

SYMPTOMS FROM THE REDUNDANT COLON

The dominating symptom of dolichocolon is constipation^[4,6,9,13,14,19,23,25,26], and patients have died from it^[5]. In 1962, Brumer^[21] examined 106 patients with chronic constipation using barium enema and found 32 (30.2%) had a redundant colon. Among 53 controls, only one (1.9%) had a colon with redundancies. He concluded that a causal connection must exist between this anomaly and constipation. The most common related cause of constipation after anorectal myectomy was later found to be a redundant colon^[27]. When evaluating patients with slow transit constipation, the cause was always associated with dolichocolon^[28]. Recently, a high proportion of patients with constipation disorders was shown to have redundant colon^[17].

Pain sometimes cramp-like, often occurs in the lower abdomen^[4,11,13,17,19,23,25], where a tender mass may sometimes be felt^[6,17,19]. Constipation and pain are often followed with distension, and many cases demonstrate how much these patients have suffered.

Non-specific symptoms have also been linked to redundant colon, such as general weakness, headache, and mild fever attacks suggested to be caused by a toxic condition because of fecal stasis^[4,10,23,29]. In the beginning of the 20th century, a theory of autointoxication was formulated^[30], but then discredited among little proof of bacterial toxin production. However, immune activation is detected in constipated patients based on levels of CD3⁺, CD4⁺, CD8⁺, and CD25⁺ T-cells and by spontaneous proliferation of lymphocytes. T-cell activation, elevated

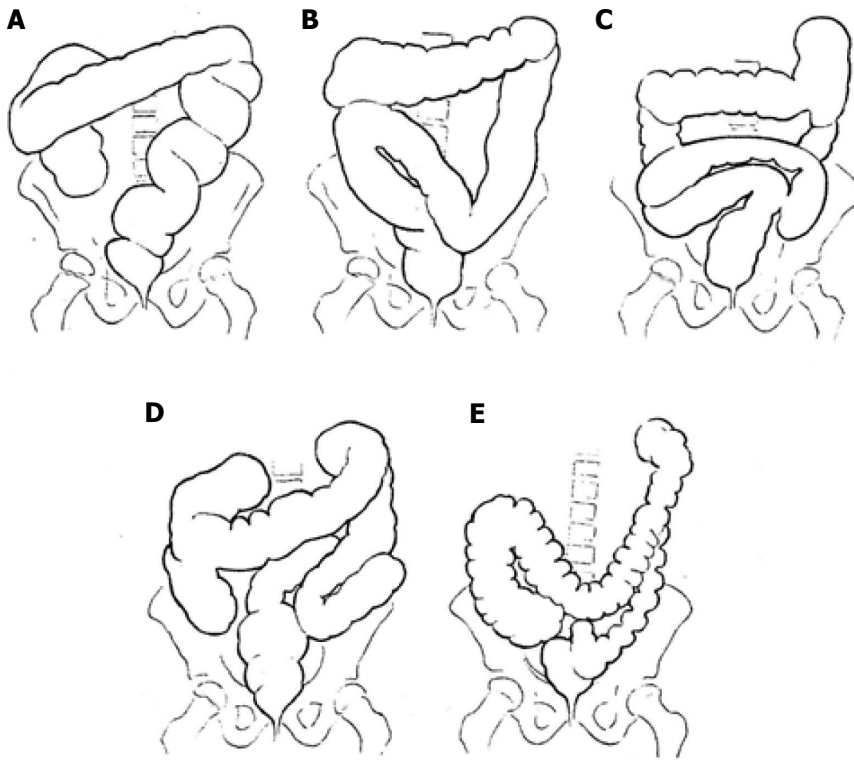


Figure 2 Different types of dolichocolon. A-C: Redundancies in the sigmoid; D: Generalized redundancies; E: Low transverse colon. From Caffey^[16], 1961.

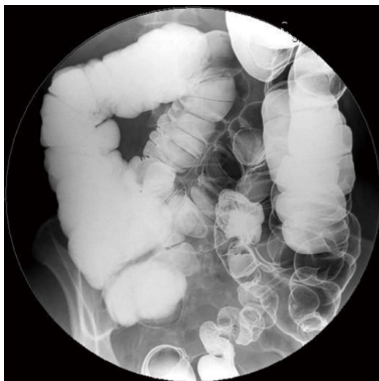

Figure 3 Barium enema showing a fully developed dolichocolon: A sigmoid loop rising over the line between the iliac crests, a transverse colon below the same line and extra loops at the flexures.

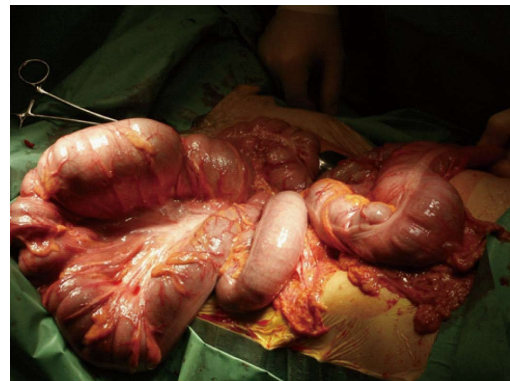


Figure 4 Dolichocolon with loose mesenteries allowing the colon to be drawn out of the abdomen: The transverse colon is localized at the right, and the sigmoid loop at the left.

levels of antibacterial antibodies, and a tendency towards elevated concentrations of IgG, IgM, and circulating immune complexes, provide evidence of the stimulation of systemic cellular and humoral immunity in chronic constipation^[31].

An elongated colon is often associated with a failure of agglutination of the mesentery with the parietal peritoneum. Consequently, the elongated colon is not fixed to the dorsal wall and can swing free on a long mesentery (Figure 4), and loose redundant loops have a potential risk of volvulus.

FUNCTION OF A REDUNDANT COLON

Information to the function of a redundant colon is

scarce. Atony and a weak muscular tone may be limited to the site of the redundancy^[14] or dysfunction may be the result of derangement of the autonomous intestinal nervous system^[32]. Kantor^[19] suggested that constipation varies directly with colon length, and Metcalf *et al*^[33] later stated that transit is largely proportional to the length and volume of a colon segment. In an overview, Müller-Lissner *et al*^[34] stated that, although a long colon could prolong stool residence time, no studies have correlated colonic transit time with colon length. Subsequently, Raahave *et al*^[17] demonstrated that the mean colon transit time was 36.26 h in patients without redundancies, 43.80 h in those with one redundancy, 41.65 h in those with two redundancies, and 52.27 h in those with three to

four redundancies. The mean colon transit time of 44 controls was 24.75 h. The difference in colon transit time between the four levels of redundancies was significant. Abdominal pain, bloating, and infrequent defecation increased significantly with an increased number of redundancies. A separate analysis found a significant positive correlation between colon transit time and fecal load and a redundant sigmoid colon.

In studies of patients undergoing subtotal colectomy for slow transit constipation, the majority of colon specimens were significantly redundant^[35-38]. Colon transit time is meant to be a measure of the speed of fecal propulsion through the colon, and an even distribution of radiopaque markers suggests the same function of all parts of the colon, including redundancies. Possible reasons for dysmotility are disorders of the enteric nervous system, neuroendocrine system or brain-gut axis, including lack of interstitial cells of Cajal^[39].

DIAGNOSIS OF DOLICHOCOLON

A redundant colon should be suspected in patients with constipation, abdominal pain, distension and seldom defecation, especially when symptoms have been present from childhood. However, these symptoms may also come from pure functional colonic disorders, which is why many patients with dolichocolon have not received a diagnosis. A colon transit study and a barium enema or CT-colonography is needed to confirm the diagnosis. This is essential in guiding therapy.

TREATMENT OF CONSTIPATION

From the very beginning, chronic constipation was suggested to be treated with enemas, mineral oil, other laxatives, abdominal massage, a supporting corset, and eventually sedatives^[4,10,11]. Murray^[40] focused on diet and advocated cereals containing husk, as well as the use of salads, raw fruits and vegetables, that grow above the ground. Large quantities of water must be taken, and moderate use of weak tea and coffee is allowed, but no alcoholic beverages. The colonic content was lubricated with oil and a tincture of belladonna given three times a day to increase the intestinal tone. In addition, abdominal electrotherapy was used over the abdomen, just as an afternoon siesta took place since the patients tire very easily. Short walks were advised as exercise. A mild sedative was eventually added^[14]. The intervention was discontinued, when the function of the colon was restored, except the retention enema with oil and high residue diet may be more or less a permanent part of the regimen. The majority of patients with a redundant colon who are given this treatment will then return to a state of approximate well-being. In the subsequent years, most authors agreed with these principles^[23,29,32,41]. A gap of interest in redundant colon then followed for nearly half a century. In general, redundancy of the colon was regarded as an unimportant observation.

Redundant colon is not mentioned in a European Perspective of Diagnosis and Treatment of Chronic Constipation^[42] or in the current American Gastroenterological Association Medical Position Statement on Constipation^[43]. This is a surprise, considering existing knowledge. Patients with constipation disorders and a redundant colon have had improvements in their quality of life by a fiber-rich diet supplemented with husk, sufficient water intake, a prokinetic drug, and physical activity^[39]. Apart from the prokinetic drug, current treatment resembles the regimen of a hundred years ago.

SURGERY FOR DOLICHOCOLON

Immediate surgery was advocated when a sigmoid loop is twisted (volvulus)^[11,20,23,29,41]. In this context, it is notable that sigmoid volvulus accounts for a disproportionally high number of cases of intestinal obstruction in developing countries such as Africa (20%-45%) compared to developed countries (1%-7%). In addition, sigmoid volvulus occurs in much younger patients^[44]. Today, it will first be tried to straighten out the twisted loop by an endoscopic maneuver. If this fails, acute surgery is necessary.

Most authors advise against surgery for dolichocolon^[11,19,23,32,41]. Lane^[30] introduced colectomy for chronic constipation with a death rate of 20.5%, but without giving any information with regard to colon anatomy among 39 patients. Subtotal colectomy for a redundant colon was mentioned as a possibility in 1914^[10]. However, resection of colonic segments was performed with satisfactory results in five cases^[45] and without improvement in three cases^[13]. In 1960, Davis^[46] presented the results of 14 children operated on for symptomatic dolichocolon resistant to conservative treatment. No failures occurred, and the results were excellent in eight patients, good in three, and fair in three. Hollender^[25] reported good functional results after various colonic resections in 11 patients with dolichocolon. In other studies of patients who underwent subtotal colectomy for slow transit constipation, the majority of colon specimens were significantly redundant^[35-37].

In 15 patients, the cause of constipation was slow colonic transit, which was associated with dolichocolon^[28]. After hemicolectomy or colectomy, the patients received daily evacuations and experienced less pain. Recently 31 patients with slow transit constipation and a dolichocolon underwent colectomy^[38]. At follow-up, most patients reported daily defecation and no uncontrolled diarrhea. Abdominal pain was very seldom and patient satisfaction high.

FUTURE PERSPECTIVES

The prevalence of dolichocolon is not known, because population based investigations have not been made. However, in projects with colonoscopic screening for cancer it may be possible to estimate the number and

localization of colonic redundancies. Colorectal length may be determined by magnetic resonance imaging or by tracking the progression of an electromagnetic capsule^[47]. It will hopefully then be possible to determine the prevalence of dolichocolon and a causal relationship to constipation and volvulus.

CONCLUSION

Dolichocolon is an anatomic variant with redundancies of the colonic segments and flexures. The diagnosis is established by barium enema or CT-colonography. Accumulating data from 200 years shows dolichocolon is congenital and causes constipation. Treatment is conservative, and only patients refractive to this therapy may undergo a subtotal colectomy. A redundant loop may cause volvulus, requiring an endoscopic maneuver or surgery. Future research has to show the prevalence of dolichocolon in a population and to determine whether it always gives rise to constipation.

ACKNOWLEDGEMENTS

The author is thankful to Jette Meelby, librarian, The Library of Health Sciences, Hilleroed Hospital for retrieving ancient articles, which made the study possible.

REFERENCES

- 1 **Langman J.** Medical embryology. 3rd ed. Baltimore: The Williams & Wilkins Company, 1975
- 2 **Monterossi P.** Über widernatürliche Biegungen des Dickdarms als Uhrförmige des Todes neugeborener Kinder. *Deutsch Arch Physiol* 1820; **6**: 556-571
- 3 **Treves F.** Lectures on the Anatomy of the Intestinal Canal and Peritoneum in Man. *Br Med J* 1885; **1**: 415-419 [PMID: 20751176 DOI: 10.1136/bmj.1.1261.415]
- 4 **Shober JB.** Anomalous positions of the colon. *Am J Med Sci* 1898; **116**: 405-419 [DOI: 10.1097/00000441-189810000-00003]
- 5 **Buchanan A.** Fatal cases of the obstruction and enormous distension of the belly. *London Med Gazette* 1839; **2**: 639-644
- 6 **Black CE.** XI. Displacements of the Colon. *Ann Surg* 1912; **56**: 888-899 [PMID: 17862941 DOI: 10.1097/00000658-191212000-00011]
- 7 **Bryant J.** Observations upon the growth and length of the human intestine. *Am J Med Sci* 1924; **167**: 499-520 [DOI: 10.1097/00000441-192404000-00003]
- 8 **Phillips M,** Patel A, Meredith P, Will O, Brassett C. Segmental colonic length and mobility. *Ann R Coll Surg Engl* 2015; **97**: 439-444 [PMID: 26274737 DOI: 10.1308/003588415X14181254790527]
- 9 **Kienböck R.** Ueber das Sigma elongatum mobile (Röntgenbefund). *Muench Med Wochen* 1913; **60**: 68-70
- 10 **Lardennois G,** Aubourg P. Allongements segmentaires du gros intestin les dolichocolies. *Jour Radiol Electrol* 1914; **1**: 65-74
- 11 **White FW.** The redundant colon. *Med Clin N Am* 1924; **8**: 1611-1633
- 12 **Larimore JW.** The human large intestine in the newborn and in the adult. *Ann Clin Med* 1926; **5**: 439-463
- 13 **Moeller PF.** The redundant colon. *Acta Radiol* 1926; **6**: 432-457 [DOI: 10.1177/028418512600600137]
- 14 **Gauss H.** Redundant colon. *Arch Surg* 1927; **15**: 560-579 [DOI: 10.1001/archsurg.1927.01130220063005]
- 15 **Kantor JL.** Anomalies of the colon: Their roentgen diagnosis and clinical significance. *Radiology* 1934; **23**: 651-662 [DOI: 10.1148/23.6.651]
- 16 **Caffey J.** Pediatric X-ray diagnosis. 4th ed. Chicago: Year Book Medical Publishers, 1961
- 17 **Raahave D,** Christensen E, Loud FB, Knudsen LL. Correlation of bowel symptoms with colonic transit, length, and faecal load in functional faecal retention. *Dan Med Bull* 2009; **56**: 83-88 [PMID: 19486620]
- 18 **Hanson ME,** Pickhardt PJ, Kim DH, Pfau PR. Anatomic factors predictive of incomplete colonoscopy based on findings at CT colonography. *AJR Am J Roentgenol* 2007; **189**: 774-779 [PMID: 17885044 DOI: 10.2214/AJR.07.2048]
- 19 **Kantor JL.** Common anomalies of the duodenum and colon: Their practical significance. *JAMA* 1931; **97**: 1785-1790 [DOI: 10.1001/jama.1931.02730240035008]
- 20 **Galambos A,** Galambos WM. Redundancy of the colon. *Am J Dig Dis* 1946; **13**: 87-101 [PMID: 21022340 DOI: 10.1007/BF03002757]
- 21 **Brunner P,** Seppälä P, Wegelius U. Redundant colon as a cause of constipation. *Gut* 1962; **3**: 140-141 [DOI: 10.1136/gut.3.2.140]
- 22 **Heredia DJ,** Dickson EJ, Bayguinov PO, Hennig GW, Smith TK. Colonic elongation inhibits pellet propulsion and migrating motor complexes in the murine large bowel. *J Physiol* 2010; **588**: 2919-2934 [PMID: 20547675 DOI: 10.1113/jphysiol.2010.191445]
- 23 **Friedenwald J,** Feldman M. Clinical observations on the redundant colon (dolichocolon). *South Med J* 1934; **27**: 147-154 [DOI: 10.1097/00007611-193402000-00010]
- 24 **Yik YI,** Cook DJ, Veysey DM, Tudball CF, Cain TM, Southwell BR, Hutson JM. How common is colonic elongation in children with slow-transit constipation or anorectal retention? *J Pediatr Surg* 2012; **47**: 1414-1420 [PMID: 22813806 DOI: 10.1016/j.jpedsurg.2012.01.007]
- 25 **Hollender LF,** Muller AM, Viville C, Santizo G. [Dolichocolon in adults: surgical indications]. *Acta Gastroenterol Belg* 1965; **28**: 550-567 [PMID: 5844749]
- 26 **Kantor JL.** A clinical study of common anatomical abnormalities of the colon. I. The redundant colon. *Am J Roentgenol Soc* 1924; **12**: 414-430
- 27 **Tomita R,** Howard ER. Clinical studies on anorectal myectomy for chronically constipated patients with outlet obstruction in childhood. *Hepatogastroenterology* 2008; **55**: 1600-1605 [PMID: 19102350]
- 28 **Ripetti V,** Caputo D, Greco S, Alloni R, Coppola R. Is total colectomy the right choice in intractable slow-transit constipation? *Surgery* 2006; **140**: 435-440 [PMID: 16934606 DOI: 10.1016/j.surg.2006.02.000]
- 29 **White FW.** Studies of the redundant colon. *N Engl J Med* 1928; **198**: 783-787 [DOI: 10.1056/NEJM192805311981501]
- 30 **Lane WA.** Remarks on the results of the operative treatment of chronic constipation. *Br Med J* 1908; **1**: 126-130 [PMID: 20763645 DOI: 10.1136/bmj.1.2455.126]
- 31 **Khalif IL,** Quigley EM, Konovitch EA, Maximova ID. Alterations in the colonic flora and intestinal permeability and evidence of immune activation in chronic constipation. *Dig Liver Dis* 2005; **37**: 838-849 [PMID: 16169298 DOI: 10.1016/j.dld.2005.06.008]
- 32 **LaRochelle FD,** Smith EE. The dolichocolon. *Radiology* 1932; **18**: 1111-1114 [DOI: 10.1148/18.6.1111]
- 33 **Metcalfe AM,** Phillips SF, Zinsmeister AR, MacCarty RL, Beart RW, Wolf BG. Simplified assessment of segmental colonic transit. *Gastroenterology* 1987; **92**: 40-47 [DOI: 10.1016/0016-5085(87)90837-7]
- 34 **Müller-Lissner SA,** Kamm MA, Scarpignato C, Wald A. Myths and misconceptions about chronic constipation. *Am J Gastroenterol* 2005; **100**: 232-242 [PMID: 15654804 DOI: 10.1111/j.1572-0241.2005.40885.x]
- 35 **Lux N,** Athanasiadis S, Fischbach N, Meyer B. Funktionelle Ergebnisse nach subtotaler und partieller Colectomie bei der therapieresistenten chronischen Obstipation. *Chirurg* 1992; **68**: 739-747
- 36 **Webster C,** Dayton M. Results after colectomy for colonic inertia: a sixteen-year experience. *Amer J Surg* 2001; **182**: 639-644 [DOI: 10.1054/aj.2001.31826

- 10.1016/S0002-9610(01)00820-0]
- 37 **Lundin E**, Karlbom U, Pählman L, Graf W. Outcome of segmental colonic resection for slow-transit constipation. *Br J Surg* 2002; **89**: 1270-1274 [PMID: 12296895 DOI: 10.1046/j.1365-2168.2002.02213.x]
 - 38 **Raahave D**, Loud FB, Christensen E, Knudsen LL. Colectomy for refractory constipation. *Scand J Gastroenterol* 2010; **45**: 592-602 [PMID: 20408774 DOI: 10.3109/00365521003587796]
 - 39 **Raahave D**. Faecal retention: a common cause in functional bowel disorders, appendicitis and haemorrhoids--with medical and surgical therapy. *Dan Med J* 2015; **62**: pii B5031 [PMID: 25748875]
 - 40 **Murray RS**. Redundant colon. *J Tenn Med Ass* 1925; **18**: 37-43
 - 41 **Kantor JL**. The common affections of the colon, their origin and their management. *Bull NY Acad Med* 1928; **4**: 757-788
 - 42 **Tack J**, Müller-Lissner S, Stanghellini V, Boeckxstaens G, Kamm MA, Simren M, Galmiche JP, Fried M. Diagnosis and treatment of chronic constipation--a European perspective. *Neurogastroenterol Motil* 2011; **23**: 697-710 [PMID: 21605282 DOI: 10.1111/j.1365-2982.2011.01709.x]
 - 43 **American Gastroenterological Association**, Bharucha AE, Dorn SD, Lembo A, Pressman A. American Gastroenterological Association medical position statement on constipation. *Gastroenterology* 2013; **144**: 211-217 [PMID: 23261064 DOI: 10.1053/j.gastro.2012.10.029]
 - 44 **Madiba TE**, Haffajee MR. Sigmoid colon morphology in the population groups of Durban, South Africa, with special reference to sigmoid volvulus. *Clin Anat* 2011; **24**: 441-453 [PMID: 21480385 DOI: 10.1002/ca.21100]
 - 45 **Slesinger EG**. Elongation of the pelvic colon and its surgical treatment. *Lancet* 1926; **2**: 274-275
 - 46 **Davis DA**. A new concept in the treatment of symptomatic redundant colon or dolichocolon. *West J Surg Gynecol* 1960; **68**: 101-106
 - 47 **Mark EB**, Poulsen JL, Haase AM, Frøkjær JB, Schlageter V, Scott SM, Krogh K, Drewes AM. Assessment of colorectal length using the electromagnetic capsule tracking system: a comparative validation study in healthy subjects. *Colorectal Dis* 2017; **19**: O350-O357 [PMID: 28688203 DOI: 10.1111/codi.13810]

P- Reviewer: Maric I, Shah OJ, Sukocheva OA **S- Editor:** Song XX
L- Editor: A **E- Editor:** Yan JL





Published by **Baishideng Publishing Group Inc**

8226 Regency Drive, Pleasanton, CA 94588, USA

Telephone: +1-925-223-8242

Fax: +1-925-223-8243

E-mail: bpgoffice@wjgnet.com

Help Desk: <http://www.wjgnet.com/esps/helpdesk.aspx>

<http://www.wjgnet.com>

