

World Journal of *Orthopedics*

World J Orthop 2018 April 18; 9(4): 60-71



**MINIREVIEWS**

- 60 Why total knees fail-A modern perspective review
Lum ZC, Shieh AK, Dorr LD

ORIGINAL ARTICLE**Basic Study**

- 65 Snapping elbow-A guide to diagnosis and treatment
Bjerre JJ, Finn Johannsen E, Rathcke M, Krogsgaard MR

Contents

World Journal of Orthopedics
Volume 9 Number 4 April 18, 2018

ABOUT COVER

Editorial Board Member of *World Journal of Orthopedics*, Wing-Hoi Cheung, BSc, PhD, Associate Professor, Department of Orthopaedics and Traumatology, The Chinese University of Hong Kong, Hong Kong, China

AIM AND SCOPE

World Journal of Orthopedics (*World J Orthop*, *WJO*, online ISSN 2218-5836, DOI: 10.5312) is a peer-reviewed open access academic journal that aims to guide clinical practice and improve diagnostic and therapeutic skills of clinicians.

WJO covers topics concerning arthroscopy, evidence-based medicine, epidemiology, nursing, sports medicine, therapy of bone and spinal diseases, bone trauma, osteoarthropathy, bone tumors and osteoporosis, minimally invasive therapy, diagnostic imaging. Priority publication will be given to articles concerning diagnosis and treatment of orthopedic diseases. The following aspects are covered: Clinical diagnosis, laboratory diagnosis, differential diagnosis, imaging tests, pathological diagnosis, molecular biological diagnosis, immunological diagnosis, genetic diagnosis, functional diagnostics, and physical diagnosis; and comprehensive therapy, drug therapy, surgical therapy, interventional treatment, minimally invasive therapy, and robot-assisted therapy.

We encourage authors to submit their manuscripts to *WJO*. We will give priority to manuscripts that are supported by major national and international foundations and those that are of great basic and clinical significance.

INDEXING/ABSTRACTING

World Journal of Orthopedics is now indexed in Emerging Sources Citation Index (Web of Science), PubMed, PubMed Central and Scopus.

EDITORS FOR THIS ISSUE

Responsible Assistant Editor: *Xiang Li*
Responsible Electronic Editor: *Wen-Wen Tan*
Proofing Editor-in-Chief: *Lian-Sheng Ma*

Responsible Science Editor: *Li-Jun Cui*
Proofing Editorial Office Director: *Ya-Juan Ma*

NAME OF JOURNAL
World Journal of Orthopedics

ISSN
ISSN 2218-5836 (online)

LAUNCH DATE
November 18, 2010

FREQUENCY
Monthly

EDITORS-IN-CHIEF
Quanjun (Trey) Cui, MD, Professor, Department of Orthopaedic Surgery, School of Medicine, University of Virginia, Charlottesville, VA 22908, United States

Bao-Gan Peng, MD, PhD, Professor, Department of Spinal Surgery, General Hospital of Armed Police Force, Beijing 100039, China

EDITORIAL BOARD MEMBERS
All editorial board members resources online at <http://www.wjgnet.com>

www.wjgnet.com/2218-5836/editorialboard.htm

EDITORIAL OFFICE
Xiu-Xia Song, Director
World Journal of Orthopedics
Baishideng Publishing Group Inc
7901 Stoneridge Drive, Suite 501, Pleasanton, CA 94588, USA
Telephone: +1-925-2238242
Fax: +1-925-2238243
E-mail: editorialoffice@wjgnet.com
Help Desk: <http://www.fgpublishing.com/helpdesk>
<http://www.wjgnet.com>

PUBLISHER
Baishideng Publishing Group Inc
7901 Stoneridge Drive,
Suite 501, Pleasanton, CA 94588, USA
Telephone: +1-925-2238242
Fax: +1-925-2238243
E-mail: bpgoffice@wjgnet.com
Help Desk: <http://www.fgpublishing.com/helpdesk>
<http://www.wjgnet.com>

PUBLICATION DATE
April 18, 2018

COPYRIGHT
© 2018 Baishideng Publishing Group Inc. Articles published by this Open-Access journal are distributed under the terms of the Creative Commons Attribution Non-commercial License, which permits use, distribution, and reproduction in any medium, provided the original work is properly cited, the use is non commercial and is otherwise in compliance with the license.

SPECIAL STATEMENT
All articles published in journals owned by the Baishideng Publishing Group (BPG) represent the views and opinions of their authors, and not the views, opinions or policies of the BPG, except where otherwise explicitly indicated.

INSTRUCTIONS TO AUTHORS
<http://www.wjgnet.com/bpg/gerinfo/204>

ONLINE SUBMISSION
<http://www.fgpublishing.com>

Basic Study

Snapping elbow-A guide to diagnosis and treatment

Jonathan Jetsmark Bjerre, Finn Elkjær Johannsen, Martin Rathcke, Michael Rindom Krogsgaard

Jonathan Jetsmark Bjerre, Martin Rathcke, Michael Rindom Krogsgaard, Section for Sportstraumatology M51, Bispebjerg-Frederiksberg Hospital, Copenhagen NV DK-2400, Denmark

Finn Elkjær Johannsen, Institute for Sportsmedicine M81, Bispebjerg-Frederiksberg Hospital, Copenhagen NV DK-2400, Denmark

ORCID number: Jonathan Jetsmark Bjerre (0000-0002-6477-3219); Finn Elkjær Johannsen (0000-0002-3732-6229); Martin Rathcke (0000-0002-5629-7371); Michael Rindom Krogsgaard (0000-0002-9976-4865).

Author contributions: Rathcke M and Krogsgaard MR designed the study; Johannsen FE and Rathcke M recorded the case stories; Bjerre JJ did the literature analyses; Bjerre JJ and Krogsgaard MR wrote the paper.

Institutional review board statement: The project was considered a register research project by Danish Committee System on Health Research Ethics.

Conflict-of-interest statement: None of the authors have any proprietary interests in the materials described in the article.

Data sharing statement: Not applicable.

Open-Access: This article is an open-access article which was selected by an in-house editor and fully peer-reviewed by external reviewers. It is distributed in accordance with the Creative Commons Attribution Non Commercial (CC BY-NC 4.0) license, which permits others to distribute, remix, adapt, build upon this work non-commercially, and license their derivative works on different terms, provided the original work is properly cited and the use is non-commercial. See: <http://creativecommons.org/licenses/by-nc/4.0/>

Manuscript source: Invited manuscript

Correspondence to: Michael Rindom Krogsgaard, MD, PhD, Professor, Surgeon, Section for Sportstraumatology M51, Bispebjerg-Frederiksberg Hospital, Bispebjerg Bakke 23, Copenhagen NV DK-2400, Denmark. michael.rindom.krogsgaard@regionh.dk
Telephone: +45-31226817

Received: November 11, 2017

Peer-review started: November 11, 2017

First decision: December 11, 2017

Revised: December 21, 2017

Accepted: March 1, 2018

Article in press: March 2, 2018

Published online: April 18, 2018

Abstract

AIM

To develop practical guidelines for diagnosis and treatment of the painful snapping elbow syndrome (SE).

METHODS

Clinical studies were searched in the databases PubMed and Scopus for the phrases "SE", "snapping triceps", "snapping ulnar nerve" and "snapping annular ligament". A total of 36 relevant studies were identified. From these we extracted information about number of patients, diagnostic methods, patho-anatomical findings, treatments and outcomes. Practical guidelines for diagnosis and treatment of SE were developed based on analysis of the data. We present two illustrative patient cases-one with intra-articular pathology and one with extra-articular pathology.

RESULTS

Snapping is audible, palpable and often visible. It has a lateral (intra-articular) or medial (extra-articular) pathology. Snapping over the medial humeral epicondyle is caused by dislocation of the ulnar nerve or a part of the triceps tendon, and is demonstrated by dynamic ultrasonography. Treatment is by open surgery. Lateral snapping over the radial head has an intra-articular pathology: A synovial plica, a torn annular ligament or a meniscus-like remnant from the foetal elbow. Pathology can be visualized by conventional arthrography, magnetic resonance (MR) arthrography, high resolution magnetic resonance imaging (MRI) and arthroscopy, while conventional MRI and radiographs often turn out normal. Treatment is by arthroscopic or eventual open resection. Early surgical intervention is recommended as

the snapping can damage the ulnar nerve (medial) or the intra-articular cartilage (lateral). If medial snapping only occurs during repeated or loaded extension/flexion of the elbow (in sports or work) it may be treated by reduction of these activities. Differential diagnoses are loose bodies (which can be visualized by radiographs) and postero-lateral instability (demonstrates by clinical examination). An algorithm for diagnosis and treatment is suggested.

CONCLUSION

The primary step is establishment of laterality. From this follows relevant diagnostic measures and treatment as defined in this guideline.

Key words: Elbow; Arthroscopy; Surgery; Diagnosis; Ultrasonography; Snapping

© **The Author(s) 2018.** Published by Baishideng Publishing Group Inc. All rights reserved.

Core tip: Elbow snapping is medial or lateral. Medial snapping is caused by dislocation of the ulnar nerve or a part of the triceps tendon, demonstrated clinically and by dynamic ultrasonography. Treatment is transposition of the nerve and/or resection of the snapping tendon. Lateral snapping is intra-articular by a synovial plica, a torn annular ligament or a meniscus-like remnant from the foetal elbow, demonstrated by arthrography, magnetic resonance arthrography, high resolution magnetic resonance imaging or arthroscopy. Treatment is arthroscopic resection. Early surgical intervention is recommended to reduce tissue damage. Medial snapping promoted by repeated, loaded activities might be treated by activity reduction.

Bjerre JJ, Finn Johannsen E, Rathcke M, Krogsgaard MR. Snapping elbow-A guide to diagnosis and treatment. *World J Orthop* 2018; 9(4): 65-71 Available from: URL: <http://www.wjgnet.com/2218-5836/full/v9/i4/65.htm> DOI: <http://dx.doi.org/10.5312/wjo.v9.i4.65>

INTRODUCTION

Snapping elbow (SE) is a rare condition, which can be confused with more common pathologies like an intra-articular free body, lateral epicondylitis or medial epicondylitis. Symptoms from SE occur during dynamic activities. Therefore, standard radiographs and magnetic resonance imaging (MRI) are often normal, leaving risk that the condition remains undiagnosed.

It is useful to distinguish between lateral and medial snapping, as pathology, diagnostic strategy and treatment are different in the two situations.

We suggest a practical guideline for diagnosis and treatment of SE, based on our own experience with three elbows in two patients and a review of the literature.

MATERIALS AND METHODS

Literature was searched in Pubmed with four phrases: "SE" (resulting in 85 hits), "snapping triceps" (39 hits), "snapping ulnar nerve" (31 hits) and "snapping annular ligament" (9 hits). A similar search was performed in Scopus, and two additional, relevant articles were identified. We excluded papers that had no information about diagnostic strategy or treatment as well as articles in other languages than English or Scandinavian.

One article was not available online or from the author.

From the 36 remaining articles (Figure 1) information about number of patients, diagnostic method, patho-anatomical findings, treatments and outcomes was extracted.

We treated two cases with principally different reasons for snapping.

Case reports 1

A 16-year-old boy with painful locking of the right elbow during 2-3 years. No trauma in history. Standard MR scanning and radiographs were normal. A sore clicking was found at the lateral epicondyle with 80°-90° of elbow flexion, and it was most painful with simultaneous pronation. He had similar but milder symptoms on the left side. Both elbows were stable and with normal range of motion.

Dynamic ultrasound raised suspicion of a tight, lateral part of the triceps tendon as the cause of snapping. However, extraarticular injection of 1 cc Carbocain plus 1 cc of Depomedrol® in this area did not relieve the symptoms.

At arthroscopy an inter-positioned lunar plica antero-laterally (video 1) was resected, and a tight chord of capsule in relation to the plica was loosened.

Pain and snapping disappeared after the operation. A similar condition was treated by arthroscopy in the left elbow 6 wk later. At 3-years follow-up he felt a slight tenderness in the right elbow from time to time, but it was different from his preoperative pain and he had no snapping. The left elbow was symptom free.

Case reports 2

A 16-year-old boy with painful medial elbow clicking bilaterally for over a year, in particular during heavy resistance training of the triceps muscle. The snapping was mildly painful, but he had post-exercise pain that forced him to reduce the training load. Popping of the triceps muscle over the medial epicondyle at 110° of flexion was suspected by clinical examination (video 2). There were no neurological symptoms and a negative Tinel's test in relation to the ulnar nerve. Dynamic sonography visualized the popping tissue (video 3), but it was not possible to distinguish if this originated from the ulnar nerve or a part of the triceps tendon. The elbow appeared otherwise normal.

Open surgery showed that snapping was caused by

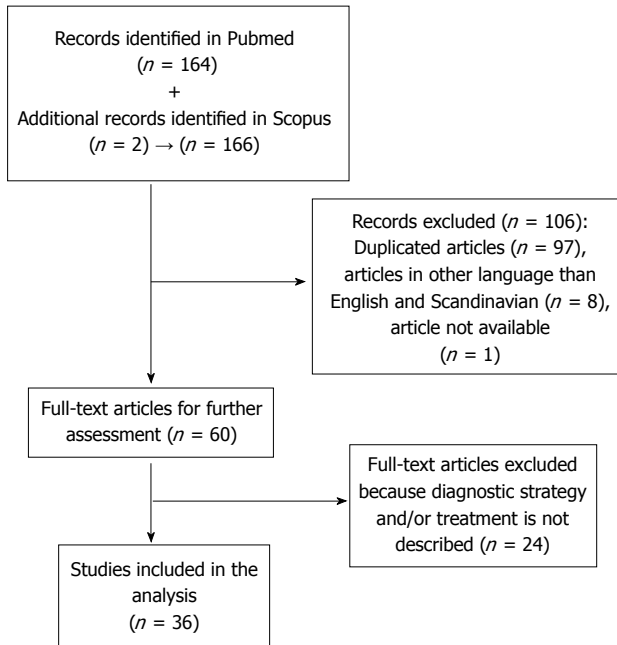


Figure 1 From the 36 remaining articles information about number of patients, diagnostic method, patho-anatomical findings, treatments and outcomes was extracted.

dislocation of the ulnar nerve (video 4). The sulcus was therefore deepened 3 mm, the nerve was repositioned, and a part of the medial triceps tendon was transpositioned to form a cover over the sulcus. This resolved the snapping condition, and the patient was able to exercise normally between two and five months postoperatively. Then a feeling of instability of the nerve during heavy resistance training occurred, but it was pain free. One year after the operation he stopped regular training and had no symptoms. This was still the case at 3-years follow-up. Both patients declared, that they were satisfied with the treatment, and with their present experience they would agree to be operated for SE again, if necessary.

RESULTS

The identified clinical reports of SE are summarized in the tables. They are divided into lateral, intra-articular cases (Table 1) and medial, extra-articular cases (Table 2) of SE. There are 105 cases of lateral snapping with a mean age of 39.7 years (range 11-66) and 42 cases of medial snapping with a mean age of 28.7 years (range 9-65). In some patients SE was presumably triggered by athletic performance (throwing and tennis typical for lateral snapping, and weightlifting, decathlon and dumbbell exercises for medial snapping). However, the majority of cases could not be connected to sports.

This review does not allow to make an estimate of the incidence of SE, but based on the reported cases, the different pathologies can be ranked with intraarticular plica as the most common, followed by medially snapping triceps (rare), snapping ulnar nerve (rare), snapping annular ligament (very rare)

and extremely rare pathologies: snapping medial antebrachial cutaneous nerve, intraarticular meniscus and laterally snapping triceps.

Intra-articular, lateral snapping

Intra-articular snapping is caused by annular ligament pathology, lateral meniscal remnants or hypertrophic synovial plicae^[1-12]. Clicking due to dynamic impingement of these soft tissues is difficult to demonstrate with static MRI.

Three reports describe snapping caused by anomalous meniscal remnants^[5,7]. Standard MRI did not reveal the pathology, but it was demonstrated by MRI- and radiographic arthrography, respectively.

In one report a plica was demonstrated by radiographic arthrography and MRI as a protruding shadow^[11]. Contrast MRI was used to diagnose three cases of a snapping plica^[10]. In one case conventional MRI raised suspicion of a small, pathological structure, which was diagnosed as a plica by high-resolution MRI^[13].

By conventional MRI it was in most cases not possible to visualize lateral SE pathology, and diagnoses were established with MR-arthrography, high resolution MRI or radiographic arthrography. With arthroscopy the intra-articular snapping pathology can be visualized and treated in the same procedure by resection of the snapping tissue.

Arthroscopic resection of plicae or meniscus-like tissues was standard treatment, except in three cases of open resection. Reported results were good with either method (Table 1), as elbow function normalized in the majority of cases.

One patient who had postero-lateral rotatory elbow instability did not improve, but the snapping might have been caused by instability and not by intra-articular pathology^[2].

Extra-articular, medial snapping

Subluxation of either the ulnar nerve or a medial part of the triceps tendon, or of both can cause extra-articular snapping of the elbow^[15-26]. In many cases it can be recognized by thorough physical examination. The ulnar nerve snaps in the interval 70-90 degrees of flexion, and the triceps around 115 degrees. These snaps are usually visible and audible^[27]. By dynamic ultrasound and dynamic MRI^[28] the snapping tissue can be visualized, but interpretation of the anatomical structures is not always conclusive, as described in our case 2^[20,27,28]. Dislocation of the snapping structure is not visible on standard MRI with the elbow extended, but with the elbow flexed dislocation can often be demonstrated^[29].

A snapping triceps can be treated by either resection^[19,22-23,25,30-34] or by suture of the snapping part to the main tendon^[18,25]. Medial epicondylectomy was used in one case^[19]. Ulnar nerve dislocation was treated by anterior transposition^[16,26,35] or fixation of the nerve in the deepened cubital tunnel^[35].

Table 1 Literature reports on intra-articular snapping elbow

Report and year	No. of patients	Snapping Pathology	Diagnostic procedure	Treatment	Results
Akagi <i>et al</i> ^[1] , 1998	One	Snapping plica	Arthrogram, arthroscopy	Open arthrotomy	Complete recovery
Antuna <i>et al</i> ^[2] , 2001	Fourteen	Snapping plica	MRI, arthroscopic examination	Arthroscopic resection	Ten complete recoveries, two partial recoveries, two failures
Aoki <i>et al</i> ^[3] , 2003	Two	Snapping annular ligament	Arthroscopic examination	One had arthroscopic resection	One complete recovery after resection
Chai <i>et al</i> ^[4] , 2004	One	Snapping annular ligament	Ultrasonography	Arthroscopic resection	Relief of snapping
Fukase <i>et al</i> ^[13] , 2005	One	Snapping plica	Special MRI ¹	Open resection	Complete recovery
Huang <i>et al</i> ^[5] , 2005	One	Snapping meniscus	MR arthrography	Arthroscopic resection	Complete recovery
Huang <i>et al</i> ^[6] , 2005	One	Snapping annular ligament	MRI, arthroscopic examination	Arthroscopic resection	Relief of snapping, less pain
Kang <i>et al</i> ^[7] , 2010	Two	Snapping meniscus	MRI, arthrography	Arthroscopic resection	Complete recovery
Maruyama <i>et al</i> ^[8] , 2010	One	Snapping annular ligament	Arthroscopy	Arthroscopic release of the ligament	Complete recovery
Brahe Pedersen <i>et al</i> ^[9] , 2017	Sixtyfour	Hypertrophic synovial plica	Clinical examination and ultrasound	Arthroscopic resection	Significant improvement in Oxford Elbow score after 3 and 22 mo
Shinohara <i>et al</i> ^[14] , 2010	One	Tight fibrous structure	MRI, arthroscopy	Arthroscopic resection	Complete recovery
Steinert <i>et al</i> ^[10] , 2008	Three	Hypertrophic synovial plica	Contrast MRI (in two), arthroscopy	Arthroscopic resection	Complete recovery
Tateishi <i>et al</i> ^[11] , 2005	One	Snapping plica	MRI, arthrogram	Open resection	Complete recovery

¹Special MRI was high-resolution magnetic resonance imaging of the elbow using microscopy coils. MRI: Magnetic resonance imaging; MR: Magnetic resonance.

One case series reported snapping of the medial antebrachial cutaneous nerve^[35] that is medial to the medial humeral condyle (and not posterior as the ulnar nerve). There were no neurological symptoms reported from this nerve, and snapping was observed intra-operatively. In three of the four patients there was also snapping of triceps and the ulnar nerve. In retrospective review of the preoperative ultrasonography investigations, snapping of the medial antebrachial cutaneous nerve could be identified. In three patients the medial antebrachial cutaneous nerve was transpositioned and in one it was decompressed, while triceps- and ulnar nerve dislocation was also treated in three.

The most common symptoms were pain and painful snapping, and neurological symptoms from the ulnar nerve were rarely reported.

DISCUSSION

It is useful to divide snapping of the elbow joint into lateral and medial snapping, as these are caused by different pathological conditions and can easily be distinguished clinically (Figure 2).

Generally, intra-articular snapping pathology cannot be demonstrated by conventional MRI, and MR-arthrography, high resolution MRI or radiographic arthrography is necessary^[1,6,9,13].

In a series with 14 patients treated for lateral, intra-articular plicas snapping over the radial head by arthroscopic resection^[2], ten patients were completely relieved of their symptoms, two still experienced mild pain and one was asymptomatic for 4 years, but then

experienced recurrence of symptoms. In one patient treatment failed, but he was subsequently diagnosed with postero-lateral instability as the possible cause of the snapping phenomenon. In the largest series reported^[9] with 64 patients, there was a significant and clinically relevant increase in Oxford Elbow Score three and 22 mo after operation. Therefore, surgical treatment of the lateral SE is successful in the majority of cases, and it should preferably be performed arthroscopically, as this permits optimal visualization of the joint and minimize morbidity. Non-surgical treatment has not been described for lateral SE.

Dynamic ultrasonography is the best to visualize medial snapping, but it can be difficult to identify which anatomic structure that is snapping (as described in case 2)^[20,25,27]. Fabrizio *et al*^[36] reported a variation of the triceps brachii with a thin fourth muscular head inserting on the medial part of the olecranon as a cause of medial snapping. An accessory snapping triceps tendon can clinically be confused with snapping of the ulnar nerve, as the two structures are closely located at the medial epicondyle. Watts described this diagnostic pitfall in a report of three cases^[34], of which two primary had transposition of the ulnar nerve and one a fixation of the nerve in the ulnar sulcus. In all three cases snapping persisted, and the cause was identified as a discrete accessory tendon originating from the triceps. The authors concluded from their series that a subluxing ulnar nerve does not snap, and that medial snapping is always caused by anterior sliding of a strip of the triceps tendon during elbow flexion.

Snapping of a medial part of the triceps muscle is recognized as a reason for continuous snapping after

Table 2 Reports of extra-articular snapping elbow

Report and year	No. of cases	Snapping pathology	Diagnostic procedure	Treatment	Results
Anand <i>et al</i> ^[16] , 2012	One	Snapping ulnar nerve	Open surgery	Transposition of nerve	Complete recovery, returned to elite sport
Cesmehasi <i>et al</i> ^[35] , 2015	Four	Snapping medial antebrachial cutaneous nerve (4), triceps (3) and ulnar nerve (3)	Open surgery/sonography	Open decompression, stabilization or transposition of nerves, resection of tendon	Improvement (mild persistent symptoms to complete recovery)
Chuang <i>et al</i> ^[17] , 2016	One	Snapping triceps and subluxing ulnar nerve	Dynamic sonography	NSAIDs and reduction in repetitive elbow flexion activities at work	Partial improvement
Dreyfuss <i>et al</i> ^[18] , 1978	Two	Snapping triceps	Open reinsertion of the snapping part of the triceps	Reinsertion of the snapping tendon	1 complete recovery, 1 partial
Haws <i>et al</i> ^[30] , 1995	One	Snapping triceps	Open exploration	Open resection of tendon	Complete recovery
Hayashi <i>et al</i> ^[19] , 1984	One	Snapping triceps	Physical examination, radiographs, open surgery	Medial epicondylectomy and division of tendon	Complete recovery
Jacobson <i>et al</i> ^[20] , 2001	Three	Snapping ulnar nerve, snapping triceps	Dynamic sonography	Open “surgical treatment for each abnormality”	Not reported
Lasecki <i>et al</i> ^[21] , 2014	One	Snapping triceps and ulnar nerve	MRI and dynamic sonography	Not reported	Not reported
Minami <i>et al</i> ^[31] , 1999	One	Snapping triceps	Not reported	Open tendon resection	Complete recovery
Reis <i>et al</i> ^[22] , 1980	One	Snapping triceps	Open surgery	Open tendon resection	Complete recovery
Rolfesen ^[23] , 1970	One	Snapping triceps	Open surgery	Open tendon resection	Complete recovery
Spinner <i>et al</i> ^[32] , 2001	One	Snapping triceps	Physical examination	Open tendon Excision	Complete recovery
Spinner <i>et al</i> ^[24] , 1999	Two	Snapping triceps	Physical examination, MRI	Reduction in weight lifting	Symptoms only appeared during weight lifting
Spinner <i>et al</i> ^[33] , 1999	One	Snapping triceps lateral	Palpation and MRI	Open tendon resection	Complete recovery
Spinner <i>et al</i> ^[25] , 2000	Fifteen	Snapping triceps after operation for snapping ulnar nerve	Physical examination, MRI	Lateral transposition or excision of tendon (nine patients), six refused surgery	Complete relief of snapping in surgically treated patients. No relief in non-operated
Watts <i>et al</i> ^[34] , 2009	Three	Snapping triceps	Open exploration	Excision (two), tendon division (one)	Complete recovery
Xarchas <i>et al</i> ^[26] , 2007	Three	Snapping ulnar nerve	Palpation	Anterior nerve transposition (two), NSAIDs and change of job as waitress (one)	Complete recovery after surgery. Not reported for non-surgery

NSAIDs: Non-steroidal anti-inflammatory drugs; MRI: Magnetic resonance imaging.

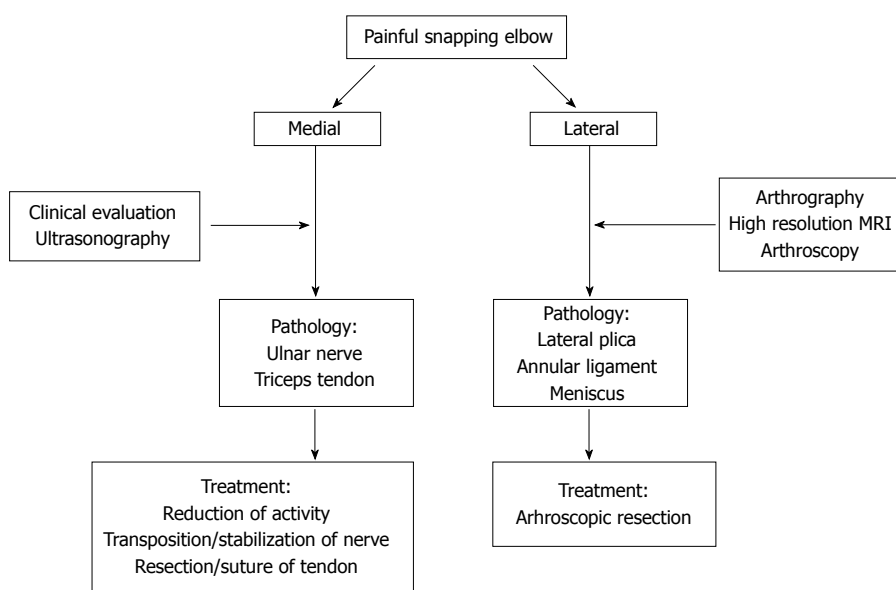


Figure 2 Snapping of the elbow joint into lateral and medial snapping caused by different pathological conditions and can easily be distinguished clinically.

ulnar nerve transposition^[22-23,25,30-32,34]. It is unclear in these cases if the snapping triceps was unrecognised during ulnar nerve surgery or if it was a complication to dissection of the tendon during release of the ulnar nerve. However, we and others present cases of medial snapping, treated successfully by ulnar nerve surgery^[20,26]. Therefore, the triceps should always be inspected in flexion and extension of the elbow during surgery for ulnar nerve snapping.

It is unknown to which extent the medial antebrachial cutaneous nerve is involved in medial snapping, as there is only one case report of this nerve as snapping structure^[35]. It is challenging to decide by ultrasonography which anatomical structure that causes medial snapping^[35] and the final diagnosis is established during operation. All snapping pathologies should be addressed.

Medial snapping in persons with repeated or loaded activities involving elbow flexion and extension during work (e.g., a waitress, a postman) or sports (weightlifting, body building) can be treated by reduction of these activities^[17,24,26]. In other cases, surgical intervention should preferably be early, as intra-articular pathologies can lead to damage of the cartilage, and snapping of the ulnar nerve can lead to neuropathy^[12,25].

Intra-articular loose bodies and postero-lateral elbow instability can cause locking, which may be interpreted as lateral snapping^[2,12]. Radiographs and CT are useful to identify intra-articular loose bodies, while postero-lateral instability is a clinical diagnosis. Also, lateral snapping is sometimes treated as epicondylitis, which is not a snapping condition.

In conclusion, SE is clinically divided into intra-articular (lateral) and extra-articular (medial) cases, based on the location of snapping. Intra-articular pathology is best visualized with high-resolution MRI, MR arthrography or radiographic arthrography. Arthroscopic or open resection of the pathological tissue is successful in most cases. Extra-articular pathology is best diagnosed by dynamic ultrasonography and during surgery. Solitary snapping of the ulnar nerve is extremely rare, and a triceps associated snapping tendon should always be suspected. Treatment is by open surgery.

ARTICLE HIGHLIGHTS

Research background

Patients with snapping elbow (SE) are seen by orthopaedic surgeons, rheumatologists and physical therapists, but the diagnosis is rare.

Research motivation

Most health care workers have no clinical experience with SE, as it is a rare condition. Therefore, there is a risk of misdiagnosis and delay of relevant treatment. Snapping can be visible, audible and palpable, but usual diagnostic measures can fail to demonstrate pathology.

Research objectives

From a literature search combined with our own clinical experience we wanted to analyse what is known about SE, its diagnosis and its treatment. The main purpose was to present a guideline to identify the patho-anatomical cause of

SE, its general binary categorization and the best treatment of each pathology.

Research methods

Literature was searched in PubMed and Scopus and key points in diagnosis and treatment were identified. Two typical cases are described.

Research results

Our review indicates that SE should be clinically divided into lateral and medial, and that diagnosis and treatment is a logic consequence of this. Lateral, intra-articular pathology is best diagnosed with high-resolution MRI, MR-arthrography or radiographic arthrography. Surgical intervention is the treatment of choice and successful in the majority of the cases. Medial, extra-articular pathology is best diagnosed by dynamic ultrasonography and during surgery. It is most commonly caused by subluxation of a medial part of the triceps tendon or the ulnar nerve. Treatment is by open surgery, except in patients with repeated, loaded activities during flexion and extension (at work or during sports), in which case symptoms may resolve by reduction of this activity.

Research conclusions

This guideline suggests a standardized approach to diagnosis and treatment of patients with SE. As early surgical intervention is recommended because the snapping can damage nerve (medial) or cartilage (lateral), this guideline is a tool for better patient care.

Research perspectives

There are no randomized studies on treatment of SE, but the largest series of 64 cases is on lateral SE, meaning that randomized controlled studies could be performed regarding treatment of this pathology. The other pathologies are too rare. There are probably many undiagnosed cases, and studies on incidence would describe the magnitude of this health problem.

REFERENCES

- 1 Akagi M, Nakamura T. Snapping elbow caused by the synovial fold in the radiohumeral joint. *J Shoulder Elbow Surg* 1998; **7**: 427-429 [PMID: 9752657 DOI: 10.1016/S1058-2746(98)90037-4]
- 2 Antuna SA, O'Driscoll SW. Snapping plicae associated with radiocapitellar chondromalacia. *Arthroscopy* 2001; **17**: 491-495 [PMID: 11337715 DOI: 10.1053/jars.2001.20096]
- 3 Aoki M, Okamura K, Yamashita T. Snapping annular ligament of the elbow joint in the throwing arms of young brothers. *Arthroscopy* 2003; **19**: E4-E7 [PMID: 14551563 DOI: 10.1016/S0749-8063(03)00741-2]
- 4 Chai JW, Kim S, Lim HK, Bae KJ. Ultrasonographic diagnosis of snapping annular ligament in the elbow. *Ultrasonography* 2015; **34**: 71-73 [PMID: 25327527 DOI: 10.14366/usg.14032]
- 5 Huang GS, Lee CH, Lee HS, Chen CY. A meniscus causing painful snapping of the elbow joint: MR imaging with arthroscopic and histologic correlation. *Eur Radiol* 2005; **15**: 2411-2414 [PMID: 15717195 DOI: 10.1007/s00330-005-2685-1]
- 6 Huang GS, Lee CH, Lee HS, Chen CY. MRI, arthroscopy, and histologic observations of an annular ligament causing painful snapping of the elbow joint. *AJR Am J Roentgenol* 2005; **185**: 397-399 [PMID: 16037511 DOI: 10.2214/ajr.185.2.01850397]
- 7 Kang ST, Kim TH. Lateral sided snapping elbow caused by a meniscus: two case reports and literature review. *Knee Surg Sports Traumatol Arthrosc* 2010; **18**: 840-844 [PMID: 20151108 DOI: 10.1007/s00167-010-1076-6]
- 8 Maruyama M, Takahara M, Kikuchi N, Ito K, Watanabe T, Ogino T. Snapping elbow with congenital radial head dislocation: case report. *J Hand Surg Am* 2010; **35**: 981-985 [PMID: 20456870 DOI: 10.1016/j.jhss.2010.02.026]
- 9 Brahe Pedersen J, Kristensen PK, Mønsted P, Thillemann TM. Short-term results after arthroscopic resection of synovial plicae in the radiohumeral joint: a case series of 64 procedures. *SICOT J* 2017; **3**: 42 [PMID: 28589876 DOI: 10.1051/sicotj/2017021]
- 10 Steinert AF, Goebel S, Rucker A, Barthel T. Snapping elbow

- caused by hypertrophic synovial plica in the radiohumeral joint: a report of three cases and review of literature. *Arch Orthop Trauma Surg* 2010; **130**: 347-351 [PMID: 19089437 DOI: 10.1007/s00402-008-0798-0]
- 11 **Tateishi K**, Tsumura N, Matsumoto T, Fujioka H, Kokubu T, Kuroda R, Shiba R, Kurosaka M. Bilateral painful snapping elbows triggered by daily dumbbell exercises: a case report. *Knee Surg Sports Traumatol Arthrosc* 2006; **14**: 487-490 [PMID: 16261350 DOI: 10.1007/s00167-005-0692-z]
 - 12 **Ruch DS**, Papadonikolakis A, Campolattaro RM. The posterolateral plica: a cause of refractory lateral elbow pain. *J Shoulder Elbow Surg* 2006; **15**: 367-370 [PMID: 16679240 DOI: 10.1016/j.jse.2005.08.013]
 - 13 **Fukase N**, Kokubu T, Fujioka H, Iwama Y, Fujii M, Kurosaka M. Usefulness of MRI for diagnosis of painful snapping elbow. *Skeletal Radiol* 2006; **35**: 797-800 [PMID: 15940486 DOI: 10.1007/s00256-005-0940-9]
 - 14 **Shinohara T**, Horii E, Tatebe M, Yamamoto M, Okui N, Hirata H. Painful snapping elbow in patients with congenital radioulnar synostosis: report of two cases. *J Hand Surg Am* 2010; **35**: 1336-1339 [PMID: 20684930 DOI: 10.1016/j.jhsa.2010.05.006]
 - 15 **Kang JH**, Joo BE, Kim KH, Park BK, Cha J, Kim DH. Ultrasonographic and Electrophysiological Evaluation of Ulnar Nerve Instability and Snapping of the Triceps Medial Head in Healthy Subjects. *Am J Phys Med Rehabil* 2017; **96**: e141-e146 [PMID: 28151762 DOI: 10.1097/PHM.0000000000000706]
 - 16 **Anand A**, Campion NJ, Chakraverty R, Pimpalnerkar A. Bilateral snapping ulnar nerve syndrome in a professional decathlete – a rare case report and a review of the literature. *Eur Orthop Traumatol* 2012; **3**: 263-266 [DOI: 10.1007/s12570-012-0111-0]
 - 17 **Chuang HJ**, Hsiao MY, Wu CH, Özçakar L. Dynamic Ultrasound Imaging for Ulnar Nerve Subluxation and Snapping Triceps Syndrome. *Am J Phys Med Rehabil* 2016; **95**: e113-e114 [PMID: 26945221 DOI: 10.1097/PHM.0000000000000466]
 - 18 **Dreyfuss U**, Kessler I. Snapping elbow due to dislocation of the medial head of the triceps. A report of two cases. *J Bone Joint Surg Br* 1978; **60**: 56-57 [PMID: 627579]
 - 19 **Hayashi Y**, Kojima T, Kohno T. A case of cubital tunnel syndrome caused by the snapping of the medial head of the triceps brachii muscle. *J Hand Surg Am* 1984; **9A**: 96-99 [PMID: 6693751 DOI: 10.1016/S0363-5023(84)80194-X]
 - 20 **Jacobson JA**, Jebson PJ, Jeffers AW, Fessell DP, Hayes CW. Ulnar nerve dislocation and snapping triceps syndrome: diagnosis with dynamic sonography--report of three cases. *Radiology* 2001; **220**: 601-605 [PMID: 11526255 DOI: 10.1148/radiol.2202001723]
 - 21 **Lasecki M**, Olchowcy C, Pawluś A, Zaleska-Dorobisz U. The Snapping Elbow Syndrome as a Reason for Chronic Elbow Neuralgia in a Tennis Player - MR, US and Sonoelastography Evaluation. *Pol J Radiol* 2014; **79**: 467-471 [PMID: 25525475 DOI: 10.12659/PJR.891393]
 - 22 **Reis ND**. Anomalous triceps tendon as a cause for snapping elbow and ulnar neuritis: a case report. *J Hand Surg Am* 1980; **5**: 361-362 [PMID: 7419878 DOI: 10.1016/S0363-5023(80)80176-6]
 - 23 **Rolfesen L**. Snapping triceps tendon with ulnar neuritis. Report on a case. *Acta Orthop Scand* 1970; **41**: 74-76 [PMID: 5453901 DOI: 10.3109/17453677008991979]
 - 24 **Spinner RJ**, Wenger DE, Barry CJ, Goldner RD. Episodic snapping of the medial head of the triceps due to weightlifting. *J South Orthop Assoc* 1999; **8**: 288-292 [PMID: 12132803]
 - 25 **Spinner RJ**, O'Driscoll SW, Jupiter JB, Goldner RD. Unrecognized dislocation of the medial portion of the triceps: another cause of failed ulnar nerve transposition. *J Neurosurg* 2000; **92**: 52-57 [PMID: 10616082 DOI: 10.3171/jns.2000.92.1.0052]
 - 26 **Xarchas KC**, Psillakis I, Koukou O, Kazakas KJ, Ververidis A, Verettas DA. Ulnar nerve dislocation at the elbow: review of the literature and report of three cases. *Open Orthop J* 2007; **1**: 1-3 [PMID: 19461901 DOI: 10.2174/1874325000701010001]
 - 27 **Spinner RJ**, Goldner RD. Snapping of the medial head of the triceps: diagnosis and treatment. *Tech Hand Up Extrem Surg* 2002; **6**: 91-97 [PMID: 16520623 DOI: 10.1097/00130911-200206000-00008]
 - 28 **Guillin R**, Marchand AJ, Roux A, Niederberger E, Duvauferrier R. Imaging of snapping phenomena. *Br J Radiol* 2012; **85**: 1343-1353 [PMID: 22744321 DOI: 10.1259/bjr/52009417]
 - 29 **Spinner RJ**, Hayden FR Jr, Hipps CT, Goldner RD. Imaging the snapping triceps. *AJR Am J Roentgenol* 1996; **167**: 1550-1551 [PMID: 8956595 DOI: 10.2214/ajr.167.6.8956595]
 - 30 **Haws M**, Brown RE. Bilateral snapping triceps tendon after bilateral ulnar nerve transposition for ulnar nerve subluxation. *Ann Plast Surg* 1995; **34**: 550-551 [PMID: 7639496 DOI: 10.1097/0000637-199505000-00017]
 - 31 **Minami A**, Kato H, Iwasaki N. Snapping of Triceps Tendon After Anterior Nerve Transposition for Recurrent Subluxation of the Ulnar Nerve. *Hand Surg* 1999; **4**: 193-196 [PMID: 11089180 DOI: 10.1142/S0218810499000253]
 - 32 **Spinner RJ**, Gabel GT. Latrogenic snapping of the medial head of the triceps after ulnar nerve transposition. *J South Orthop Assoc* 2001; **10**: 236-240 [PMID: 12132823]
 - 33 **Spinner RJ**, Goldner RD, Fada RA, Sotereanos DG. Snapping of the triceps tendon over the lateral epicondyle. *J Hand Surg Am* 1999; **24**: 381-385 [PMID: 10194025 DOI: 10.1053/jhsu.1999.0381]
 - 34 **Watts AC**, McEachan J, Reid J, Rymaszewski L. The snapping elbow: a diagnostic pitfall. *J Shoulder Elbow Surg* 2009; **18**: e9-e10 [PMID: 18667338 DOI: 10.1016/j.jse.2008.03.010]
 - 35 **Cesmebasi A**, O'Driscoll SW, Smith J, Skinner JA, Spinner RJ. The snapping medial antebrachial cutaneous nerve. *Clin Anat* 2015; **28**: 872-877 [PMID: 26212210 DOI: 10.1002/ca.22601]
 - 36 **Fabrizio PA**, Clemente FR. Variation in the triceps brachii muscle: a fourth muscular head. *Clin Anat* 1997; **10**: 259-263 [PMID: 9213044 DOI: 10.1002/(SICI)1098-2353(1997)10:43.0.CO;2-N]

P- Reviewer: Kodde IF, Papachristou GC, Sinha A **S- Editor:** Cui LJ
L- Editor: A **E- Editor:** Li D





Published by **Baishideng Publishing Group Inc**
7901 Stoneridge Drive, Suite 501, Pleasanton, CA 94588, USA
Telephone: +1-925-223-8242
Fax: +1-925-223-8243
E-mail: bpgoffice@wjgnet.com
Help Desk: <http://www.f6publishing.com/helpdesk>
<http://www.wjgnet.com>

