

World Journal of *Gastroenterology*

World J Gastroenterol 2018 June 7; 24(21): 2211-2326



**REVIEW**

- 2211 Irritable bowel syndrome in children: Current knowledge, challenges and opportunities
Devanarayana NM, Rajindrajith S
- 2236 Prognostic and predictive blood biomarkers in gastric cancer and the potential application of circulating tumor cells
Li TT, Liu H, Yu J, Shi GY, Zhao LY, Li GX

MINIREVIEWS

- 2247 Predictive factors for anastomotic leakage after laparoscopic colorectal surgery
Sciuto A, Merola G, De Palma GD, Sodo M, Pirozzi F, Bracale UM, Bracale U
- 2261 Hepatitis B virus pathogenesis: Fresh insights into hepatitis B virus RNA
Sekiba K, Otsuka M, Ohno M, Yamagami M, Kishikawa T, Suzuki T, Ishibashi R, Seimiya T, Tanaka E, Koike K

ORIGINAL ARTICLE**Basic Study**

- 2269 Multiple cytokine profiling in serum for early detection of gastric cancer
Li J, Xu L, Run ZC, Feng W, Liu W, Zhang PJ, Li Z

Retrospective Study

- 2279 Magnetic resonance imaging and Crohn's disease endoscopic index of severity: Correlations and concordance
Zhu NY, Zhao XS, Miao F

Clinical Trials Study

- 2291 Fiber-enriched diet helps to control symptoms and improves esophageal motility in patients with non-erosive gastroesophageal reflux disease
Morozov S, Isakov V, Konovalova M

Prospective Study

- 2300 Acute kidney injury in acute-on-chronic liver failure is different from in decompensated cirrhosis
Jiang QQ, Han MF, Ma K, Chen G, Wan XY, Kilonzo SB, Wu WY, Wang YL, You J, Ning Q

META-ANALYSIS

- 2311 Intraleisional steroid is beneficial in benign refractory esophageal strictures: A meta-analysis
Szapáry L, Tinusz B, Farkas N, Márta K, Szakó L, Meczker Á, Hágendorn R, Bajor J, Vincze Á, Gyöngyi Z, Mikó A, Csopor D, Hegyi P, Erőss B

CASE REPORT

- 2320 Obeticholic acid for severe bile acid diarrhea with intestinal failure: A case report and review of the literature
Hvas CL, Ott P, Paine P, Lal S, Jørgensen SP, Dahlerup JF

ABOUT COVER

Editorial board member of *World Journal of Gastroenterology*, Vicente Lorenzo-Zúñiga, MD, PhD, Associate Professor, Chief Doctor, Staff Physician, Endoscopy Unit, Department of Gastroenterology, Hospital Universitari Germans Trias i Pujol/CIBERehd, Badalona 08916, Spain

AIMS AND SCOPE

World Journal of Gastroenterology (*World J Gastroenterol*, *WJG*, print ISSN 1007-9327, online ISSN 2219-2840, DOI: 10.3748) is a peer-reviewed open access journal. *WJG* was established on October 1, 1995. It is published weekly on the 7th, 14th, 21st, and 28th each month. The *WJG* Editorial Board consists of 642 experts in gastroenterology and hepatology from 59 countries.

The primary task of *WJG* is to rapidly publish high-quality original articles, reviews, and commentaries in the fields of gastroenterology, hepatology, gastrointestinal endoscopy, gastrointestinal surgery, hepatobiliary surgery, gastrointestinal oncology, gastrointestinal radiation oncology, gastrointestinal imaging, gastrointestinal interventional therapy, gastrointestinal infectious diseases, gastrointestinal pharmacology, gastrointestinal pathophysiology, gastrointestinal pathology, evidence-based medicine in gastroenterology, pancreatology, gastrointestinal laboratory medicine, gastrointestinal molecular biology, gastrointestinal immunology, gastrointestinal microbiology, gastrointestinal genetics, gastrointestinal translational medicine, gastrointestinal diagnostics, and gastrointestinal therapeutics. *WJG* is dedicated to become an influential and prestigious journal in gastroenterology and hepatology, to promote the development of above disciplines, and to improve the diagnostic and therapeutic skill and expertise of clinicians.

INDEXING/ABSTRACTING

World Journal of Gastroenterology (*WJG*) is now indexed in Current Contents[®]/Clinical Medicine, Science Citation Index Expanded (also known as SciSearch[®]), Journal Citation Reports[®], Index Medicus, MEDLINE, PubMed, PubMed Central and Directory of Open Access Journals. The 2017 edition of Journal Citation Reports[®] cites the 2016 impact factor for *WJG* as 3.365 (5-year impact factor: 3.176), ranking *WJG* as 29th among 79 journals in gastroenterology and hepatology (quartile in category Q2).

EDITORS FOR THIS ISSUE

Responsible Assistant Editor: Xiang Li
Responsible Electronic Editor: Yan Huang
Proofing Editor-in-Chief: Lian-Sheng Ma

Responsible Science Editor: Xue-Jiao Wang
Proofing Editorial Office Director: Ze-Mao Gong

NAME OF JOURNAL
World Journal of Gastroenterology

ISSN
ISSN 1007-9327 (print)
ISSN 2219-2840 (online)

LAUNCH DATE
October 1, 1995

FREQUENCY
Weekly

EDITORS-IN-CHIEF
Damian Garcia-Olmo, MD, PhD, Doctor, Professor, Surgeon, Department of Surgery, Universidad Autonoma de Madrid; Department of General Surgery, Fundacion Jimenez Diaz University Hospital, Madrid 28040, Spain

Stephen C Strom, PhD, Professor, Department of Laboratory Medicine, Division of Pathology, Karolinska Institutet, Stockholm 141-86, Sweden

Andrzej S Tarnawski, MD, PhD, DSc (Med), Professor of Medicine, Chief Gastroenterology, VA Long Beach Health Care System, University of California, Irvine, CA, 5901 E. Seventh Str., Long Beach,

CA 90822, United States

EDITORIAL BOARD MEMBERS
All editorial board members resources online at <http://www.wjgnet.com/1007-9327/editorialboard.htm>

EDITORIAL OFFICE
Ze-Mao Gong, Director
World Journal of Gastroenterology
Baishideng Publishing Group Inc
7901 Stoneridge Drive, Suite 501,
Pleasanton, CA 94588, USA
Telephone: +1-925-2238242
Fax: +1-925-2238243
E-mail: editorialoffice@wjgnet.com
Help Desk: <http://www.f6publishing.com/helpdesk>
<http://www.wjgnet.com>

PUBLISHER
Baishideng Publishing Group Inc
7901 Stoneridge Drive, Suite 501,
Pleasanton, CA 94588, USA
Telephone: +1-925-2238242
Fax: +1-925-2238243
E-mail: bpgoffice@wjgnet.com
Help Desk: <http://www.f6publishing.com/helpdesk>
<http://www.wjgnet.com>

PUBLICATION DATE
June 7, 2018

COPYRIGHT
© 2018 Baishideng Publishing Group Inc. Articles published by this Open-Access journal are distributed under the terms of the Creative Commons Attribution Non-commercial License, which permits use, distribution, and reproduction in any medium, provided the original work is properly cited, the use is non commercial and is otherwise in compliance with the license.

SPECIAL STATEMENT
All articles published in journals owned by the Baishideng Publishing Group (BPG) represent the views and opinions of their authors, and not the views, opinions or policies of the BPG, except where otherwise explicitly indicated.

INSTRUCTIONS TO AUTHORS
Full instructions are available online at <http://www.wjgnet.com/bpg/gerinfo/204>

ONLINE SUBMISSION
<http://www.f6publishing.com>

Obeticholic acid for severe bile acid diarrhea with intestinal failure: A case report and review of the literature

Christian Lodberg Hvas, Peter Ott, Peter Paine, Simon Lal, Søren Peter Jørgensen, Jens Frederik Dahlerup

Christian Lodberg Hvas, Peter Ott, Søren Peter Jørgensen, Jens Frederik Dahlerup, Department of Hepatology and Gastroenterology, Aarhus University Hospital, Aarhus C 8000, Denmark

Peter Paine, Simon Lal, Department of Gastroenterology, Salford Royal NHS Foundation Trust, Salford, Manchester M6 8HD, United Kingdom

ORCID number: Christian Lodberg Hvas (0000-0001-7973-7184); Peter Ott (0000-0002-3088-1983); Peter Paine (0000-0003-4131-9651); Simon Lal (0000-0002-6245-8864); Søren Peter Jørgensen (0000-0002-6530-6655); Jens Frederik Dahlerup (0000-0002-1587-7636).

Author contributions: Hvas CL treated the intestinal failure in the patient and wrote the first draft of the manuscript; Ott P managed the communications with Intercept Pharmaceuticals, discussed the treatment and drafted the manuscript; Paine P and Lal S discussed the differential diagnoses during the treatment of the patient and revised the manuscript; Jørgensen SP provided expertise on BAD and FXR biology and revised the manuscript; Dahlerup JF was responsible for treating the patient, handled the communication with National Health Authorities, and revised the manuscript; all authors approved the final version of the manuscript.

Informed consent statement: The patient gave oral and written consent for the publication of this case report. A signed informed consent statement has been uploaded with the submission of the manuscript.

Conflict-of-interest statement: Hvas CL reports lecture fees from Takeda, Ferring, Novartis, MSD, and Tillotts. Ott P reports a lecture fee from Intercept Pharmaceuticals. Lal S reports grants from Fresenius Kabi and Shire. Dahlerup JF reports lecture fees from Pharmacosmos, MSD, and Takeda. All other authors declare that they have no conflicts of interest.

CARE checklist (2013) statement: This case report conforms to the CARE checklist (2013), and a fulfilled PDF version of the checklist was attached with the submission of the manuscript.

Open-Access: This article is an open-access article which was selected by an in-house editor and fully peer-reviewed by external

reviewers. It is distributed in accordance with the Creative Commons Attribution Non Commercial (CC BY-NC 4.0) license, which permits others to distribute, remix, adapt, build upon this work non-commercially, and license their derivative works on different terms, provided the original work is properly cited and the use is non-commercial. See: <http://creativecommons.org/licenses/by-nc/4.0/>

Manuscript source: Unsolicited manuscript

Correspondence to: Christian Lodberg Hvas, MD, PhD, Associate Professor, Department of Hepatology and Gastroenterology, Aarhus University Hospital, Nørrebrogade 44, Aarhus C 8000, Denmark. christian.hvas@auh.rm.dk
Telephone: +45-78463895
Fax: +45-78462820

Received: January 20, 2018
Peer-review started: January 22, 2018
First decision: February 26, 2018
Revised: March 8, 2018
Accepted: March 31, 2018
Article in press: March 31, 2018
Published online: June 7, 2018

Abstract

Bile acid diarrhea results from excessive amounts of bile acids entering the colon due to hepatic overexcretion of bile acids or bile acid malabsorption in the terminal ileum. The main therapies include bile acid sequestrants, such as colestyramine and colesevelam, which may be given in combination with the opioid receptor agonist loperamide. Some patients are refractory to conventional treatments. We report the use of the farnesoid X receptor agonist obeticholic acid in a patient with refractory bile acid diarrhea and subsequent intestinal failure. A 32-year-old woman with quiescent colonic Crohn's disease and a normal terminal ileum had been diagnosed with severe bile acid malabsorption and complained of watery diarrhea and fatigue. The

diarrhea resulted in hypokalemia and sodium depletion that made her dependent on twice weekly intravenous fluid and electrolyte infusions. Conventional therapies with colestyramine, colesevelam, and loperamide had no effect. Second-line antisecretory therapies with pantoprazole, liraglutide, and octreotide also failed. Third-line treatment with obeticholic acid reduced the number of stools from an average of 13 to an average of 7 per 24 h and improved the patient's quality of life. The fluid and electrolyte balances normalized. The effect was sustained during follow-up for 6 mo with treatment at a daily dosage of 25 mg. The diarrhea worsened shortly after cessation of obeticholic acid. This case report supports the initial report that obeticholic acid may reduce bile acid production and improve symptoms in patients with bile acid diarrhea.

Key words: Bile acid malabsorption; Diarrhea; Farnesoid X-activated receptor; Crohn's disease

© The Author(s) 2018. Published by Baishideng Publishing Group Inc. All rights reserved.

Core tip: Bile acid diarrhea develops when excessive amounts of bile acids enter the terminal ileum and exceed the intestinal absorptive capacity. The excess bile acids enter the colon and cause secretory diarrhea. We report a patient with multiple potential causes of chronic diarrhea and suggest a systematic strategy for the diagnosis and treatment of this condition. Furthermore, we describe the use of a new treatment for severe bile acid diarrhea, obeticholic acid, which stimulates the farnesoid X receptor of the terminal ileum and increases fibroblast growth factor 19, thereby decreasing hepatic bile acid production *via* negative feedback.

Hvas CL, Ott P, Paine P, Lal S, Jørgensen SP, Dahlerup JF. Obeticholic acid for severe bile acid diarrhea with intestinal failure: A case report and review of the literature. *World J Gastroenterol* 2018; 24(21): 2320-2326 Available from: URL: <http://www.wjgnet.com/1007-9327/full/v24/i21/2320.htm> DOI: <http://dx.doi.org/10.3748/wjg.v24.i21.2320>

INTRODUCTION

Chronic secretory diarrhea causes intestinal losses of water, sodium, and potassium^[1]. In severe cases, it may negatively affect the fluid and electrolyte balance. Chronic secretory diarrhea may be caused by intestinal inflammation, infection, drug side effects or abuse, neuroendocrine tumors, functional diarrhea, or bile acid diarrhea (BAD). When no cause is identified, the condition is termed diarrhea-predominant irritable bowel syndrome (IBS-D)^[2].

BAD occurs when excess amounts of bile acids enter the colon and induce colonic fluid and electrolyte secretion and motility changes^[3]. Based on the

pathophysiology, BAD is classified as type 1, which is caused by ileal resection, disease, or injury, type 2, which consists of primary or idiopathic BAD, and type 3, which is secondary to other conditions, *e.g.*, cholecystectomy^[4-6].

The medical treatments of BAD include the bile acid sequestrants colestyramine and colesevelam^[3,7,8]. Antisecretory or antimotility drugs such as loperamide and proton pump inhibitors may be added. Some patients with BAD experience an insufficient effect of the available conventional medical treatments and suffer from an impaired quality of life^[9,10].

BAD is proposed to result from defective gut-liver feedback mechanisms. Hepatic bile acid synthesis is inhibited by fibroblast growth factor 19 (FGF19) that is produced by ileal enterocytes upon stimulation by bile acids in the terminal ileum *via* the farnesoid X receptor (FXR)^[5,11]. Decreased circulating FGF19 levels have been reported in patients with primary BAD^[12] and in patients with Crohn's disease and diarrhea^[13]. Obeticholic acid, a potent FXR agonist, stimulates ileal FGF19 production and may thereby decrease hepatic bile acid production in BAD^[14]. Obeticholic acid is currently used to treat primary biliary cholangitis^[15,16] and non-alcoholic steatohepatitis^[17,18], but it may also improve BAD^[14].

In this case report, we describe the investigations and treatments of a 32-year-old woman with Crohn's disease who suffered from chronic secretory diarrhea that could be potentially attributed to multiple causal factors. Because no infectious, inflammatory, or metabolic cause was demonstrated other than severe bile acid malabsorption, both type 1 and type 2 BAD were considered. The patient experienced a marked and sustained improvement following treatment with obeticholic acid.

CASE REPORT

A 32-year-old Caucasian woman was referred to our unit for refractory diarrhea lasting 10 years. She had a 15-year history of recurrent depression and primary tonic-myoelonic epilepsy. Following the onset of diarrhea, she had been diagnosed with colonic Crohn's disease, and ⁷⁵selenium homotaurocholic acid test (SeHCAT) scintigraphy^[19] performed six years before referral to our unit had revealed a day-7 relative bile acid retention of 0, indicating severe bile acid malabsorption. Conventional treatments for BAD with the bile acid sequestrants colestyramine and colesevelam had a limited or transient effect, and the diarrhea had been unresponsive to antisecretory treatments such as loperamide and codeine phosphate. At the time of referral, the patient received low-dose 6-mercaptopurine for Crohn's disease, 625 mg colesevelam three times per day, 2-8 mg of loperamide per day for BAD, 1500 mg of levetiracetam per day for depression, and 400 mg of lamotrigine per day for epilepsy. The doses of both levetiracetam and lamotrigine had been optimized

Table 1 Potential causes of chronic diarrhea and their diagnostic investigations and results in a patient with severe bile acid diarrhea and intestinal failure

Potential cause of diarrhea	Investigations	Results
Excess bile acid production with deficient retention	SeHCAT scintigraphy	0 retention, indicating an excess loss of bile acids
Active Crohn's disease	Small bowel imaging; colonoscopy; fecal calprotectin	Normal MRI of small bowel and capsule endoscopy; normal colonoscopy with biopsies; fecal calprotectin < 30 mg/kg
Small bowel disease (celiac disease, autoimmune enteropathy)	Duodenal and jejunal biopsies; plasma tissue transglutaminase antibody	Normal biopsies; anti-transglutaminase negative
<i>Clostridium difficile</i> infection	<i>Clostridium difficile</i> toxin test	Positive before fecal transplant; negative repeated tests after fecal transplant
Pathogenic intestinal infection	<i>Salmonella</i> , <i>Shigella</i> , <i>Campylobacter</i> , and <i>Yersinia</i> fecal cultures; PCR for intestinal parasites	Negative
Systemic infection	HIV test; gamma-interferon test for tuberculosis	Negative
Small intestinal bacterial overgrowth (SIBO)	Hydrogen breath test	Negative
Use of antidepressant and antiepileptic medications	Observation during drug holiday; therapeutic drug monitoring	Treatment dose optimized
Laxative use	Urine laxative screen repeated with a patient-blinded sampling time	Negative × 2
Neuroendocrine tumor	Chromogranin A, gastrin, vasoactive intestinal polypeptide, renin, and aldosterone	All within the reference range
Metabolic disease	Thyroid function test and synacthen test	All within the normal range

SeHCAT: Selenium homotaurocholic acid test.

using therapeutic drug monitoring. Prior treatments also included 40 mg of escitalopram per day and 225 mg of venlafaxin per day, which led to poor control of the depression and did not affect bowel function. Anti-inflammatory Crohn's disease treatments with infliximab, adalimumab, natalizumab, and vedolizumab had been provided before referral and did not affect the diarrhea. Crohn's disease remission had been verified *via* a colonoscopy and fecal calprotectin measurement. The duodenal biopsies were normal. The patient had not undergone bowel surgery.

During the first admission to our unit, the results from all investigations were reviewed, and a diagnostic workup was planned (Table 1). The patient's height and weight were 52 kg and 170 cm, respectively. Biochemical analysis revealed severe electrolyte deficiency with low plasma levels of potassium and magnesium. Although the plasma sodium level was normal, sodium depletion was indicated by the urinary sodium being below the detection limit using both single urine measurements and an analysis of a 24-h urine collection. Fecal cultures were negative for *Campylobacter*, *Salmonella*, *Yersinia*, and *Shigella* species, but a PCR toxin test for *Clostridium difficile* was positive. A 10-d trial of 125 mg of vancomycin four times per day had a transient effect on the diarrhea, and repeat fecal tests were negative. MRI of the small bowel and pan-enteric double balloon endoscopy revealed endoscopic remission, and duodenal, jejunal, ileal, and colonic biopsies were normal. A laxative screen and markers of systemic infection or metabolic disease were normal (Table 1). All medical treatments were reviewed, and because the diarrhea persisted despite conventional treatment, trials of spironolactone, octreotide, and liraglutide were initiated during the admission but were without effect or

produced unacceptable side effects (Table 2). The dose of 6-mercaptopurine was optimized using thiopurine metabolite measurements, revealing a normal TPMT genotype and phenotype, an E-TGN level of 247 nmol/mmol HGB, and an E-MeMP level of 2354 nmol/mmol HGB.

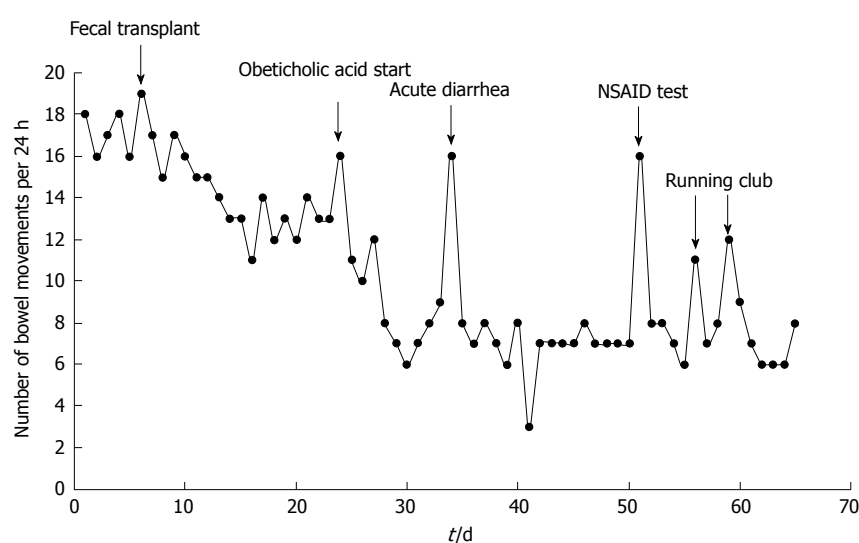
Due to having persistent dehydration with a passage of up to 5 L of watery stools per day, the patient was considered for long-term intravenous support. The patient's potassium levels normalized upon infusions of up to 100 mmol of potassium per day, but the urinary sodium became measurable in the 24-h urine samples only after hypertonic NaCl was applied at 2000 mL of 3% NaCl per day. Because intravenous supplementation was necessary to sustain a normal hydration and electrolyte status, the patient was classified as having type III intestinal failure, subtype A3^[20]. A scheduled regimen was established with twice weekly infusions of fluids and electrolytes, but the patient remained underweight, had watery diarrhea, and had a poor quality of life.

A trial of obeticholic acid was considered because of the promising initial reports^[14]. Following collaboration with Intercept Pharmaceuticals and approval from the National Health Authorities, we were able to start obeticholic acid during admission. In the initial investigation, a repeat *Clostridium difficile* test was positive, and a fecal transplant using an anonymous donor was performed following a short vancomycin taper. Subsequently, the mean number of bowel passages per 24 h decreased from a mean of 17 to a mean of 13. Obeticholic acid was then started at 10 mg per day and increased to 25 mg per day after 4 d. Importantly, obeticholic acid further reduced the number of bowel movements from a mean of 13 to a mean of 7 per 24 h (Figure 1). When the number of bowel movements

Table 2 Anti-diarrheal drug treatments, their mechanisms of action, and their treatment results in a patient with severe bile acid diarrhea and intestinal failure

Drug	Mechanism of action	Treatment effect
Colestyramine (Questran®)	Bile salt sequestrant	Limited effect
Colesevelam (Cholestigel®)	Bile salt sequestrant	Limited effect
Pantoprazole	Proton pump inhibitor	No effect
Loperamide (Imodium®)	Decreases intestinal motility	No effect
Codeine phosphate	Decreases intestinal motility	No effect; sedation
Spironolactone	Increases renal potassium reabsorption	No effect on potassium deficiency
Octreotide	Antisecretory	No effect; abdominal pain
Liraglutide (Victoza®)	Increases glucagon-like peptide 1 (GLP-1)	No effect; weight loss of 2 kg to 52 kg
Obeticholic acid (Ocaliva®)	Stimulates ileal FGF19 production, thereby inhibiting hepatic bile acid production	Marked reduction of stool volume and fecal electrolyte loss

FGF19: Fibroblast growth factor 19.

**Figure 1** Bowel movement frequencies before and during the initial two months of treatment with 25 mg obeticholic acid once daily for severe bile acid diarrhea with intestinal failure.

during the two weeks of treatment with 25 mg of obeticholic acid per day was compared with that of the two weeks before treatment, the difference was highly statistically significant ($P = 0.00001$, Mann-Whitney U test). While nightly bowel movements had been a persistent problem before the initiation of treatment, these were reduced from a mean of 3 nightly bowel openings to a mean of 2 nightly bowel openings following treatment, and on occasional nights, the patient did not open her bowel during the night. The patient's weight increased by 2 kg to 54 kg, and she was weaned off intravenous fluid support. She resumed social activities, including running, although this occasionally induced an increase in the number of bowel movements (Figure 1). She remained sensitive to non-steroid anti-inflammatory drug treatment because a single dose of 400 mg of ibuprofen transiently induced liquid stools (Figure 1). The quality of life was estimated using the Euroqol EQ-5D-3L questionnaire (<https://euroqol.org>). Before the treatment, the patient reported an overall wellbeing of 35 on a 0-100 scale. This increased to 85 following two weeks of obeticholic acid treatment and remained at this

level for six months of follow-up.

To examine whether the effects were specific to obeticholic acid and whether the effect would last without continued treatment, the patient agreed to a treatment pause. Following three days without obeticholic acid, the patient's condition deteriorated, with an increase in the number of bowel movements in 24 h from 7 to 16 and profound hypokalemia. Shortly after restarting obeticholic acid, the patient's bowel control was reestablished. During 6 mo of follow-up, we observed no adverse effects, and control of Crohn's disease, epilepsy, and depression did not change. A single episode of increased serum pancreatic amylase (266 U/L; reference range: 10-65 U/L) necessitated a pause of the 6-mercaptopurine treatment. Ultrasound examination revealed a normal pancreas and bile ducts, and the p-amylase level normalized. A diagnosis of acute pancreatitis could therefore not be confirmed, and treatment was restarted without further episodes or an increase in the pancreatic or liver function tests. The plasma lipids were slightly elevated before the treatment and decreased during the obeticholic

acid treatment. Thus, the patient's total cholesterol decreased from 7.5 to 5.9 mmol/L, and her LDL-cholesterol level decreased from 4.5 to 3.1 mmol/L, while her HDL-cholesterol increased slightly from 2.0 to 2.1 mmol/L. Measurements of fasting serum FGF19 were performed once before and six times during treatment with obeticholic acid, using the Human FGF-19 Quantikine ELISA kit DF 1900 (R&D Systems, Minneapolis, MN, United States). Although the mean FGF19 level increased from 35.7 to 167.0 pg/mL during treatment with 25 mg per day, we observed a marked fluctuation in the serum FGF levels during obeticholic treatment, with serum FGF19 concentrations ranging from 21 pg/mL to 728 pg/mL.

DISCUSSION

This case report demonstrates the challenges related to the diagnosis and treatment of patients with multifactorial chronic diarrhea. In this patient, a thorough and systematic evaluation of several differential diagnoses was pivotal for understanding the causes of chronic diarrhea in the presence of a severely disrupted electrolyte balance and intestinal failure. Because the SeHCAT retention rate was 0 on day 7, an overproduction of bile acids in combination with severe bile acid malabsorption was indicated. In the absence of other causes of chronic diarrhea, we concluded that the patient had severe BAD. Before treatment with obeticholic acid, the patient had intestinal failure with a dependency on intravenous fluid and electrolyte support. To the best of our knowledge, this is the first report of BAD of such severity.

For patients with chronic diarrhea, the SeHCAT scintigraphy identifies those with BAD and, hence, a treatable cause of diarrhea^[8,19,21-23]. It further helps to tailor the treatment. This investigation therefore remains an important tool in the diagnostic workup and should be considered in patients with Crohn's disease and unresolved diarrhea^[6].

While this patient was refractory to conventional therapies for diarrhea, she improved both clinically and biochemically following treatment with obeticholic acid. This adds to the promising data that indicate obeticholic acid may improve BAD *via* a modulation of negative feedback signaling of FGF19 on hepatic bile acid production^[14]. Obeticholic acid is marketed for the treatment of primary biliary cholangitis and has been investigated in dosages of 10 mg to 50 mg daily for 3 mo^[15] and up to 10 mg daily for 12 mo^[16]. Pruritus was the most common side effect and occurred in up to two-thirds of the treated patients, even at low doses. We observed no side effects in this patient. Because the treatment was well-tolerated, and the improvements of fluid balance and quality of life were sustained during the follow-up, we did not change the treatment dose.

We measured fasting serum FGF19 levels both before and during treatment and found that obeticholic acid

increased FGF19 levels, but with substantial variation between samples obtained during treatment. The finding supports that hepatic bile production is inhibited by FGF19 signaling following the obeticholic acid-induced stimulation of FXR in ileal enterocytes^[12,24,25]. It also emphasizes that the use of FGF19 measurement should be validated. In general, FGF19 levels depend on renal function, age, and systemic inflammation^[26,27]. In patients with Crohn's disease, FGF19 levels are generally lower than in control patients, and low levels are associated with ileal resection and with active disease, independently of ileal resection^[13].

In conclusion, we found that treatment with oral obeticholic acid (25 mg daily) induced a marked and sustained improvement of bowel function, fluid and electrolyte balance, and quality of life in this patient with severe BAD and intestinal failure. Future clinical trials should investigate the long-term clinical effects of obeticholic acid, including safety measures and serum FGF19 dynamics.

ARTICLE HIGHLIGHTS

Case characteristics

A 32-year-old woman with chronic diarrhea that had multiple potential causes including bile acid diarrhea, Crohn's disease, and medications for epilepsy and depression.

Clinical diagnosis

Bile acid diarrhea (BAD), diagnosed by selenium homotaurocholic acid test scintigraphy with 0 bile acid retention after seven days.

Laboratory diagnosis

Persistently low plasma levels of sodium and potassium and undetectable 24-h urine sodium excretion, indicating intestinal failure with dependency of intravenous fluid support.

Pathological diagnosis

Normal duodenal, jejunal, ileal, and colonic biopsies, indicating quiescent Crohn's disease. Positive *Clostridium difficile* toxin PCR test indicating *Clostridium difficile* colitis.

Treatment

Clostridium difficile colitis was treated with vancomycin followed by fecal microbiota transplantation. Bile acid diarrhea was refractory to conventional treatments including colestyramine and colestesvelam, and oral obeticholic acid treatment was commenced at 10 mg per day, increasing to 25 mg per day. Upon this, the patient's bowel habits and quality of life improved.

Related reports

Obeticholic is licensed for primary biliary cholangitis and has been used in non-alcoholic steatohepatitis. It was recently reported that obeticholic acid may improve bile acid diarrhea through induction of fibroblast growth factor 19 that inhibits hepatic bile production.

Term explanation

BAD—bile acid diarrhea, resulting from excess hepatic production and/or deficient ileal reabsorption of bile acids, which in turn induces colonic fluid and electrolyte secretion and leads to chronic secretory diarrhea.

Experiences and lessons

In patients with chronic diarrhea, a thorough and systematic diagnostic workup

may help to differentiate between potential causes of diarrhea. Some patients with bile acid diarrhea are refractory to conventional treatments. Obeticholic acid may be of clinical benefit in these patients.

REFERENCES

- 1 **Thiagarajah JR**, Donowitz M, Verkman AS. Secretory diarrhoea: mechanisms and emerging therapies. *Nat Rev Gastroenterol Hepatol* 2015; **12**: 446-457 [PMID: 26122478 DOI: 10.1038/nrgastro.2015.111]
- 2 **Ford AC**, Lacy BE, Talley NJ. Irritable Bowel Syndrome. *N Engl J Med* 2017; **376**: 2566-2578 [PMID: 28657875 DOI: 10.1056/NEJMr1607547]
- 3 **Camilleri M**. Bile Acid diarrhea: prevalence, pathogenesis, and therapy. *Gut Liver* 2015; **9**: 332-339 [PMID: 25918262 DOI: 10.5009/gnl14397]
- 4 **Hofmann AF**, Mangelsdorf DJ, Kliewer SA. Chronic diarrhea due to excessive bile acid synthesis and not defective ileal transport: a new syndrome of defective fibroblast growth factor 19 release. *Clin Gastroenterol Hepatol* 2009; **7**: 1151-1154 [PMID: 19665580 DOI: 10.1016/j.cgh.2009.07.026]
- 5 **Walters JR**, Tasleem AM, Omer OS, Brydon WG, Dew T, le Roux CW. A new mechanism for bile acid diarrhea: defective feedback inhibition of bile acid biosynthesis. *Clin Gastroenterol Hepatol* 2009; **7**: 1189-1194 [PMID: 19426836 DOI: 10.1016/j.cgh.2009.04.024]
- 6 **Vitek L**. Bile acid malabsorption in inflammatory bowel disease. *Inflamm Bowel Dis* 2015; **21**: 476-483 [PMID: 25248001 DOI: 10.1097/MIB.0000000000000193]
- 7 **Wilcox C**, Turner J, Green J. Systematic review: the management of chronic diarrhoea due to bile acid malabsorption. *Aliment Pharmacol Ther* 2014; **39**: 923-939 [PMID: 24602022 DOI: 10.1111/apt.12684]
- 8 **Orekoya O**, McLaughlin J, Leitao E, Johns W, Lal S, Paine P. Quantifying bile acid malabsorption helps predict response and tailor sequestrant therapy. *Clin Med (Lond)* 2015; **15**: 252-257 [PMID: 26031975 DOI: 10.7861/clinmedicine.15-3-252]
- 9 **Bannaga A**, Kelman L, O'Connor M, Pitchford C, Walters JR, Arasaradnam RP. How bad is bile acid diarrhoea: an online survey of patient-reported symptoms and outcomes. *BMJ Open Gastroenterol* 2017; **4**: e000116 [PMID: 28123771 DOI: 10.1136/bmjgast-2016-000116]
- 10 **Damsgaard B**, Dalby HR, Krogh K, Jørgensen SMD, Arveschoug AK, Agnholt J, Dahlerup JF, Jørgensen SP. Long-term effect of medical treatment of diarrhoea in 377 patients with SeHCAT scan diagnosed bile acid malabsorption from 2003 to 2016; a retrospective study. *Aliment Pharmacol Ther* 2018; **47**: 951-957 [PMID: 29368342 DOI: 10.1111/apt.14533]
- 11 **Holt JA**, Luo G, Billin AN, Bisi J, McNeill YY, Kozarsky KF, Donahee M, Wang DY, Mansfield TA, Kliewer SA, Goodwin B, Jones SA. Definition of a novel growth factor-dependent signal cascade for the suppression of bile acid biosynthesis. *Genes Dev* 2003; **17**: 1581-1591 [PMID: 12815072 DOI: 10.1101/gad.1083503]
- 12 **Pattani SS**, Brydon WG, Dew T, Johnston IM, Nolan JD, Srinivas M, Basumani P, Bardhan KD, Walters JR. Fibroblast growth factor 19 in patients with bile acid diarrhoea: a prospective comparison of FGF19 serum assay and SeHCAT retention. *Aliment Pharmacol Ther* 2013; **38**: 967-976 [PMID: 23981126 DOI: 10.1111/apt.12466]
- 13 **Nolan JD**, Johnston IM, Pattani SS, Dew T, Orchard TR, Walters JR. Diarrhea in Crohn's disease: investigating the role of the ileal hormone fibroblast growth factor 19. *J Crohns Colitis* 2015; **9**: 125-131 [PMID: 25518063 DOI: 10.1093/ecco-jcc/jju022]
- 14 **Walters JR**, Johnston IM, Nolan JD, Vassie C, Pruzanski ME, Shapiro DA. The response of patients with bile acid diarrhoea to the farnesoid X receptor agonist obeticholic acid. *Aliment Pharmacol Ther* 2015; **41**: 54-64 [PMID: 25329562 DOI: 10.1111/apt.12999]
- 15 **Hirschfield GM**, Mason A, Luketic V, Lindor K, Gordon SC, Mayo M, Kowdley KV, Vincent C, Bodhenheimer HC Jr, Parés A, Trauner M, Marschall HU, Adorini L, Sciacca C, Beecher-Jones T, Castellote E, Böhm O, Shapiro D. Efficacy of obeticholic acid in patients with primary biliary cirrhosis and inadequate response to ursodeoxycholic acid. *Gastroenterology* 2015; **148**: 751-761.e8 [PMID: 25500425 DOI: 10.1053/j.gastro.2014.12.005]
- 16 **Nevens F**, Andreone P, Mazzella G, Strasser SI, Bowlus C, Invernizzi P, Drenth JP, Pockros PJ, Regula J, Beuers U, Trauner M, Jones DE, Floreani A, Hohenester S, Luketic V, Shiffman M, van Erpecum KJ, Vargas V, Vincent C, Hirschfield GM, Shah H, Hansen B, Lindor KD, Marschall HU, Kowdley KV, Hooshmand-Rad R, Marmon T, Sheeron S, Pencek R, MacConell L, Pruzanski M, Shapiro D; POISE Study Group. A Placebo-Controlled Trial of Obeticholic Acid in Primary Biliary Cholangitis. *N Engl J Med* 2016; **375**: 631-643 [PMID: 27532829 DOI: 10.1056/NEJMoa1509840]
- 17 **Mudaliar S**, Henry RR, Sanyal AJ, Morrow L, Marschall HU, Kipnes M, Adorini L, Sciacca CI, Clopton P, Castellote E, Dillon P, Pruzanski M, Shapiro D. Efficacy and safety of the farnesoid X receptor agonist obeticholic acid in patients with type 2 diabetes and nonalcoholic fatty liver disease. *Gastroenterology* 2013; **145**: 574-582.e1 [PMID: 23727264 DOI: 10.1053/j.gastro.2013.05.042]
- 18 **Neuschwander-Tetri BA**, Loomba R, Sanyal AJ, Lavine JE, Van Natta ML, Abdelmalek MF, Chalasani N, Dasarthy S, Diehl AM, Hameed B, Kowdley KV, McCullough A, Terrault N, Clark JM, Tonascia J, Brunt EM, Kleiner DE, Doo E; NASH Clinical Research Network. Farnesoid X nuclear receptor ligand obeticholic acid for non-cirrhotic, non-alcoholic steatohepatitis (FLINT): a multicentre, randomised, placebo-controlled trial. *Lancet* 2015; **385**: 956-965 [PMID: 25468160 DOI: 10.1016/S0140-6736(14)61933-4]
- 19 **Riemsma R**, Al M, Corro Ramos I, Deshpande SN, Armstrong N, Lee YC, Ryder S, Noake C, Krol M, Oppe M, Kleijnen J, Severens H. SeHCAT [tauroselcholic (selenium-75) acid] for the investigation of bile acid malabsorption and measurement of bile acid pool loss: a systematic review and cost-effectiveness analysis. *Health Technol Assess* 2013; **17**: 1-236 [PMID: 24351663 DOI: 10.3310/hta17610]
- 20 **Pironi L**, Arends J, Baxter J, Bozzetti F, Peláez RB, Cuerda C, Forbes A, Gabe S, Gillanders L, Holst M, Jeppesen PB, Joly F, Kelly D, Klek S, Irtun Ø, Olde Damink SW, Panisic M, Rasmussen HH, Staun M, Szczepanek K, Van Gossum A, Wanten G, Schneider SM, Shaffer J; Home Artificial Nutrition & Chronic Intestinal Failure; Acute Intestinal Failure Special Interest Groups of ESPEN. ESPEN endorsed recommendations. Definition and classification of intestinal failure in adults. *Clin Nutr* 2015; **34**: 171-180 [PMID: 25311444 DOI: 10.1016/j.clnu.2014.08.017]
- 21 **Schiller LR**, Hogan RB, Morawski SG, Santa Ana CA, Bern MJ, Norgaard RP, Bo-Linn GW, Fordtran JS. Studies of the prevalence and significance of radiolabeled bile acid malabsorption in a group of patients with idiopathic chronic diarrhea. *Gastroenterology* 1987; **92**: 151-160 [PMID: 3781183 DOI: 10.1016/0016-5085(87)90852-3]
- 22 **Wildt S**, Nørby Rasmussen S, Lysegård Madsen J, Rumessen JJ. Bile acid malabsorption in patients with chronic diarrhoea: clinical value of SeHCAT test. *Scand J Gastroenterol* 2003; **38**: 826-830 [PMID: 12940434 DOI: 10.1080/00365520310004461]
- 23 **Borghede MK**, Schlütter JM, Agnholt JS, Christensen LA, Gormsen LC, Dahlerup JF. Bile acid malabsorption investigated by selenium-75-homocholic acid taurine ((75)SeHCAT) scans: causes and treatment responses to cholestyramine in 298 patients with chronic watery diarrhoea. *Eur J Intern Med* 2011; **22**: e137-e140 [PMID: 22075299 DOI: 10.1016/j.ejim.2011.08.013]
- 24 **Johnston IM**, Nolan JD, Pattani SS, Appleby RN, Zhang JH, Kennie SL, Madhan GK, Jameie-Oskooei S, Pathmasirirengam S, Lin J, Hong A, Dixon PH, Williamson C, Walters JR. Characterizing Factors Associated With Differences in FGF19 Blood Levels and Synthesis in Patients With Primary Bile Acid Diarrhea. *Am J Gastroenterol* 2016; **111**: 423-432 [PMID: 26511111 DOI: 10.1038/nrgastro.2015.111]

- 26856750 DOI: 10.1038/ajg.2015.424]
- 25 **Walters JR.** Bile acid diarrhoea and FGF19: new views on diagnosis, pathogenesis and therapy. *Nat Rev Gastroenterol Hepatol* 2014; **11**: 426-434 [PMID: 24662279 DOI: 10.1038/nrgastro.2014.32]
- 26 **Reiche M,** Bachmann A, Lössner U, Blüher M, Stumvoll M, Fasshauer M. Fibroblast growth factor 19 serum levels: relation to renal function and metabolic parameters. *Horm Metab Res* 2010; **42**: 178-181 [PMID: 20013647 DOI: 10.1055/s-0029-1243249]
- 27 **Gälman C,** Angelin B, Rudling M. Pronounced variation in bile acid synthesis in humans is related to gender, hypertriglyceridaemia and circulating levels of fibroblast growth factor 19. *J Intern Med* 2011; **270**: 580-588 [PMID: 22003820 DOI: 10.1111/j.1365-2796.2011.02466.x]

P- Reviewer: Munck LK, Walters JRF, Wenzl HH
S- Editor: Wang XJ **L- Editor:** A **E- Editor:** Huang Y





Published by **Baishideng Publishing Group Inc**
7901 Stoneridge Drive, Suite 501, Pleasanton, CA 94588, USA
Telephone: +1-925-223-8242
Fax: +1-925-223-8243
E-mail: bpgoffice@wjgnet.com
Help Desk: <http://www.f6publishing.com/helpdesk>
<http://www.wjgnet.com>



ISSN 1007-9327

