

World Journal of *Gastroenterology*

World J Gastroenterol 2018 May 7; 24(17): 1825-1924



**REVIEW**

- 1825** Is it possible to stop nucleos(t)ide analogue treatment in chronic hepatitis B patients?
Moreno-Cubero E, Sánchez del Arco RT, Peña-Asensio J, Sanz de Villalobos E, Miquel J, Larrubia JR
- 1839** Emergence of immunotherapy as a novel way to treat hepatocellular carcinoma
Mukaida N, Nakamoto Y

MINIREVIEWS

- 1859** Endoscopic management of Crohn's strictures
Bessissow T, Reinglas J, Aruljothy A, Lakatos PL, Van Assche G
- 1868** Anti-integrin therapy for inflammatory bowel disease
Park SC, Jeon YT
- 1881** Olfactomedin-4 in digestive diseases: A mini-review
Wang XY, Chen SH, Zhang YN, Xu CF

ORIGINAL ARTICLE**Basic Study**

- 1888** Oral treatment with plecanatide or dolcanatide attenuates visceral hypersensitivity *via* activation of guanylate cyclase-C in rat models
Boulete IM, Thadi A, Beaufrand C, Patwa V, Joshi A, Foss JA, Eddy EP, Eutamene H, Palejwala VA, Theodorou V, Shailubhai K
- 1901** Mitochondrial pathway mediated by reactive oxygen species involvement in α -hederin-induced apoptosis in hepatocellular carcinoma cells
Li J, Wu DD, Zhang JX, Wang J, Ma JJ, Hu X, Dong WG

Retrospective Study

- 1911** Usefulness of three-dimensional visualization technology in minimally invasive treatment for infected necrotizing pancreatitis
Wang PF, Liu ZW, Cai SW, Su JJ, He L, Feng J, Xin XL, Lu SC

CASE REPORT

- 1919** Development of tenofovir disoproxil fumarate resistance after complete viral suppression in a patient with treatment-naïve chronic hepatitis B: A case report and review of the literature
Cho WH, Lee HJ, Bang KB, Kim SB, Song IH

ABOUT COVER

Editorial board member of *World Journal of Gastroenterology*, Khaled Ali Jadallah, MD, Associate Professor, Doctor, Department of Internal Medicine, King Abdullah University Hospital, Jordan University of Science and Technology, Irbid 22110, Jordan

AIMS AND SCOPE

World Journal of Gastroenterology (*World J Gastroenterol*, *WJG*, print ISSN 1007-9327, online ISSN 2219-2840, DOI: 10.3748) is a peer-reviewed open access journal. *WJG* was established on October 1, 1995. It is published weekly on the 7th, 14th, 21st, and 28th each month. The *WJG* Editorial Board consists of 642 experts in gastroenterology and hepatology from 59 countries.

The primary task of *WJG* is to rapidly publish high-quality original articles, reviews, and commentaries in the fields of gastroenterology, hepatology, gastrointestinal endoscopy, gastrointestinal surgery, hepatobiliary surgery, gastrointestinal oncology, gastrointestinal radiation oncology, gastrointestinal imaging, gastrointestinal interventional therapy, gastrointestinal infectious diseases, gastrointestinal pharmacology, gastrointestinal pathophysiology, gastrointestinal pathology, evidence-based medicine in gastroenterology, pancreatology, gastrointestinal laboratory medicine, gastrointestinal molecular biology, gastrointestinal immunology, gastrointestinal microbiology, gastrointestinal genetics, gastrointestinal translational medicine, gastrointestinal diagnostics, and gastrointestinal therapeutics. *WJG* is dedicated to become an influential and prestigious journal in gastroenterology and hepatology, to promote the development of above disciplines, and to improve the diagnostic and therapeutic skill and expertise of clinicians.

INDEXING/ABSTRACTING

World Journal of Gastroenterology (*WJG*) is now indexed in Current Contents[®]/Clinical Medicine, Science Citation Index Expanded (also known as SciSearch[®]), Journal Citation Reports[®], Index Medicus, MEDLINE, PubMed, PubMed Central and Directory of Open Access Journals. The 2017 edition of Journal Citation Reports[®] cites the 2016 impact factor for *WJG* as 3.365 (5-year impact factor: 3.176), ranking *WJG* as 29th among 79 journals in gastroenterology and hepatology (quartile in category Q2).

EDITORS FOR THIS ISSUE

Responsible Assistant Editor: *Xiang Li*
Responsible Electronic Editor: *Yan Huang*
Proofing Editor-in-Chief: *Lian-Sheng Ma*

Responsible Science Editor: *Fang-Fang Ji*
Proofing Editorial Office Director: *Ze-Mao Gong*

NAME OF JOURNAL
World Journal of Gastroenterology

ISSN
ISSN 1007-9327 (print)
ISSN 2219-2840 (online)

LAUNCH DATE
October 1, 1995

FREQUENCY
Weekly

EDITORS-IN-CHIEF
Damian Garcia-Olmo, MD, PhD, Doctor, Professor, Surgeon, Department of Surgery, Universidad Autonoma de Madrid; Department of General Surgery, Fundacion Jimenez Diaz University Hospital, Madrid 28040, Spain

Stephen C Strom, PhD, Professor, Department of Laboratory Medicine, Division of Pathology, Karolinska Institutet, Stockholm 141-86, Sweden

Andrzej S Tarnawski, MD, PhD, DSc (Med), Professor of Medicine, Chief Gastroenterology, VA Long Beach Health Care System, University of California, Irvine, CA, 5901 E. Seventh Str., Long Beach,

CA 90822, United States

EDITORIAL BOARD MEMBERS
All editorial board members resources online at <http://www.wjgnet.com/1007-9327/editorialboard.htm>

EDITORIAL OFFICE
Ze-Mao Gong, Director
World Journal of Gastroenterology
Baishideng Publishing Group Inc
7901 Stoneridge Drive, Suite 501,
Pleasanton, CA 94588, USA
Telephone: +1-925-2238242
Fax: +1-925-2238243
E-mail: editorialoffice@wjgnet.com
Help Desk: <http://www.f6publishing.com/helpdesk>
<http://www.wjgnet.com>

PUBLISHER
Baishideng Publishing Group Inc
7901 Stoneridge Drive, Suite 501,
Pleasanton, CA 94588, USA
Telephone: +1-925-2238242
Fax: +1-925-2238243
E-mail: bpgoffice@wjgnet.com
Help Desk: <http://www.f6publishing.com/helpdesk>
<http://www.wjgnet.com>

PUBLICATION DATE
May 7, 2018

COPYRIGHT
© 2018 Baishideng Publishing Group Inc. Articles published by this Open-Access journal are distributed under the terms of the Creative Commons Attribution Non-commercial License, which permits use, distribution, and reproduction in any medium, provided the original work is properly cited, the use is non commercial and is otherwise in compliance with the license.

SPECIAL STATEMENT
All articles published in journals owned by the Baishideng Publishing Group (BPG) represent the views and opinions of their authors, and not the views, opinions or policies of the BPG, except where otherwise explicitly indicated.

INSTRUCTIONS TO AUTHORS
Full instructions are available online at <http://www.wjgnet.com/bpg/gerinfo/204>

ONLINE SUBMISSION
<http://www.f6publishing.com>

Endoscopic management of Crohn's strictures

Talat Bessissow, Jason Reinglas, Achuthan Aruljothy, Peter L Lakatos, Gert Van Assche

Talat Bessissow, Jason Reinglas, Achuthan Aruljothy, Peter L Lakatos, Division of Gastroenterology, Department of Medicine, McGill University Health Center, Montreal, QC H3G1A4, Canada

Peter L Lakatos, 1st Department of Medicine, Semmelweis University, Budapest 1085, Hungary

Gert Van Assche, Division of Gastroenterology and Hepatology, University Hospitals Leuven, Belgium and University of Leuven, Leuven 3000, Belgium

ORCID number: Talat Bessissow (0000-0003-2610-1910); Jason Reinglas (0000-0001-5455-260X); Achuthan Aruljothy (0000-0003-3896-983X); Peter L Lakatos (0000-0002-3948-6488); Gert Van Assche (0000-0003-0401-4664).

Author contributions: All authors equally contributed to this paper with conception and design of the study, literature review and analysis, drafting, critical revision, editing, and final approval of the final revision.

Conflict-of-interest statement: None.

Open-Access: This article is an open-access article which was selected by an in-house editor and fully peer-reviewed by external reviewers. It is distributed in accordance with the Creative Commons Attribution Non Commercial (CC BY-NC 4.0) license, which permits others to distribute, remix, adapt, build upon this work non-commercially, and license their derivative works on different terms, provided the original work is properly cited and the use is non-commercial. See: <http://creativecommons.org/licenses/by-nc/4.0/>

Manuscript source: Invited manuscript

Correspondence to: Talat Bessissow, MD, CM, FRCPC, Division of Gastroenterology, Department of Medicine, McGill University Health Center, Montreal, 1650 Cedar Avenue C7-200, Montreal, QC H3G1A4, Canada. talat.bessissow@mcgill.ca
Telephone: +1-514-9341934
Fax: +1-514-9348531

Received: March 10, 2018

Peer-review started: March 11, 2018

First decision: March 29, 2018

Revised: April 14, 2018

Accepted: April 23, 2018

Article in press: April 23, 2018

Published online: May 7, 2018

Abstract

Symptomatic intestinal strictures develop in more than one third of patients with Crohn's disease (CD) within 10 years of disease onset. Strictures can be inflammatory, fibrotic or mixed and result in a significant decline in quality of life, frequently requiring surgery for palliation of symptoms. Patients under the age of 40 with perianal disease are more likely to suffer from disabling ileocolonic disease thus may have a greater risk for fibrostenotic strictures. Treatment options for fibrostenotic strictures are limited to endoscopic and surgical therapy. Endoscopic balloon dilatation (EBD) appears to be a safe, less invasive and effective alternative modality to replace or defer surgery. Serious complications are rare and occur in less than 3% of procedures. For non-complex strictures without adjacent fistulization or perforation that are less than 5 cm in length, EBD should be considered as first-line therapy. The aim of this review is to present the current literature on the endoscopic management of small bowel and colonic strictures in CD, which includes balloon dilatation, adjuvant techniques of intralesional injection of steroids and anti-tumor necrosis factor, and metal stent insertion. Short and long-term outcomes, complications and safety of EBD will be discussed.

Key words: Endoscopy; Crohn's disease; Stricture; Stenosis; Inflammatory bowel disease; Endoscopic balloon dilation

© **The Author(s) 2018.** Published by Baishideng Publishing Group Inc. All rights reserved.

Core tip: Endoscopic balloon dilation (EBD) for Crohn's disease-related fibrostenotic strictures has been recognized as a safe, and less invasive intervention with rare

complications that occur in less than 3% of procedures. EBD can replace or defer surgery and help avoid frequent intestinal resections, which result in short bowel syndrome and impair quality of life. For non-complex strictures without adjacent fistulization or perforation that are less than 5 cm in length, EBD should be considered as first-line therapy. In this review we discuss safety, short and long-term outcomes, as well as adjuvant techniques of intralesional injection of steroids, anti-tumor necrosis factor, and metal stent insertion.

Bessissow T, Reinglas J, Aruljothy A, Lakatos PL, Van Assche G. Endoscopic management of Crohn's strictures. *World J Gastroenterol* 2018; 24(17): 1859-1867 Available from: URL: <http://www.wjgnet.com/1007-9327/full/v24/i17/1859.htm> DOI: <http://dx.doi.org/10.3748/wjg.v24.i17.1859>

INTRODUCTION

Intestinal strictures are a common complication of Crohn's disease (CD) affecting one-third of the patient population within 10 years of disease onset. This number, however, is likely under-reported^[1,2]. In general, CD strictures are classified into inflammatory, fibrotic or mixed, although all symptomatic inflammatory strictures likely have some component of fibrosis and vice-versa^[2,3]. Risk factors and predictors of intestinal strictures to date are clinical, environmental, genetic or endoscopic parameters^[4] (Table 1). Although no clinical factors exist which can accurately predict the stricturing phenotype of CD, there do exist factors which may predict the likelihood of small bowel disease and a disabling disease course thus indirectly may suggest an increased risk for the development of fibrostenotic disease. These factors include the presence of perianal disease, age of CD diagnosis less than 40 years old and the need for steroids during the first flare^[4,5]. Patients frequently complain of progressive post-prandial abdominal pain, bloating, nausea, vomiting and weight loss. The diagnosis of intestinal strictures usually coincides with a spiraling decline in quality of life and results in surgery in 75% of patients at least once during their lifetime^[1]. CD patients will frequently undergo multiple bowel resections over their lifetime that repeatedly exposes them to immediate and long-term post-operative complications such as anastomotic leaks with intra-abdominal sepsis, short bowel syndrome, and adhesions with recurrent bowel obstructions^[2,6].

The pathogenesis of CD complications develops from chronic accumulation of inflammatory bowel damage variably leading to stricture, fistula and/or abscess formation^[2]. Stricture development, although not fully understood, involves the progressive deposition of extracellular matrix protein (ECM) produced by myofibroblasts at variable sites of the bowel being injured by chronically uncontrolled relapsing and remitting transmural inflammation^[7]. During chronic intestinal

inflammation, the baseline release of profibrotic cytokines (e.g., IL-4 and IL-13) increases over time further accelerating the process of excessive matrix deposition^[7,8]. There may also exist a point where inflammation is no longer required to trigger fibrosis. As ECM is deposited during chronic inflammation, the bowel wall becomes stiffer. Bowel wall stiffness acts independently as a mesenchymal cell activator, resulting in ongoing myofibroblast stimulation, thus progressive fibrotic stenosis^[9].

Treatment options for fibrostenotic strictures are limited to endoscopic and surgical therapy (i.e., stricturoplasty and small bowel resection)^[10]. Fortunately, most *de novo* strictures form in the ileum and ileocolic regions, which are accessible by ileocolonoscopy or balloon-assisted enteroscopy^[11]. Although pharmacotherapy may delay the time before operative management, it has not been shown to prevent it^[12]. Approximately 80% of patients will have their first bowel resection 10 years following their diagnosis of CD^[2]. To date no specific intestinal anti-fibrotic therapy exists, nor has any immunosuppressant or biologic therapy been shown to prevent stricture formation.

The following review presents the current data on the endoscopic management of small bowel and colonic strictures in CD. Short and long-term outcomes, complications and a description of the procedure will be discussed.

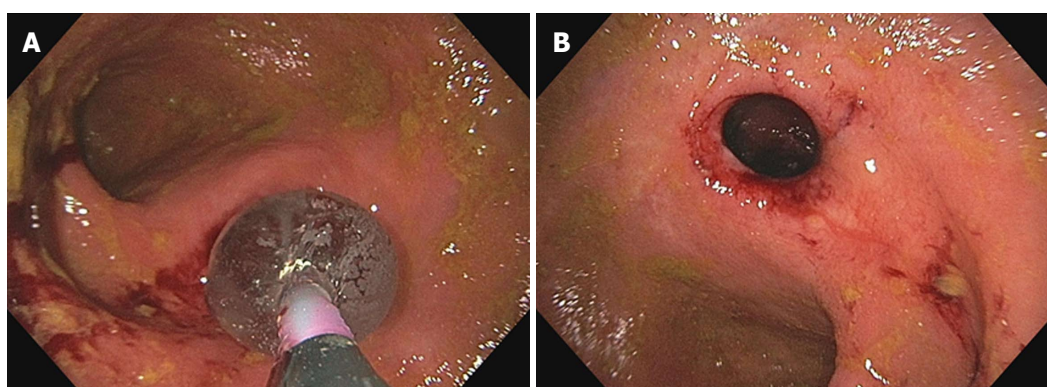
EFFICACY OF ENDOSCOPIC BALLOON DILATION

Endoscopic balloon dilation (EBD) is a minimally invasive bowel-length preserving mean of managing symptomatic CD patients with short fibrotic strictures (Figure 1). EBD has become an established modality of therapy and often plays an important role in delaying or acting as a bridge to surgery^[10,13]. The most common location of the small bowel to undergo EBD using a colonoscope is the distal ileum or at the ileocolonic anastomosis of a patient following a small bowel resection^[14]. Strictures located in the distal duodenum to proximal jejunum or distal jejunum to proximal ileum may be accessed with ante- or retrograde enteroscopy, respectively^[15].

Short- and long-term efficacy has been inconsistently defined in studies^[13]. In general, short-term efficacy has been described as the technical success of the procedure or the ability to traverse the dilated area freely with the endoscope immediately after dilatation^[13,16]. Long-term efficacy, in most studies, has been described as the time elapsed until another intervention (either surgical or endoscopic) is required^[2,13,16]. Despite the lack of a formal definition, excellent short- and moderate long-term efficacy of EBD for CD strictures has been documented in many studies^[14,16,17]. Table 2 shows a summary of published studies on EBD using conventional colonoscopy in CD patients. In a systematic review and descriptive

Table 1 Risk factors and predictors of fibrostenosing Crohn's disease

Clinical ^[4]	Age at diagnosis < 40 yr
	Perianal disease at diagnosis
	Need for steroids during first flare
	Small bowel disease location
Environmental ^[4]	Prior appendectomy
Endoscopic ^[4]	Smoking
Genetic ^[4]	Deep mucosal ulcerations
	Nucleotide oligomerisation domain 2 (<i>NOD2</i>) variants
	Janus-associated kinase 2 (<i>JAK2</i>)
	Caspase-recruitment domain 15 (<i>CARD15</i>)
	<i>NOD2/CARD15</i> mutations on both chromosomes
	TNF superfamily 15 (<i>TNFSF15</i>) in Asians
	5T5T in the <i>MMP3</i> gene
	rs1363670
Serological ^[4]	Antimicrobial antibodies
	anti- <i>Saccharomyces cerevisiae</i> antibodies (ASCA) IgA in Asians

**Figure 1** Endoscopic balloon dilatation of ileocolonic anastomosis (A) and endoscopic appearance post endoscopic dilatation (B).

pooled analysis of 12 studies conducted between 1991 to 2013 evaluating 1463 CD patients who underwent 3213 EBD procedures, the technical success rate was 89% with an associated relief of clinical symptoms in 81% of patients^[14]. The majority of strictures were ileal (98.6%) at anastomotic sites (62%), which were 2 cm or less. However, the recurrence rate of strictures was high. At the 36.6 mo median follow-up, 47.5% of patients had symptomatic recurrence and 28.6% of all patients had required surgical intervention. This study concluded that the chance of requiring repeat EBD or surgical intervention at 2 years was 73.5% and 42.9%, respectively^[14]. Another large recent systematic review with meta-analysis involving 1089 patients (2664 EBDs) across 25 studies revealed similar results^[17]. The technical success rate was 92.3% with a reported symptomatic response rate of 70.4%. The proportion of patients requiring a repeat dilation after 1 and 2 years was 31.6% (160/506) and 25.9% (117/451), respectively. Most patients within 5 years required recurrent dilations (80%) and/or surgical interventions (75%)^[17]. Of interest is the lower symptomatic success rate as compared to the technical success rate across studies. This likely occurred due to a lack of a standardized

means of reporting technical and clinical efficacy and/or a superimposed process existing that contributed to the patient's symptoms (e.g., ongoing inflammation, intestinal bacterial overgrowth, IBS, etc.)^[10]. Despite this discrepancy, the short-term clinical success rate remains high.

In the setting of small bowel strictures not in reach of the enteroscope or colonoscope, the double balloon enteroscope can be used in an antegrade or retrograde fashion for diagnostic and/or therapeutic intervention^[15]. Although there are only a few small studies which have evaluated its use in dilating small bowel CD strictures, the results were positive^[18,19]. Nishida *et al.*^[20] performed a retrospective review on their center's experience with dilating small bowel strictures between 2006 to 2015. Overall, small bowel dilation using the double balloon enteroscope was found to be successful but there was a greater risk for requiring surgery in patients with multiple strictures as compared to those with a single stricture (adjusted hazard ratio, 14.94; 95%CI: 1.91-117.12; $P = 0.010$)^[20]. As such, a single stricture but not necessarily multiple strictures may be a good indication for considering dilation using the double balloon enteroscope.

Table 2 Summary of published studies on endoscopic balloon for Crohn's disease strictures

Authors	Published year	No. of patients	Anastomotic strictures (%)	Maximum balloon caliber (mm)	Technical success (%)	Clinical efficacy (%)	Major complication (%)
Blomberg <i>et al</i> ^[52]	1991	27	100	25	100	67	0
Williams <i>et al</i> ^[53]	1991	7	71	20	71	71	0
Breysem <i>et al</i> ^[54]	1992	18	78	18	89	50	0
Cockuyt <i>et al</i> ^[55]	1995	55	67	20	85	62	8
Ramboer <i>et al</i> ^[56]	1995	13	69	18	100	100	0
Matsui <i>et al</i> ^[57]	2000	55	43	20	86	78	2
Dear <i>et al</i> ^[58]	2001	22	95	18	100	73	0
Brooker <i>et al</i> ^[59]	2003	14	79	20	100	79	0
Morini <i>et al</i> ^[60]	2003	43	67	18	79	42	0
Sabate <i>et al</i> ^[61]	2003	38	68	25	84	53	3
Thomas-Gibson <i>et al</i> ^[62]	2003	59	90	18	73	41	3
Singh <i>et al</i> ^[63]	2005	17	35	20	100	76	18
Aljouni <i>et al</i> ^[64]	2006	37	37	20	90	87	3
Ferlitsch <i>et al</i> ^[65]	2006	46	59	20	85	66	4
Nomura <i>et al</i> ^[66]	2006	16	35	20	94	65	6
Foster <i>et al</i> ^[67]	2008	24	41	20	92	NA	13
Hoffman <i>et al</i> ^[68]	2008	25	57	20	100	52	16
Stienecker <i>et al</i> ^[69]	2009	25	42	18	97	94	3
Mueller <i>et al</i> ^[70]	2010	55	23	18	95	76	2
Thienpont <i>et al</i> ^[71]	2010*	138	84	18	97	76	3
Scimeca <i>et al</i> ^[72]	2011	37	90	20	84	89	0
Gustavsson <i>et al</i> ^[51]	2012	178	80	25	89	64	11
Karstensen <i>et al</i> ^[73]	2012	23	24	15	83	74	1.9
De'Angelis <i>et al</i> ^[74]	2013	26	52	18	100	93	2
Endo <i>et al</i> ^[75]	2013	30	36	20	94	64	10
Honzawa <i>et al</i> ^[76]	2013	25	21	20	88	62	12
Nanda <i>et al</i> ^[77]	2013	31	100	18	100	45	0
Atreja <i>et al</i> ^[78]	2014	128	48	20	83	67	3
Bhalme <i>et al</i> ^[79]	2014	79	61	20	95	77	0
Hagel <i>et al</i> ^[80]	2014	77	57	20	55	65	10
Krauss <i>et al</i> ^[81]	2014	20	25	18	100	NA	14
Ding <i>et al</i> ^[82]	2016	54	100	20	89	82	2

Clinical efficacy was defined according to each study (*i.e.*, resolution of obstructive symptoms after dilation with the avoidance of surgery or additional intervention). Technical success was defined by successful passage of the endoscope or colonoscope immediately after dilation. Clinical efficacy was defined as the resolution of obstructive symptoms after dilation with the avoidance of surgery. Major complications (calculated per number of dilations) included were perforations, bleeding, intra-abdominal abscesses or fistulas. NA: Not available.

PREDICTORS OF SUCCESSFUL ENDOSCOPIC DILATATION

Factors that are predictive of a successful EBD include short straight strictures in-line with the bowel lumen distal to the duodenum, which are non-ulcerated in a location without any adjacent abscess and at least 5 cm from a fistula orifice^[21,22]. Strictures located in the duodenum were found to have a 5 fold increased hazard for time to shorter surgery as compared to strictures located in the jejunum/ileum or colon (HR = 4.7, $P = 0.038$; HR = 5.6, $P = 0.03$; respectively)^[23]. Additionally, a stricture length ≤ 5 cm was associated with a lower chance of requiring surgical intervention following EBD (HR = 2.5, 95%CI: 1.4-4.4; $P = 0.002$). For every 1 cm increase in stricture length, the risk for surgery increased by 8% ($P = 0.005$)^[23]. In contrast to popular belief, anastomotic strictures have been associated with poorer short-term outcomes than *de novo* strictures^[23,24]. This was highlighted in the aforementioned review by Bettenworth *et al*^[14] which documented a lower technical success rate

for post-surgical strictures as compared to native strictures (OR = 2.3, $P < 0.001$). Similarly, a recent study published by the Cleveland Clinic group after performing a retrospective review on 307 patients who had undergone either EBD or surgical resection for an ileocolonic anastomotic stricture had worse short-term outcomes (*i.e.*, technical success) but similar long-term outcomes as compared to the aforementioned studies evaluating EBD of *de novo* strictures^[24]. Of the 176 patients who had undergone EBD, the technical success rate was 86% (range 71% to 100%) with a long-term clinical efficacy, defined as an avoidance of surgery, of 58% over a follow-up period of 33 mo^[24]. The presence of active inflammation identified on endoscopy, elevated CRP, medical treatment after dilation, cigarette smoking and intralesional steroid injection have demonstrated conflicting results with respect to the need for surgery and successful EBD^[2,17,23,24].

ENDOSCOPIC ADJUVANT TECHNIQUES

Intralesional injection of steroids has been demon-

Table 3 Practical considerations

Predictors favoring successful dilation ^[11,22-25]	Symptomatic predominantly fibrotic stricture Short (≤ 5 cm) stricture Single straight stricture Stricture distal to the duodenum Anastomotic stricture more favorable than de novo stricture First dilation Lack of a superimposed process contributing to symptoms (<i>e.g.</i> , SIBO or IBS)
Risk factors for complications ^[22-25]	Predominantly inflammatory stricture without medical optimization Stricture greater than 5 cm Multiple small bowel strictures Strictures caused by extrinsic compression (<i>e.g.</i> , adhesions) Fistulization within 5 cm of the area to be dilated Adjacent perforation or intra-abdominal collection Complete small bowel obstruction Tortuous or tethered small bowel or significant stricture angulation Duodenal stricture
¹ Short term outcome ^[15,18]	85%-95% (technical success), 70%-80% (clinical response)
² Long term outcome ^[15,18]	32% (year 1 post dilation), 80% (year 5 post dilation)
³ Complication rate ^[25,45]	1%-4%

¹Short term outcome refers to the time elapsed immediately after the dilation takes place; technical success refers to the ability to successfully complete the dilation; clinical response refers to the symptomatic improvement of the patient immediately following the dilation; ²Long term outcome refers to the percentage of patients requiring a repeat intervention; ³Complication rate encompasses only major complications requiring urgent intervention such as bleeding, perforation and infection.

strated to be effective for peptic, corrosive, anastomotic or post-radiotherapy fibrotic strictures^[25]. However, strong evidence for the use of intralesional injection of steroids in CD is lacking^[25-28]. Studies that have evaluated its use in CD have used the formulation triamcinolone due to its rapid onset of action and long-lasting duration of effectiveness of 3-4 wk^[29]. Only two small randomized placebo controlled studies have been performed evaluating the use of intralesional steroids versus saline injection after failing medical therapy and EBD. The first study conducted in 2007, included 13 adult patients with short (≤ 5 cm) ileocolonic anastomotic strictures^[30]. Five of the seven patients in the intervention group required re-dilation after the procedure and one patient had a complication versus one of six in the placebo group required re-dilation. There was no significant difference with respect to success of the procedure between groups^[30]. This trial was stopped early due to the trend toward harm and remains the influential study behind the current American College of Gastroenterology and British Society of Gastroenterology position statements against the routine use of intralesional steroids^[31,32]. The second study published in 2010 included 29 pediatric patients with short ileal or colonic strictures (12 anastomotic, 17 *de novo*)^[33]. In contrast, this study did demonstrate a reduction in time to re-dilation and surgery in the intervention group. Within the sub-group of patients evaluated in a recent large systematic review evaluating the management of CD strictures, intralesional steroid injection did not improve outcomes^[33]. Similarly, a review conducted in 2013 summarizing the findings from five retrospective case-series evaluating the use of intralesional steroids in CD patients concluded the data to be contradictory and limited^[34].

Although controversial, intralesional injection of anti-tumor necrosis factor has been evaluated in patients with small bowel and colonic CD strictures with promising results, but concerns related to immunization may limit its potential as a therapeutic option^[35,36]. One small case series evaluated the effect of a 90-120 mg intralesional injection of infliximab in three symptomatic patients with colonic CD strictures. All three patients had an improved endoscopic appearance of the stricture as well as relief of their obstructive symptoms for at least four months following the injection^[35]. Similarly, another small case series evaluating intralesional injections of 40 mg of infliximab into small bowel CD strictures combined with EBD in six patients was associated with improved symptoms and a reduction in their modified simple endoscopic score for Crohn's disease (SES-CD)^[37]. The results of a larger randomized controlled trial evaluating the efficacy of performing intralesional injections of adalimumab into intestinal CD strictures are awaited^[38].

Endoscopic metal stent insertion has been attempted in few patients with CD strictures. Although the technical success rate has been reportedly high, major complications such as bowel perforation, stent migration and fistulization was reported in 67% of patients^[39]. Additionally, in order to avoid stent impaction, most studies suggest removing the stent after one month^[40-42]. One small prospective cohort study concluded the risk for complications was too high to suggest the use of endoscopic metal stents as a treatment option for CD strictures after evaluating the data from 11 patients at their center^[40]. The use of biodegradable instead of metal stents has been evaluated recently in a case-series last year involving six patients with intestinal and colonic CD strictures. Although technical success was good,

premature stent failure occurred in all of the patients^[43].

SAFETY OF ENDOSCOPIC BALLOON DILATION

Although EBD is a minimally invasive procedure, bowel perforation and severe bleeding has been reported in most large studies^[17,23,24]. In the aforementioned review by Bettenworth *et al.*^[14], major complications requiring hospitalization occurred in 2.8% of patients. Similarly, another large systematic review evaluating 24 non-randomized studies including 1163 patients found the rate of iatrogenic perforation to be 3%^[44]. The rate for major complications including infection and hemorrhage in this study was 4%^[44]. In a study directly comparing EBD to surgical intervention for the management of intestinal CD strictures, perforation occurred in 1.1% of the patients in the EBD group whereas the post-operative complication rate (*e.g.*, intra-abdominal sepsis) was 8.8%^[24]. Despite these significant complications, no deaths have been reported to date. Since benign or inflammatory intestinal strictures are indistinguishable from early adenocarcinoma on imaging, there exists a risk that malignancy may be missed when EBD is performed instead of surgical excision^[3]. Population based studies have suggested a greater risk for small bowel malignancy in patients with longstanding CD. Several case reports exist documenting the development of small bowel malignancy following stricturoplasty and bypassed loops^[45-51]. As such, biopsies of the stricture should occur prior to dilation^[22]. There has been no evidence to suggest obtaining biopsies prior to EBD increases the risk for perforation.

CONCLUSION

EBD remains a safe and effective modality of treating CD strictures in appropriately selected patients. Although it may not be able to prevent operative management in all patients, it can significantly delay it. For an isolated intestinal fibrostenotic CD stricture less than or equal to 5 cm in length without adjacent fistulization or perforation, EBD should be considered as first-line therapy (Table 3).

REFERENCES

- 1 Cosnes J, Cattan S, Blain A, Beaugerie L, Carbonnel F, Parc R, Gendre JP. Long-term evolution of disease behavior of Crohn's disease. *Inflamm Bowel Dis* 2002; **8**: 244-250 [PMID: 12131607 DOI: 10.1097/00054725-200207000-00002]
- 2 Rieder F, Zimmermann EM, Remzi FH, Sandborn WJ. Crohn's disease complicated by strictures: a systematic review. *Gut* 2013; **62**: 1072-1084 [PMID: 23626373 DOI: 10.1136/gutjnl-2012-304353]
- 3 Bettenworth D, Nowacki TM, Cordes F, Buerke B, Lenze F. Assessment of stricturing Crohn's disease: Current clinical practice and future avenues. *World J Gastroenterol* 2016; **22**: 1008-1016 [PMID: 26811643 DOI: 10.3748/wjg.v22.i3.1008]
- 4 Rieder F, Lawrence IC, Leite A, Sans M. Predictors of fibrostenotic Crohn's disease. *Inflamm Bowel Dis* 2011; **17**: 2000-2007 [PMID: 21308880 DOI: 10.1002/ibd.21627]
- 5 Burke JP, Mulsow JJ, O'Keane C, Docherty NG, Watson RW, O'Connell PR. Fibrogenesis in Crohn's disease. *Am J Gastroenterol* 2007; **102**: 439-448 [PMID: 17156147 DOI: 10.1111/j.1572-0241.2006.01010.x]
- 6 Shivananda S, Hordijk ML, Pena AS, Mayberry JF. Crohn's disease: risk of recurrence and reoperation in a defined population. *Gut* 1989; **30**: 990-995 [PMID: 2759493 DOI: 10.1136/gut.30.7.990]
- 7 Fiocchi C, Lund PK. Themes in fibrosis and gastrointestinal inflammation. *Am J Physiol Gastrointest Liver Physiol* 2011; **300**: G677-G683 [PMID: 21415411 DOI: 10.1152/ajpgi.00104.2011]
- 8 Graham MF, Diegelmann RF, Elson CO, Lindblad WJ, Gottschalk N, Gay S, Gay R. Collagen content and types in the intestinal strictures of Crohn's disease. *Gastroenterology* 1988; **94**: 257-265 [PMID: 3335305 DOI: 10.1016/0016-5085(88)90411-8]
- 9 Wells RG. The role of matrix stiffness in regulating cell behavior. *Hepatology* 2008; **47**: 1394-1400 [PMID: 18307210 DOI: 10.1002/hep.22193]
- 10 Gionchetti P, Dignass A, Danese S, Magro Dias FJ, Rogler G, Lakatos PL, Adamina M, Ardizzone S, Buskens CJ, Sebastian S, Laureti S, Sampietro GM, Vucelic B, van der Woude CJ, Barreiro-de Acosta M, Maaser C, Portela F, Vavricka SR, Gomollón F; ECCO. 3rd European Evidence-based Consensus on the Diagnosis and Management of Crohn's Disease 2016: Part 2: Surgical Management and Special Situations. *J Crohns Colitis* 2017; **11**: 135-149 [PMID: 27660342 DOI: 10.1093/ecco-jcc/jjw169]
- 11 Louis E, Collard A, Oger AF, Degroote E, Aboul Nasr El Yafi FA, Belaiche J. Behaviour of Crohn's disease according to the Vienna classification: changing pattern over the course of the disease. *Gut* 2001; **49**: 777-782 [PMID: 11709511 DOI: 10.1136/gut.49.6.777]
- 12 Cosnes J, Nion-Larmurier I, Beaugerie L, Afchain P, Tiert E, Gendre JP. Impact of the increasing use of immunosuppressants in Crohn's disease on the need for intestinal surgery. *Gut* 2005; **54**: 237-241 [PMID: 15647188 DOI: 10.1136/gut.2004.045294]
- 13 Klag T, Wehkamp J, Goetz M. Endoscopic Balloon Dilation for Crohn's Disease-Associated Strictures. *Clin Endosc* 2017; **50**: 429-436 [PMID: 29017297 DOI: 10.5946/ce.2017.147]
- 14 Bettenworth D, Gustavsson A, Atreja A, Lopez R, Tysk C, van Assche G, Rieder F. A Pooled Analysis of Efficacy, Safety, and Long-term Outcome of Endoscopic Balloon Dilation Therapy for Patients with Stricture Crohn's Disease. *Inflamm Bowel Dis* 2017; **23**: 133-142 [PMID: 28002130 DOI: 10.1097/MIB.0000000000000988]
- 15 Tharian B, Caddy G, Tham TC. Enteroscopy in small bowel Crohn's disease: A review. *World J Gastrointest Endosc* 2013; **5**: 476-486 [PMID: 24147191 DOI: 10.4253/wjge.v5.i10.476]
- 16 Hirai F. Current status of endoscopic balloon dilation for Crohn's disease. *Intest Res* 2017; **15**: 166-173 [PMID: 28522945 DOI: 10.5217/ir.2017.15.2.166]
- 17 Morar PS, Faiz O, Warusavitarne J, Brown S, Cohen R, Hind D, Abercrombie J, Raguath K, Sanders DS, Arnott I, Wilson G, Bloom S, Arebi N; Crohn's Stricture Study (CroSS) Group. Systematic review with meta-analysis: endoscopic balloon dilatation for Crohn's disease strictures. *Aliment Pharmacol Ther* 2015; **42**: 1137-1148 [PMID: 26358739 DOI: 10.1111/apt.13388]
- 18 Gill RS, Kaffes AJ. Small bowel stricture characterization and outcomes of dilatation by double-balloon enteroscopy: a single-centre experience. *Therap Adv Gastroenterol* 2014; **7**: 108-114 [PMID: 24790641 DOI: 10.1177/1756283X13513995]
- 19 Fukumoto A, Tanaka S, Yamamoto H, Yao T, Matsui T, Iida M, Goto H, Sakamoto C, Chiba T, Sugano K. Diagnosis and treatment of small-bowel stricture by double balloon endoscopy. *Gastrointest Endosc* 2007; **66**: S108-S112 [PMID: 17709019 DOI: 10.1016/j.gie.2007.02.027]
- 20 Nishida Y, Hosomi S, Yamagami H, Yukawa T, Nagami Y, Tanaka F, Kamata N, Tanigawa T, Shiba M, Watanabe T, Tominaga K, Fujiwara Y, Arakawa T. Analysis of the Risk Factors of Surgery after Endoscopic Balloon Dilation for Small Intestinal Strictures in Crohn's Disease Using Double-balloon Endoscopy. *Intern Med* 2017; **56**: 2245-2252 [PMID: 28794359 DOI: 10.2169/

- internalmedicine.8224-16]
- 21 **Chen M**, Shen B. Endoscopic Therapy in Crohn's Disease: Principle, Preparation, and Technique. *Inflamm Bowel Dis* 2015; **21**: 2222-2240 [PMID: 26284298 DOI: 10.1097/MIB.0000000000000433]
 - 22 **Rieder F**, Latella G, Magro F, Yuksel ES, Higgins PD, Di Sabatino A, de Bruyn JR, Rimola J, Brito J, Bettenworth D, van Assche G, Bemelman W, d'Hoore A, Pellino G, Dignass AU. European Crohn's and Colitis Organisation Topical Review on Prediction, Diagnosis and Management of Fibrostenosing Crohn's Disease. *J Crohns Colitis* 2016; **10**: 873-885 [PMID: 26928961 DOI: 10.1093/ecco-jcc/jjw055]
 - 23 **Bettenworth D**, Rieder F. Medical therapy of stricturing Crohn's disease: what the gut can learn from other organs - a systematic review. *Fibrogenesis Tissue Repair* 2014; **7**: 5 [PMID: 24678903 DOI: 10.1186/1755-1536-7-5]
 - 24 **Lian L**, Stocchi L, Remzi FH, Shen B. Comparison of Endoscopic Dilation vs Surgery for Anastomotic Stricture in Patients With Crohn's Disease Following Ileocolonic Resection. *Clin Gastroenterol Hepatol* 2017; **15**: 1226-1231 [PMID: 27816758 DOI: 10.1016/j.cgh.2016.10.030]
 - 25 **Nelson RS**, Hernandez AJ, Goldstein HM, Saca A. Treatment of irradiation esophagitis. Value of hydrocortisone injection. *Am J Gastroenterol* 1979; **71**: 17-23 [PMID: 433887]
 - 26 **Kochhar R**, Poornachandra KS. Intraleisional steroid injection therapy in the management of resistant gastrointestinal strictures. *World J Gastrointest Endosc* 2010; **2**: 61-68 [PMID: 21160692 DOI: 10.4253/wjge.v2.i2.61]
 - 27 **Kochhar R**, Makharia GK. Usefulness of intraleisional triamcinolone in treatment of benign esophageal strictures. *Gastrointest Endosc* 2002; **56**: 829-834 [PMID: 12447293 DOI: 10.1016/S0016-5107(02)70355-6]
 - 28 **Ramage JI Jr**, Rumalla A, Baron TH, Pochron NL, Zinsmeister AR, Murray JA, Norton ID, Diehl N, Romero Y. A prospective, randomized, double-blind, placebo-controlled trial of endoscopic steroid injection therapy for recalcitrant esophageal peptic strictures. *Am J Gastroenterol* 2005; **100**: 2419-2425 [PMID: 16279894 DOI: 10.1111/j.1572-0241.2005.00331.x]
 - 29 **Roques C**, Téot L. The use of corticosteroids to treat keloids: a review. *Int J Low Extrem Wounds* 2008; **7**: 137-145 [PMID: 18611924 DOI: 10.1177/1534734608320786]
 - 30 **East JE**, Brooker JC, Rutter MD, Saunders BP. A pilot study of intrastricture steroid versus placebo injection after balloon dilatation of Crohn's strictures. *Clin Gastroenterol Hepatol* 2007; **5**: 1065-1069 [PMID: 17627903 DOI: 10.1016/j.cgh.2007.04.013]
 - 31 **Lichtenstein GR**, Hanauer SB, Sandborn WJ; Practice Parameters Committee of American College of Gastroenterology. Management of Crohn's disease in adults. *Am J Gastroenterol* 2009; **104**: 465-83; quiz 464, 484 [PMID: 19174807 DOI: 10.1038/ajg.2008.168]
 - 32 **Carter MJ**, Lobo AJ, Travis SP; IBD Section, British Society of Gastroenterology. Guidelines for the management of inflammatory bowel disease in adults. *Gut* 2004; **53** Suppl 5: V1-16 [PMID: 15306569 DOI: 10.1136/gut.2004.043372]
 - 33 **Di Nardo G**, Oliva S, Passariello M, Pallotta N, Civitelli F, Frediani S, Gualdi G, Gandullia P, Mallardo S, Cucchiara S. Intraleisional steroid injection after endoscopic balloon dilation in pediatric Crohn's disease with stricture: a prospective, randomized, double-blind, controlled trial. *Gastrointest Endosc* 2010; **72**: 1201-1208 [PMID: 20951986 DOI: 10.1016/j.gie.2010.08.003]
 - 34 **Bevan R**, Rees CJ, Rutter MD, Macafee DAL. Review of the use of intraleisional steroid injections in the management of ileocolonic Crohn's strictures. *Frontline Gastroenterol* 2013; **4**: 238-243 [PMID: 28839732 DOI: 10.1136/flgastro-2012-100297]
 - 35 **Swaminath A**, Lichtiger S. Dilation of colonic strictures by intraleisional injection of infliximab in patients with Crohn's colitis. *Inflamm Bowel Dis* 2008; **14**: 213-216 [PMID: 18022870 DOI: 10.1002/ibd.20318]
 - 36 **Sorrentino D**, Avellini C, Beltrami CA, Pasqual E, Zearo E. Selective effect of infliximab on the inflammatory component of a colonic stricture in Crohn's disease. *Int J Colorectal Dis* 2006; **21**: 276-281 [PMID: 15951989 DOI: 10.1007/s00384-005-0739-0]
 - 37 **Hendel J**, Karstensen JG, Vilmann P. Serial intraleisional injections of infliximab in small bowel Crohn's strictures are feasible and might lower inflammation. *United European Gastroenterol J* 2014; **2**: 406-412 [PMID: 25360319 DOI: 10.1177/2050640614547805]
 - 38 ClinicalTrials.gov [Internet]. Bethesda (MD): National Library of Medicine (US). 2013 Nov 18. Identifier: NCT01986127, A Randomized, Double-blinded, Placebo-controlled Study on the Effects of Adalimumab Intraleisional Intestinal Strictures of Crohn's Disease Patients; [cited Dec 29, 2017]. Available from: URL: <https://clinicaltrials.gov/ct2/show/study/NCT01986127> ClinicalTrials.gov
 - 39 **Levine RA**, Wasvary H, Kadro O. Endoprosthetic management of refractory ileocolonic anastomotic strictures after resection for Crohn's disease: report of nine-year follow-up and review of the literature. *Inflamm Bowel Dis* 2012; **18**: 506-512 [PMID: 21542067 DOI: 10.1002/ibd.21739]
 - 40 **Attar A**, Maunoury V, Vahedi K, Vernier-Massouille G, Vida S, Bulois P, Colombel JF, Bouhnik Y; GETAID. Safety and efficacy of extractible self-expandable metal stents in the treatment of Crohn's disease intestinal strictures: a prospective pilot study. *Inflamm Bowel Dis* 2012; **18**: 1849-1854 [PMID: 22161935 DOI: 10.1002/ibd.22844]
 - 41 **Branche J**, Attar A, Vernier-Massouille G, Bulois P, Colombel JF, Bouhnik Y, Maunoury V. Extractible self-expandable metal stent in the treatment of Crohn's disease anastomotic strictures. *Endoscopy* 2012; **44** Suppl 2 UCTN: E325-E326 [PMID: 23012003 DOI: 10.1055/s-0032-1309854]
 - 42 **Loras C**, Pérez-Roldán F, Gornals JB, Barrio J, Igea F, González-Huix F, González-Carro P, Pérez-Miranda M, Espiñós JC, Fernández-Bañares F, Esteve M. Endoscopic treatment with self-expanding metal stents for Crohn's disease strictures. *Aliment Pharmacol Ther* 2012; **36**: 833-839 [PMID: 22966851 DOI: 10.1111/apt.12039]
 - 43 **Karstensen JG**, Christensen KR, Brynskov J, Rønholdt C, Vilmann P, Hendel J. Biodegradable stents for the treatment of bowel strictures in Crohn's disease: technical results and challenges. *Endosc Int Open* 2016; **4**: E296-E300 [PMID: 27004247 DOI: 10.1055/s-0042-101940]
 - 44 **Navaneethan U**, Lourdasamy V, Njei B, Shen B. Endoscopic balloon dilation in the management of strictures in Crohn's disease: a systematic review and meta-analysis of non-randomized trials. *Surg Endosc* 2016; **30**: 5434-5443 [PMID: 27126619 DOI: 10.1007/s00464-016-4902-1]
 - 45 **Menon AM**, Mirza AH, Moolla S, Morton DG. Adenocarcinoma of the small bowel arising from a previous strictureplasty for Crohn's disease: report of a case. *Dis Colon Rectum* 2007; **50**: 257-259 [PMID: 17180254 DOI: 10.1007/s10350-006-0771-3]
 - 46 **Partridge SK**, Hodin RA. Small bowel adenocarcinoma at a strictureplasty site in a patient with Crohn's disease: report of a case. *Dis Colon Rectum* 2004; **47**: 778-781 [PMID: 15037927 DOI: 10.1007/s10350-003-0101-y]
 - 47 **Barwood N**, Platell C. Case report: adenocarcinoma arising in a Crohn's stricture of the jejunum. *J Gastroenterol Hepatol* 1999; **14**: 1132-1134 [PMID: 10574144 DOI: 10.1046/j.1440-1746.1999.02020.x]
 - 48 **Jaskowiak NT**, Michelassi F. Adenocarcinoma at a strictureplasty site in Crohn's disease: report of a case. *Dis Colon Rectum* 2001; **44**: 284-287 [PMID: 11227948 DOI: 10.1007/BF02234306]
 - 49 **Collier PE**, Turowski P, Diamond DL. Small intestinal adenocarcinoma complicating regional enteritis. *Cancer* 1985; **55**: 516-521 [PMID: 3965106]
 - 50 **Ribeiro MB**, Greenstein AJ, Heimann TM, Yamazaki Y, Aufses AH Jr. Adenocarcinoma of the small intestine in Crohn's disease. *Surg Gynecol Obstet* 1991; **173**: 343-349 [PMID: 1948581]
 - 51 **Gustavsson A**, Magnuson A, Blomberg B, Andersson M, Halfvarson J, Tysk C. Endoscopic dilation is an efficacious and safe treatment of intestinal strictures in Crohn's disease. *Aliment Pharmacol Ther* 2012; **36**: 151-158 [PMID: 22612326 DOI: 10.1111/j.1365-2036.2012.05146.x]
 - 52 **Blomberg B**, Rolny P, Järnerot G. Endoscopic treatment of

- anastomotic strictures in Crohn's disease. *Endoscopy* 1991; **23**: 195-198 [PMID: 1915133 DOI: 10.1055/s-2007-1010654]
- 53 **Williams AJ**, Palmer KR. Endoscopic balloon dilatation as a therapeutic option in the management of intestinal strictures resulting from Crohn's disease. *Br J Surg* 1991; **78**: 453-454 [PMID: 2032105]
 - 54 **Breysem Y**, Janssens JF, Coremans G, Vantrappen G, Hendrickx G, Rutgeerts P. Endoscopic balloon dilation of colonic and ileo-colonic Crohn's strictures: long-term results. *Gastrointest Endosc* 1992; **38**: 142-147 [PMID: 1568610 DOI: 10.1016/S0016-5107(92)70379-4]
 - 55 **Couckuyt H**, Gevers AM, Coremans G, Hiele M, Rutgeerts P. Efficacy and safety of hydrostatic balloon dilatation of ileocolonic Crohn's strictures: a prospective longterm analysis. *Gut* 1995; **36**: 577-580 [PMID: 7737567 DOI: 10.1136/gut.36.4.577]
 - 56 **Ramboer C**, Verhamme M, Dhondt E, Huys S, Van Eygen K, Vermeire L. Endoscopic treatment of stenosis in recurrent Crohn's disease with balloon dilation combined with local corticosteroid injection. *Gastrointest Endosc* 1995; **42**: 252-255 [PMID: 7498692 DOI: 10.1016/S0016-5107(95)70101-X]
 - 57 **Matsui T**, Ikeda K, Tsuda S, Yao K, Sou S, Satoh S, Hatakeyama S, Matake H, Sakurai T, Yao T. Long-term outcome of endoscopic balloon dilation in obstructive gastrointestinal Crohn's disease: a prospective long-term study. *Diagn Ther Endosc* 2000; **6**: 67-75 [PMID: 18493528 DOI: 10.1155/DTE.6.67]
 - 58 **Dear KL**, Hunter JO. Colonoscopic hydrostatic balloon dilatation of Crohn's strictures. *J Clin Gastroenterol* 2001; **33**: 315-318 [PMID: 11588547 DOI: 10.1097/00004836-200110000-00012]
 - 59 **Brooker JC**, Beckett CG, Saunders BP, Benson MJ. Long-acting steroid injection after endoscopic dilation of anastomotic Crohn's strictures may improve the outcome: a retrospective case series. *Endoscopy* 2003; **35**: 333-337 [PMID: 12664391 DOI: 10.1055/s-2003-38145]
 - 60 **Morini S**, Hassan C, Lorenzetti R, Zullo A, Cerro P, Winn S, Giustini M, Taggi F. Long-term outcome of endoscopic pneumatic dilatation in Crohn's disease. *Dig Liver Dis* 2003; **35**: 893-897 [PMID: 14703886 DOI: 10.1016/j.dld.2003.06.001]
 - 61 **Sabaté JM**, Villarejo J, Bouhnik Y, Allez M, Gornet JM, Vahedi K, Modigliani R, Lémann M. Hydrostatic balloon dilatation of Crohn's strictures. *Aliment Pharmacol Ther* 2003; **18**: 409-413 [PMID: 12940926 DOI: 10.1046/j.1365-2036.2003.01715.x]
 - 62 **Thomas-Gibson S**, Brooker JC, Hayward CM, Shah SG, Williams CB, Saunders BP. Colonoscopic balloon dilation of Crohn's strictures: a review of long-term outcomes. *Eur J Gastroenterol Hepatol* 2003; **15**: 485-488 [PMID: 12702904 DOI: 10.1097/01.meg.0000059110.41030.bc]
 - 63 **Singh VV**, Draganov P, Valentine J. Efficacy and safety of endoscopic balloon dilation of symptomatic upper and lower gastrointestinal Crohn's disease strictures. *J Clin Gastroenterol* 2005; **39**: 284-290 [PMID: 15758621 DOI: 10.1097/01.mcg.0000155128.31208.44]
 - 64 **Ajlouni Y**, Iser JH, Gibson PR. Endoscopic balloon dilatation of intestinal strictures in Crohn's disease: safe alternative to surgery. *J Gastroenterol Hepatol* 2007; **22**: 486-490 [PMID: 17376038 DOI: 10.1111/j.1440-1746.2006.04764.x]
 - 65 **Ferlitsch A**, Reinisch W, Püspök A, Dejaco C, Schillinger M, Schöfl R, Pötzi R, Gangl A, Vogelsang H. Safety and efficacy of endoscopic balloon dilation for treatment of Crohn's disease strictures. *Endoscopy* 2006; **38**: 483-487 [PMID: 16767583 DOI: 10.1055/s-2006-924999]
 - 66 **Nomura E**, Takagi S, Kikuchi T, Negoro K, Takahashi S, Kinouchi Y, Hiwatashi N, Shimosegawa T. Efficacy and safety of endoscopic balloon dilation for Crohn's strictures. *Dis Colon Rectum* 2006; **49**: S59-S67 [PMID: 17106817 DOI: 10.1007/s10350-006-0685-0]
 - 67 **Foster EN**, Quiros JA, Prindiville TP. Long-term follow-up of the endoscopic treatment of strictures in pediatric and adult patients with inflammatory bowel disease. *J Clin Gastroenterol* 2008; **42**: 880-885 [PMID: 18645528 DOI: 10.1097/MCG.0b013e3181354440]
 - 68 **Hoffmann JC**, Heller F, Faiss S, von Lampe B, Kroesen AJ, Wahnschaffe U, Schulzke JD, Zeitz M, Bojarski C. Through the endoscope balloon dilation of ileocolonic strictures: prognostic factors, complications, and effectiveness. *Int J Colorectal Dis* 2008; **23**: 689-696 [PMID: 18338175 DOI: 10.1007/s00384-008-0461-9]
 - 69 **Stienecker K**, Gleichmann D, Neumayer U, Glaser HJ, Tonus C. Long-term results of endoscopic balloon dilatation of lower gastrointestinal tract strictures in Crohn's disease: a prospective study. *World J Gastroenterol* 2009; **15**: 2623-2627 [PMID: 19496192 DOI: 10.3748/wjg.15.2623]
 - 70 **Mueller T**, Rieder B, Bechtner G, Pfeiffer A. The response of Crohn's strictures to endoscopic balloon dilation. *Aliment Pharmacol Ther* 2010; **31**: 634-639 [PMID: 20047581 DOI: 10.1111/j.1365-2036.2009.04225.x]
 - 71 **Thienpont C**, D'Hoore A, Vermeire S, Demedts I, Bisschops R, Coremans G, Rutgeerts P, Van Assche G. Long-term outcome of endoscopic dilatation in patients with Crohn's disease is not affected by disease activity or medical therapy. *Gut* 2010; **59**: 320-324 [PMID: 19840991 DOI: 10.1136/gut.2009.180182]
 - 72 **Scimeca D**, Moccia F, Cottone M, Montalbano LM, D'Amico G, Olivo M, Orlando R, Orlando A. Efficacy and safety of endoscopic balloon dilation of symptomatic intestinal Crohn's disease strictures. *Dig Liver Dis* 2011; **43**: 121-125 [PMID: 20561831 DOI: 10.1016/j.dld.2010.05.001]
 - 73 **Karstensen JG**, Hendel J, Vilmann P. Endoscopic balloon dilatation for Crohn's strictures of the gastrointestinal tract is feasible. *Dan Med J* 2012; **59**: A4471 [PMID: 22759846]
 - 74 **de'Angelis N**, Carra MC, Borrelli O, Bizzarri B, Vincenzi F, Fornaroli F, De Caro G, de'Angelis GL. Short- and long-term efficacy of endoscopic balloon dilation in Crohn's disease strictures. *World J Gastroenterol* 2013; **19**: 2660-2667 [PMID: 23674873 DOI: 10.3748/wjg.v19.i17.2660]
 - 75 **Endo K**, Takahashi S, Shiga H, Kakuta Y, Kinouchi Y, Shimosegawa T. Short and long-term outcomes of endoscopic balloon dilatation for Crohn's disease strictures. *World J Gastroenterol* 2013; **19**: 86-91 [PMID: 23326167 DOI: 10.3748/wjg.v19.i1.86]
 - 76 **Honzawa Y**, Nakase H, Matsuura M, Higuchi H, Toyonaga T, Matsumura K, Yoshino T, Okazaki K, Chiba T. Prior use of immunomodulatory drugs improves the clinical outcome of endoscopic balloon dilation for intestinal stricture in patients with Crohn's disease. *Dig Endosc* 2013; **25**: 535-543 [PMID: 23363364 DOI: 10.1111/den.12029]
 - 77 **Nanda K**, Courtney W, Keegan D, Byrne K, Nolan B, O'Donoghue D, Mulcahy H, Doherty G. Prolonged avoidance of repeat surgery with endoscopic balloon dilatation of anastomotic strictures in Crohn's disease. *J Crohns Colitis* 2013; **7**: 474-480 [PMID: 22898397 DOI: 10.1016/j.crohns.2012.07.019]
 - 78 **Atreja A**, Aggarwal A, Dwivedi S, Rieder F, Lopez R, Lashner BA, Brzezinski A, Vargo JJ, Shen B. Safety and efficacy of endoscopic dilation for primary and anastomotic Crohn's disease strictures. *J Crohns Colitis* 2014; **8**: 392-400 [PMID: 24189349 DOI: 10.1016/j.crohns.2013.10.001]
 - 79 **Bhalme M**, Sarkar S, Lal S, Bodger K, Baker R, Willert RP. Endoscopic balloon dilatation of Crohn's disease strictures: results from a large United kingdom series. *Inflamm Bowel Dis* 2014; **20**: 265-270 [PMID: 24374876 DOI: 10.1097/01.MIB.0000439067.76964.53]
 - 80 **Hagel AF**, Hahn A, Dauth W, Matzel K, Konturek PC, Neurath MF, Raithel M. Outcome and complications of endoscopic balloon dilations in various types of ileocaecal and colonic stenosis in patients with Crohn's disease. *Surg Endosc* 2014; **28**: 2966-2972 [PMID: 24853850 DOI: 10.1007/s00464-014-3559-x]
 - 81 **Krauss E**, Agaimy A, Gottfried A, Maiss J, Weidinger T, Albrecht H, Hartmann A, Hohenberger W, Neurath MF, Kessler H, Mudter J. Long term follow up of through-the-scope balloon dilation as compared to strictureplasty and bowel resection of intestinal strictures in crohn's disease. *Int J Clin Exp Pathol* 2014; **7**: 7419-7431 [PMID: 25550777]
 - 82 **Ding NS**, Yip WM, Choi CH, Saunders B, Thomas-Gibson S, Arebi N, Humphries A, Hart A. Endoscopic Dilatation of Crohn's Anastomotic Strictures is Effective in the Long Term, and Escalation of Medical Therapy Improves Outcomes in the Biologic

Era. *J Crohns Colitis* 2016; **10**: 1172-1178 [PMID: 26971054 DOI:

10.1093/ecco-jcc/jjw072]

P- Reviewer: Gangl A, M'Koma A, Souza JL, Wittmann T
S- Editor: Gong ZM **L- Editor:** A **E- Editor:** Huang Y





Published by **Baishideng Publishing Group Inc**
7901 Stoneridge Drive, Suite 501, Pleasanton, CA 94588, USA
Telephone: +1-925-223-8242
Fax: +1-925-223-8243
E-mail: bpgoffice@wjgnet.com
Help Desk: <http://www.f6publishing.com/helpdesk>
<http://www.wjgnet.com>



ISSN 1007-9327

