

World Journal of *Clinical Cases*

World J Clin Cases 2018 September 6; 6(9): 233-307



MINIREVIEWS

- 233 Hepatitis B virus-persistent infection and innate immunity defect: Cell-related or virus-related?
Tang J, Wu ZY, Dai RJ, Ma J, Gong GZ
- 242 Diagnostic value of imaging examinations in patients with primary hepatocellular carcinoma
Li XH, Liang Q, Chen TW, Wang J, Zhang XM

ORIGINAL ARTICLE

Basic Study

- 249 Impact of sorafenib on epidural fibrosis: An immunohistochemical study
Tanriverdi O, Erdogan U, Tanik C, Yilmaz I, Gunaldi O, Adilay HU, Arslanhan A, Eseoglu M

SYSTEMATIC REVIEWS

- 259 Conversion therapy and suitable timing for subsequent salvage surgery for initially unresectable hepatocellular carcinoma: What is new?
Zhang ZF, Luo YJ, Lu Q, Dai SX, Sha WH

CASE REPORT

- 274 Unexpected complication during extracorporeal membrane oxygenation support: Ventilator associated systemic air embolism
Ryu SM, Park SM
- 279 Chronic carpal tunnel syndrome caused by covert tophaceous gout: A case report
Luo PB, Zhang CQ
- 284 Case report and review of the literature of primary gastrointestinal amyloidosis diagnosed with enteroscopy and endoscopic ultrasonography
Liu YP, Jiang WW, Chen GX, Li YQ
- 291 Acetaminophen-induced acute pancreatitis: A case report and literature review
He YH, Lu L, Wang YF, Huang JS, Zhu WQ, Guo Y, Li CX, Li HM
- 296 Polycystic kidney and hepatic disease 1 gene mutations in von Meyenburg complexes: Case report
Lin S, Shang TY, Wang MF, Lin J, Ye XJ, Zeng DW, Huang JF, Zhang NW, Wu YL, Zhu YY



- 301** Clival metastasis of renal clear cell carcinoma: Case report and literature review

Zhang WQ, Bao Y, Qiu B, Wang Y, Li ZP, Wang YB

ABOUT COVER

Editorial Board Member of *World Journal of Clinical Cases*, Steven M Schwarz, MD, Professor, Department of Pediatrics, Children's Hospital at Downstate, SUNY-Downstate Medical Center, Brooklyn, NY 11203, United States

AIM AND SCOPE

World Journal of Clinical Cases (*World J Clin Cases*, *WJCC*, online ISSN 2307-8960, DOI: 10.12998) is a peer-reviewed open access academic journal that aims to guide clinical practice and improve diagnostic and therapeutic skills of clinicians.

The primary task of *WJCC* is to rapidly publish high-quality Autobiography, Case Report, Clinical Case Conference (Clinicopathological Conference), Clinical Management, Diagnostic Advances, Editorial, Field of Vision, Frontier, Medical Ethics, Original Articles, Clinical Practice, Meta-Analysis, Minireviews, Review, Therapeutics Advances, and Topic Highlight, in the fields of allergy, anesthesiology, cardiac medicine, clinical genetics, clinical neurology, critical care, dentistry, dermatology, emergency medicine, endocrinology, family medicine, gastroenterology and hepatology, geriatrics and gerontology, hematology, immunology, infectious diseases, internal medicine, obstetrics and gynecology, oncology, ophthalmology, orthopedics, otolaryngology, pathology, pediatrics, peripheral vascular disease, psychiatry, radiology, rehabilitation, respiratory medicine, rheumatology, surgery, toxicology, transplantation, and urology and nephrology.

INDEXING/ABSTRACTING

World Journal of Clinical Cases (*WJCC*) is now indexed in PubMed, PubMed Central, Science Citation Index Expanded (also known as SciSearch®), and Journal Citation Reports/Science Edition. The 2018 Edition of Journal Citation Reports cites the 2017 impact factor for *WJCC* as 1.931 (5-year impact factor: N/A), ranking *WJCC* as 60 among 154 journals in Medicine, General and Internal (quartile in category Q2).

EDITORS FOR THIS ISSUE

Responsible Assistant Editor: *Xiang Li*
Responsible Electronic Editor: *Wen-Wen Tan*
Proofing Editor-in-Chief: *Lian-Sheng Ma*

Responsible Science Editor: *Fang-Fang Ji*
Proofing Editorial Office Director: *Jin-Lei Wang*

NAME OF JOURNAL
World Journal of Clinical Cases

ISSN
ISSN 2307-8960 (online)

LAUNCH DATE
April 16, 2013

FREQUENCY
Semimonthly

EDITORS-IN-CHIEF
Sandro Vento, MD, Department of Internal Medicine, University of Botswana, Private Bag 00713, Gaborone, Botswana

EDITORIAL BOARD MEMBERS
All editorial board members resources online at <http://www.wjgnet.com/2307-8960/editorialboard.htm>

EDITORIAL OFFICE
Jin-Lei Wang, Director

World Journal of Clinical Cases
Baishideng Publishing Group Inc
7901 Stoneridge Drive, Suite 501, Pleasanton, CA 94588, USA
Telephone: +1-925-2238242
Fax: +1-925-2238243
E-mail: editorialoffice@wjgnet.com
Help Desk: <http://www.f6publishing.com/helpdesk>
<http://www.wjgnet.com>

PUBLISHER
Baishideng Publishing Group Inc
7901 Stoneridge Drive, Suite 501, Pleasanton, CA 94588, USA
Telephone: +1-925-2238242
Fax: +1-925-2238243
E-mail: bpgoffice@wjgnet.com
Help Desk: <http://www.f6publishing.com/helpdesk>
<http://www.wjgnet.com>

PUBLICATION DATE
September 6, 2018

COPYRIGHT

© 2018 Baishideng Publishing Group Inc. Articles published by this Open Access journal are distributed under the terms of the Creative Commons Attribution Non-commercial License, which permits use, distribution, and reproduction in any medium, provided the original work is properly cited, the use is non commercial and is otherwise in compliance with the license.

SPECIAL STATEMENT

All articles published in journals owned by the Baishideng Publishing Group (BPG) represent the views and opinions of their authors, and not the views, opinions or policies of the BPG, except where otherwise explicitly indicated.

INSTRUCTIONS TO AUTHORS

<http://www.wjgnet.com/bpg/gerinfo/204>

ONLINE SUBMISSION

<http://www.f6publishing.com>

Polycystic kidney and hepatic disease 1 gene mutations in von Meyenburg complexes: Case report

Su Lin, Tian-Yu Shang, Ming-Fang Wang, Jian Lin, Xiao-Jian Ye, Da-Wu Zeng, Jiao-Feng Huang, Nan-Wen Zhang, Yi-Long Wu, Yue-Yong Zhu

Su Lin, Tian-Yu Shang, Ming-Fang Wang, Da-Wu Zeng, Jiao-Feng Huang, Yi-Long Wu, Yue-Yong Zhu, Liver Research Center, the First Affiliated Hospital, Fujian Medical University, Fuzhou 350005, Fujian Province, China

Jian Lin, Department of Hepato-Biliary-Pancreatic Surgery, the First Affiliated Hospital, Fujian Medical University, Fuzhou 350005, Fujian Province, China

Xiao-Jian Ye, Department of Ultrasound, the First Affiliated Hospital, Fujian Medical University, Fuzhou 350005, Fujian Province, China

Nan-Wen Zhang, Department of Pharmacology, School of Pharmacy, Fujian Medical University, Fuzhou 350005, Fujian Province, China

ORCID number: Su Lin (0000-0001-7517-9859); Tian-Yu Shang (0000-0002-0976-8951); Ming-Fang Wang (0000-0001-7306-955X); Jian Lin (0000-0003-4584-6045); Xiao-Jian Ye (0000-0001-5563-3321); Da-Wu Zeng (0000-0003-3818-0062); Jiao-Feng Huang (0000-0003-1383-6897); Nan-Wen Zhang (0000-0002-6711-1560); Yi-Long Wu (0000-0001-8650-3458); Yue-Yong Zhu (0000-0002-0746-4911).

Author contributions: All authors designed the report and wrote the paper.

Supported by Pilot Project of Fujian Science and Technology Department, No. 2015Y0057; Fujian Medical Innovation Project, No. 2018-ZQN-54; and Science and Technology Project of Fujian Education Department, No. JAT160211.

Informed consent statement: Written informed consent was obtained from the probands and families for this study, and direct sequencing of PKHD1 was performed.

Conflict-of-interest statement: No potential conflicts of interest relevant to this article were reported.

CARE Checklist (2013) statement: The authors have read the CARE Checklist (2013), and the manuscript was prepared and revised according to the CARE Checklist (2013).

Open-Access: This article is an open-access article which was selected by an in-house editor and fully peer-reviewed by external reviewers. It is distributed in accordance with the Creative Commons Attribution Non Commercial (CC BY-NC 4.0) license, which permits others to distribute, remix, adapt, build upon this work non-commercially, and license their derivative works on different terms, provided the original work is properly cited and the use is non-commercial. See: <http://creativecommons.org/licenses/by-nc/4.0/>

Manuscript source: Unsolicited manuscript

Correspondence to: Yue-Yong Zhu, MD, PhD, Professor, Liver Research Center, the First Affiliated Hospital, Fujian Medical University, Chazhong Road 20th, Taijiang District, Fuzhou 350005, Fujian Province, China. zhuyueyong@fjmu.edu.cn
Telephone: +86-591-87981660
Fax: +86-591-87981028

Received: March 10, 2018

Peer-review started: March 10, 2018

First decision: April 18, 2018

Revised: May 4, 2018

Accepted: June 7, 2018

Article in press: June 8, 2018

Published online: September 6, 2018

Abstract

Von Meyenburg complexes (VMCs) are a rare type of ductal plate malformation. We herein report two Chinese families with VMCs, and the suspicious gene mutation of this disease. Proband A was a 62-year-old woman with abnormal echographic presentation of the liver. She received magnetic resonance imaging (MRI) examination and liver biopsy, and the results showed she had VMCs. Histologically proved hepatocellular carcinoma was found 1 year after the diagnosis of VMCs. Proband B was a 57-year-old woman with intrahepatic diffuse

lesions displayed by abdominal ultrasonography. Her final diagnoses were VMCs, congenital hepatic fibrosis, and hepatitis B surface e antigen-negative chronic hepatitis B after a series of examinations. Then, all the family members of both proband A and proband B were screened for VMCs by MRI or ultrasonography. The results showed that four of the 11 family members from two families, including two males and two females, were diagnosed with VMCs. DNA samples were extracted from the peripheral blood of those 11 individuals of two VMCs pedigrees and subjected to polymerase chain reaction amplification of the polycystic kidney and hepatic disease 1 (*PKHD1*) gene. Two different mutation loci were identified. Heterozygous mutations located in exon 32 (c.4280delG, p.Gly1427ValfsX6) in family A and exon 28 (c.3118C>T, p.Arg1040Ter) in family B were detected. We speculate that *PKHD1* gene mutations may be responsible for the development of VMCs.

Key words: Von Meyenburg complexes; Ductal plate malformations; *PKHD1*; Gene mutation; Fibrosis

© The Author(s) 2018. Published by Baishideng Publishing Group Inc. All rights reserved.

Core tip: Von Meyenburg complexes (VMCs) are a rare type of ductal plate malformation. Although generally benign, VMCs have been found to correlate with malignant diseases and progress towards adenocarcinomas. Mutations of the *PKHD1* gene have been demonstrated to cause autosomal recessive polycystic kidney disease, a type of ductal plate malformation. In this study, mutations of the *PKHD1* gene located in exon 28 and exon 32, respectively, were identified in two Chinese VMCs families, with four VMCs patients reported in total.

Lin S, Shang TY, Wang MF, Lin J, Ye XJ, Zeng DW, Huang JF, Zhang NW, Wu YL, Zhu YY. Polycystic kidney and hepatic disease 1 gene mutations in von Meyenburg complexes: Case report. *World J Clin Cases* 2018; 6(9): 296-300 Available from: URL: <http://www.wjgnet.com/2307-8960/full/v6/i9/296.htm> DOI: <http://dx.doi.org/10.12998/wjcc.v6.i9.296>

INTRODUCTION

Von Meyenburg complexes (VMCs), or biliary hamartomas, are a rare type of ductal plate malformation (DPM). Although generally benign, VMCs have been found to correlate with malignant diseases and progress towards adenocarcinomas^[1]. Family cluster of VMCs has been observed clinically, indicating a genetic background of this disease. However, the gene mutation associated with this rare disorder has not been reported until now.

Mutations of the polycystic kidney and hepatic disease 1 (*PKHD1*) gene are confirmed to incur autosomal recessive polycystic kidney disease (ARPKD), a severe type of DPMs. Epigenetic changes in the liver and bile

ducts vary from different exon mutation regions of *PKHD1*. Herein, we reported the *PKHD1* gene sequences in two families of VMCs.

CASE REPORT

Two probands with histology-proved VMCs were included in this study. None of the family members/offspring in pedigree died or had clinical full-blown ARPKD.

Pedigree 1 (VMC1): Proband A was a 62-year-old woman with no medical history, who was referred due to abnormal echographic presentation of the liver (Figure 1A, I : 2). Laboratory examinations showed 36 U/L alanine aminotransferase (ALT), 32 U/L aspartate aminotransferase (AST), 13.2 μmol/L total bilirubin, 2.22 ng/mL α-fetoprotein (AFP), positive hepatitis B surface antigen (HBsAg) and e antigen (HBeAg), and 3.13×10^6 copies/mL HBV DNA, and hepatitis C virus and human immunodeficiency virus antibodies were both negative. Magnetic resonance imaging (MRI) displayed a typical feature of VMCs (Figure 1B); however, no renal cysts were found. She denied a history of alcohol consumption or drug administration. Liver biopsy confirmed the diagnosis of VMCs and chronic hepatitis B. The woman was given entecavir for successive 6 mo, and a 1-year follow-up by MRI displayed carcinoma in the right lobe of liver (Figure 1C). The subsequent intraoperative pathology revealed a moderately differentiated hepatocellular carcinoma (HCC) and the existence of VMCs (Figure 1D). The woman reported that one of her siblings was also diagnosed with HCC and VMCs 2 years ago and died of HCC. Subsequently, her five family members received MRI scans, and VMCs were identified in two members, without renal kidney cysts seen.

Pedigree 2 (VMC2): Proband B was a previously healthy 57-year-old woman (Figure 1F, III : 2), and abdominal ultrasonography displayed intrahepatic diffuse lesions (Figure 1G and H) with no kidney cysts. Laboratory tests showed 34 U/L ALT, 32U/L AST, 10.8 μmol/L total bilirubin, 3.8 ng/mL AFP, 1310.95 IU/mL HBsAg, 0.02 s/co HBeAb, 11.57 s/co HBeAb, and < 500 copies/mL HBV-DNA viral load. She was finally diagnosed with VMCs, congenital hepatic fibrosis (CHF), and HBeAg-negative chronic hepatitis B after MRI and histopathological examinations. Liver ultrasonography was performed in three members of her family, and her husband, also her cousin (Figure 1F, III : 1), reported an abnormal echographic presentation (Figure 1H).

The method of proteinase K and phenol were applied to extracted genomic DNA from venous blood of the members. Seventy-two primers were designed (Shanghai Genesky Biotechnology Co., Ltd.; Shanghai, China), adopting an online software (http://frodo.wi.mit.edu/cgi-bin/primer3/primer3_www.cgi) to amplify exons 1-67 and the ambient introns of the *PKHD1* gene (supplementary Table 1).

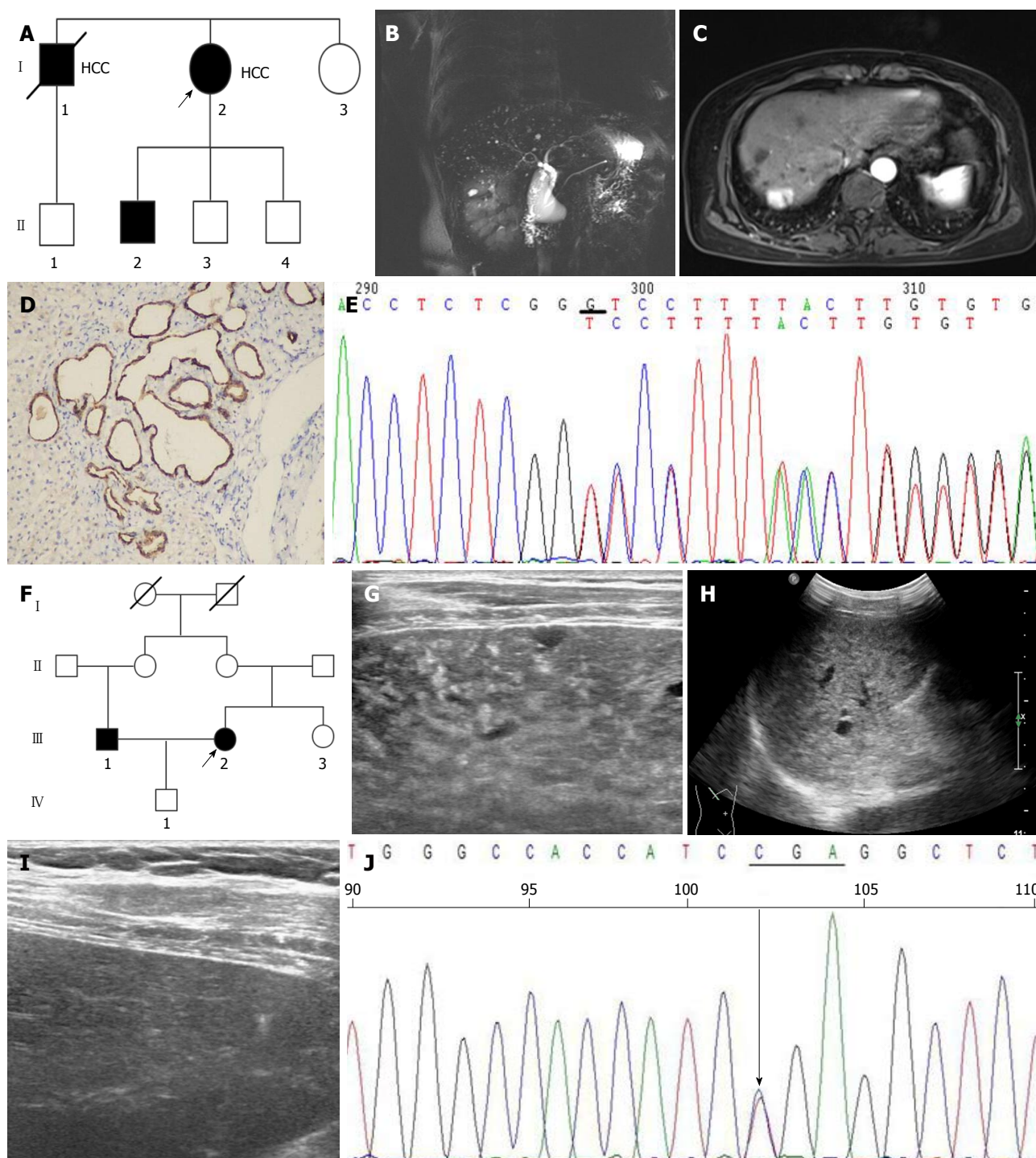


Figure 1 Genetic, clinical, and molecular findings. A: Pedigree of the family cluster with five von Meyenburg complexes (VMCs) patients of two generations, with affected status indicated by black shading. The arrow indicates the proband; B: MRI findings display a typical feature of VMCs; C: A 1-year follow-up by MRI shows carcinoma in the right lobe of liver; D: Intraoperative pathology diagnoses a moderately differentiated HCC and VMCs; E: Electropherograms show a heterozygous deletion mutation at exon 32 in the *PKHD1* gene (c.4280delG) in the proband (I : 2); F: Pedigree of the family cluster with one von Meyenburg complexes (VMCs) patient of four generations, with affected status indicated by black shading. The arrow indicates the proband; G and H: B ultrasound findings of proband B; I : B ultrasound findings of III : 1; J: Electropherograms show a heterozygous deletion mutation at exon 28 in the *PKHD1* gene (p.Arg1040Ter) in the proband B (III : 2). HCC: Hepatocellular carcinoma; MRI: Magnetic resonance imaging

Outcomes

Venous blood samples were collected for amplifying exons 1-67 and the ambient intronic sequences of the *PKHD1* gene, and genomic DNA from the proband A and II : Two were sequenced for the entire coding

region and splice sites of *PKHD1*. One heterozygous deletion mutation was detected at exon 32 in the *PKHD1* gene (c.4280delG), leading to p.Gly1427ValfsX6 at protein level (Figure 1E). Further sequencing analysis of the entire family 1 revealed that other affected

individuals (II: 1, II: 2) were also heterozygous for 4280delG, while unaffected siblings were wild type at the sequence position. Another mutation was located in exon 28 (p.Arg1040Ter) from proband B (Figure 1 I), while mutations of *PKHD1* of the remaining members of family 2 were not detected.

DISCUSSION

Ductal plate arises from single- or double-layered epithelial structures of hepatoblasts around the portal vein in the embryonic stage. Ductal plate undergoes remodeling (molding process from large bile ducts to microscopic bile ducts) and gives rise to the formation of bile ducts. DPM is defined as the developmental abnormalities considered to be resulted from the lack of ductal plate remodeling during bile duct morphogenesis. The congenital DPM diseases incorporate congenital hepatic fibrosis, autosomal dominant polycystic kidney disease (ADPKD), autosomal dominant polycystic liver disease (ADPLD), ARPKD, Caroli's disease, Caroli's syndrome, and VMCs^[2]. ADPLD is a heritable disease characterized by the malformation of medium sizes ducts, which ultimately generate cysts full of fluid. This malformation is usually underdiagnosed and genetically distinct from polycystic liver disease associated with ADPKD but with similar pathogenesis, manifestations, and management^[3]. Liver cysts are more frequently found in patients with ADPKD and adult-type polycystic liver disease, where the development of renal cysts precedes hepatic cysts^[4]. Dissimilar to ADPLD, hepatic cysts in ADPKD are originated from peribiliary bile duct glands and dilated biliary microhamartomas^[5]. By contrast, VMCs are caused from malformations of the small-sized intra-hepatic duct^[4] and are considered a histopathological lesion that transforms into cysts^[6].

Often found as small, symptomless and scattered cysts^[7], VMCs are diagnosed accidentally upon their special radiologic appearance and sometimes in a manner of either not exact abdominal symptoms or the onset of liver sepsis^[8]. A consecutive autopsy study indicates that the incidence in adults was about 5.6% and in children was 0.9%^[9]. In another biopsy series, the incidence was only 0.6%^[10]. Our previous study showed that the prevalence in patients subjected to diagnostic liver biopsy was 0.35%^[11].

Mutations of the *PKHD1* gene have been demonstrated to cause ARPKD, a type of DPM^[12]. *PKHD1* gene contains 76 exons and more than 300 types of mutation. *PKHD1* exon 2-deficient mice exhibit hepatic, pancreatic, and renal abnormalities, grossly cystic and fibrotic livers, and progressive bile duct dilatation as well as structural abnormalities and shortening of primary cilia in the bile ducts relative to the wild-type animals^[13]. Deletion of exon 40 on the *PKHD1* gene resulted in bile duct abnormality in mice^[14]. In addition, mutation of the *PKHD1* gene by disrupting exon 4 down-regulated fibrocystin/polyductin (FPC) expression, resulting in in-

trahepatic bile duct proliferation with progressive cyst formation and associated periportal fibrosis in mice^[15]. Herein, we examined the genetic mutations of two VMCs pedigrees. Two mutations (c.4280delG and c.3118C>T) of the *PKHD1* gene located on exons 32 and 28 were detected, respectively, both of which led to early termination of synthesis. These heterozygous deletion mutations may result in a single-dose deficiency of the *PKHD1* gene, which affects the development of bile ducts. The exon 28-32 of *PKHD1* gene mainly encodes the IPT/TIG (Ig-like, plexins, transcription factors), IPT_PCSR (plexins and cell surface receptors), and initial G8 (this domain is named G8 after its 8 conserved glycines) domains of the fibrocystin protein. These domains are involved in the regulation of cell growth, signal transduction, proliferation, and adhesion. Our previous study also showed that silencing of the *PKHD1* gene promoted the proliferation, migration, and invasion of human intrahepatic cholangiocarcinoma HuCCT-1 cells *via* the PI3K/Akt signaling pathway, indicating that PKHD1 may contribute to the development and progression of intrahepatic cholangiocarcinoma^[16]. It is therefore hypothesized that the protein component encoded by exon 28-32 of the *PKHD1* gene may have a closer correlation with the development of bile duct than with renal tubules. The mutation in exon 28-32 may lead to the malformations of the ductal plate alone without kidney involvement.

In summary, our report provides four cases to the literature of VMCs associated with *PKHD1* gene mutations. To be more persuasive, more clinicopathologic and molecular studies are needed to validate the findings and test the hypothesis from the present study.

ARTICLE HIGHLIGHTS

Case characteristics

A 62-year-old woman and a 57-year-old woman were both previously healthy, who were referred due to abnormal echographic presentation of the liver.

Differential diagnosis

Liver cirrhosis, metastases, microabscesses, and simple liver cysts.

Laboratory diagnosis

Proband A and B were diagnosed with chronic hepatitis B and HBeAg-negative chronic hepatitis B, respectively, by laboratory examinations of positive hepatitis B surface antigen (HBsAg), negative anti-hepatitis C virus and anti-human immuno-deficiency virus tests, and normal liver function tests.

Imaging diagnosis

Abdominal ultrasonography displayed intrahepatic diffuse lesions and magnetic resonance imaging (MRI) showed cystic lesions that shared no connection with the intra- and extra-hepatic bile duct system and were of normal size for von Meyenburg complexes (VMCs). A carcinoma in the right lobe of the liver was also found in proband A. No kidney cyst was seen in the imaging examinations of any family member.

Pathological diagnosis

Pathological diagnosis confirmed the diagnoses of hepatocellular carcinoma VMCs and chronic hepatitis B in proband A and of congenital hepatic fibrosis

(CHF) and VMCs in proband B.

Treatment

Proband A was given entecavir and complete surgical resection of the hepatocellular carcinoma lesion. Proband B did not receive any medication and was followed up regularly.

Related reports

In most of cases, VMCs are incidentally detected, focusing on the location of the disease (liver surface, extrahepatic), relative symptoms, mimicking metastatic disease or malignancy, and association with liver tumor.

Term explanation

PKHD1 gene is located on chromosome 6p12. It encodes a protein named fibrocystin/polyductin (FPC). FPC protein is involved in the maintenance of the normal tubular structure of intrahepatic bile duct epithelial cells. Mutation of PKHD1 may cause the structural and functional disorder of FPC, leading eventually to the development of renal and hepatic cysts. VMCs are benign neoplasms characterized by the disorderly arrangement of biliary epithelium, which form abnormal biliary ducts surrounded by ample fibrous stroma.

Experiences and lessons

The PKHD1 gene mutations were identified in two VMCs patients, providing new insights into the pathogenesis, diagnosis, and progression of the VMCs.

REFERENCES

- 1 Song JS, Lee YJ, Kim KW, Huh J, Jang SJ, Yu E. Cholangiocarcinoma arising in von Meyenburg complexes: report of four cases. *Pathol Int* 2008; **58**: 503-512 [PMID: 18705771 DOI: 10.1111/j.1440-1827.2008.02264.x]
- 2 Desmet VJ. Congenital diseases of intrahepatic bile ducts: variations on the theme "ductal plate malformation". *Hepatology* 1992; **16**: 1069-1083 [PMID: 1398487 DOI: 10.1002/hep.1840160434]
- 3 Qian Q, Li A, King BF, Kamath PS, Lager DJ, Huston J 3rd, Shub C, Davila S, Somlo S, Torres VE. Clinical profile of autosomal dominant polycystic liver disease. *Hepatology* 2003; **37**: 164-171 [PMID: 12500201 DOI: 10.1053/jhep.2003.50006]
- 4 Venkatanarasimha N, Thomas R, Armstrong EM, Shirley JF, Fox BM, Jackson SA. Imaging features of ductal plate malformations in adults. *Clin Radiol* 2011; **66**: 1086-1093 [PMID: 21840516 DOI: 10.1016/j.crad.2011.05.008]
- 5 Kida T, Nakanuma Y, Terada T. Cystic dilatation of peribiliary glands in livers with adult polycystic disease and livers with solitary nonparasitic cysts: an autopsy study. *Hepatology* 1992; **16**: 334-340 [PMID: 1639342 DOI: 10.1002/hep.1840160209]
- 6 Karhunen PJ. Adult polycystic liver disease and biliary microhamartomas (von Meyenburg's complexes). *Acta Pathol Microbiol Immunol Scand A* 1986; **94**: 397-400 [PMID: 3811921 DOI: 10.1111/j.1699-0463.1986.tb03011.x]
- 7 Tohmé-Noun C, Cazals D, Noun R, Menassa L, Valla D, Vilgrain V. Multiple biliary hamartomas: magnetic resonance features with histopathologic correlation. *Eur Radiol* 2008; **18**: 493-499 [PMID: 17934738 DOI: 10.1007/s00330-007-0790-z]
- 8 Sinakos E, Papalavrentios L, Chourmouzi D, Dimopoulou D, Drevelegas A, Akriviadis E. The clinical presentation of Von Meyenburg complexes. *Hippokratia* 2011; **15**: 170-173 [PMID: 22110302]
- 9 Redston MS, Wanless IR. The hepatic von Meyenburg complex: prevalence and association with hepatic and renal cysts among 2843 autopsies [corrected]. *Mod Pathol* 1996; **9**: 233-237 [PMID: 8685220]
- 10 Thommesen N. Biliary hamartomas (von Meyenburg complexes) in liver needle biopsies. *Acta Pathol Microbiol Scand A* 1978; **86**: 93-99 [PMID: 696321 DOI: 10.1111/j.1699-0463.1978.tb02019.x]
- 11 Lin S, Weng Z, Xu J, Wang MF, Zhu YY, Jiang JJ. A study of multiple biliary hamartomas based on 1697 liver biopsies. *Eur J Gastroenterol Hepatol* 2013; **25**: 948-952 [PMID: 23510964 DOI: 10.1097/MEG.0b013e32835fb9ee]
- 12 Bergmann C, Senderek J, Küpper F, Schneider F, Dornia C, Windelen E, Eggermann T, Rudnik-Schöneborn S, Kirfel J, Furu L, Onuchic LF, Rossetti S, Harris PC, Somlo S, Guay-Woodford L, Germino GG, Moser M, Büttner R, Zerres K. PKHD1 mutations in autosomal recessive polycystic kidney disease (ARPKD). *Hum Mutat* 2004; **23**: 453-463 [PMID: 15108277 DOI: 10.1002/humu.20029]
- 13 Woollard JR, Punyashtiti R, Richardson S, Masyuk TV, Whelan S, Huang BQ, Lager DJ, vanDeursen J, Torres VE, Gattone VH, LaRusso NF, Harris PC, Ward CJ. A mouse model of autosomal recessive polycystic kidney disease with biliary duct and proximal tubule dilatation. *Kidney Int* 2007; **72**: 328-336 [PMID: 17519956 DOI: 10.1038/sj.ki.5002294]
- 14 Moser M, Matthiesen S, Kirfel J, Schorle H, Bergmann C, Senderek J, Rudnik-Schöneborn S, Zerres K, Büttner R. A mouse model for cystic biliary dysgenesis in autosomal recessive polycystic kidney disease (ARPKD). *Hepatology* 2005; **41**: 1113-1121 [PMID: 15830394 DOI: 10.1002/hep.20655]
- 15 Gallagher AR, Esquivel EL, Briere TS, Tian X, Mitobe M, Menezes LF, Markowitz GS, Jain D, Onuchic LF, Somlo S. Biliary and pancreatic dysgenesis in mice harboring a mutation in Pkhd1. *Am J Pathol* 2008; **172**: 417-429 [PMID: 18202188 DOI: 10.2353/ajpath.2008.070381]
- 16 Lin S, He C, Wang MF, Wu YL, Lin J, Liu Y, Zhu YY. shRNA-mediated silencing of PKHD1 gene promotes proliferation, migration and invasion of human intrahepatic cholangiocarcinoma HuCCT-1 cells. *Int J Clin Exp Pathol* 2017; **10**: 2496-2509

P- Reviewer: Burgesser MV, Cheungpasitporn W, Rangan G
S- Editor: Ji FF L- Editor: Filipodia E- Editor: Tan WW





Published by **Baishideng Publishing Group Inc**
7901 Stoneridge Drive, Suite 501, Pleasanton, CA 94588, USA
Telephone: +1-925-223-8242
Fax: +1-925-223-8243
E-mail: bpgoffice@wjgnet.com
Help Desk: <http://www.f6publishing.com/helpdesk>
<http://www.wjgnet.com>

