

World Journal of *Transplantation*

World J Transplant 2018 October 22; 8(6): 198-236





EDITORIAL

- 198 Surgeon's perspective on short bowel syndrome: Where are we?
Marino IR, Lauro A

REVIEW

- 203 Complement-mediated renal diseases after kidney transplantation - current diagnostic and therapeutic options in *de novo* and recurrent diseases
Abbas F, El Kossi M, Kim JJ, Shaheen IS, Sharma A, Halawa A

SYSTEMATIC REVIEW

- 220 Impact of machine perfusion of the liver on post-transplant biliary complications: A systematic review
Boteon YL, Boteon AP, Attard J, Wallace L, Bhogal RH, Afford SC

CASE REPORT

- 232 Treatment of transplant renal artery pseudoaneurysm using expandable hydrogel coils: A case report and review of literature
Marie Y, Kumar A, Hinchliffe S, Curran S, Brown P, Turner D, Shrestha B

ABOUT COVER

Editorial Board Member of *World Journal of Transplantation*, Yuri L Boteon, MD, PhD, Academic Research, Doctor, Surgeon, The Liver Transplant and Hepatobiliary Surgery Unit, Queen Elizabeth Hospital Birmingham, Birmingham B15 2TT, United Kingdom

AIM AND SCOPE

World Journal of Transplantation (*World J Transplant*, *WJT*, online ISSN 2220-3230, DOI: 10.5500) is a peer-reviewed open access academic journal that aims to guide clinical practice and improve diagnostic and therapeutic skills of clinicians.

WJT covers topics concerning organ and tissue donation and preservation; tissue injury, repair, inflammation, and aging; immune recognition, regulation, effector mechanisms, and opportunities for induction of tolerance, thoracic transplantation (heart, lung), abdominal transplantation (kidney, liver, pancreas, islets), transplantation of tissues, cell therapy and islet transplantation, clinical transplantation, experimental transplantation, immunobiology and genomics, and xenotransplantation. The current columns of *WJT* include editorial, frontier, diagnostic advances, therapeutics advances, field of vision, mini-reviews, review, topic highlight, medical ethics, original articles, case report, clinical case conference (Clinicopathological conference), and autobiography.

AIM AND SCOPE

World Journal of Transplantation (*WJT*) is now abstracted and indexed in PubMed, PubMed Central, China National Knowledge Infrastructure (CNKI), and Superstar Journals Database.

EDITORS FOR THIS ISSUE

Responsible Assistant Editor: *Xiang Li*
Responsible Electronic Editor: *Yan Huang*
Proofing Editor-in-Chief: *Lian-Sheng Ma*

Responsible Science Editor: *Ying Dou*
Proofing Editorial Office Director: *Jin-Lai Wang*

NAME OF JOURNAL
World Journal of Transplantation

ISSN
ISSN 2220-3230 (online)

LAUNCH DATE
December 24, 2011

EDITOR-IN-CHIEF
Maurizio Salvadori, MD, Professor, Renal Unit, Careggi University Hospital, Florence 50139, Italy

EDITORIAL BOARD MEMBERS
All editorial board members resources online at <http://www.wjgnet.com/2220-3230/editorialboard.htm>

EDITORIAL OFFICE
Jin-Lai Wang, Director
World Journal of Transplantation
Baishideng Publishing Group Inc
7901 Stoneridge Drive, Suite 501, Pleasanton, CA 94588, USA

Telephone: +1-925-2238242
Fax: +1-925-2238243
E-mail: editorialoffice@wjgnet.com
Help Desk: <http://www.f6publishing.com/helpdesk>
<http://www.wjgnet.com>

PUBLISHER
Baishideng Publishing Group Inc
7901 Stoneridge Drive, Suite 501,
Pleasanton, CA 94588, USA
Telephone: +1-925-2238242
Fax: +1-925-2238243
E-mail: bpgoffice@wjgnet.com
Help Desk: <http://www.f6publishing.com/helpdesk>
<http://www.wjgnet.com>

PUBLICATION DATE
October 22, 2018

COPYRIGHT
© 2018 Baishideng Publishing Group Inc. Articles

published by this Open-Access journal are distributed under the terms of the Creative Commons Attribution Non-commercial License, which permits use, distribution, and reproduction in any medium, provided the original work is properly cited, the use is non commercial and is otherwise in compliance with the license.

SPECIAL STATEMENT
All articles published in journals owned by the Baishideng Publishing Group (BPG) represent the views and opinions of their authors, and not the views, opinions or policies of the BPG, except where otherwise explicitly indicated.

INSTRUCTIONS TO AUTHORS
<http://www.wjgnet.com/bpg/gerinfo/204>

ONLINE SUBMISSION
<http://www.f6publishing.com>

Treatment of transplant renal artery pseudoaneurysm using expandable hydrogel coils: A case report and review of literature

Yazin Marie, Avneesh Kumar, Sarah Hinchliffe, Simon Curran, Peter Brown, Douglas Turner, Badri Shrestha

Yazin Marie, Avneesh Kumar, Sarah Hinchliffe, Simon Curran, Badri Shrestha, Sheffield Kidney Institute, Sheffield Teaching Hospitals NHS Foundation Trust, Sheffield S5 7AU, United Kingdom

Peter Brown, Douglas Turner, Radiology Department, Sheffield Teaching Hospitals NHS Foundation Trust, Sheffield S5 7AU, United Kingdom

ORCID number: Badri Shrestha (0000-0002-7309-7080).

Author contributions: Marie Y and Shrestha B managed the patient and prepared the manuscript; Kumar A, Hinchliffe S and Curran S were involved in managing the patient and contributed to manuscript preparation; Brown P and Turner D performed radiological investigations, managed the patient and contributed to manuscript preparation.

Informed consent statement: The patient involved in this study gave his written informed consent authorizing use and disclosure of her protected health information.

Conflict-of-interest statement: All authors have no conflicts of interests to declare.

CARE Checklist (2013) statement: The authors have read the CARE Checklist (2013), and the manuscript was prepared and revised according to the CARE Checklist (2013).

Open-Access: This article is an open-access article which was selected by an in-house editor and fully peer-reviewed by external reviewers. It is distributed in accordance with the Creative Commons Attribution Non Commercial (CC BY-NC 4.0) license, which permits others to distribute, remix, adapt, build upon this work non-commercially, and license their derivative works on different terms, provided the original work is properly cited and the use is non-commercial. See: <http://creativecommons.org/licenses/by-nc/4.0/>

Manuscript source: Unsolicited manuscript

Correspondence to: Badri Shrestha, MD MS MPhil FRCS (Eng, Edin and Gen), FACS, FEBS Consultant Transplant

Surgeon, Sheffield Kidney Institute, Sheffield Teaching Hospitals NHS Foundation Trust, Herries Road, Sheffield S5 7AU, United Kingdom. shresthabm@doctors.net.uk
Telephone: +44-11-42434343
Fax: +44-11-42714604

Received: March 9, 2018

Peer-review started: March 11, 2018

First decision: March 30, 2018

Revised: April 28, 2018

Accepted: October 8, 2018

Article in press: October 8, 2018

Published online: October 22, 2018

Abstract

Transplant renal artery (TRA) pseudoaneurysm can result in bleeding, infection, graft dysfunction and graft loss. We report the management of a renal transplant recipient who presented five months after renal transplantation with deterioration of renal function, who was found to have TRA pseudoaneurysm and TRA stenosis. Both were treated radiologically by using expandable hydrogel coils (EHC) in combination with stenting. Improvement in clinical, biochemical and radiological parameters were observed after the intervention. To our knowledge, this is the first report in the transplant literature on the use of EHC for the treatment of a TRA pseudoaneurysm.

Key words: Pseudoaneurysm; Transplant renal artery; Expandable hydrogel coils; Outcomes

© **The Author(s) 2018.** Published by Baishideng Publishing Group Inc. All rights reserved.

Core tip: Transplant renal artery (TRA) pseudoaneurysm is an uncommon complication after renal transplantation, which can cause transplant dysfunction, bleeding, infection

and graft loss. Expandable hydrogel coils should be considered in the treatment of TRA pseudoaneurysm as they have been effective in our patient.

Marie Y, Kumar A, Hinchliffe S, Curran S, Brown P, Turner D, Shrestha B. Treatment of transplant renal artery pseudoaneurysm using expandable hydrogel coils: A case report and review of literature. *World J Transplant* 2018; 8(6): 232-236 Available from: URL: <http://www.wjgnet.com/2220-3230/full/v8/i6/232.htm> DOI: <http://dx.doi.org/10.5500/wjt.v8.i6.232>

INTRODUCTION

Transplant renal artery (TRA) pseudoaneurysm can result in bleeding, infection, graft dysfunction, graft loss, lower limb ischaemia, limb loss and mortality^[1]. The treatment of TRA pseudoaneurysm remains challenging. The expandable hydrogel coil (EHC) embolization system is a relatively new type of device that has been described to successfully treat intracranial and peripheral pseudoaneurysms. These are helical platinum coils coated with expandable hydrogel polymer. The hydrogel coating undergoes full expansion within 20 min attending a size between 4-5 times the size of the coils on coming in contact with blood. The stasis of the blood causes organization of thrombus, which fills the aneurysm causing complete its occlusion^[1]. To our knowledge, there is no published data in the transplant literature on the application of EHC in the treatment of TRA pseudoaneurysm. We describe the successful management of a case of TRA pseudoaneurysm using EHC and review the pertinent literature.

CASE REPORT

A 38-year-old male patient received a renal transplant (RT) of a kidney from a donation after circulatory death donor. The right donor kidney had a single renal artery on an aortic patch and the short renal vein which was elongated by using a segment of inferior vena cava. The kidney was implanted in the right iliac fossa by anastomosing the renal artery to the external iliac artery in an end-to-side fashion using continuous 5/0 prolene sutures (Ethicon Inc., United Kingdom) and renal vein to the external iliac vein in the similar fashion. An extravesical ureteroneocystostomy was performed as describe by Lich-Gregoir. The vascular anastomosis time was 45 min while the total cold ischaemic time was 15 h and 38 min. The patient received basiliximab (Sandoz, United Kingdom) and methyl prednisolone as induction therapy and tacrolimus, mycophenolate mofetil and prednisolone as maintenance immunosuppression.

The transplant had delayed graft function and required haemodialysis during the first week until renal function started to improve. The initial ultrasound scan

of the transplant kidney showed a well perfused graft with no evidence of hydronephrosis or any collection and the resistive indices (RI) were within normal limits. The renal function was stable with a serum creatinine of 136 $\mu\text{mol/L}$ and an estimated glomerular filtration rate (eGFR) of 51 mL/min per 1.73 m² at 3 mo post-transplantation.

At five months post-transplantation, on routine outpatient review, deterioration in kidney renal function with a rise in serum creatinine to 633 $\mu\text{mol/L}$ (eGFR 13 mL/min per 1.73 m²) was observed. A duplex ultrasound scan showed a well-perfused kidney with no evidence of hydronephrosis. An ultrasound-guided biopsy of the kidney, which was treated with three pulses of intravenous methyl prednisolone, showed features of acute cellular rejection. However, there was no improvement in renal function. A repeat duplex ultrasound scan showed damped flow signals on the intra-renal blood vessels with reduced RI ranging between 0.4 and 0.45. There were associated high velocities at the transplant artery origin which were suspicious of TRA stenosis. A computerized tomography (CT) scan was done which showed a 20 mm \times 25 mm pseudoaneurysm arising from the aortic patch and the TRA origin lying adjacent to the pseudoaneurysm was tightly narrowed (Figures 1 and 2). After discussion in the departmental multidisciplinary team meeting and with patient's informed consent, he underwent radiological intervention as described below.

Under ultrasound guidance, the right common femoral artery was punctured, and a 5Fr sheath was inserted. 7500 unit of heparin was administered intravenously. The dimensions of the TRA were confirmed and were found to be like those of CT scan findings. The TRA was catheterized using a size 4Fr Berenstein[®] catheter and Terumo[®] wire (Terumo Medical Corporation, United States), subsequently exchanged for a 0.014 Thruway wire (Boston Scientific Inc., Ireland) and was left in situ as a "safety wire". The left common femoral artery was punctured and a 6Fr destination sheath was placed over the aortic bifurcation. Through the ipsilateral 6Fr sheath, a 10 mm percutaneous transluminal angioplasty (PTA) balloon was placed opposite the aneurysm neck. From the 6Fr sheath, a 4Fr Cobra (Cook Medical, United States) and 2/7 Progreate[®] microcatheter (Terumo Medical Corporation, United States) were used to gain access to the aneurysm sac. Within the right external iliac artery, the PTA balloon was inflated to reduce the risk of coil prolapse and migration and the aneurysm was embolized using two Azur[®] 20 mm Framing coils (Terumo Medical Corporation, United States), and packed with Azur[®] Hydrogel Coils. The pseudoaneurysm was filled with coils and hydrogel leading to its complete occlusion. Subsequently, the stenosed transplant RA was stented using a 6 mm \times 20 mm Hippocampus stent (Medtronic, United Kingdom), which restored the patency of the stenosed renal artery and normal blood flow (Figure 3).

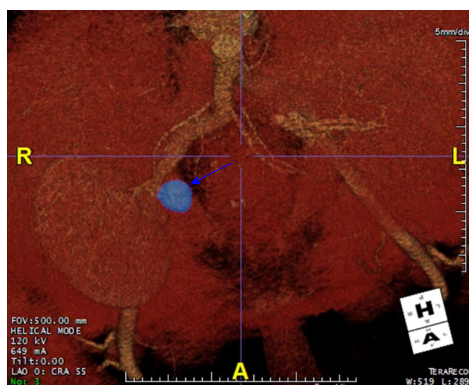


Figure 1 Computerized tomography angiogram showing a 20 mm x 25 mm pseudoaneurysm arising from the aortic patch (blue arrow).

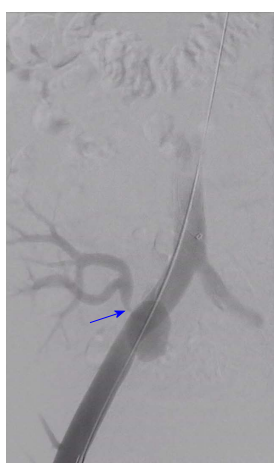

Figure 2 Angiogram showing transplant renal artery stenosis (blue arrow) due to compression caused by the pseudoaneurysm. Guide wire is present within the right common and external iliac artery.

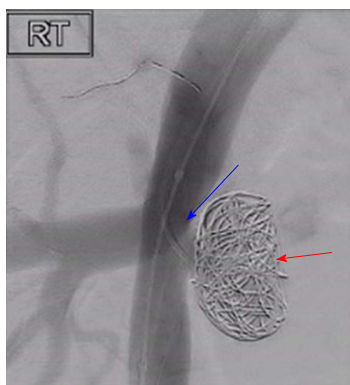


Figure 3 Successful coiling of the pseudoaneurysm (red arrow) and stenting of the transplant renal artery stenosis (blue arrow).

Following embolization of the pseudoaneurysm and stenting of the TRA, improvement in renal function occurred leading to a fall in the serum creatinine level to 159 $\mu\text{mol/L}$ (eGFR 47 mL/min per 1.73 m^2). A follow-up CT angiogram one month after the intervention showed a patent TRA with successful coiling of the pseudoaneurysm and satisfactory position of the stent

with no evidence of TRA stenosis. The patient continues to be followed up in the routine RT clinic and has a serum creatinine of 150 $\mu\text{mol/L}$ (eGFR 49 mL/min per 1.73 m^2).

DISCUSSION

Renal Transplantation remains the treatment of choice in end stage renal disease patients. Vascular complications after RT include TRA stenosis, TRA thrombosis, transplant renal vein thrombosis, arteriovenous fistula and TRA pseudoaneurysm^[2]. TRA pseudoaneurysm is an uncommon complication and can be classified anatomically as intrarenal or extrarenal based on the involvement of either TRA or iliac artery, respectively. Aetiologically, TRA pseudoaneurysms can be of infective or non-infective origin. Infective pseudoaneurysms are more common and can be of fungal (mycotic) and non-fungal (non-mycotic) origin. Amongst the infective pseudoaneurysms, *Candida albicans* and *Aspergillus* species have been reported to be the predominant microorganisms, while *Pseudomonas* species were the leading cause of non-mycotic infective pseudoaneurysms^[2-8]. Non-infective TRA pseudoaneurysms can result from injury to the arterial wall, faulty suture techniques^[9-11] or following a biopsy^[12,13].

TRA pseudoaneurysms can be asymptomatic^[14] or can present with RT dysfunction, fever, pain (mainly at the site of the transplant) or a combination of these presentations. Graft loss is a recognized complication of TRA pseudoaneurysms and sometimes bleeding from the ruptured pseudoaneurysm can lead to hemorrhagic shock or death of the patient^[8,15]. Lumbar plexopathy has been reported in a previous literature because of pressure effect of the pseudoaneurysm^[16], while malignant hypertension is a rare presentation^[17].

The choice of the modality of treatment of TRA pseudoaneurysms depends on several factors including the aetiology, haemodynamic stability of the patient, presentation, anatomy, graft function and the radiological features of the pseudoaneurysm^[18-22]. Aneurysms larger than 25 mm, progressive enlargement, deterioration of renal function or presentation with symptoms are the main indications for repair^[18]. Treatment modalities include minimally invasive techniques using mainly exclusion stents to the external iliac artery, but this may sacrifice the graft^[14]. Ultrasound-guided percutaneous thrombin injection in combination with a covered stent has been reported as a successful way of treating TRA pseudoaneurysm with preservation of renal function^[18,19].

Traditional aneurysm coiling in general can be associated with complications such as migration, non-target embolisation, inadequate filling, compaction and the technical difficulty in placing the coils leading to added risk to organs, patients and increase in cost^[23].

Expandable hydrogel technology coils have been described to treat intracranial and peripheral pseudoaneurysms successfully for number of years. The main

advantage of using EHC is related to their superior mechanical occlusion properties resulting in fewer coils deployed and a lower recurrence rate. They are also compatible with imaging modalities^[24-26].

In our case, successful radiological and clinical outcomes were achieved with return of serum creatinine to baseline within 48 h of intervention without any complication related to the RT or lower limb. We have employed EHC system to treat TRA pseudoaneurysm, achieved excellent volumetric filling and targeted embolisation and subsequently deployed a stent leading to restoration of transplant renal function to its normality. It offers a new non-invasive technique to treat TRA pseudoaneurysms with preservation of renal grafts; therefore, it should be considered as a first line treatment modality in this clinical situation.

ARTICLE HIGHLIGHTS

Case characteristics

A 38-year-old male, who had received a deceased donor renal transplant presented with deterioration of renal function five months post-transplantation.

Clinical diagnosis

On examination, there were clinical features pointing to definitive diagnosis.

Differential diagnosis

Differential diagnosis included obstructive uropathy, acute rejection, infections, drug nephrotoxicity and transplant renal artery stenosis.

Laboratory diagnosis

The serum creatinine was significantly elevated.

Imaging diagnosis

The Duplex ultrasound scan showed reduced resistive index with high velocity flow in the renal artery suggestive of transplant renal artery stenosis. A computerized tomography angiogram showed a 20 mm × 25 mm pseudoaneurysm at the anastomosis site and stenosis of the transplant renal artery adjacent to the pseudoaneurysm.

Treatment

Endovascular embolisation of the pseudoaneurysm using expandable hydrogel coils (EHC) followed by deployment of stent lead to resolution of the pseudoaneurysm and transplant renal artery stenosis and restoration of renal function to normality.

Related reports

Follow-up of the patient was satisfactory with no adverse events related to the procedure.

Experiences and lessons

This is the first reported case of treatment of a transplant renal artery pseudoaneurysm with wide neck with the use of EHC leading to successful outcomes.

REFERENCES

- 1 **Ding YH**, Dai D, Lewis DA, Cloft HJ, Kallmes DF. Angiographic and histologic analysis of experimental aneurysms embolized with platinum coils, Matrix, and HydroCoil. *AJNR Am J Neuroradiol* 2005; **26**: 1757-1763 [PMID: 16091526]
- 2 **Aktas S**, Boyvat F, Sevmis S, Moray G, Karakayali H, Haberal M. Analysis of vascular complications after renal transplantation. *Transplant Proc* 2011; **43**: 557-561 [PMID: 21440760 DOI: 10.1016/j.transproceed.2011.01.007]
- 3 **Kountidou CS**, Stier K, Niehues SM, Lingnau A, Schostak M, Fuller TF, Lützenberg R. Successful repair of post-transplant mycotic aneurysm of iliac artery with renal graft preservation: a case report. *Urology* 2012; **80**: 1151-1153 [PMID: 22999448 DOI: 10.1016/j.urology.2012.07.048]
- 4 **Minz M**, Sharma A, Kumar S, Singh S, Shivaprakash MR, Bag S. Use of autogenous internal iliac artery for bridging the external iliac artery after excision of Aspergillus mycotic aneurysm in renal transplant recipients. *J Vasc Surg* 2011; **53**: 802-804 [PMID: 21215589 DOI: 10.1016/j.jvs.2010.10.102]
- 5 **Smeds MR**, Ofstein R, Peterson GJ, Peterson BG, Jacobs DL. Endovascular repair of a para-anastomotic pseudoaneurysm after renal autotransplantation: an alternative to open reconstruction. *Ann Vasc Surg* 2013; **27**: 110.e5-110.e8 [PMID: 23079504 DOI: 10.1016/j.avsg.2012.06.003]
- 6 **Chandak P**, Kessar N, Uwechue RU, Abboudi H, Hossain M, Harris F, Jones K, Fronck J. Successful excision of a suspected mycotic transplant renal artery patch aneurysm with renal allograft autotransplantation. *Transplantation* 2014; **97**: e25-e26 [PMID: 24492430 DOI: 10.1097/01.TP.0000438628.75848.9a]
- 7 **Orlando G**, Di Cocco P, Gravante G, D'Angelo M, Famulari A, Pisani F. Fatal hemorrhage in two renal graft recipients with multi-drug resistant *Pseudomonas aeruginosa* infection. *Transpl Infect Dis* 2009; **11**: 442-447 [PMID: 19508700 DOI: 10.1111/j.1399-3062.2009.00412.x]
- 8 **Burkey SH**, Vazquez MA, Valentine RJ. De novo renal artery aneurysm presenting 6 years after transplantation: a complication of recurrent arterial stenosis? *J Vasc Surg* 2000; **32**: 388-391 [PMID: 10918000 DOI: 10.1067/mva.2000.106943]
- 9 **Ngan CY**, Luke PP. Renal artery pseudoaneurysm of infectious etiology: a life-threatening complication after renal transplantation. *Urology* 2006; **68**: 668-669 [PMID: 16979702 DOI: 10.1016/j.urology.2006.04.017]
- 10 **Rivera M**, Villacorta J, Jiménez-Alvaro S, Quereda C. Asymptomatic large extracapsular renal pseudoaneurysm following kidney transplant biopsy. *Am J Kidney Dis* 2011; **57**: 175-178 [PMID: 21184923 DOI: 10.1053/j.ajkd.2010.07.020]
- 11 **Duwe KM**, Newhouse JH, Fayter J, Stern L, Budorick NE. Conservative management of an extrarenal pseudoaneurysm after percutaneous needle biopsy of a renal allograft. *J Ultrasound Med* 2000; **19**: 281-283 [PMID: 10759353 DOI: 10.7863/jum.2000.19.4.281]
- 12 **Antonopoulos IM**, Yamacake KG, Tiseo BC, Carnevale FC, Z E Jr, Nahas WC. Renal pseudoaneurysm after core-needle biopsy of renal allograft successfully managed with superselective embolization. *Int Braz J Urol* 2016; **42**: 165-167 [PMID: 27136484 DOI: 10.1590/S1677-5538.IBJU.2014.0315]
- 13 **Patrono D**, Verhelst R, Buemi A, Darius T, Godefroid N, Mourad M. Presentation and management of mycotic pseudoaneurysm after kidney transplantation. *Transpl Infect Dis* 2015; **17**: 129-136 [PMID: 25620391 DOI: 10.1111/tid.12346]
- 14 **Orlic P**, Vukas D, Drescik I, Ivancic A, Blecic G, Budiselic B, Velcic G, Maricic A, Oguic R, Mozetic V, Valencic M, Sotosek S, Vukas D Jr. Vascular complications after 725 kidney transplantations during 3 decades. *Transplant Proc* 2003; **35**: 1381-1384 [PMID: 12826165 DOI: 10.1016/S0041-1345(03)00506-2]
- 15 **Luzzio CC**, Waclawik AJ, Gallagher CL, Knechtle SJ. Iliac artery pseudoaneurysm following renal transplantation presenting as lumbosacral plexopathy. *Transplantation* 1999; **67**: 1077-1078 [PMID: 10221499 DOI: 10.1097/00007890-199904150-00026]
- 16 **Madhav D**, Kumar P, Mohan C, Vijay, Mahesh U; Anusha; Suneetha; Suryaprakash. Candida-associated pseudo-aneurysm of the transplant renal artery presenting as malignant hypertension and managed successfully without nephrectomy. *Saudi J Kidney Dis Transpl* 2015; **26**: 1000-1005 [PMID: 26354578 DOI: 10.4103/1319-2442.164591]
- 17 **Bracale UM**, Santangelo M, Carbone F, Del Guercio L, Maurea

- S, Porcellini M, Bracale G. Anastomotic pseudoaneurysm complicating renal transplantation: treatment options. *Eur J Vasc Endovasc Surg* 2010; **39**: 565-568 [PMID: 20122855 DOI: 10.1016/j.ejvs.2009.12.010]
- 18 **Asztalos L**, Olvasztó S, Fedor R, Szabó L, Balázs G, Lukács G. Renal artery aneurysm at the anastomosis after kidney transplantation. *Transplant Proc* 2006; **38**: 2915-2918 [PMID: 17112863 DOI: 10.1016/j.transproceed.2006.08.115]
- 19 **Zavos G**, Pappas P, Kakisis JD, Leonardou P, Manoli E, Bokos J, Kostakis A. Endovascular repair as first-choice treatment of iliac pseudoaneurysms following renal transplantation. *Transplant Proc* 2005; **37**: 4300-4302 [PMID: 16387102 DOI: 10.1016/j.transproceed.2005.11.034]
- 20 **Kubal C**, Cacciola R, Riley P, Ready A. Internal iliac artery pseudoaneurysm following renal transplant biopsy successfully treated with endovascular stenting and thrombosis: a case report. *Transplant Proc* 2007; **39**: 1676-1678 [PMID: 17580217 DOI: 10.1016/j.transproceed.2007.03.018]
- 21 **Dimitroulis D**, Bokos J, Zavos G, Nikiteas N, Karidis NP, Katsaronis P, Kostakis A. Vascular complications in renal transplantation: a single-center experience in 1367 renal transplantations and review of the literature. *Transplant Proc* 2009; **41**: 1609-1614 [PMID: 19545690 DOI: 10.1016/j.transproceed.2009.02.077]
- 22 **Sharron JA**, Esterl RM, Washburn WK, Abrahamian GA. Surgical treatment of an extrarenal pseudoaneurysm after kidney transplantation. *Vasc Endovascular Surg* 2009; **43**: 317-321 [PMID: 19223384 DOI: 10.1177/1538574409331697]
- 23 **Sluzewski M**, van Rooij WJ, Slob MJ, Bescós JO, Slump CH, Wijnalda D. Relation between aneurysm volume, packing, and compaction in 145 cerebral aneurysms treated with coils. *Radiology* 2004; **231**: 653-658 [PMID: 15118115 DOI: 10.1148/radiol.2313030460]
- 24 **Kallmes DF**, Fujiwara NH. New expandable hydrogel-platinum coil hybrid device for aneurysm embolization. *AJNR Am J Neuroradiol* 2002; **23**: 1580-1588 [PMID: 12372752]
- 25 **Deshaias EM**, Adamo MA, Boulos AS. A prospective single-center analysis of the safety and efficacy of the hydrocoil embolization system for the treatment of intracranial aneurysms. *J Neurosurg* 2007; **106**: 226-233 [PMID: 17410704 DOI: 10.3171/jns.2007.106.2.226]
- 26 **White PM**, Lewis SC, Nahser H, Sellar RJ, Goddard T, Gholkar A; HELPS Trial Collaboration. HydroCoil Endovascular Aneurysm Occlusion and Packing Study (HELPS trial): procedural safety and operator-assessed efficacy results. *AJNR Am J Neuroradiol* 2008; **29**: 217-223 [PMID: 18184832 DOI: 10.3174/ajnr.A0936]

P- Reviewer: Koukoulaki M, Popovic DD **S- Editor:** Ji FF
L- Editor: A **E- Editor:** Huang Y





Published by **Baishideng Publishing Group Inc**
7901 Stoneridge Drive, Suite 501, Pleasanton, CA 94588, USA
Telephone: +1-925-223-8242
Fax: +1-925-223-8243
E-mail: bpgoffice@wjgnet.com
Help Desk: <http://www.f6publishing.com/helpdesk>
<http://www.wjgnet.com>

