

World Journal of *Nephrology*

World J Nephrol 2018 September 7; 7(5): 96-116



**ORIGINAL ARTICLE****Basic Study**

- 96** A small molecule fibrokinase inhibitor in a model of fibropolycystic hepatorenal disease
Paka P, Huang B, Duan B, Li JS, Zhou P, Paka L, Yamin MA, Friedman SL, Goldberg ID, Narayan P
- 108** Unique interstitial miRNA signature drives fibrosis in a murine model of autosomal dominant polycystic kidney disease
Patil A, Sweeney Jr WE, Pan CG, Avner ED

ABOUT COVER

Editorial Board Member of *World Journal of Nephrology*, Jacob A Akoh, MD, Doctor, Department of Surgery, Derriford Hospital, Plymouth PL6 8DH, United Kingdom

AIM AND SCOPE

World Journal of Nephrology (*World J Nephrol*, *WJN*, online ISSN 2220-6124, DOI: 10.5527) is a peer-reviewed open access academic journal that aims to guide clinical practice and improve diagnostic and therapeutic skills of clinicians.

WJN covers topics concerning kidney development, renal regeneration, kidney tumors, therapy of renal disease, hemodialysis, peritoneal dialysis, kidney transplantation, diagnostic imaging, evidence-based medicine, epidemiology and nursing. Priority publication will be given to articles concerning diagnosis and treatment of nephrology diseases. The following aspects are covered: Clinical diagnosis, laboratory diagnosis, differential diagnosis, imaging tests, pathological diagnosis, molecular biological diagnosis, immunological diagnosis, genetic diagnosis, functional diagnostics, and physical diagnosis; and comprehensive therapy, drug therapy, surgical therapy, interventional treatment, minimally invasive therapy, and robot-assisted therapy.

We encourage authors to submit their manuscripts to *WJN*. We will give priority to manuscripts that are supported by major national and international foundations and those that are of great basic and clinical significance.

INDEXING/ABSTRACTING

World Journal of Nephrology (*WJN*) is now abstracted and indexed in PubMed, PubMed Central, China National Knowledge Infrastructure (CNKI), and Superstar Journals Database.

EDITORS FOR THIS ISSUE

Responsible Assistant Editor: *Xiang Li*
Responsible Electronic Editor: *Han Song*
Proofing Editor-in-Chief: *Lian-Sheng Ma*

Responsible Science Editor: *Ying Dou*
Proofing Editorial Office Director: *Jin-Lei Wang*

NAME OF JOURNAL
World Journal of Nephrology

ISSN
ISSN 2220-6124 (online)

LAUNCH DATE
February 6, 2012

EDITORIAL BOARD MEMBERS
All editorial board members resources online at <http://www.wjnet.com/2220-6124/editorialboard.htm>

EDITORIAL OFFICE
Jin-Lei Wang, Director
World Journal of Nephrology
Baishideng Publishing Group Inc
7901 Stoneridge Drive,
Suite 501, Pleasanton, CA 94588, USA

Telephone: +1-925-2238242
Fax: +1-925-2238243
E-mail: editorialoffice@wjnet.com
Help Desk: <http://www.f6publishing.com/helpdesk>
<http://www.wjnet.com>

PUBLISHER
Baishideng Publishing Group Inc
7901 Stoneridge Drive,
Suite 501, Pleasanton, CA 94588, USA
Telephone: +1-925-2238242
Fax: +1-925-2238243
E-mail: bpgoffice@wjnet.com
Help Desk: <http://www.f6publishing.com/helpdesk>
<http://www.wjnet.com>

PUBLICATION DATE
September 7, 2018

COPYRIGHT

© 2018 Baishideng Publishing Group Inc. Articles published by this Open-Access journal are distributed under the terms of the Creative Commons Attribution Non-commercial License, which permits use, distribution, and reproduction in any medium, provided the original work is properly cited, the use is non commercial and is otherwise in compliance with the license.

SPECIAL STATEMENT

All articles published in journals owned by the Baishideng Publishing Group (BPG) represent the views and opinions of their authors, and not the views, opinions or policies of the BPG, except where otherwise explicitly indicated.

INSTRUCTIONS TO AUTHORS
<http://www.wjnet.com/bpg/gerinfo/204>

ONLINE SUBMISSION
<http://www.f6publishing.com>

Basic Study

A small molecule fibrokinase inhibitor in a model of fibropolycystic hepatorenal disease

Prani Paka, Brian Huang, Bin Duan, Jing-Song Li, Ping Zhou, Latha Paka, Michael A Yamin, Scott L Friedman, Itzhak D Goldberg, Prakash Narayan

Prani Paka, Brian Huang, Bin Duan, Jing-Song Li, Ping Zhou, Latha Paka, Michael A Yamin, Itzhak D Goldberg, Prakash Narayan, Department of Research and Development, Angion Biomedica Corp., Uniondale, NY 11553, United States

Scott L Friedman, Icahn School of Medicine, 1 Gustave L. Levy Place, New York, NY 10029, United States

ORCID number: Prani Paka (0000-0002-4638-8202); Brian Huang (0000-0001-8645-5142); Bin Duan (0000-0003-3302-1900); Jing-Song Li (0000-0002-7982-7152); Ping Zhou (0000-0001-9467-6834); Latha Paka (0000-0003-2795-3592); Michael A Yamin (0000-0001-6086-5047); Scott L Friedman (0000-0003-1178-6195); Itzhak D Goldberg (0000-0002-9070-6925); Prakash Narayan (0000-0002-7007-0245).

Author contributions: Narayan P, Paka P, Yamin MA, Paka L and Friedman SL substantially contributed to the conception and design of the study, acquisition, analysis and interpretation of data; Goldberg ID has contributed for funding acquisition and scientific advice; Narayan P drafted the article related to the intellectual content of the manuscript; Paka L made revisions for the reviewer's comments for the final version of the article to be published; Paka P, Huang B and Zhou P also performed *in vitro* work; Duan B and Li JS performed animal care, experimental dosing, pre and post-surgical procedures in animal models; all authors reviewed and approved the final version of the article to be published.

Institutional animal care and use committee statement: Angion's Animal Welfare Assurance # A4532-01. All the study protocols were designed to minimize pain and distress to the animals and were reviewed approved by our Angion's animal care and use committee.

Conflict-of-interest statement: Dr. Narayan reports in addition, Dr. Narayan has a patent null issued.

Data sharing statement: Angion Biomedica is a for-profit small business engaged in developing therapeutics for unmet medical needs. In keeping with corporate policy, data and research resources generated by the company are proprietary. Once all

intellectual property that results from the generation of the data and research resources is protected *via* filing of patents, data and research resources generated will be made available.

ARRIVE guidelines statement: The authors have read the ARRIVE guidelines, and the manuscript was prepared and revised according to the ARRIVE guidelines.

Open-Access: This article is an open-access article which was selected by an in-house editor and fully peer-reviewed by external reviewers. It is distributed in accordance with the Creative Commons Attribution Non Commercial (CC BY-NC 4.0) license, which permits others to distribute, remix, adapt, build upon this work non-commercially, and license their derivative works on different terms, provided the original work is properly cited and the use is non-commercial. See: <http://creativecommons.org/licenses/by-nc/4.0/>

Manuscript source: Unsolicited manuscript

Correspondence to: Prakash Narayan, PhD, Research Scientist, Department of Research and Development, Angion Biomedica Corp., 51 Charles Lindbergh Blvd., Uniondale, NY 11553, United States. pnarayan@angion.com
Telephone: +1-516-3261200

Received: March 25, 2018

Peer-review started: March 25, 2018

First decision: April 10, 2018

Revised: July 11, 2018

Accepted: August 11, 2018

Article in press: August 11, 2018

Published online: September 7, 2018

Abstract

AIM

To evaluate the novel platelet-derived growth factor receptor and vascular endothelial growth factor receptor dual kinase inhibitor ANG3070 in a polycystic kidney

disease-congenital hepatic fibrosis model.

METHODS

At 6 wk of age, PCK rats were randomized to vehicle or ANG3070 for 4 wk. At 10 wk, 24 h urine and left kidneys were collected and rats were continued on treatment for 4 wk. At 14 wk, 24 h urine was collected, rats were sacrificed, and liver and right kidneys were collected for histological evaluation. For Western blot studies, PCK rats were treated with vehicle or ANG3070 for 7 d and sacrificed approximately 30 min after the last treatments.

RESULTS

Compared to the wild-type cohort, the PCK kidney (Vehicle cohort) exhibited a marked increase in kidney and liver mass, hepato-renal cystic volume, hepato-renal fibrosis and hepato-renal injury biomarkers. Intervention with ANG3070 in PCK rats decreased kidney weight, reduced renal cystic volume and reduced total kidney hydroxyproline, indicating significantly reduced renal interstitial fibrosis compared to the PCK-Vehicle cohort. ANG3070 treatment also mitigated several markers of kidney injury, including urinary neutrophil gelatinase-associated lipocalin, kidney injury molecule-1, cystatin C and interleukin-18 levels. In addition, this treatment attenuated key indices of renal dysfunction, including proteinuria, albuminuria and serum blood urea nitrogen and creatinine, and significantly improved renal function compared to the PCK-Vehicle cohort. ANG3070 treatment also significantly decreased liver enlargement, hepatic lesions, and liver fibrosis, and mitigated liver dysfunction compared to the PCK-Vehicle cohort.

CONCLUSION

These results suggest that ANG3070 has the potential to slow disease, and may serve as a bridge toward hepato-renal transplantation in patients with fibropolycystic disease.

Key words: Congenital hepatic fibrosis; Cyst; Fibrosis; Autosomal recessive polycystic kidney disease; Kidney; Liver; Therapy

© The Author(s) 2018. Published by Baishideng Publishing Group Inc. All rights reserved.

Core tip: In autosomal recessive polycystic kidney disease (ARPKD)-congenital hepatic fibrosis (CHF), a genetically acquired and congenital disease, approximately 20-30% of affected patients succumb within the first 1-2 mo of life, with pulmonary insufficiency secondary to renal enlargement as the primary cause of death. For children, nephrectomy and dialysis or kidney liver transplant is often warranted by approximately ten years of age. Other than transplantation, there is no cure for ARPKD-CHF. We report that platelet-derived growth factor and vascular endothelial growth factor are the intermediaries between the cystic and fibrotic components of progressive fibropolycystic disease and ANG3070, a novel dual kinase inhibitor therapy that may serve as an interesting bridge

toward hepato-renal transplantation in patients with ARPKD-CHF.

Paka P, Huang B, Duan B, Li JS, Zhou P, Paka L, Yamin MA, Friedman SL, Goldberg ID, Narayan P. A small molecule fibrokinase inhibitor in a model of fibropolycystic hepatorenal disease. *World J Nephrol* 2018; 7(5): 96-107 Available from: URL: <http://www.wjgnet.com/2220-6124/full/v7/i5/96.htm> DOI: <http://dx.doi.org/10.5527/wjn.v7.i5.96>

INTRODUCTION

The highly aggressive fibropolycystic disease, autosomal recessive polycystic kidney disease (ARPKD) - congenital hepatic fibrosis (CHF), is characterized by the formation and expansion of fluid-filled cysts in the kidneys, enlargement of the kidneys and progressive fibrosis of both the kidney and the liver^[1,2]. Caroli's disease, which manifests as cystic dilatation of the intrahepatic ducts, often accompanies ARPKD-CHF^[3]. Afflicted children that survive past two years of age more often than not require renal and/or hepatic transplantation by age ten. The need for transplantation is driven as much by progressive organ dysfunction as by significant enlargement of the diseased organ(s) accompanied by severe pain^[4].

Aberrant signaling by tyrosine kinases, including platelet-derived growth factor (PDGF) and vascular endothelial growth factor (VEGF) and their receptors (R), PDGFR and VEGFR/KDR, respectively, has been implicated in the formation and expansion of renal cysts. A PDGF-driven ciliopathy and/or overexpression of PDGF in the cyst lining and adjacent tubules are thought to, in part, drive renal cystic disease^[5-7]. Cowley *et al*^[8] posited that elevated and abnormal c-myc proto-oncogene expression drives ARPKD; c-myc expression is controlled by PDGF^[9].

VEGF-driven angiogenesis is also thought to contribute to the growth of renal cysts, and inhibition of VEGFR/KDR signaling is associated with decreased tubule cell proliferation, decreased cystogenesis, and blunted renal enlargement^[10,11]. Nevertheless, the role of VEGF in fibropolycystic disease is more controversial, with at least two reports suggesting that this growth factor might be associated with disease mitigation^[12]. Aside from their roles in renal cyst formation and expansion, it is being recognized in ARPKD-CHF that aberrant PDGF and VEGF signaling are also associated with extracellular matrix deposition in the liver and kidney^[13-15].

The PCK rat model is a well-established and well-characterized model that resembles human polycystic kidney and liver disease^[16]. In the present study, we employed the PCK rat model to evaluate the therapeutic effects of ANG3070 on hepato-renal fibropolycystic disease. ANG3070 is an orally bioavailable, highly water-soluble, small molecule PDGFR and VEGFR/KDR inhibitor that binds

its target receptors with nanomolar affinity but exhibits limited interaction with other receptor tyrosine kinases as described by Panicker *et al*^[17] and Narayan *et al*^[18].

MATERIALS AND METHODS

Animal model

All studies relating to animals were approved by the Angion Biomedica animal use and care committee. Four week old male PCK/CrljCrl-Pkhd1^{pck}/Crl rats and age-matched male Sprague-Dawley (wild-type) rats were purchased from Charles River Labs (Wilmington, MA) and acclimatized for a week with a standard laboratory diet and water *ad libitum* at Angion prior to starting experiments. The PCK rat model includes ARPKD and autosomal dominant polycystic kidney disease (ADPKD). Many of the biochemical and morphological changes using these PCK rat models closely resemble human hepato-renal fibro polycystic disease^[16]. We will use the best-characterized PCK rat model to establish therapeutic efficacy and the time window of our novel dual kinase inhibitor, ANG3070. PCK rats exhibit renal pathology starting from 4 wk of age with continuous progression of hepato-renal fibropolycystic disease with aging^[16,17].

Sample size

Upon consultation with a biostatistician and based on formal power analysis, we expect a 30%-50% reduction in hepato-renal injury and pathology with ANG3070 treatment vs vehicle cohort, with a 30% standard deviation in each group and 80% power required to observe $P < 0.05$. Ten to 14 PCK rats were required for each group.

The total rats used in three separate experiments = approximately 18 wild type SD rats and 68 PCK rats. Some animals (PCK, $n = 2$; wild-type, $n = 4$) were sacrificed at 6 wk of age to confirm disease pathology. The PCK rats were then randomized to vehicle (water, $n = 14$) or ANG3070 (25 mg/kg, PO, BID; $n = 14$). Drug dose and dosing schedule was based on data (not shown) from previous studies in models of chronic kidney disease. At 10 wk of age (*i.e.*, after 4 wk of drug treatment), 24 h urine was collected, animals were anesthetized with isoflurane (2%), a midline incision was made and the left kidney was removed for analysis. Animals were then returned to their cages and allowed to recover. At 14 wk of age (*i.e.*, after 8 wk of drug dosing), 24 h urine was collected, animals were anesthetized, and the right kidney and liver were removed. For Western blot studies, 10 wk old male PCK rats were treated with vehicle or ANG3070 (25 mg/kg, PO, BID) for 7 d and sacrificed approximately 30 min after the last vehicle/drug administration. Kidneys were collected and stored in formalin and liquid N₂.

Cystic index

Cystic index (*i.e.*, the percentage of renal parenchyma occupied by cysts) was quantified using two independent blinded observers in hematoxylin and eosin (H and E)

- stained kidney sections using digital planimetry (NIS Elements Viewer) as described previously^[18]. The data from the two observers were averaged for each kidney.

Tissue and biomarker analysis

Body weight, kidney and liver masses were determined. Serum aspartate aminotransferase (AST), alanine aminotransferase (ALT), blood urea nitrogen (BUN) and serum creatinine (SCr) were measured by Northwell laboratory (New Hyde Park, NY). Proteinuria was measured using a modified Bradford and Lowry Bio-Rad protein assay and expressed as mg/24 h urine. Microalbuminuria (Abcam ELISA) was expressed as $\mu\text{g}/24 \text{ h}$ urine. Levels of neutrophil gelatinase-associated lipocalin (NGAL) (BioPorto Diagnostics, <http://www.bioparto.com>), cystatin C (R and D Systems, <http://www.rndsystems.com>), interleukin-18 (IL-18) (Biomedical Assay, <http://www.biotechist.com>) and kidney injury molecule-1 (KIM-1) (BioTrend, <http://www.biotrend.com>) were determined in urine samples using an enzyme-linked immunosorbent assay. Kidney and liver hydroxyproline, markers of tissue fibrosis, were measured from tissue homogenates^[19] and expressed as $\mu\text{g}/\text{kidney}$ or $\mu\text{g}/\text{liver}$.

Histopathology and immunohistochemistry

Formalin-fixed kidney and liver sections from PCK and/or wild-type rats were stained with Masson's trichrome or Picrosirius red to visualize collagen deposition in these tissues. The presence of multiple large and small cysts in the kidney and highly dilated irregular-shaped ducts in the liver, characteristic of this model of fibropolycystic kidney and liver disease, made it difficult to quantify fibrosis using histochemical stains. These stains therefore acted instead as a visual aid for the presence and location of matrix deposition in this model. Kidneys were also stained with anti-phospho PDGFR antibody (Antibody #3161, Cell Signaling) conjugated to horseradish peroxidase to visualize the presence and location of the activated receptor in this model of renal disease.

Western blot analysis

As described by Takikita-Suzuki *et al*^[20], the frozen kidney tissue was homogenized on ice in buffer containing Tris-HCl (20 mmol/L; pH 7.5), ethylenediamine tetraacetic acid (1 mmol/L), NaCl (140 mmol/L), Nonidet P-40 (1%), aprotinin (50 $\mu\text{g}/\text{mL}$), NaF (50 mmol/L), sodium orthovanadate (1 mmol/L) and phenylmethyl sulfonyl fluoride (1 mmol/L). Homogenized tissue was centrifuged for 30 min at 15000 rpm at 4 °C. Supernatant was collected and protein concentrations were measured using the method of Bradford. After 12% sodium dodecyl sulfate-polyacrylamide gel electrophoresis, the protein was transferred to a nylon membrane (Amersham Pharmacia Biotech, Buckinghamshire, England, United Kingdom). Blocking was performed for 2 h in phosphate-buffered saline (PBS) solution containing 5% (w/v) skim milk,

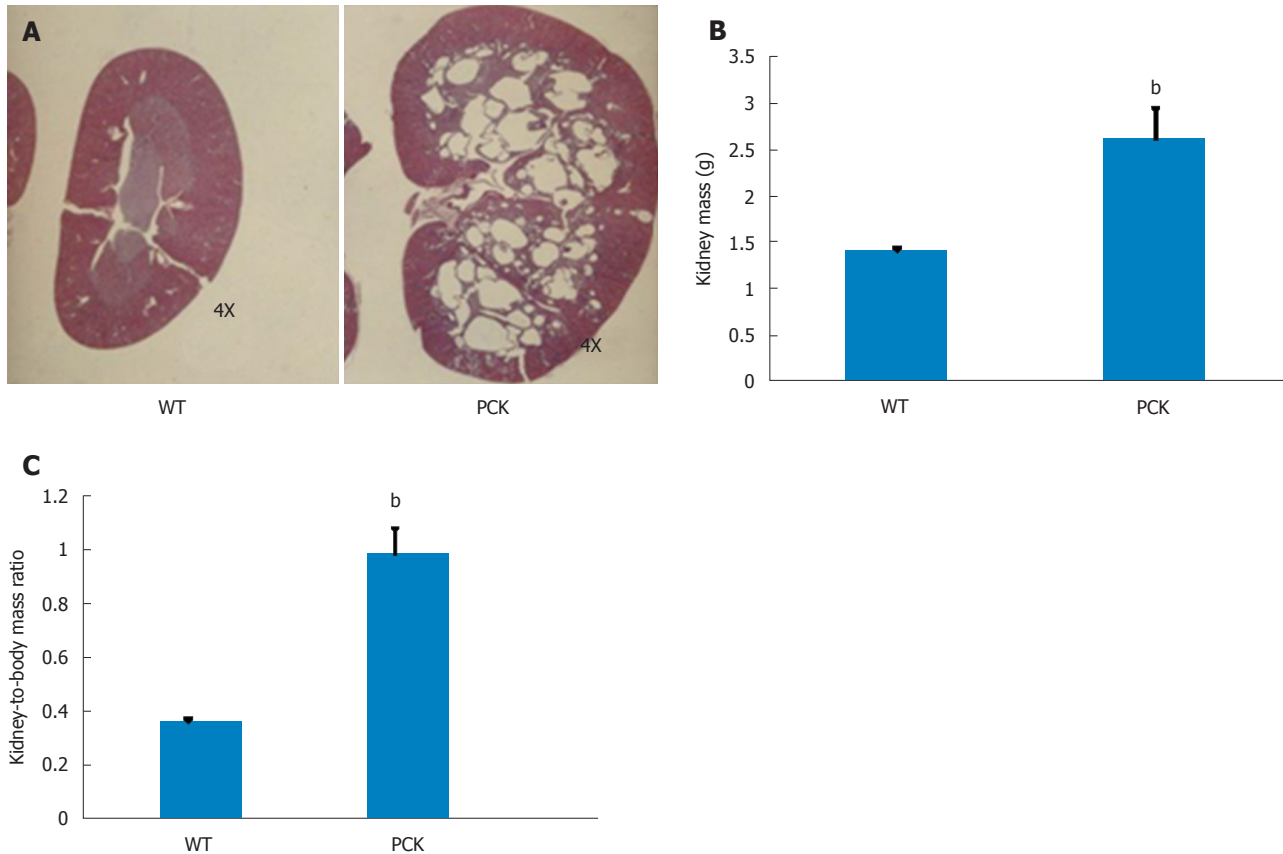


Figure 1 Renal characteristics in the PCK rat. A: Renal sagittal sections from 6 wk old wild-type (WT, Sprague-Dawley) and PCK rats showing an enlarged renal parenchyma and the medulla almost completely occupied with numerous cysts in the latter; B, C: At this time point, both kidney mass (B) and kidney-to-body mass ratio (C) were greater in the PCK rat (^b $P < 0.01$, vs WT).

followed with incubation with anti- α smooth muscle actin (α -SMA; Abcam) or anti-pPDGFR β (Antibody #3161, Cell Signaling) antibodies, followed by an appropriate HRP-conjugated secondary antibody (Cell Signaling). Proteins were detected using an enhanced chemiluminescence kit (Amersham/GE Healthcare, United Kingdom). Densitometric analysis for pPDGFR β was performed with normalization to GAPDH.

Statistical analysis

Data are presented as mean \pm SD. Between-group effects were analyzed by one-way analysis of variance followed by Tukey's *post-hoc* test. A P -value < 0.05 is considered significant.

RESULTS

ANG3070 slows progressive kidney pathophysiology

Four-week treatment study: By approximately 6 wk of age, kidneys from PCK rats were enlarged and filled with numerous cysts (Figure 1). Both renal mass and renal-to-body mass ratio in PCK rats were significantly greater compared to the wild-type, age-matched cohort (Figure 1). By 10 wk of age, PCK rats (treated with vehicle, *i.e.*, 0.5 mL water, PO, BID) exhibited significant renomegaly compared to the wild-type cohort.

Intervention with ANG3070 from weeks 6-10 was associated with a reduction in renal mass, renal-to-body mass ratio and renal cystic index (Figure 2). Compared to kidneys from wild-type animals, kidneys from PCK rats exhibited increased fibrosis, evidenced by increased tissue hydroxyproline content with ANG3070 treatment of the PCK rat associated with a reduction in renal hydroxyproline content (Figure 2). In addition to its effects on renal morphology, ANG3070 therapy was associated with the mitigation of kidney injury demonstrated by a reduction in 24-h urine NGAL and urine KIM-1 and amelioration of renal dysfunction, evidenced by reduced proteinuria and reduced albuminuria (Figure 2).

Eight-week treatment study: The effects of 8 wk of ANG3070 treatment were obvious in both kidneys and livers harvested from 14 wk old animals. At this time, the average kidney mass in the PCK rat (vehicle cohort) was several fold that of its wild-type counterpart and cystic index was approximately 30%. Nevertheless, a reduction in renal mass, renal-to-body mass ratio and cystic index was observed with drug treatment. At 14 wk of age, in addition to severe renal cyst formation, kidneys from PCK rats exhibited interstitial fibrosis evidenced by trichrome staining. The dominating presence of large cysts made analysis of the trichrome-stained area impractical, and

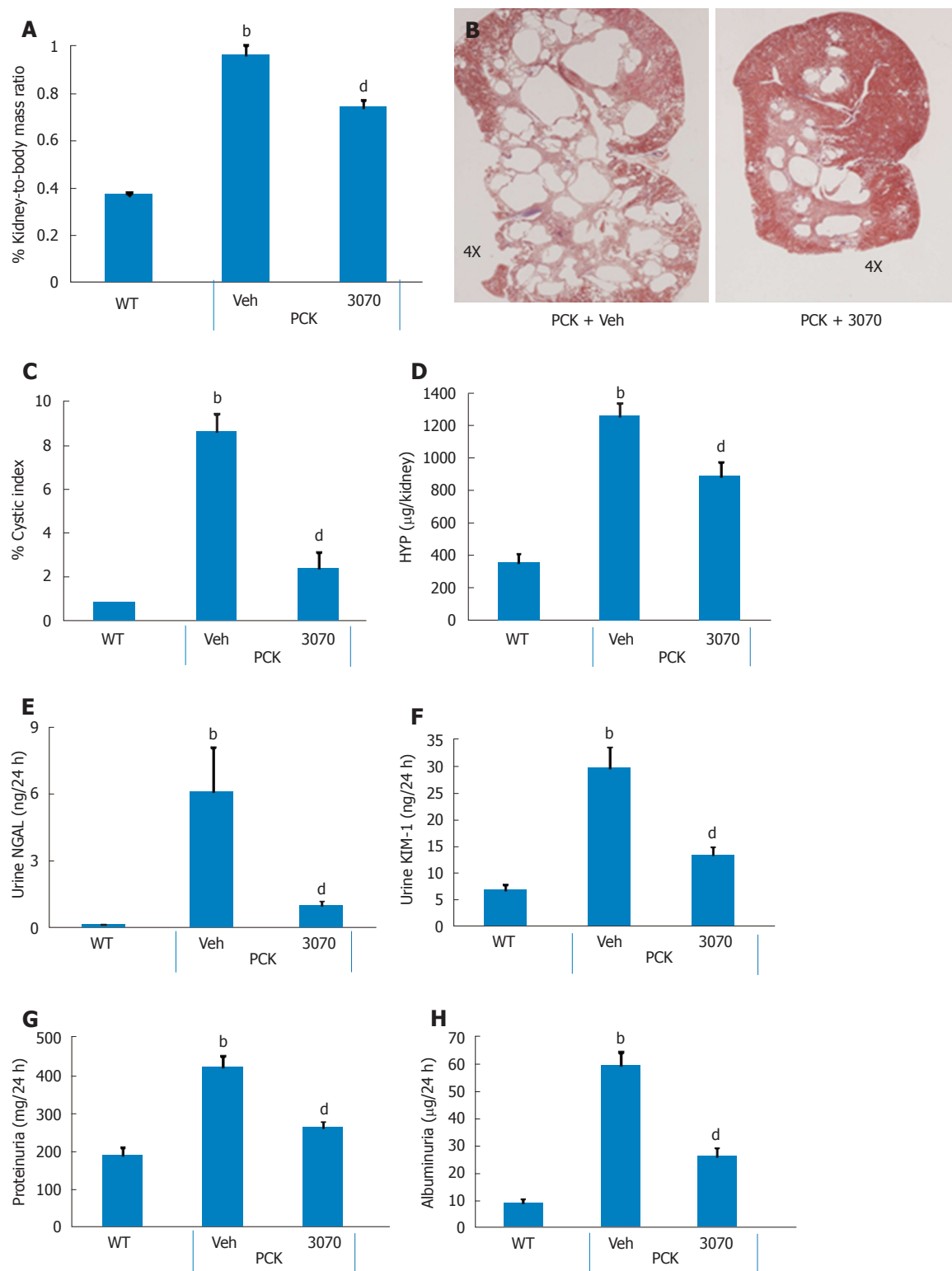


Figure 2 ANG3070 therapy attenuates renal mass, cystic index, renal injury, fibrosis and renal dysfunction. A, C: By approximately 10 wk of age, PCK rats [vehicle (Veh) cohort] had significantly larger renal mass and renal-to-body mass ratio (A) and increased cystic index (C) compared to the age-matched WT cohort ($^bP < 0.01$); B: Representative hematoxylin and eosin (HE)-stained renal sagittal sections (B) from PCK + Veh and a PCK + ANG3070 rats demonstrating cystic distribution across the renal parenchyma. Treatment of PCK rats with ANG3070 from weeks six to ten was associated with reduced kidney mass and kidney-to-body mass ratio (A) ($^dP < 0.01$, vs PCK + Veh); C: Treatment with ANG3070 reduced renal cystic index ($^dP < 0.01$, vs PCK + Veh); D: Total kidney hydroxyproline (a marker of collagen) content was increased at week ten in the PCK (Veh) rat, treatment with ANG3070 was associated with a reduction in this marker of kidney fibrosis ($^bP < 0.01$, vs WT; $^dP < 0.01$, vs PCK + Veh); E, F: Compared to the WT cohort, PCK (Veh) rats exhibited renal injury evidenced by increased urine neutrophil gelatinase-associated lipocalin (NGAL) (E) and urine kidney injury molecule-1 (KIM-1) (F) ($^bP < 0.01$, vs WT). Treatment with ANG3070 was associated with a reduction in these urinary markers (E and F) of renal injury; G, H: Renal dysfunction, evidenced by elevated proteinuria (G) and albuminuria (H) was reduced with ANG3070 treatment ($^dP < 0.01$, vs PCK + Veh). HYP: Collagen marker.

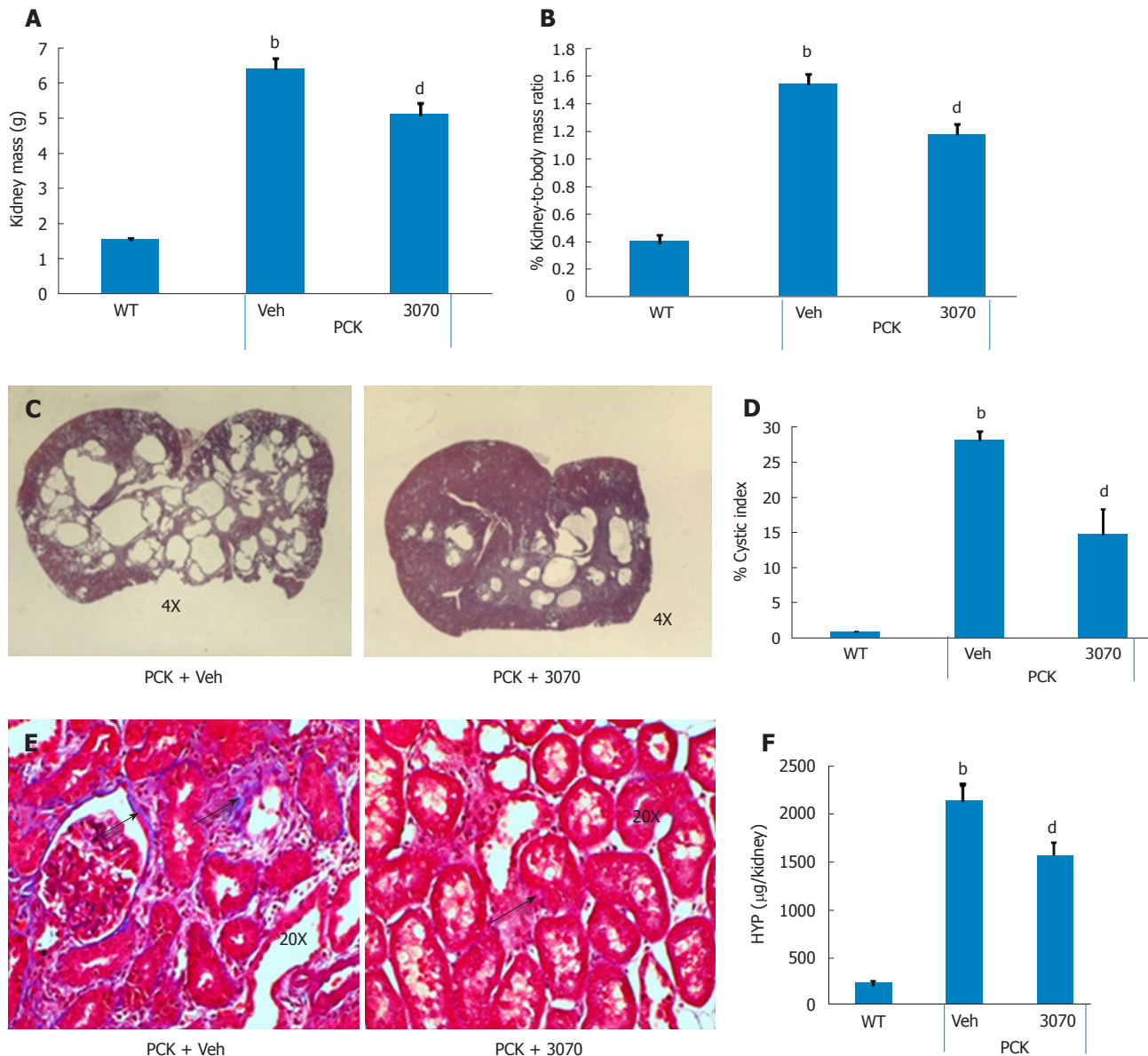


Figure 3 ANG3070 attenuates renal pathology and fibrosis in the PCK rat. A, B and D: By week 14, kidney mass (A), kidney-to-body mass ratio (B) and renal cystic index (D) were several-fold higher in PCK [vehicle (Veh)] rats compared to the WT cohort (^a $P < 0.01$, vs WT). ANG3070 therapy from weeks 6-14, mitigated renomegaly (A and B); C: Representative H and E-stained renal transverse sections from PCK + Veh and a PCK + ANG3070 rats demonstrating cystic distribution across the renal parenchyma at week 14; D: Treatment with ANG3070 reduced renal cystic index (^d $P < 0.01$, vs PCK + veh); E: Representative Masson's trichrome stained renal sections from PCK rats showing scarring within the renal interstitium (arrows) of PCK rats; F: Total kidney hydroxyproline (HYP-a marker of collagen) content was increased at week 14 in the PCK (Veh) rat (^b $P < 0.01$, vs WT). Treatment with ANG3070 was associated with a reduction in HYP, marker of kidney fibrosis (^d $P < 0.01$, vs PCK + Veh).

the extent of renal extracellular matrix deposition was therefore estimated biochemically in renal homogenates. Compared to the wild-type cohort, the PCK kidney (vehicle cohort) exhibited a marked increase in hydroxyproline content. Intervention with ANG3070 reduced renal fibrosis, evidenced by a decrease in total PCK kidney hydroxyproline content (Figure 3). Equally important, treatment with drug reduced renal injury, as evidenced by decreased 24-h urine - NGAL, KIM-1, cystatin C and IL-18 levels and attenuated key indices of renal dysfunction including proteinuria, albuminuria, BUN and SCr (Figure 4).

ANG3070 mitigates liver lesions: In addition to fibropolycystic kidney disease, PCK rats exhibit features of CHF and Caroli's disease, including hepatomegaly and ductal fibrosis with highly dilated intrahepatic ducts. Upon sacrifice (*i.e.*, approximately 14 wk of age), these characteristics of CHF and Caroli's disease were seen in PCK rats. Livers showed dilated intrahepatic ducts which were surrounded by matrix deposition, visible using H and E and Picrosirius red stains (Figure 5). Furthermore, frank hepatomegaly was evident in the PCK (vehicle) cohort. Although there was no increase in ALT (PCK vs wild-type, data not shown), AST was elevated. Treatment with

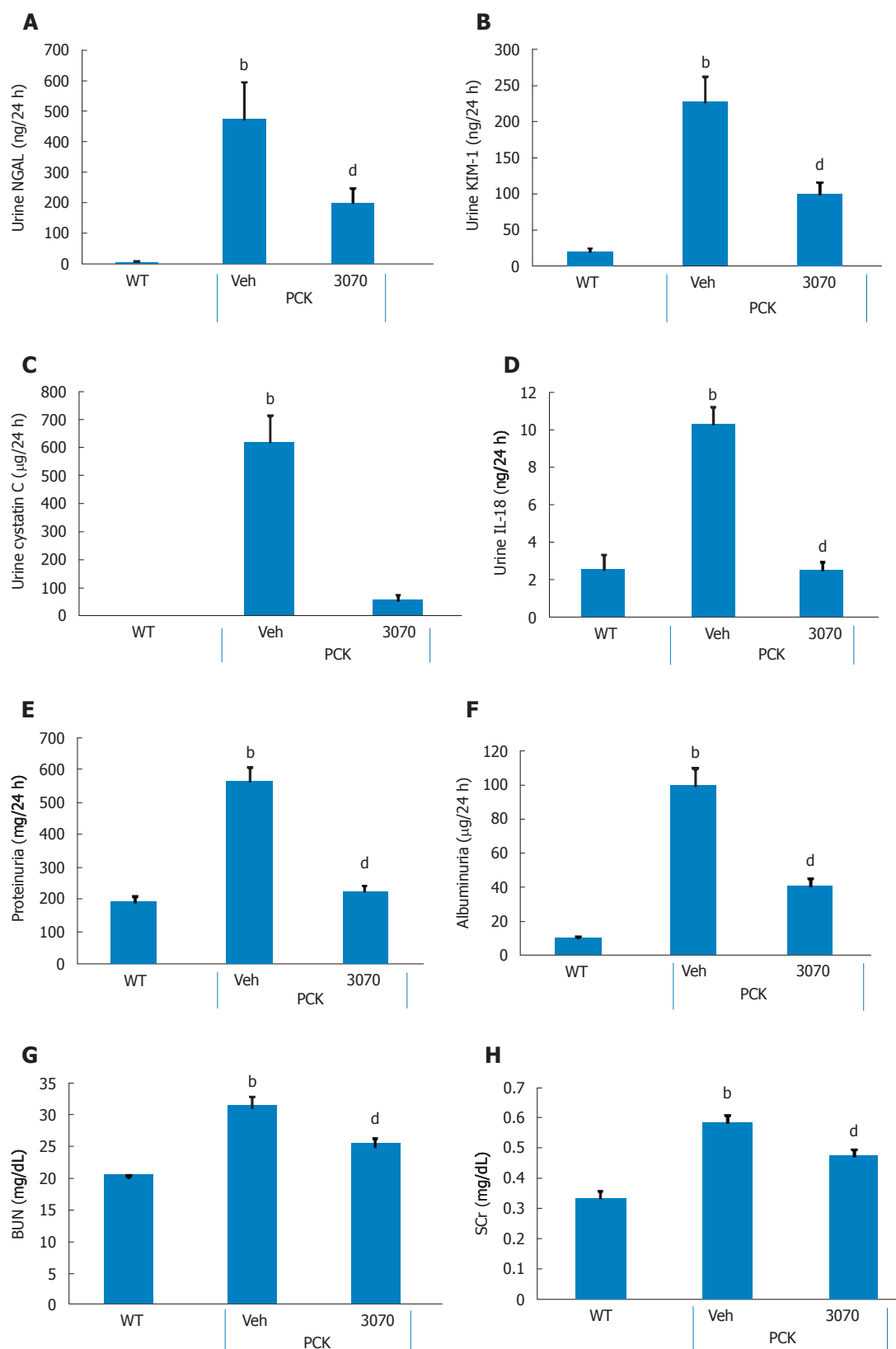


Figure 4 ANG3070 attenuates renal injury biomarkers and renal dysfunction. A-D: Compared to the WT cohort, at 14 wk of age, PCK [vehicle (Veh)] rats exhibited severe renal injury evidenced by increased urine - neutrophil gelatinase-associated lipocalin (NGAL) (A), kidney injury molecule-1 (KIM-1) (B), cystatin C (C) and interleukin-18 (IL-18) (D) (^b $P < 0.01$, vs WT). Treatment with ANG3070 was associated with a reduction in these urinary markers (A-D) of renal injury (^d $P < 0.01$, vs PCK + Veh); E-H: Renal dysfunction, evidenced by elevated proteinuria (E), albuminuria (F), blood urea nitrogen (BUN) (G) and serum creatinine (SCr) (H), was reduced with ANG3070 treatment (^b $P < 0.01$, vs WT; ^d $P < 0.01$, vs PCK + Veh).

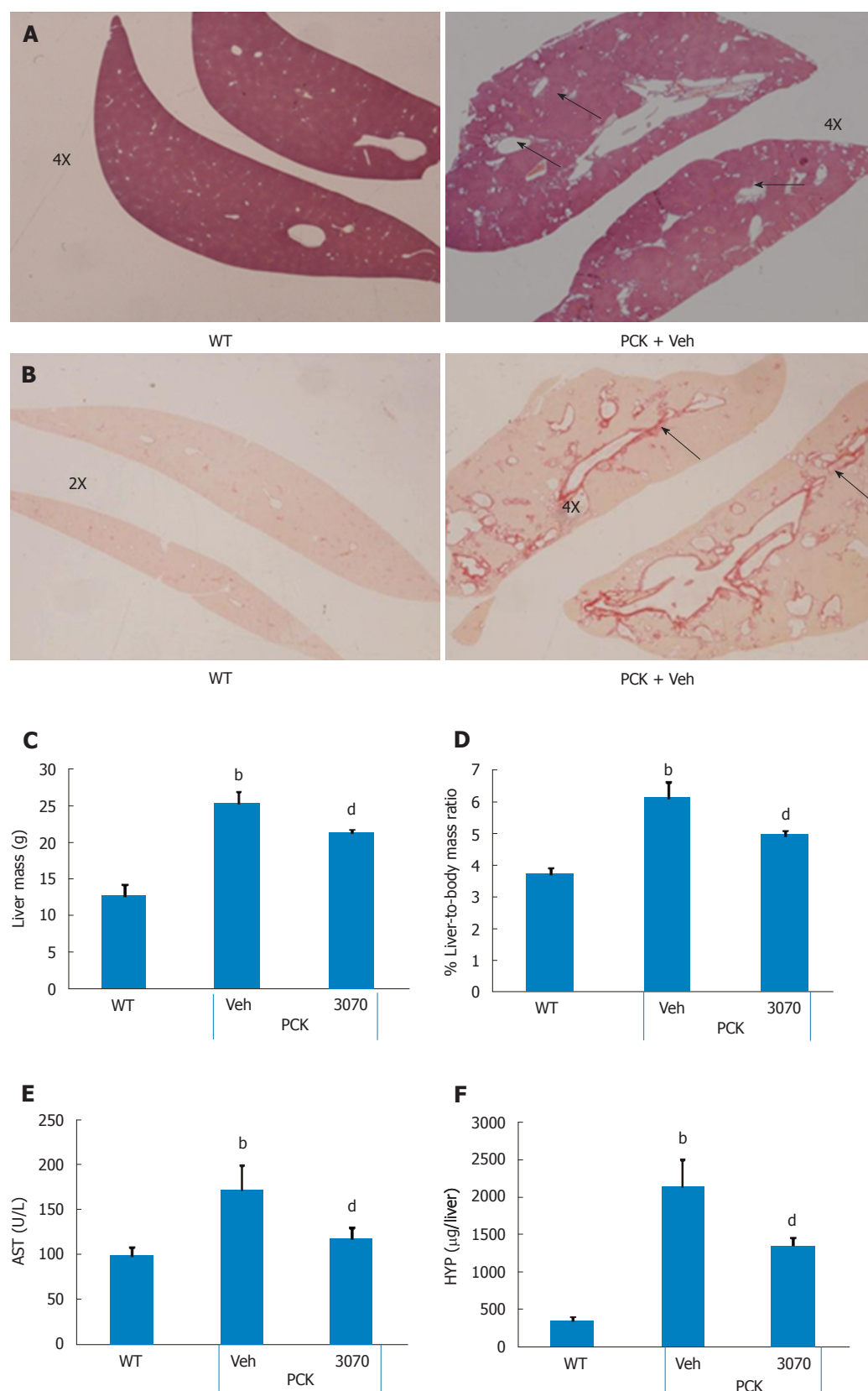


Figure 5 ANG3070 attenuates hepatic lesions, fibrosis and improves liver function in the PCK rat. A: Compared to the WT cohort, multiple, highly dilated bile ducts (arrows) are visible in H and E-stained PCK [vehicle (Veh)] livers by week 14; B: Representative Picrosirius red-stained liver showing ductal fibrosis (arrows) in the PCK (Veh) cohort; C-F: At sacrifice, PCK rats (Veh) exhibited increased liver mass (C), liver-to-body mass ratio (D) and aspartate aminotransferase (AST) (E) compared to the WT cohort. Total liver hydroxyproline content was also increased in the PCK rat (F). Treatment with ANG3070 was associated with a reduction in AST (E), hepatic lesions and fibrosis (HYP: Collagen marker) (A, B, C and F) (^b $P < 0.01$, vs WT; ^d $P < 0.01$, vs PCK + Veh).

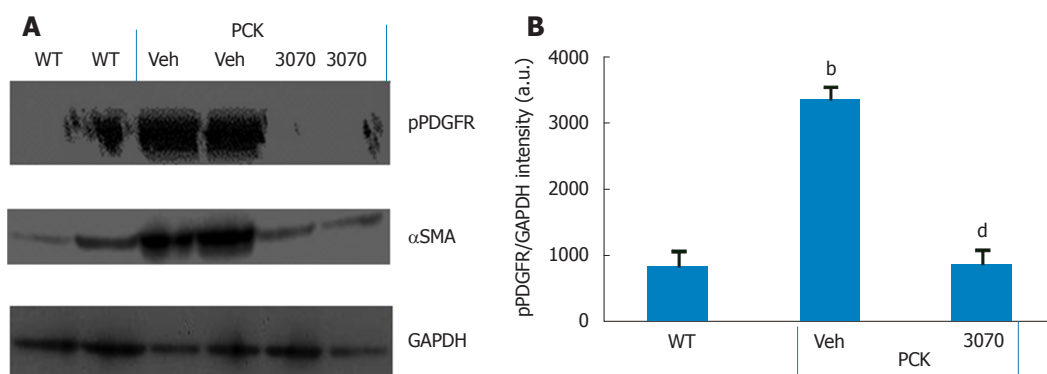


Figure 6 ANG3070 decreases phosphorylated platelet-derived growth factor receptor in the PCK rat kidney. A: Western blot analysis of kidney homogenates showed intense phosphorylated platelet-derived growth factor receptor (pPDGFR) levels in the PCK + vehicle (Veh) cohort compared to the WT and PCK + ANG3070 cohorts. A similar expression profile was seen with the fibrotic marker α smooth muscle actin (α SMA) in these kidneys. GAPDH expression is shown at the bottom; B: pPDGFR in renal homogenates from 10 wk old WT, PCK + Veh and PCK + ANG3070-treated animals was visualized with anti-PDGFR- α antibody and submitted to densitometric analysis with normalization to GAPDH. ANG3070 treatment was associated with a marked reduction in phosphorylated PDGFR levels (^b $P < 0.01$, vs WT; ^d $P < 0.01$, vs PCK + Veh).

ANG3070 reduced liver mass, liver-to-body mass ratio, AST and total liver hydroxyproline content (Figure 5).

ANG3070 pharmacodynamics: It has been reported that the cystic milieu is enriched in growth factors such as PDGF^[20]. The presence of multiple large and extensive cysts made immuno-histochemical quantification of pPDGFR impractical. Therefore, to determine whether the salutary effects of ANG3070 are associated with inhibition of this target, we evaluated the levels of pPDGFR together with the fibrotic marker α -SMA in renal homogenates from wild-type and vehicle- or ANG3070-treated PCK rats. As seen in Figure 6, compared to kidneys from wild-type animals, kidneys from the vehicle-treated PCK animals exhibited increased levels of both pPDGFR and α -SMA. In comparison to the PCK + Veh cohort, kidneys from the PCK + ANG3070 cohort exhibited decreased pPDGFR and α -SMA levels. Densitometric analysis of Western blots of renal homogenates from wild-type vs vehicle-treated PCK rats exhibited increased pPDGFR intensity, an effect that was reduced with ANG3070 treatment (Figure 6).

ANG3070 safety/toxicology profile: ANG3070 was efficacious and no potential toxic effects were observed in several rodent models. As detailed below, to date, there is no evidence of toxicity (liver or renal) in mice or rats dosed repeatedly over several weeks with ANG3070. In hundreds of mice and rats dosed several weeks with 150 mg/kg ANG3070 (PO, QD), there were no excursions in BUN (Veh 73 mg/dL; ANG3070 69 mg/dL) or SCr (veh 0.36 mg/dL; ANG3070 0.35 mg/dL) with ANG3070. In other rats dosed for 3 wk with ANG3070 (25 mg/kg, PO, BID \times 3 wk), no excursions were seen in liver enzymes vs vehicle-dosed rats (ALT - veh: 92 IU; ANG3070: 61 IU; AST - Veh 158 IU; ANG3070 136 IU). There were no adverse events reported in 14 d toxicology studies in rats and dogs at nine-fold higher doses (450

mg/d) (data not shown) than the efficacious dose of ANG3070 (50 mg/d) at which antifibrotic efficacy was observed in fibropolycystic kidney disease-CHF. These studies indicate that ANG3070 was safe and well-tolerated without any potential toxic effects. In PCK rats, treatment of ANG3070 for several weeks did not increase sCR, BUN, AST and ALT. In fact, sCR and AST were reduced with 3070 treatment. Overall ANG3070 was efficacious in decreasing kidney and liver fibrosis with no potential toxic effects in other organs.

DISCUSSION

We herein report that intervention with the orally bioavailable small molecule PAGFR and VEGFR dual kinase inhibitor ANG3070 ameliorates fibropolycystic disease progression in the PCK rat model of ARPKD-CHF. Intervention with this drug mitigated renomegaly, renal injury and renal dysfunction and fibrosis, effects associated with reduced renal PDGFR phosphorylation. Treatment with ANG3070 also reduced hepatic enlargement and fibrosis while improving liver function.

The formation and expansion of fluid-filled cysts drive kidney enlargement, with both an increasing cystic index and progressive extracellular matrix deposition driving functional insufficiency in fibropolycystic ARPKD-CHF^[21,22]. A genetically-acquired and congenital disease, approximately 20-30% of affected patients succumb within the first 1-2 mo of life, with pulmonary insufficiency secondary to renal enlargement as the primary cause of death. For children making it past that stage, nephrectomy and dialysis or kidney transplant is often warranted by approximately ten years of age^[23,24]. Intervention at this age is driven both by renal insufficiency and the need for a reduction in severe flank pain due to highly enlarged kidneys. The hepatic lesion in ARPKD-CHF is CHF resulting from a malformation of the ductal plate secondary biliary strictures and periportal

fibrosis, with the majority of patients also presenting with hepatomegaly^[25,26]. Clinical studies in ARPKD-CHF reveal that a subset of patients progress to hepatocellular carcinoma^[27]. Other than transplantation, there is no cure for ARPKD-CHF.

Mutations in the human *PKHD1* gene or mutations in *PKHD1* orthologs in rats and mice are required for development of ARPKD-CHF. However, experimental studies have identified that epithelial cells drive changes in the renal interstitium, with alterations in the cystic epithelia followed by changes in the interstitial fibroblasts and progressive accumulation of extracellular matrix. This ultimately leads to the development of renal fibrosis within that organ^[28,29]. Furthermore, data from a number of studies suggest that growth factors, including PDGF and VEGF, are the intermediaries between the cystic and fibrotic components of progressive fibropolycystic disease^[5,11]. A study^[5] in the DBA/2FG-*pcy* mouse model of PKD suggests that increased expression of PDGF-A and PDGF-B chains may contribute to the progression of renal cystic lesions. Qin *et al*^[30] reported impaired degradation of PDGFR in renal cells from PKD mice. In the ORPK murine model of PKD, responses to PDGF by fibroblasts, in which ciliary assembly is defective, are abnormal. In fact, Norman *et al*^[31] identified a paracrine, PDGF-mediated regulatory loop between inner medullary collecting duct epithelial cells and medullary fibroblasts, highlighting the importance of tubular epithelial-interstitial fibroblast interactions in PKD. Compared to age-matched normal fibroblasts, PKD fibroblasts demonstrate an enhanced proliferative response to PDGF, synthesize more fibroblast growth factor, and elicit more rapid and persistent tyrosine phosphorylation of intracellular proteins. Consistent with these reports, pPDGFR signaling in our hands appeared to be increased in PCK rats compared to the wild-type cohort. PDGF activation was accompanied by upregulation of the fibrotic marker α SMA and matrix deposition in the renal interstitium. ANG3070 treatment decreased pPDGFR signaling and α SMA expression, indicating a decrease in fibrosis.

In the kidney, VEGF expression is most prominent in glomerular podocytes and in tubular epithelial cells, while VEGF receptors are mainly found on pre-glomerular, glomerular, and peritubular endothelial cells. Raina *et al*^[32] reported that anti-VEGF therapy in the Han: SPRD rat, a model of ADPKD, was associated with an exaggerated cystic response of the proximal tubules and severe kidney injury. Huang *et al*^[33] reported that VEGF therapy in the *Pkd1^{nl/nl}* mouse model of ADPKD was associated with robust benefits across a spectrum of endpoints, with far more modest benefits evident in the *Cys1^{cpk/cpk}* mouse, a model of ARPKD. On the other hand, it has been postulated that VEGF-driven angiogenesis drives cyst cells to grow, and may be responsible for increased vascular permeability and fluid secretion into the cysts. In fact, data from clinical trials

point to a relationship between circulating VEGF and renal structural disease, including total renal volume, cyst volume and cyst number, and are indicative of a potential role for upregulated angiogenesis in early renal cyst progression^[10-13]. Finally, Jiang *et al*^[14] postulated that a pathogenic triumvirate, comprised by hyperproliferation of cyst wall growth, pericystic fibrosis, and inflammation, drives CHF/ARPKD progression.

ANG3070 is a proprietary, highly water-soluble, orally bioavailable potent inhibitor of PDGF and VEGF/KDR, which binds its targets with a K_d of approximately 5 nmol/L. In the PCK rat model of ARPKD-CHF, ANG3070 efficacy was observed across a spectrum of clinically-relevant endpoints, including a decrease in renomegaly, renal cystic index, renal injury markers, renal fibrosis and improvement in kidney function. Importantly, intervention with ANG3070, even after established renal disease at both 10 and 14 wk (a time when renal pathology is fairly advanced in the PCK rat), proved efficacious. Taken together, these data indicate that ANG3070 has therapeutic efficacy and slows a hallmark indicator of disease progression in ARPKD-CHF *via* cystic expansion of the kidney.

Another salient finding of this study was the effect of ANG3070 in mitigating renal injury in this model of ARPKD-CHF. Urinary markers of renal injury, including NGAL, KIM-1, cystatin C and IL-18, were increased in the PCK rat compared to wild-type controls. Previous studies have described the elevation of such markers in models of ARPKD-CHF. In fact, work by Nieto *et al*^[34] indicates that BUN, SCr and 24-h urine IL-18 levels are biomarkers for increasing cystic index and increasing renal mass in the PCK rat. The fact that ANG3070 treatment was associated with a reduction of these biomarkers, including BUN, SCr and urine IL-18, not only suggests that this drug attenuates kidney injury but also suggests that it mitigates cystogenesis and renal expansion.

A pharmacodynamic exercise to confirm the mechanism of action of ANG3070 was undertaken in renal homogenates from the wild-type and PCK cohorts. Consistent with data from the aforementioned studies, PDGFR signaling was enhanced in the PCK rat kidney, evidenced by increased levels of pPDGFR. Administration of ANG3070 to the PCK rat reduced renal phosphorylated PDGFR levels, suggesting that the drug is indeed engaging its target and that the salutary effects of ANG3070 in the kidney are associated with inhibition of PDGFR signaling.

In addition to its effects on the kidney, ANG3070 exhibited activity against the hepatic lesions that accompany this disease. While hepatomegaly, elevated serum AST and increased hepatic collagen content were observed in the PCK rat at 14 wk of age, 8 wk treatment with ANG3070 resulted in significant amelioration of both liver pathology and liver dysfunction. This is an important finding, in that not only can hepatomegaly and hepatic fibrosis necessitate liver transplantation in

ARPKD-CHF patients, but also that a cytokine-driven feedback mechanism might exist between hepatic and renal lesions in this disease. Needless to say, there were some clear limitations to this study. Given the historical challenges associated with demonstrating a pharmacodynamic signature of VEGFR/KDR phosphorylation inhibition, we did not attempt to evaluate this signaling mechanism in the kidney or liver. Finally, the PCK rat is one model of ARPKD-CHF and it remains to be determined whether ANG3070 exerts similar effects in other models of this disease. In summary, intervention with ANG3070 favorably impacted both the renal and hepatic components in the PCK rat model of fibropolycystic disease. These data suggest that ANG3070 has the potential to slow ARPKD-CHF and may serve as a bridge toward hepato-renal transplantation in patients with fibropolycystic disease.

ARTICLE HIGHLIGHTS

Research background

In autosomal recessive polycystic kidney disease (ARPKD)-congenital hepatic fibrosis (CHF), a genetically acquired and congenital disease, mutations in the human *PKHD1* gene or mutations in *PKHD1* orthologs in rats and mice are required for the development of ARPKD-CHF. Nevertheless, experimental studies have identified that epithelial cells drive changes in the renal interstitium, with alterations made to the cystic epithelia followed by changes in the interstitial fibroblasts and progressive accumulation of extracellular matrix. This leads to the development of renal fibrosis within the kidney and/or liver. For children, nephrectomy and dialysis or kidney or liver transplant is often warranted by approximately ten years of age. Other than transplantation, there is no cure for ARPKD-CHF. We report that platelet-derived growth factor (PDGF) and vascular endothelial growth factor (VEGF) are the intermediaries between the cystic and fibrotic components of progressive fibropolycystic disease, and that a PDGFR + VEGFR dual inhibitor can be a novel therapeutic approach.

Research motivation

The development of new therapies that prevent the transition from cystogenesis to fibrosis or adenocarcinoma in advanced stages of ARPKD-CHF will have tremendous clinical potential and decrease the number of hepato-renal transplants in patients with ARPKD-CHF.

Research objectives

The main objectives of our studies were to evaluate a novel PDGFR and VEGFR dual kinase inhibitor, ANG3070, in a PKD-CHF model. These studies could lead to a novel therapeutic approach for fibropolycystic kidney disease.

Research methods

Renal pathology was confirmed in PCK rats at 6 wk compared to the age and gender-matched wild type SD rats. At 6 wk of age, PCK rats were then randomized to vehicle or ANG3070 for 4 wk. At 10 wk, 24 h urine and left kidneys were collected and rats were continued on treatments for 4 wk. At 14 wk, 24 h urine was collected, rats were sacrificed, and liver and right kidneys were collected for histological evaluation. For Western blot studies, PCK rats were treated with vehicle or ANG3070 for 7 d and sacrificed approximately 30 min after the last treatments.

Research results

A well-characterized PCK rat model was used to study fibropolycystic kidney disease. Compared to the wild-type cohort, the PCK kidney (Vehicle cohort)

exhibited a marked increase in kidney and liver mass, hepato-renal cystic volume, hepato-renal fibrosis and hepato-renal injury biomarkers. Intervention with ANG3070 in PCK rats decreased kidney weight, reduced renal cystic volume and reduced total kidney hydroxyproline, thus indicating significantly reduced renal interstitial fibrosis compared to the PCK-Vehicle cohort. ANG3070 treatment also mitigated several markers of kidney injury, including urinary neutrophil gelatinase-associated lipocalin, kidney injury molecule-1, Cystatin C and interleukin-18 levels. This treatment also significantly attenuated key indices of renal dysfunction, including proteinuria, albuminuria and serum blood urea nitrogen and creatinine, and improved renal function compared to the PCK-Vehicle cohort. ANG3070 treatment also significantly decreased liver enlargement, hepatic lesions, decreased liver fibrosis and mitigated liver dysfunction compared to the PCK-Vehicle cohort. A dose-response study of ANG3070 needs to be evaluated to establish a minimum dose for maximal therapeutic efficacy in this PCK rat model.

Research conclusions

The development of new therapies that prevent the transition from cystogenesis to fibrosis or adenocarcinoma in advanced stages of ARPKD-CHF will have tremendous clinical potential. Studies indicate that PDGF and VEGF are the intermediaries between the cystic and fibrotic components of progressive fibropolycystic disease. We have identified and synthesized a novel small molecule PDGFR + VEGFR/KDR dual kinase inhibitor, ANG3070, using molecular modeling coupled with rational drug design, medicinal chemistry and structure activity relationship. We have evaluated ANG3070 therapeutic effects in a rat model of ARPKD-CHF and have proven it to be efficacious in mitigating kidney and liver injury biomarkers and decreasing hepatic and renal dysfunction. These studies could lead to the identification of a novel therapeutic approach in slowing fibropolycystic disease and decreasing the number of hepato-renal transplants in patients with ARPKD-CHF. These results suggest that ANG3070 has the potential in slowing disease, and may serve as a bridge toward hepato-renal transplantation in patients with fibropolycystic disease.

Research perspectives

The results of our studies suggest that ANG3070 has the potential therapeutic effect of slowing disease, and may serve as a bridge toward hepato-renal transplantation in patients with the fibropolycystic disease ARPKD-CHF.

REFERENCES

- 1 **Hartung EA**, Guay-Woodford LM. Autosomal recessive polycystic kidney disease: a hepatorenal fibrocystic disorder with pleiotropic effects. *Pediatrics* 2014; **134**: e833-e845 [PMID: 25113295 DOI: 10.1542/peds.2013-3646]
- 2 **Gunay-Aygun M**, Avner ED, Bacallao RL, Choyke PL, Flynn JT, Germino GG, Guay-Woodford L, Harris P, Heller T, Ingelfinger J, Kaskel F, Kleta R, LaRusso NF, Mohan P, Pazour GJ, Shneider BL, Torres VE, Wilson P, Zak C, Zhou J, Gahl WA. Autosomal recessive polycystic kidney disease and congenital hepatic fibrosis: summary statement of a first National Institutes of Health/Office of Rare Diseases conference. *J Pediatr* 2006; **149**: 159-164 [PMID: 16887426 DOI: 10.1016/j.jpeds.2006.03.014]
- 3 **Sung JM**, Huang JJ, Lin XZ, Ruaan MK, Lin CY, Chang TT, Shu HF, Chow NH. Caroli's disease and congenital hepatic fibrosis associated with polycystic kidney disease. A case presenting with acute focal bacterial nephritis. *Clin Nephrol* 1992; **38**: 324-328 [PMID: 1468163]
- 4 **ARPKD/CHF Alliance**. ARPKD/CHF Alliance Homepage. Available from: URL: <http://www.arpkdchf.org>
- 5 **Nakamura T**, Ebihara I, Nagaoka I, Tomino Y, Nagao S, Takahashi H, Koide H. Growth factor gene expression in kidney of murine polycystic kidney disease. *J Am Soc Nephrol* 1993; **3**: 1378-1386 [PMID: 8094982]
- 6 **Park JH**, Woo YM, Ko JY, Kim DY, Li X. Autosomal Dominant Polycystic Kidney Disease Induced by Ciliary Defects. 2015 [PMID: 27512773]
- 7 **Torres VE**, Harris PC, Pirson Y. Autosomal dominant polycystic kidney disease. *Lancet* 2007; **369**: 1287-1301 [PMID: 17434405 DOI: 10.1016/S0140-6736(07)60601-1]

- 8 **Cowley BD Jr**, Smardo FL Jr, Grantham JJ, Calvet JP. Elevated c-myc protooncogene expression in autosomal recessive polycystic kidney disease. *Proc Natl Acad Sci USA* 1987; **84**: 8394-8398 [PMID: 3479800 DOI: 10.1073/pnas.84.23.8394]
- 9 **Frick KK**, Womer RB, Scher CD. Platelet-derived growth factor-induced c-myc RNA expression. Analysis of an inducible pathway independent of protein kinase C. *J Biol Chem* 1988; **263**: 2948-2952 [PMID: 2449430]
- 10 **Schrijvers BF**, Flyvbjerg A, De Vriese AS. The role of vascular endothelial growth factor (VEGF) in renal pathophysiology. *Kidney Int* 2004; **65**: 2003-2017 [PMID: 15149314 DOI: 10.1111/j.1523-1755.2004.00621.x]
- 11 **Bello-Reuss E**, Holubec K, Rajaraman S. Angiogenesis in autosomal-dominant polycystic kidney disease. *Kidney Int* 2001; **60**: 37-45 [PMID: 11422734 DOI: 10.1046/j.1523-1755.2001.00768.x]
- 12 **Spirli C**, Okolicsanyi S, Fiorotto R, Fabris L, Cadamuro M, Lecchi S, Tian X, Somlo S, Strazzabosco M. ERK1/2-dependent vascular endothelial growth factor signaling sustains cyst growth in polycystin-2 defective mice. *Gastroenterology* 2010; **138**: 360-371.e7 [PMID: 19766642 DOI: 10.1053/j.gastro.2009.09.005]
- 13 **Tao Y**, Kim J, Yin Y, Zafar I, Falk S, He Z, Faubel S, Schrier RW, Edelstein CL. VEGF receptor inhibition slows the progression of polycystic kidney disease. *Kidney Int* 2007; **72**: 1358-1366 [PMID: 17882148 DOI: 10.1038/sj.ki.5002550]
- 14 **Jiang L**, Fang P, Weemhoff JL, Apte U, Pritchard MT. Evidence for a "Pathogenic Triumvirate" in Congenital Hepatic Fibrosis in Autosomal Recessive Polycystic Kidney Disease. *Biomed Res Int* 2016; **2016**: 4918798 [PMID: 27891514 DOI: 10.1155/2016/4918798]
- 15 **Rajekar H**, Vasishtha RK, Chawla YK, Dhiman RK. Noncirrhotic portal hypertension. *J Clin Exp Hepatol* 2011; **1**: 94-108 [PMID: 25755321 DOI: 10.1016/S0973-6883(11)60128-X]
- 16 **Lager DJ**, Qian Q, Bengal RJ, Ishibashi M, Torres VE. The pck rat: a new model that resembles human autosomal dominant polycystic kidney and liver disease. *Kidney Int* 2001; **59**: 126-136 [PMID: 11135065 DOI: 10.1046/j.1523-1755.2001.00473.x]
- 17 **Panicker B**, Mishra RK, Lim DS, Oehlen LJWM, Jung D. Antifibrotic Compounds and Uses Thereof. United States patent US9040555. 2012 Jan 26
- 18 **Narayan P**, Huang B, Prani PAKA, Paka L, Goldberg ID. Methods and uses of compounds for treating disease. United States patent US20150105380. 2013 Sep 23
- 19 **Samuel CS**. Determination of collagen content, concentration, and sub-types in kidney tissue. *Methods Mol Biol* 2009; **466**: 223-235 [PMID: 19148607 DOI: 10.1007/978-1-59745-352-3_16]
- 20 **Takikita-Suzuki M**, Haneda M, Sasahara M, Owada MK, Nakagawa T, Isono M, Takikita S, Koya D, Ogasawara K, Kikkawa R. Activation of Src kinase in platelet-derived growth factor-B-dependent tubular regeneration after acute ischemic renal injury. *Am J Pathol* 2003; **163**: 277-286 [PMID: 12819032 DOI: 10.1016/S0002-9440(10)63651-6]
- 21 **Al-Lawati TT**. Fibropolycystic disease of the liver and kidney in Oman. *Arab J Gastroenterol* 2013; **14**: 173-175 [PMID: 24433648 DOI: 10.1016/j.ajg.2013.11.004]
- 22 **Brancatelli G**, Federle MP, Vilgrain V, Vullierme MP, Marin D, Lagalla R. Fibropolycystic liver disease: CT and MR imaging findings. *Radiographics* 2005; **25**: 659-670 [PMID: 15888616 DOI: 10.1148/rg.253045114]
- 23 **Summerfield JA**, Nagafuchi Y, Sherlock S, Cadafalch J, Scheuer PJ. Hepatobiliary fibropolycystic diseases. A clinical and histological review of 51 patients. *J Hepatol* 1986; **2**: 141-156 [PMID: 3958471 DOI: 10.1016/S0168-8278(86)80073-3]
- 24 **Ko JS**, Yi NJ, Suh KS, Seo JK. Pediatric liver transplantation for fibropolycystic liver disease. *Pediatr Transplant* 2012; **16**: 195-200 [PMID: 22360404 DOI: 10.1111/j.1399-3046.2012.01661.x]
- 25 **Wilson PD**, Du J, Norman JT. Autocrine, endocrine and paracrine regulation of growth abnormalities in autosomal dominant polycystic kidney disease. *Eur J Cell Biol* 1993; **61**: 131-138 [PMID: 8223698]
- 26 **Schneider L**, Cammer M, Lehman J, Nielsen SK, Guerra CF, Veland IR, Stock C, Hoffmann EK, Yoder BK, Schwab A, Satir P, Christensen ST. Directional cell migration and chemotaxis in wound healing response to PDGF-AA are coordinated by the primary cilium in fibroblasts. *Cell Physiol Biochem* 2010; **25**: 279-292 [PMID: 20110689 DOI: 10.1159/000276562]
- 27 **Jain D**, Nayak NC, Saigal S. Hepatocellular carcinoma arising in association with von-Meyenburg's complexes: an incidental finding or precursor lesions? A clinicopathologic study of 4 cases. *Ann Diagn Pathol* 2010; **14**: 317-320 [PMID: 20850692 DOI: 10.1016/j.anndiagpath.2010.04.003]
- 28 **Knecht A**, Fine LG, Kleinman KS, Rodemann HP, Müller GA, Woo DD, Norman JT. Fibroblasts of rabbit kidney in culture. II. Paracrine stimulation of papillary fibroblasts by PDGF. *Am J Physiol* 1991; **261**: F292-F299 [PMID: 1652205 DOI: 10.1152/ajprenal.1991.261.2.F292]
- 29 **Sweeney WE Jr**, Avner ED. Molecular and cellular pathophysiology of autosomal recessive polycystic kidney disease (ARPKD). *Cell Tissue Res* 2006; **326**: 671-685 [PMID: 16767405 DOI: 10.1007/s00441-006-0226-0]
- 30 **Qin S**, Taglienti M, Nauli SM, Contrino L, Takakura A, Zhou J, Kreidberg JA. Failure to ubiquitinate c-Met leads to hyperactivation of mTOR signaling in a mouse model of autosomal dominant polycystic kidney disease. *J Clin Invest* 2010; **120**: 3617-3628 [PMID: 20852388 DOI: 10.1172/JCI41531]
- 31 **Norman JT**, Orphanides C, Garcia P, Fine LG. Hypoxia-induced changes in extracellular matrix metabolism in renal cells. *Exp Nephrol* 1999; **7**: 463-469 [PMID: 10559644 DOI: 10.1159/000020625]
- 32 **Raina S**, Honer M, Krämer SD, Liu Y, Wang X, Segerer S, Wüthrich RP, Serra AL. Anti-VEGF antibody treatment accelerates polycystic kidney disease. *Am J Physiol Renal Physiol* 2011; **301**: F773-F783 [PMID: 21677148 DOI: 10.1152/ajprenal.00058.2011]
- 33 **Huang JL**, Woolf AS, Kolatsi-Joannou M, Baluk P, Sandford RN, Peters DJ, McDonald DM, Price KL, Winyard PJ, Long DA. Vascular Endothelial Growth Factor C for Polycystic Kidney Diseases. *J Am Soc Nephrol* 2016; **27**: 69-77 [PMID: 26038530 DOI: 10.1681/ASN.2014090856]
- 34 **Nieto JA**, Yamin MA, Goldberg ID, Narayan P. An Empirical Biomarker-Based Calculator for Cystic Index in a Model of Autosomal Recessive Polycystic Kidney Disease-The Nieto-Narayan Formula. *PLoS One* 2016; **11**: e0163063 [PMID: 27695033 DOI: 10.1371/journal.pone.0163063]

P-Reviewer: El-Shabrawi MHF, Gheita TAA, Niu ZS, Tarantino G

S-Editor: Ji FF **L-Editor:** Filipodia **E-Editor:** Song H





Published by **Baishideng Publishing Group Inc**
7901 Stoneridge Drive, Pleasanton, CA 94588, USA
Telephone: +1-925-223-8242
Fax: +1-925-223-8243
E-mail: bpgoffice@wjgnet.com
Help Desk: <http://www.f6publishing.com/helpdesk>
<http://www.wjgnet.com>

