


World Journal of *Gastrointestinal Oncology*

World J Gastrointest Oncol 2018 July 15; 10(7): 145-201





REVIEW

- 145 Novel biomarkers for patient stratification in colorectal cancer: A review of definitions, emerging concepts, and data
Chand M, Keller DS, Mirnezami R, Bullock M, Bhangu A, Moran B, Tekkis PP, Brown G, Mirnezami A, Berho M
- 159 HER2 inhibition in gastro-oesophageal cancer: A review drawing on lessons learned from breast cancer
Lote H, Valeri N, Chau I
- 172 Advances in molecular, genetic and immune signatures of gastric cancer: Are we ready to apply them in our patients' decision making?
Gkolfinopoulos S, Papamichael D, Papadimitriou K, Papanastasopoulos P, Vassiliou V, Kountourakis P

MINIREVIEWS

- 184 Prediction of malignancy and adverse outcome of solid pseudopapillary tumor of the pancreas
You L, Yang F, Fu DL

ORIGINAL ARTICLE

Retrospective Study

- 194 Atypical anastomotic malignancies of small bowel after subtotal gastrectomy with Billroth II gastroenterostomy for peptic ulcer: Report of three cases and review of the literature
Kotidis E, Ioannidis O, Pramateftakis MG, Christou K, Kanellos I, Tsalis K

Contents

World Journal of Gastrointestinal Oncology
Volume 10 Number 7 July 15, 2018

ABOUT COVER

Editorial Board Member of *World Journal of Gastrointestinal Oncology*, Joseph Chao, MD, Assistant Professor, Medical Oncology and Therapeutics Research, City of Hope Comprehensive Cancer Center, Duarte, CA 91010, United States

AIM AND SCOPE

World Journal of Gastrointestinal Oncology (*World J Gastrointest Oncol*, *WJGO*, online ISSN 1948-5204, DOI: 10.4251) is a peer-reviewed open access academic journal that aims to guide clinical practice and improve diagnostic and therapeutic skills of clinicians.

WJGO covers topics concerning carcinogenesis, tumorigenesis, metastasis, diagnosis, prevention, prognosis, clinical manifestations, nutritional support, molecular mechanisms, and therapy of benign and malignant tumors of the digestive tract. The current columns of *WJGO* include editorial, frontier, diagnostic advances, therapeutics advances, field of vision, mini-reviews, review, topic highlight, medical ethics, original articles, case report, clinical case conference (Clinicopathological conference), and autobiography. Priority publication will be given to articles concerning diagnosis and treatment of gastrointestinal oncology diseases. The following aspects are covered: Clinical diagnosis, laboratory diagnosis, differential diagnosis, imaging tests, pathological diagnosis, molecular biological diagnosis, immunological diagnosis, genetic diagnosis, functional diagnostics, and physical diagnosis; and comprehensive therapy, drug therapy, surgical therapy, interventional treatment, minimally invasive therapy, and robot-assisted therapy.

We encourage authors to submit their manuscripts to *WJGO*. We will give priority to manuscripts that are supported by major national and international foundations and those that are of great clinical significance.

INDEXING/ABSTRACTING

World Journal of Gastrointestinal Oncology (*WJGO*) is now indexed in Science Citation Index Expanded (also known as SciSearch®), PubMed, and PubMed Central. The 2018 edition of Journal Citation Reports® cites the 2017 impact factor for *WJGO* as 3.140 (5-year impact factor: 3.228), ranking *WJGO* as 39 among 80 journals in gastroenterology and hepatology (quartile in category Q2), and 114 among 222 journals in oncology (quartile in category Q3).

EDITORS FOR THIS ISSUE

Responsible Assistant Editor: *Xiang Li*
Responsible Electronic Editor: *Wen-Wen Tan*
Proofing Editor-in-Chief: *Lian-Sheng Ma*

Responsible Science Editor: *Fang-Fang Ji*
Proofing Editorial Office Director: *Jin-Lai Wang*

NAME OF JOURNAL

World Journal of Gastrointestinal Oncology

ISSN

ISSN 1948-5204 (online)

LAUNCH DATE

February 15, 2009

FREQUENCY

Monthly

EDITORIAL BOARD MEMBERS

All editorial board members resources online at <http://www.wjgnet.com/1948-5204/editorialboard.htm>

EDITORIAL OFFICE

Jin-Lei Wang, Director
World Journal of Gastrointestinal Oncology
Baishideng Publishing Group Inc

7901 Stoneridge Drive, Suite 501, Pleasanton, CA 94588, USA

Telephone: +1-925-2238242

Fax: +1-925-2238243

E-mail: editorialoffice@wjgnet.com

Help Desk: <http://www.wjgnet.com/helpdesk>

<http://www.wjgnet.com>

PUBLISHER

Baishideng Publishing Group Inc

7901 Stoneridge Drive,
Suite 501, Pleasanton, CA 94588, USA

Telephone: +1-925-2238242

Fax: +1-925-2238243

E-mail: bpgoffice@wjgnet.com

Help Desk: <http://www.wjgnet.com/helpdesk>

<http://www.wjgnet.com>

PUBLICATION DATE

July 15, 2018

COPYRIGHT

© 2018 Baishideng Publishing Group Inc. Articles published by this Open-Access journal are distributed under the terms of the Creative Commons Attribution Non-commercial License, which permits use, distribution, and reproduction in any medium, provided the original work is properly cited, the use is non commercial and is otherwise in compliance with the license.

SPECIAL STATEMENT

All articles published in journals owned by the Baishideng Publishing Group (BPG) represent the views and opinions of their authors, and not the views, opinions or policies of the BPG, except where otherwise explicitly indicated.

INSTRUCTIONS TO AUTHORS

<http://www.wjgnet.com/bpg/gerinfo/204>

ONLINE SUBMISSION

<http://www.wjgnet.com>

Prediction of malignancy and adverse outcome of solid pseudopapillary tumor of the pancreas

Li You, Feng Yang, De-Liang Fu

Li You, Feng Yang, De-Liang Fu, Department of Pancreatic Surgery, Pancreatic Disease Institute, Huashan Hospital, Shanghai Medical College, Fudan University, Shanghai 200040, China

ORCID number: Li You (0000-0003-2951-1616); Feng Yang (0000-0001-8790-6072); De-Liang Fu (0000-0003-4060-8101).

Author contributions: You L contributed to data acquisition, drafting the article, and final approval of the version to be published; Yang F contributed to the conception and design of this paper, data acquisition, drafting and revising the article, and final approval of the version to be published; Fu DL contributed to the conception and design of this paper, and final approval of it.

Conflict-of-interest statement: We declare no conflicts of interest.

Open-Access: This article is an open-access article which was selected by an in-house editor and fully peer-reviewed by external reviewers. It is distributed in accordance with the Creative Commons Attribution Non Commercial (CC BY-NC 4.0) license, which permits others to distribute, remix, adapt, build upon this work non-commercially, and license their derivative works on different terms, provided the original work is properly cited and the use is non-commercial. See: <http://creativecommons.org/licenses/by-nc/4.0/>

Manuscript source: Invited manuscript

Correspondence to: Feng Yang, MD, PhD, Associate Professor, Surgeon, Surgical Oncologist, Department of Pancreatic Surgery, Pancreatic Disease Institute, Huashan Hospital, Shanghai Medical College, Fudan University, 12 Central Urumqi Road, Shanghai 200040, China. yffudan98@126.com
Telephone: +86-21-52887164
Fax: +86-21-52888277

Received: March 16, 2018

Peer-review started: March 16, 2018

First decision: April 9, 2018

Revised: April 23, 2018

Accepted: May 23, 2018

Article in press: May 23, 2018

Published online: July 15, 2018

Abstract

Since solid pseudopapillary tumor of the pancreas (SPTP) was officially classified by the World Health Organization in 1996, SPTP has recently received special attention in the literature. Studies have shown that SPTP is a heterogeneous tumor, with a small percentage of patients harboring aggressive behaviors. However, criteria for malignancy grade in SPTP have not been well established. The prognosis of SPTP is generally good, with cases having a chance for long-term survival even with recurrence and/or metastasis after surgical resection. The current American Joint Committee on Cancer/Union for International Cancer Control tumor, node, metastasis staging system is not specific to SPTP. The lack of a predictive staging classification that accurately describes the heterogeneity of this disease hinders meaningful research into optimal individualized therapy. Here we summarize and discuss the associated factors proposed for appraisal of the malignant potential and adverse outcome of SPTP.

Key words: Pancreas; Recurrence; Solid pseudopapillary tumor; Malignancy; Metastasis

© **The Author(s) 2018.** Published by Baishideng Publishing Group Inc. All rights reserved.

Core tip: Solid pseudopapillary tumor of the pancreas (SPTP) is a heterogeneous tumor, with a small percentage of patients harboring aggressive behaviors. Its prognosis is generally good, with cases having a chance for long-term survival even with recurrence and/or metastasis after surgical resection. The lack of a predictive staging classification that accurately describes the heterogeneity of this disease hinders meaningful research into optimal individualized therapy. Here we summarize and discuss the associated factors proposed for appraisal of the malignant potential and adverse outcome of SPTP.

You L, Yang F, Fu DL. Prediction of malignancy and adverse outcome of solid pseudopapillary tumor of the pancreas. *World J Gastrointest Oncol* 2018; 10(7): 184-193 Available from: URL: <http://www.wjgnet.com/1948-5204/full/v10/i7/184.htm> DOI: <http://dx.doi.org/10.4251/wjgo.v10.i7.184>

INTRODUCTION

Since solid pseudopapillary tumor of the pancreas (SPTP) was officially classified by the World Health Organization (WHO) in 1996, SPTP has been accepted worldwide. It had also been called Frantz tumor, papillary cystic tumor/neoplasm/carcinoma, solid and papillary neoplasm, solid and papillary epithelial neoplasm, solid and cystic tumor, and solid and cystic papillary epithelial neoplasm. Most of the tumors are found in young women in their second or third decade while it is rare in male patients, accounting for 12.05% of all cases. More than half of the patients are under the age of 25 years^[1]. Occasionally, it occurs in children^[2]. There was no significant difference in age between male and female patients. Approximately one-third of patients were asymptomatic, with the tumors incidentally discovered during physical examination or in work-up for unrelated diseases^[1]. Although several genetic alterations such as somatic mutations in exon 3 of CTNNB1, and upregulated genes activated in Wnt/ β -catenin, Hedgehog, and androgen receptor signaling pathways have been identified^[3-5], the tumorigenesis of SPTP is still not clear. The incidence of SPTP seems to be increasing, and study of this rare tumor is thus of clinical significance.

Previously, SPTP was mostly considered as a benign tumor, but not until the 2010 version of the WHO classification was issued, all SPTPs are considered as low-grade malignant tumors. Studies have shown that SPTP is a heterogeneous tumor, with a small percentage of patients harboring aggressive behaviors^[6-8]. Even if the tumor has no evidence of malignant potential, such as perineural invasion, vascular invasion, invasion of pancreatic parenchyma, and infiltration of peripancreatic tissue, it may metastasize to the liver or recur after surgery. Long-term survival can be achieved in SPTP patients with advanced or metastatic disease, which reveals that SPTP is a relatively indolent disease compared with other pancreatic carcinomas. It is difficult to elucidate the natural course of SPTP and to predict its malignancy and outcome after surgery due to limited follow-up studies. As such, SPTP remains a pancreatic surgical enigma and studies have failed to identify prognostic factors predicting its malignant behavior.

EPIDEMIOLOGIC TREND

The incidence of SPTP has increased markedly in recent years, possibly due to the ready use of modern imaging, diagnostic endoscopy, and physician awareness. Although epidemiologic trends have been documented for

pancreatic cystic lesions^[9-11], the true incidence and epidemiologic trend for SPTP are less clear. An understanding of its epidemiology has been hampered by the pervasive tendency to report the incidence along with other pancreatic tumors.

As the incidence of pancreatic tumors in China increases year by year^[12], the number of patients with pancreatic diseases admitted to Huashan Hospital affiliated to Fudan University, Shanghai, China has continued to grow, so has the number of surgical procedures performed during the last decade. The number of patients with SPTP also increased during these years, with an average of more than six patients with this disease having been confirmed each year. Literature related to SPTP and the number of patients reported have rapidly grown since 1996 (Figure 1). A total of 390 cases were described in a previous systematic review of SPTP cases reported in China between 1996 and 2006^[1]. Law *et al.*^[13] conducted a systematic review of English literature concerning SPTP published up to 2012, and identified 2744 cases of SPTP. A nationwide survey from South Korea showed that SPTP ranked as the third most common pancreatic cystic tumors (18.3%)^[14]. These figures indicate that SPTP is not uncommon now worldwide. Given the population trend and the paucity of studies available to guide management of patients with SPTP, further research is imperative.

NATURE HISTORY AND TUMOR BIOLOGY

The origin, biological behavior and nature history of SPTP are not fully understood until now, leaving it as an enigmatic entity. SPTP was regarded as a borderline malignant tumor initially due to lack of evidence-based demonstration of true benign tumor. The WHO used the term "low-grade malignant" instead of "benign" in 2010. SPTP has a wide variability of tumor features from completely solid to almost completely cystic. Imaging studies have shown that smaller SPTPs usually appear as completely or mostly solid, while larger SPTPs typically appear as a large well-encapsulated heterogeneous mass with varying solid-cystic components due to necrosis, hemorrhage and degeneration^[15]. A recent report revealed that evolution of liver metastasis from SPTP was relatively slow, with the metastatic lesions having a similar growth pattern of primary tumor characterized by a solid-cystic mass with pseudopapillary structures^[16].

Parallel to the controversy regarding its histogenetic derivation, assessment of the malignant potential of SPTP remained a major controversial issue for decades. Although SPTP is considered as a tumor of low-grade malignancy, patients with this disease occasionally present with invasion into the portal/splenic vein (Figure 2) and/or adjacent organs or liver metastasis, mimicking pancreatic ductal adenocarcinoma. The prognosis of SPTP is generally good, with cases having a chance for long-term survival even with recurrence and/or meta-

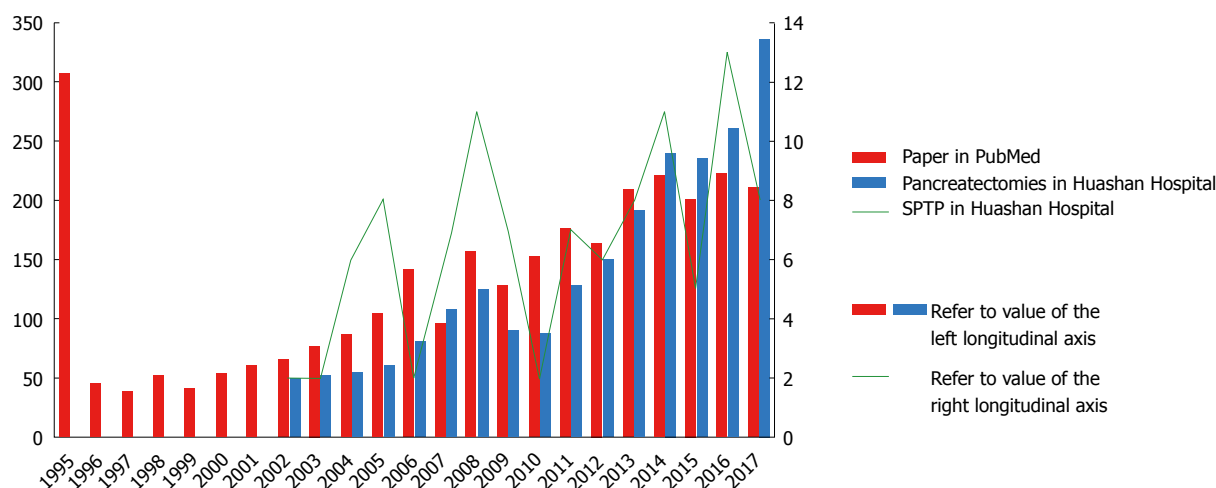


Figure 1 Publications concerning solid pseudopapillary tumor of the pancreas in PubMed, and number of pancreatectomies and patients undergoing surgery for solid pseudopapillary tumor of the pancreas in Huashan Hospital affiliated to Fudan University. Literature retrieved from PubMed (March 1, 2018) with the search terms “frantz tumor”, “solid and cystic papillary epithelial neoplasm”, “solid and cystic tumor”, “papillary cystic tumor”, “solid and papillary neoplasm”, “papillary cystic carcinoma”, “papillary and cystic tumor”, “papillary and solid neoplasm”, “solid and papillary epithelial neoplasm”, “papillary cystic neoplasm”, “solid pseudopapillary tumor”, “pancreas”, and “pancreatic” in “all fields”. SPTP: Solid pseudopapillary tumor of the pancreas.

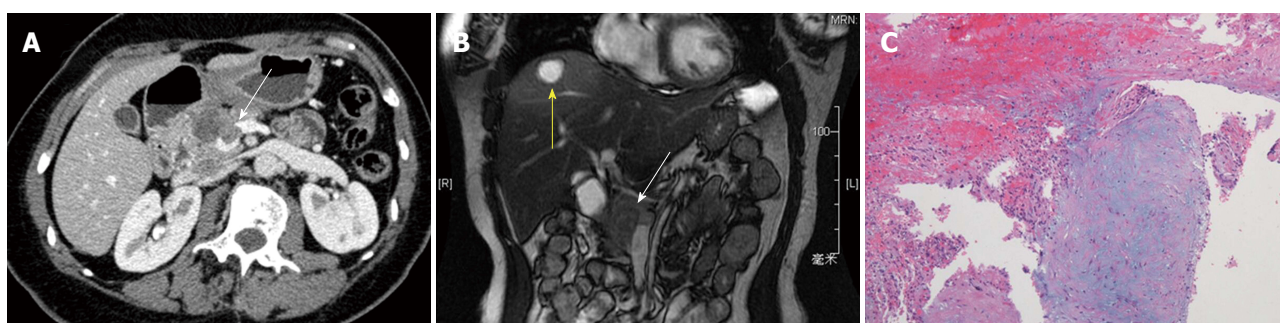

Figure 2 Solid pseudopapillary tumor of the pancreas presenting with invasion into the portal splenic confluence. A: Enhanced computed tomography scan revealed intraluminal filling defect in the portal splenic confluence (arrow); B: An abnormal signal of the pancreatic head (arrow) and high signal foci in the right anterior lobe of the liver (yellow arrow) can be readily delineated from the coronal magnetic resonance imaging (MRI) section; C: Splenic vein tumor thrombus was noted by hematoxylin-eosin staining ($\times 100$).

stasis after surgical resection. Up to 10% of patients experienced a recurrence and/or metastasis of the disease after years of follow-up, and only a small subset of patients eventually died of this disease^[6-8,17-37] (Table 1).

DIAGNOSIS OF MALIGNANT SPTP

Studies showed that tumor markers such as carbohydrate antigen 19-9 (CA19-9) and carcinoembryonic antigen (CEA) were usually within normal ranges in patients with this disease. Thus, routine tumor markers are of no value to predict malignant SPTP^[1]. Radiologically, SPTP typically appears as a well-capsulated heterogeneous mass with solid and cystic components, while small SPTP commonly represents a solid mass. Capsule and intratumoral hemorrhage are important clues to the diagnosis as they are rarely detected in other pancreatic neoplasms. In some cases, calcification may be present, whereas pancreatic duct dilatation is rarely found. Yang *et al.*^[16] reported that the liver metastatic lesions from

SPTP increased in sizes gradually with cystic change. The relatively slow evolution of liver metastasis indicates its classic growth pattern. Although the proportion of solid component^[38] and incomplete capsule^[39,40] were shown to be associated with malignancy by a few reports, no consistent results were demonstrated. Rastogi *et al.*^[41] reported that tumors with greater enhancement assessed by contrast-enhanced computed tomography (CT) had aggressive characteristics. However, no correlations between malignancy and other radiological features including calcification were found. These findings indicate that diagnosis of malignant SPTP is difficult with imaging studies. Endoscopic ultrasound-guided fine needle aspiration (EUS-FNA) has been shown to be useful for preoperative definite diagnosis^[42]. However, it may cause rupture of tumor and seeding of the needle tract by tumor cells during the procedure^[43,44]. Although EUS-FNA has been used more frequently than ever in SPTP^[13], its malignant nature is still difficult to confirm because of lack of specific markers.

Position emission tomography/computed tomogra-

Table 1 Reported series (> 20 cases) of solid pseudopapillary tumor of the pancreas in the English literature

Ref.	Country	Centers	F/M	Age (yr)	Size (cm)	Malignant, <i>n</i> (%)	Follow up (mo)	R/M (<i>n</i>)	Alive (<i>n</i>)
Peng <i>et al</i> ^[17] , 2006	China	Single	25/0	33 (11-65)	9.3 (2.5-25)	3 (12)	3-111	0	25
Yu <i>et al</i> ^[18] , 2007	China	Single	25/1	25.2 (13-57)	7.5 (3.8-15)	9 (34.6)	66 (10-237)	2	24
Machado <i>et al</i> ^[19] , 2008	Brazil	Single	27/7	23 (10-72)	7 (1.5-15)	13 (38.2)	84 (3-170)	2	33
Lee <i>et al</i> ^[20] , 2008	South Korea	Multi	57/5	30 (8-63)	6.5 (1.5-14)	9 (14.5)	47.5 (5.1-240.4)	2	62
Matos <i>et al</i> ^[21] , 2009	United States/ Germany	Multi	20/1	33 (13-60)	5.5 (2.5-19.3)	3 (14.3)	55 (7-176)	0	21
Nguyen <i>et al</i> ^[22] , 2011	Australia	Multi	30/4	33.3 (19.6-42.3)	6 (4.5-9)	9 (26.5)	70 (48-178)	2	32
Kim <i>et al</i> ^[23] , 2011	South Korea	Single	98/16	36 (11-75)	4.2 (1.2-15)	26 (22.8)	57 (11-177)	4	114
Butte <i>et al</i> ^[24] , 2011	United States	Single	38/7	38 (10-63)	4.9 (1.4-20)	9 (20)	44 (1-250)	5	38 ¹
Cai <i>et al</i> ^[25] , 2013	China	Single	30/3	29.2 (12-59)	4.9 (2-15)	17 (51.5)	45 (4-118)	1	32
El Nakeeb <i>et al</i> ^[26] , 2013	Egypt	Single	22/2	24.83 (12-52)	9.2 (3-25)	6 (25)	71.6 (1-180)	2	22
Raman <i>et al</i> ^[27] , 2013	United States	Single	43/8	29.3 (12.2-74.8)	5.3 (1.7-11.1)	11 (21.6)	37 (0-122)	1	50
Serrano <i>et al</i> ^[28] , 2014	Canada	Single	26/6	36 (13-64)	4.7 (1.5-14)	15 (46.9)	43 (3-207)	3	31
Suzuki <i>et al</i> ^[29] , 2014	Japan	Single	29/5	37.1 (15-68)	4.3 (1-11)	3 (8.8)	67 (3-326)	0	34
Kim <i>et al</i> ^[30] , 2014	South Korea	Single	85/21	36 (10-65)	4.5 (1-15)	17 (16)	56.9 (37-93.4)	2	105
Kang <i>et al</i> ^[6] , 2014	South Korea	Multi	317/34	36.8 ± 12.4	5.7 ± 3.3	98 (27.9)	> 6	9	316 ²
Estrella <i>et al</i> ^[7] , 2014	United States	Single	54/10	33 (9-62)	5 (1.4-20)	49 (76.6)	76 (2-203)	10	53 ³
Yu <i>et al</i> ^[31] , 2015	China	Multi	93/4	31.2 (16-57)	5.9 (1.5-14)	16 (16.5)	70.2 (3.5-221.5)	3	96
Zhang <i>et al</i> ^[32] , 2015	China	Single	56/6	26 (8-66)	7.2 (3-15)	3 (4.8)	46 (2-135)	0	62
Yang <i>et al</i> ^[8] , 2016	China	Single	58/13	31 (12-64)	5 (1-13)	13 (18.3)	45 (3-118)	3	70
Irtan <i>et al</i> ^[33] , 2016	France	Multi	41/10	13.1 (8.7-17.9)	7 (2-12)	22 (43.1)	65 (0.3-221)	7	51
Marchegiani <i>et al</i> ^[34] , 2016	Italy/United States	Multi	113/18	33 (7-68)	4 (0.7-20)	16 (12.2)	62 (12-304)	2	105 ⁴
Xu <i>et al</i> ^[35] , 2017	China	Single	93/28	33.7 (11-68)	5 (1-13)	35 (28.9)	42.7 (6-97)	3	100 ⁵
Song <i>et al</i> ^[36] , 2017	China	Single	46/7	35.4 (14-67)	6.4 (2-14)	10 (18.9)	48 (3-123)	2	45 ⁶
Lubezky <i>et al</i> ^[37] , 2017	Israel	Single	29/3	28.4 ± 12.2	5.9 (0.9-14)	13 (40.6)	49.2 (1-228)	4	31

Note: We included data from the latest or most complete study in the case of duplicate reports on overlapping patients from the same institutions; ¹Three patients died of SPTP, and four patients died of other causes; ²317 patients with more than 6 mo follow-up were reported for evaluation of oncologic outcome; ³Follow-up information was available for 59 patients; ⁴Follow-up information was available for 105 patients; ⁵Follow-up information was available for 103 patients; ⁶Follow-up information was available for 48 patients. F: Female; M: Male; R/M: Recurrence and/or metastasis.

phy (PET/CT) is a useful modality in the detection of malignant tumors and has been widely used in patients with pancreatic disease^[45]. Limited data are available on PET/CT characteristics of SPTP, making the value of this modality controversial. It has been reported that SPTP has significantly higher tumor size-adjusted metabolic tumor volume and total lesion glycolysis compared with pancreatic ductal adenocarcinoma^[46], which leads to a high rate of false positivity in F-18-fluorodeoxyglucose PET/CT when diagnosing this disease (Figure 3). However, this feature suggests that PET/CT may be helpful in detecting metastases of SPTP. Kang *et al*^[47] categorized SPTP into five types according to the PET images and found no association between the fluorodeoxyglucose uptake and malignant potential. Until now, no definitive conclusions can be drawn about the clinical significance of PET/CT in SPTP due to limited cases reported. Thus, the clinical application value of PET scan in SPTP needs further investigation.

TREATMENT OF MALIGNANT SPTP

Surgical resection is curative in most of the patients with SPTP resulting in a five-year disease-specific survival rate of 98.5%^[8]. Long-term survival can be achieved

even in those with advanced or metastatic disease. It is interesting to note that patients who underwent limited resection with microscopically positive margins had similar outcomes as those who underwent extensive surgery with R0 resection^[7]. The generally good prognosis of SPTP attributes to its relatively low malignant biological behavior. Therefore, aggressive surgical intervention is the optimal therapy for patients with advanced SPTP, even with metastasis. Wang *et al*^[48] reported four patients with liver metastases undergoing aggressive surgery. All the patients received surgical resections for both the primary and metastatic lesions as completely as possible, and had good clinical outcomes during follow-up.

Adjuvant therapies such as chemotherapy (5-fluorouracil and gemcitabine as the main chemotherapeutic drugs) and radiotherapy have been reported in a few patients with a mean survival of 51.1 mo^[13]. Sporadic reports found that neoadjuvant chemotherapy or radiation therapy could benefit some patients with unresectable tumors^[49-51]. Other therapeutic methods including radiofrequency ablation^[52], transcatheter arterial chemoembolization^[53], selective internal radiotherapy (SIRT)^[54] and liver transplantation^[55] have also been reported to achieve good results for patients with

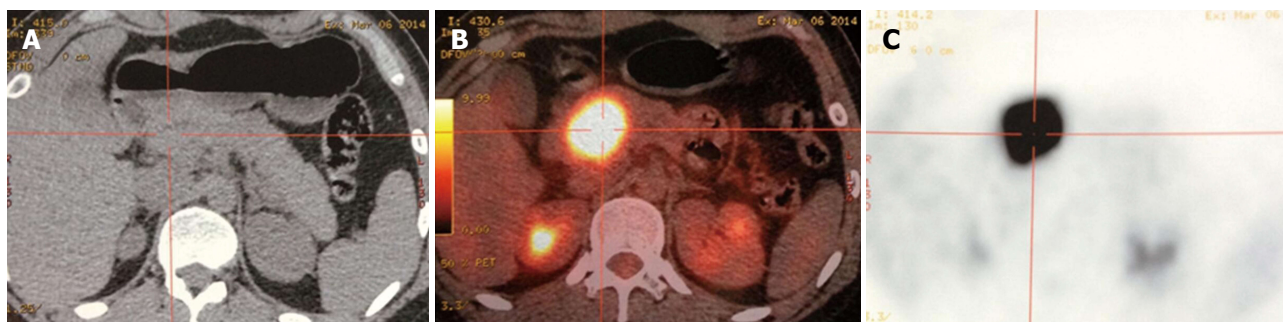


Figure 3 High uptake of F-18-fluorodeoxyglucose in a patient with solid pseudopapillary tumor of the pancreas. SPTP in a 25-year-old female patient with a T2 stage tumor. A: CT scan revealed a 5-cm isodense mass in the pancreatic head. B and C: Transaxial PET/CT (B) and PET (C) showed a hypermetabolic lesion with the maximum standardized uptake value of 33. She was disease free for 32 mo after surgical resection. SPTP: Solid pseudopapillary tumor of the pancreas; PET/CT: Position emission tomography/computed tomography.

liver metastasis from SPTP. However, despite a better understanding of this disease, individual treatment of unresectable or metastatic SPTP requires further study.

PREDICTORS OF MALIGNANCY

Malignant SPTP occurs in 18.3% of adult patients and in 43.1% of pediatric patients^[8,33]. Preoperative differential diagnosis between benign and malignant SPTP is usually very difficult except in patients with tumor invasion to adjacent organs or with distant metastasis. There has been no consistency about the diagnostic criteria of malignant SPTP until today. Criteria for malignancy in SPTP have not been well established. Many researchers used the WHO-defined criteria for classification of solid pseudopapillary carcinoma, such as angioinvasion, perineural invasion, or deep infiltration into the surrounding tissue or metastasis to confirm the diagnosis of malignant SPTP^[30]. Butte *et al.*^[24] defined malignant SPTP as locally unresectable tumor with macrovascular invasion, metastatic disease to regional or distant sites, or recurrence of disease after surgery. Ye *et al.*^[56] considered SPTP with incomplete capsules as malignant.

Due to the arbitrary criteria of malignancy used, and rarity of the disease with small proportion of malignancy, conflicting results have been reported about factors associated with malignant potential across institutions^[8,20,23,24,26,27,30,31,35,36,38,39,56-58] (Figure 4). Butte *et al.*^[24] found that patients with malignant SPTP presented with larger tumor size ($P < 0.005$). Chung *et al.*^[39] explored differential imaging features between malignant and benign SPTP, and found that malignant SPTP more frequently had focal lobulated margins ($P = 0.027$) and focal discontinuity of capsule ($P = 0.005$). The study by Ye *et al.*^[56] revealed that SPTP with incomplete capsule had larger tumor size ($P = 0.0015$) and mainly exophytic growth pattern ($P = 0.0194$). Yu *et al.*^[31] and Xu *et al.*^[35] showed that positive status for Ki-67 correlated with malignancy of SPTP, while Yang *et al.*^[8] did not demonstrate any association between the Ki-67 index and malignant SPTP. Most other studies^[20,23,26,27,57,58] found no significant differences between benign and malignant

SPTP, including age, sex, symptomatology, laboratory data, tumor marker, tumor size and location, tumor composition, growth pattern, and histopathology. Thus, malignancy cannot be easily predicted on the basis of preoperative findings and immunohistochemical patterns.

PREDICTORS OF ADVERSE OUTCOME

Most of the patients with SPTP have a good prognosis, while some have a less favorable prognosis because of recurrence and/or metastases. Studies on SPTP were characterized by case reports and small case series lacking of long-term follow-up. Kang *et al.*^[6] reported a low recurrence rate (2.8%) and excellent disease free survival and overall survival for SPTP after surgical resection in South Korea. The patients had a 5-year disease free survival of 95.4% and an overall survival of 98.8%. In a recent systematic review, the 5-year and 10-year recurrence free survival was 89.5% and 86.3%, respectively, with the 5-year and 10-year disease specific survival of 92.3% and 86.5%, respectively^[8]. It is unclear whether factors associated with malignant potential are statistically significant predictors of adverse outcomes. Although a few recent studies have gathered significant series of SPTP, results are inconclusive with regard to predictors of prognosis^[3,6-8,28,33-38,59,60] (Figure 5).

Estrella *et al.*^[7] showed that recurrent/metastatic SPTP was significantly associated with larger tumor size, invasion of muscular vessels, and the European Neuroendocrine Tumour Society (ENETS) tumor stage, but not with other clinicopathologic factors. In addition, muscular vessel invasion, ENETS T4 disease, and stage IV were important predictors of poor disease-specific survival after surgical resection. Kang *et al.*^[6] demonstrated that tumor size larger than 8 cm, microscopic malignant features, and stage IV were significant prognostic factors for tumor recurrence by multivariate analysis. Irtan *et al.*^[33] confirmed that the significant risk factors for recurrence in pediatric cases of SPTP were age < 13.5 years at diagnosis and positive surgical margins at initial tumor resection. It is interesting to note that many other studies^[6-8,22,28,34,60] have shown that patients who

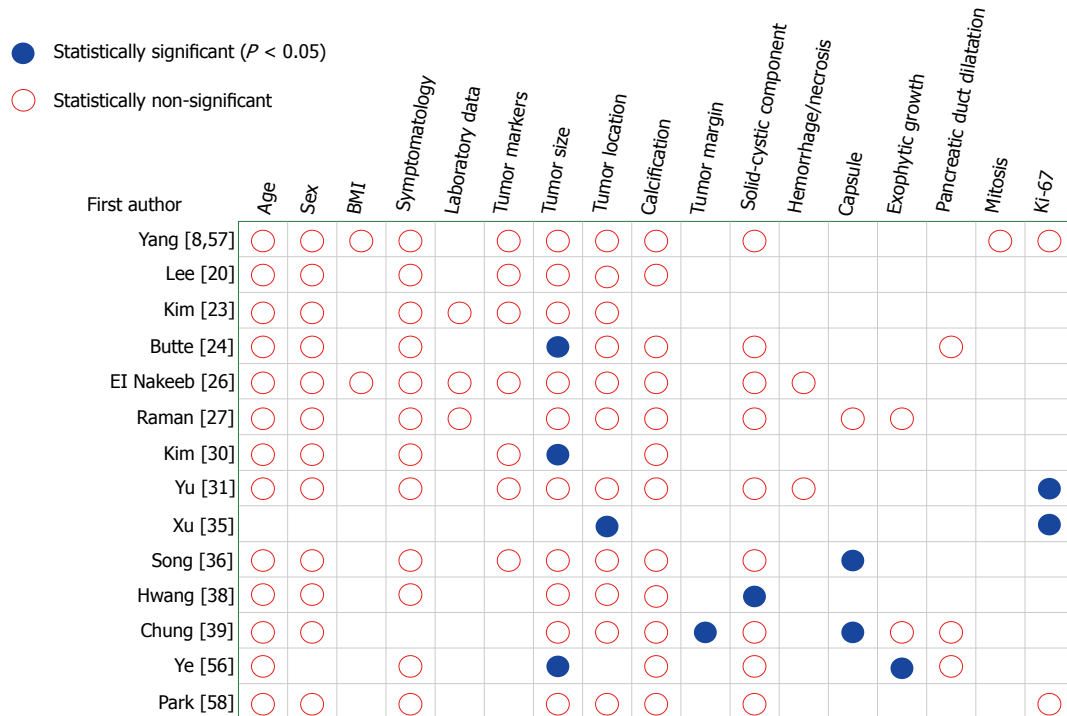


Figure 4 Factors associated with malignant solid pseudopapillary tumor of the pancreas by univariate analysis.

underwent limited resection and those with R1 resection had the same clinical outcomes as those who received more extensive resection with negative margin. Serrano *et al*^[28] clarified that patients with stage IV or lymphovascular invasion more commonly developed recurrence. Both studies of Marchegiani *et al*^[34] and Hwang *et al*^[38] revealed that recurrence was more common in patients with malignant SPTP which fulfilled the WHO criteria. The study by Zhang *et al*^[59] indicated that recurrence in malignant SPTP correlated with family malignant tumor history.

Several studies^[3,57,61,62] have proposed Ki-67 as an additional support to histology for predicting tumor outcome, but conflicting results do exist. Yang *et al*^[8] identified the most discriminating value of Ki-67 index using receiver operating characteristic curve analysis and demonstrated that the prognostic value of Ki-67 was maintained in both the Huashan cohort and the new historical cohort from literature. The result was consistent with a latest study by Kim *et al*^[3]. However, similar to most studies, multivariate analysis could not be performed due to the small number of events. Nevertheless, a much larger number of patients is needed to validate the prognostic relevance of Ki-67.

CHALLENGES AND PERSPECTIVES

Recent studies have analyzed the biological behavior of SPTP, however reliable data on long-term follow-up are still needed. Case reports, small retrospective case series, and subjective views rather than facts dominate the available data. These studies have limitations

including a small number of cases or events, no uniform parameters studied, lack of a gold standard for judging malignancy, and short length of follow-up. Although some studies adopted the WHO definition of malignancy, a considerable number of studies did not specify the proportion of malignant patients. The excellent prognosis makes overall survival difficult to be assessed, even if several studies have evaluated disease/recurrence free survival. In the light of these limitations, multicenter large-scale studies with long-term follow-up are needed to determine prognostic factors.

To date, no staging systems have been used to stratify patients in any international guidelines for management and follow-up of SPTP^[63-65]. The American Joint Committee on Cancer (AJCC)/Union for International Cancer Control (UICC) tumor, node, metastasis (TNM) staging system is a generally accepted standard for cancer staging with the principal aim of facilitating a uniform and standardized analysis of malignant tumors. While the current TNM staging system applies well to pancreatic carcinoma, it is not specific to SPTP. Tumors considered for the TNM system have potentials of local invasiveness (T-categorization) and spread via the lymphatic and blood vessels (N- and M-categories). In view of the rarity of lymphatic and hematogenous metastasis from SPTP, its usefulness in this condition was evidently limited.

The relative rarity of SPTP has delayed the development of evidence-based treatment guidelines. Patients with benign SPTP are still at risk of tumor recurrence or metastasis after surgical resection. Contemporary evidence supports surgery as the primary treatment for patients with operable metastatic SPTP^[48,66]. One ob-

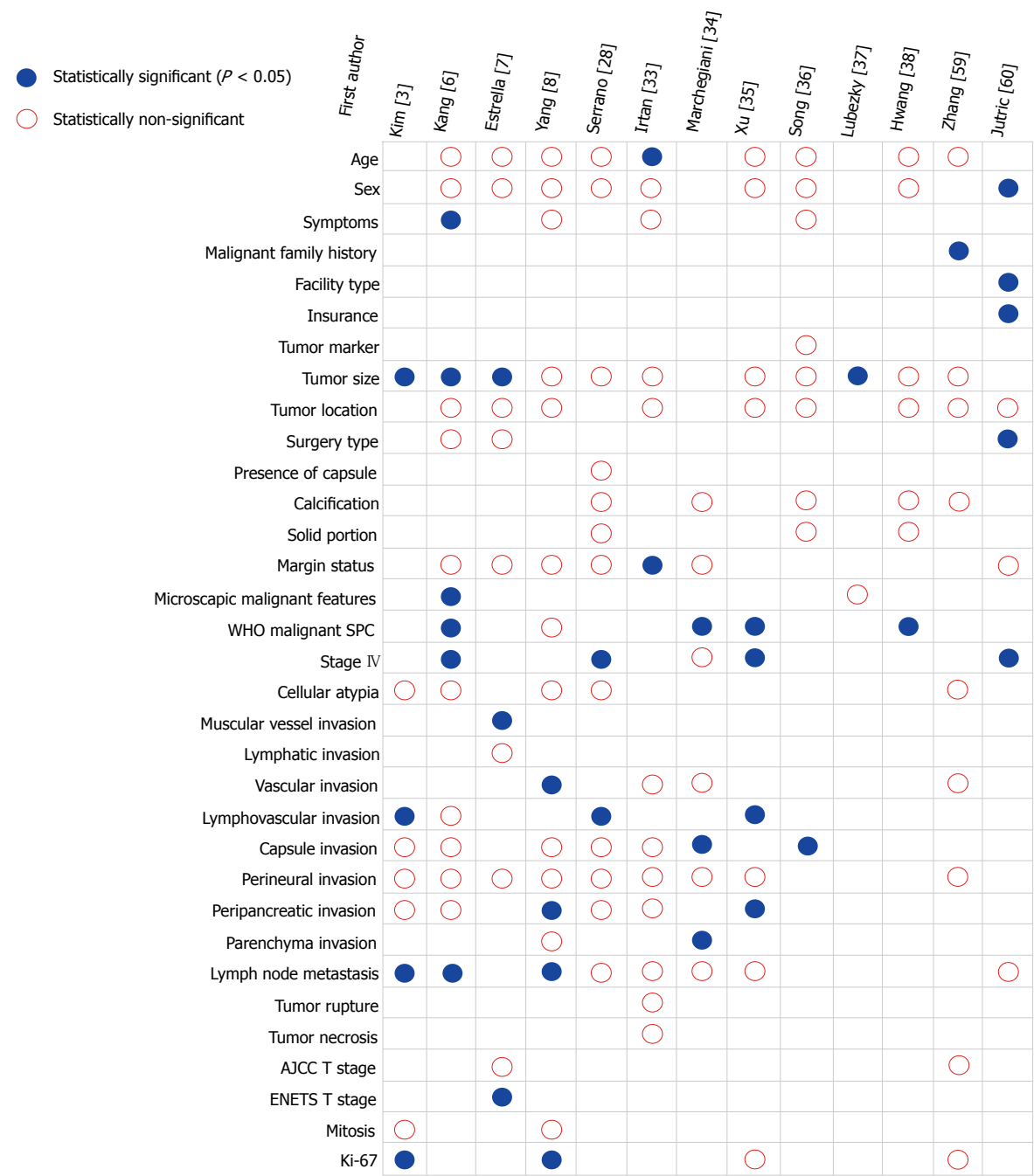

Figure 5 Predictors for adverse outcome of solid pseudopapillary tumor of the pancreas after surgical resection by univariate analysis. WHO: World Health Organization; SPC: Solid pseudopapillary carcinoma; AJCC: American Joint Committee on Cancer; ENETS: European Neuroendocrine Tumour Society.

stale to better management of patients is the lack of a predictive classification that accurately describes the complexity and heterogeneity of this disease. In order to provide proper information to predict prognosis, a more specific and standardized histopathological evaluation of SPTP is needed. It is obvious that we urgently need an international consensus for collecting standardized data on SPTP. Better understanding of molecular mechanisms involved in SPTP tumorigenesis is important for improved management. It is probable that novel molecular prognostic variables for SPTP, which may be incorporated

into classification systems, will emerge in future.

REFERENCES

- 1 Yang F, Fu DL, Jin C, Long J, Yu XJ, Xu J, Ni QX. Clinical experiences of solid pseudopapillary tumors of the pancreas in China. *J Gastroenterol Hepatol* 2008; **23**: 1847-1851 [PMID: 18752561 DOI: 10.1111/j.1440-1746.2008.05526.x]
- 2 Leraas HJ, Kim J, Sun Z, Ezekian B, Gulack BC, Reed CR, Tracy ET. Solid Pseudopapillary Neoplasm of the Pancreas in Children and Adults: A National Study of 369 Patients. *J Pediatr Hematol Oncol* 2018; **40**: e233-e236 [PMID: 29240036 DOI: 10.1097/

- MPH.0000000000001049]
- 3 **Kim EK**, Jang M, Park M, Kim H. LEF1, TFE3, and AR are putative diagnostic markers of solid pseudopapillary neoplasms. *Oncotarget* 2017; **8**: 93404-93413 [PMID: 29212159 DOI: 10.18632/oncotarget.21854]
- 4 **Park M**, Kim M, Hwang D, Park M, Kim WK, Kim SK, Shin J, Park ES, Kang CM, Paik YK, Kim H. Characterization of gene expression and activated signaling pathways in solid-pseudopapillary neoplasm of pancreas. *Mod Pathol* 2014; **27**: 580-593 [PMID: 24072181 DOI: 10.1038/modpathol.2013.154]
- 5 **Park M**, Lim JS, Lee HJ, Na K, Lee MJ, Kang CM, Paik YK, Kim H. Distinct Protein Expression Profiles of Solid-Pseudopapillary Neoplasms of the Pancreas. *J Proteome Res* 2015; **14**: 3007-3014 [PMID: 26148796 DOI: 10.1021/acs.jproteome.5b00423]
- 6 **Kang CM**, Choi SH, Kim SC, Lee WJ, Choi DW, Kim SW; Korean Pancreatic Surgery Club. Predicting recurrence of pancreatic solid pseudopapillary tumors after surgical resection: a multicenter analysis in Korea. *Ann Surg* 2014; **260**: 348-355 [PMID: 24743622 DOI: 10.1097/SLA.0000000000000583]
- 7 **Estrella JS**, Li L, Rashid A, Wang H, Katz MH, Fleming JB, Abbruzzese JL, Wang H. Solid pseudopapillary neoplasm of the pancreas: clinicopathologic and survival analyses of 64 cases from a single institution. *Am J Surg Pathol* 2014; **38**: 147-157 [PMID: 24418850 DOI: 10.1097/PAS.0000000000000141]
- 8 **Yang F**, Yu X, Bao Y, Du Z, Jin C, Fu D. Prognostic value of Ki-67 in solid pseudopapillary tumor of the pancreas: Huashan experience and systematic review of the literature. *Surgery* 2016; **159**: 1023-1031 [PMID: 26619927 DOI: 10.1016/j.surg.2015.10.018]
- 9 **Soroida Y**, Sato M, Hikita H, Hagiwara S, Sato M, Gotoh H, Kato S, Iwai T, Yamazaki T, Yatomi Y, Sasano T, Ikeda H. Pancreatic cysts in general population on ultrasonography: Prevalence and development of risk score. *J Gastroenterol* 2016; **51**: 1133-1140 [PMID: 26988361 DOI: 10.1007/s00535-016-1196-y]
- 10 **Zanini N**, Giordano M, Smerieri E, Cipolla d'Abruzzo G, Guidi M, Pazzagli G, De Luca F, Chiaruzzi G, Vitullo G, Piva P, Lombardi R, Jovine E, Gatti M, Landolfo G. Estimation of the prevalence of asymptomatic pancreatic cysts in the population of San Marino. *Pancreatol* 2015; **15**: 417-422 [PMID: 26028332 DOI: 10.1016/j.pan.2015.05.461]
- 11 **Moris M**, Bridges MD, Pooley RA, Raimondo M, Woodward TA, Stauffer JA, Asbun HJ, Wallace MB. Association Between Advances in High-Resolution Cross-Section Imaging Technologies and Increase in Prevalence of Pancreatic Cysts From 2005 to 2014. *Clin Gastroenterol Hepatol* 2016; **14**: 585-593.e3 [PMID: 26370569 DOI: 10.1016/j.cgh.2015.08.038]
- 12 **Lin QJ**, Yang F, Jin C, Fu DL. Current status and progress of pancreatic cancer in China. *World J Gastroenterol* 2015; **21**: 7988-8003 [PMID: 26185370 DOI: 10.3748/wjg.v21.i26.7988]
- 13 **Law JK**, Ahmed A, Singh VK, Akshintala VS, Olson MT, Raman SP, Ali SZ, Fishman EK, Kamel I, Canto MI, Dal Molin M, Moran RA, Khashab MA, Ahuja N, Goggins M, Hruban RH, Wolfgang CL, Lennon AM. A systematic review of solid-pseudopapillary neoplasms: are these rare lesions? *Pancreas* 2014; **43**: 331-337 [PMID: 24622060 DOI: 10.1097/MPA.0000000000000061]
- 14 **Yoon WJ**, Lee JK, Lee KH, Ryu JK, Kim YT, Yoon YB. Cystic neoplasms of the exocrine pancreas: an update of a nationwide survey in Korea. *Pancreas* 2008; **37**: 254-258 [PMID: 18815545 DOI: 10.1097/MPA.0b013e3181676ba4]
- 15 **Baek JH**, Lee JM, Kim SH, Kim SJ, Kim SH, Lee JY, Han JK, Choi BI. Small (<or=3 cm) solid pseudopapillary tumors of the pancreas at multiphasic multidetector CT. *Radiology* 2010; **257**: 97-106 [PMID: 20663966 DOI: 10.1148/radiol.10092089]
- 16 **Yang F**, Jin C, Fu D. Evolution of liver metastasis from solid pseudopapillary tumor of the pancreas. *Surgery* 2017; **161**: 1739-1740 [PMID: 27302102 DOI: 10.1016/j.surg.2016.05.001]
- 17 **Peng CH**, Chen DF, Zhou GW, Yang WP, Tao ZY, Lei RQ, Zhange SD, Li HW. The solid-pseudopapillary tumor of pancreas: the clinical characteristics and surgical treatment. *J Surg Res* 2006; **131**: 276-282 [PMID: 16457845 DOI: 10.1016/j.jss.2005.11.585]
- 18 **Yu CC**, Tseng JH, Yeh CN, Hwang TL, Jan YY. Clinicopathological study of solid and pseudopapillary tumor of pancreas: emphasis on magnetic resonance imaging findings. *World J Gastroenterol* 2007; **13**: 1811-1815 [PMID: 17465471 DOI: 10.3748/wjg.v13.i12.1811]
- 19 **Machado MC**, Machado MA, Bacchella T, Jukemura J, Almeida JL, Cunha JE. Solid pseudopapillary neoplasm of the pancreas: distinct patterns of onset, diagnosis, and prognosis for male versus female patients. *Surgery* 2008; **143**: 29-34 [PMID: 18154930 DOI: 10.1016/j.surg.2007.07.030]
- 20 **Lee SE**, Jang JY, Hwang DW, Park KW, Kim SW. Clinical features and outcome of solid pseudopapillary neoplasm: differences between adults and children. *Arch Surg* 2008; **143**: 1218-1221 [PMID: 19075175 DOI: 10.1001/archsurg.143.12.1218]
- 21 **Matos JM**, Grützmann R, Agaram NP, Saeger HD, Kumar HR, Lillemoe KD, Schmidt CM. Solid pseudopapillary neoplasms of the pancreas: a multi-institutional study of 21 patients. *J Surg Res* 2009; **157**: e137-e142 [PMID: 19818965 DOI: 10.1016/j.jss.2009.03.091]
- 22 **Nguyen NQ**, Johns AL, Gill AJ, Ring N, Chang DK, Clarkson A, Merrett ND, Kench JG, Colvin EK, Scarlett CJ, Biankin AV. Clinical and immunohistochemical features of 34 solid pseudopapillary tumors of the pancreas. *J Gastroenterol Hepatol* 2011; **26**: 267-274 [PMID: 21261715 DOI: 10.1111/j.1440-1746.2010.06466.x]
- 23 **Kim CW**, Han DJ, Kim J, Kim YH, Park JB, Kim SC. Solid pseudopapillary tumor of the pancreas: can malignancy be predicted? *Surgery* 2011; **149**: 625-634 [PMID: 21300390 DOI: 10.1016/j.surg.2010.11.005]
- 24 **Butte JM**, Brennan MF, Gönen M, Tang LH, D'Angelica MI, Fong Y, Dematteo RP, Jarnagin WR, Allen PJ. Solid pseudopapillary tumors of the pancreas. Clinical features, surgical outcomes, and long-term survival in 45 consecutive patients from a single center. *J Gastrointest Surg* 2011; **15**: 350-357 [PMID: 20824369 DOI: 10.1007/s11605-010-1337-1]
- 25 **Cai H**, Zhou M, Hu Y, He H, Chen J, Tian W, Deng Y. Solid-pseudopapillary neoplasms of the pancreas: clinical and pathological features of 33 cases. *Surg Today* 2013; **43**: 148-154 [PMID: 22825652 DOI: 10.1007/s00595-012-0260-3]
- 26 **El Nakeeb A**, Abdel Wahab M, Elkashef WF, Azer M, Kandil T. Solid pseudopapillary tumour of the pancreas: Incidence, prognosis and outcome of surgery (single center experience). *Int J Surg* 2013; **11**: 447-457 [PMID: 23619333 DOI: 10.1016/j.ijss.2013.04.009]
- 27 **Raman SP**, Kawamoto S, Law JK, Blackford A, Lennon AM, Wolfgang CL, Hruban RH, Cameron JL, Fishman EK. Institutional experience with solid pseudopapillary neoplasms: focus on computed tomography, magnetic resonance imaging, conventional ultrasound, endoscopic ultrasound, and predictors of aggressive histology. *J Comput Assist Tomogr* 2013; **37**: 824-833 [PMID: 24045264 DOI: 10.1097/RCT.0b013e31829d44fa]
- 28 **Serrano PE**, Serra S, Al-Ali H, Gallinger S, Greig PD, McGilvray ID, Moulton CA, Wei AC, Cleary SP. Risk factors associated with recurrence in patients with solid pseudopapillary tumors of the pancreas. *JOP* 2014; **15**: 561-568 [PMID: 25435571 DOI: 10.6092/1590-8577/2423]
- 29 **Suzuki S**, Hatori T, Furukawa T, Shiratori K, Yamamoto M. Clinical and pathological features of solid pseudopapillary neoplasms of the pancreas at a single institution. *Dig Surg* 2014; **31**: 143-150 [PMID: 24970563 DOI: 10.1159/000363420]
- 30 **Kim MJ**, Choi DW, Choi SH, Heo JS, Sung JY. Surgical treatment of solid pseudopapillary neoplasms of the pancreas and risk factors for malignancy. *Br J Surg* 2014; **101**: 1266-1271 [PMID: 25052300 DOI: 10.1002/bjs.9577]
- 31 **Yu P**, Cheng X, Du Y, Yang L, Xu Z, Yin W, Zhong Z, Wang X, Xu H, Hu C. Solid Pseudopapillary Neoplasms of the Pancreas: a 19-Year Multicenter Experience in China. *J Gastrointest Surg* 2015; **19**: 1433-1440 [PMID: 26001371 DOI: 10.1007/s11605-015-2862-8]
- 32 **Zhang C**, Liu F, Chang H, Li H, Zhou X, Lu J, Qin C, Sun Y, Sun H, Lin J. Less Aggressive Surgical Procedure for Treatment of Solid Pseudopapillary Tumor: Limited Experience from a Single Institute. *PLoS One* 2015; **10**: e0143452 [PMID: 26599966 DOI: 10.1371/journal.pone.0143452]
- 33 **Irtan S**, Galmiche-Rolland L, Elie C, Orbach D, Sauvanet A, Elias D, Guérin F, Coze C, Faure-Contet C, Becmeur F, Demarche M, Galifer

- RB, Galloy MA, Podevin G, Aubert D, Piolat C, De Lagausie P, Sarnacki S. Recurrence of Solid Pseudopapillary Neoplasms of the Pancreas: Results of a Nationwide Study of Risk Factors and Treatment Modalities. *Pediatr Blood Cancer* 2016; **63**: 1515-1521 [PMID: 27186826 DOI: 10.1002/pbc.25986]
- 34 **Marchegiani G**, Andrianello S, Massignani M, Malleo G, Maggino L, Paiella S, Ferrone CR, Luchini C, Scarpa A, Capelli P, Mino-Kenudson M, Lillemoe KD, Bassi C, Castillo CF, Salvia R. Solid pseudopapillary tumors of the pancreas: Specific pathological features predict the likelihood of postoperative recurrence. *J Surg Oncol* 2016; **114**: 597-601 [PMID: 27471041 DOI: 10.1002/jso.24380]
- 35 **Xu Y**, Zhao G, Pu N, Nuerxiat A, Ji Y, Zhang L, Rong Y, Lou W, Wang D, Kuang T, Xu X, Wu W. One Hundred Twenty-One Resected Solid Pseudopapillary Tumors of the Pancreas: An 8-Year Single-Institution Experience at Zhongshan Hospital, Shanghai, China. *Pancreas* 2017; **46**: 1023-1028 [PMID: 28742543 DOI: 10.1097/MPA.0000000000000885]
- 36 **Song H**, Dong M, Zhou J, Sheng W, Zhong B, Gao W. Solid Pseudopapillary Neoplasm of the Pancreas: Clinicopathologic Feature, Risk Factors of Malignancy, and Survival Analysis of 53 Cases from a Single Center. *Biomed Res Int* 2017; **2017**: 5465261 [PMID: 29094047 DOI: 10.1155/2017/5465261]
- 37 **Lubezky N**, Papoulas M, Lessing Y, Gitstein G, Brazowski E, Nachmany I, Lahat G, Goykman Y, Ben-Yehuda A, Nakache R, Klausner JM. Solid pseudopapillary neoplasm of the pancreas: Management and long-term outcome. *Eur J Surg Oncol* 2017; **43**: 1056-1060 [PMID: 28238521 DOI: 10.1016/j.ejso.2017.02.001]
- 38 **Hwang J**, Kim DY, Kim SC, Namgoong JM, Hong SM. Solid-pseudopapillary neoplasm of the pancreas in children: can we predict malignancy? *J Pediatr Surg* 2014; **49**: 1730-1733 [PMID: 25487471 DOI: 10.1016/j.jpedsurg.2014.09.011]
- 39 **Chung YE**, Kim MJ, Choi JY, Lim JS, Hong HS, Kim YC, Cho HJ, Kim KA, Choi SY. Differentiation of benign and malignant solid pseudopapillary neoplasms of the pancreas. *J Comput Assist Tomogr* 2009; **33**: 689-694 [PMID: 19820493 DOI: 10.1097/RCT.0b013e31818f2a74]
- 40 **Barat M**, Dohan A, Dautry R, Barral M, Pocard M, Soyer P. Solid pseudopapillary adenocarcinoma of the pancreas: CT presentation of a rare malignant variant. *Diagn Interv Imaging* 2017; **98**: 823-824 [PMID: 28377084 DOI: 10.1016/j.diii.2017.01.012]
- 41 **Rastogi A**, Assing M, Taggart M, Rao B, Sun J, Elsayes K, Tamm E, Bhosale P. Does Computed Tomography Have the Ability to Differentiate Aggressive From Nonaggressive Solid Pseudopapillary Neoplasm? *J Comput Assist Tomogr* 2018; **42**: 405-411 [PMID: 29287021 DOI: 10.1097/RCT.0000000000000698]
- 42 **Law JK**, Stoitia A, Wever W, Gleeson FC, Dries AM, Blackford A, Kiswani V, Shin EJ, Khashab MA, Canto MI, Singh VK, Lennon AM. Endoscopic ultrasound-guided fine needle aspiration improves the pre-operative diagnostic yield of solid-pseudopapillary neoplasm of the pancreas: an international multicenter case series (with video). *Surg Endosc* 2014; **28**: 2592-2598 [PMID: 24718662 DOI: 10.1007/s00464-014-3508-8]
- 43 **Virgilio E**, Mercantini P, Ferri M, Cunsolo G, Tarantino G, Cavallini M, Ziparo V. Is EUS-FNA of solid-pseudopapillary neoplasms of the pancreas as a preoperative procedure really necessary and free of acceptable risks? *Pancreatology* 2014; **14**: 536-538 [PMID: 25227317 DOI: 10.1016/j.pan.2014.08.004]
- 44 **Lévy P**, Hammel P, Ruszniewski P. [Do not biopsy pseudopapillary and solid tumors of the pancreas!]. *Gastroenterol Clin Biol* 2009; **33**: 501-502 [PMID: 19394178 DOI: 10.1016/j.gcb.2009.03.003]
- 45 **Wang XY**, Yang F, Jin C, Fu DL. Utility of PET/CT in diagnosis, staging, assessment of resectability and metabolic response of pancreatic cancer. *World J Gastroenterol* 2014; **20**: 15580-15589 [PMID: 25400441 DOI: 10.3748/wjg.v20.i42.15580]
- 46 **Kim YI**, Kim SK, Paeng JC, Lee HY. Comparison of F-18-FDG PET/CT findings between pancreatic solid pseudopapillary tumor and pancreatic ductal adenocarcinoma. *Eur J Radiol* 2014; **83**: 231-235 [PMID: 24290142 DOI: 10.1016/j.ejrad.2013.09.031]
- 47 **Kang CM**, Cho A, Kim H, Chung YE, Hwang HK, Choi SH, Lee WJ. Clinical correlations with (18)FDG PET scan patterns in solid pseudopapillary tumors of the pancreas: still a surgical enigma? *Pancreatology* 2014; **14**: 515-523 [PMID: 25256437 DOI: 10.1016/j.pan.2014.08.003]
- 48 **Wang WB**, Zhang TP, Sun MQ, Peng Z, Chen G, Zhao YP. Solid pseudopapillary tumor of the pancreas with liver metastasis: Clinical features and management. *Eur J Surg Oncol* 2014; **40**: 1572-1577 [PMID: 24961631 DOI: 10.1016/j.ejso.2014.05.012]
- 49 **Maffuz A**, Bustamante Fde T, Silva JA, Torres-Vargas S. Preoperative gemcitabine for unresectable, solid pseudopapillary tumour of the pancreas. *Lancet Oncol* 2005; **6**: 185-186 [PMID: 15737835 DOI: 10.1016/S1470-2045(05)01770-5]
- 50 **Kanter J**, Wilson DB, Strasberg S. Downsizing to resectability of a large solid and cystic papillary tumor of the pancreas by single-agent chemotherapy. *J Pediatr Surg* 2009; **44**: e23-e25 [PMID: 19853735 DOI: 10.1016/j.jpedsurg.2009.07.026]
- 51 **Naar L**, Spanomichou DA, Mastoraki A, Smyrniotis V, Arkadopoulos N. Solid Pseudopapillary Neoplasms of the Pancreas: A Surgical and Genetic Enigma. *World J Surg* 2017; **41**: 1871-1881 [PMID: 28251269 DOI: 10.1007/s00268-017-3921-y]
- 52 **Li JX**, Wu H, Huang JW, Prasoon P, Zeng Y. Synchronous intra-operative radiofrequency ablation for multiple liver metastasis and resection of giant solid pseudopapillary tumors of the pancreas. *Chin Med J (Engl)* 2012; **125**: 1661-1663 [PMID: 22800840]
- 53 **Liu T**, He J, Cao D, Huang Y. Successful treatment of liver metastasis from solid pseudopapillary tumor of the pancreas: a case report. *Contemp Oncol (Pozn)* 2013; **17**: 400-403 [PMID: 24592130 DOI: 10.5114/wo.2013.37225]
- 54 **Krug S**, Bartsch DK, Schober M, Librizzi D, Pfestroff A, Burbelko M, Moll R, Michl P, Gress TM. Successful selective internal radiotherapy (SIRT) in a patient with a malignant solid pseudopapillary pancreatic neoplasm (SPN). *Pancreatology* 2012; **12**: 423-427 [PMID: 23127531 DOI: 10.1016/j.pan.2012.07.014]
- 55 **Dovigo AG**, Diaz MB, Gutiérrez MG, Selles CF, Grobas JP, Valladares M, Suárez F, Marini M. Liver transplantation as treatment in a massive metastasis from Gruber-Frantz pancreatic tumor: a case report. *Transplant Proc* 2011; **43**: 2272-2273 [PMID: 21839254 DOI: 10.1016/j.transproceed.2011.05.029]
- 56 **Ye J**, Ma M, Cheng D, Yuan F, Deng X, Zhan Q, Shen B, Peng C. Solid-pseudopapillary tumor of the pancreas: clinical features, pathological characteristics, and origin. *J Surg Oncol* 2012; **106**: 728-735 [PMID: 22688864 DOI: 10.1002/jso.23195]
- 57 **Yang F**, Jin C, Long J, Yu XJ, Xu J, Di Y, Li J, Fu de L, Ni QX. Solid pseudopapillary tumor of the pancreas: a case series of 26 consecutive patients. *Am J Surg* 2009; **198**: 210-215 [PMID: 19268906 DOI: 10.1016/j.amjsurg.2008.07.062]
- 58 **Park JK**, Cho EJ, Ryu JK, Kim YT, Yoon YB. Natural history and malignant risk factors of solid pseudopapillary tumors of the pancreas. *Postgrad Med* 2013; **125**: 92-99 [PMID: 23816775 DOI: 10.3810/pgm.2013.03.2634]
- 59 **Zhang H**, Wang W, Yu S, Xiao Y, Chen J. The prognosis and clinical characteristics of advanced (malignant) solid pseudopapillary neoplasm of the pancreas. *Tumour Biol* 2016; **37**: 5347-5353 [PMID: 26561472 DOI: 10.1007/s13277-015-4371-5]
- 60 **Jutric Z**, Rozenfeld Y, Grendar J, Hammill CW, Cassera MA, Newell PH, Hansen PD, Wolf RF. Analysis of 340 Patients with Solid Pseudopapillary Tumors of the Pancreas: A Closer Look at Patients with Metastatic Disease. *Ann Surg Oncol* 2017; **24**: 2015-2022 [PMID: 28299507 DOI: 10.1245/s10434-017-5772-z]
- 61 **Adamthwaite JA**, Verbeke CS, Stringer MD, Guillou PJ, Menon KV. Solid pseudopapillary tumour of the pancreas: diverse presentation, outcome and histology. *JOP* 2006; **7**: 635-642 [PMID: 17095844]
- 62 **Yagci A**, Yakan S, Coskun A, Erkan N, Yıldırım M, Yalcın E, Postacı H. Diagnosis and treatment of solid pseudopapillary tumor of the pancreas: experience of one single institution from Turkey. *World J Surg Oncol* 2013; **11**: 308 [PMID: 24289652 DOI: 10.1186/1477-7819-11-308]
- 63 **Del Chiaro M**, Verbeke C, Salvia R, Klöppel G, Werner J, McKay C, Friess H, Manfredi R, Van Cutsem E, Lohr M, Segersvärd

- R; European Study Group on Cystic Tumours of the Pancreas. European experts consensus statement on cystic tumours of the pancreas. *Dig Liver Dis* 2013; **45**: 703-711 [PMID: 23415799 DOI: 10.1016/j.dld.2013.01.010]
- 64 **Italian Association of Hospital Gastroenterologists and Endoscopists**; Italian Association for the Study of the Pancreas, Buscarini E, Pezzilli R, Cannizzaro R, De Angelis C, Gion M, Morana G, Zamboni G, Arcidiacono P, Balzano G, Barresi L, Basso D, Bocus P, Calculli L, Capurso G, Canzonieri V, Casadei R, Crippa S, D'Onofrio M, Frulloni L, Fusaroli P, Manfredi G, Pacchioni D, Pasquali C, Rocca R, Ventrucchi M, Venturini S, Villanacci V, Zerbi A, Falconi M; Cystic Pancreatic Neoplasm Study Group. Italian consensus guidelines for the diagnostic work-up and follow-up of cystic pancreatic neoplasms. *Dig Liver Dis* 2014; **46**: 479-493 [PMID: 24809235 DOI: 10.1016/j.dld.2013.12.019]
- 65 **Vege SS**, Ziring B, Jain R, Moayyedi P; Clinical Guidelines Committee; American Gastroenterology Association. American gastroenterological association institute guideline on the diagnosis and management of asymptomatic neoplastic pancreatic cysts. *Gastroenterology* 2015; **148**: 819-822; quiz e12-13 [PMID: 25805375 DOI: 10.1053/j.gastro.2015.01.015]
- 66 **Tajima H**, Takamura H, Kitagawa H, Nakayama A, Shoji M, Watanabe T, Tsukada T, Nakanuma S, Okamoto K, Sakai S, Kinoshita J, Makino I, Nakamura K, Hayashi H, Oyama K, Inokuchi M, Nakagawara H, Miyashita T, Ninomiya I, Fushida S, Fujimura T, Wakayama T, Iseki S, Ikeda H, Ohta T. Multiple liver metastases of pancreatic solid pseudopapillary tumor treated with resection following chemotherapy and transcatheter arterial embolization: A case report. *Oncol Lett* 2015; **9**: 1733-1738 [PMID: 25789032 DOI: 10.3892/ol.2015.2967]

P- Reviewer: Sugita R **S- Editor:** Ji FF **L- Editor:** Ma JY
E- Editor: Tan WW





Published by **Baishideng Publishing Group Inc**
7901 Stoneridge Drive, Suite 501, Pleasanton, CA 94588, USA
Telephone: +1-925-223-8242
Fax: +1-925-223-8243
E-mail: bpgoffice@wjgnet.com
Help Desk: <http://www.f6publishing.com/helpdesk>
<http://www.wjgnet.com>

