

World Journal of *Gastroenterology*

World J Gastroenterol 2018 July 14; 24(26): 2785-2920



**REVIEW**

- 2785** Liver transplantation and alcoholic liver disease: History, controversies and considerations
Marroni CA, Fleck Jr AM, Fernandes SA, Galant LH, Mucenic M, de Mattos Meine MH, Mariante-Neto G, Brandão ABM
- 2806** Current clinical management of gastrointestinal stromal tumor
Akahoshi K, Oya M, Koga T, Shiratsuchi Y
- 2818** Biomarkers of gastric cancer: Current topics and future perspective
Matsuoka T, Yashiro M

MINIREVIEWS

- 2833** Bowel preparation quality scales for colonoscopy
Kastenberg D, Bertiger G, Brogadir S
- 2844** Current practices and future prospects for the management of gallbladder polyps: A topical review
McCain RS, Diamond A, Jones C, Coleman HG
- 2853** New horizons in the endoscopic ultrasonography-based diagnosis of pancreatic cystic lesions
Alvarez-Sánchez MV, Napoléon B

ORIGINAL ARTICLE**Basic Study**

- 2867** Total polysaccharides of the Sijunzi decoction attenuate tumor necrosis factor- α -induced damage to the barrier function of a Caco-2 cell monolayer *via* the nuclear factor- κ B-myosin light chain kinase-myosin light chain pathway
Lu Y, Li L, Zhang JW, Zhong XQ, Wei JA, Han L

Retrospective Study

- 2878** Efficacy and safety of endoscopic submucosal tunnel dissection for superficial esophageal squamous cell carcinoma and precancerous lesions
Wang J, Zhu XN, Zhu LL, Chen W, Ma YH, Gan T, Yang JL
- 2886** Impact of the number of examined lymph nodes on outcomes in patients with lymph node-negative gallbladder carcinoma
Fan DX, Xu RW, Li YC, Zhao BQ, Sun MY

Observational Study

- 2893** Upper gastrointestinal tract capsule endoscopy using a nurse-led protocol: First reported experience
Ching HL, Healy A, Thurston V, Hale MF, Sidhu R, McAlindon ME

**SYSTEMATIC REVIEWS**

- 2902** Role of band ligation for secondary prophylaxis of variceal bleeding

Aggeletopoulou I, Konstantakis C, Manolakopoulos S, Triantos C

CASE REPORT

- 2915** Gastric adenocarcinoma of fundic gland type with signet-ring cell carcinoma component: A case report and review of the literature

Kai K, Satake M, Tokunaga O

ABOUT COVER

Editorial board member of *World Journal of Gastroenterology*, Yasemin H Balaban, MD, Doctor, Professor, Department of Gastroenterology, Hacettepe University, Ankara 06100, Turkey

AIMS AND SCOPE

World Journal of Gastroenterology (*World J Gastroenterol*, *WJG*, print ISSN 1007-9327, online ISSN 2219-2840, DOI: 10.3748) is a peer-reviewed open access journal. *WJG* was established on October 1, 1995. It is published weekly on the 7th, 14th, 21st, and 28th each month. The *WJG* Editorial Board consists of 642 experts in gastroenterology and hepatology from 59 countries.

The primary task of *WJG* is to rapidly publish high-quality original articles, reviews, and commentaries in the fields of gastroenterology, hepatology, gastrointestinal endoscopy, gastrointestinal surgery, hepatobiliary surgery, gastrointestinal oncology, gastrointestinal radiation oncology, gastrointestinal imaging, gastrointestinal interventional therapy, gastrointestinal infectious diseases, gastrointestinal pharmacology, gastrointestinal pathophysiology, gastrointestinal pathology, evidence-based medicine in gastroenterology, pancreatology, gastrointestinal laboratory medicine, gastrointestinal molecular biology, gastrointestinal immunology, gastrointestinal microbiology, gastrointestinal genetics, gastrointestinal translational medicine, gastrointestinal diagnostics, and gastrointestinal therapeutics. *WJG* is dedicated to become an influential and prestigious journal in gastroenterology and hepatology, to promote the development of above disciplines, and to improve the diagnostic and therapeutic skill and expertise of clinicians.

INDEXING/ABSTRACTING

World Journal of Gastroenterology (*WJG*) is now indexed in Current Contents®/Clinical Medicine, Science Citation Index Expanded (also known as SciSearch®), Journal Citation Reports®, Index Medicus, MEDLINE, PubMed, PubMed Central and Directory of Open Access Journals. The 2018 edition of Journal Citation Reports® cites the 2017 impact factor for *WJG* as 3.300 (5-year impact factor: 3.387), ranking *WJG* as 35th among 80 journals in gastroenterology and hepatology (quartile in category Q2).

EDITORS FOR THIS ISSUE

Responsible Assistant Editor: *Xiang Li*
Responsible Electronic Editor: *Shu-Yu Yin*
Proofing Editor-in-Chief: *Lian-Sheng Ma*

Responsible Science Editor: *Xue-Jiao Wang*
Proofing Editorial Office Director: *Ze-Mao Gong*

NAME OF JOURNAL
World Journal of Gastroenterology

ISSN
ISSN 1007-9327 (print)
ISSN 2219-2840 (online)

LAUNCH DATE
October 1, 1995

FREQUENCY
Weekly

EDITORS-IN-CHIEF
Damian Garcia-Olmo, MD, PhD, Doctor, Professor, Surgeon, Department of Surgery, Universidad Autonoma de Madrid; Department of General Surgery, Fundacion Jimenez Diaz University Hospital, Madrid 28040, Spain

Stephen C Strom, PhD, Professor, Department of Laboratory Medicine, Division of Pathology, Karolinska Institutet, Stockholm 141-86, Sweden

Andrzej S Tarnawski, MD, PhD, DSc (Med), Professor of Medicine, Chief Gastroenterology, VA Long Beach Health Care System, University of California, Irvine, CA, 5901 E. Seventh Str., Long Beach,

CA 90822, United States

EDITORIAL BOARD MEMBERS
All editorial board members resources online at <http://www.wjgnet.com/1007-9327/editorialboard.htm>

EDITORIAL OFFICE
Ze-Mao Gong, Director
World Journal of Gastroenterology
Baishideng Publishing Group Inc
7901 Stoneridge Drive, Suite 501,
Pleasanton, CA 94588, USA
Telephone: +1-925-2238242
Fax: +1-925-2238243
E-mail: editorialoffice@wjgnet.com
Help Desk: <http://www.f6publishing.com/helpdesk>
<http://www.wjgnet.com>

PUBLISHER
Baishideng Publishing Group Inc
7901 Stoneridge Drive, Suite 501,
Pleasanton, CA 94588, USA
Telephone: +1-925-2238242
Fax: +1-925-2238243
E-mail: bpgoffice@wjgnet.com
Help Desk: <http://www.f6publishing.com/helpdesk>
<http://www.wjgnet.com>

PUBLICATION DATE
July 14, 2018

COPYRIGHT
© 2018 Baishideng Publishing Group Inc. Articles published by this Open-Access journal are distributed under the terms of the Creative Commons Attribution Non-commercial License, which permits use, distribution, and reproduction in any medium, provided the original work is properly cited, the use is non commercial and is otherwise in compliance with the license.

SPECIAL STATEMENT
All articles published in journals owned by the Baishideng Publishing Group (BPG) represent the views and opinions of their authors, and not the views, opinions or policies of the BPG, except where otherwise explicitly indicated.

INSTRUCTIONS TO AUTHORS
Full instructions are available online at <http://www.wjgnet.com/bpg/gerinfo/204>

ONLINE SUBMISSION
<http://www.f6publishing.com>

New horizons in the endoscopic ultrasonography-based diagnosis of pancreatic cystic lesions

María-Victoria Alvarez-Sánchez, Bertrand Napoléon

María-Victoria Alvarez-Sánchez, Instituto de Investigación Sanitaria Galicia Sur, Complejo Hospitalario Universitario de Pontevedra, Pontevedra 36003, Spain

Bertrand Napoléon, Department of Gastroenterology, Ramsay Générale de Santé Private Hospital Jean Mermoz, Lyon 69008, France

ORCID number: María-Victoria Alvarez-Sánchez (0000-0002-2640-2265); Bertrand Napoléon (0000-0001-5866-8132).

Author contributions: Alvarez-Sánchez MV and Napoléon B contributed equally to reviewing the literature, writing and drafting the article, critical revision and final approval.

Conflict-of-interest statement: María-Victoria Alvarez-Sánchez has no conflicts of interest or financial ties to disclose. Bertrand Napoléon received educational fees from Boston Scientific SA and Mauna Kea Technologies.

Open-Access: This article is an open-access article which was selected by an in-house editor and fully peer-reviewed by external reviewers. It is distributed in accordance with the Creative Commons Attribution Non Commercial (CC BY-NC 4.0) license, which permits others to distribute, remix, adapt, build upon this work non-commercially, and license their derivative works on different terms, provided the original work is properly cited and the use is non-commercial. See: <http://creativecommons.org/licenses/by-nc/4.0/>

Manuscript source: Invited manuscript

Correspondence to: María-Victoria Alvarez-Sánchez, MD, Attending Doctor, Department of Gastroenterology, Complejo Hospitalario Universitario de Pontevedra, Instituto de Investigación Sanitaria Galicia Sur (IISGS), Avenida de Mourente sn, Pontevedra 36003, Spain. victoria.alvarez.sanchez@hotmail.com
Telephone: +34-986-800907
Fax: +34-986-800309

Received: March 28, 2018

Peer-review started: March 29, 2018

First decision: April 27, 2018

Revised: May 28, 2018

Accepted: June 16, 2018

Article in press: June 16, 2018

Published online: July 14, 2018

Abstract

Pancreatic cystic lesions (PCLs) are increasingly being identified because of the widespread use of high-resolution abdominal imaging. These cysts encompass a spectrum from malignant disease to benign lesions, and therefore, accurate diagnosis is crucial to determine the best management strategy, either surgical resection or surveillance. However, the current standard of diagnosis is not accurate enough due to limitations of imaging and tissue sampling techniques, which entail the risk of unnecessary burdensome surgery for benign lesions or missed opportunities of prophylactic surgery for potentially malignant PCLs. In the last decade, endoscopic innovations based on endoscopic ultrasonography (EUS) imaging have emerged, aiming to overcome the present limitations. These new EUS-based technologies are contrast harmonic EUS, needle-based confocal endomicroscopy, through-the-needle cystoscopy and through-the needle intracystic biopsy. Here, we present a comprehensive and critical review of these emerging endoscopic tools for the diagnosis of PCLs, with a special emphasis on feasibility, safety and diagnostic performance.

Key words: Intraductal papillary mucinous neoplasm; Pancreatic cystic lesions; Endoscopic ultrasonography; Confocal endomicroscopy; Mucinous cystadenoma; Through-the-needle cystoscopy; Serous cystadenoma; Through-the-needle forceps biopsy; Contrast harmonic endoscopic ultrasonography

© The Author(s) 2018. Published by Baishideng Publishing Group Inc. All rights reserved.

Core tip: This paper provides a focused update on emerging endoscopic technologies for improving the diagnosis and prediction of the malignant potential of pancreatic cystic lesions. Basic principles, diagnostic

performance, safety and limitations are critically reviewed.

Alvarez-Sánchez MV, Napoléon B. New horizons in the endoscopic ultrasonography-based diagnosis of pancreatic cystic lesions. *World J Gastroenterol* 2018; 24(26): 2853-2866 Available from: URL: <http://www.wjgnet.com/1007-9327/full/v24/i26/2853.htm> DOI: <http://dx.doi.org/10.3748/wjg.v24.i26.2853>

INTRODUCTION

Pancreatic cystic lesions (PCLs), initially thought to be rare, have become an incidental finding increasingly identified because of technological advances and the widespread use of high-resolution abdominal imaging. It is estimated that approximately 3% and 20% of patients undergoing abdominal computed tomography (CT) and magnetic resonance imaging (MRI), respectively, present a PCL^[1-2]. Among neoplastic cysts, certain subtypes, basically mucinous cysts, entail a risk of present or future malignancy. Other neoplastic cysts, such as serous cystadenomas (SCAs), are considered benign cysts without potential of malignancy. These two types of neoplastic cysts are sometimes indistinguishable, and therefore, the awareness of possible malignant potential may lead physicians to refer these patients to surgical resection. Despite improvements in pancreatic surgery, considerable morbidity and mortality still occur in 18%-38% and 0.2%-2% of patients who undergo surgery because of PCLs^[3-6]. Accurate assessment of malignant potential is therefore of the utmost importance to avoid unnecessary surgery for benign cysts while considering appropriate surveillance for low-risk lesions and surgical treatment for malignant and high-risk cysts.

The initial step of the diagnostic approach to PCLs usually relies on radiological imaging focusing on size and morphological features. Once a PCL has been identified, most commonly by CT, an MRI is recommended due to its higher ability to evaluate nodules and to depict a communication between the cyst and the main pancreatic duct. Owing to the frequent lack of specific radiological features of many PCLs, the overall accuracy of CT and MRI remains low, ranging from 23% to 93%^[7-16]. Endoscopic ultrasonography (EUS) further characterizes PCLs and performs better than CT or MRI in assessing the morphology of small cysts and in depicting nodules in mucinous cysts, but EUS imaging alone also shows inadequate accuracy in the range of 40%-94%^[17-23]. A major advantage of EUS is the ability to safely obtain cyst fluid for biochemical and cytological analysis. However, the scant cellularity of the cyst fluid accounts for the low diagnostic yield of cytology. Although the cyst fluid carcinoembryonic antigen (CEA) level has been proven to be more accurate than cytology or EUS morphology alone, the reported sensitivity of CEA and cytology for mucinous lesions in a recent meta-analysis

do not exceed 63% and 54%, respectively^[24].

All the above limitations have led to the recent updated International, AGA and European guidelines based on predictors of malignancy, which have been shown to be far from providing reliable differentiation between the various PCLs, and recommendations provided in these guidelines are based on low-grade evidence^[25-27]. Moreover, the Fukuoka International Consensus Guideline, restricted their recommendations to branch-duct IPMNs that are diagnosed easily in a vast majority of cases (multiple cysts, communication with the main pancreatic duct)^[28]. The Fukuoka guidelines were evaluated in a prospective study yielding a high negative predictive value (NPV) of 94% for malignancy but a low positive predictive value (PPV) of approximately 38%, frequently prompting unnecessary surgery^[29]. Efforts to overcome current limitations have boosted the research in this area. Molecular analysis of DNA-based biomarkers in cyst fluid has been described with promising results^[30]. Genomics, miRNA, proteomics and metabolomics in cyst fluid seem to be promising, but validation studies are pending. In addition to molecular testing, endoscopic innovations based on EUS imaging have emerged in the last decade and they are more easily available than the omics technologies though with a longer learning curve. Although not all of these EUS-based innovations have been validated, they warrant a thorough analysis to evaluate their diagnostic performance and potential impact as a part of the diagnostic workflow of PCLs.

In this article, we aim to review the evolving role of emergent EUS-based technologies-contrast harmonic enhanced imaging, needle-based confocal endomicroscopy, through-the-needle cystoscopy, and through-the-needle intracystic biopsy-in the clinical diagnosis of PCLs, with a critical focus on feasibility, safety and diagnostic performance. Novel approaches to cystic fluid analysis, such as omics technologies and other biomarkers, are beyond of the scope of this review.

A literature search was performed for all available studies concerning the EUS diagnosis of PCLs in PubMed and Embase databases. The following search domains (including closely related words) were used: "pancreatic cysts" in combination with "contrast harmonic EUS" or "contrast enhanced EUS" or "needle confocal endomicroscopy" or "cystoscopy" or "intracystic biopsy". The search was limited to papers published in English until December 2017. Titles were then screened for suitability, and the full-text papers were retrieved. A hand-search of the references listed in the articles accessed was also performed to identify other relevant original studies. Both retrospective and prospective studies reporting data on the feasibility, diagnostic performance and safety of the above referred procedures in patients with PCLs were considered for inclusion. Indications, technical details, performance outcomes, impact on final diagnosis and management, complications and mortality were extracted and further discussed.

CONTRAST-HARMONIC ENHANCED ENDOSCOPIC ULTRASOUND

Because perfusion patterns on CT or MRI explorations allow the characterization of focal lesions, EUS has recently incorporated the use of ultrasound contrast agents (UCAs) to depict blood flow in small vessels. Available UCAs consist of microbubbles composed of an inert gas encapsulated by a shell^[31]. Gases are compressible, and when exposed to an ultrasound wave, microbubbles alternatively compress under positive pressure and expand under negative pressure, producing a backscattered acoustic signal with harmonic components^[31-32]. These harmonic components are higher than those obtained from tissue and may be selectively detected and reproduced on the ultrasound image for displaying the microvasculature pattern^[31]. Not until recently, when new UCAs, broadband EUS transducers and contrast-specific software programs became available, was contrast harmonic EUS (CH-EUS) feasible for the first time, allowing the discrimination between tissue and contrast signals. Second-generation UCAs, which contain a soluble gas, unlike air-filled first-generation agents, are commonly used for CH-EUS. They have a resistant but more flexible and longer lasting shell, making possible the use of low acoustic power (a low mechanical index) and continuous real-time assessment^[31-35].

Several steps must be followed to perform CH-EUS^[31]. After fundamental B-mode exploration of the target area, a dual screen is displayed, simultaneously showing the CH-EUS image and the conventional B-mode image. Next, optimal parameters, notably, a low MI, should be selected on the ultrasound platform. The UCA is then injected intravenously slowly through a large-gauge intravenous catheter of 16G-18G in order to avoid breaking microbubbles. Finally, the venous catheter must be flushed with saline to clear out persistent microbubbles in the vein. After intravenous injection of microbubbles, it takes 10-20 s to observe the arrival of the contrast agent. The arterial phase lasts 30-45 s, during which the enhancement increases progressively. After the arterial phase, there is a progressive washout of the contrast, and the venous phase persists from 30 s to 120 s.

Clinical outcomes: Review of the literature

Among the 71 articles retrieved from PubMed and Embase databases using the terms "pancreatic cysts" and "contrast harmonic EUS", only seven were suitable for further review^[36-42]. All of the studies but one were retrospective, and the majority was devoted to the diagnosis of mural nodules and/or malignancy in intraductal pancreatic mucinous neoplasms (IPMNs). Only three articles addressed the issue of the differential diagnosis of PCLs. Selected articles are summarized in Table 1.

Hocke *et al.*^[36] performed CH-EUS in 125 patients with PCLs. Contrast enhancement of cyst walls, septa

and nodules was observed in all PCNs, including mucinous cysts, cystic adenocarcinomas, SCAs and cystic neuroendocrine neoplasms (NENs), but in only 6% of nonneoplastic cystic lesions (PCs and dysontogenic cysts). Further supporting these results, in another study by Fusaroli *et al.*^[37], of 76 patients with PCLs, most SCAs were hyper-enhanced during CH-EUS, without a significant difference (86% vs 89%, $P = \text{NS}$), when in fact, 90% of pseudocysts showed hypoenhancement ($P = 0.000004$ vs serous cysts and $P = 0.000005$ vs mucinous cysts). In addition, Kamata *et al.*^[38] reported that CH-EUS did not add any advantage to EUS for differentiating mucinous and nonmucinous cysts when the presence of mural nodules was considered a sign of mucinous cysts (sensitivity, 79% vs 85%; specificity, 96% vs 46%; accuracy, 73% vs 84%, respectively, $P = 0.057$).

Yamashita *et al.*^[39] used CT, color Doppler EUS and CH-EUS to prospectively study 17 patients with mural nodules in branch duct type IPMN (BD-IPMN) detected by EUS before being referred for surgery. After pathological analysis, 75% of mural nodules corresponded to adenocarcinomas, and 25% corresponded to adenomas. Compared with surgical specimens, CH-EUS depicted vascularity in all pathologically confirmed nodules and in one case with mucous clots (sensitivity, 100%; specificity, 80%; PPV, 92%; NPV, 100%; and accuracy, 94%). Moreover, the sensitivity of CT and color Doppler-EUS was only 41% and 0%, respectively. Comparable results were found in later studies. Fujita *et al.*^[40] observed that CT, MRI, and EUS detected mural nodules histologically confirmed in 86%, 71% and 100% of cases. Although EUS was highly sensitive, it was not able to distinguish mucous clots from mural nodules that were correctly classified in all cases after assessing the vascular pattern by CH-EUS (Figure 1). CH-EUS was also shown to be more accurate than CT or EUS in diagnosing mural nodules in the study by Harima *et al.*^[41] (accuracy of 98%, 72% and 92%, respectively).

Fusaroli *et al.*^[37] observed that all hyper-enhanced solid components during CH-EUS turned out to be malignant, whereas nonenhanced ones were either mucous clots or internal debris. Nevertheless, other authors found it difficult to discriminate between adenomas or adenocarcinomas in BD-IPMN based on the vascular pattern. Only one study evaluated the accuracy of quantitative CH-EUS for differentiating between low-grade dysplasia (LGD) or intermediate-grade dysplasia and high-grade dysplasia (HGD) or invasive carcinoma. In this study, Yamamoto *et al.*^[42] retrospectively analyzed the time-intensity curve in 30 patients with resected IPMNs who underwent CH-EUS. The analyzed parameters were the echo intensity change and the echo intensity reduction rate of the mural nodule and the nodule/parenchyma contrast ratio. All of the parameters were significantly higher in the HGD/invasive group ($P < 0.05$), with the nodule/parenchyma contrast ratio being the most accurate parameter (accuracy, 93%). Moreover, a positive linear correlation was observed between the echo intensity change in the mural nodule and the micro-

Table 1 Contrast harmonic enhanced endoscopic ultrasound in pancreatic cystic lesions

Authors	Study	n	Main outcomes	Complications
Yamashita <i>et al</i> ^[39] , 2013	P	17	Differential diagnosis between mural nodules and mucus clots: CH-EUS: Sen 100%, Spe 80%, PPV 92%, NPV 100%, A 94% CT and Doppler-EUS: Sen 41% and 0% respectively	0
Hocke <i>et al</i> ^[36] , 2014	R	125	Differential diagnosis between non-neoplastic cysts and PCNs. Hyperenhancement: 100% PCNs Hypoenhancement: 94% non-neoplastic cysts (PCs and dysontogenic cysts) CH-EUS superior to EUS in differential diagnosis between PCNs and non-neoplastic cysts (^a <i>P</i> < 0.001)	0
Harima <i>et al</i> ^[41] , 2015	R	30	Performance for diagnosing mural nodules CT: Sen 71%, Spe 100%, PPV 100%, NPV 90%, A 92% EUS: Sen 72%, Spe 61%, PPV 50%, NPV 100%, A 72% CH-EUS: Sen 100%, Spe 97%, PPV 93%, NPV 100%, A 98%	0
Fujita <i>et al</i> ^[40] , 2016	R	50	Sensitivity for diagnosing mural nodules: CT: 86% <i>vs</i> MRI 71% <i>vs</i> EUS 100% EUS was not able to distinguish mural nodules from mucus clots CH-EUS correctly differentiated mural nodules from mucus clots in all cases	0
Fusaroli <i>et al</i> ^[37] , 2016	R	76	Differential diagnosis between non-neoplastic cysts and PCNs and between benign and malignant cysts. Hyperenhancement: 86% SCAs and 89% mucinous cysts (<i>P</i> = ns) Hypoenhancement: 90% PCs (^b <i>P</i> < 0.000004 <i>vs</i> SCAs and ^c <i>P</i> < 0.000005 <i>vs</i> mucinous cysts) Hyperenhanced solid components : 100% malignant cysts Non- hype-enhanced solid components: 100% benign cysts	0
Kamata <i>et al</i> ^[38] , 2016	R	70	Mural nodule as a sign of mucinous cyst EUS <i>vs</i> CH-EUS: Sen 85% <i>vs</i> 79%, Spe 46% <i>vs</i> 96%, A 73% <i>vs</i> 84% (<i>P</i> = 0.057) Mural nodule as a sign of malignancy EUS <i>vs</i> CH-EUS: Sen 97% <i>vs</i> 97%, Spe 40% <i>vs</i> 75%, A 64% <i>vs</i> 84% (^d <i>P</i> = 0.0001)	0
Yamamoto <i>et al</i> ^[42] , 2016	R	30	Quantitative CH-EUS in IPMNs Echo intensity change and echo intensity reduction rate, and nodule/parenchyma contrast ratio significantly higher in HGD/invasive carcinoma (^e <i>P</i> < 0.05) Microvessel density in mural nodule Significantly higher in HGD/invasive carcinoma (^f <i>P</i> < 0.002) Significant correlation between echo intensity change and microvessel density (^g <i>P</i> < 0.001)	0

P: Prospective; R: Retrospective; CT: Computed tomography; MRI: Magnetic resonance imaging; EUS: Endoscopic ultrasonography; CH-EUS: Contrast harmonic endoscopic ultrasonography; Sen: Sensitivity; Spe: Specificity; PPV: Positive predictive value; NPV: Negative predictive value; A: Accuracy; PCNs: Pancreatic cystic neoplasms; IPMN: Intraductal papillary mucinous neoplasm; HGD: High grade dysplasia.

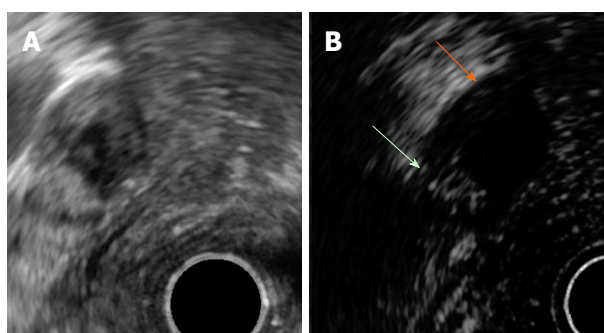


Figure 1 Mural nodule and mucus in branch duct type intraductal pancreatic mucinous neoplasms. A: EUS B mode image. B: Contrast harmonic EUS image. Microbubbles in a mural nodule (green arrow). No bubbles in a mucus clot (orange arrow). EUS: Endoscopic ultrasonography.

vessel density in pathologic specimens ($r = 0.803$, $P < 0.001$).

No mortality or CH-EUS-related adverse events were reported in any study.

NEEDLE-BASED CONFOCAL LASER ENDOMICROSCOPY

Needle-based confocal laser endomicroscopy (nCLE) is an emergent endoscopic modality that enables imaging

of a target tissue at a subcellular level of resolution, providing real-time *in vivo* optical biopsy. For CLE imaging, a low-power laser is used to illuminate the tissue. The laser beam is focused on a plane of interest, and the reflected light from the tissue is filtered and transformed into an electrical signal by a detection system and finally translated into grayscale images by a computer system^[43,44]. The final result consists of images with very high spatial resolution and magnification of the focal plane examined within the tissue. Because confocal imaging relies on reflected fluorescent light, intravenous injection of a fluorescent dye, most commonly sodium fluorescein, is required. Fluorescein acts as a contrast agent highlighting blood vessels and tissue architecture^[43-46].

Recent advances have allowed the incorporation of CLE technology into a miniprobe of 0.85 mm (AQ-Flex) that can be passed through a 19-gauge (19G) EUS needle. This probe is provided with 10,000 optical fibers and has a field of view of 325 μm , 3.5 μm of lateral resolution and 40-70 μm of confocal depth^[46].

Before starting the procedure, a 19G EUS needle is preloaded with the AQ-Flex probe that should be inserted until 2 mm of the probe is positioned beyond the needle tip (Figure 2). At this moment, the probe is fixed to the inlet of the needle channel by a locking system. After identifying the cyst, a single pass with the preloaded 19G

Table 2 Needle-based confocal laser endomicroscopy in pancreatic cystic lesions

Authors	Study	n	Main outcomes	Complications
Konda <i>et al</i> ^[48] , 2011	P	16	94% Technical success (feasibility study)	12% post-procedure pancreatitis
Konda <i>et al</i> ^[49] , 2013	P	66	Stage 1: Description of visualized structures (<i>n</i> = 26) with histological correlation Stage 2: Performance assessment of defined criteria (<i>n</i> = 31): Villous pattern: Sen 59%, Spe 100%, PPV 100%, NPV 50%, A 71% for PCNs Significant association with PCNs (^a <i>P</i> = 0.004)	3% post-procedure pancreatitis 4.5% intracystic self-limited bleeding
Nakai <i>et al</i> ^[50] , 2015	P	30	Villous pattern in 18 patients with highly certain diagnosis: Sen 80%, Spe 100%, PPV 100%, NPV 80%, A 89% for mucinous cysts Significant association with mucinous cysts (^b <i>P</i> = 0.001)	7% post-procedure (cystoscopy followed by nCLE) pancreatitis
Napoléon <i>et al</i> ^[51] , 2015	P	31	Superficial vascular network: Sen 69%, Spe 100%, PPV 100%, NPV 82%, A 87% for SCAs	3% post-procedure pancreatitis
Napoléon <i>et al</i> ^[52] , 2016	R	31	Step 1: Description of nCLE patterns for mucinous cysts, PCs and cystic NENs with histological correlation Step 2: Retrospective external validation of nCLE criteria Accuracy 94% for mucinous cysts (90% IPMN - 90% MCA) - 87% SCA - 87% PCs Substantial global IOA: Perfect PC, almost perfect SCA, moderate IPMN, fair MCA	
Kadayifci <i>et al</i> ^[53] , 2017	P	20	nCLE performance for mucinous cysts: Sen 66% -Spe 100% -A 80%	0 complications
Krishna <i>et al</i> ^[54] , 2017	P	10	Reproducibility of the <i>in vivo</i> nCLE criteria in <i>ex vivo</i> specimens	
Napoléon <i>et al</i> ^[55] , in press	P	209	Diagnostic yield 91% in 78 patients with non-communicating cysts and pathological diagnosis: Sen 95%, Spe 100% - PPV 100% - NPV 98% - A 99% for SCAs Sen 95%, Spe 100% - PPV 100% - NPV 94% - A 97% for mucinous cysts Sen 100%, Spe 95% - PPV 70% - NPV 100% - A 96% for NENs Sen 96%, Spe 95% - PPV 98% - NPV 91% - A 96% for premalignant cysts	1.3% post-procedure pancreatitis
Karia <i>et al</i> ^[56] , 2016	R	15	IOA poor to fair for all nCLE variables	
Krishna <i>et al</i> ^[57] , 2016	R	49	nCLE performance on 26 patients with definitive diagnosis (23 with pathological diagnosis): Sen 94%, Spe 82% - PPV 88% - NPV 92% - A 89% for mucinous cysts IOA and IOR: Substantial for all nCLE criteria	6.1% post-procedure pancreatitis
Krishna <i>et al</i> ^[58] , 2017	R	29	nCLE performance on 29 patients with definitive diagnosis (23 with pathological diagnosis): Sen 95%, Spe 94% - A 95% for mucinous cysts Sen 99%, Spe 98% - A 98% for SCAs Sen 99%, Spe 98% - A 98% for NENs IOA and IOR: Almost perfect for mucinous cysts and SCAs	

P: Prospective; R: Retrospective; Sen: Sensitivity; Spe: Specificity; PPV: Positive predictive value; NPV: Negative predictive value; A: Accuracy; PCNs: Pancreatic cystic neoplasms; PC: Pseudocyst; MCA: Mucinous cystadenoma; SCA: Serous cystadenoma; IPMN: Intraductal papillary mucinous neoplasm; NENs: Neuroendocrine neoplasm; IOA: Interobserver agreement; IOR: Intraobserver reliability.

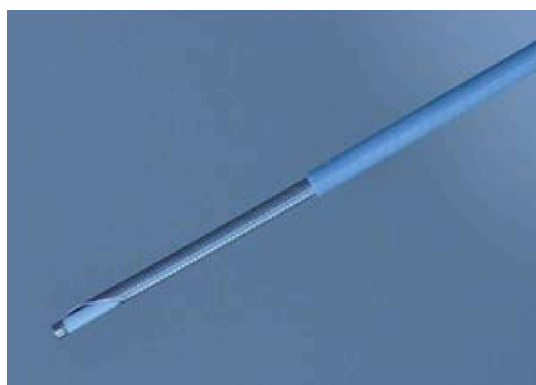

Figure 2 Needle-based confocal laser endomicroscopy probe in a 19G needle.

EUS needle is performed, and the needle is advanced under EUS guidance until the needle tip contacts the cyst wall. Immediately after, 2.5-5 mL of 10% fluorescein

is injected; nCLE imaging begins, during which gentle apposition of the probe to the cyst wall is pursued. The elevator, endoscope dials and torquing are useful for imaging in a fanning technique^[43]. Because images are obtained at a rate of 12 frames/s, video-recording is always performed for 2-5 min and further reviewed with a dedicated software program. At the end of the procedure, the probe is withdrawn, and the cyst fluid is aspirated as per standard practice. Antibiotic prophylaxis is systematically administered^[47].

Clinical outcomes: Review of the literature

A literature search in PubMed and Embase databases identified 24 articles reporting on nCLE in PCLs. Only 11 of these articles were deemed eligible and consisted of 7 prospective and 4 retrospective studies (Table 2)^[48-58]. Most of them were focused on feasibility, safety and performance in differentiating mucinous from nonmucinous cysts or in the differential diagnosis among the

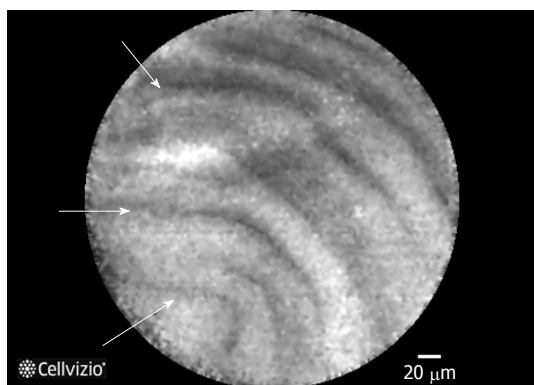


Figure 3 Needle-based confocal laser endomicroscopy image of an intraductal pancreatic mucinous neoplasms displaying multiple papillary projections.

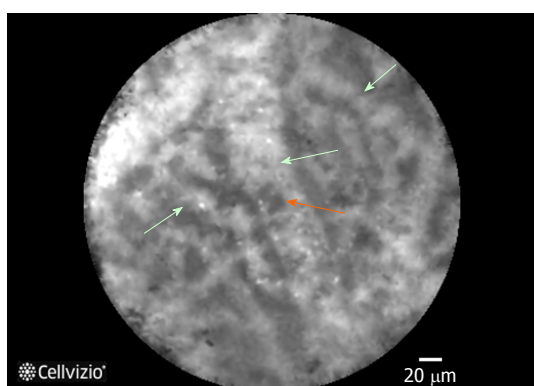


Figure 4 Needle-based confocal laser endomicroscopy image of the superficial vascular network pattern of a serous cystadenoma. Multiple interconnected vessels (green arrows). Red cells inside displayed as black structures (orange arrow).

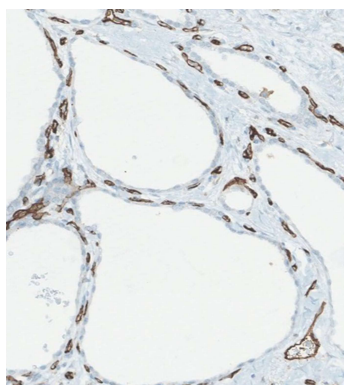


Figure 5 Staining with a vascular marker of serous cystadenomas histological specimen. Capillary necklace with subepithelial vessels showed in brown.

several types of PCLs. Three studies aimed to externally validate the nCLE criteria, and one study performed an *ex vivo* validation of the *in vivo* nCLE criteria.

The first series was reported in 2011 by Konda *et al.*^[48] and was a feasibility study of 16 cysts and 2 solid masses of the pancreas. The nCLE procedure was feasible in 15 of 16 cysts, although the technical challenges described

in 6 of them were related to the transduodenal approach, the post loading technique (the insertion of the CLE probe after positioning the EUS needle inside the lesion) and the longer length of the metallic tip at the distal end of the probe. Complications occurred in two patients, both of whom developed pancreatitis requiring hospitalization. This study was followed by a larger multicenter study (*in vivo* nCLE Study in the Pancreas with Endosonography of Cystic Tumors, INSPECT) that was reported by the same group and that aimed to evaluate the diagnostic potential and safety of nCLE in the differential diagnosis of PCLs in 66 patients^[49]. A consensus description of visualized structures on 26 patients was achieved, and the correlation between histology and nCLE was investigated during the first stage of the study. Then, the performance of nCLE criteria to identify PCNs, including mucinous cystadenoma (MCA), IPMN or adenocarcinoma, was assessed in 31 additional patients. The presence of villous structures was highly specific (100%) but provided low sensitivity, at 59%, and it was the only specific finding having a significant association with PCNs ($P = 0.004$). Post procedure pancreatitis occurred in 3% of cases: one patient experienced transient abdominal pain, and three cases of intracystic bleeding were observed and spontaneously solved.

The DETECT trial (Diagnosis of Pancreatic Cysts: Endoscopic Ultrasound, Through-the-Needle Confocal Laser Endomicroscopy and Cystoscopy Trial) was designed to evaluate the diagnostic yield of cystoscopy followed by nCLE in 30 patients^[50]. A highly certain diagnosis was possible in 18 of these patients based on the clinical presentation, other image findings, fluid analysis and cytology. In these patients, a papillary projection (Figure 3) and/or a dark ring on nCLE, corresponding to the villous pattern previously reported by Konda, was associated with mucinous cysts ($P = 0.001$) with 80% sensitivity, 100% specificity, 100% PPV, 80% NPV and 89% accuracy. Two patients (7%) developed post procedure pancreatitis.

After the above initial experiences, Napoléon and colleagues described new nCLE criteria based on histological correlation in two consecutive studies^[51-52]. In the first one, a criterion for *in vivo* diagnosis of SCA was defined and consensually identified as a superficial vascular network (Figure 4). The presence of small and regular structures circulating inside the opacified channels during nCLE suggested the vascular nature of these channels, which was confirmed by histological assessment of surgical specimens (Figure 5). This vascular network was demonstrated to be at a superficial depth of 50-70 μm and, therefore, at the reach of the nCLE probe. Moreover, SCA was the only PCL that featured this pattern among 31 patients with PCLs of unknown diagnosis. The sensitivity, specificity, PPV, NPV and accuracy of this criterion for diagnosing SCA were 69%, 100%, 100%, 82% and 87%, respectively. Only one patient suffered mild acute pancreatitis (3%). In a second study (CONTACT 1), the same authors identified three other nCLE criteria that included a thick gray line

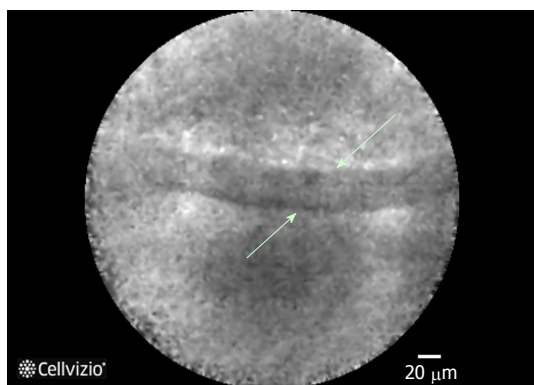


Figure 6 Epithelial border image in a mucinous cystadenoma at needle-based confocal laser endomicroscopy.




Figure 7 Heterogeneous sized grey and white particles in a pseudocyst at needle-based confocal laser endomicroscopy.

for mucinous neoplasms (Figure 6), a field of bright particles for PCs (Figure 7) and black neoplastic clusters with white fibrous areas for NENs. In this case, the histological correlation was the epithelial border, a mix of inflammatory cells and neoplastic cell proliferation with several forms of architectural organization respectively. In the retrospective validation, four external and blinded reviewers evaluated the diagnostic performance of these criteria. A conclusive diagnosis was achieved in 23 of 31 patients (74%). Overall, the accuracy of nCLE criteria was 94% for mucinous cysts, 87% for SCA and 87% for PC. Trends toward high specificity were also shown (> 90% for mucinous cysts and 100% for nonmucinous cysts). NENs were excluded from the external validation due to the small number in this series ($n = 2$). More recently, Krishna *et al*^[54] have further confirmed the reproducibility of the *in vivo* nCLE criteria in *ex vivo* specimens of 10 patients with surgically resected PCLs.

To overcome the limitations of the reduced number of patients and the lack of pathological confirmation in previous series, Napoléon *et al*^[55] designed a larger multicenter and prospective study (CONTACT 2) whose results are now available (submitted). Among 209 enrolled patients with a noncommunicating solitary cyst, 78 patients with a final diagnosis proven by surgical histopathology or cytopathological analysis of cyst fluid by EUS fine needle aspiration (EUS-FNA) were included

in the final results. The overall diagnostic yield of nCLE was 91%, and the sensitivity and specificity for the main types of PCLs were higher than 95%. Perfect specificity (100%) was observed for diagnosing SCA and premalignant mucinous cysts. Furthermore, the nCLE area under the curve was significantly higher than that of CEA dosage for differentiating mucinous from nonmucinous cysts ($P < 0.01$) and higher than that of EUS morphology in differentiating between premalignant and benign PCLs ($P < 0.05$). However, nCLE criteria were not highly specific for NENs and PCs. NEN criteria were also observed in one cystic solid pseudopapillary neoplasia (CSPPN), one cystic lymphoma and 1 PC. Additionally, one mucinous lesion and one SCA exhibited PC criteria. Acute pancreatitis occurred only in 1.3% of patients. Although the impact of nCLE on patient management was not evaluated, it is noteworthy that in 29% of patients with a previous inconclusive EUS-FNA, nCLE was conclusive in 91% of cases and 100% accurate.

The first reports on interobserver agreement (IOA) yielded diverging results^[51,56]. In the first one (CONTACT 1), four external reviewers assessed the IOA of the nCLE criteria in 31 cases^[51]. The diagnostic accuracy for mucinous cysts was 94%, and the global IOA was rated as substantial ($k = 0.72$, 95%CI: 0.52-0.87). A later validation study reported low diagnostic accuracy for the type of PCL (46%), with an IOA ranging from poor to fair for all nCLE variables^[56]. However, careful interpretation of these results is advised due to limitations such as poor image quality and short duration of video capture, which may have accounted for the poor results, and other methodological issues such as the lack of intraobserver reliability and few patients with a histological gold-standard diagnosis. More recently, two other studies aimed to validate nCLE criteria. One investigation consisted of a retrospective analysis at a single center^[57,58]. nCLE videos from 26 patients (23 with pathological diagnosis) were reviewed by 6 blinded nCLE-naïve observers^[57]. Substantial IOA and IOR were achieved for differentiating mucinous from nonmucinous cysts ($k = 0.67$, 95%CI: 0.57-0.77 and $k = 0.78 \pm 0.13$, respectively) and for detecting all nCLE criteria. These results were further corroborated by an international external interobserver and intraobserver study^[58]. In 29 patients, the overall accuracy of nCLE for the diagnosis of mucinous cysts was 95%, with an almost perfect IOA and IOR among six expert endosonographers with nCLE experience ($k = 0.81$, 95%CI: 0.71-0.90 and $k = 0.86 \pm 0.11$, respectively). Furthermore, nCLE was 98% accurate in diagnosing SCA and the IOA and IOR for recognizing the fern pattern (previously defined as superficial vascular network) were also almost perfect ($k = 0.83$, 95%CI: 0.73-0.92 and $k = 0.85 \pm 0.11$, respectively).

THROUGH-THE-NEEDLE CYSTOSCOPY

Through-the-needle cystoscopy is a procedure that allows



Figure 8 Moray forceps.

direct assessment of the cyst content as well as the inner cyst wall by means of single-operator cholangioscopy fiberoptic probe (Spyglass®, Boston Scientific, Natick, Mass, United States). The probe has 6000-pixel optic bundles, a 300 cm working length and a diameter of 0.77 mm. It provides a 70-degree field of view and has a 2-7 mm focal length^[43,50]. The cystic cavity is accessed under EUS guidance with a 19G EUS needle. Before starting the procedure, the needle stylet is removed, and the fiberoptic probe is preloaded through the 19G needle and prefitted with the advancement of the probe 2 mm beyond the needle tip. Then, the probe is withdrawn 2-3 mm inside the needle, and once inside the cyst, the probe is advanced again to the prefitted position. Prophylactic antibiotics are always given, and cystoscopy images may be recorded for further review^[50].

Clinical outcomes: Review of the literature

Of the 8 references retrieved, only 3 suitable articles were identified^[50,59-60]. The first one reported on two patients who underwent through-the-needle cystoscopy followed by biliary forceps biopsy^[59]. In both cases, it was possible to rule out a pseudocyst because a flat normal mucosa was visualized lining the inner cyst wall. In addition, cystoscopy enabled a better delineation of mural nodules and targeted biopsies of the selected suspicious areas. Severe acute pancreatitis occurred in one patient one month after the procedure. It is not possible to rule out a delayed procedure-related complication, although very unlikely.

In the prospective DETECT study, Nakai *et al.*^[50] performed through-the needle-cystoscopy followed by nCLE in 30 patients. The cyst content was evaluated for clarity, the presence of mucin or debris, and the smoothness, nodularity and vascularity of the cyst walls were assessed. The median image time of cystoscopy was 4 min, and 33% of the images were rated as fair or poor. The mucinous content was described as viscous and cloudy fluid. Typical findings and their clinical correlations were finger-like projections and a mucin cloud in IPMNs, smooth cyst walls with cloudy fluid in MCNs, and smooth cyst walls with prominent regular vessels in SCAs. However, the only significant association in 18 high-certainty diagnoses was observed between mucin on cystoscopy and mucinous cysts ($P = 0.0004$), with 90% sensitivity, 100% specificity, 100% PPV, 100% NPV and 94% accuracy. However, finger-like projections were identified in only two of the ten high-certainty mucinous lesions. When cystoscopy and nCLE were combined, the sensitivity increased from 90% to 100%. Post procedure pancreatitis was reported twice.

In a retrospective study published last year, Chai *et al.*^[60] performed through-the-needle cystoscopy in 43 patients. Based on the blood vessel distribution, the presence of partitions or ridge-like structures and the presence of papilla-like structures, the characteristic findings of different PCLs were defined and then validated by surgical pathology, FNA or fluid cytology. The authors concluded that a tree-like branching pattern of blood vessels may suggest the diagnosis of SCA (specificity, 91%; sensitivity, 69%) and that intracystic papilla-like structures may be characteristic of mucinous cysts (specificity, 92%; sensitivity, 22%). No pancreatitis was observed, and only two patients presented mild abdominal post procedure pain.

THROUGH-THE-NEEDLE FORCEPS BIOPSY

The low sensitivity of EUS-FNA cytology because of relatively acellular samples makes appealing the possibility to obtain biopsies. The design of minibiopsy forceps has led to the development of a new EUS-FNA tissue acquisition technique. Moray® micro forceps (US Endoscopy, Ohio, United States) were designed for use in EUS procedures to enhance sampling from lesions that can occur within and outside the gastrointestinal tract, leading to a more definitive diagnosis (Figure 8). These forceps are 230 cm in length and have serrated jaws (jaw opening of 4.3 mm) and a spring sheath 0.8 mm in diameter, allowing use through a 19G EUS needle^[43,61].

Clinical outcomes: Review of the literature

No formal study was retrieved after searching PubMed and Embase for "pancreatic cyst" and "intracystic biopsy". Only two pilot studies reporting on 2 cases each and four additional case reports were identified^[59,61-65].

Through-the-needle intracystic biopsy was first described by Aparicio *et al.*^[59] in two patients. They used 0.8 mm endoscopic retrograde cholangiopancreatography biopsy forces followed by a 3-4 min observation with a fiberoptic probe to rule out immediate bleeding. In both cases, a mucinous-like cylindric epithelium without cellular atypia was observed. As stated above, one patient presented severe acute pancreatitis one month later. After this preliminary experience, six more cases were reported to undergo intracystic biopsy, enabling the correct diagnosis of 5 mucinous cysts (one of them with mild dysplasia) and one benign lymphoepithelial cyst without any complication^[61-65].

DISCUSSION

PCLs remain a diagnostic and therapeutic challenge to clinicians. Several issues remain to be solved, notably, how to improve diagnosis and better predict malignant behavior. It has been reported that 36% of SCAs are treated with unnecessary surgery because of an uncertain diagnosis^[66]. In the attempt to cover this need,

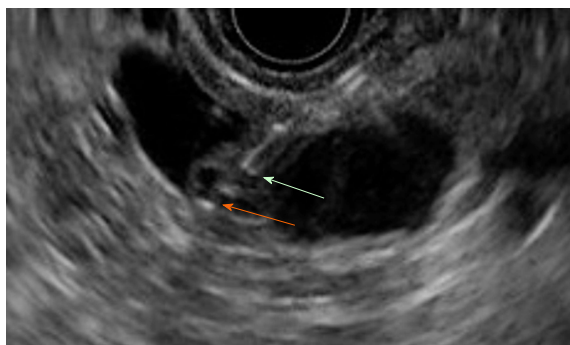


Figure 9 Moray forceps inside a cyst. Green arrow: The tip of the 19G needle. Orange arrow: The tip of the Moray forceps grasping the cyst wall.

several EUS-based tools have emerged recently and some experience is now available using these technologies in the diagnosis of PCLs.

On the grounds that CH-EUS has been proved to be accurate for the differential diagnosis of solid pancreatic masses, it was hypothesized that CH-EUS might also be helpful in PCLs, and some experience has been reported in the last five years^[67-70]. Due to its high spatial resolution, CH-EUS may define the inner structure of cysts by depicting small septa or mural nodules that become echogenic during CH-EUS, whereas the intracystic content remains invisible (Figure 9). This modality may assist not only in the differential diagnosis but also in identifying malignancy risk features.

Current evidence suggests that CH-EUS is highly accurate for distinguishing nonneoplastic cysts (PCs and dysontogenic cysts) from neoplastic cysts because the former do not exhibit cystic wall vascularization. This feature prevents pointless and onerous surgery in this benign setting. However, a different scenario is observed among different neoplastic cysts whose biological behavior may be significantly different and where misinterpretations are common in CH-EUS. Benign SCAs, the most common nonmucinous cystic neoplasms, and potentially malignant mucinous cysts show undistinctive features on CH-EUS. Consequently CH-EUS cannot be used for the differential diagnosis of neoplastic cysts.

The presence of mural nodules is considered in the international consensus guidelines on IPMN management as a high-risk stigma and strongly supports surgical resection. Mural nodules may sometimes be too small for detection by CT or MRI. The high spatial resolution of EUS enables better identification in these cases. However, the performance of EUS is not enough to discriminate between mural nodules or mucous clots. Hyperenhancement of solid components during CH-EUS may differentiate mural nodules from mucous clots or debris. This step is essential to avoid unnecessary surgery and is included in the last guidelines^[25]. Nodules in BD-IPMNs include not only malignant nodules but also benign adenomas that might be followed without surgery, but the preoperative differentiation between them does not seem possible with qualitative CH-EUS. Angiogenesis plays a key role in tumor growth and progression; in

fact, neovascularization was reported to be crucial in the tumorigenesis of invasive IPMNs with a progressive increase in microvessel density from benign to malignant tissue^[71]. According to this observation, preliminary experience with quantitative CH-EUS suggests that the analysis of echo intensity changes during CH-EUS may be an accurate method to discriminate between low/intermediate-grade dysplasia and high-grade dysplasia/invasive carcinoma. Further trials are necessary to confirm this interest.

When it comes to safety, CH-EUS exhibits an excellent safety profile with no adverse events in series reporting on PCLs. UCAs are the sole factor adding risk to conventional EUS. Concerns were raised after a study reporting on UCAs used for stress echocardiography, where 4 deaths and 190 serious adverse events were observed and associated with the use of UCAs^[72]. Consequently, the Food and Drug Administration issued a black box warning regarding the use of UCAs in several pathologic cardiorespiratory states. Later experience in large cohorts of patients has shown that the rate of UCA-related serious adverse events is lower than 0.01%, with anaphylactoid reactions occurring in 1/10.000 cases^[73-74].

More recent evidence confirms that nCLE is feasible during EUS-FNA and allows *in vivo* diagnosis of PCLs with high accuracy; nCLE criteria have been defined for IPMN, MCA, SCA, PC and cystic NEN with a proven histopathological correlation. Unlike CH-EUS, a perfect specificity of 100% has been confirmed with nCLE for benign SCA and for mucinous lesions. The superficial vascular network is exclusive to SCAs, allowing SCA diagnosis with high confidence, therefore preventing unnecessary surgical resection. Sensitivity of this pattern, although high, is not perfect, and epithelium denudation may account for the lack of a vascular pattern in oligocystic SCA. Specificity is also perfect for the overall group of mucinous lesions, but when they are further classified as either IPMN or MCA, the specific findings of papillae or epithelial borders, respectively, may both be present. Other times, papillae or epithelial borders cannot be visualized, and the explanation is the nonuniform distribution of papillae throughout the epithelium of IPMNs or modifications induced by inflammation in some MCAs. These inflammatory changes are also the reason why a field of bright, gray and black particles is not specific for PCs and may be found in other cystic tumors following infection or bleeding. Finally, the presence of dark spots of cell aggregates surrounded by gray areas of fibrosis and vessels, initially attributed to NENs, is not specific and may be present in other premalignant lesions, such as CSPPNs. However, due to the similar premalignant nature, the impact on clinical management of misdiagnosis between NENs and CSPPNs or between IPMNs and MCAs is of little importance.

The major concern related to nCLE is the risk of acute pancreatitis, which has ranged from 1.3% in the largest and most recent study to 12% in the first feasibility study. The use of Spyglass® (Boston Scientific, Natick, Mass, United States) for cystoscopy may also explain

the second highest rate of pancreatitis in the DETECT study^[50]. The average rate from the rest of the studies is 2.7%, which is comparable with that of the conventional EUS-FNA procedure^[75]. Only one series reported intracystic bleeding in 3 patients (4.5%); however, no intervention was required, and they were solved spontaneously. Several factors that add to the risk of complications have been suggested, such as needle size, duration of the procedure and abrasion of the cyst lining with the needle tip. Some tips have been suggested during nCLE to maximize the procedure safety. The interposition of the main pancreatic duct should be avoided when selecting the puncture site to lower the risk of acute pancreatitis. Once inside the cyst, limited brushing of the cyst wall is recommended to avoid cystic bleeding and pancreatitis; instead, it is preferred to perform consecutive apposition between the probe and the cyst wall. Finally, the exploration should be stopped as soon as nCLE criteria are met, or after 6 min if no specific criteria are found, to minimize the risk of adverse events^[43]. No study reported adverse events related to the injection of fluorescein, but severe allergic reactions are possible, although very uncommon (1/222000)^[76]. Minor side effects, such as nausea, vomiting, mild epigastric pain, transient hypotension, injection site erythema or diffuse rash, have been reported in 1.4% of cases^[77]. The learning curve for nCLE seems to have an important effect on the pancreatitis rate since one study reported three acute-pancreatitis cases among the first 25 patients and none in the successive 34 patients^[58]. Technical challenges reported in initial feasibility studies are now overcome, and several tips have been suggested to avoid them (preloading of the nCLE probe, use of the most flexible needle). However, other limitations remain to be solved. The most important one is the limited surface of the cystic wall that is accessible to be scanned. Exploration is feasible over the area in front of the needle tip but less than 50% of the cystic surface is likely to be visualized. The second argued limitation is the high cost of the probe, which is considered a limiting step to implementing nCLE technology in routine practice. Nevertheless, a health economic evaluation carried out in France demonstrated that nCLE resulted in a reduction of 23% of surgical interventions^[78]. This finding translated into a reduction in clinical costs of 13% in the public sector and 14% in the private sector. The improved diagnostic accuracy of nCLE reduces the number of false positives and false negatives, avoiding unnecessary surgical interventions and lifelong surveillance for benign cysts.

The heterogeneous distribution of neoplastic tissue in PCLs makes it reasonable to attempt to directly explore the inner cyst walls. Limited experience with through-the-needle cystoscopy has demonstrated the feasibility for direct visualization of cyst walls and has suggested that it may help to target biopsies to suspicious areas. Patterns at cystoscopy have been proposed for SCAs, MCNs and IPMNs but have not been validated yet. Like for nCLE, the main complication is

acute pancreatitis, and therefore, limiting the time inside the cyst is strongly recommended. The greatest interest seems to be the ability to detect mucin clots that have a typical appearance on cystoscopy. Nevertheless, the performance of cystoscopy was not higher than the string test that is more simple and free of cost^[50]. Beside the cost of the fiberoptic system, other limitations of cystoscopy in reported studies are mainly related to the suboptimal quality of images. Therefore, the real place of cystoscopy need to be established.

Through-the-needle intracystic biopsy has been suggested to be a feasible technique for tissue acquisition in one series and several case reports. It allows histological diagnosis including the grade of dysplasia, although the retrieved samples are small. However, the processing of the samples is not always easy. Because of the small-sized specimens, they sometimes disintegrate during fixation in formalin. In addition, lesions such as mural nodules may not be targetable by the stiff 19G EUS-FNA, especially those located in the uncinate process. Finally, concerns remain about the risk of bleeding following through-the-needle forceps biopsy, similarly to brush cytology, even if no cases of bleeding have been reported. Formal studies in larger series are required to validate the results of this new technique and to confirm its safety.

In summary, CH-EUS seems to be a safe and complementary tool to EUS-FNA for the assessment of PCLs. CH-EUS is especially accurate in differentiating nonneoplastic cysts from PCNs and mural nodules from mucus clots. Moreover, the recent International Association of Pancreatology and the European guidelines have recommended CH-EUS for further evaluation of mural nodules in IPMN and PCN respectively. Larger and prospective studies are required to confirm the role of quantitative CH-EUS in the differential diagnosis between malignant and benign mucinous neoplasms. EUS nCLE is a minimally invasive tool with remarkable potential for diagnosing PCLs. Future research should also address new nCLE criteria associated with the grade of dysplasia or cancer, the additional clinical value of combining nCLE with the current standard of PCLs diagnosis and the cost-effectiveness of nCLE during the initial EUS-FNA or after inconclusive results of EUS-FNA. Meanwhile, and based on available evidence at present, excluding cost-effectiveness, we propose an algorithm of diagnosis for PCLs (Figure 10). Through-the-needle cystoscopy and biopsy must be evaluated in formal studies in larger series to validate their results and to confirm their safety before integrating them in the diagnostic flowchart of PCLs.

CONCLUSION

PCLs are increasingly identified on imaging, but their characterization remains challenging due to limitations of the current endoscopic and imaging techniques. In this article, we presented a comprehensive review about emerging endoscopic tools for the diagnosis of PCLs.

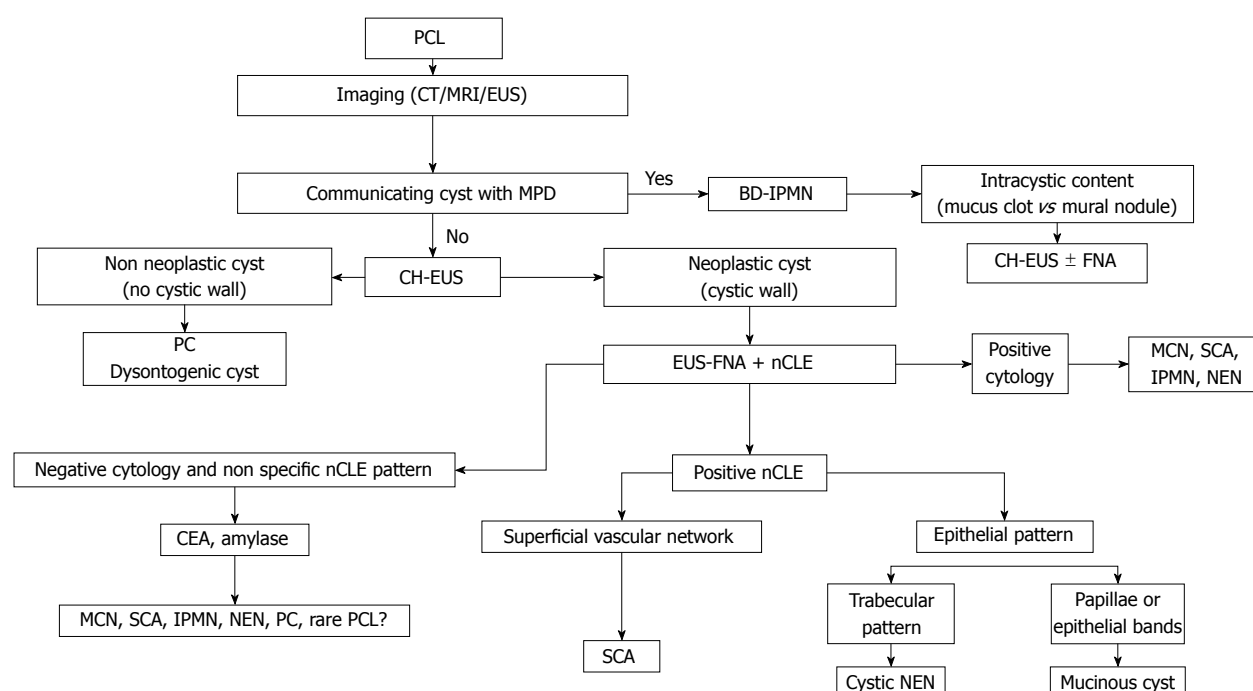


Figure 10 Diagnostic algorithm integrating new endoscopic ultrasonography-based technologies. PCL: Pancreatic cystic lesion; PC: Pseudocyst; MPD: Main pancreatic duct; BD-IPMN: Branch duct intraductal pancreatic mucinous neoplasm; MCN: Mucinous cystic neoplasm; SCA: Serous cystadenoma; NEN: Neuroendocrine tumour; CT: Computed tomography; MRI: Magnetic resonance imaging; EUS: Endoscopic ultrasonography; CH-EUS: Contrast harmonic enhanced EUS; EUS-FNA: EUS guided fine needle aspiration; nCLE: Needle-based confocal endomicroscopy.

Among them, through-the-needle cystoscopy and biopsy still have the lowest amounts of available evidence, with the most extensive experience reported for CH-EUS and nCLE. Both modalities have been demonstrated to provide valuable information for the decision-making process and to be supplementary techniques to EUS-FNA. Limitations for their widespread implementation are their elevated cost and learning curve. Future studies should address their clinical impact on patient management, the optimal timing for their application in the diagnostic work flow of PCLs and their cost-effectiveness. Through-the-needle cystoscopy and intracystic biopsy must be further evaluated in formal and larger trials. Moreover, because a combination of these new techniques may further improve our ability to diagnose PCLs, multi-arm trials incorporating these new technologies and emergent molecular markers would be of most value to determine the best diagnostic approach.

REFERENCES

- Laffan TA, Horton KM, Klein AP, Berlanstein B, Siegelman SS, Kawamoto S, Johnson PT, Fishman EK, Hruban RH. Prevalence of unsuspected pancreatic cysts on MDCT. *AJR Am J Roentgenol* 2008; **191**: 802-807 [PMID: 18716113 DOI: 10.2214/AJR.07.3340]
- Lee KS, Sekhar A, Rofsky NM, Pedrosa I. Prevalence of incidental pancreatic cysts in the adult population on MR imaging. *Am J Gastroenterol* 2010; **105**: 2079-2084 [PMID: 20354507 DOI: 10.1038/ajg.2010.122]
- Ferrone CR, Correa-Gallego C, Warshaw AL, Brugge WR, Forcione DG, Thayer SP, Fernández-del Castillo C. Current trends in pancreatic cystic neoplasms. *Arch Surg* 2009; **144**: 448-454 [PMID: 19451487 DOI: 10.1001/archsurg.2009.36]
- Valsangkar NP, Morales-Oyarvide V, Thayer SP, Ferrone CR, Wargo JA, Warshaw AL, Fernández-del Castillo C. 851 resected cystic tumors of the pancreas: a 33-year experience at the Massachusetts General Hospital. *Surgery* 2012; **152**: S4-S12 [PMID: 22770958 DOI: 10.1016/j.surg.2012.05.033]
- Salvia R, Fernández-del Castillo C, Bassi C, Thayer SP, Falconi M, Mantovani W, Pederzoli P, Warshaw AL. Main-duct intraductal papillary mucinous neoplasms of the pancreas: clinical predictors of malignancy and long-term survival following resection. *Ann Surg* 2004; **239**: 678-685; discussion 685-687 [PMID: 15082972 DOI: 10.1097/01.sla.0000124386.54496.15]
- Sohn TA, Yeo CJ, Cameron JL, Hruban RH, Fukushima N, Campbell KA, Lillemoe KD. Intraductal papillary mucinous neoplasms of the pancreas: an updated experience. *Ann Surg* 2004; **239**: 788-797; discussion 797-799 [PMID: 15166958 DOI: 10.1097/01.sla.0000128306.90650.a]
- Procacci C, Biasiutti C, Carbognin G, Accordini S, Bicego E, Guarise A, Spoto E, Andreis IA, De Marco R, Megibow AJ. Characterization of cystic tumors of the pancreas: CT accuracy. *J Comput Assist Tomogr* 1999; **23**: 906-912 [PMID: 10589565 DOI: 10.1097/00004728-199911000-00014]
- Curry CA, Eng J, Horton KM, Urban B, Siegelman S, Kuszyk BS, Fishman EK. CT of primary cystic pancreatic neoplasms: can CT be used for patient triage and treatment? *AJR Am J Roentgenol* 2000; **175**: 99-103 [PMID: 10882255 DOI: 10.2214/ajr.175.1.1750099]
- Visser BC, Yeh BM, Qayyum A, Way LW, McCulloch CE, Coakley FV. Characterization of cystic pancreatic masses: relative accuracy of CT and MRI. *AJR Am J Roentgenol* 2007; **189**: 648-656 [PMID: 17715113 DOI: 10.2214/AJR.07.2365]
- Chaudhari VV, Raman SS, Vuong NL, Zimmerman P, Farrell J, Reber H, Sayre J, Lu DS. Pancreatic cystic lesions: discrimination accuracy based on clinical data and high resolution CT features. *J Comput Assist Tomogr* 2007; **31**: 860-867 [PMID: 18043347 DOI: 10.1097/RCT.0b013e318039b277]
- Lu X, Zhang S, Ma C, Peng C, Lv Y, Zou X. The diagnostic value of EUS in pancreatic cystic neoplasms compared with CT and MRI. *Endosc Ultrasound* 2015; **4**: 324-329 [PMID: 26643701 DOI: 10.4103/2303-9027.170425]

- 12 **Sahani DV**, Sainani NI, Blake MA, Crippa S, Mino-Kenudson M, del-Castillo CF. Prospective evaluation of reader performance on MDCT in characterization of cystic pancreatic lesions and prediction of cyst biologic aggressiveness. *AJR Am J Roentgenol* 2011; **197**: W53-W61 [PMID: 21700995 DOI: 10.2214/AJR.10.5866]
- 13 **Sainani NI**, Saokar A, Deshpande V, Fernández-del Castillo C, Hahn P, Sahani DV. Comparative performance of MDCT and MRI with MR cholangiopancreatography in characterizing small pancreatic cysts. *AJR Am J Roentgenol* 2009; **193**: 722-731 [PMID: 19696285 DOI: 10.2214/AJR.08.1253]
- 14 **de Jong K**, van Hooft JE, Nio CY, Gouma DJ, Dijkgraaf MG, Bruno MJ, Fockens P. Accuracy of preoperative workup in a prospective series of surgically resected cystic pancreatic lesions. *Scand J Gastroenterol* 2012; **47**: 1056-1063 [PMID: 22571417 DOI: 10.3109/00365521.2012.674970]
- 15 **Fisher WE**, Hodges SE, Yagnik V, Morón FE, Wu MF, Hilsenbeck SG, Rajman IL, Brunicaudi FC. Accuracy of CT in predicting malignant potential of cystic pancreatic neoplasms. *HPB (Oxford)* 2008; **10**: 483-490 [PMID: 19088937 DOI: 10.1080/13651820802291225]
- 16 **Lee HJ**, Kim MJ, Choi JY, Hong HS, Kim KA. Relative accuracy of CT and MRI in the differentiation of benign from malignant pancreatic cystic lesions. *Clin Radiol* 2011; **66**: 315-321 [PMID: 21356393 DOI: 10.1016/j.crad.2010.06.019]
- 17 **Brugge WR**, Lewandrowski K, Lee-Lewandrowski E, Centeno BA, Szydlowski T, Regan S, del Castillo CF, Warshaw AL. Diagnosis of pancreatic cystic neoplasms: a report of the cooperative pancreatic cyst study. *Gastroenterology* 2004; **126**: 1330-1336 [PMID: 15131794 DOI: 10.1053/j.gastro.2004.02.013]
- 18 **Sedlack R**, Affi A, Vazquez-Sequeiros E, Norton ID, Clain JE, Wiersma MJ. Utility of EUS in the evaluation of cystic pancreatic lesions. *Gastrointest Endosc* 2002; **56**: 543-547 [PMID: 12297771 DOI: 10.1067/mge.2002.128106]
- 19 **Stojanović N**, Ruvidić R, Jovčić G, Mijović A. Drug-induced agranulocytosis: bone marrow granulocytic progenitor cells. *Biomed Pharmacother* 1990; **44**: 181-184 [PMID: 2397279 DOI: 10.1067/mge.2002.128542]
- 20 **Pais SA**, Attasaranya S, Leblanc JK, Sherman S, Schmidt CM, DeWitt J. Role of endoscopic ultrasound in the diagnosis of intraductal papillary mucinous neoplasms: correlation with surgical histopathology. *Clin Gastroenterol Hepatol* 2007; **5**: 489-495 [PMID: 17350894 DOI: 10.1016/j.cgh.2006.12.007]
- 21 **Koito K**, Namieno T, Nagakawa T, Shyonai T, Hirokawa N, Morita K. Solitary cystic tumor of the pancreas: EUS-pathologic correlation. *Gastrointest Endosc* 1997; **45**: 268-276 [PMID: 9087833 DOI: 10.1016/S0016-5107(97)70269-4]
- 22 **Gerke H**, Jaffe TA, Mitchell RM, Byrne MF, Stiffler HL, Branch MS, Baillie J, Jowell PS. Endoscopic ultrasound and computer tomography are inaccurate methods of classifying cystic pancreatic lesions. *Dig Liver Dis* 2006; **38**: 39-44 [PMID: 16314152 DOI: 10.1016/j.dld.2005.09.023]
- 23 **Ahmad NA**, Kochman ML, Brensinger C, Brugge WR, Faigel DO, Gress FG, Kimmey MB, Nickl NJ, Savides TJ, Wallace MB, Wiersma MJ, Ginsberg GG. Interobserver agreement among endosonographers for the diagnosis of neoplastic versus non-neoplastic pancreatic cystic lesions. *Gastrointest Endosc* 2003; **58**: 59-64 [PMID: 12838222 DOI: 10.1067/mge.2003.298]
- 24 **Thornton GD**, McPhail MJ, Nayagam S, Hewitt MJ, Vlavianos P, Monahan KJ. Endoscopic ultrasound guided fine needle aspiration for the diagnosis of pancreatic cystic neoplasms: a meta-analysis. *Pancreatol* 2013; **13**: 48-57 [PMID: 23395570 DOI: 10.1016/j.pan.2012.11.313]
- 25 **Takaori K**. "Revisions of the International Consensus Fukuoka Guidelines for the Management of IPMN of the Pancreas": Progress for twelve years. *Pancreatol* 2017; **17**: 645-646 [PMID: 28864411 DOI: 10.1016/j.pan.2017.08.008]
- 26 **Vege SS**, Ziring B, Jain R, Moayyedi P; Clinical Guidelines Committee; American Gastroenterology Association. American gastroenterological association institute guideline on the diagnosis and management of asymptomatic neoplastic pancreatic cysts. *Gastroenterology* 2015; **148**: 819-822; quiz 822-823 [PMID: 25805375 DOI: 10.1053/j.gastro.2015.01.015]
- 27 **European Study Group on Cystic Tumours of the Pancreas**. European evidence-based guidelines on pancreatic cystic neoplasms. *Gut* 2018; **67**: 789-804 [PMID: 29574408 DOI: 10.1136/gutjnl-2018-316027]
- 28 **Tanaka M**, Fernández-del Castillo C, Adsay V, Chari S, Falconi M, Jang JY, Kimura W, Levy P, Pitman MB, Schmidt CM, Shimizu M, Wolfgang CL, Yamaguchi K, Yamao K; International Association of Pancreatology. International consensus guidelines 2012 for the management of IPMN and MCN of the pancreas. *Pancreatol* 2012; **12**: 183-197 [PMID: 22687371 DOI: 10.1016/j.pan.2012.04.004]
- 29 **Robles EP**, Maire F, Cros J, Vullierme MP, Rebours V, Sauvanet A, Aubert A, Dokmak S, Lévy P, Ruszniewski P. Accuracy of 2012 International Consensus Guidelines for the prediction of malignancy of branch-duct intraductal papillary mucinous neoplasms of the pancreas. *United European Gastroenterol J* 2016; **4**: 580-586 [PMID: 27536368 DOI: 10.1177/2050640615623370]
- 30 **Springer S**, Wang Y, Dal Molin M, Masica DL, Jiao Y, Kinde I, Blackford A, Raman SP, Wolfgang CL, Tomita T, Niknafs N, Douville C, Ptak J, Dobbys L, Allen PJ, Klimstra DS, Schattner MA, Schmidt CM, Yip-Schneider M, Cummings OW, Brand RE, Zeh HJ, Singhi AD, Scarpa A, Salvia R, Malleo G, Zamboni G, Falconi M, Jang JY, Kim SW, Kwon W, Hong SM, Song KB, Kim SC, Swan N, Murphy J, Geoghegan J, Brugge W, Fernandez-Del Castillo C, Mino-Kenudson M, Schulick R, Edil BH, Adsay V, Paulino J, van Hooft J, Yachida S, Nara S, Hiraoka N, Yamao K, Hijioka S, van der Merwe S, Goggins M, Canto MI, Ahuja N, Hirose K, Makary M, Weiss MJ, Cameron J, Pittman M, Eshleman JR, Diaz LA Jr, Papadopoulos N, Kinzler KW, Karchin R, Hruban RH, Vogelstein B, Lennan AM. A combination of molecular markers and clinical features improve the classification of pancreatic cysts. *Gastroenterology* 2015; **149**: 1501-1510 [PMID: 26253305 DOI: 10.1053/j.gastro.2015.07.041]
- 31 **Alvarez-Sánchez MV**, Napoléon B. Contrast-enhanced harmonic endoscopic ultrasound imaging: basic principles, present situation and future perspectives. *World J Gastroenterol* 2014; **20**: 15549-15563 [PMID: 25400439 DOI: 10.3748/wjg.v20.i42.15549]
- 32 **Ignée A**, Atkinson NS, Schuessler G, Dietrich CF. Ultrasound contrast agents. *Endosc Ultrasound* 2016; **5**: 355-362 [PMID: 27824024 DOI: 10.4103/2303-9027.193594]
- 33 **Kang ST**, Yeh CK. Ultrasound microbubble contrast agents for diagnostic and therapeutic applications: current status and future design. *Chang Gung Med J* 2012; **35**: 125-139 [PMID: 22537927]
- 34 **Kitano M**, Kudo M, Sakamoto H, Komaki T. Endoscopic ultrasonography and contrast-enhanced endoscopic ultrasonography. *Pancreatol* 2011; **11** Suppl 2: 28-33 [PMID: 21464584 DOI: 10.1159/000323493]
- 35 **Sanchez MV**, Varadarajulu S, Napoleon B. EUS contrast agents: what is available, how do they work, and are they effective? *Gastrointest Endosc* 2009; **69**: S71-S77 [PMID: 19179175 DOI: 10.1016/j.gie.2008.12.004]
- 36 **Hocke M**, Cui XW, Domagk D, Ignée A, Dietrich CF. Pancreatic cystic lesions: The value of contrast-enhanced endoscopic ultrasound to influence the clinical pathway. *Endosc Ultrasound* 2014; **3**: 123-130 [PMID: 24955342 DOI: 10.4103/2303-9027.131040]
- 37 **Fusaroli P**, Serrani M, De Giorgio R, D'Ercole MC, Ceroni L, Lisotti A, Caletti G. Contrast Harmonic-Endoscopic Ultrasound Is Useful to Identify Neoplastic Features of Pancreatic Cysts (With Videos). *Pancreas* 2016; **45**: 265-268 [PMID: 26474428 DOI: 10.1097/MPA.0000000000000441]
- 38 **Kamata K**, Kitano M, Omoto S, Kadosaka K, Miyata T, Yamao K, Imai H, Sakamoto H, Harwani Y, Chikugo T, Chiba Y, Matsumoto I, Takeyama Y, Kudo M. Contrast-enhanced harmonic endoscopic ultrasonography for differential diagnosis of pancreatic cysts. *Endoscopy* 2016; **48**: 35-41 [PMID: 26605974 DOI: 10.1055/s-0034-1393564]
- 39 **Yamashita Y**, Ueda K, Itonaga M, Yoshida T, Maeda H, Maekita T, Iguchi M, Tamai H, Ichinose M, Kato J. Usefulness of contrast-enhanced endoscopic sonography for discriminating mural nodules

- from mucous clots in intraductal papillary mucinous neoplasms: a single-center prospective study. *J Ultrasound Med* 2013; **32**: 61-68 [PMID: 23269711 DOI: 10.7863/jum.2013.32.1.61]
- 40 **Fujita M**, Itoi T, Ikeuchi N, Sofuni A, Tsuchiya T, Ishii K, Kamada K, Umeda J, Tanaka R, Tonoizuka R, Honjo M, Mukai S, Moriyasu F. Effectiveness of contrast-enhanced endoscopic ultrasound for detecting mural nodules in intraductal papillary mucinous neoplasm of the pancreas and for making therapeutic decisions. *Endosc Ultrasound* 2016; **5**: 377-383 [PMID: 28000629 DOI: 10.4103/2303-9027.190927]
- 41 **Harima H**, Kaino S, Shinoda S, Kawano M, Suenaga S, Sakaida I. Differential diagnosis of benign and malignant branch duct intraductal papillary mucinous neoplasm using contrast-enhanced endoscopic ultrasonography. *World J Gastroenterol* 2015; **21**: 6252-6260 [PMID: 26034360 DOI: 10.3748/wjg.v21.i20.6252]
- 42 **Yamamoto N**, Kato H, Tomoda T, Matsumoto K, Sakakihara I, Noma Y, Horiguchi S, Harada R, Tsutsumi K, Hori K, Tanaka T, Okada H, de Yamamoto K. Contrast-enhanced harmonic endoscopic ultrasonography with time-intensity curve analysis for intraductal papillary mucinous neoplasms of the pancreas. *Endoscopy* 2016; **48**: 26-34 [PMID: 26561919 DOI: 10.1055/s-0034-1393563]
- 43 **Leung Ki EL**, Napoleon B. Nuevas herramientas y recursos en la evaluación de quistes pancreáticos por ultrasonografía endoscópica. In: Fauze Maluf-Filho/Shyam Varadarajulu. Avances en ultrasonografía endoscópica. *Clínicas iberoamericanas de gastroenterología y hepatología* 2018; 51-68
- 44 **Nakai Y**, Isayama H, Shinoura S, Iwashita T, Samarasena JB, Chang KJ, Koike K. Confocal laser endomicroscopy in gastrointestinal and pancreatobiliary diseases. *Dig Endosc* 2014; **26** Suppl 1: 86-94 [PMID: 24033351 DOI: 10.1111/den.12152]
- 45 **Giovannini M**. Needle-based confocal laser endomicroscopy. *Endosc Ultrasound* 2015; **4**: 284-288 [PMID: 26643694 DOI: 10.4103/2303-9027.170405]
- 46 **Tsujino T**, Yan-Lin Huang J, Nakai Y, Samarasena JB, Lee JG, Chang KJ. In vivo identification of pancreatic cystic neoplasms with needle-based confocal laser endomicroscopy. *Best Pract Res Clin Gastroenterol* 2015; **29**: 601-610 [PMID: 26381305 DOI: 10.1016/j.bpg.2015.06.006]
- 47 **Ștefănescu D**, Pereira SP, Keane M, Săftoiu A. Needle-based confocal laser endomicroscopy in pancreatic cystic tumors assessment. *Rom J Morphol Embryol* 2015; **56**: 1263-1268 [PMID: 26743270]
- 48 **Konda VJ**, Aslanian HR, Wallace MB, Siddiqui UD, Hart J, Waxman I. First assessment of needle-based confocal laser endomicroscopy during EUS-FNA procedures of the pancreas (with videos). *Gastrointest Endosc* 2011; **74**: 1049-1060 [PMID: 21924718 DOI: 10.1016/j.gie.2011.07.018]
- 49 **Wefers H**, Sies H. Generation of photoemissive species during quinone redox cycling. *Biochem Pharmacol* 1986; **35**: 22-24 [PMID: 2416319 DOI: 10.1055/s-0033-1344714]
- 50 **Nakai Y**, Iwashita T, Park DH, Samarasena JB, Lee JG, Chang KJ. Diagnosis of pancreatic cysts: EUS-guided, through-the-needle confocal laser-induced endomicroscopy and cystoscopy trial: DETECT study. *Gastrointest Endosc* 2015; **81**: 1204-1214 [PMID: 25634486 DOI: 10.1016/j.gie.2014.10.025]
- 51 **Napoléon B**, Lemaistre AI, Pujol B, Caillol F, Lucidarme D, Bourdariat R, Morellon-Mialhe B, Fumex F, Lefort C, Lepilliez V, Palazzo L, Monges G, Filoche B, Giovannini M. A novel approach to the diagnosis of pancreatic serous cystadenoma: needle-based confocal laser endomicroscopy. *Endoscopy* 2015; **47**: 26-32 [PMID: 25325684 DOI: 10.1055/s-0034-1390693]
- 52 **Napoleon B**, Lemaistre AI, Pujol B, Caillol F, Lucidarme D, Bourdariat R, Morellon-Mialhe B, Fumex F, Lefort C, Lepilliez V, Palazzo L, Monges G, Poizat F, Giovannini M. In vivo characterization of pancreatic cystic lesions by needle-based confocal laser endomicroscopy (nCLE): proposition of a comprehensive nCLE classification confirmed by an external retrospective evaluation. *Surg Endosc* 2016; **30**: 2603-2612 [PMID: 26428198 DOI: 10.1007/s00464-015-4510-5]
- 53 **Kadayifci A**, Atar M, Basar O, Forcione DG, Brugge WR. Needle-Based Confocal Laser Endomicroscopy for Evaluation of Cystic Neoplasms of the Pancreas. *Dig Dis Sci* 2017; **62**: 1346-1353 [PMID: 28281172 DOI: 10.1007/s10620-017-4521-2]
- 54 **Krishna SG**, Modi RM, Kamboj AK, Swanson BJ, Hart PA, Dillhoff ME, Manilchuk A, Schmidt CR, Conwell DL. In vivo and ex vivo confocal endomicroscopy of pancreatic cystic lesions: A prospective study. *World J Gastroenterol* 2017; **23**: 3338-3348 [PMID: 28566895 DOI: 10.3748/wjg.v23.i18.3338]
- 55 **Napoléon B**, Palazzo M, Lemaistre AI, Caillol F, Palazzo L, Aubert A, Buscail L, Maire F, Mialhe-Morellon B, Pujol B, Giovannini M. Needle-based confocal laser endomicroscopy characterization of pancreatic cystic lesions with a definitive diagnoses: a prospective multicentre study. *Endoscopy* 2017; In press
- 56 **Karia K**, Waxman I, Konda VJ, Gress FG, Sethi A, Siddiqui UD, Sharaiha RZ, Kedia P, Jamal-Kabani A, Gaidhane M, Kahaleh M. Needle-based confocal endomicroscopy for pancreatic cysts: the current agreement in interpretation. *Gastrointest Endosc* 2016; **83**: 924-927 [PMID: 26382051 DOI: 10.1016/j.gie.2015.08.080]
- 57 **Krishna SG**, Swanson B, Hart PA, El-Dika S, Walker JP, McCarthy ST, Malli A, Shah ZK, Conwell DL. Validation of diagnostic characteristics of needle based confocal laser endomicroscopy in differentiation of pancreatic cystic lesions. *Endosc Int Open* 2016; **4**: E1124-E1135 [PMID: 27853737 DOI: 10.1055/s-0042-116491]
- 58 **Krishna SG**, Brugge WR, Dewitt JM, Kongkam P, Napoleon B, Robles-Medrand C, Tan D, El-Dika S, McCarthy S, Walker J, Dillhoff ME, Manilchuk A, Schmidt C, Swanson B, Shah ZK, Hart PA, Conwell DL. Needle-based confocal laser endomicroscopy for the diagnosis of pancreatic cystic lesions: an international external interobserver and intraobserver study (with videos). *Gastrointest Endosc* 2017; **86**: 644-654.e2 [PMID: 28286093 DOI: 10.1016/j.gie.2017.03.002]
- 59 **Aparicio JR**, Martínez J, Niveiro M, Cabezas A, Ruiz F, De Madaria E, Casellas JA. Direct intracystic biopsy and pancreatic cystoscopy through a 19-gauge needle EUS (with videos). *Gastrointest Endosc* 2010; **72**: 1285-1288 [PMID: 20970789 DOI: 10.1016/j.gie.2010.08.036]
- 60 **Chai N**, Feng J, Guo Y, Li H, Ning B, Wang X, Wang Y, Wang Y, Zhai Y, Linghu E. Preliminary study of single-operator cholangioscopy for diagnosing pancreatic cystic lesions. *Gastrointest Endosc* 2017; **86**: 208-218 [PMID: 28185905 DOI: 10.1016/j.gie.2017.01.038]
- 61 **Shakhatreh MH**, Naini SR, Brijbassie AA, Grider DJ, Shen P, Yeaton P. Use of a novel through-the-needle biopsy forceps in endoscopic ultrasound. *Endosc Int Open* 2016; **4**: E439-E442 [PMID: 27092324 DOI: 10.1055/s-0042-101941]
- 62 **Barresi L**, Tarantino I, Ligresti D, Curcio G, Granata A, Traina M. A new tissue acquisition technique in pancreatic cystic neoplasm: endoscopic ultrasound-guided through-the-needle forceps biopsy. *Endoscopy* 2015; **47** Suppl 1: E297-E298 [PMID: 26099102 DOI: 10.1055/s-0034-1392031]
- 63 **Pham KD**, Engjom T, Gjølberg Kolleset H, Helgeland L. Diagnosis of a mucinous pancreatic cyst and resection of an intracystic nodule using a novel through-the-needle micro forceps. *Endoscopy* 2016; **48** Suppl 1: E125-E126 [PMID: 27031299 DOI: 10.1055/s-0042-105437]
- 64 **Attili F**, Pagliari D, Rimbaz M, Inzani F, Brizi MG, Costamagna G, Larghi A. Endoscopic ultrasound-guided histological diagnosis of a mucinous non-neoplastic pancreatic cyst using a specially designed through-the-needle microforceps. *Endoscopy* 2016; **48** Suppl 1: E188-E189 [PMID: 27213974 DOI: 10.1055/s-0042-108194]
- 65 **Huelsen A**, Cooper C, Saad N, Gupta S. Endoscopic ultrasound-guided, through-the-needle forceps biopsy in the assessment of an incidental large pancreatic cystic lesion with prior inconclusive fine-needle aspiration. *Endoscopy* 2017; **49**: E109-E110 [PMID: 28192812 DOI: 10.1055/s-0043-100217]
- 66 **Jais B**, Rebours V, Malleo G, Salvia R, Fontana M, Maggino L, Bassi C, Manfredi R, Moran R, Lennon AM, Zaheer A, Wolfgang C, Hruban R, Marchegiani G, Fernández Del Castillo C, Brugge W, Ha Y, Kim MH, Oh D, Hirai I, Kimura W, Jang JY, Kim SW, Jung W, Kang H, Song SY, Kang CM, Lee WJ, Crippa S, Falconi

- M, Gomatos I, Neoptolemos J, Milanetto AC, Sperti C, Ricci C, Casadei R, Bissolati M, Balzano G, Frigerio I, Girelli R, Delhay M, Bernier B, Wang H, Jang KT, Song DH, Huggett MT, Oppong KW, Pererva L, Kopchak KV, Del Chiaro M, Segersvard R, Lee LS, Conwell D, Osvaldt A, Campos V, Agüero Garcete G, Napoleon B, Matsumoto I, Shinzeki M, Bolado F, Fernandez JM, Keane MG, Pereira SP, Acuna IA, Vaquero EC, Angiolini MR, Zerbi A, Tang J, Leong RW, Faccineto A, Morana G, Petrone MC, Arcidiacono PG, Moon JH, Choi HJ, Gill RS, Pavey D, Ouasssi M, Sastre B, Spandre M, De Angelis CG, Rios-Vives MA, Concepcion-Martin M, Ikeura T, Okazaki K, Frulloni L, Messina O, Lévy P. Serous cystic neoplasm of the pancreas: a multinational study of 2622 patients under the auspices of the International Association of Pancreatology and European Pancreatic Club (European Study Group on Cystic Tumors of the Pancreas). *Gut* 2016; **65**: 305-312 [PMID: 26045140 DOI: 10.1136/gutjnl-2015-309638]
- 67 **Kitano M**, Kudo M, Yamao K, Takagi T, Sakamoto H, Komaki T, Kamata K, Imai H, Chiba Y, Okada M, Murakami T, Takeyama Y. Characterization of small solid tumors in the pancreas: the value of contrast-enhanced harmonic endoscopic ultrasonography. *Am J Gastroenterol* 2012; **107**: 303-310 [PMID: 22008892 DOI: 10.1038/ajg.2011.354]
- 68 **Napoleon B**, Alvarez-Sanchez MV, Gincoul R, Pujol B, Lefort C, Lepilliez V, Labadie M, Souquet JC, Queneau PE, Scoazec JY, Chayvialle JA, Ponchon T. Contrast-enhanced harmonic endoscopic ultrasound in solid lesions of the pancreas: results of a pilot study. *Endoscopy* 2010; **42**: 564-570 [PMID: 20593334 DOI: 10.1055/s-0030-1255537]
- 69 **Gincul R**, Palazzo M, Pujol B, Tubach F, Palazzo L, Lefort C, Fumex F, Lombard A, Ribeiro D, Fabre M, Hervieu V, Labadie M, Ponchon T, Napoléon B. Contrast-harmonic endoscopic ultrasound for the diagnosis of pancreatic adenocarcinoma: a prospective multicenter trial. *Endoscopy* 2014; **46**: 373-379 [PMID: 24532350 DOI: 10.1055/s-0034-1364969]
- 70 **Omoto S**, Takenaka M, Kitano M, Miyata T, Kamata K, Minaga K, Arizumi T, Yamao K, Imai H, Sakamoto H, Harwani Y, Sakurai T, Watanabe T, Nishida N, Takeyama Y, Chiba Y, Kudo M. Characterization of Pancreatic Tumors with Quantitative Perfusion Analysis in Contrast-Enhanced Harmonic Endoscopic Ultrasonography. *Oncology* 2017; **93** Suppl 1: 55-60 [PMID: 29258065 DOI: 10.1159/000481231]
- 71 **Tachezy M**, Reichelt U, Melenberg T, Gebauer F, Izbicki JR, Kaifi JT. Angiogenesis index CD105 (endoglin)/CD31 (PECAM-1) as a predictive factor for invasion and proliferation in intraductal papillary mucinous neoplasm (IPMN) of the pancreas. *Histol Histopathol* 2010; **25**: 1239-1246 [PMID: 20712008 DOI: 10.14670/HH-25.1239]
- 72 **Main ML**. Ultrasound contrast agent safety: from anecdote to evidence. *JACC Cardiovasc Imaging* 2009; **2**: 1057-1059 [PMID: 19761982 DOI: 10.1016/j.jcmg.2009.05.008]
- 73 **Szebeni J**. Complement activation-related pseudoallergy: a new class of drug-induced acute immune toxicity. *Toxicology* 2005; **216**: 106-121 [PMID: 16140450 DOI: 10.1016/j.tox.2005.07.023]
- 74 **Piscaglia F**, Bolondi L; Italian Society for Ultrasound in Medicine and Biology (SIUMB) Study Group on Ultrasound Contrast Agents. The safety of Sonovue in abdominal applications: retrospective analysis of 23188 investigations. *Ultrasound Med Biol* 2006; **32**: 1369-1375 [PMID: 16965977 DOI: 10.1016/j.ultrasmedbio.2006.05.031]
- 75 **de Jong K**, Poley JW, van Hooft JE, Visser M, Bruno MJ, Fockens P. Endoscopic ultrasound-guided fine-needle aspiration of pancreatic cystic lesions provides inadequate material for cytology and laboratory analysis: initial results from a prospective study. *Endoscopy* 2011; **43**: 585-590 [PMID: 21611945 DOI: 10.1055/s-0030-1256440]
- 76 **Yannuzzi LA**, Rohrer KT, Tindel LJ, Sobel RS, Costanza MA, Shields W, Zang E. Fluorescein angiography complication survey. *Ophthalmology* 1986; **93**: 611-617 [PMID: 3523356 DOI: 10.1016/S0161-6420(86)33697-2]
- 77 **Wallace MB**, Meining A, Canto MI, Fockens P, Miehke S, Roesch T, Lightdale CJ, Pohl H, Carr-Locke D, Löhr M, Coron E, Filoche B, Giovannini M, Moreau J, Schmidt C, Kiesslich R. The safety of intravenous fluorescein for confocal laser endomicroscopy in the gastrointestinal tract. *Aliment Pharmacol Ther* 2010; **31**: 548-552 [PMID: 20002025 DOI: 10.1111/j.1365-2036.2009.04207.x]
- 78 **Le Pen C**, Palazzo L, Napoléon B. A health economic evaluation of needle-based confocal laser endomicroscopy for the diagnosis of pancreatic cysts. *Endosc Int Open* 2017; **5**: E987-E995 [PMID: 29159273 DOI: 10.1055/s-0043-117947]

P- Reviewer: Andrianello S, De Lisi S, Fusaroli P, Kitamura K, Liu QD
S- Editor: Wang XJ **L- Editor:** A **E- Editor:** Yin SY





Published by **Baishideng Publishing Group Inc**
7901 Stoneridge Drive, Suite 501, Pleasanton, CA 94588, USA
Telephone: +1-925-223-8242
Fax: +1-925-223-8243
E-mail: bpgoffice@wjgnet.com
Help Desk: <http://www.f6publishing.com/helpdesk>
<http://www.wjgnet.com>



ISSN 1007-9327

