

# World Journal of *Gastroenterology*

*World J Gastroenterol* 2018 May 14; 24(18): 1925-2046



**REVIEW**

- 1925** Gastrointestinal stromal tumors: A multidisciplinary challenge  
*Sanchez-Hidalgo JM, Duran-Martinez M, Molero-Payan R, Rufian-Peña S, Arjona-Sanchez A, Casado-Adam A, Cosano-Alvarez A, Briceño-Delgado J*
- 1942** New therapeutic options opened by the molecular classification of gastric cancer  
*Chivu-Economescu M, Matei L, Necula LG, Dragu DL, Bleotu C, Diaconu CC*
- 1962** Ambiguous roles of innate lymphoid cells in chronic development of liver diseases  
*Shen Y, Li J, Wang SQ, Jiang W*

**MINIREVIEWS**

- 1978** Laparoscopic gastrojejunostomy for gastric outlet obstruction in patients with unresectable hepatopancreatobiliary cancers: A personal series and systematic review of the literature  
*Manuel-Vázquez A, Latorre-Fragua R, Ramiro-Pérez C, López-Marciano A, De la Plaza-Llamas R, Ramia JM*
- 1989** Mouse models for investigating the underlying mechanisms of nonalcoholic steatohepatitis-derived hepatocellular carcinoma  
*Takakura K, Oikawa T, Tomita Y, Mizuno Y, Nakano M, Saeki C, Torisu Y, Saruta M*

**ORIGINAL ARTICLE****Basic Study**

- 1995** Microbiota modification by probiotic supplementation reduces colitis associated colon cancer in mice  
*Mendes MC, Paulino DS, Brambilla SR, Camargo JA, Persinoti GF, Carnevali JB*
- 2009** Ischemia/reperfusion injury in porcine intestine - Viability assessment  
*Strand-Amundsen RJ, Reims HM, Reinholt FP, Ruud TE, Yang R, Høgetveit JO, Tønnessen TI*

**Clinical Trials Study**

- 2024** Quantitative assessment of hepatic fibrosis in chronic hepatitis B and C: T1 mapping on Gd-EOB-DTPA-enhanced liver magnetic resonance imaging  
*Pan S, Wang XQ, Guo QY*

**Observational Study**

- 2036** Thiopurines are negatively associated with anthropometric parameters in pediatric Crohn's disease  
*Gupta N, Lustig RH, Chao C, Vittinghoff E, Andrews H, Leu CS*



## ABOUT COVER

Editorial board member of *World Journal of Gastroenterology*, Andrew Stewart Day, MD, Professor, Paediatrics Department, University of Otago, Christchurch 8041, New Zealand

## AIMS AND SCOPE

*World Journal of Gastroenterology* (*World J Gastroenterol*, *WJG*, print ISSN 1007-9327, online ISSN 2219-2840, DOI: 10.3748) is a peer-reviewed open access journal. *WJG* was established on October 1, 1995. It is published weekly on the 7<sup>th</sup>, 14<sup>th</sup>, 21<sup>st</sup>, and 28<sup>th</sup> each month. The *WJG* Editorial Board consists of 642 experts in gastroenterology and hepatology from 59 countries.

The primary task of *WJG* is to rapidly publish high-quality original articles, reviews, and commentaries in the fields of gastroenterology, hepatology, gastrointestinal endoscopy, gastrointestinal surgery, hepatobiliary surgery, gastrointestinal oncology, gastrointestinal radiation oncology, gastrointestinal imaging, gastrointestinal interventional therapy, gastrointestinal infectious diseases, gastrointestinal pharmacology, gastrointestinal pathophysiology, gastrointestinal pathology, evidence-based medicine in gastroenterology, pancreatology, gastrointestinal laboratory medicine, gastrointestinal molecular biology, gastrointestinal immunology, gastrointestinal microbiology, gastrointestinal genetics, gastrointestinal translational medicine, gastrointestinal diagnostics, and gastrointestinal therapeutics. *WJG* is dedicated to become an influential and prestigious journal in gastroenterology and hepatology, to promote the development of above disciplines, and to improve the diagnostic and therapeutic skill and expertise of clinicians.

## INDEXING/ABSTRACTING

*World Journal of Gastroenterology* (*WJG*) is now indexed in Current Contents<sup>®</sup>/Clinical Medicine, Science Citation Index Expanded (also known as SciSearch<sup>®</sup>), Journal Citation Reports<sup>®</sup>, Index Medicus, MEDLINE, PubMed, PubMed Central and Directory of Open Access Journals. The 2017 edition of Journal Citation Reports<sup>®</sup> cites the 2016 impact factor for *WJG* as 3.365 (5-year impact factor: 3.176), ranking *WJG* as 29<sup>th</sup> among 79 journals in gastroenterology and hepatology (quartile in category Q2).

## EDITORS FOR THIS ISSUE

Responsible Assistant Editor: *Xiang Li*  
Responsible Electronic Editor: *Yan Huang*  
Proofing Editor-in-Chief: *Lian-Sheng Ma*

Responsible Science Editor: *Xue-Jiao Wang*  
Proofing Editorial Office Director: *Ze-Mao Gong*

NAME OF JOURNAL  
*World Journal of Gastroenterology*

ISSN  
ISSN 1007-9327 (print)  
ISSN 2219-2840 (online)

LAUNCH DATE  
October 1, 1995

FREQUENCY  
Weekly

EDITORS-IN-CHIEF  
**Damian Garcia-Olmo, MD, PhD, Doctor, Professor, Surgeon**, Department of Surgery, Universidad Autonoma de Madrid; Department of General Surgery, Fundacion Jimenez Diaz University Hospital, Madrid 28040, Spain

**Stephen C Strom, PhD, Professor**, Department of Laboratory Medicine, Division of Pathology, Karolinska Institutet, Stockholm 141-86, Sweden

**Andrzej S Tarnawski, MD, PhD, DSc (Med), Professor of Medicine, Chief Gastroenterology**, VA Long Beach Health Care System, University of California, Irvine, CA, 5901 E. Seventh Str., Long Beach,

CA 90822, United States

EDITORIAL BOARD MEMBERS  
All editorial board members resources online at <http://www.wjgnet.com/1007-9327/editorialboard.htm>

EDITORIAL OFFICE  
**Ze-Mao Gong, Director**  
*World Journal of Gastroenterology*  
Baishideng Publishing Group Inc  
7901 Stoneridge Drive, Suite 501,  
Pleasanton, CA 94588, USA  
Telephone: +1-925-2238242  
Fax: +1-925-2238243  
E-mail: [editorialoffice@wjgnet.com](mailto:editorialoffice@wjgnet.com)  
Help Desk: <http://www.f6publishing.com/helpdesk>  
<http://www.wjgnet.com>

PUBLISHER  
Baishideng Publishing Group Inc  
7901 Stoneridge Drive, Suite 501,  
Pleasanton, CA 94588, USA  
Telephone: +1-925-2238242  
Fax: +1-925-2238243  
E-mail: [bpgoffice@wjgnet.com](mailto:bpgoffice@wjgnet.com)  
Help Desk: <http://www.f6publishing.com/helpdesk>  
<http://www.wjgnet.com>

PUBLICATION DATE  
May 14, 2018

COPYRIGHT  
© 2018 Baishideng Publishing Group Inc. Articles published by this Open-Access journal are distributed under the terms of the Creative Commons Attribution Non-commercial License, which permits use, distribution, and reproduction in any medium, provided the original work is properly cited, the use is non commercial and is otherwise in compliance with the license.

SPECIAL STATEMENT  
All articles published in journals owned by the Baishideng Publishing Group (BPG) represent the views and opinions of their authors, and not the views, opinions or policies of the BPG, except where otherwise explicitly indicated.

INSTRUCTIONS TO AUTHORS  
Full instructions are available online at <http://www.wjgnet.com/bpg/gerinfo/204>

ONLINE SUBMISSION  
<http://www.f6publishing.com>

# Laparoscopic gastrojejunostomy for gastric outlet obstruction in patients with unresectable hepatopancreatobiliary cancers: A personal series and systematic review of the literature

Alba Manuel-Vázquez, Raquel Latorre-Fragua, Carmen Ramiro-Pérez, Aylhin López-Marcano, Roberto De la Plaza-Llamas, José Manuel Ramia

Alba Manuel-Vázquez, Raquel Latorre-Fragua, Carmen Ramiro-Pérez, Aylhin López-Marcano, Roberto De la Plaza-Llamas, José Manuel Ramia, Department of General and Digestive Surgery, University Hospital of Guadalajara, Guadalajara 19002, Spain

ORCID number: Manuel-Vázquez A (0000-0002-3267-0274); Latorre-Fragua R (0000-0001-5311-0025); Ramiro-Pérez C (0000-0002-1383-2303); López-Marcano A (0000-0003-1095-3887); De la Plaza-Llamas R (0000-0001-9501-5480); Ramia JM (0000-0003-1186-953X)

**Author contributions:** Manuel-Vázquez A designed the study, performed the research, analyzed data, and wrote the paper; Latorre-Fragua R, Ramiro-Pérez C, López-Marcano A performed the research, analyzed and interpreted of data; De la Plaza-Llamas R critically reviewed; Ramia JM critically reviewed, finally approved and supervised the report.

**Conflict-of-interest statement:** We have no financial relationships to disclose. **Data sharing statement:** No additional data are available.

**Open-Access:** This article is an open-access article which was selected by an in-house editor and fully peer-reviewed by external reviewers. It is distributed in accordance with the Creative Commons Attribution Non Commercial (CC BY-NC 4.0) license, which permits others to distribute, remix, adapt, build upon this work non-commercially, and license their derivative works on different terms, provided the original work is properly cited and the use is non-commercial. See: <http://creativecommons.org/licenses/by-nc/4.0/>

**Manuscript source:** Invited manuscript

**Correspondence to:** Alba Manuel-Vázquez, MD, PhD, Doctor, Department of General and Digestive Surgery, University Hospital of Guadalajara, Calle Donante de sangre s/n, Guadalajara 19002, Spain. [alba\\_manuel\\_vazquez@hotmail.com](mailto:alba_manuel_vazquez@hotmail.com)

Telephone: +34-949-209200

Fax: +34-949-209218

Received: April 6, 2018

Peer-review started: April 8, 2018

First decision: April 21, 2018

Revised: April 26, 2018

Accepted: May 6, 2018

Article in press: May 6, 2018

Published online: May 14, 2018

## Abstract

The major symptoms of advanced hepatopancreatobiliary cancer are biliary obstruction, pain and gastric outlet obstruction (GOO). For obstructive jaundice, surgical treatment should be considered in recurrent stent complications. The role of surgery for pain relief is marginal nowadays. On the last, there is no consensus for treatment of malignant GOO. Endoscopic duodenal stents are associated with shorter length of stay and faster relief to oral intake with more recurrent symptoms. Surgical gastrojejunostomy shows better long-term results and lower re-intervention rates, but there are limited data about laparoscopic approach. We performed a systematic review of the literature, according PRISMA guidelines, to search for articles on laparoscopic gastrojejunostomy for malignant GOO treatment. We also report our personal series, from 2009 to 2017. A review of the literature suggests that there is no standardized surgical technique either standardized outcomes to report. Most of the studies are case series, so level of evidence is low. Decision-making must consider medical condition, nutritional status, quality of life and life expectancy. Evaluation of

the patient and multidisciplinary expertise are required to select appropriate approach. Given the limited studies and the difficulty to perform prospective controlled trials, no study can answer all the complexities of malignant GOO and more outcome data is needed.

**Key words:** Duodenal obstruction; Gastrojejunostomy; Gastroenterosmy; Gastric outlet obstruction; Gastric bypass; Laparoscopy; Laparoscopic surgery; Sytematic review

© **The Author(s) 2018.** Published by Baishideng Publishing Group Inc. All rights reserved.

**Core tip:** Both non-operative endoscopic approach and surgical treatment are available for palliative treatment of gastric outlet obstruction due to advanced hepatopancreatic-biliary cancer. Stent is usually preferred in patients with poor general condition or short life expectancy. Laparoscopic gastrojejunostomy is a feasible, safe and efficient technical option. Given the limited studies, we performed a systematic review of laparoscopic gastrojejunostomy in patients with advanced hepatopancreatic-biliary malignancy. Clinical prospective trials comparing different approaches with adequate sample size are warranted.

Manuel-Vázquez A, Latorre-Fragua R, Ramiro-Pérez C, López-Marcano A, De la Plaza-Llamas R, Ramia JM. Laparoscopic gastrojejunostomy for gastric outlet obstruction in patients with unresectable hepatopancreatobiliary cancers: A personal series and systematic review of the literature. *World J Gastroenterol* 2018; 24(18): 1978-1988 Available from: URL: <http://www.wjgnet.com/1007-9327/full/v24/i18/1978.htm> DOI: <http://dx.doi.org/10.3748/wjg.v24.i18.1978>

## INTRODUCTION

Obstructive jaundice, gastric outlet obstruction (GOO) and tumor-associated pain are the major symptoms of advanced hepatobiliary-pancreatic (HPB) cancer. Usually these cancers are not resected because of infiltration of local structures or disseminated disease. Today, these complications can be managed with endoscopic stenting and percutaneous treatment, which have lower rates of associated morbidity; thus, surgical strategies have decreased.

Around 70% of cases of advanced HPB cancer present obstructive jaundice<sup>[1,2]</sup>, which is the most common symptom<sup>[3-5]</sup>. To resolve jaundice in unresectable or metastatic patients, endoscopic or percutaneous biliary stent is accepted as the gold standard<sup>[6]</sup>. Surgical treatment of biliary obstruction should be considered in persistent stent-problems, such as recurrent cholangitis or recurrent obstructive jaundice<sup>[6]</sup>; however laparoscopic surgery for biliary bypass is not a standard procedure<sup>[1,7]</sup>. Furthermore, the role of surgical pain relief in these patients seems to be marginal nowadays<sup>[6]</sup>.

Finally, there is no consensus about the role of surgery in the management of malignant GOO. This clinical syndrome is characterized by abdominal pain, weight loss, nausea and vomiting, due to the mechanical obstruction, and may be caused by gastric, duodenal, HPB or extraluminal diseases; therefore, the treatment depends on underlying cause<sup>[8]</sup>. In recent decades, 50%-80% of cases have been attributed to malignancy. GOO may develop in up to 20% of patients with advanced HPB disease<sup>[4,9-14]</sup>. The aim of GOO treatment is to reestablish oral intake by restoring gastrointestinal continuity.

Decision-making with regard to palliative treatment of malignant GOO due to advanced HPB cancer has become more complex in recent years. Traditionally, open gastrojejunostomy (OGJ) was the only option<sup>[11,15]</sup>. In the 1990s, endoscopic duodenal stents were introduced. In the last few years, laparoscopic gastrojejunostomy (LGJ) has emerged as a feasible and safe option that offers improved morbidity and mortality rates compared with the open surgical approach<sup>[3]</sup>. As can be seen, then, several options are available and there is no current gold standard<sup>[9]</sup>.

The literature on GOO focus on gastric disease and mixes different causes with different prognoses. This means that, the level of evidence in patients with HPB malignant diseases is low and data on the laparoscopic approach to GJ for malignant GOO due to advanced HPB cancers are limited.

Our aim in this paper is to review various aspects of the management of malignant GOO due to advanced HPB cancer. Focusing on the laparoscopic approach for gastroenteroanastomosis, we perform a systematic review of the literature and a retrospective review of our personal series of laparoscopic GJ for the treatment of malignant GOO due to advanced HPB cancer.

## ROLE OF PROPHYLACTIC GASTROJEJUNOSTOMY

A cancer may be found to be unresectable during preoperative staging examinations. Only some 20% of HPB neoplasms are found to be resectable<sup>[16-18]</sup>. Despite the indications of preoperative staging radiological and endoscopic images, between 8% and 33% of patients are found to be unresectable on laparotomy<sup>[19]</sup>. This means that surgeons may be encounter this situation intraoperatively and must decide whether to perform prophylactic GJ. This decision should be based on the probability of GOO; between 10%-15% of patients develop GOO at a later stage<sup>[3,11,20]</sup>.

Gurusamy *et al*<sup>[2]</sup> report no differences in overall survival, postoperative morbidity and mortality, quality of life (QOL) or length of stay (LOS). This Cochrane review included two RCTs assessing the role of prophylactic GJ in unresectable periampullary cancer<sup>[21,22]</sup>. The authors reported a long-term GOO incidence of 27.8% in patients with advanced HPB cancer who did not undergo

prophylactic GJ and concluded that prophylactic GJ may not be necessary in all patients with advanced HPB malignancy undergoing laparotomy<sup>[2]</sup>.

## PALLIATIVE TREATMENT OF GOO

Physicians may also find a patient with uncontrolled vomiting and a diagnosis of advanced HPB malignancy. Palliative treatment should be offered to relieve the symptoms of GOO and ultimately to improve patient QOL. Palliative treatment is mandatory when the vomiting is uncontrolled.

### Stent vs palliative surgery

Traditionally, OGJ was the only option for the treatment of malignant GOO<sup>[11,13,15]</sup>. Since 1992, several studies have described the use, safety and efficacy of self-expandable metallic stents (SEMS)<sup>[10,23-33]</sup>. Thus, several options are currently available and there is no established gold standard.

The literature on palliative GJ show good functional outcomes and symptoms relief in up to 70% of patients and reduced re-intervention rates, but it is associated with postoperative complications, such as delayed gastric emptying (DGE)<sup>[8,12,14,34,35]</sup>. For its part, palliative endoscopic treatment is a well-established procedure today and is considered a valid alternative for avoiding surgery. The endoscopic approach is associated with shorter length of stay (LOS), faster initial relief and shorter time to oral intake, but also with greater symptom recurrences and risk of stent migration<sup>[8,12-14,36-39]</sup>.

The current literature mixes together different etiologies, and even includes benign causes such as superior mesenteric artery syndrome, peptic ulcer stenosis, chronic pancreatitis or annular pancreas, different grades of GOO, and prophylactic and palliative treatments<sup>[40-44]</sup>. Kohan *et al.*<sup>[45]</sup> report the results of surgical palliative treatment for pancreatic cancer; but they mixed elective bypass for the treatment of symptomatic malignant GOO together with and prophylactic GJ in advanced HPB cancer patients undergoing surgery for biliary obstruction.

Table 1 shows the results of previous systematic reviews and meta-analysis comparing endoscopic duodenal stent vs GJ for the treatment of malignant GOO, including both gastric and advanced HPB cancers and other metastatic cancers. Minata *et al.*<sup>[8]</sup>, Nagaraja *et al.*<sup>[13]</sup> and Ly *et al.*<sup>[38]</sup> have demonstrated shorter LOS and faster oral intake with endoscopic palliative treatment, but lower re-intervention rates with OGJ. No differences in survival or major complications were found. Nagaraja *et al.*<sup>[13]</sup> concluded that the endoscopic approach minimizes pain, hospitalization, and physiologic stress to the patient, which are the main goals of palliation.

Decisions regarding the best therapeutic strategy for individual patients with malignant GOO due to advanced HPB cancer should be based on the performance

and medical condition, the extent of the cancer, the prognosis, their quality of life and expectancy, and the availability and likely success of each treatment option<sup>[36,46,47]</sup>.

Depending on the medical condition, one of the main factors to consider is nutritional status; thus, hypoalbuminemia is considered as a risk factor for GJ whether the disease is benign or malignant<sup>[48]</sup>. Surgeons should correct this situation if surgical palliation is the aim and at least 1-2 wk of nutritional treatment should be considered in order to decrease the risk of postoperative complications<sup>[48]</sup>. According Sasaki *et al.*<sup>[49]</sup>, poor performance status should be considered as additional risk factor.

With regard to the extent of the cancer, the presence of carcinomatosis with ascites has been reported as an independent predictive factor for poor clinical success of stent placement, without any differences in stent patency<sup>[50]</sup>.

The choice of palliative GJ or endoscopic enteral stent should consider the life expectancy of patients and the likelihood of recurrent GOO after stenting. As regards the prognosis of malignant disease, in the SUSTENT study, Jeurnink *et al.*<sup>[12]</sup>, concluded that palliative GJ is the treatment of choice in patients expected to live two months or longer, whereas stent is preferable for patients with a life expectancy below this figure. This conclusion is based on the finding that surgery was more effective than endoscopic stent after a follow-up of two months<sup>[12]</sup>. Recurrent obstruction due to tumor ingrowth into stent or stent migration has been reported in 17%-27% of patients with endoscopic stent<sup>[4,51]</sup>. Severe complications associated with stenting include bleeding and perforation and have been reported in 1.2% of cases<sup>[51]</sup>. Comparing stent types, migration rates are higher with covered stents than with uncovered ones; in contrast, uncovered stenting has higher obstruction rates<sup>[8,52,53]</sup>. In addition, some patients may suffer combined obstructive jaundice and GOO. There are several options for treatment, but biliary endoscopic stenting can pose a challenge if a duodenal stent is in place<sup>[54]</sup>; patients with stent for biliary obstruction who subsequently have an endoscopic enteral stent are at an increased risk of biliary stent dysfunction<sup>[55]</sup>. Another option is endoscopic double stenting, a combination of biliary and duodenal stent placement, where different approaches could make it possible<sup>[56]</sup>.

### Laparoscopic GJ for malignant GOO

Wilson *et al.*<sup>[57]</sup> published the first report of LGJ in two patients with malignant GOO due to advanced HPB cancer. Today, LGJ is a feasible option, and presents improved morbidity and mortality rates compared with the open surgical approach<sup>[3]</sup>.

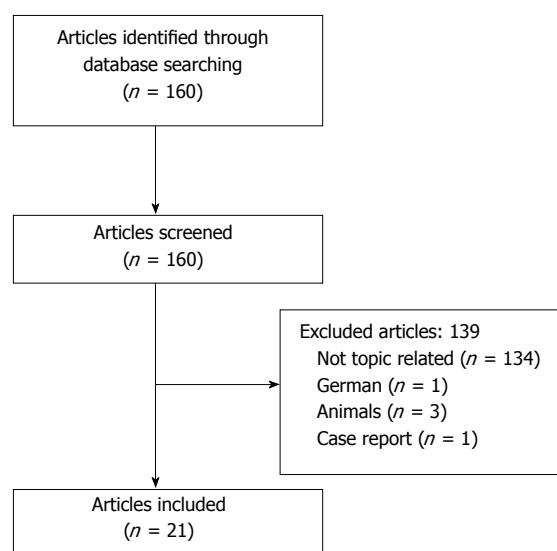
In 2007, Siddiqui *et al.*<sup>[58]</sup> designed a model for patients with malignant GOO and performed a decision analysis. They concluded that endoscopic enteral stent



**Table 1** Systematic review and meta-analysis: Stents *vs* gastrojejunostomy

Ref.	Type of study	GJ studies	Surgery	Endoscopic stent	No differences
Minata <i>et al</i> <sup>[8]</sup> , 2016	Systematic review	LGJ (Mehta 2006, Jeurnink 2010) OGJ (Jeurnink 2010, Fiori 2013)	Lower re-intervention rate	Less invasive COVERED: Higher migration UNCOVERED: Higher obstruction Shorter LOS	Technical success Complications
Nagaraja <i>et al</i> <sup>[13]</sup> , 2014	Meta-analysis	Laparoscopic GJ (Mittal 2004, Mehta 2006, Jeurnink 2007, Jeurnink 2010)			Technical and clinical outcomes
Ly <i>et al</i> <sup>[38]</sup> , 2010	Systematic review	Open GJ (Jeurnink 2007, El-Shabrawi 2006, Mehta 2006, Espinal 2006, Mejia 2006, del Piano 2005, Maetani 2005, Fiori 2004, Mittal 2004, Maetani 2004, Johnsson 2004, Wong 2002, Yim 2001) Laparoscopic GJ (Jeurnink 2007, Mehta 2006, Mittal 2004)	More major medical complications	More likely to tolerate an oral intake More likely to tolerate an oral diet earlier Shorter LOS	Survival 30 d-mortality Major complications

LOS: Length of stay; GJ: Gastrojejunostomy.

**Figure 1** Flowchart.

was a optimal strategy, associated with a 72% success rate and the lowest 1-mo mortality rate (2.1%), one of the drawbacks was recurrent duodenal obstruction, found in up to 25%. They reported a 69% success rate after LGJ (overall 1-mo mortality 2.5% and a cost increase of \$10340), and 63% success after open GJ with higher 1-mo mortality (4.5%) and more expensive treatment (a cost increase of \$12191)<sup>[58]</sup>.

Given the limited number of controlled trials of the laparoscopic approach in palliative GJ<sup>[39,59,60]</sup>, data available are insufficient to perform an analysis comparing LGJ with OGJ or endoscopic stent<sup>[38]</sup>.

We therefore performed a systematic literature review, in accordance with the PRISMA guidelines, on patients with advanced HPB malignancy who had undergone laparoscopic palliative GJ up to February 2018. The search items were the following MESH terms: [(Gastric outlet obstruction) OR (Gastric Outlet Obstructions) OR (Obstruction, Gastric Outlet) OR (Obstructions, Gastric Outlet) OR (Outlet Obstruction, Gastric) OR (Outlet Obstructions, Gastric) OR (Duodenal

obstruction) OR (Duodenal Obstructions) OR (Obstruction, Duodenal) OR (Obstructions, Duodenal)] AND [(Gastric bypass) OR (Bypass, Gastric) OR (Gastrojejunostomy) OR (Gastrojejunostomies) OR (Gastroenterostomy) OR (Gastroenterostomies)] AND [(Laparoscopy) OR (Laparoscopies) OR (Surgical Procedures, Laparoscopic) OR (Laparoscopic Surgical Procedure) OR (Procedure, Laparoscopic Surgical) OR (Procedures, Laparoscopic Surgical) OR (Surgery, Laparoscopic) OR (Laparoscopic Surgical Procedures) OR (Laparoscopic Surgery) OR (Laparoscopic Surgeries) OR (Surgeries, Laparoscopic) OR (Surgical Procedure, Laparoscopic)]. Eligibility criteria were any type of article that included patients with advanced HPB malignancy who had undergone laparoscopic palliative GJ, excluding case reports or reports of prophylactic GJ.

The articles were included or rejected based on the information in the title and summary, and in case of doubt, after reading the complete article.

Figure 1 presents a flowchart of systematic review of patients with advanced HPB malignancy who had undergone laparoscopic palliative GJ. The initial search yielded, 160 articles, but only 21 (13.12%) met the search criteria.

The outcomes and surgical techniques of LGJ for malignant GOO are displayed in Tables 2 and 3<sup>[3-5,9,15,37,39,57,60-72]</sup>. Most studies were case series (12/21)<sup>[5,9,15,57,61-64,66,69,72]</sup>, five were cohort series<sup>[3,4,37,60,68]</sup>, two case/control studies<sup>[70,71]</sup> and only two studies were randomized controlled trials (RCT)<sup>[39,67]</sup>. The studies included different etiologies for GOO, among them benign disease<sup>[66]</sup> and only nine publications recorded all patients with advanced HPB malignancy<sup>[4,5,9,61-65]</sup>. The systematic review included 495 patients, of whom 55 (11.11%) had advanced HPB cancer and had undergone LGJ. There was a mix of associated treatments for biliary obstruction, including endoscopic stent (ES), percutaneous drainage (PD), and biliary bypass (choledochojejunostomy, CJ; cholecystojejunostomy, CCJ). The results displayed in Table 2, show that there are no standardized outcomes for reporting results after

**Table 2 Systematic review of laparoscopic gastrojejunostomy for gastric obstruction due to advanced hepatobiliary cancer**

Ref.	n	Type of study	HPB Etiology	Biliary obstruction	Operating time	Perioperative morbidity	Time to initiate intake	Time to solid food	LOS	Duration of food intake	Comment
All HPB Malignancy											
Journink <i>et al</i> <sup>[60]</sup> , 2007	95	Cohort: GJ (42) vs duodenal stent (53)	GJ: All patients (laparoscopy: 10)	GJ: 17 previous treatment	ND	GJ: 4 major (hemorrhage, severe pain, cholangitis, respiratory failure); 13 minor (mild pain, wound infection, nausea and vomiting)	ND	GJ: 10.1 ± 4.8 d	GJ: 18d (4-55)	ND	
Hamade <i>et al</i> <sup>[4]</sup> , 2005	21	Cohort: laparoscopic GJ/CJ/GJ+CJ	All patients	5 biliary bypass, 8 GJ+biliary bypass	gastric bypass 75 min, GJ+CJ 130 min	1 pneumonia, 1 central line sepsis, 1 wound abscess	ND	ND	4 d (1-14)	9 patients untill death	Includes pre-treatment, profilactic and therapeutic GJ
Denley <i>et al</i> <sup>[9]</sup> , 2005	18	Case series: LGJ	All patients	ND	ND	2 reconversions, 1 leak, 1 sepsis, 1 DGE	ND	ND	6 (3-22)	15 patients untill death	
Kazanjan <i>et al</i> <sup>[5]</sup> , 2004	9	Case series: LGJ	All patients	ND	116 min (75-300)	1 DGE, 1 Cholangitis	ND	4 d (3-6)	7 d (5-18)	ND	4 patient previous stent
Alam <i>et al</i> <sup>[61]</sup> , 2003	8	Case series: LGJ	All patients	ND	135 min	Pneumonia (1)	ND	4 (2-7)	7 (5-13)	7 patients untill death	
Kuriansky <i>et al</i> <sup>[62]</sup> , 2000	12	Case series: LGJ+biliary bypass	All patients	12 CCJ	89.16 min (35-150)	2 wound infection, 1 pneumonia, 2 DGE, 1 reintervention (bleeding)	ND	ND	6.4 (5-17)	All patients untill death	
Casaccia <i>et al</i> <sup>[63]</sup> , 1999	6	Case series: LGJ	All patients	4 ES. 2 Laparoscopic CCJ	82 min (60-135)	1 Bleeding (transfusion)	ND	ND	4.5 (4-6)	ND	
Casaccia <i>et al</i> <sup>[64]</sup> , 1998	5	Case series: LGJ	All patients	4 ES. 1 laparoscopic CCJ	ND	1 Bleeding (transfusion)	ND	ND	4 (4-6)	ND	
Rhodes <i>et al</i> <sup>[65]</sup> , 1995	16	Case series: laparoscopic CCJ ± GJ (5GJ, 3 both, 9CCJ)	All patients	ND	75 min	1 DGE, 1 ictus	ND	ND	4 d (3-33)	ND	Results of the entire data series
Wilson <i>et al</i> <sup>[57]</sup> , 1992	2	Case series: LGJ	All patients	ND	120 min	None	2d	3 d, 4 d	4-5 d	1 patient untill death	
Mixed malignancies											
Zhang <i>et al</i> <sup>[66]</sup> , 2011	28	Case series: LGJ for benign/malignant disease	7 HPB malignancy	ND	170 min	2 reinterventions (anastomotic leak, trocar site hemorrhage), 2 bleeding controlled by endoscopy, 1 ileus, 5 DGE	3d	5 d	8 d (2-83)	ND	Results of the entire data series
Guzman <i>et al</i> <sup>[3]</sup> , 2009	20	Cohort: LGJ AND OGJ	Laparoscopy: 8 HPB malignancy	ND	116 min	2 DGE	ND	7 d	8 d	ND	
Navarra <i>et al</i> <sup>[67]</sup> , 2006	24	RCT: 12 LGJ vs 12 OGJ	Laparoscopy: 5 HPB malignancy	ND	150 min	None	ND	4.08 d	11 d	ND	



Mehta <i>et al</i> <sup>[39]</sup> , 2006	27	RCT: 14 LGJ <i>vs</i> 13 SEMS	ND	6 patients (ES, PD)	ND	2 bleeding, 1 wound infection, 1 pneumonia, 3 DGE. 3 mortality (sepsis, pneumonia, carcinomatosis)	ND	ND	11.4 D	ND
Al-Rashedy <i>et al</i> <sup>[68]</sup> , 2005	26	Cohort: LGJ and OGJ	Laparoscopy: 7 HPB malignancy	ND	ND	2 (13.3%)	ND	ND	3 (3-8)	ND
Khan <i>et al</i> <sup>[69]</sup> , 2005	19	Case series: laparoscopic CCJ $\pm$ GJ (16 GJ, 1 CCJ, 2 both)	7 HPB malignancy	2 CCJ	164 min single bypass, 245 min double bypass	ND	3d	ND	ND	ND
Mittal <i>et al</i> <sup>[37]</sup> , 2004	56	Cohort: 16 OGJ, 14 LGJ, 16 ES.	Laparoscopy: 9 HPB malignancy	None patient	ND	4 pneumonia, 1 ileus, 1 wound infection	ND	5 d (4-8)	13.5 d (6-36) (after procedure 7d)	ND
Bergamaschi <i>et al</i> <sup>[70]</sup> , 2002	55	Case/control: antiperistaltic <i>vs</i> isoperistaltic LGJ	AP-LGJ: 29 HPB malignancy, IP-LGJ 14 HPB malignancy	ND	100min (AP) <i>vs</i> 99min (IP)	14 (II: 1, III: 9, IV: 3)	ND	5.1d (AP) <i>vs</i> 5.3 d (IP)	8.4 d (AP) <i>vs</i> 8.1 d (IP)	ND
Bergamaschi <i>et al</i> <sup>[71]</sup> , 1998	22	Case / control: OGJ (prophylactic and GOO treatment) <i>vs</i> LGJ (GOO treatment)	Laparoscopy: 9 HPB malignancy	1 ES, 3 PD	94 min	Pneumonia (1), SSI (1), delayed gastric emptying (1)	ND	8.4 (media)	18.4 (media)	ND
Brune <i>et al</i> <sup>[15]</sup> , 1997	16	Case series: LGJ	13 HPB malignancy	ES/PD	126 min (70-210)	1 reintervention (hemorrhage), 3 delayed gastric emptying	ND	ND	4.7 (2-8)	16 patients untill death
Nagy <i>et al</i> <sup>[72]</sup> , 1995	10	Case series: LGJ	9 HPB malignancy	8 ES/1 PD/ 2 simultaneous CJ	ND	2 reconversions, 1 CCF, 1 pneumonia, 1 CD infection	ND	10 d (4-15)	ND	All patients untill death

HPB: Hepatopancreatic-biliary; LOS: Length of stay; LGJ: Laparoscopic gastrojejunostomy; OGJ: Open gastrojejunostomy; ND: Not described; GOO: Gastric outlet obstruction; CCJ: Cholecystojejunostomy; CJ: Choledochojejunostomy; ES: Endoscopic stent; PD: Percutaneous drainage; AP: Antiperistaltic; IP: Isoperistaltic; CCF: Congestive cardiac failure; RCT: Randomized controlled trial; CD: *Clostridium difficile*; DGE: Delayed gastric emptying.

LGJ. Regarding the surgical technique (Table 3), most LGJ were antecolic-isoperistaltic stapler plus manual suture, but there was no standardized approach for LGJ.

### Personal series: palliative laparoscopic gastrojejunostomy

We also performed a retrospective study at the Department of General Surgery and Digestive of the University Hospital of Guadalajara. The period analyzed was January 2009-March 2018. We included all consecutive patients who underwent laparoscopic palliative GJ for malignant GOO due to advanced HPB cancer, excluding prophylactic GJ and OGJ. All patients had histological diagnosis of HPB cancer. For this purpose, the Mambrino XXI® electronic medical history was used.

Our results are shown in Table 4. All GJ were performed by the same surgeon using the same approach (IP, antecolic and stapler plus manual suture).

Three patients had previous biliary stent, and another patient needed a percutaneous biliary stent after laparoscopic GJ due to obstructive jaundice. The clinical success rate was 100%, with all patients maintaining oral intake until death. The median time from surgery to hospital discharge was 12 d (range 5-13), excluding hospital stay prior surgery attributable to GOO. One patient died due to sepsis caused by a hepatic abscess on postoperative (PO) day 78, and another died due to carcinomatosis and tumor progression on PO day 82. Median overall-survival was 214.67 d.

### Other surgical options for malignant GOO

Several surgical procedures for GJ have been reported since Devine *et al*'s first description in 1925, which introduced a procedure consisting of transection of the stomach and anastomosis between the jejunal loop and the proximal stump of the stomach<sup>[73]</sup>. But GJ may be not fully effective due to of DGE or tumor bleeding;

**Table 3** Systematic review of laparoscopic gastrojejunostomy for gastric obstruction due to advanced hepatobiliary cancer: Surgical technique

Ref.	Peristalsis	Location	Type
All HPB malignancy			
Jeurnink <i>et al</i> <sup>[60]</sup> , 2007	ND	Antecolic	Completely stapler
Hamade <i>et al</i> <sup>[4]</sup> , 2005	IP	Antecolic	Stapler + manual suture
Denley <i>et al</i> <sup>[9]</sup> , 2005	IP	Antecolic	Stapler + manual suture
Kazanjian <i>et al</i> <sup>[5]</sup> , 2004	ND	Antecolic	Completely stapler
Alam <i>et al</i> <sup>[61]</sup> , 2003	IP	ND	Completely stapler
Kuriansky <i>et al</i> <sup>[62]</sup> , 2000	ND	Retrocolic	Completely stapler
Casaccia <i>et al</i> <sup>[63]</sup> , 1999	ND	Antecolic	Completely stapler/stapler+ manual suture
Casaccia <i>et al</i> <sup>[64]</sup> , 1998	ND	Antecolic	Completely stapler/stapler+ manual suture
Rhodes <i>et al</i> <sup>[65]</sup> , 1995	ND	ND	Stapler + manual suture
Wilson <i>et al</i> <sup>[57]</sup> , 1992	ND	Antecolic	Stapler + manual suture
Mixed malignancies			
Zhang <i>et al</i> <sup>[66]</sup> , 2011	ND	Antecolic (majority)	Stapler + manual suture
Guzman <i>et al</i> <sup>[3]</sup> , 2009	ND	ND	Stapler + manual suture
Navarra <i>et al</i> <sup>[67]</sup> , 2006	IP	Antecolic	Stapler + manual suture
Mehta <i>et al</i> <sup>[39]</sup> , 2006	ND	Antecolic	Stapler + manual suture
Al-Rashedy <i>et al</i> <sup>[68]</sup> , 2005	ND	Antecolic	Hand-sutured or stapler
Khan <i>et al</i> <sup>[69]</sup> , 2005	ND	Antecolic	Stapler + manual suture
Mittal <i>et al</i> <sup>[37]</sup> , 2004	ND	ND	ND
Bergamaschi <i>et al</i> <sup>[70]</sup> , 2002	29 AP vs 14 IP	Antecolic	17 completely stapled/38 stapler+ manual suture
Bergamaschi <i>et al</i> <sup>[71]</sup> , 1998	ND	ND	7 completely stapled/2 stapler+ manual suture
Brune <i>et al</i> <sup>[15]</sup> , 1997	IP	Antecolic	Stapler + manual suture
Nagy <i>et al</i> <sup>[72]</sup> , 1995	ND	Antecolic	Stapler + manual suture

IP: Isoperistaltic; AP: Antiperistaltic; ND: Not described.

**Table 4** Personal serie of laparoscopic gastrojejunostomy

Age/sex	Biliary obstruction	Surgical technique	Clinical success	Time to initiate intake	Surgery-discharge (d)	90-d morbidity	Duration of food intake	Survival (d)
87/F	No	IP antecolic, stapler + manual suture	Yes	4	12	CD infection	Until death	402
76/M	Biliary stent	IP antecolic, stapler + manual suture	Yes	3	12	No	Until death	228
91/F	No	IP antecolic, stapler + manual suture	Yes	1	5	No	Until death	278
78/F	No	IP antecolic, stapler + manual suture	Yes	3	10	Readmission: Sepsis due to hepatic abscess (death)	78	78
68/F	Biliary stent	IP antecolic, stapler + manual suture	Yes	3	12	Readmission: Intestinal obstruction due to carcinomatosis (death)	82	82
76/M	Biliary stent	IP antecolic, stapler + manual suture	Yes	3	13	Catheter-related bacteriemia. Readmission: Biliary stent due to jaundice.	Until death	220
76/F	No	IP antecolic, stapler + manual suture	Yes	3	5	No	Until death	ND

M: Male; F: Female; IP: Isoperistaltic; CD: *Clostridium difficile*; ND: Not described; LOS: Length of stay.

so a modified Devine procedure has been developed, in which the stomach is partially divided into proximal and distal parts, and the proximal part of the stomach is anastomosed to the proximal part of the jejunum<sup>[74,75]</sup>. This technique, stomach-partitioning GJ (SP-GJ), minimizes contact between food and the tumor and allows endoscopic examination<sup>[74]</sup>. The first laparoscopic approach for SP-GJ was described by Matsumoto *et al*<sup>[76]</sup> in 2005. This surgical technique is associated with lower incidence of bleeding and delayed gastric emptying, with no increase in anastomotic leakage<sup>[74-78]</sup>.

Other surgical approaches reported in the literature

for the management of malignant GOO include natural orifice transumbilical surgery<sup>[79]</sup> or a laparoscopic-assisted approach for a circular mechanical GJ, in which the proximal jejunum is exteriorized by laparoscopy via an epigastric trocar-site incision<sup>[80]</sup>.

#### Novel endoscopic approaches for malignant GOO

EUS-gastroenteroanastomosis (EUS-GE) was first described by Fritscher-Ravens *et al*<sup>[81,82]</sup> in 2002. It is produced by anatomical puncture from the stomach into the third part of the duodenum (-EUS-guided gastroduodenostomy), or into the jejunum (EUS-guided

**Table 5** Technical options for gastric outlet obstruction: advantages and disadvantages

Procedure	Advantages	Disadvantages
Open GJ	Bypass of tumor Established surgical procedure Lower re-intervention rate Good long-term results	Most invasive procedure Longer LOS Nutritional status Critically ill patients
Laparoscopic GJ	Bypass of tumor Lower re-intervention rate Established surgical procedure Less invasive than open GJ Good long-term results	Invasive procedure Longer LOS Nutritional status Critically ill patients
Endoscopic enteral stent	Short procedure time Established endoscopic procedure Broad indication regardless patient condition Short LOS	Stent migration Patency
EUS-GJ	Good short-term results Bypass of tumor Short procedure time Short LOS Less invasive	Special device Non-establish endoscopic procedure Serious adverse events

EUS-GJ: Endoscopic ultrasound gastrojejunostomy; GJ: Gastrojejunostomy; LOS: Length of stay.

gastrojejunostomy)<sup>[83]</sup>.

This new EUS technique involves the placement of a lumen-apposing metal stent (LAMS). Data regarding its use are limited<sup>[84-87]</sup>. In 2017, Pérez-Miranda *et al.*<sup>[87]</sup> reported the results of a multicenter cohort study comparing EUS-GJ and LGJ. All patients in the EUS-GJ group had symptomatic GOO, compared with only 34% of patients in LGJ group. The clinical success rates in the two groups were 84% vs 90%, LOS was 9.4 d vs 8.9 d and adverse events were 12% vs 41%, with the EUS-GJ group presenting better results in all cases. This is a new EUS technique and it should be reserved for use at experienced centers.

## CONCLUSION

Palliative treatment of GOO due to advanced HPB cancer may improve QOL and resolve symptoms. Both a non-operative endoscopic approach and surgical treatment are available (Table 5) and an estimation of probable survival is essential for the choice of treatment. Evaluation of the patient and multidisciplinary expertise are required to select the appropriate approach.

Stent is usually preferred in patients with poor general condition or short life expectancy. LGJ is a feasible, safe and efficient technical option. Given the limited studies and the difficulty of performing prospective controlled trials due to patient heterogeneity, no study can cover all the complexities of malignant GOO and more outcome data are needed. Prospective clinical trials with adequate sample sizes comparing different approaches size are warranted.

## REFERENCES

- Gentileschi P, Kini S, Gagner M. Palliative laparoscopic hepatico- and gastrojejunostomy for advanced pancreatic cancer. *JSL* 2002; **6**: 331-338 [PMID: 12500832]
- Gurusamy KS, Kumar S, Davidson BR. Prophylactic gastrojejunostomy for unresectable periampullary carcinoma. *Cochrane Database Syst Rev* 2013; **2**: CD008533 [PMID: 23450583 DOI: 10.1002/14651858.CD008533.pub3]
- Guzman EA, Dagens A, Bening L, Pigazzi A. Laparoscopic gastrojejunostomy in patients with obstruction of the gastric outlet secondary to advanced malignancies. *Am Surg* 2009; **75**: 129-132 [PMID: 19280805]
- Hamade AM, Al-Bahrani AZ, Ower A, Hamoodi AA, Abid GH, Bani Hani OI, O'Shea S, Lee SH, Ammori BJ. Therapeutic, prophylactic, and pre-resection applications of laparoscopic gastric and biliary bypass for patients with periampullary malignancy. *Surg Endosc* 2005; **19**: 1333-1340 [PMID: 16021372 DOI: 10.1007/s00464-004-2282-4]
- Kazanjan KK, Reber HA, Hines OJ. Laparoscopic gastrojejunostomy for gastric outlet obstruction in pancreatic cancer. *Am Surg* 2004; **70**: 910-913 [PMID: 15529849]
- Bahra M, Jacob D. Surgical palliation of advanced pancreatic cancer. *Recent Results Cancer Res* 2008; **177**: 111-120 [PMID: 18084953 DOI: 10.1007/978-3-540-71279-4\_13]
- Moss AC, Morris E, Mac Mathuna P. Palliative biliary stents for obstructing pancreatic carcinoma. *Cochrane Database Syst Rev* 2006; **2**: CD004200 [PMID: 16625598 DOI: 10.1002/14651858.CD004200.pub4]
- Minata MK, Bernardo WM, Rocha RS, Morita FH, Aquino JC, Cheng S, Zilberstein B, Sakai P, de Moura EG. Stents and surgical interventions in the palliation of gastric outlet obstruction: a systematic review. *Endosc Int Open* 2016; **4**: E1158-E1170 [PMID: 27857965 DOI: 10.1055/s-0042-115935]
- Denley SM, Moug SJ, Carter CR, McKay CJ. The outcome of laparoscopic gastrojejunostomy in malignant gastric outlet obstruction. *Int J Gastrointest Cancer* 2005; **35**: 165-169 [PMID: 16110117 DOI: 10.1385/IJGC:35:3:165]
- Del Piano M, Ballarè M, Montino F, Todesco A, Orsello M, Magnani C, Garello E. Endoscopy or surgery for malignant GI outlet obstruction? *Gastrointest Endosc* 2005; **61**: 421-426 [PMID: 15758914 DOI: 10.1016/S0016-5107(04)02757-9]
- Watanapa P, Williamson RC. Surgical palliation for pancreatic cancer: developments during the past two decades. *Br J Surg* 1992; **79**: 8-20 [PMID: 1371087 DOI: 10.1002/bjs.1800790105]
- Jeurnink SM, Steyerberg EW, van Hooft JE, van Eijck CH, Schwartz MP, Vleggaar FP, Kuipers EJ, Siersema PD; Dutch SUSTENT Study Group. Surgical gastrojejunostomy or endoscopic stent placement for the palliation of malignant gastric outlet obstruction (SUSTENT study): a multicenter randomized trial.

- Gastrointest Endosc* 2010; **71**: 490-499 [PMID: 20003966 DOI: 10.1016/j.gie.2009.09.042]
- 13 **Nagaraja V**, Eslick GD, Cox MR. Endoscopic stenting versus operative gastrojejunostomy for malignant gastric outlet obstruction-a systematic review and meta-analysis of randomized and non-randomized trials. *J Gastrointest Oncol* 2014; **5**: 92-98 [PMID: 24772336]
  - 14 **Yoshida Y**, Fukutomi A, Tanaka M, Sugiura T, Kawata N, Kawai S, Kito Y, Hamauchi S, Tsushima T, Yokota T, Todaka A, Machida N, Yamazaki K, Onozawa Y, Yasui H. Gastrojejunostomy versus duodenal stent placement for gastric outlet obstruction in patients with unresectable pancreatic cancer. *Pancreatol* 2017; **17**: 983-989 [PMID: 29066391 DOI: 10.1016/j.pan.2017.09.011]
  - 15 **Brune IB**, Feussner H, Neuhaus H, Classen M, Siewert JR. Laparoscopic gastrojejunostomy and endoscopic biliary stent placement for palliation of incurable gastric outlet obstruction with cholestasis. *Surg Endosc* 1997; **11**: 834-837 [PMID: 9266646 DOI: 10.1007/s004649900465]
  - 16 **Engelken FJ**, Bettschart V, Rahman MQ, Parks RW, Garden OJ. Prognostic factors in the palliation of pancreatic cancer. *Eur J Surg Oncol* 2003; **29**: 368-373 [PMID: 12711291 DOI: 10.1053/ejso.2002.1405]
  - 17 **Michelassi F**, Erroi F, Dawson PJ, Pietrabissa A, Noda S, Handcock M, Block GE. Experience with 647 consecutive tumors of the duodenum, ampulla, head of the pancreas, and distal common bile duct. *Ann Surg* 1989; **210**: 544-554; discussion 554-556 [PMID: 2679459 DOI: 10.1097/0000658-198910000-00015]
  - 18 **Smith RA**, Bosonnet L, Ghaneh P, Sutton R, Evans J, Healey P, Garvey C, Hughes M, Raraty M, Campbell F, Neoptolemos JP. The platelet-lymphocyte ratio improves the predictive value of serum CA19-9 levels in determining patient selection for staging laparoscopy in suspected periampullary cancer. *Surgery* 2008; **143**: 658-666 [PMID: 18436014 DOI: 10.1016/j.surg.2007.12.014]
  - 19 **Mayo SC**, Austin DF, Sheppard BC, Mori M, Shipley DK, Billingsley KG. Evolving preoperative evaluation of patients with pancreatic cancer: does laparoscopy have a role in the current era? *J Am Coll Surg* 2009; **208**: 87-95 [PMID: 19228509 DOI: 10.1016/j.jamcollsurg.2008.10.014]
  - 20 **Wong YT**, Brams DM, Munson L, Sanders L, Heiss F, Chase M, Birkett DH. Gastric outlet obstruction secondary to pancreatic cancer: surgical vs endoscopic palliation. *Surg Endosc* 2002; **16**: 310-312 [PMID: 11967685 DOI: 10.1007/s00464-001-9061-2]
  - 21 **Lillemoe KD**, Cameron JL, Hardacre JM, Sohn TA, Sauter PK, Coleman J, Pitt HA, Yeo CJ. Is prophylactic gastrojejunostomy indicated for unresectable periampullary cancer? A prospective randomized trial. *Ann Surg* 1999; **230**: 322-328; discussion 328-330 [PMID: 10493479 DOI: 10.1097/0000658-199909000-00005]
  - 22 **Van Heek NT**, De Castro SM, van Eijck CH, van Geenen RC, Hesselink EJ, Breslau PJ, Tran TC, Kazemier G, Visser MR, Busch OR, Obertop H, Goema DJ. The need for a prophylactic gastrojejunostomy for unresectable periampullary cancer: a prospective randomized multicenter trial with special focus on assessment of quality of life. *Ann Surg* 2003; **238**: 894-902; discussion 902-5 [PMID: 14631226 DOI: 10.1097/01.sla.0000098617.21801.95]
  - 23 **Topazian M**, Ring E, Grendell J. Palliation of obstructing gastric cancer with steel mesh, self-expanding endoprotheses. *Gastrointest Endosc* 1992; **38**: 58-60 [PMID: 1377147 DOI: 10.1016/S0016-5107(92)70334-4]
  - 24 **Solt J**, Papp Z. Strecker stent implantation in malignant gastric outlet stenosis. *Gastrointest Endosc* 1993; **39**: 442-444 [PMID: 7685724 DOI: 10.1016/S0016-5107(93)70126-1]
  - 25 **Song HY**, Yang DH, Kuh JH, Choi KC. Obstructing cancer of the gastric antrum: palliative treatment with covered metallic stents. *Radiology* 1993; **187**: 357-358 [PMID: 7682722 DOI: 10.1148/radiology.187.2.7682722]
  - 26 **Maetani I**, Ogawa S, Hoshi H, Sato M, Yoshioka H, Igarashi Y, Sakai Y. Self-expanding metal stents for palliative treatment of malignant biliary and duodenal stenoses. *Endoscopy* 1994; **26**: 701-704 [PMID: 7532126 DOI: 10.1055/s-2007-1009069]
  - 27 **Strecker EP**, Boos I, Husfeldt KJ. Malignant duodenal stenosis: palliation with peroral implantation of a self-expanding nitinol stent. *Radiology* 1995; **196**: 349-351 [PMID: 7542395 DOI: 10.1148/radiology.196.2.7542395]
  - 28 **Maetani I**, Inoue H, Sato M, Ohashi S, Igarashi Y, Sakai Y. Peroral insertion techniques of self-expanding metal stents for malignant gastric outlet and duodenal stenoses. *Gastrointest Endosc* 1996; **44**: 468-471 [PMID: 8905371 DOI: 10.1016/S0016-5107(96)70102-5]
  - 29 **Feretis C**, Benakis P, Dimopoulos C, Manouras A, Tsimbloulis B, Apostolidis N. Duodenal obstruction caused by pancreatic head carcinoma: palliation with self-expandable endoprotheses. *Gastrointest Endosc* 1997; **46**: 161-165 [PMID: 9283868 DOI: 10.1016/S0016-5107(97)70066-X]
  - 30 **Nevitt AW**, Vida F, Kozarek RA, Traverso LW, Raltz SL. Expandable metallic prostheses for malignant obstructions of gastric outlet and proximal small bowel. *Gastrointest Endosc* 1998; **47**: 271-276 [PMID: 9540882 DOI: 10.1016/S0016-5107(98)70326-8]
  - 31 **Yates MR 3rd**, Morgan DE, Baron TH. Palliation of malignant gastric and small intestinal strictures with self-expandable metal stents. *Endoscopy* 1998; **30**: 266-272 [PMID: 9615875 DOI: 10.1055/s-2007-1001253]
  - 32 **Soetikno RM**, Carr-Locke DL. Expandable metal stents for gastric-outlet, duodenal, and small intestinal obstruction. *Gastrointest Endosc Clin N Am* 1999; **9**: 447-458 [PMID: 10388860]
  - 33 **Park HS**, Do YS, Suh SW, Choo SW, Lim HK, Kim SH, Shim YM, Park KC, Choo IW. Upper gastrointestinal tract malignant obstruction: initial results of palliation with a flexible covered stent. *Radiology* 1999; **210**: 865-870 [PMID: 10207494 DOI: 10.1148/radiology.210.3.r99mr13865]
  - 34 **Fiori E**, Lamazza A, Volpino P, Burza A, Paparelli C, Cavallaro G, Schillaci A, Cangemi V. Palliative management of malignant antropyloric strictures. Gastroenterostomy vs. endoscopic stenting. A randomized prospective trial. *Anticancer Res* 2004; **24**: 269-271 [PMID: 15015607]
  - 35 **Maetani I**, Tada T, Ukita T, Inoue H, Sakai Y, Nagao J. Comparison of duodenal stent placement with surgical gastrojejunostomy for palliation in patients with duodenal obstructions caused by pancreaticobiliary malignancies. *Endoscopy* 2004; **36**: 73-78 [PMID: 14722859 DOI: 10.1055/s-2004-814123]
  - 36 **Potz BA**, Miner TJ. Surgical palliation of gastric outlet obstruction in advanced malignancy. *World J Gastrointest Surg* 2016; **8**: 545-555 [PMID: 27648158 DOI: 10.4240/wjgs.v8.i8.545]
  - 37 **Mittal A**, Windsor J, Woodfield J, Casey P, Lane M. Matched study of three methods for palliation of malignant pyloroduodenal obstruction. *Br J Surg* 2004; **91**: 205-209 [PMID: 14760669 DOI: 10.1002/bjs.4396]
  - 38 **Ly J**, O'Grady G, Mittal A, Plank L, Windsor JA. A systematic review of methods to palliate malignant gastric outlet obstruction. *Surg Endosc* 2010; **24**: 290-297 [PMID: 19551436 DOI: 10.1007/s00464-009-0577-1]
  - 39 **Mehta S**, Hindmarsh A, Cheong E, Cockburn J, Saada J, Tighe R, Lewis MP, Rhodes M. Prospective randomized trial of laparoscopic gastrojejunostomy versus duodenal stenting for malignant gastric outflow obstruction. *Surg Endosc* 2006; **20**: 239-242 [PMID: 16362479 DOI: 10.1007/s00464-005-0130-9]
  - 40 **Levenick JM**, Gordon SR, Sutton JE, Suriawinata A, Gardner TB. A comprehensive, case-based review of groove pancreatitis. *Pancreas* 2009; **38**: e169-e175 [PMID: 19629001 DOI: 10.1097/MPA.0b013e3181ac73f1]
  - 41 **Kirby GC**, Faulconer ER, Robinson SJ, Perry A, Downing R. Superior mesenteric artery syndrome: a single centre experience of laparoscopic duodenojejunostomy as the operation of choice. *Ann R Coll Surg Engl* 2017; **99**: 472-475 [PMID: 28660836 DOI: 10.1308/rcsann.2017.0063]
  - 42 **Pottorf BJ**, Husain FA, Hollis HW Jr, Lin E. Laparoscopic management of duodenal obstruction resulting from superior mesenteric artery syndrome. *JAMA Surg* 2014; **149**: 1319-1322 [PMID: 25353279 DOI: 10.1001/jamasurg.2014.1409]
  - 43 **Zilberstein B**, Sorbello MP, Orso IR, Cecconello I. Laparoscopic



- duodenal-jejunal bypass for the treatment of duodenal obstruction caused by annular pancreas: description of a surgical technique. *Surg Laparosc Endosc Percutan Tech* 2011; **21**: e60-e64 [PMID: 21471781 DOI: 10.1097/SLE.0b013e318205514d]
- 44 **De Ugarte DA**, Dutton EP, Hiyama DT. Annular pancreas in the adult: management with laparoscopic gastrojejunostomy. *Am Surg* 2006; **72**: 71-73 [PMID: 16494188]
- 45 **Kohan G**, Ocampo CG, Zandalazini HI, Klappenbach R, Yazzi F, Ditulio O, Coturel A, Canullán C, Porras LT, Rodríguez JA. Laparoscopic hepaticojejunostomy and gastrojejunostomy for palliative treatment of pancreatic head cancer in 48 patients. *Surg Endosc* 2015; **29**: 1970-1975 [PMID: 25303913 DOI: 10.1007/s00464-014-3894-y]
- 46 **Miner TJ**. Palliative surgery for advanced cancer: lessons learned in patient selection and outcome assessment. *Am J Clin Oncol* 2005; **28**: 411-414 [PMID: 16062085 DOI: 10.1097/01.coc.0000158489.82482.2b]
- 47 **Miner TJ**, Cohen J, Charpentier K, McPhillips J, Marvell L, Cioffi WG. The palliative triangle: improved patient selection and outcomes associated with palliative operations. *Arch Surg* 2011; **146**: 517-522 [PMID: 21576604 DOI: 10.1001/archsurg.2011.92]
- 48 **Poulsen M**, Trezza M, Atimash GH, Sorensen LT, Kallehave F, Hemmingsen U, Jorgensen LN. Risk factors for morbidity and mortality following gastroenterostomy. *J Gastrointest Surg* 2009; **13**: 1238-1244 [PMID: 19399561 DOI: 10.1007/s11605-009-0888-5]
- 49 **Sasaki T**, Isayama H, Nakai Y, Togawa O, Kogure H, Kawakubo K, Mizuno S, Yashima Y, Ito Y, Yamamoto N, Sasahira N, Hirano K, Tsujino T, Toda N, Tada M, Omata M, Koike K. Predictive factors of solid food intake in patients with malignant gastric outlet obstruction receiving self-expandable metallic stents for palliation. *Dig Endosc* 2012; **24**: 226-230 [PMID: 22725106 DOI: 10.1111/j.1443-1661.2011.01208.x]
- 50 **Jeon HH**, Park CH, Park JC, Shim CN, Kim S, Lee HJ, Lee H, Shin SK, Lee SK, Lee YC. Carcinomatosis matters: clinical outcomes and prognostic factors for clinical success of stent placement in malignant gastric outlet obstruction. *Surg Endosc* 2014; **28**: 988-995 [PMID: 24185750 DOI: 10.1007/s00464-013-3268-x]
- 51 **Dormann A**, Meisner S, Verin N, Wenk Lang A. Self-expanding metal stents for gastroduodenal malignancies: systematic review of their clinical effectiveness. *Endoscopy* 2004; **36**: 543-550 [PMID: 15202052 DOI: 10.1055/s-2004-814434]
- 52 **Chandrasegaram MD**, Eslick GD, Mansfield CO, Liem H, Richardson M, Ahmed S, Cox MR. Endoscopic stenting versus operative gastrojejunostomy for malignant gastric outlet obstruction. *Surg Endosc* 2012; **26**: 323-329 [PMID: 21898024 DOI: 10.1007/s00464-011-1870-3]
- 53 **Hamada T**, Nakai Y, Isayama H, Sasaki T, Kogure H, Kawakubo K, Sasahira N, Yamamoto N, Togawa O, Mizuno S, Ito Y, Hirano K, Toda N, Tada M, Koike K. Duodenal metal stent placement is a risk factor for biliary metal stent dysfunction: an analysis using a time-dependent covariate. *Surg Endosc* 2013; **27**: 1243-1248 [PMID: 23073685 DOI: 10.1007/s00464-012-2585-9]
- 54 **Woo SM**, Kim DH, Lee WJ, Park KW, Park SJ, Han SS, Kim TH, Koh YH, Kim HB, Hong EK. Comparison of uncovered and covered stents for the treatment of malignant duodenal obstruction caused by pancreaticobiliary cancer. *Surg Endosc* 2013; **27**: 2031-2039 [PMID: 23288317 DOI: 10.1007/s00464-012-2705-6]
- 55 **Hamada T**, Hakuta R, Takahara N, Sasaki T, Nakai Y, Isayama H, Koike K. Covered versus uncovered metal stents for malignant gastric outlet obstruction: Systematic review and meta-analysis. *Dig Endosc* 2017; **29**: 259-271 [PMID: 27997723 DOI: 10.1111/den.12786]
- 56 **Nakai Y**, Hamada T, Isayama H, Itoi T, Koike K. Endoscopic management of combined malignant biliary and gastric outlet obstruction. *Dig Endosc* 2017; **29**: 16-25 [PMID: 27552727 DOI: 10.1111/den.12729]
- 57 **Wilson RG**, Varma JS. Laparoscopic gastroenterostomy for malignant duodenal obstruction. *Br J Surg* 1992; **79**: 1348 [PMID: 1486437 DOI: 10.1002/bjs.1800791235]
- 58 **Siddiqui A**, Spechler SJ, Huerta S. Surgical bypass versus endoscopic stenting for malignant gastroduodenal obstruction: a decision analysis. *Dig Dis Sci* 2007; **52**: 276-281 [PMID: 17160470 DOI: 10.1007/s10620-006-9536-z]
- 59 **Fiori E**, Lamazza A, Demasi E, Decesare A, Schillaci A, Sterpetti AV. Endoscopic stenting for gastric outlet obstruction in patients with unresectable antro pyloric cancer. Systematic review of the literature and final results of a prospective study. The point of view of a surgical group. *Am J Surg* 2013; **206**: 210-217 [PMID: 23735668 DOI: 10.1016/j.amjsurg.2012.08.018]
- 60 **Jeurnink SM**, Steyerberg EW, Hof Gv, van Eijck CH, Kuipers EJ, Siersema PD. Gastrojejunostomy versus stent placement in patients with malignant gastric outlet obstruction: a comparison in 95 patients. *J Surg Oncol* 2007; **96**: 389-396 [PMID: 17474082 DOI: 10.1002/jso.20828]
- 61 **Alam TA**, Baines M, Parker MC. The management of gastric outlet obstruction secondary to inoperable cancer. *Surg Endosc* 2003; **17**: 320-323 [PMID: 12384765 DOI: 10.1007/s00464-001-9197-0]
- 62 **Kuriansky J**, Sáenz A, Astudillo E, Cardona V, Fernández-Cruz L. Simultaneous laparoscopic biliary and retrocolic gastric bypass in patients with unresectable carcinoma of the pancreas. *Surg Endosc* 2000; **14**: 179-181 [PMID: 10656956 DOI: 10.1007/s004649900095]
- 63 **Casaccia M**, Diviacco P, Molinello P, Danovaro L, Casaccia M. Laparoscopic palliation of unresectable pancreatic cancers: preliminary results. *Eur J Surg* 1999; **165**: 556-559 [PMID: 10433139 DOI: 10.1080/110241599750006451]
- 64 **Casaccia M**, Diviacco P, Molinello P, Danovaro L, Casaccia M. Laparoscopic gastrojejunostomy in the palliation of pancreatic cancer: reflections on the preliminary results. *Surg Laparosc Endosc* 1998; **8**: 331-334 [PMID: 9799138 DOI: 10.1097/00019509-199810000-00001]
- 65 **Rhodes M**, Nathanson L, Fielding G. Laparoscopic biliary and gastric bypass: a useful adjunct in the treatment of carcinoma of the pancreas. *Gut* 1995; **36**: 778-780 [PMID: 7541010 DOI: 10.1136/gut.36.5.778]
- 66 **Zhang LP**, Tabrizian P, Nguyen S, Telem D, Divino C. Laparoscopic gastrojejunostomy for the treatment of gastric outlet obstruction. *JSLs* 2011; **15**: 169-173 [PMID: 21902969 DOI: 10.4293/108680811X13022985132074]
- 67 **Navarra G**, Musolino C, Venneri A, De Marco ML, Bartolotta M. Palliative antecolic isoperistaltic gastrojejunostomy: a randomized controlled trial comparing open and laparoscopic approaches. *Surg Endosc* 2006; **20**: 1831-1834 [PMID: 17063298 DOI: 10.1007/s00464-005-0454-5]
- 68 **Al-Rashedy M**, Dadibhai M, Shareif A, Khandelwal MI, Ballester P, Abid G, McCloy RF, Ammori BJ. Laparoscopic gastric bypass for gastric outlet obstruction is associated with smoother, faster recovery and shorter hospital stay compared with open surgery. *J Hepatobiliary Pancreat Surg* 2005; **12**: 474-478 [PMID: 16365822 DOI: 10.1007/s00534-005-1013-0]
- 69 **Khan AZ**, Miles WF, Singh KK. Initial experience with laparoscopic bypass for upper gastrointestinal malignancy: a new option for palliation of patients with advanced upper gastrointestinal tumors. *J Laparoendosc Adv Surg Tech A* 2005; **15**: 374-378 [PMID: 16108739 DOI: 10.1089/lap.2005.15.374]
- 70 **Bergamaschi R**, Arnaud JP, Mårvik R, Myrvold HE. Laparoscopic antiperistaltic versus isoperistaltic gastrojejunostomy for palliation of gastric outlet obstruction in advanced cancer. *Surg Laparosc Endosc Percutan Tech* 2002; **12**: 393-397 [PMID: 12496544 DOI: 10.1097/00129689-200212000-00002]
- 71 **Bergamaschi R**, Mårvik R, Thoresen JE, Ystgaard B, Johnsen G, Myrvold HE. Open versus laparoscopic gastrojejunostomy for palliation in advanced pancreatic cancer. *Surg Laparosc Endosc* 1998; **8**: 92-96 [PMID: 9566559 DOI: 10.1097/00019509-19980400-00002]
- 72 **Nagy A**, Brosseuk D, Hemming A, Scudamore C, Mamazza J. Laparoscopic gastroenterostomy for duodenal obstruction. *Am J Surg* 1995; **169**: 539-542 [PMID: 7538268 DOI: 10.1016/S0002-

- 9610(99)80213-X]
- 73 **Devine HB**. Basic principles and supreme difficulties in gastric surgery. *Surg Gynecol obstet* 1925; **40**: 1-16
- 74 **Schantz SP**, Schickler W, Evans TK, Coffey RJ. Palliative gastroenterostomy for pancreatic cancer. *Am J Surg* 1989; **76**: 793-796
- 75 **Kaminishi M**, Yamaguchi H, Shimizu N, Nomura S, Yoshikawa A, Hashimoto M, Sakai S, Oohara T. Stomach-partitioning gastrojejunostomy for unresectable gastric carcinoma. *Arch Surg* 1997; **132**: 184-187 [PMID: 9041924 DOI: 10.1001/archsurg.1997.01430260082018]
- 76 **Matsumoto T**, Izumi K, Shiromizu A, Shibata K, Ohta M, Kitano S. Laparoscopic gastric partitioning gastrojejunostomy for an unresectable duodenal malignant tumor. *J Minim Access Surg* 2005; **1**: 129-132 [PMID: 21188010 DOI: 10.4103/0972-9941.18997]
- 77 **Kushibiki T**, Ebihara Y, Hontani K, Tanaka K, Nakanishi Y, Asano T, Noji T, Kurashima Y, Murakami S, Nakamura T, Tsuchikawa T, Okamura K, Shichinohe T, Hirano S. The Surgical Outcomes of Totally Laparoscopic Stomach-partitioning Gastrojejunostomy for Gastric Outlet Obstruction: A Retrospective, Cohort Study. *Surg Laparosc Endosc Percutan Tech* 2018; **28**: e49-e53 [PMID: 29252935 DOI: 10.1097/SLE.0000000000000501]
- 78 **Eguchi H**, Yada K, Shibata K, Matsumoto T, Etoh T, Yasuda K, Inomata M, Shiraishi N, Ohta M, Kitano S. Laparoscopic stomach-partitioning gastrojejunostomy is an effective palliative procedure to improve quality of life in patients with malignant gastroduodenal outlet obstruction. *Asian J Endosc Surg* 2012; **5**: 153-156 [PMID: 22994415 DOI: 10.1111/j.1758-5910.2012.00151.x]
- 79 **Nguyen NT**, Slone J, Reavis KM, Woolridge J, Smith BR, Chang K. Laparoscopic transumbilical gastrojejunostomy: an advanced anastomotic procedure performed through a single site. *J Laparoendosc Adv Surg Tech A* 2009; **19**: 199-201 [PMID: 19243266 DOI: 10.1089/lap.2008.0365]
- 80 **Chung RS**, Li P. Palliative gastrojejunostomy. A minimally invasive approach. *Surg Endosc* 1997; **11**: 676-678 [PMID: 9171134 DOI: 10.1007/s004649900421]
- 81 **Fritscher-Ravens A**, Mosse CA, Mills TN, Mukherjee D, Park PO, Swain P. A through-the-scope device for suturing and tissue approximation under EUS control. *Gastrointest Endosc* 2002; **56**: 737-742 [PMID: 12397289 DOI: 10.1067/mge.2002.129084]
- 82 **Fritscher-Ravens A**, Mosse CA, Mukherjee D, Mills T, Park PO, Swain CP. Transluminal endosurgery: single lumen access anastomotic device for flexible endoscopy. *Gastrointest Endosc* 2003; **58**: 585-591 [PMID: 14520300 DOI: 10.1067/S0016-5107(03)02006-6]
- 83 **Itoi T**, Baron TH, Khashab MA, Tsuchiya T, Irani S, Dhir V, Bun Teoh AY. Technical review of endoscopic ultrasonography-guided gastroenterostomy in 2017. *Dig Endosc* 2017; **29**: 495-502 [PMID: 28032663 DOI: 10.1111/den.12794]
- 84 **Khashab MA**, Kumbhari V, Grimm IS, Ngamruengphong S, Aguila G, El Zein M, Kalloo AN, Baron TH. EUS-guided gastroenterostomy: the first U.S. clinical experience (with video). *Gastrointest Endosc* 2015; **82**: 932-938 [PMID: 26215646 DOI: 10.1016/j.gie.2015.06.017]
- 85 **Tyberg A**, Perez-Miranda M, Sanchez-Ocaña R, Peñas I, de la Serna C, Shah J, Binmoeller K, Gaidhane M, Grimm I, Baron T, Kahaleh M. Endoscopic ultrasound-guided gastrojejunostomy with a lumen-apposing metal stent: a multicenter, international experience. *Endosc Int Open* 2016; **4**: E276-E281 [PMID: 27004243 DOI: 10.1055/s-0042-101789]
- 86 **Itoi T**, Tsuchiya T, Tonozuka R, Ijima M, Kusano C. Novel EUS-guided double-balloon-occluded gastrojejunostomy bypass. *Gastrointest Endosc* 2016; **83**: 461-462 [PMID: 26299530 DOI: 10.1016/j.gie.2015.08.030]
- 87 **Perez-Miranda M**, Tyberg A, Poletto D, Toscano E, Gaidhane M, Desai AP, Kumta NA, Fayad L, Nieto J, Barthet M, Shah R, Brauer BC, Sharaiaha RZ, Kahaleh M. EUS-guided Gastrojejunostomy Versus Laparoscopic Gastrojejunostomy: An International Collaborative Study. *J Clin Gastroenterol* 2017; **51**: 896-899 [PMID: 28697151 DOI: 10.1097/MCG.0000000000000887]

**P- Reviewer:** Fiori E, Nakai Y **S- Editor:** Gong ZM **L- Editor:** A  
**E- Editor:** Huang Y





Published by **Baishideng Publishing Group Inc**  
7901 Stoneridge Drive, Suite 501, Pleasanton, CA 94588, USA  
Telephone: +1-925-223-8242  
Fax: +1-925-223-8243  
E-mail: [bpgoffice@wjgnet.com](mailto:bpgoffice@wjgnet.com)  
Help Desk: <http://www.f6publishing.com/helpdesk>  
<http://www.wjgnet.com>



ISSN 1007-9327

