

World Journal of *Orthopedics*

World J Orthop 2018 September 18; 9(9): 112-184



**MINIREVIEWS**

- 112 Robotic exoskeletons: The current pros and cons
Gorgey AS

ORIGINAL ARTICLE**Basic Study**

- 120 Vascular endothelial growth factor for the treatment of femoral head osteonecrosis: An experimental study in canines
Dailiana ZH, Stefanou N, Khaldi L, Dimakopoulos G, Bowers JR, Fink C, Urbaniak JR

- 130 Assessment of palmar subcutaneous tissue vascularization in patients with Dupuytren's contracture
Shchudlo N, Varsegova T, Stupina T, Dolganova T, Shchudlo M, Shihaleva N, Kostin V

Prospective Study

- 138 Single rod instrumentation in patients with scoliosis and co-morbidities: Indications and outcomes
Tsirikos AI, Loughenbury PR
- 149 Outcomes of mobile bearing unicompartmental knee arthroplasty in medial osteoarthritis knee with and without preoperative genu recurvatum
Pongcharoen B, Boontanapibul K

Randomized Clinical Trial

- 156 Acute effects of partial-body vibration in sitting position
Faes Y, Banz N, Buscher N, Blasimann A, Radlinger L, Eichelberger P, Elfering A
- 165 Corticosteroid injection alone vs additional physiotherapy treatment in early stage frozen shoulders
Kraal T, Sierevelt I, van Deurzen D, van den Bekerom MPJ, Beimers L

EVIDENCE-BASED MEDICINE

- 173 Is there consensus regarding surgical treatment of bone sarcomas?
Baad-Hansen T, Freund SS, Bech BH, Keller J

CASE REPORT

- 180 Spontaneous and simultaneous complete bilateral rupture of the quadriceps tendon in a patient receiving hemodialysis: A case report and literature review
Zribi W, Zribi M, Guidara AR, Ben Jemaa M, Abid A, Krid N, Naceur A, Keskes H

ABOUT COVER

Editorial Board Member of *World Journal of Orthopedics*, Lars Victor von Engelhardt, MD, PhD, Assistant Professor, Chief Doctor, Reader (Associate Professor), Surgeon, Department of Orthopedics, Trauma Surgery and Sports Medicine, University of Witten/Herdecke and Katholisches Karl-Leisner Klinikum Kleve, Kleve 47533, Germany

AIM AND SCOPE

World Journal of Orthopedics (*World J Orthop*, *WJO*, online ISSN 2218-5836, DOI: 10.5312) is a peer-reviewed open access academic journal that aims to guide clinical practice and improve diagnostic and therapeutic skills of clinicians.

WJO covers topics concerning arthroscopy, evidence-based medicine, epidemiology, nursing, sports medicine, therapy of bone and spinal diseases, bone trauma, osteoarthropathy, bone tumors and osteoporosis, minimally invasive therapy, diagnostic imaging. Priority publication will be given to articles concerning diagnosis and treatment of orthopedic diseases. The following aspects are covered: Clinical diagnosis, laboratory diagnosis, differential diagnosis, imaging tests, pathological diagnosis, molecular biological diagnosis, immunological diagnosis, genetic diagnosis, functional diagnostics, and physical diagnosis; and comprehensive therapy, drug therapy, surgical therapy, interventional treatment, minimally invasive therapy, and robot-assisted therapy.

We encourage authors to submit their manuscripts to *WJO*. We will give priority to manuscripts that are supported by major national and international foundations and those that are of great basic and clinical significance.

INDEXING/ABSTRACTING

World Journal of Orthopedics is now abstracted and indexed in PubMed, PubMed Central, Emerging Sources Citation Index (Web of Science), China National Knowledge Infrastructure (CNKI), and Superstar Journals Database.

EDITORS FOR
THIS ISSUE

Responsible Assistant Editor: *Xiang Li*
Responsible Electronic Editor: *Han Song*
Proofing Editor-in-Chief: *Lian-Sheng Ma*

Responsible Science Editor: *Fang-Fang Ji*
Proofing Editorial Office Director: *Jin-Lei Wang*

NAME OF JOURNAL
World Journal of Orthopedics

ISSN
ISSN 2218-5836 (online)

LAUNCH DATE
November 18, 2010

FREQUENCY
Monthly

EDITOR-IN-CHIEF
Bao-Gan Peng, MD, PhD, Professor, Department of Spinal Surgery, General Hospital of Armed Police Force, Beijing 100039, China

EDITORIAL BOARD MEMBERS
All editorial board members resources online at <http://www.wjgnet.com/2218-5836/editorialboard.htm>

EDITORIAL OFFICE
Jin-Lei Wang, Director

World Journal of Orthopedics
Baishideng Publishing Group Inc
7901 Stoneridge Drive, Suite 501, Pleasanton, CA 94588, USA
Telephone: +1-925-2238242
Fax: +1-925-2238243
E-mail: editorialoffice@wjgnet.com
Help Desk: <http://www.f0publishing.com/helpdesk>
<http://www.wjgnet.com>

PUBLISHER
Baishideng Publishing Group Inc
7901 Stoneridge Drive,
Suite 501, Pleasanton, CA 94588, USA
Telephone: +1-925-2238242
Fax: +1-925-2238243
E-mail: bpgoffice@wjgnet.com
Help Desk: <http://www.f0publishing.com/helpdesk>
<http://www.wjgnet.com>

PUBLICATION DATE
September 18, 2018

COPYRIGHT

© 2018 Baishideng Publishing Group Inc. Articles published by this Open-Access journal are distributed under the terms of the Creative Commons Attribution Non-commercial License, which permits use, distribution, and reproduction in any medium, provided the original work is properly cited, the use is non commercial and is otherwise in compliance with the license.

SPECIAL STATEMENT

All articles published in journals owned by the Baishideng Publishing Group (BPG) represent the views and opinions of their authors, and not the views, opinions or policies of the BPG, except where otherwise explicitly indicated.

INSTRUCTIONS TO AUTHORS

<http://www.wjgnet.com/bpg/gerinfo/204>

ONLINE SUBMISSION

<http://www.f0publishing.com>

Spontaneous and simultaneous complete bilateral rupture of the quadriceps tendon in a patient receiving hemodialysis: A case report and literature review

Wassim Zribi, Mohamed Zribi, Ahmed Racem Guidara, Mohamed Ben Jemaa, Ameer Abid, Nabil Krid, Abdessalem Naceur, Hassib Keskes

Wassim Zribi, Mohamed Zribi, Ahmed Racem Guidara, Mohamed Ben Jemaa, Ameer Abid, Abdessalem Naceur, Hassib Keskes, Department of Orthopaedic Surgery and Traumatology, Habib Bourguiba University Hospital, Sfax 3000, Tunisia

Nabil Krid, Department of Orthopaedic Surgery and Traumatology, Marechal Leclerc Argentan Hospital, Argentan 61200, France

ORCID number: Wassim Zribi (0000-0001-7210-9361); Mohamed Zribi (0000-0001-9328-3246); Ahmed Racem Guidara (0000-0002-1406-9872); Mohamed Ben Jemaa (0000-0001-6958-9878); Ameer Abid (0000-0003-2334-2057); Nabil Krid (0000-0002-2809-8850); Abdessalem Naceur (0000-0002-7829-5828); Hassib Keskes (0000-0003-2231-760X).

Author contributions: Zribi W and Zribi M performed the surgery; Guidara AR is the corresponding author, he wrote the great part of the manuscript; Ben Jemaa M, Krid N and Abid A contributed in gathering the data and writing the manuscript; Naceur A corrected some grammar mistakes and contributed in the improvement of English language; Keskes H corrected the hole manuscript and gave his permission for submitting.

Informed consent statement: The patient involved in this study gave her written informed consent authorizing use and disclosure of her protected health information.

Conflict-of-interest statement: None of the authors have any financial or other conflicts of interest that may bias the current study.

CARE Checklist (2013) statement: The authors have read the CARE Checklist (2013), and the manuscript was prepared and revised according to the CARE Checklist (2013).

Open-Access: This article is an open-access article which was selected by an in-house editor and fully peer-reviewed by external reviewers. It is distributed in accordance with the Creative Commons Attribution Non Commercial (CC BY-NC 4.0) license, which

permits others to distribute, remix, adapt, build upon this work non-commercially, and license their derivative works on different terms, provided the original work is properly cited and the use is non-commercial. See: <http://creativecommons.org/licenses/by-nc/4.0/>

Manuscript source: Unsolicited manuscript

Correspondence to: Ahmed Racem Guidara, MD, Doctor, Surgeon, Department of Orthopaedic Surgery and Traumatology, Habib Bourguiba University Hospital, El Ain Street, Sfax 3000, Tunisia. rassimou@live.fr
Telephone: +216-22-650267

Received: May 8, 2018

Peer-review started: May 8, 2018

First decision: June 5, 2018

Revised: June 18, 2018

Accepted: June 28, 2018

Article in press: June 28, 2018

Published online: September 18, 2018

Abstract

The spontaneous and simultaneous rupture of both quadriceps tendons is uncommon and has rarely been reported in the literature. The current case involves a 43-year-old man with end-stage renal disease requiring hemodialysis for the past 20 years. The patient experienced bilateral knee pain and swelling and was unable to bear weight. Physical examination revealed bilateral quadriceps tendon defect above the patella and loss of active extension. Although plain radiographs of both knees showed no fracture or widening of the joint space, an inferiorly positioned patella was observed. Ultrasonography of the knees revealed a quadriceps tendon defect at the upper edge of each patella, while MR imaging revealed a tear in each quadriceps tendon

from the superior poles of the patella. The patient then underwent surgical correction wherein the tendons were repaired using sutures passed through drill holes in the patella. The knees were immobilized with splints for 4 wk before starting physiotherapy. The patient subsequently regained full functional activity within 1 year.

Key words: Quadriceps tendon; Tear; Krackow sutures; Renal failure; Hyperparathyroidism

© **The Author(s) 2018.** Published by Baishideng Publishing Group Inc. All rights reserved.

Core tip: Spontaneous bilateral quadriceps tendon rupture is uncommon, while the symmetry of physical findings may make the diagnosis even more difficult. Testing the extensor mechanism must be an essential part of every knee examination. Early diagnosis and surgical repair are associated with the best outcomes. The most likely etiology of tendon ruptures in patients receiving hemodialysis is the fragility of the junction between the tendon and the bone resulting from long-standing and poorly controlled hyperparathyroidism.

Zribi W, Zribi M, Guidara AR, Ben Jemaa M, Abid A, Krid N, Naceur A, Keskes H. Spontaneous and simultaneous complete bilateral rupture of the quadriceps tendon in a patient receiving hemodialysis: A case report and literature review. *World J Orthop* 2018; 9(9): 180-184 Available from: URL: <http://www.wjgnet.com/2218-5836/full/v9/i9/180.htm> DOI: <http://dx.doi.org/10.5312/wjo.v9.i9.180>

INTRODUCTION

Bilateral quadriceps rupture is a very rare disabling injury. Although traumatic in nature, it is often secondary to metabolic disorders and predisposing medical conditions, such as diabetes, gout, hyperparathyroidism^[1], systemic diseases, or chronic renal failure^[2,3]. The spontaneous and simultaneous rupture of both quadriceps tendons has been rarely reported in the literature and is usually observed in patients aged over 40 years; a sex ratio of 6:1 has been recorded for this phenomenon^[4,5]. The most commonly reported mechanism is the sudden reflexive eccentric contraction of the quadriceps, with the foot anchored to the ground and the knees flexed. We herein report a case involving spontaneous bilateral rupture of the quadriceps tendon in a patient with renal failure receiving hemodialysis. Accordingly, we present clinical particularities, imaging data, and the management employed.

CASE REPORT

A 43-year-old male with renal failure (hemodialysis for 20 years) presented with bilateral pain and cutaneous

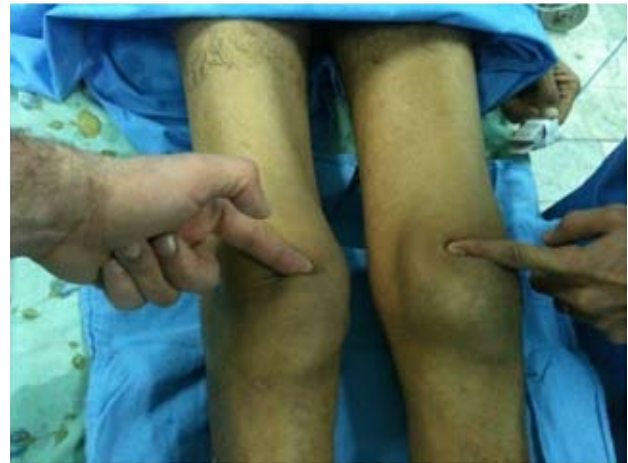

Figure 1 Palpation showing bilateral depression above the patella.

depression upon palpation above the patella (Figure 1). The patient exhibited good general conditions with no signs of malnutrition. Bone densitometry, which was previously performed, revealed osteopenia related to chronic kidney disease. There was no significant medical history, and no other co-morbidities were noted. Although no traumatic context had been reported, clinical examination noted incomplete active knee extension that was very painful. Radiographs of the knee showed a lowering of the patella with diffuse bone demineralization due to renal failure (Figure 2). The patient subsequently underwent ultrasonography and magnetic resonance imaging (MRI) to examine the appearance of the overlying tendon and muscle (Figure 3). Accordingly, simultaneous and spontaneous rupture of both quadriceps tendons at the patellar insertion was confirmed. Laboratory analyses revealed a white blood cell count of 8540/mm³, hemoglobin of 8 g/dL, platelet count of 352000/mm³. Blood testing revealed the following values: sodium, 137 mmol/L; potassium, 4.8 mmol/L; calcium, 2.2 mmol/L; phosphorus, 0.9 mmol/L; serum uric acid, 267 μmol/L; creatinine, 765 μmol/L; and serum parathyroid hormone, 45 pg/mL (normal, 9-65 pg/mL). Hemostasis assessment was within normal limits. The treatment consisted of tendon reinsertion through tendon-to-bone repair (Figure 4). The patient was immobilized for 4 wk with a splint before undergoing regular rehabilitation. He was allowed to fully bear weight 6 wk after his surgery. The operative follow-up was simple. A year later, the patient showed excellent results and regained his former autonomy (Figure 5).

DISCUSSION

Bilateral rupture of the quadriceps tendon is a rare injury. Accordingly, the first reported case of simultaneous bilateral rupture of quadriceps tendons had been by Steiner and Palmer in 1949. Patients usually complain of severe knee pain and complete functional disability

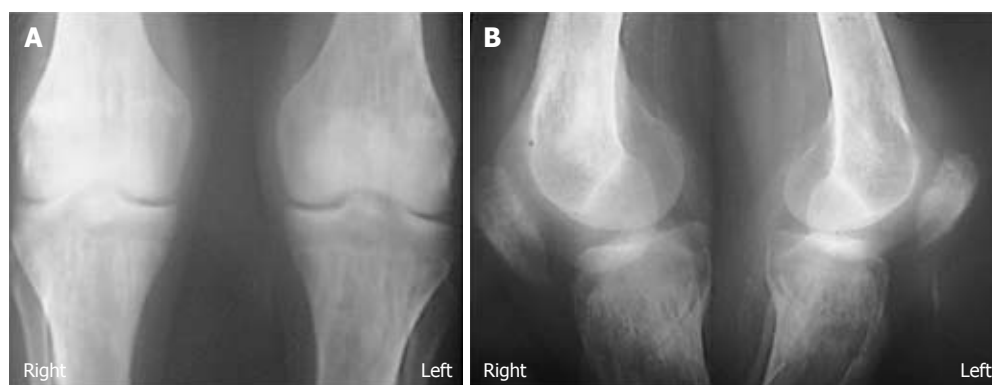

Figure 2 Knee radiographs showing patellar lowering and diffuse bone demineralization. A: Antero-posterior X-rays; B: Lateral X-rays.

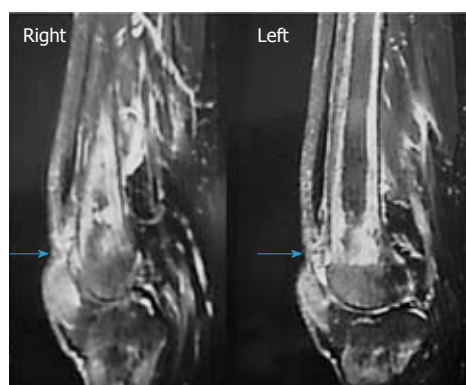


Figure 3 Magnetic resonance imaging of the knee (sagittal view) showing a complete bilateral rupture of the tendon.

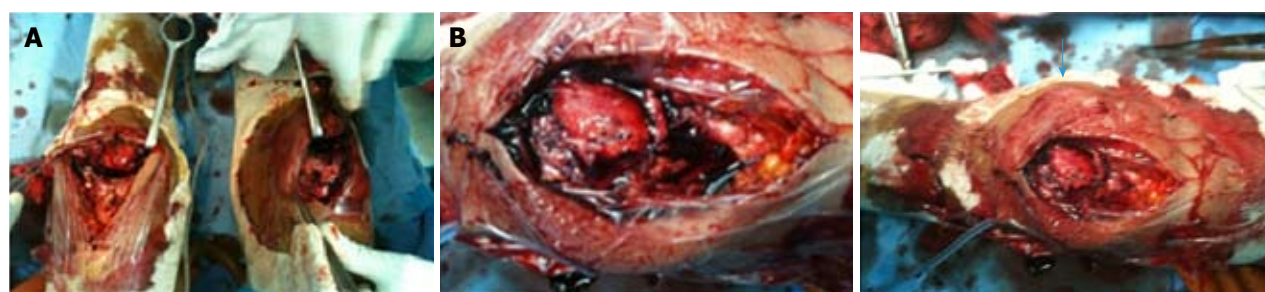

Figure 4 Surgical management of the injury through bilateral reinsertion of the tendon. A: Exposing the bilateral rupture of the quadriceps tendon; B: Quadriceps tendon reinserted through tendon-to-bone repair.

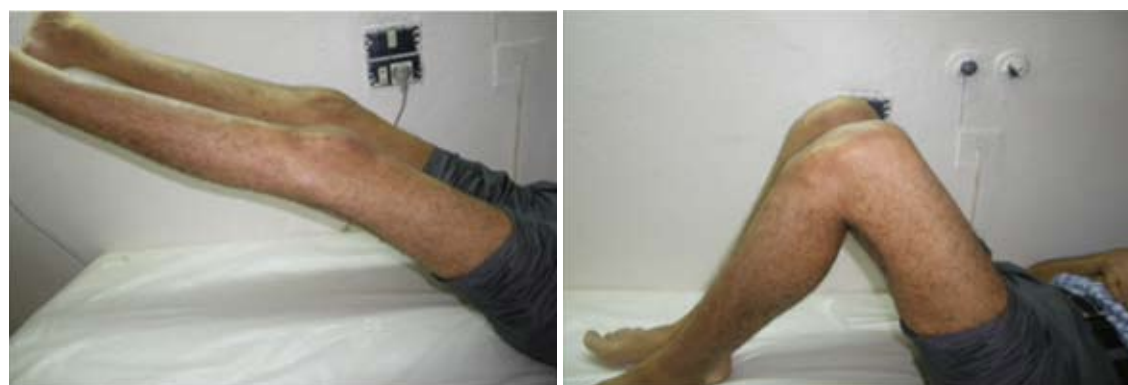

Figure 5 Complete active extensions of the knees.

of the lower limbs. In younger patients, however, major trauma by direct shock or laceration by a blunt object has been more common. In the absence of a traumatic context, assessment should be focused on identifying systemic diseases wherein tendons become weakened. Hence, tendon ruptures could be caused by the diminution of local circulation, abnormalities in collagen metabolism, repeated microtrauma, weakening, and calcifications, which consequently reduce the elasticity of the tendon. Most authors agree that bone resorption at the tendon insertion sites due to secondary hyperparathyroidism contributes to the pathogenesis of tendon ruptures. In addition, weakening of the tendon may be observed when collagen is replaced by elastin during chronic metabolic acidosis due to chronic renal failure. Such patients are therefore at risk for bilateral ruptures. Many cases of bilateral ruptures in athletes consuming anabolic agents have been also reported in the literature^[6]. Moreover, direct corticosteroid injections and fluoroquinolone use have all been associated with increased risk of tendon rupture^[6]. Though fluoroquinolone use has most commonly affected the Achilles tendon, cases involving the rotator cuff, biceps, wrist extensors, and quadriceps tendons among others, have also been described^[7,8]. The diagnosis of quadriceps tendon rupture has been based primarily on anamnesis and clinical examination.

Accordingly, Siwek and Rao^[4] in 1981 showed that 28% of ruptures had not been initially diagnosed. Therefore, clinical examination is crucial and allows for rapid diagnosis, which is critical for optimal therapeutic management. Clinically, patients are no longer able to perform full active extension of the knee^[9]. In a supine position, patients cannot elevate the lower limb while keeping it extended or maintain this position against gravity. In a seated position with the knees flexed at 90°, patients are unable to completely extend the knee when both the quadriceps tendon and retinaculum (aponeurosis of the vastus medialis and vastus lateralis, which are inserted on the patella) are torn. On the other hand, when the quadriceps tendon is torn while the retinaculum is intact, patients are able to achieve partial active extension without reaching full extension. During palpation of the quadriceps tendon, a "hole" and an interruption of tendon continuity are felt. However, the swelling and hematoma that subsequently develop may obscure the palpability of this "hole"^[5]. Quadriceps tendon tears generally occur 2 cm above the upper pole of the patella. However, tearing occasionally occurs higher at the myotendinous junction, particularly in patients with reduced mobility and muscle atrophy. A differential diagnosis for patients unable to perform full active knee extension may include femoral nerve palsy, which might be traumatic or iatrogenic^[10]. Accordingly, radiological examinations may help establish a more accurate diagnosis. Radiographic views of the knee may show soft tissue swelling above the kneecap. Calcifications at the superior pole of the patella may indirectly indicate quadriceps tendinopathy, which is a predisposition to

rupture^[11]. Considering that the patella is no longer subject to quadriceps traction, it may be located lower compared to the uninjured side in unilateral conditions (patella baja or patella infera).

Although ultrasonography is a non-invasive, rapid, and effective diagnostic tool for confirming a partial or complete quadriceps tendon rupture, interpretation of its results is examiner-dependent and must be performed by a trained specialist. MRI is another very sensitive diagnostic tool that can precisely locate the tear, determine which four layers of the quadriceps tendon are affected or whether the rupture is partial, and determine whether the retinaculum is torn^[5]. As such, our patient underwent MRI to identify quadriceps tendon ruptures prior to surgery. Surgery based on reintegration for fresh lesions and tendinous plasty for old ones has always been the standard treatment for ruptures, with early surgical repair providing the best results^[5]. Nonetheless, various surgical techniques have been described. In the case of tendon body tearing, an end-to-end suture allows for an excellent repair. For ruptures close to the patellar insertion, Krackow points^[12] can be made in the tendon stump, which is then passed through the patella using longitudinal bony tunnels, ensuring good holding. A torn retinaculum must also be sutured. Lighthart *et al.*^[13] studied quadriceps tendon strength after transosseous suturing and tendon anchoring. Accordingly, their results showed no difference between the two techniques.

After the operation, walking was permitted albeit with a splint keeping the knee extended for 4 to 6 wk, which helps protect the reconstruction^[14]. A mobilization of 0°-30° can be allowed to prevent adhesions. Most authors have reported good functional results, always with complete motion recovery and return to previous activities^[13,14]. Though quadriceps amyotrophy is quite common, it carries no functional repercussions in everyday life. Moreover, recovery is difficult despite physiotherapy. In fact, only 4 to 6 wk of actual physiotherapy is provided postoperatively. Furthermore, a secondary rupture may occur but remains rare^[7].

A missed diagnosis may lead to delayed repair, which could be problematic due to significant quadriceps retraction. As a result, end-to-end tendon suturing becomes difficult, and more complex surgical techniques are often necessary to fix the consequent defect and restore the extensor system of the knee. Several techniques have been described^[5], including tendon grafting (auto- or allograft) and tendon flap advancement. Nonetheless, delayed repairs have worse results and higher complication rates. Early diagnosis and treatment are therefore essential for good healing and functional recovery.

Spontaneous ruptures of the knee extensor system are rare, and bilateral forms, which result in functional disability of both lower limbs, are exceptionally rare. Given that early diagnosis allows for rapid surgical management and thus optimal functional recovery, careful investigation of such ruptures through clinical examination, plain radiographs, and MRI is therefore

necessary for better tear analysis.

ARTICLE HIGHLIGHTS

Case characteristics

This case involves spontaneous bilateral rupture of the quadriceps tendon in a patient with renal failure receiving hemodialysis. Accordingly, we present clinical particularities, imaging data, and the management employed.

Clinical diagnosis

Bilateral rupture of the quadriceps tendon.

Differential diagnosis

Femoral nerve palsy.

Laboratory diagnosis

Blood testing revealed renal failure and anemia without other abnormalities.

Imaging diagnosis

Knee radiographs revealed lowering of the patella with diffuse bone demineralization caused by renal failure. Magnetic resonance imaging confirmed the diagnosis of bilateral rupture of the quadriceps tendon.

Treatment

Tendon reinsertion through tendon-to-bone repair.

Related reports

Only few cases of spontaneous bilateral rupture of the quadriceps tendon have been to date reported in the literature.

Experiences and lessons

This case will help improve the understanding of the management of bilateral rupture of the quadriceps tendon, which is a rare injury. The main lesson learned was that early diagnosis and surgical repair are essential for achieving the best outcomes.

ACKNOWLEDGEMENTS

We thank the patient described for allowing us to share his details and thank Dr. Wassim Zribi and Dr. Mohamed Zribi for advice and performing the surgery.

REFERENCES

1 Mokoko-Louckou AE, Chaibou B, Abdouli I, Bouhelo-Pam

- KPB, Idrissi ME, Shimi M, Ibrahim AE, Mrini AE. [Spontaneous simultaneous bilateral rupture of the quadriceps tendon in patients with parathyroid adenoma: case report and literature review]. *Pan Afr Med J* 2018; **29**: 14 [PMID: 29662599 DOI: 10.11604/pamj.2018.29.14.13540]
- 2 Arumilli B, Adeyemo F, Samarji R. Bilateral simultaneous complete quadriceps rupture following chronic symptomatic tendinopathy: a case report. *J Med Case Rep* 2009; **3**: 9031 [PMID: 19918285 DOI: 10.4076/1752-1947-3-9031]
- 3 Neubauer T, Wagner M, Potschka T, Riedl M. Bilateral, simultaneous rupture of the quadriceps tendon: a diagnostic pitfall? Report of three cases and meta-analysis of the literature. *Knee Surg Sports Traumatol Arthrosc* 2007; **15**: 43-53 [PMID: 16951978 DOI: 10.1007/s00167-006-0133-7]
- 4 Siwek CW, Rao JP. Ruptures of the extensor mechanism of the knee joint. *J Bone Joint Surg Am* 1981; **63**: 932-937 [PMID: 6985557 DOI: 10.2106/00004623-198163060-00010]
- 5 Ilan DI, Tejwani N, Keschner M, Leibman M. Quadriceps tendon rupture. *J Am Acad Orthop Surg* 2003; **11**: 192-200 [PMID: 12828449 DOI: 10.5435/00124635-200305000-00006]
- 6 Lewis AC, Purushotham B, Power DM. Bilateral simultaneous quadriceps tendon rupture in a bodybuilder. *Orthopedics* 2005; **28**: 701-702 [PMID: 16119286]
- 7 Stinner DJ, Orr JD, Hsu JR. Fluoroquinolone-associated bilateral patellar tendon rupture: a case report and review of the literature. *Mil Med* 2010; **175**: 457-459 [PMID: 20572481 DOI: 10.7205/MILMED-D-09-00142]
- 8 Casparian JM, Luchi M, Moffat RE, Hinthorn D. Quinolones and tendon ruptures. *South Med J* 2000; **93**: 488-491 [PMID: 10832946 DOI: 10.1097/00007611-200005000-00008]
- 9 Ramsey RH, Muller GE. Quadriceps tendon rupture: a diagnostic trap. *Clin Orthop Relat Res* 1970; **70**: 161-164 [PMID: 5445722 DOI: 10.1097/00003086-197005000-00019]
- 10 Thoms RJ, Kondrashov D, Silber J. Iatrogenic femoral nerve palsy masquerading as knee extensor mechanism rupture. *Am J Orthop (Belle Mead NJ)* 2009; **38**: 142-144 [PMID: 19377648]
- 11 Hardy JR, Chimutengwende-Gordon M, Bakar I. Rupture of the quadriceps tendon: an association with a patellar spur. *J Bone Joint Surg Br* 2005; **87**: 1361-1363 [PMID: 16189308 DOI: 10.1302/0301-620X.87B10.16624]
- 12 Krackow KA, Thomas SC, Jones LC. A new stitch for ligament-tendon fixation. Brief note. *J Bone Joint Surg Am* 1986; **68**: 764-766 [PMID: 3522596 DOI: 10.2106/00004623-198668050-00020]
- 13 Lighthart WA, Cohen DA, Levine RG, Parks BG, Boucher HR. Suture anchor versus suture through tunnel fixation for quadriceps tendon rupture: a biomechanical study. *Orthopedics* 2008; **31**: 441 [PMID: 19292325 DOI: 10.3928/01477447-20080501-18]
- 14 Ennaciri B, Montbarbon E, Beaudouin E. Surgical management of acute quadriceps tendon rupture (a case report with literature review). *Pan Afr Med J* 2015; **22**: 243 [PMID: 26958106 DOI: 10.11604/pamj.2015.22.243.7533]

P- Reviewer: Kocazeybek B, Kute VB, Zaky A S- Editor: Ji FF
L- Editor: A E- Editor: Song H





Published by **Baishideng Publishing Group Inc**
7901 Stoneridge Drive, Suite 501, Pleasanton, CA 94588, USA
Telephone: +1-925-223-8242
Fax: +1-925-223-8243
E-mail: bpgoffice@wjgnet.com
Help Desk: <http://www.f6publishing.com/helpdesk>
<http://www.wjgnet.com>

