

# World Journal of *Radiology*

*World J Radiol* 2018 September 28; 10(9): 91-115



**MINIREVIEWS**

- 91** Role of imaging methods in diagnosis and treatment of Morton's neuroma  
*Santiago FR, Muñoz PT, Pryest P, Martínez AM, Olleta NP*

**ORIGINAL ARTICLE****Basic Study**

- 100** Optimized cardiac magnetic resonance imaging inversion recovery sequence for metal artifact reduction and accurate myocardial scar assessment in patients with cardiac implantable electronic devices  
*Ibrahim EH, Runge M, Stojanovska J, Agarwal P, Ghadimi-Mahani M, Attili A, Chenevert T, den Harder C, Bogun F*

**Retrospective Study**

- 108** Korean single-center experience with femoral access closure using the ExoSeal device  
*Han Y, Kwon JH, Park S*

## ABOUT COVER

Editorial Board Member of *World Journal of Radiology*, Neeraj Lalwani, MBBS, MD, Associate Professor, Department of Radiology, Wake Forest University and Baptist Medical Center, Winston-Salem, NC 27106, United States

## AIM AND SCOPE

*World Journal of Radiology* (*World J Radiol*, *WJR*, online ISSN 1949-8470, DOI: 10.4329) is a peer-reviewed open access academic journal that aims to guide clinical practice and improve diagnostic and therapeutic skills of clinicians.

*WJR* covers topics concerning diagnostic radiology, radiation oncology, radiologic physics, neuroradiology, nuclear radiology, pediatric radiology, vascular/interventional radiology, medical imaging achieved by various modalities and related methods analysis. The current columns of *WJR* include editorial, frontier, diagnostic advances, therapeutics advances, field of vision, mini-reviews, review, topic highlight, medical ethics, original articles, case report, clinical case conference (clinicopathological conference), and autobiography.

We encourage authors to submit their manuscripts to *WJR*. We will give priority to manuscripts that are supported by major national and international foundations and those that are of great basic and clinical significance.

## INDEXING/ABSTRACTING

*World Journal of Radiology* is now abstracted and indexed in Emerging Sources Citation Index (Web of Science), PubMed, PubMed Central, China National Knowledge Infrastructure (CNKI), and Superstar Journals Database.

## EDITORS FOR THIS ISSUE

Responsible Assistant Editor: *Xiang Li*  
Responsible Electronic Editor: *Han Song*  
Proofing Editor-in-Chief: *Lian-Sheng Ma*

Responsible Science Editor: *Ying Dou*  
Proofing Editorial Office Director: *Jin-Lei Wang*

NAME OF JOURNAL  
*World Journal of Radiology*

ISSN  
ISSN 1949-8470 (online)

LAUNCH DATE  
January 31, 2009

FREQUENCY  
Monthly

EDITORS-IN-CHIEF  
**Kai U Juergens, MD, Associate Professor, MRT** und PET/CT, Nuklearmedizin Bremen Mitte, ZEMODI - Zentrum für morphologische und molekulare Diagnostik, Bremen 28177, Germany

**Edwin JR van Beek, MD, PhD, Professor**, Clinical Research Imaging Centre and Department of Medical Radiology, University of Edinburgh, Edinburgh EH16 4TJ, United Kingdom

**Thomas J Vogl, MD, Professor, Reader in Health Technology Assessment**, Department of Diagnostic and Interventional Radiology, Johann Wolfgang Goethe University of Frankfurt, Frankfurt 60590,

Germany

EDITORIAL BOARD MEMBERS  
All editorial board members resources online at <http://www.wjgnet.com/1949-8470/editorialboard.htm>

EDITORIAL OFFICE  
Jin-Lei Wang, Director  
*World Journal of Radiology*  
Baishideng Publishing Group Inc  
7901 Stoneridge Drive, Suite 501, Pleasanton, CA 94588, USA  
Telephone: +1-925-2238242  
Fax: +1-925-2238243  
E-mail: [editorialoffice@wjgnet.com](mailto:editorialoffice@wjgnet.com)  
Help Desk: <http://www.f6publishing.com/helpdesk>  
<http://www.wjgnet.com>

PUBLISHER  
Baishideng Publishing Group Inc  
7901 Stoneridge Drive, Suite 501, Pleasanton, CA 94588, USA  
Telephone: +1-925-2238242  
Fax: +1-925-2238243  
E-mail: [bpgoffice@wjgnet.com](mailto:bpgoffice@wjgnet.com)  
Help Desk: <http://www.f6publishing.com/helpdesk>  
<http://www.wjgnet.com>

PUBLICATION DATE  
September 28, 2018

COPYRIGHT  
© 2018 Baishideng Publishing Group Inc. Articles published by this Open-Access journal are distributed under the terms of the Creative Commons Attribution Non-commercial License, which permits use, distribution, and reproduction in any medium, provided the original work is properly cited, the use is non commercial and is otherwise in compliance with the license.

SPECIAL STATEMENT  
All articles published in journals owned by the Baishideng Publishing Group (BPG) represent the views and opinions of their authors, and not the views, opinions or policies of the BPG, except where otherwise explicitly indicated.

INSTRUCTIONS TO AUTHORS  
<http://www.wjgnet.com/bpg/gerinfo/204>

ONLINE SUBMISSION  
<http://www.f6publishing.com>

## Role of imaging methods in diagnosis and treatment of Morton's neuroma

Fernando Ruiz Santiago, Pablo Tomás Muñoz, Patel Pryest, Alberto Martínez Martínez, Nicolás Prados Olleta

Fernando Ruiz Santiago, Pablo Tomás Muñoz, Alberto Martínez Martínez, Radiology Department, Hospital of Neuro-Traumatology (Virgen de las Nieves), Granada 18014, Spain

Patel Pryest, Radiology Department, North Tyneside General Hospital, North Shields NE29 8NH, United Kingdom

Nicolás Prados Olleta, Orthopaedic Department, Hospital of Neuro-Traumatology (Virgen de las Nieves), Granada 18014, Spain

ORCID number: Fernando Ruiz Santiago (0000-0002-6843-0803); Pablo Tomás Muñoz (0000-0002-6405-0811); Patel Pryest (0000-0001-6969-5793); Alberto Martínez Martínez (0000-0002-8069-9549); Nicolás Prados Olleta (0000-0003-0224-4570).

**Author contributions:** All authors contributed to the conception and design of the study, data acquisition, and manuscript preparation and review.

**Conflict-of-interest statement:** All authors declare no real or potential conflicts of interest related to this study or its publication.

**Open-Access:** This article is an open-access article which was selected by an in-house editor and fully peer-reviewed by external reviewers. It is distributed in accordance with the Creative Commons Attribution Non Commercial (CC BY-NC 4.0) license, which permits others to distribute, remix, adapt, build upon this work non-commercially, and license their derivative works on different terms, provided the original work is properly cited and the use is non-commercial. See: <http://creativecommons.org/licenses/by-nc/4.0/>

**Manuscript source:** Invited manuscript

**Correspondence to:** Fernando Ruiz Santiago, PhD, Adjunct Professor, Chief Doctor, Radiology Department, Hospital of Neuro-Traumatology (Virgen de las Nieves), Carretera de Jaen SN, Granada 18014, Spain. [ferusan12@gmail.com](mailto:ferusan12@gmail.com)  
Telephone: +34-62-7633829

Received: April 26, 2018

Peer-review started: April 26, 2018

First decision: June 14, 2018

Revised: July 21, 2018

Accepted: August 4, 2018

Article in press: August 5, 2018

Published online: September 28, 2018

### Abstract

Among the many causes of forefoot pain, Morton's neuroma (MN) is often suspected, particularly in women, due to its high incidence. However, there remain controversies about its relationship with symptomatology and which diagnostic and treatment choices to choose. This article mainly focuses on the role of the various imaging methods and their abilities to support an accurate diagnosis of MN, ruling out other causes of forefoot pain, and as a way of providing targeted imaging-guided therapy for patients with MN.

**Key words:** Morton's neuroma; Diagnosis; Infiltrative; Imaging; Therapy

© **The Author(s) 2018.** Published by Baishideng Publishing Group Inc. All rights reserved.

**Core tip:** Nowadays, ultrasound and magnetic resonance imaging provide accurate diagnosis of Morton's neuroma (MN) and are invaluable tools for ruling out other causes of forefoot pain. This extended review is intended to show the potential of imaging methods for diagnosis as well as treatment of MN.

Santiago FR, Muñoz PT, Pryest P, Martínez AM, Olleta NP. Role of imaging methods in diagnosis and treatment of Morton's neuroma. *World J Radiol* 2018; 10(9): 91-99 Available from: URL: <http://www.wjgnet.com/1949-8470/full/v10/i9/91.htm> DOI: <http://dx.doi.org/10.4329/wjr.v10.i9.91>



## INTRODUCTION

Morton's neuroma (MN) is considered a nerve entrapment neuropathy, causing symptoms relating to impingement of the common plantar digital and proper plantar digital nerves, such as burning, tingling or numbness. It is a common problem but mainly affects middle-aged women, occurring more than 5 times more frequently in women than in men<sup>[1]</sup>.

It is considered that MN occurs secondary to mechanical stress on the nerves, leading to proliferation of fibrosis in and around the affected nerve<sup>[2]</sup>. It has been reported to be more frequent in the 3<sup>rd</sup> web space (in 68% of cases), followed by the 2<sup>nd</sup> web space (in 32% of cases). The presence of a neuroma in the 1<sup>st</sup> and 4<sup>th</sup> web spaces is extremely rare<sup>[3]</sup>. Two main anatomical reasons have been postulated to explain this distribution; firstly, the 3<sup>rd</sup> metatarsal nerve is theoretically thicker because it is usually formed by the confluence of medial and lateral plantar nerves<sup>[4]</sup>; and, secondly, the larger shearing forces that occur at the 3<sup>rd</sup> web space due to the relatively greater mobility of the 4<sup>th</sup> metatarsal relative to the 3<sup>rd</sup> metatarsal<sup>[1]</sup>.

Other authors have found a similar proportion of MN in the 2<sup>nd</sup> and 3<sup>rd</sup> web spaces<sup>[5,6]</sup> and this could be explained by the fact that the 2<sup>nd</sup> and 3<sup>rd</sup> intermetatarsal spaces are the narrowest of the foot<sup>[7]</sup>. The occurrence of multiple neuromas in the same foot has also been reported, but is considered rare by some authors<sup>[8]</sup>; although, in other case series, it has been found in between 28% and 65% of cases<sup>[5,6,9]</sup>.

## CLINICAL PRESENTATION

Not all patients with MN show clinical symptoms. The prevalence of asymptomatic MN has been reported as 33%-54% when using ultrasound (US) or magnetic resonance imaging (MRI) for diagnosis<sup>[9,10]</sup>. Nevertheless, when forefoot pain secondary to MN is present, it is elicited under pressure of the web space. The thumb index finger squeeze test has been reported to be the most sensitive screening method for clinical diagnosis of MN, having accuracy of around 96% (Figure 1). In this maneuver, the intermetatarsal space is squeezed between the tips of the index finger (dorsal) and thumb (plantar). The Mulder's click is reproduced by firm medial to lateral compression of the metatarsal heads, when one hand is clasping the forefoot. A palpable and/or audible click is perceived, though it is mainly present for larger neuromas; its accuracy is around 62%<sup>[5]</sup>.

## IMAGING OF MN

Pathognomonic diagnostic clinical tests for MN do not exist, and many of the clinical tests provide false positive results in feet with alternative pathologies<sup>[11]</sup>. Therefore, imaging may be required to confirm the diagnosis of MN and exclude other causes of forefoot pain, such as metatarsophalangeal joint arthritis or intermetatarsal

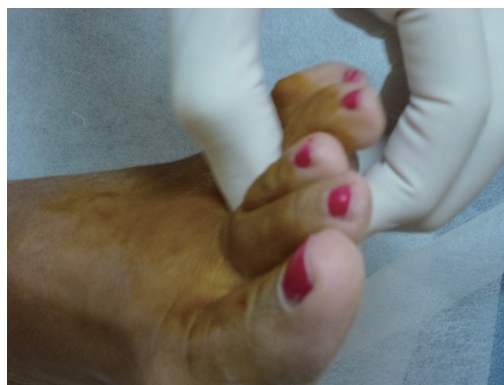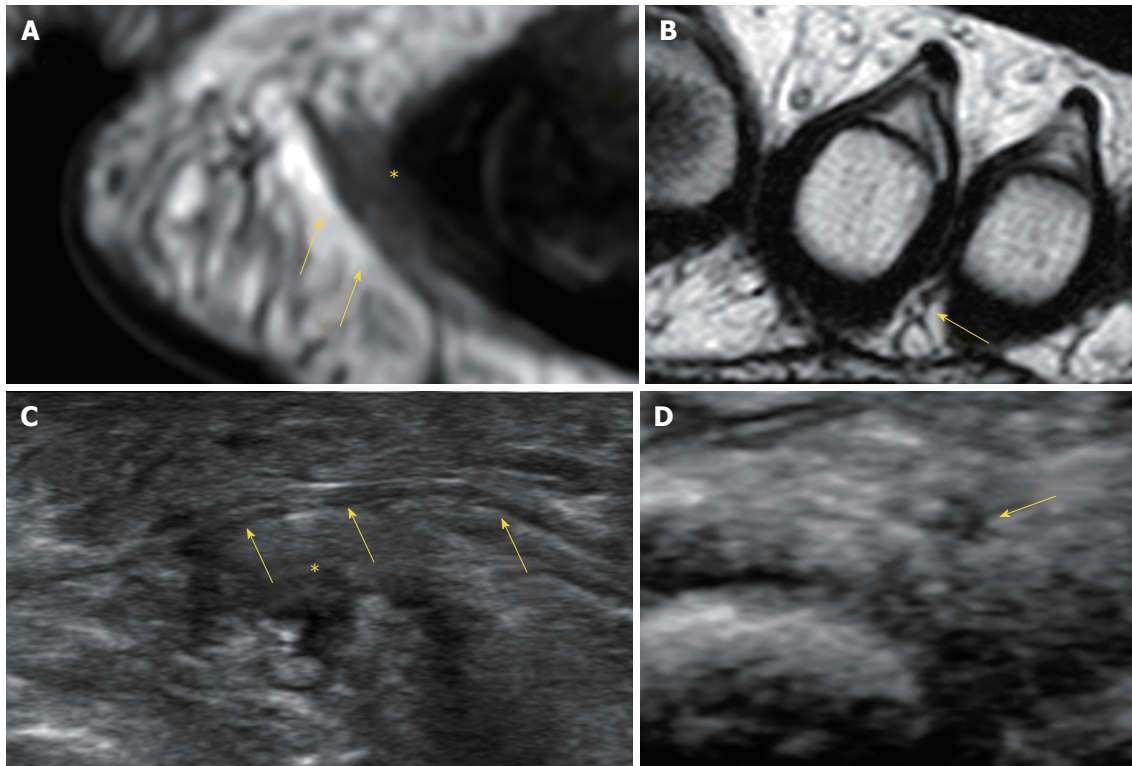


Figure 1 Thumb index finger squeeze test.

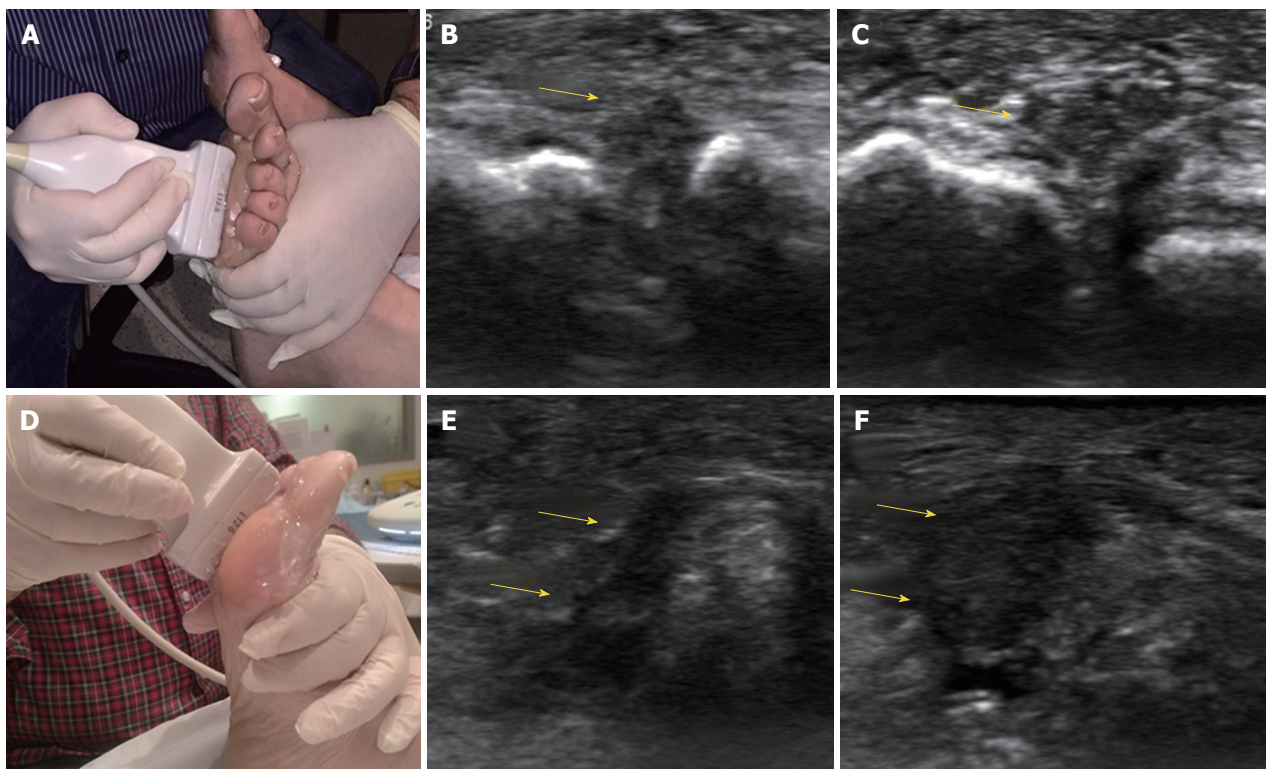
bursitis. The available evidence suggests that US is more accurate than MRI for diagnosis of MN. Analysis of pooled sensitivity showed similarity between US (90%) and MRI (93%), both being relatively high; yet, MRI (68%) showed a relatively lower specificity than US (88%) in the detection of MN<sup>[12]</sup>. Diameter of the normal plantar digital nerve is around 1 mm at the level of the intermetatarsal heads<sup>[13]</sup> and can be identified on high-resolution sonography and MRI (Figure 2).

In US, MN is detected as a well-defined, round or ovoid mass in the short axis view and as an elongated/fusiform mass in the long axis view; it is hypoechoic relative to the adjacent tissues and located between the metatarsal heads along the plantar aspect of the intermetatarsal spaces<sup>[14]</sup> (Figure 3). Squeezing of the lateral aspect of the forefoot helps to extrude the intermetatarsal contents toward the plantar aspect of the forefoot, leading to a better delineation of the MN. This displacement may coincide with a palpable and/or audible click, known as the sonographic Mulder sign<sup>[15]</sup>. The extruding content may be formed by the MN and/or the bursa. It is theorized that the click will only happen when there is a MN because a thickened bursa is much more pliable than a neuroma<sup>[16]</sup>. As both entities may coexist, we can complete the US scan with another maneuver that will help in differentiating between MN and bursal tissue. The intermetatarsal space is compressed dorsally by the fingers whilst the probe is scanning along the plantar aspect of the web space in the long axis view. A MN will have a fusiform elongated shape and be displaceable, but it will not be as compressible as the intermetatarsal bursa. The bursa, located along the dorsal aspect of the intermetatarsal nerve, will show a more rounded or oval shape and will be compressible to a greater extent than the neural tissue (Figure 4).

US may also detect other causes of forefoot pain, such as joint pathology (osteoarthritis or synovitis), soft tissue abnormalities (bursitis or inflammation-related change) and even bone lesions (stress fracture, bone erosion or cyst). Soft tissue masses different from MN can also be characterized, differentiating solid from cystic content, as well as the presence of neovascularity. Any intermetatarsal mass longer than 20 mm should

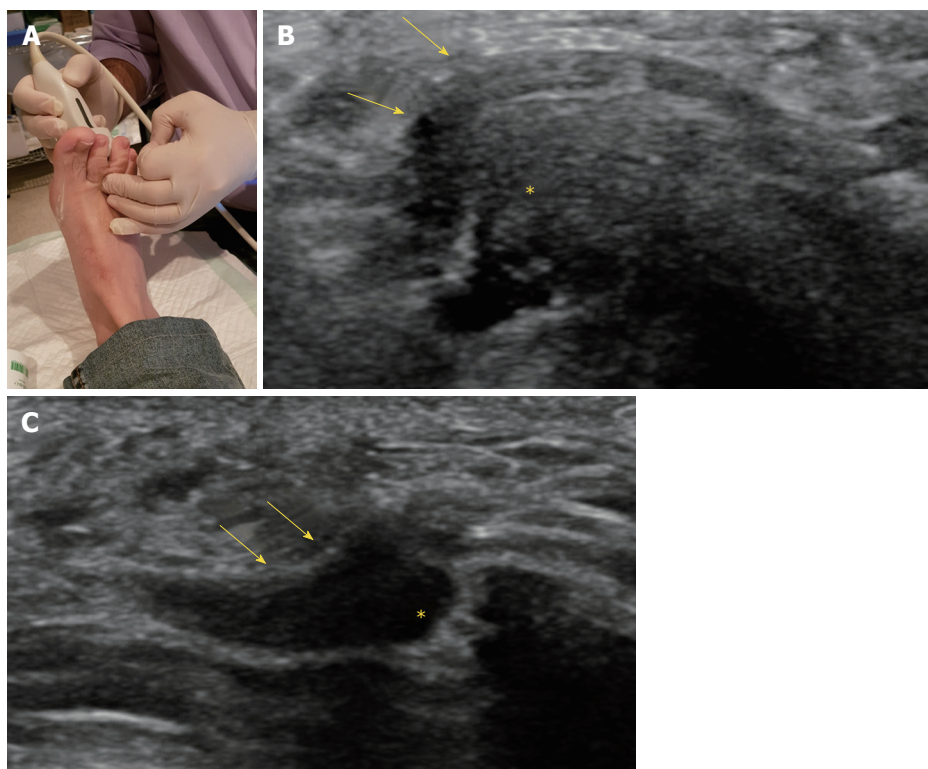


**Figure 2** Imaging of the normal digital nerves. A, B: Long and short axis views of normal digital nerves (arrows) in magnetic resonance imaging (A) and ultrasound (US) (B); C, D: Long (C) and short (D) axis views of normal digital nerves (arrows) in US. In all images, arrows indicate normal digital nerve and asterisks (\*) indicate bursa.

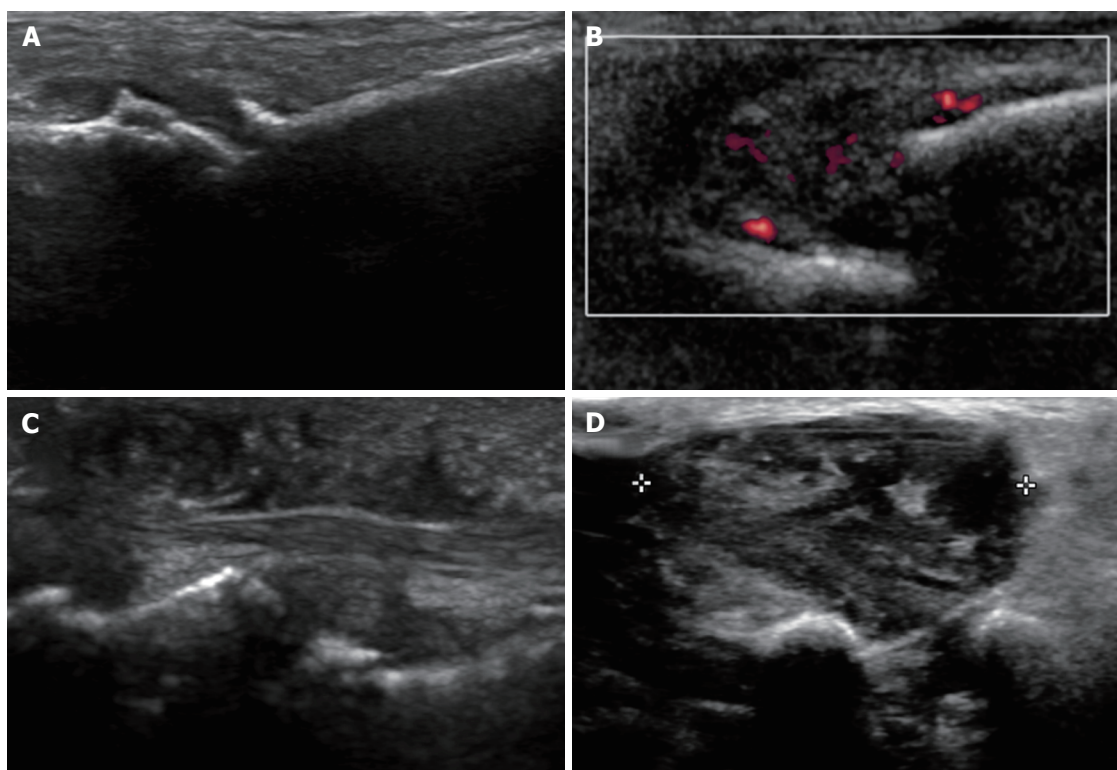


**Figure 3** Ultrasound imaging of Morton's neuroma. A: Clasp of the forefoot in the short axis view; B, C: Short axis views of the intermetatarsal space before (B) and after (C) squeezing the forefoot; D: Clasp of the forefoot in the long axis view; E, F: Long axis views of the intermetatarsal space before (E) and after (F) squeezing the forefoot. In all images, arrows indicate Morton's neuroma.





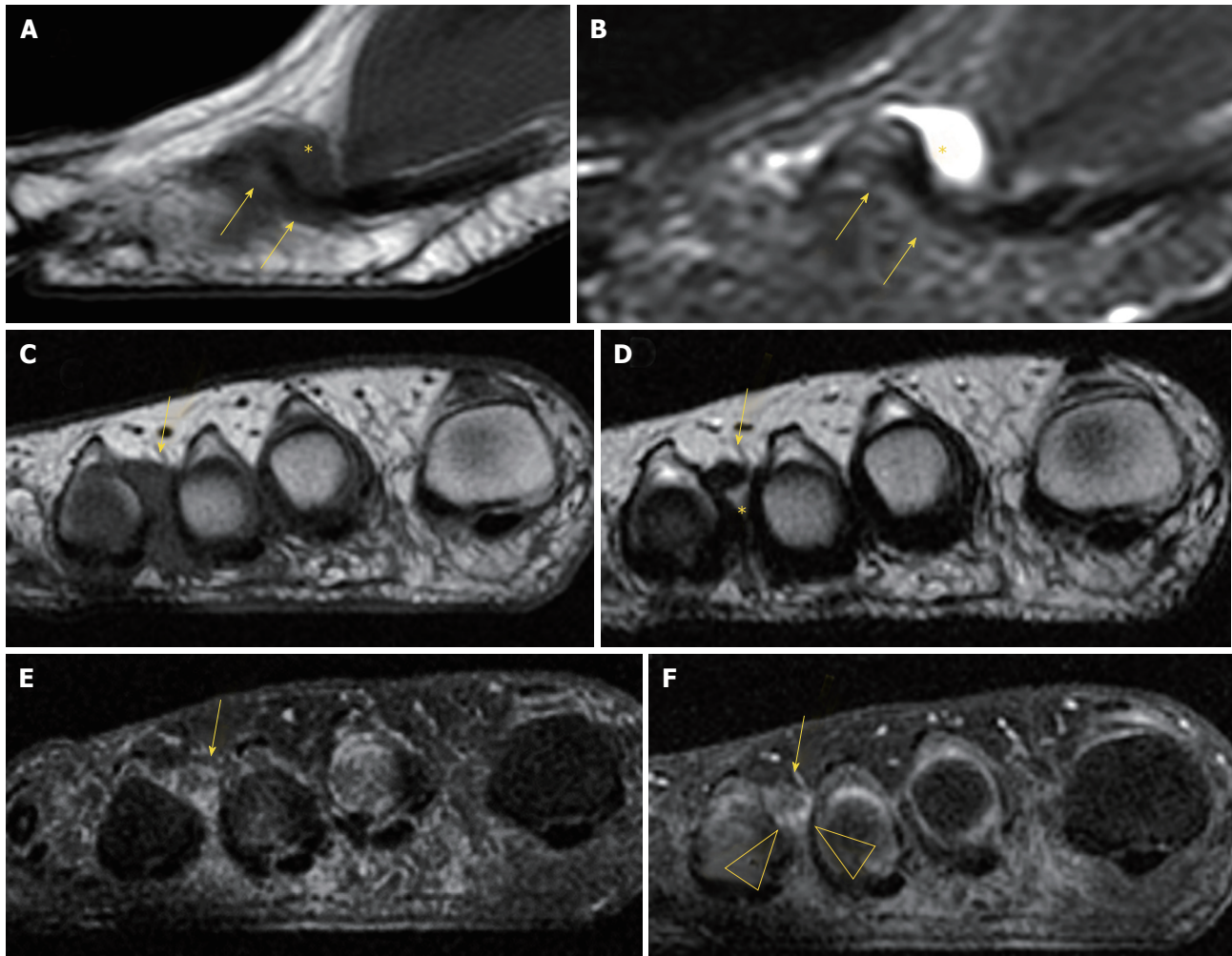
**Figure 4 Displacement of Morton's neuroma.** A: Pressure on the dorsal aspect of the web space; B, C: Long axis views of the neuroma and bursa before (B) and after (C) pressure of the dorsal aspect of the intermetatarsal space. In all images, arrows indicate Morton's neuroma and asterisks (\*) indicate bursa.



**Figure 5 Causes of forefoot pain.** A: Osteoarthritis; B: Rheumatoid arthritis with metatarsophalangeal joint subluxation; C: Psoriasis with soft tissue swelling; D: Giant cell tumor of the tendon sheath.

raise suspicion that it is not a neuroma<sup>[17]</sup>. If appropriate diagnosis is not achieved with imaging features alone,

biopsy under US guidance may help to obtain an accurate diagnosis (Figure 5).



**Figure 6** Magnetic resonance imaging of Morton's neuroma. A, B: Sagittal T1 (A) and short tau inversion recovery (B) of Morton's neuroma and bursa; C, D: Coronal T1 (C) and T2 (D) of Morton's neuroma and bursa. Coronal T1 fat before (A) and after gadolinium administration (B), showing enhancement of the bursal tissue surrounding the neuroma (arrowhead). In all images, arrows indicate Morton's neuroma and asterisks (\*) indicate bursa.

On MRI, MN is usually seen as a well-demarcated ovoid or dumbbell-shaped intermetatarsal mass. This mass shows intermediate to low signal intensity on both T1-weighted images (T1WI) and T2WI<sup>[18]</sup>. By contrast, bursal tissue appears hypo- or isointense on T1WI and hyperintense on T2WI, allowing for differentiation between bursal and neural tissues. There is no typical enhancement pattern of MN after intravenous administration of gadolinium contrast medium, with varying degrees of enhancement reported in the literature<sup>[19]</sup>; in our experience, however, the enhancement of most MN is low to zero. When present, this is usually due to the enhancement of the bursal tissue surrounding the neuroma. In the appropriate clinical setting, administration of gadolinium contrast medium is not required for a reliable diagnosis of MN (Figure 6).

MRI may also detect other causes of forefoot pain, including abnormalities of the bone (edema, fracture, erosion and cyst) and soft tissues (such as bursitis, synovitis, muscle edema and atrophy, and plantar plate

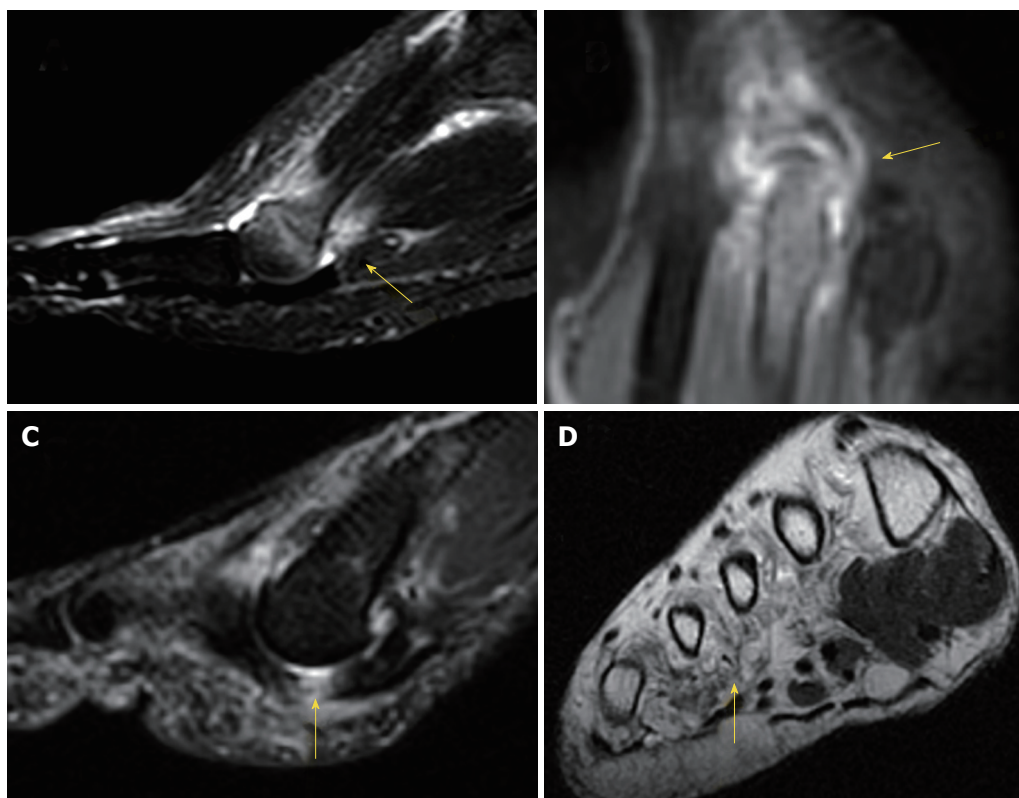
tears) (Figure 7).

## MN TREATMENT

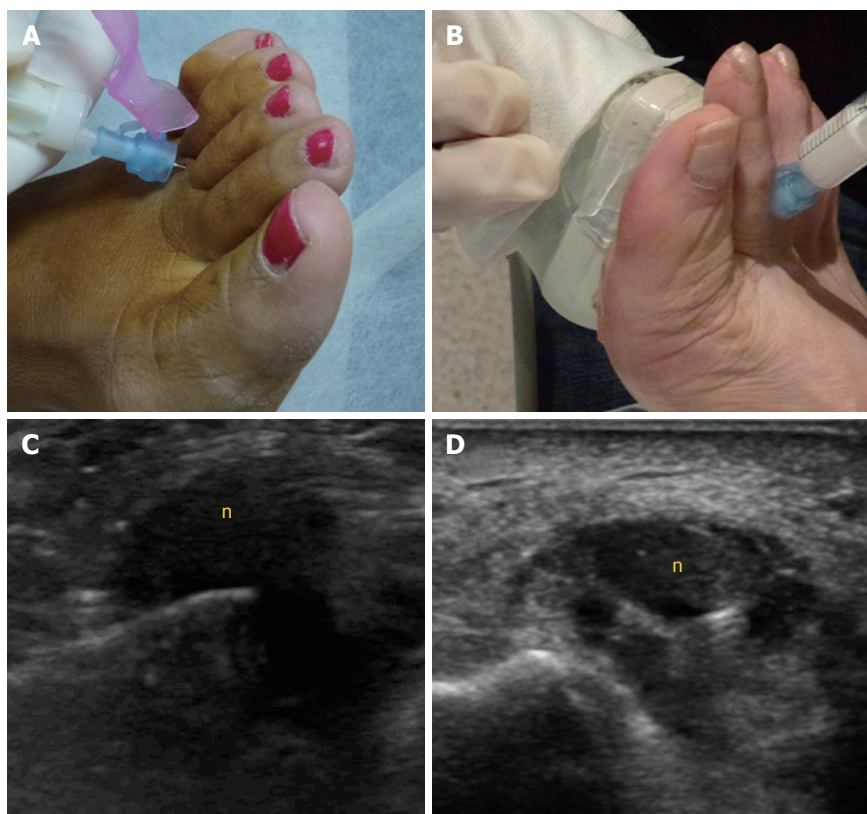
The treatment for MN should initially be conservative, including shoe modification, use of insoles and administration of antiinflammatory drugs. Percutaneous therapies may be the second step, and eventually surgery, if previous measures fail<sup>[2]</sup>. Success of conservative management approaches that include use of insoles and shoe modification has been reported to be around 48%<sup>[20]</sup>.

The percutaneous treatments mainly include injections of local anesthetics with or without steroids, or of alcohol. Percutaneous injection may be performed blindly or under US guidance (Figure 8). Studies of US-guided injections have shown that anesthetics with corticosteroids produce an effect (at 3 mo follow-up) that is superior to anesthetic injections alone<sup>[21]</sup>. Previous nonrandomized cohort studies have also shown





**Figure 7 Magnetic resonance imaging in forefoot pain.** A: Stress fracture of the 2<sup>nd</sup> metatarsal; B: Synovitis in rheumatoid arthritis; C: Plantar plate tear (arrow); D: Muscle atrophy in diabetes (arrow).



**Figure 8 Morton's neuroma injections.** A, B: Blind (A) and ultrasound (US)-guided (B) injections; C, D: Long (C) and short (D) axis views of an US-guided injection into a Morton's neuroma (denoted by "n").

a degree of improvement of about 45% for both blind and single US-guided injections<sup>[22]</sup>, and of around 75% to 80% for blind multiple injections<sup>[23]</sup>. We only found one study comparing the blind technique, based on anatomical landmarks, to the echo-guided technique. In that study, no significant differences were found between the injection methods, but the sample size (only 36 cases) constitutes a substantial limitation that might have prevented the study from reaching a statistically significant difference<sup>[24]</sup>.

Previous studies comparing modification of the forefoot loading area with injection of steroids have demonstrated greater pain improvement (at 6 mo follow-up) experienced by the steroid-treated group, but this difference disappeared at 1 year of follow-up<sup>[25]</sup>.

The influence of neuroma size on treatment response to injections has also been debated. One study showed that neuromas less than 5 mm had a better response at 6 mo than those greater than 5 mm; at 12 mo, however, the response to injections was no longer significantly different for the two size groups<sup>[26]</sup>. A recent retrospective case series study found a cut-off value of 6.3 mm, above which larger MNs failed to respond, as well as to corticosteroid injections<sup>[27]</sup>. Overall, most of the reported data in the literature do not support any influence of neuroma size on the outcome<sup>[23,24,28]</sup>.

Corticosteroids may cause dermal/subcutaneous tissue atrophy, hypopigmentation and fat necrosis, with reported incidence of 1%-5%<sup>[21,29]</sup> (Figure 9). Particulate steroids have greater dermal and subcutaneous tissue atrophy. Triamcinolone, in particular, has greater risk for inducing dermal changes than methylprednisolone, due to its increased crystal size<sup>[29]</sup>.

Other drugs used in MN treatment include alcohol, botulinum toxin and hyaluronic acid. Alcohol injection has a reported success range between 69%-84%, with a complication rate of 3%<sup>[30,31]</sup>. The most specific complication of this procedure has been plantar pain, presumed due to an inflammatory reaction secondary to perilesional leakage of the alcohol<sup>[30]</sup>. Case series using botulinum toxin<sup>[32]</sup> and hyaluronic acid<sup>[33]</sup> have shown clinical benefits of 70.6% and 84% respectively. Nevertheless, more studies are needed before considering these injections an alternative to the more traditional treatments.

Percutaneous radiofrequency ablation<sup>[34]</sup> has also been used in patients unresponsive to conservative therapies. The reported success with radiofrequency ranges from 68% to 100%, probably influenced by technical factors such as variability in the number of ablation cycles and in patient's inclusion criteria<sup>[34,35]</sup>. A case series using cryoablation showed that 77.7% of patients were completely satisfied following treatment, but this result needs to be confirmed by further prospective studies in order to be considered a valid alternative to radiofrequency ablation<sup>[36]</sup>. The global rate

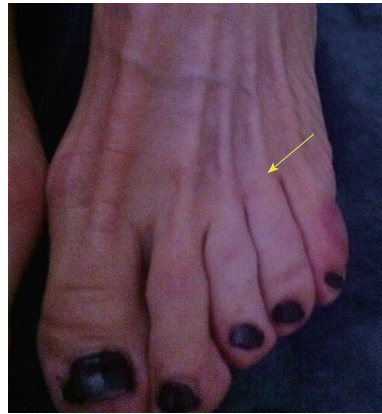


Figure 9 Skin discoloration after steroid injection.

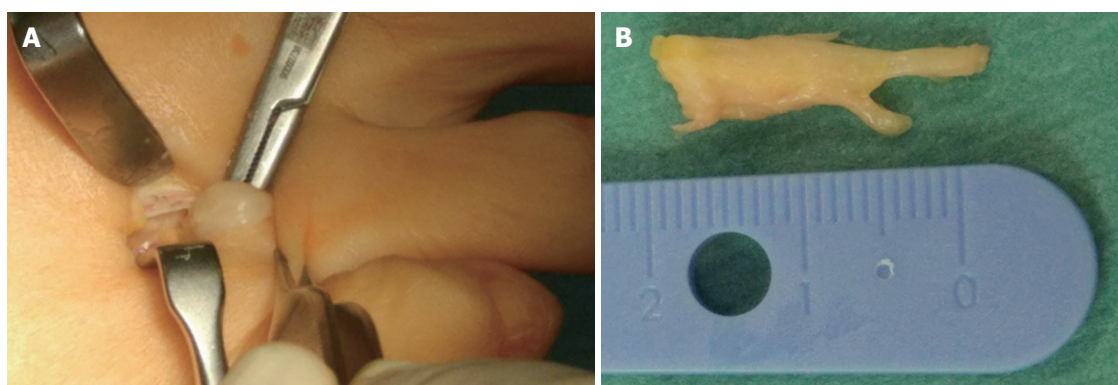
of complications with radiofrequency ablation is about 5%, including hematoma and persistent pain, followed by temporary nerve irritation and infection, as well as pain and numbness at the injection site<sup>[31]</sup>.

Surgical treatment is indicated after failure of conservative or percutaneous therapies. It consists of lesion excision (neurectomy) or intermetatarsal ligament resection (neurolysis) (Figure 10). Neurectomy may be performed either *via* a dorsal or plantar approach, according to surgeon preferences; no statistical differences in success rate have been reported. Surgical excision success ranges from 50% to 88%<sup>[31,37,38]</sup>, with a complication rate of 25% for neurectomy and 7% for neurolysis, which would include infection, hematoma, hammertoe formation, hypertrophic or keloid scar formation, complex regional pain syndrome, and persistent postoperative pain, numbness and stiffness of the metatarsophalangeal joints. Recurrent painful neuromas after surgery have been described in 4% of cases and are less responsive to further surgical intervention; conservative measures would then have to be used prior to the consideration of further surgery<sup>[31,39]</sup>.

A minimally invasive technique may be used for decompressing the nerve by division of the deep intermetatarsal ligament, either endoscopically or percutaneously. The reported success rate for decompression (sectioning of the deep transverse intermetatarsal ligament with/without osteotomy of the metatarsal heads) is around 94%, with a complication rate of 6%<sup>[31]</sup>.

In summary, controversies still exist in the appropriate management of MN, including for the diagnosis and treatment algorithms. Although the clinical diagnosis of MN has a high accuracy, the coexistence of MN with many another causes of forefoot pain increases the importance of imaging techniques in achieving an accurate diagnosis, mainly when initial conservative measures fail to obtain any clinical improvement. Surgery should be considered when imaging findings support the clinical diagnosis of MN and when conservative measures





**Figure 10** Surgical treatment of Morton's neuroma. A: Dorsal approach to Morton's neuroma; B: Surgical specimen.

including percutaneous treatment fail to improve the patient's symptoms.

## REFERENCES

- Peters PG, Adams SB Jr, Schon LC. Interdigital neuralgia. *Foot Ankle Clin* 2011; **16**: 305-315 [PMID: 21600450 DOI: 10.1016/j.facl.2011.01.010]
- Jain S, Mannan K. The diagnosis and management of Morton's neuroma: a literature review. *Foot Ankle Spec* 2013; **6**: 307-317 [PMID: 23811947 DOI: 10.1177/1938640013493464]
- Kasperek M, Schneider W. Surgical treatment of Morton's neuroma: clinical results after open excision. *Int Orthop* 2013; **37**: 1857-1861 [PMID: 23851648 DOI: 10.1007/s00264-013-2002-6]
- Jones JR, Klenerman L. A study of the communicating branch between the medial and lateral plantar nerves. *Foot Ankle* 1984; **4**: 313-315 [PMID: 6735288 DOI: 10.1177/107110078400400608]
- Mahadevan D, Venkatesan M, Bhatt R, Bhatia M. Diagnostic Accuracy of Clinical Tests for Morton's Neuroma Compared With Ultrasonography. *J Foot Ankle Surg* 2015; **54**: 549-553 [PMID: 25432459 DOI: 10.1053/j.jfas.2014.09.021]
- Valero J, Gallart J, González D, Deus J, Lahoz M. Multiple interdigital neuromas: a retrospective study of 279 feet with 462 neuromas. *J Foot Ankle Surg* 2015; **54**: 320-322 [PMID: 25128316 DOI: 10.1053/j.jfas.2014.05.011]
- Levitsky KA, Alman BA, Jevsevar DS, Morehead J. Digital nerves of the foot: anatomic variations and implications regarding the pathogenesis of interdigital neuroma. *Foot Ankle* 1993; **14**: 208-214 [PMID: 8359767 DOI: 10.1177/107110079301400406]
- Thompson FM, Deland JT. Occurrence of two interdigital neuromas in one foot. *Foot Ankle* 1993; **14**: 15-17 [PMID: 8425725 DOI: 10.1177/107110079301400103]
- Symeonidis PD, Iselin LD, Simmons N, Fowler S, Dracopoulos G, Stavrou P. Prevalence of interdigital nerve enlargements in an asymptomatic population. *Foot Ankle Int* 2012; **33**: 543-547 [PMID: 22835390 DOI: 10.3113/FAI.2012.0543]
- Bencardino J, Rosenberg ZS, Beltran J, Liu X, Marty-Delfaut E. Morton's neuroma: is it always symptomatic? *AJR Am J Roentgenol* 2000; **175**: 649-653 [PMID: 10954445 DOI: 10.2214/ajr.175.3.1750649]
- Owens R, Gougoulas N, Guthrie H, Sakellariou A. Morton's neuroma: clinical testing and imaging in 76 feet, compared to a control group. *Foot Ankle Surg* 2011; **17**: 197-200 [PMID: 21783084 DOI: 10.1016/j.fas.2010.07.002]
- Xu Z, Duan X, Yu X, Wang H, Dong X, Xiang Z. The accuracy of ultrasonography and magnetic resonance imaging for the diagnosis of Morton's neuroma: a systematic review. *Clin Radiol* 2015; **70**: 351-358 [PMID: 25466436 DOI: 10.1016/j.crad.2014.10.017]
- Nissen KI. Plantar digital neuritis; Morton's metatarsalgia. *J Bone Joint Surg Br* 1948; **30B**: 84-94 [PMID: 18864949 DOI: 10.1302/301-620X.30B1.84]
- Bigotti B, Signori A, Sormani MP, Molfetta L, Martinoli C, Tagliafico A. Ultrasound versus magnetic resonance imaging for Morton neuroma: systematic review and meta-analysis. *Eur Radiol* 2015; **25**: 2254-2262 [PMID: 25809742 DOI: 10.1007/s00330-015-3633-3]
- Torriani M, Kattapuram SV. Technical innovation. Dynamic sonography of the forefoot: The sonographic Mulder sign. *AJR Am J Roentgenol* 2003; **180**: 1121-1123 [PMID: 12646466 DOI: 10.2214/ajr.180.4.1801121]
- Simmons DN. Imaging of the Painful Forefoot. *Techniques in Foot Ankle Surgery* 2008; **7**: 238-249 [DOI: 10.1097/BTF.0b013e31818f3505]
- Quinn TJ, Jacobson JA, Craig JG, van Holsbeeck MT. Sonography of Morton's neuromas. *AJR Am J Roentgenol* 2000; **174**: 1723-1728 [PMID: 10845513 DOI: 10.2214/ajr.174.6.1741723]
- Weishaupt D, Treiber K, Kundert HP, Zollinger H, Vienne P, Hodler J, Willmann JK, Marincek B, Zanetti M. Morton neuroma: MR imaging in prone, supine, and upright weight-bearing body positions. *Radiology* 2003; **226**: 849-856 [PMID: 12601213 DOI: 10.1148/radiol.2263011925]
- Van Hul E, Vanhoenacker F, Van Dyck P, De Schepper A, Parizel PM. Pseudotumoral soft tissue lesions of the foot and ankle: a pictorial review. *Insights Imaging* 2011; **2**: 439-452 [PMID: 22347966 DOI: 10.1007/s13244-011-0087-2]
- Kilmartin TE, Wallace WA. Effect of pronation and supination orthosis on Morton's neuroma and lower extremity function. *Foot Ankle Int* 1994; **15**: 256-262 [PMID: 7951964 DOI: 10.1177/107110079401500505]
- Thomson CE, Beggs I, Martin DJ, McMillan D, Edwards RT, Russell D, Yeo ST, Russell IT, Gibson JN. Methylprednisolone injections for the treatment of Morton neuroma: a patient-blinded randomized trial. *J Bone Joint Surg Am* 2013; **95**: 790-798, S1 [PMID: 23636185 DOI: 10.2106/JBJS.I.01780]
- Hassouna H, Singh D, Taylor H, Johnson S. Ultrasound guided steroid injection in the treatment of interdigital neuralgia. *Acta Orthop Belg* 2007; **73**: 224-229 [PMID: 17515235]
- Greenfield J, Rea J Jr, Ilfeld FW. Morton's interdigital neuroma. Indications for treatment by local injections versus surgery. *Clin Orthop Relat Res* 1984; **142**: 144 [PMID: 6200264]
- Mahadevan D, Attwal M, Bhatt R, Bhatia M. Corticosteroid injection for Morton's neuroma with or without ultrasound guidance: a randomised controlled trial. *Bone Joint J* 2016; **98-B**: 498-503 [PMID: 27037432 DOI: 10.1302/0301-620X.98B4.36880]
- Saygi B, Yildirim Y, Saygi EK, Kara H, Esemeli T. Morton neuroma: comparative results of two conservative methods. *Foot Ankle Int* 2005; **26**: 556-559 [PMID: 16045848 DOI: 10.1177/107110070502600711]
- Makki D, Haddad BZ, Mahmood Z, Shahid MS, Pathak S, Garnham I. Efficacy of corticosteroid injection versus size of plantar interdigital neuroma. *Foot Ankle Int* 2012; **33**: 722-726 [PMID: 22995258 DOI: 10.3113/FAI.2012.0722]
- Park YH, Lee JW, Choi GW, Kim HJ. Risk factors and the



- associated cutoff values for failure of corticosteroid injection in treatment of Morton's neuroma. *Int Orthop* 2018; **42**: 323-329 [PMID: 29230531 DOI: 10.1007/s00264-017-3707-8]
- 28 **Markovic M**, Crichton K, Read JW, Lam P, Slater HK. Effectiveness of ultrasound-guided corticosteroid injection in the treatment of Morton's neuroma. *Foot Ankle Int* 2008; **29**: 483-487 [PMID: 18510900 DOI: 10.3113/FAI.2008.0483]
  - 29 **van Vendeloo SN**, Ettema HB. Skin depigmentation along lymph vessels of the lower leg following local corticosteroid injection for interdigital neuroma. *Foot Ankle Surg* 2016; **22**: 139-141 [PMID: 27301735 DOI: 10.1016/j.fas.2016.01.002]
  - 30 **Hughes RJ**, Ali K, Jones H, Kendall S, Connell DA. Treatment of Morton's neuroma with alcohol injection under sonographic guidance: follow-up of 101 cases. *AJR Am J Roentgenol* 2007; **188**: 1535-1539 [PMID: 17515373 DOI: 10.2214/AJR.06.1463]
  - 31 **Valisena S**, Petri GJ, Ferrero A. Treatment of Morton's neuroma: A systematic review. *Foot Ankle Surg* 2017; pii: S1268-7731(17)30065-6 [PMID: 29409240 DOI: 10.1016/j.fas.2017.03.010]
  - 32 **Climent JM**, Mondéjar-Gómez F, Rodríguez-Ruiz C, Díaz-Llopis I, Gómez-Gallego D, Martín-Medina P. Treatment of Morton neuroma with botulinum toxin A: a pilot study. *Clin Drug Investig* 2013; **33**: 497-503 [PMID: 23740337 DOI: 10.1007/s40261-013-0090-0]
  - 33 **Lee K**, Hwang IY, Ryu CH, Lee JW, Kang SW. Ultrasound-Guided Hyaluronic Acid Injection for the Management of Morton's Neuroma. *Foot Ankle Int* 2018; **39**: 201-204 [PMID: 29153007 DOI: 10.1177/1071100717739578]
  - 34 **Masala S**, Cuzzolino A, Morini M, Raguso M, Fiori R. Ultrasound-Guided Percutaneous Radiofrequency for the Treatment of Morton's Neuroma. *Cardiovasc Intervent Radiol* 2018; **41**: 137-144 [PMID: 28956110 DOI: 10.1007/s00270-017-1786-y]
  - 35 **Finney W**, Wiener SN, Catanzariti F. Treatment of Morton's neuroma using percutaneous electrocoagulation. *J Am Podiatr Med Assoc* 1989; **79**: 615-618 [PMID: 2625669 DOI: 10.7547/87507315-79-12-615]
  - 36 **Cazzato RL**, Garmon J, Ramamurthy N, Tsoumakidou G, Caudrelier J, Thenint MA, Rao P, Koch G, Gangi A. Percutaneous MR-Guided Cryoablation of Morton's Neuroma: Rationale and Technical Details After the First 20 Patients. *Cardiovasc Intervent Radiol* 2016; **39**: 1491-1498 [PMID: 27189181 DOI: 10.1007/s00270-016-1365-7]
  - 37 **Mann RA**, Reynolds JC. Interdigital neuroma--a critical clinical analysis. *Foot Ankle* 1983; **3**: 238-243 [PMID: 6832668 DOI: 10.1177/107110078300300411]
  - 38 **Richardson DR**, Dean EM. The recurrent Morton neuroma: what now? *Foot Ankle Clin* 2014; **19**: 437-449 [PMID: 25129354 DOI: 10.1016/j.fcl.2014.06.006]
  - 39 **Johnson JE**, Johnson KA, Unni KK. Persistent pain after excision of an interdigital neuroma. Results of reoperation. *J Bone Joint Surg Am* 1988; **70**: 651-657 [PMID: 3392057 DOI: 10.2106/00004623-198870050-00003]

**P- Reviewer:** Bazeed MF, Cerwenka H, Razek AAKA

**S- Editor:** Ji FF **L- Editor:** A **E- Editor:** Song H





Published by **Baishideng Publishing Group Inc**  
7901 Stoneridge Drive, Suite 501, Pleasanton, CA 94588, USA  
Telephone: +1-925-223-8242  
Fax: +1-925-223-8243  
E-mail: [bpgoffice@wjgnet.com](mailto:bpgoffice@wjgnet.com)  
Help Desk: <http://www.f6publishing.com/helpdesk>  
<http://www.wjgnet.com>

