

# World Journal of *Cardiology*

*World J Cardiol* 2018 October 26; 10(10): 123-190



**EDITORIAL**

- 123 T-cells in myocardial infarction: Culprit instigators or mere effectors?

*Liberale L, Bonaventura A, Montecucco F*

**REVIEW**

- 127 Overview of coronary artery variants, aberrations and anomalies

*Kastellanos S, Aznaouridis K, Vlachopoulos C, Tsiamis E, Oikonomou E, Tousoulis D*

**MINIREVIEWS**

- 141 Chronic ischemic mitral valve regurgitation and surgical perspectives

*Altarabsheh SE, Deo SV, Rababa'h A, Obeidat YM, Haddad O*

**ORIGINAL ARTICLE****Observational Study**

- 145 Successful endovascular treatment in patients with acute thromboembolic ischemia of the lower limb including the crural arteries

*Giusca S, Raupp D, Dreyer D, Eisenbach C, Korosoglou G*

- 153 Incidental congenital coronary artery vascular fistulas in adults: Evaluation with adenosine-<sup>13</sup>N-ammonia PET-CT

*Said SAM, Agool A, Moons AHM, Basalus MWZ, Wagenaar NRL, Nijhuis RLG, Schroeder-Tanka JM, Slart RHJA*

**SYSTEMATIC REVIEW**

- 165 Undiscovered pathology of transient scaffolding remains a driver of failures in clinical trials

*Kharlamov AN*

**CASE REPORT**

- 187 Takotsubo syndrome - different presentations for a single disease: A case report and review of literature

*Fuensalida A, Cortés M, Gabrielli L, Méndez M, Martínez A, Martínez G*

**ABOUT COVER**

Editorial Board Member of *World Journal of Cardiology*, Mahesh Anantha-Narayanan, MD, Academic Fellow, Doctor, Division of Cardiovascular Sciences, University of Minnesota, Minneapolis, MN 55455, United States

**AIM AND SCOPE**

*World Journal of Cardiology* (*World J Cardiol*, *WJC*, online ISSN 1949-8462, DOI: 10.4330) is a peer-reviewed open access journal that aims to guide clinical practice and improve diagnostic and therapeutic skills of clinicians.

*WJC* covers topics concerning arrhythmia, heart failure, vascular disease, stroke, hypertension, prevention and epidemiology, dyslipidemia and metabolic disorders, cardiac imaging, pediatrics, nursing, and health promotion. Priority publication will be given to articles concerning diagnosis and treatment of cardiology diseases. The following aspects are covered: Clinical diagnosis, laboratory diagnosis, differential diagnosis, imaging tests, pathological diagnosis, molecular biological diagnosis, immunological diagnosis, genetic diagnosis, functional diagnostics, and physical diagnosis; and comprehensive therapy, drug therapy, surgical therapy, interventional treatment, minimally invasive therapy, and robot-assisted therapy.

We encourage authors to submit their manuscripts to *WJC*. We will give priority to manuscripts that are supported by major national and international foundations and those that are of great basic and clinical significance.

**INDEXING/ABSTRACTING**

*World Journal of Cardiology* (*WJC*) is now abstracted and indexed in Emerging Sources Citation Index (Web of Science), PubMed, PubMed Central, Scopus, China National Knowledge Infrastructure (CNKI), and Superstar Journals Database.

**EDITORS FOR THIS ISSUE**

**Responsible Assistant Editor:** *Xiang Li*  
**Responsible Electronic Editor:** *Yun-Xiao Jian Wu*  
**Proofing Editor-in-Chief:** *Lian-Sheng Ma*

**Responsible Science Editor:** *Ying Dou*  
**Proofing Editorial Office Director:** *Jin-Lei Wang*

**NAME OF JOURNAL**

*World Journal of Cardiology*

**ISSN**

ISSN 1949-8462 (online)

**LAUNCH DATE**

December 31, 2009

**FREQUENCY**

Monthly

**EDITORIAL BOARD MEMBERS**

All editorial board members resources online at <http://www.wjgnet.com/1949-8462/editorialboard.htm>

**EDITORIAL OFFICE**

Jin-Lei Wang, Director  
*World Journal of Cardiology*  
Baishideng Publishing Group Inc

7901 Stoneridge Drive, Suite 501, Pleasanton, CA 94588, USA

Telephone: +1-925-2238242

Fax: +1-925-2238243

E-mail: [editorialoffice@wjgnet.com](mailto:editorialoffice@wjgnet.com)

Help Desk: <http://www.f6publishing.com/helpdesk>

<http://www.wjgnet.com>

**PUBLISHER**

Baishideng Publishing Group Inc

7901 Stoneridge Drive, Suite 501,

Pleasanton, CA 94588, USA

Telephone: +1-925-2238242

Fax: +1-925-2238243

E-mail: [bpgooffice@wjgnet.com](mailto:bpgooffice@wjgnet.com)

Help Desk: <http://www.f6publishing.com/helpdesk>

<http://www.wjgnet.com>

**PUBLICATION DATE**

October 26, 2018

**COPYRIGHT**

© 2018 Baishideng Publishing Group Inc. Articles published by this Open-Access journal are distributed under the terms of the Creative Commons Attribution Non-commercial License, which permits use, distribution, and reproduction in any medium, provided the original work is properly cited, the use is non commercial and is otherwise in compliance with the license.

**SPECIAL STATEMENT**

All articles published in journals owned by the Baishideng Publishing Group (BPG) represent the views and opinions of their authors, and not the views, opinions or policies of the BPG, except where otherwise explicitly indicated.

**INSTRUCTIONS TO AUTHORS**

<http://www.wjgnet.com/bpg/gerinfo/204>

**ONLINE SUBMISSION**

<http://www.f6publishing.com>

## Takotsubo syndrome - different presentations for a single disease: A case report and review of literature

Alberto Fuensalida, Maurice Cortés, Luigi Gabrielli, Manuel Méndez, Alejandro Martínez, Gonzalo Martínez

Alberto Fuensalida, Maurice Cortés, Luigi Gabrielli, Manuel Méndez, Alejandro Martínez, Gonzalo Martínez, Division of Cardiovascular Diseases, Pontificia Universidad Católica de Chile, Santiago 833024, Metropolitana, Chile

ORCID number: Alberto Fuensalida (0000-0001-9936-2260); Maurice Cortés (0000-0002-3107-1982); Luigi Gabrielli (0000-0002-1551-7147); Manuel Méndez (0000-0003-4753-8943); Alejandro Martínez (0000-0002-6836-8990); Gonzalo Martínez (0000-0002-7120-855X).

**Author contributions:** Fuensalida A and Martinez G designed the report; Fuensalida A and Cortes M collected the clinical data; Gabrielli L performed the echocardiographies; Martinez A, Mendez M and G Martinez reviewed the coronary angiographies; Fuensalida A, Cortes M and Martinez G wrote the paper; Gabrielli L, Martinez A and Mendez M revised and commented the final manuscript.

**Supported by a CONICYT research Grant (FONDECYT Iniciación 11170205) for Dr Gonzalo Martínez**

**Informed consent statement:** All patients agreed to treatment and data collection by written consent at our institution.

**Conflict-of-interest statement:** The authors do not have any conflict of interest to report.

**CARE Checklist (2013) statement:** The authors have read the CARE Checklist (2013), and the manuscript was prepared and revised according to the CARE Checklist (2013).

**Open-Access:** This article is an open-access article which was selected by an in-house editor and fully peer-reviewed by external reviewers. It is distributed in accordance with the Creative Commons Attribution Non Commercial (CC BY-NC 4.0) license, which permits others to distribute, remix, adapt, build upon this work non-commercially, and license their derivative works on different terms, provided the original work is properly cited and the use is non-commercial. See: <http://creativecommons.org/licenses/by-nc/4.0/>

**Manuscript source:** Unsolicited manuscript

**Correspondence to:** Gonzalo Martínez, MD, MPhil, Assistant

Professor, Division of Cardiovascular Diseases, Pontificia Universidad Católica de Chile, Marcoleta 367, 2<sup>nd</sup> floor, Santiago 833024, Metropolitana, Chile. [gmartinezr@med.puc.cl](mailto:gmartinezr@med.puc.cl)  
Telephone: +56-223-543114

Received: June 5, 2018

Peer-review started: June 5, 2018

First decision: June 14, 2018

Revised: July 25, 2018

Accepted: July 22, 2018

Article in press: August 31, 2018

Published online: October 26, 2018

### Abstract

We report three cases of Takotsubo syndrome (TS) with atypical myocardial involvement. All three cases were triggered by physical or mental stress, resulting in transient myocardial compromise. However, the clinical presentation, localization and extent of myocardial damage varied in each case, ranging from low-risk acute chest pain to cardiogenic shock with low ejection fraction and dynamic obstruction of the left ventricular outflow tract. These cases outline the range of possible presentations of this rare entity and illustrate atypical forms of TS.

**Key words:** Coronary angiography; Acute coronary syndrome; Stress cardiomyopathy; Takotsubo syndrome

© The Author(s) 2018. Published by Baishideng Publishing Group Inc. All rights reserved.

**Core tip:** Although less frequent, atypical presentations of Takotsubo syndrome - different from the classical apical ballooning - need prompt recognition by physicians. In addition to being a diagnostic challenge, this malady can present with severe complications, such as cardiogenic shock, arrhythmias and others. Herein, we show the presentation and management of atypical cases, with emphasis on their clinical recognition.

Fuensalida A, Cortés M, Gabrielli L, Méndez M, Martínez A, Martínez G. Takotsubo syndrome - different presentations for a single disease: A case report and review of literature. *World J Cardiol* 2018; 10(10): 187-190 Available from: URL: <http://www.wjgnet.com/1949-8462/full/v10/i10/187.htm> DOI: <http://dx.doi.org/10.4330/wjc.v10.i10.187>

## INTRODUCTION

Takotsubo syndrome (TS) was described almost 3 decades ago as an entity mainly affecting older women (post menopause), triggered by emotional stress, with ST-segment elevation on the electrocardiogram and with a characteristic pattern of apical ballooning of the left ventricle<sup>[1-3]</sup>. However, it is currently recognized that TS may have a more heterogeneous presentation, affecting also men, with different electrocardiographic alterations and diverse patterns of myocardial compromise<sup>[4,5]</sup>. These atypical TS cases may comprise up to 18% of cases<sup>[4,5]</sup>.

We now describe three cases of atypical TS that presented at our institution and were managed by the authors between May 2014 and September 2016.

## CASE REPORTS

### Case 1

A 57-year-old man presented with irregular wide-complex tachyarrhythmia at 180 beats *per* minute during anaesthetic induction for elective pituitary macroadenoma surgery. He received intravenous (IV) propranolol and adenosine, after which he reverted to sinus rhythm. However, severe hemodynamic compromise ensued, requiring support with IV norepinephrine and pseudoephedrine. The electrocardiogram showed ST-segment depression from leads V1 to V5 and a transesophageal echocardiogram demonstrated diffuse left ventricular (LV) hypokinesis, with a left ventricular ejection fraction (LVEF) of 35%. Urgent coronary angiography showed absence of obstructive coronary artery disease in the epicardial arteries, whereas a LV angiogram confirmed an extensive area of akinesis involving the basal and middle segments of the anterior and inferior walls, with concomitant hyperkinesis of the apical segments (Figure 1A and 1B). An LVEF of 20% was estimated. Initial management included hemodynamic support with IV noradrenaline and dobutamine along with mechanical ventilation. Very rapid clinical improvement was evident and the patient was extubated 24 h after the event. High-sensitivity troponin peaked at 950 pg/mL. An echocardiogram performed 48 h later showed improvement in LVEF to 60%. Two months later, on beta-blockers, the macroadenoma was resected with no adverse events.

### Case 2

A 53-year-old woman with Parkinson's disease arrived to the emergency department complaining of rest

angina after suffering severe emotional stress while she was attending a trial in a police court, 4 h earlier. Electrocardiography showed sinus rhythm with antero-lateral ST-segment depression. Coronary angiography showed no obstructive disease in the epicardial coronary arteries and LV angiography revealed akinesis in the midventricular segments, with LVEF 60% (Figure 1C and D). High-sensitivity troponin peaked at 108 pg/mL. Trans-thoracic echocardiography at 24 h showed a normal size left ventricle with minimal infero-lateral hypokinesis and preserve global function. Three months later, echocardiography showed complete recovery of the infero-lateral defect.

### Case 3

A 70-year old female, with a prior history of hypertension and type-2 diabetes, presented to the emergency room with a 3-d history of intermittent oppressive chest pain, associated with dyspnoea and cough. On admission, she was tachycardic and hypotensive. The electrocardiogram showed sinus rhythm with ST-segment elevation in leads V1 to V4. Urgent coronary angiography revealed absence of obstructive coronary epicardial lesions and the left ventriculogram showed akinesis of the apex and anterior and inferior apical segments, associated with basal segment hypercontractility and severe mitral regurgitation (Figure 1D and F). The intraventricular pressure pullback showed a gradient at the level of the left ventricle outflow tract of 47 mmHg. She was urgently managed with intensive volume replacement with IV saline, resulting in a prompt recovery. Echocardiogram showed akinesis of the anterior and apical walls, with a LVEF of 45%. Peak high-sensitivity troponin was 240 pg/mL. Due to intense back pain and the presence of meningeal signs on physical examination, a magnetic resonance imaging of the spine was performed revealing spinal subarachnoid haemorrhage with a thrombosed aneurysm of the right posterior spinal artery at the T1-T2 level. She had uneventful neurological and cardiological recovery, and was discharged on beta-blockers, statins and acetylsalicylic acid. Follow-up echocardiogram at 1 mo showed complete recovery of the ventricular motion defect and a LVEF of 65%.

## DISCUSSION

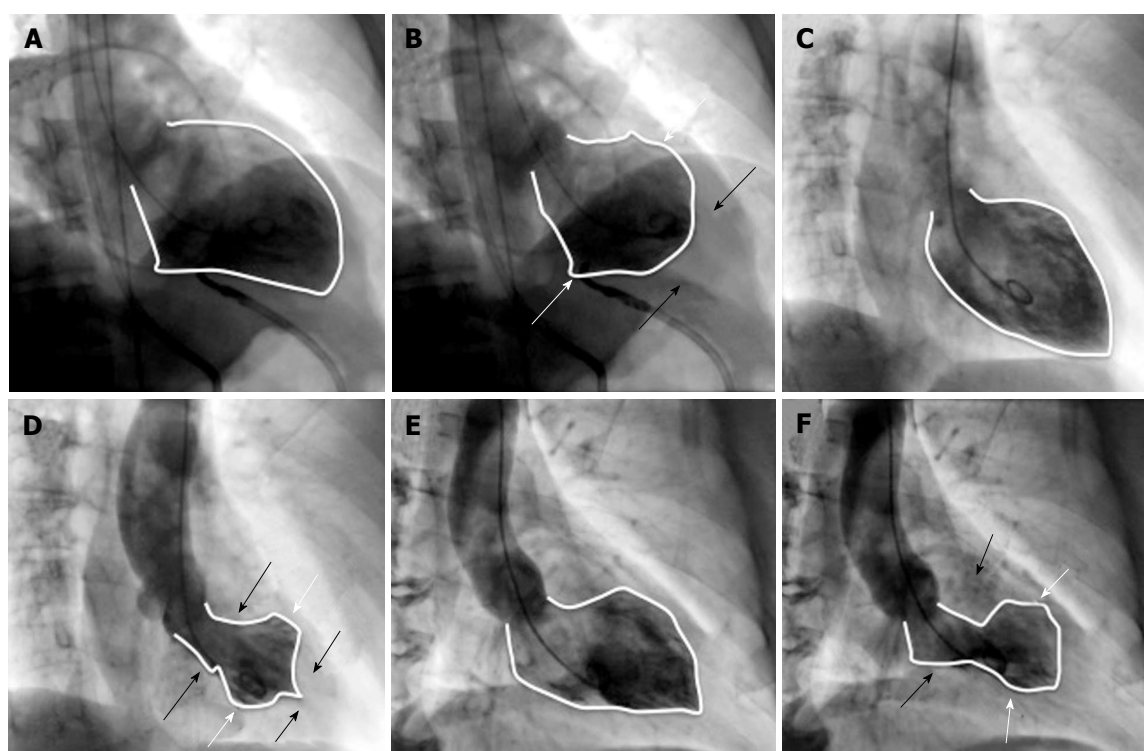
This case series highlights the heterogeneous clinical presentation of TS (Table 1). The affected myocardial segments were different in each case: (1) basal (or so called inverse TS); (2) midventricular and (3) apical with LV outflow tract obstruction and mitral regurgitation due to systolic anterior motion, secondary to hypercontractility of the basal segments. However, all three have in common the presence of a trigger factor (physical or emotional stress), dissociation between the magnitude of the myocardial damage extension and biomarker elevation, the absence of epicardial coronary disease on angiography and the complete or almost



**Table 1 Overview of clinical presentation of the 3 cases**

|        | Sex    | Age | Trigger                        | Clinical presentation                                   | ECG abnormalities                                      | Type of motility defect                         | LVEF | Peak hsTroponin | Follow-up | Recurrence |
|--------|--------|-----|--------------------------------|---------------------------------------------------------|--------------------------------------------------------|-------------------------------------------------|------|-----------------|-----------|------------|
| Case 1 | Male   | 57  | Surgery / Anesthetic induction | Ventricular arrhythmia and cardiogenic shock            | ST depression leads V1 to V5 QTc: 500 msec             | Basal                                           | 35%  | 950 pg/mL       | 15 mo     | No         |
| Case 2 | Female | 53  | Emotional stress               | Acute myocardial infarction without ST elevation        | ST depression leads V4 to V6, DI and aVL QTc: 490 msec | Midventricular                                  | 60%  | 108 pg/mL       | 38 mo     | No         |
| Case 3 | Female | 70  | Spinal aneurysm rupture        | Acute myocardial infarction with ST elevation and shock | 2 mm ST elevation leads V1 to V4 QTc: 510 msec         | Apical ballooning, LV outflow tract obstruction | 45%  | 240 pg/mL       | 16 mo     | No         |

ECG: Electrocardiography; hsTroponin: high-sensitivity troponin; LVEF: Left ventricular ejection fraction.



**Figure 1 Ventriculography of the 3 cases.** A and B are the ventriculography of case 1. A: LV at end diastole; B: LV at end systole with motion defect (white arrows show inferior and anterior basal hypokinesis; black arrows show hypercontractility of apical segments); LVEF: 20%. C and D are the ventriculography of case 2. C: LV at end diastole; D: LV at end systole with motion defect (white arrows show inferior and anterior midventricular hypokinesis; black arrows show hypercontractility of inferior and anterior basal and apical segments); LVEF: 60%. E and F are the ventriculography of case 3; E: LV at end diastole; F: LV at end systole with apical ballooning (white arrows show apical inferior and anterior hypokinesis; black arrows show inferior and anterior basal segments hypercontractility); LVEF: 45%, with severe mitral regurgitation. LV: Left ventricle; LVEF: Left ventricular ejection fraction.

complete recovery of the defect during follow-up.

The mechanisms resulting in TS are not yet fully understood, but the currently most accepted theories are transient myocardial dysfunction secondary to an exaggerated release of catecholamines, coronary vasospasm and transient microvascular dysfunction<sup>[3,6]</sup>.

The management of acute heart failure is the mainstay of treatment, and in some patients it is necessary to provide support with vasoactive drugs and/or ventricular assistance to achieve hemodynamic stability<sup>[6,7]</sup>. Once the acute episode has been

resolved, a favourable long-term prognosis is generally expected<sup>[3]</sup>, although recent reports have challenged this notion<sup>[8]</sup>. Some series suggest that this entity can have an estimated annual rate of 9.9% major events and 5.6% mortality<sup>[5]</sup>, in association with a recurrence risk of 5%-10%<sup>[6]</sup>. The magnitude of ventricular dysfunction is the main prognostic marker<sup>[4]</sup>, although factors influencing late prognosis have not yet been clearly defined.

It has been reported that atypical TS has a better prognosis than the common form, which theoretically

could be explained by the lesser amount of affected myocardium and better ventricular function<sup>[4]</sup>, although information regarding such cases is scarce. Finally, we believe that clinicians caring for patients with myocardial infarction should be familiar with these less common presentations of TS, which should be considered in patients with acute coronary syndromes without obstructive coronary disease and with cardiac enzyme elevations lower than expected in relation to the degree of apparent myocardial damage, particularly when triggered by obvious emotional or physical stress.

## ARTICLE HIGHLIGHTS

### Case characteristics

Patients presenting as acute coronary syndrome with left ventricular (LV) dysfunction, shock or LV outflow tract obstruction, and in whom no stenosis were found in angiography and full recovery of LV abnormality was achieved.

### Clinical diagnosis

Acute Coronary Syndrome, cardiogenic shock.

### Differential diagnosis

Acute coronary syndrome due to plaque rupture, spontaneous coronary artery dissection.

### Laboratory diagnosis

Elevated highsensitive troponin, electrocardiogram with different abnormalities such as ST depression and elevation, as well as ventricular arrhythmias.

### Imaging diagnosis

Coronary angiography with no coronary arteries stenosis. LV dysfunction with distinctive wall motion abnormalities not correlated to specific arterial segments. LV function recovery in follow-up echocardiogram.

### Treatment

Beta blockers, volume replacement.

### Related reports

Several reports of atypical cases with wall motion abnormalities different from apical ballooning. Retrospective study, InterTAK Registry, shows incidence about 10% to 18% of atypical cases.

### Term explanation

Takotsubo syndrome (TS) is a cardiomyopathy that simulate acute coronary syndrome, but no coronary abnormalities are present in angiography. Wall motion abnormality typically presents as apical ballooning, however, in some cases (as presented in this report) different LV segments might be affected.

### Experiences and lessons

Myocardial compromise in TS is not limited to the classical apical involvement and clinical presentations can range from life-threatening hemodynamic

compromise to low-risk chest pain. A normal coronary angiogram and discordant LV involvement are key diagnostic features. Prompt recognition of complications and subsequent treatment allow for a favourable prognosis.

## REFERENCES

- 1 Sato H, Tateishi H, Uchida T. Takotsubo-type cardiomyopathy due to multi-vessel spasm. In: Kodama K, Haze K, Hon M, editors. Clinical aspect of myocardial injury: from ischemia to heart failure. Tokyo: Kagakuhyouronsya; 1990: 56–64
- 2 Prasad A, Lerman A, Rihal CS. Apical ballooning syndrome (Tako-Tsubo or stress cardiomyopathy): a mimic of acute myocardial infarction. *Am Heart J* 2008; **155**: 408–417 [PMID: 18294473 DOI: 10.1016/j.ahj.2007.11.008]
- 3 Núñez Gil IJ, Andrés M, Almendro Delia M, Sionis A, Martín A, Bastante T, Córdoba Soriano JG, Linares Vicente JA, González Sucarrats S, Sánchez-Grande Flecha A; RETAKO investigators. Characterization of Tako-tsubo Cardiomyopathy in Spain: Results from the RETAKO National Registry. *Rev Esp Cardiol (Engl Ed)* 2015; **68**: 505–512 [PMID: 25544669 DOI: 10.1016/j.rec.2014.07.026]
- 4 Ghadri JR, Cammann VL, Napp LC, Jurisic S, Diekmann J, Bataiosu DR, Seifert B, Jaguszewski M, Sarcon A, Neumann CA, Geyer V, Prasad A, Bax JJ, Ruschitzka F, Lüscher TF, Templin C; International Takotsubo (InterTAK) Registry. Differences in the Clinical Profile and Outcomes of Typical and Atypical Takotsubo Syndrome: Data From the International Takotsubo Registry. *JAMA Cardiol* 2016; **1**: 335–340 [PMID: 27438117 DOI: 10.1001/jamacardio.2016.0225]
- 5 Templin C, Ghadri JR, Diekmann J, Napp LC, Bataiosu DR, Jaguszewski M, Cammann VL, Sarcon A, Geyer V, Neumann CA, Seifert B, Hellermann J, Schwyzer M, Eisenhardt K, Jenewein J, Franke J, Katus HA, Burgdorf C, Schunkert H, Moeller C, Thiele H, Bauersachs J, Tschöpe C, Schultheiss HP, Laney CA, Rajan L, Michels G, Pfister R, Ukena C, Böhm M, Erbel R, Cuneo A, Kuck KH, Jacobshagen C, Hasenfuss G, Karakas M, Koenig W, Rottbauer W, Said SM, Braun-Dullaues RC, Cuculi F, Banning A, Fischer TA, Vasankari T, Airaksinen KE, Fijalkowski M, Rynkiewicz A, Pawlak M, Opolski G, Dworakowski R, McCarthy P, Kaiser C, Osswald S, Galiuto L, Crea F, Dichtl W, Franz WM, Empen K, Felix SB, Delmas C, Lairez O, Erne P, Bax JJ, Ford I, Ruschitzka F, Prasad A, Lüscher TF. Clinical Features and Outcomes of Takotsubo (Stress) Cardiomyopathy. *N Engl J Med* 2015; **373**: 929–938 [PMID: 26332547 DOI: 10.1056/NEJMoa1406761]
- 6 Bybee KA, Prasad A. Stress-related cardiomyopathy syndromes. *Circulation* 2008; **118**: 397–409 [PMID: 18645066 DOI: 10.1161/CIRCULATIONAHA.106.677625]
- 7 De Backer O, Debonnaire P, Gevaert S, Missault L, Gheeraert P, Muyldermans L. Prevalence, associated factors and management implications of left ventricular outflow tract obstruction in takotsubo cardiomyopathy: a two-year, two-center experience. *BMC Cardiovasc Disord* 2014; **14**: 147 [PMID: 25339604 DOI: 10.1186/1471-2261-14-147]
- 8 Scally C, Rudd A, Mezincescu A, Wilson H, Srivanasan J, Horgan G, Broadhurst P, Newby DE, Henning A, Dawson DK. Persistent Long-Term Structural, Functional, and Metabolic Changes After Stress-Induced (Takotsubo) Cardiomyopathy. *Circulation* 2018; **137**: 1039–1048 [PMID: 29128863 DOI: 10.1161/CIRCULATIONAHA.117.031841]

P- Reviewer: Korosoglou G, Bagur R, Nurzynska D S- Editor: Dou Y

L- Editor: Filipodia E- Editor: Wu YXJ





Published by **Baishideng Publishing Group Inc**  
7901 Stoneridge Drive, Suite 501, Pleasanton, CA 94588, USA  
Telephone: +1-925-223-8242  
Fax: +1-925-223-8243  
E-mail: [bpgoffice@wjgnet.com](mailto:bpgoffice@wjgnet.com)  
Help Desk: <http://www.f6publishing.com/helpdesk>  
<http://www.wjgnet.com>

