


World Journal of *Cardiology*

World J Cardiol 2018 December 26; 10(12): 250-277



**EDITORIAL**

- 250** Risk of sudden cardiac death: Are coronary chronic total occlusions an additional risk factor?
Merinopoulos I, Corballis N, Eccleshall SC, Vassiliou VS

REVIEW

- 254** Cardiac implications of thrombotic thrombocytopenic purpura
Wiernek SL, Jiang B, Gustafson GM, Dai X

MINIREVIEWS

- 267** Instantaneous wave-free ratio (iFR®) to determine hemodynamically significant coronary stenosis: A comprehensive review
Baumann S, Chandra L, Skarga E, Renker M, Borggrefe M, Akin I, Lossnitzer D

ABOUT COVER

Editor-in-Chief of *World Journal of Cardiology*, Ramdas G Pai, FACC, FRCP (Hon), MD, Doctor, Professor, Director Cardiovascular Fellowship Program, Chair of Clinical Sciences, University of California Riverside School of Medicine, Riverside, CA 92507, United States

AIMS AND SCOPE

World Journal of Cardiology (*World J Cardiol*, *WJC*, online ISSN 1949-8462, DOI: 10.4330) is a peer-reviewed open access journal that aims to guide clinical practice and improve diagnostic and therapeutic skills of clinicians.

WJC covers topics concerning arrhythmia, heart failure, vascular disease, stroke, hypertension, prevention and epidemiology, dyslipidemia and metabolic disorders, cardiac imaging, pediatrics, etc. Priority publication will be given to articles concerning diagnosis and treatment of cardiology diseases. The following aspects are covered: Clinical diagnosis, laboratory diagnosis, differential diagnosis, imaging tests, pathological diagnosis, molecular biological diagnosis, immunological diagnosis, genetic diagnosis, etc. We encourage authors to submit their manuscripts to *WJC*.

We will give priority to manuscripts that are supported by major national and international foundations and those that are of great basic and clinical significance.

INDEXING/ABSTRACTING

World Journal of Cardiology (*WJC*) is now abstracted and indexed in Emerging Sources Citation Index (Web of Science), PubMed, PubMed Central, Scopus, China National Knowledge Infrastructure (CNKI), and Superstar Journals Database.

RESPONSIBLE EDITORS FOR THIS ISSUE

Responsible Electronic Editor: Han Song

Proofing Editorial Office Director: Jin-Lei Wang

NAME OF JOURNAL

World Journal of Cardiology

ISSN

ISSN 1949-8462 (online)

LAUNCH DATE

December 31, 2009

FREQUENCY

Monthly

EDITORS-IN-CHIEF

Marco Ciccone, Ramdas G Pai, Dimitrios Tousoulis

EDITORIAL BOARD MEMBERS

<https://www.wjnet.com/1949-8462/editorialboard.htm>

EDITORIAL OFFICE

Jin-Lei Wang, Director

PUBLICATION DATE

December 26, 2018

COPYRIGHT

© 2018 Baishideng Publishing Group Inc

INSTRUCTIONS TO AUTHORS

<https://www.wjnet.com/bpg/gerinfo/204>

GUIDELINES FOR ETHICS DOCUMENTS

<https://www.wjnet.com/bpg/GerInfo/287>

GUIDELINES FOR NON-NATIVE SPEAKERS OF ENGLISH

<https://www.wjnet.com/bpg/gerinfo/240>

PUBLICATION MISCONDUCT

<https://www.wjnet.com/bpg/gerinfo/208>

ARTICLE PROCESSING CHARGE

<https://www.wjnet.com/bpg/gerinfo/242>

STEPS FOR SUBMITTING MANUSCRIPTS

<https://www.wjnet.com/bpg/GerInfo/239>

ONLINE SUBMISSION

<https://www.f6publishing.com>

Cardiac implications of thrombotic thrombocytopenic purpura

Szymon L Wiernek, Bo Jiang, Gregory M Gustafson, Xuming Dai

ORCID number: Szymon L. Wiernek (0000-0002-3140-3692); Bo Jiang (0000-0002-2741-4057); Gregory M. Gustafson (0000-0003-1965-7507); Xuming Dai (0000-0003-3092-9323).

Author contributions: Wiernek SL searched and reviewed literature, wrote the initial draft and participated revisions; Jiang B searched and reviewed literature, participated manuscript writing and revisions; Gustafson GM carefully reviewed the content of the manuscript, participated revisions, in particular, focused on language editing; Dai X initiated and proposed manuscript concept, participated literature search and review, wrote and revised manuscript as a senior author.

Conflict-of-interest statement: All authors declared no potential conflicts of interest relevant to this manuscript.

Open-Access: This is an open-access article that was selected by an in-house editor and fully peer-reviewed by external reviewers. It is distributed in accordance with the Creative Commons Attribution Non Commercial (CC BY-NC 4.0) license, which permits others to distribute, remix, adapt, build upon this work non-commercially, and license their derivative works on different terms, provided the original work is properly cited and the use is non-commercial. See: <http://creativecommons.org/licenses/by-nc/4.0/>

Manuscript source: Invited manuscript

Received: August 28, 2018

Peer-review started: August 28,

Szymon L Wiernek, Bo Jiang, Division of Cardiology, McAllister Heart Institute, University of North Carolina at Chapel Hill, Chapel Hill, NC 27599, United States

Gregory M Gustafson, Xuming Dai, Division of Cardiology, Lang Research Center, New York Presbyterian Medical Group – Queens Hospital, Flushing, NY 11355, United States

Corresponding author to: Xuming Dai, FACC, MD, PhD, Attending Doctor, Division of Cardiology, New York Presbyterian Medical Group – Queens, 56-45 Main Street, Flushing, NY 11355, United States. xud9002@nyp.org

Telephone: +1-718-6701724

Fax: +1-718-4457473

Abstract

Thrombotic thrombocytopenic purpura (TTP) is a multisystem disorder that essentially can affect any organ in the human body. The hallmark of the pathogenesis in TTP is the large von Willebrand factor multimers on platelet-mediated micro-thrombi formation, leading to microvascular thrombosis. Autopsy studies showed that cardiac arrest and myocardial infarction are the most common immediate causes of death in these patients. Clinical manifestations of cardiac involvement in TTP vary dramatically, from asymptomatic elevation of cardiac biomarkers, to heart failure, MI and sudden cardiac death. There is limited knowledge about optimal cardiac evaluation and management in patients with TTP. The absence of typical cardiac symptoms, combined with complicated multi-organ involvement in TTP, may contribute to the under-utilization of cardiac evaluation and treatment. Prompt diagnosis and timely initiation of effective therapy could be critically important in selected cases. Based on our experience and this review of the literature, we developed several recommendations for focused cardiac evaluation for patients with acute TTP: (1) patients with suspected or confirmed TTP should be screened for the potential presence of cardiac involvement with detailed history and physical, electrocardiogram and cardiac enzymes; (2) clinical deterioration of TTP patients warrants immediate cardiac reevaluation; (3) TTP patients with clinical evidence of cardiac involvement should be monitored for telemetry, cardiac biomarkers and evaluated with transthoracic echocardiography. These patients require urgent targeted TTP treatment as well as cardiac-specific treatment. Aspirin therapy is indicated for all TTP patients. Since epicardial coronary artery involvement is rare, cardiac catheterization is usually not required, given the high risk for hemorrhage and kidney injury; (4) we recommend evidence-based medical therapy for ischemic symptoms and heart failure. TTP patients with evidence of cardiac involvement would also benefit from routine cardiology follow up during remission.

2018

First decision: October 16, 2018**Revised:** November 20, 2018**Accepted:** November 26, 2018**Article in press:** November 26, 2018**Published online:** December 26, 2018**Key words:** Thrombotic thrombocytopenic purpura; Acute myocardial infarction; Coronary artery disease; Anti-platelet therapy; von Willebrand factor; ADAMTS13**©The Author(s) 2018.** Published by Baishideng Publishing Group Inc. All rights reserved.

Core tip: Thrombotic thrombocytopenic purpura (TTP) is a grave medical condition caused by the formation of von Willebrand factor multimers that cause large platelet plugs and diffuse microemboli, leading to life-threatening, multi-organ ischemic injuries. Although cardiac involvement commonly occurs related to TTP, these cardiac manifestations have not been well studied and may thus be overlooked in clinical practice. Management of cardiac ischemia or myocardial infarction in TTP is also challenging due to increased hemorrhagic risk in the setting of thrombocytopenia. In this report, we systematically review available clinical data in the literature and summarize clinical manifestation, diagnostic workup strategies, prognosis, and the outcomes of cardiac involvement of TTP. We provide recommendations on the strategies for clinical assessment and management of TTP patients with cardiac involvement.

Wiernek SL, Jiang B, Gustafson GM, Dai X. Cardiac implications of thrombotic thrombocytopenic purpura. *World J Cardiol* 2018; 10(12): 254-266

URL: <https://www.wjgnet.com/1949-8462/full/v10/i12/254.htm>

DOI: <https://dx.doi.org/10.4330/wjc.v10.i12.254>

INTRODUCTION

Thrombotic thrombocytopenic purpura (TTP) is characterized by the concomitant occurrence of severe thrombocytopenia, microangiopathic hemolytic anemia (MAHA), and a variable degree of ischemic end organ damage. The pathophysiology is elicited by microthrombi forming in the arterioles and capillaries of multiple organs throughout the body. These thrombi are caused by systemic platelet activation and aggregation due to a failure of degradation of unfolded high molecular weight large von Willebrand factor (vWF). These microthrombi deposit systemically and cause widespread organ dysfunction, including pancreas, adrenals, heart, brain, and kidneys. As a result, the patient may present with acute kidney injury, stroke, seizure, or myocardial infarction (MI)^[1,2]. The cardiac manifestations of TTP can be variable, ranging from silent arterial thrombosis and accelerated hypertension, to acute MI (AMI), atrial fibrillation, and congestive heart failure (CHF). In addition, these platelet and coagulation abnormalities can also be seen in cyanotic congenital heart disease.

PATHOPHYSIOLOGY AND CLINICAL MANIFESTATIONS OF TTP

The center of TTP pathophysiology is a defect of a disintegrin and metalloproteinase with a thrombospondin type 1 motif member 13 (ADAMTS13), either genetically or by the development of an autoantibody. ADAMTS13, also known as vWF-cleaving protease, is a zinc-containing metalloprotease enzyme that cleaves vWF. ADAMTS13 is a 1,427 amino acid protein that is expressed predominately in hepatic stellate cells, podocytes, renal tubular epithelial cells, platelets, and endothelial cells^[1]. vWF is synthesized by megakaryocytes and endothelial cells, and is stored in the form of ultra-large multimers in granules of platelets, Weibel-Palade bodies of endothelial cells, and subendothelial connective tissue. ADAMTS13 cleaves a single peptide bond (Tyr1605-Met1606) located within the central vWF A2 domain. The proteolysis process reduces vWF multimer size and, consequently, its hemostatic function^[3,4]. Lack or loss of ADAMTS13 function results in increased circulating vWF multimers, which leads to platelet adhesion to the endothelium, platelet activation, and ultimately the formation of a platelet plug.

Depending on the mechanisms of ADAMTS13 inhibition, TTP is divided into 1) an acquired form, which arises from autoantibody-mediated ADAMTS13 inhibition, and 2) a relatively rare inherited form, which results from an autosomal recessive gene mutation causing innate ADAMTS13 dysfunction. As microthrombi form, especially where arterioles and capillaries meet, end organ ischemia and injury occur due to

vascular obstructions caused by the microthrombi. In addition, the circulating red blood cells are subjected to increased shear stress, which damages their membranes, leading to schistocyte formation and anemia.

Clinically, TTP can be manifested systemically due to the involvement of multiple organs^[5]. The classic presentation of TTP includes the following pentad: fever, changes in mental status, thrombocytopenia, reduced kidney function, and MAHA. MAHA and thrombocytopenia are hallmarks of TTP, and the possibility of TTP should be evaluated in any patients who present with these findings and who do not have an apparent alternative explanation.

CLINICAL CARDIAC INVOLVEMENT OF TTP

Extensive cardiac involvement was reported in the first TTP patient in 1925. This patient showed T wave inversions on the electrocardiogram (ECG) and extensive thrombi in the terminal arterioles and capillaries of the heart, as confirmed by autopsy examination^[6]. Subsequently, the heart was found to be the most commonly affected organ in TTP. Additional autopsy studies of deceased patients with TTP showed that cardiac arrest and AMI are the most common immediate causes of death^[7].

Clinical manifestations of cardiac involvement in TTP can vary dramatically, from an asymptomatic elevation of cardiac biomarkers, to chest pain or heart failure symptoms associated with ECG changes, elevation of cardiac enzymes, imaging evidence of massive MI, cardiomyopathy, arrhythmia, or even sudden cardiac death (SCD)^[8-11].

Elevated cardiac troponin (cTn) was reported in 59% of patients with TTP upon admission. However, the majority of this group was clinically silent from a cardiac standpoint. ECG changes are common in TTP patients with elevated cardiac enzymes^[12]. Hawkins *et al*^[9] performed extensive analysis of 111 patients with TTP and reported the most common cardiac symptoms to be chest pain (11.7%), CHF (9.0%), and syncope (0.9%). The most frequent cardiac events in those patients included MI (23.4%), CHF (15.3%), arrhythmias (9.0%), cardiogenic shock (5.4%) and SCD (7.2%). AMI in TTP can present as ST segment elevation MI (STEMI) or non-STEMI with or without echocardiographic evidence of segmental wall motion abnormalities^[11]. Patients with AMI in the setting of TTP often developed arrhythmias such as atrial fibrillation (25%), atrial flutter (13%), supraventricular tachycardia (13%) and CHF (25%)^[8].

PATHOGENESIS AND AUTOPSY EVIDENCE OF CARDIAC COMPLICATIONS IN TTP

In TTP, the large vWF multimers mediate platelet plugs and microthrombi formation. Hyalinized arteriolar and microvascular microthrombosis in the coronary artery circulation has been shown in most autopsy reports. Microthrombosis is the most common finding of cardiac pathology in autopsies of deceased patients who suffered from TTP (Table 1). Epicardial coronary arterial thrombosis is rare. Large epicardial coronary arteries are commonly spared from thrombosis in TTP. However, recurrent epicardial arterial thrombosis has been reported in one TTP patient who was treated with thrombectomy, stent placement and dual antiplatelet therapy^[13]. The interaction between vWF multimer-mediated thrombosis with existing vulnerable plaques in concomitant atherosclerotic coronary artery disease (CAD) was postulated to induce the arterial thrombosis^[14]. Thus, arterial/arteriolar thrombosis leads to myocardial ischemia, infarction and necrosis. Thrombocytopenia and ischemia-induced damage of vascular integrity subsequently leads to myocardial hemorrhage. These processes not only lead to myocardial damage, but often cause dysfunction of the cardiac conduction system. In addition, marantic endocarditis has been reported^[7,10,12]. Also, James *et al*^[15] reported myocardial degeneration in atrial and ventricular myocardium in TTP patients as a result of apoptosis.

PROGNOSTIC VALUE OF CARDIAC INVOLVEMENT IN TTP

Post-mortem studies clearly demonstrated a high incidence of cardiac involvement in deceased TTP patients. Autopsy reports revealed almost all patients with TTP have cardiac involvement, and the disease process mostly affects the microvasculature of the heart. Cardiac complications directly cause death in TTP, particularly in acute

Table 1 Cardiac involvement and pathology in autopsy studies of deceased patients with thrombotic thrombocytopenia purpura

Authors	Year	Total No.	Descriptive comments of cardiac involvement and pathology			
			Microthrombi in small vessel (arteriole/capillaries)	Epicardial coronary thrombus	Hemorrhage petechiae	Other pathology
Moschcowitz ^[6]	1925	1	1/1	0/1	n/r	
Amorosi <i>et al</i> ^[45]	1966	3	3/3	1/3	3/3	AV node involvement 1/3
James <i>et al</i> ^[46]	1966	3	3/3	0/3	3/3	
Geisinger ^[47]	1979	1	1/1	0/1	1/1	
Ridolfi <i>et al</i> ^[48]	1979	17	17/17	0/17	13/17	AV node and his bundle involvement 7/17
Ross <i>et al</i> ^[49]	1987	1	1/1	0/1	1/1	
Bowdler <i>et al</i> ^[50]	1987	1	1/1	0/1	1/1	
Siersema <i>et al</i> ^[51]	1989	3	3/3	0/3	3/3	SA, AV node, His bundle involvement 3/3
Bell <i>et al</i> ^[52]	1990	8	8/8	0/8	8/8	SA and AV node involvement 2/3
Webb <i>et al</i> ^[53]	1990	1	1/1	0/1	1/1	
Eagle <i>et al</i> ^[54]	1994	1	1/1	0/1	1/1	
James <i>et al</i> ^[15]	1997	6	6/6	0/6	6/6	SA, AV nodes and His bundle involvement 6/6
Podolsky <i>et al</i> ^[55]	1999	1	1/1	0/1	1/1	AV node involvement 1/1
Wajima <i>et al</i> ^[56]	2000	1	1/1	0/1	1/1	
Hosler <i>et al</i> ^[57]	2003	25	25/25	n/r	n/r	
Lapp <i>et al</i> ^[23]	2004	1	1/1	0/1	1/1	
Brandenburg <i>et al</i> ^[58]	2004	1	1/1	0/1	1/1	
Gami <i>et al</i> ^[59]	2005	3	3/3	n/r	n/r	
Ibernon <i>et al</i> ^[60]	2005	1	0/1	1/1	1/1	
Arnold <i>et al</i> ^[61]	2006	1	1/1	0/1	1/1	
Patschan <i>et al</i> ^[10]	2006	4	4/4	0/4	2/4	
Sarode <i>et al</i> ^[62]	2009	1	1/1	n/r	n/r	
George <i>et al</i> ^[63]	2012	1	1/1	n/r	n/r	
Nichols <i>et al</i> ^[7]	2015	18	9/18	0/18	7/18	
Summary		104	94/104 (90.4%)	2/74 (2.7%)	56/73 (76.7%)	

AV: Atrioventricular; SA: Sinoatrial.

myocardial necrosis as a result of extensive circulatory microthrombosis. AMI and CHF are known independent risk factors for in-hospital mortality in patients with TTP^[16,17]. Elevated LDH and troponin at presentation were found to be independent risk factors for MI^[10]. cTn I above 2.5 ng/mL was found to independently predict mortality and refractory TTP. Therefore, evidence of cardiac involvement in TTP provides important prognostic value. A systematically structured approach to monitor signs and evidence of cardiac involvement may be cost-effective.

CARDIAC EVALUATION OF TTP

There is limited knowledge about optimal cardiac evaluation for patients with TTP. There are also large variations in clinical practice. Clinically, the majority of patients with TTP present without any clinical symptoms of myocardial ischemia. The traditional clinical pentad (fever, thrombocytopenia, microangiopathic anemia, neurological symptoms and acute kidney injury) of TTP does not include cardiac

symptoms. In current practice, cardiac evaluation is not part of routine initial evaluation for patients with suspected or confirmed TTP. The lack of or atypical cardiac symptoms in TTP may have contributed to the under-utilization of cardiac evaluation and delay in diagnosis. However, increasing data suggest that the presence of cardiac involvement in TTP strongly associates with an adverse outcome. Therefore, timely recognition and appropriate monitoring of cardiac status in TTP could be critically important in many cases. In recent decades, there have been dramatic advancements in laboratory, telemetry, non-invasive and invasive approaches of cardiac evaluation and therapeutics. The cost effectiveness and clinical significance of cardiac evaluation and therapeutics in TTP are thus important topics of discussion.

Cardiac biomarkers in TTP

Serial troponin-I or -T measurements are sensitive and specific biomarkers of myocardial injury. The overall incidence of troponin positivity in the TTP population has not been defined. However, multiple studies have shown that elevated troponin is a reliable biomarker for cardiac involvement in TTP. Elevated level of cTn upon admission is a risk factor for death and TTP refraction^[17]. It seems reasonable to recommend a routine troponin measurement when a diagnosis of TTP is suspected or clinical deterioration is observed.

Telemetry monitoring in TTP

Considering the fact that there are consistent correlations between poor clinical outcome and evidence of cardiac involvement in TTP, it would be reasonable to monitor the patient on telemetry if cardiac involvement is suspected, *i.e.* positive troponin, abnormal admission ECG, or echocardiographic evidence of cardiomyopathy^[18]. The evidence of cardiac conduction system involvement in TTP mandates telemetry monitoring. However, the cost-effectiveness of telemetry monitoring of all troponin-positive TTP patients has not been determined.

Cardiac imaging assessment of cardiac structure and function in TTP

Transthoracic echocardiography (TTE) is the most commonly used imaging modality to evaluate cardiac structure and function. In TTP patients with clinical symptoms, such as shortness of breath, palpitations, chest pain *etc.*, that suggest ischemia, heart failure, arrhythmia or hemodynamic/electrical instability, a TTE should be performed^[19]. TTE is also appropriate as an initial evaluation of cardiac structure and function in TTP patients with clinical data suggesting cardiac involvement, such as positive biomarkers (troponin, BNP *etc.*), abnormal ECG and telemetry monitoring. Currently, there is no data available documenting the utilization and outcomes of TTE studies for TTP patients. The cost-effectiveness has also not been determined. Transesophageal echocardiography (TEE) is often unnecessary and rarely recommended for TTP patients, as thrombocytopenia is known to elevate the bleeding risk. The benefit of imaging modalities, such as cardiac magnetic resonance imaging (MRI), for assessing the impact of TTP on cardiac structure and function has not been studied.

Ischemic workup in TTP

The hallmark of TTP pathogenesis is thrombus formation in the micro-circulation. Occlusion of this micro-circulation, or less commonly of the epicardial coronary circulation, directly causes myocardial ischemia. Clinical evidence of ischemic symptoms, elevated troponin, or decreased myocardial contraction are all suggestive of myocardial ischemia in TTP. However, methods that will reliably evaluate the etiology of ischemia in these patients have not been adequately investigated. Non-invasive imaging modalities, such as Doppler coronary artery blood flow velocity and myocardial contrast echocardiography, are considered cost effective methods that correspond well with invasive techniques, but they are used less frequently in routine cardiology practice. Their role in patients with TTP has not been studied. Positron emission tomography (PET) and cardiac MRI myocardial perfusion imaging studies both measure rest and stress myocardial blood flow and enable coronary flow reserve (CFR) quantification. Both modalities are well established for the detection of CAD-related ischemia, and for the evaluation of microvascular disease. Both are sensitive in detecting the heterogeneous distribution of microvascular defects, which may indicate microvascular disease^[20,21]. High resolution, ECG-gated cardiac computed tomography (CT) angiography (CTA) enables non-invasive imaging of the epicardial coronary arteries. Theoretically, CTA provides a reasonable approach to evaluate myocardial ischemia and the involvement of epicardial coronary arteries in TTP without the concern of bleeding risk associated with an invasive approach. However, its clinical significance has not been studied in this patient group.

In TTP, the high incidences of elevated cardiac enzymes and myocardial injury are mostly driven by ischemia at the level of the microvasculature. There are a few reports in the literature that describe using invasive coronary angiography to evaluate coronary artery patency in TTP patients^[10]. While the majority of TTP patients had no obstructive disease in their epicardial arteries, there is a report of a patient with angiographic documentation of epicardial artery occlusion in TTP^[22]. However, other TTP patients that presented with STEMI and cardiogenic shock were found to have clean coronary arteries on angiograms, with the visible “slow flow” phenomenon^[23]. Therefore, diagnostic testing in this population should focus more on microvasculature of the heart rather than the epicardial arteries, especially in patients who recover from an acute episode and remain symptomatic from a cardiac standpoint. ECG evidence of acute STEMI probably deserves evaluation of the large epicardial arteries either by CTA or, more accurately, by invasive coronary angiography with the associated increased risk of hemorrhage, renal insufficiency and/or exacerbation of pre-existing anemia.

For the purpose of risk stratification and planning of both clinical treatment and monitoring when TTP is diagnosed, cardiac involvement should be systematically evaluated by ECG, cTn, and echocardiography. Patients with positive initial cardiac workup should have an Echocardiogram done during initial hospitalization, as left ventricular (LV) dysfunction has been reported in several publications^[9]. A coronary angiogram may be indicated if concomitant atherosclerotic CAD is suspected based on risk profile and clinical features, but should be postponed if possible until the patient recovers from the TTP episode^[14].

TREATMENT FOR CARDIAC COMPLICATIONS IN TTP

Therapeutic plasma exchange (TPE) - removing circulating anti-ADAMTS13 antibodies - is the cornerstone of TTP treatment, which resulted in reduced mortality from approximately 90% to 10%-20%. Immunosuppression with steroids or rituximab appears to be efficacious for acquired TTP, resulting in autoantibody formation against ADAMTS13. Experimental agents, such as recombinant ADAMTS13^[24] as a specific protease supplement, and novel small molecules targeted on the vWF GpIb α -binding site on platelets are also promising therapies to further improve TTP treatment. In refractory TTP, other therapeutic approaches are also common, such as splenectomy, vincristine, cyclophosphamide, intravenous immunoglobulins, cyclosporine A, azathioprine, and mycophenolate mofetil, although there is not enough evidence yet to prove the efficacy of these treatment strategies. Platelet transfusion is generally not indicated; however, some authors recommend transfusing platelets in acute TTP episodes to decrease the risk of hemorrhage. As cardiac involvement is an integrated pathological process in TTP, general therapeutic strategies should also benefit the cardiac system.

Despite the recognition of the significant association between cardiac involvement and adverse clinical outcome in TTP, targeted management approaches for cardiac complications in TTP have not been well investigated. On the other hand, recent decades have seen significant advancements in evidenced-based medical and procedural treatments for acute coronary syndrome (ACS) and cardiomyopathy. Anecdotal case reports have successfully applied all the available therapeutic tools that have saved the lives of TTP patients with life-threatening cardiopulmonary complications. These reports have documented successful primary percutaneous coronary intervention (PCI) in the setting of ongoing STEMI with angiographic evidence of epicardial coronary artery occlusions^[22], thrombolytic therapy for massive pulmonary embolism or STEMI in the setting of TTP^[25,26], extracorporeal membrane oxygenation (ECMO) support for cardiogenic shock due to acute global ischemia resulted from diffuse microthrombi, to subsequent heart transplantation after the resolution of TTP^[27]. Hemodynamic support and targeted treatment for cardiac complications of TTP may provide the opportunity for TTP-targeted therapy to take effect and eventually improve mortality, particularly in cases of severe TTP with hemodynamically-compromising cardiac complications.

Treatment for ischemic injury

In general, the most common cause of acute ischemia injury to the myocardium is ACS, as a result of an acute atherothrombotic event in the coronary arteries. Antiplatelet and anticoagulation therapies aiming to terminate or reverse the thrombotic process are the main strategy to ameliorate ongoing ischemia. In TTP, thrombocytopenia with various degrees of microthrombosis is universal, and is directly responsible for most of the cardiac complications, especially myocardial

ischemia. Existing evidence suggests that the majority of these injuries are caused by microthrombosis in the microvascular beds and rarely involve large epicardial arteries. The safety and efficacy of antiplatelet and anticoagulation therapy in the setting of TTP and ongoing myocardial ischemia is still a topic of debate.

In current practice, antiplatelet therapy is always considered in patients with TTP to prevent microthrombi formation. Aspirin is generally recommended for TTP patients as an antiplatelet agent. The effectiveness and safety of other antiplatelet agents remains less certain. In a landmark study published by Rock *et al*^[28] comparing plasma exchange with plasma effusion, all patients received dipyridamole (400 mg daily) and aspirin (325 mg daily) for a period of at least 2 wk as a standard therapy. Treatment and maintenance with both aspirin and dipyridamole is suggested by some studies to prevent TTP relapse^[29]. Patients receiving aspirin and dipyridamole during the acute phase were noted to have lower mortality. In addition, ticlopidine maintenance was shown to prevent relapses after 1 year^[30]. Some authors even suggest intravenous infusion of dipyridamole as an adjunctive therapy^[31]. However, the mechanisms of thrombi formation in TTP may differ from atherothrombotic ACS. Thus, aspirin with dipyridamole may not have the same beneficial effects in TTP as it does for ACS^[32,33]. Other P2Y₁₂ receptor inhibitors, such as clopidogrel, prasugrel and ticagrelor, have not been tested for treating acute cardiac involvement in TTP. Furthermore, these thienopyridine derivatives (ticlopidine, clopidogrel, and prasugrel) are known to possess the potential of inducing acquired TTP^[34].

Unfractionated heparin (UFH) or low molecular weight heparin (LMWH) products have not been well studied in microvascular thrombi-induced myocardial injury in TTP, nor have GPIIb/IIIa inhibitors and direct thrombin inhibitors. Anticoagulation remains the treatment of choice for other thromboembolic disorders like antiphospholipid syndrome, cancer-associated thrombosis, and heparin-induced thrombocytopenia. The risk of hemorrhage in the setting of thrombocytopenia in TTP with its pathological microthrombi formation leads to the dilemma for anticoagulation therapy.

In the setting of STEMI with potentially large epicardial artery occlusion, which carries the highest risk of cardiac death, the decision of whether or not to use aggressive antiplatelet and anticoagulation (with or without pursuing invasive coronary angiography and intervention) must be decided on a case by case basis. The clinical decision is made by weighing clinical risk and benefit in adjunction with TTP therapy. There are reports of successful PCI for STEMI in TTP patients, as well as successful use of thrombolysis therapy^[13,25]. Should a TTP patient undergo a primary PCI for epicardial coronary artery occlusion, the patient is probably a better candidate for bare metal stents than for drug eluting stents, so as to reduce the required dual antiplatelet therapy duration. Due to thrombocytopenia in TTP and platelet dysfunction, the risk of bleeding during procedural treatments (diagnostic cardiac catheterization and PCI, pacemaker placement *etc*) for TTP patients is high. However, the threshold of platelet counts for these procedures is not defined. Physicians will need to assess on a case-by-case basis.

Treatment of microvascular disease remains a challenge, and not much data is available on this topic. Potentially beneficial treatments of microvascular disease in patients without TTP are beta blockers, non-dihydropyridine calcium channel blockers, nitrates, angiotensin converting enzyme inhibitors, and statins. But clinical evidence is lacking in TTP patients.

Statins have an established role in lowering cholesterol and reducing cardiovascular mortality in the general population. Statins help with the remodeling of coronary vessels, plaque stabilization, and the improvement of the perfusion of myocardial muscle. There are also other benefits observed with statins, including anti-inflammatory function and improvement in endothelial function. Statins could be beneficial in the TTP cohort of patients, as they have been shown to be an inhibitor of regulated vWF secretion in human umbilical vein endothelial cells^[35]. These pleiotropic effects of statins have been shown to be beneficial in patients with coronary microvascular dysfunction, and have a potential role in the treatment of microvascular disease related to TTP. A recent study showed that Simvastatin can increase the expression of ADAMTS13 in podocytes^[36]. Statins are safe in the majority of cases, but statin-induced TTP has also been reported^[37,38]. There is a paucity of data on the use of statins in TTP patients.

Treatment for heart failure and cardiomyopathy

Heart failure symptoms are relatively common in TTP presentation during the hospital course. With the common involvement of kidney injury, potentially significant volume changes during TPE, and ischemic injury of myocardium with potential decrease of contractile function, volume overload and pulmonary congestion may occur. Therefore, it is critical to have close clinical monitoring and to treat

decompensated heart failure with both intravenous diuretics and vasodilatory agents for afterload reduction with or without inotropic support. Hemodynamic support may also be indicated in critically ill TTP patients with cardiac complications.

β -adrenergic receptor blockers: β -blockers are proven beneficial for cardiomyopathy and ischemic heart disease at the epicardial and the microcirculation level^[39]. β -blockers are indicated for patients with myocardial injury and decreased LV ejection fraction (LVEF). Although there are no direct large-scale clinical studies on the use of β -blockers in TTP patients, they intuitively should be used for TTP patients with evidence of cardiac involvement. Published reports show complete recovery of TTP-related ischemic cardiomyopathy with regimens that include β -blockers^[40]. β -blockers and calcium channel blockers are commonly used to treat angina symptoms in patients with coronary microvascular dysfunction. Additionally, β -blockers like Nebivolol have been shown to improve endothelial function, which may help patients with TTP^[41].

Calcium channel blockers: Calcium channel blockers are commonly used in the treatment of microvascular dysfunction. Reported anti-atherogenic and antithrombotic properties of calcium channel blockers might have significant benefits in TTP treatment^[42], however their efficacy in these patients has not been established.

Angiotensin-converting enzyme inhibitor/angiotensin receptor blockers: Inhibitors of the renin-angiotensin system have a well-documented role in patients post-MI with decreased LVEF. Angiotensin-converting enzyme inhibitor (ACEi) and angiotensin receptor blockers (ARB) have been shown to be effective in the treatment of endothelial dysfunction and in the improvement of CFR. ARB is usually the choice when patients are unable to tolerate ACEi. Patients who are not candidates for either could benefit from a nitrate-hydralazine combination or Spironolactone. The addition of spironolactone was found particularly beneficial in patients with microvascular disease and diabetes. While these agents have been confirmed by large clinical trials to be beneficial in treating heart failure, cardiomyopathy, endothelial dysfunction and microcirculation dysfunction, which are all common in TTP patients, there is no data on the use or efficacy of ACEi/ARB in TTP patients.

Treatment of cardiac conduction system complication

For cardiac conduction system complications, *i.e.*, heart block, or arrhythmia, dedicated therapy will be indicated. Temporary transvenous pacemakers may be necessary for a hemodynamically significant heart block. Anti-arrhythmic agents may also be indicated for tachyarrhythmias with or without cardioversion, depending on clinical status. There are no long-term follow up data on cardiac conduction complications in TTP patients.

FOLLOW UP CARDIAC CARE OF TTP

With the advancement in understanding of the pathophysiology of TTP, as well as effective therapeutic strategies, the lethality of TTP has decreased. Its overall mortality has been reduced from 90% to 10%-20%. However, long-term follow up of TTP survivors showed their increased mortality over time when compared to the general population. Speculated causes include ADAMTS13 deficiency as a risk factor for cardiovascular disease, as well as ischemia from microvascular thrombosis, causing end organ damage over time. There are cases suggesting cardiac and renal complications to be responsible for suboptimal long-term outcomes in these patients. Therefore, routine cardiology follow up after recovery from acute TTP seems reasonable, especially for the patients with cardiac involvement during the acute phase. However, data are not available at this time to show the long-term cardiac implications of TTP and the significance of follow up cardiology care of TTP.

Ischemic workup and treatment

Considering the common occurrence of renal insufficiency and increased hemorrhagic risk during acute TTP, CAD status in the setting of ischemic injury during TTP is not often investigated. After recovery of acute TTP, ischemic workup should be performed with either a non-invasive stress test with myocardial perfusion imaging, or cardiac catheterization for patients with high pre-test probability of severe CAD.. Coronary CT angiography is also an option for defining the coronary anatomy. Exclusion of epicardial CAD and confirmation of microvascular disease may be helpful in the management of patients with chronic ischemic symptoms. Indeed, multiple reports showed adverse outcomes related to coronary microvascular

dysfunction^[43]. A recent report showed that microvascular disease is directly related to increased mortality when compared to the general population^[44]. However, despite the evidence of cardiac microvascular involvement in TTP, the long-term CAD risk for TTP survivors in comparison to the general population is unknown.

Other medications like ranolazine, ivabradine, amitriptyline, imipramine, or nortriptyline were found to be beneficial in the treatment of angina in coronary microvascular dysfunction, but their role in the TTP cohort is unknown. They could be considered for treatment of TTP patients who remain symptomatic with angina after recovery from an acute episode.

Cardiomyopathy follow up

TTP patients with evidence of ischemic injury and decreased LV function during the acute phase should be followed by cardiology as outpatients. It is reasonable to recommend evidence-based, guideline-directed medical therapy for cardiomyopathy with β -blockers, ACEi/ARB and other indicated agents. It is also reasonable to follow up on the recovery of EF. The long-term follow up on the trajectory of LV contractile function in TTP patients has not been established, although existing reports seem to suggest a favorable outcome commonly with full LVEF recovery. The risk of sudden cardiac death in TTP patients with severely reduced EF is unknown. The potential need for a permanent pacemaker for conduction system complications and an implantable cardioverter-defibrillator (ICD) for primary prevention of sudden cardiac death of patients with TTP is unclear.

CONCLUSION

Cardiac involvement in TTP is common. The presence of cardiac involvement is associated with adverse clinical outcomes in TTP patients. Contemporary diagnostic and therapeutic approaches provide the opportunity to improve clinical management of the cardiac complications related to TTP. Based on the above review of the literature and our own experience, we propose the following recommendations to clinicians managing TTP patients (Figure 1), in addition to the TTP routine workup and treatment. (1) All patients with suspected or confirmed TTP diagnosis should be screened for the potential presence of cardiac involvement by clinical symptoms/signs, ECG and cTn. (2) Any clinical deterioration of TTP patients with initial negative cardiac involvement warrants reassessment for the potential development of cardiac complications. (3) TTP patients with a positive screen or subsequent assessment of cardiac involvement should be monitored on telemetry, have cardiac biomarkers monitored as an indicator of disease progression, have TTE performed to assess cardiac structure and function, and have enhanced TTP-targeted treatment for disease control. (4) Aspirin therapy is indicated for all TTP patients. (5) Consider other targeted therapies (UFH, LMWH, low dose thrombolytics *etc*) for obstructive microthrombosis-related ischemia, with a balanced consideration of risk for hemorrhagic complications. (6) Apply evidence-based medical therapy for ischemia and cardiomyopathy, including diuretics, β -blockers, ACEi/ARB, statins, *etc*. (7) Treatment of arrhythmias and conduction abnormalities according to current guidelines. And (8) cardiology follow up and further evaluation as indicated after the acute phase of TTP.

Due to the lack of evidence from large clinical studies, the management of cardiac complications in TTP is largely based on the cohort data, experience and expert opinions. Future clinical studies on these topics are urgently needed. A multiple center prospective registry of TTP with a focus on cardiac implications and management is necessary to gather the evidence to better assess the clinical cost-effectiveness of these approaches.

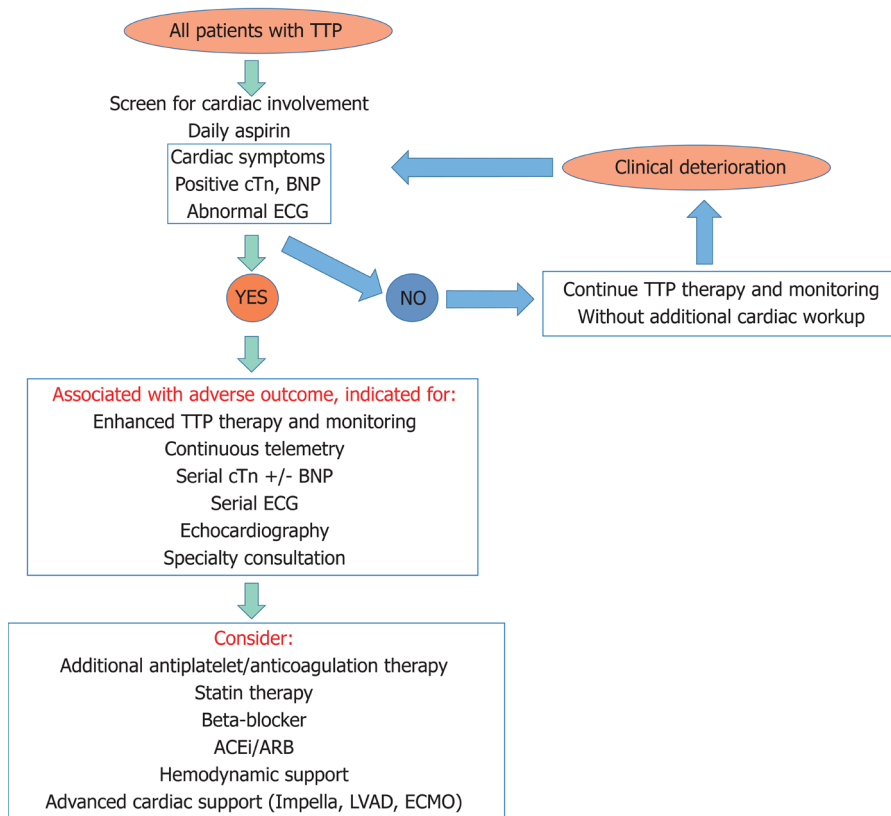


Figure 1 Recommendations on clinical assessment and management of cardiac involvement of thrombotic thrombocytopenia purpura. All patients with a diagnosis of thrombotic thrombocytopenia purpura (TTP) should be given low dose aspirin daily and screened for cardiac involvement by clinical cardiac symptoms, cardiac biomarkers (cardiac troponin, B-type natriuretic peptide etc) and electrocardiogram. Positive screen of cardiac involvement of TTP predicts adverse outcome, requiring further evaluation and treatment as recommended above. TTP: Thrombotic thrombocytopenia purpura; cTn, Cardiac troponin; BNP: B-type natriuretic peptide; ECG: Electrocardiogram; ACEi: Angiotensin converting enzyme inhibitors; ARB: Angiotensin receptor blockers; LVAD: Left ventricular assist device; ECMO: Extracorporeal membrane oxygenation.

REFERENCES

- 1 Kremer Hovinga JA, Coppo P, Lämmle B, Moake JL, Miyata T, Vanhoorelbeke K. Thrombotic thrombocytopenic purpura. *Nat Rev Dis Primers* 2017; **3**: 17020 [PMID: 28382967 DOI: 10.1038/nrdp.2017.20]
- 2 Joly BS, Coppo P, Veyradier A. Thrombotic thrombocytopenic purpura. *Blood* 2017; **129**: 2836-2846 [PMID: 28416507 DOI: 10.1182/blood-2016-10-709857]
- 3 Furlan M, Robles R, Lämmle B. Partial purification and characterization of a protease from human plasma cleaving von Willebrand factor to fragments produced by in vivo proteolysis. *Blood* 1996; **87**: 4223-4234 [PMID: 8639781]
- 4 Tsai HM. Physiologic cleavage of von Willebrand factor by a plasma protease is dependent on its conformation and requires calcium ion. *Blood* 1996; **87**: 4235-4244 [PMID: 8639782]
- 5 Kiss JE. Thrombotic thrombocytopenic purpura: recognition and management. *Int J Hematol* 2010; **91**: 36-45 [PMID: 20058208 DOI: 10.1007/s12185-009-0478-z]
- 6 Moschowitz E. An acute febrile pleiochromic anemia with hyaline thrombosis of the terminal arterioles and capillaries: an undescribed disease. 1925. *Mt Sinai J Med* 2003; **70**: 352-355 [PMID: 14631522]
- 7 Nichols L, Berg A, Rollins-Raval MA, Raval JS. Cardiac injury is a common postmortem finding in thrombotic thrombocytopenic purpura patients: is empiric cardiac monitoring and protection needed? *Ther Apher Dial* 2015; **19**: 87-92 [PMID: 25196220 DOI: 10.1111/1744-9987.12191]
- 8 Gandhi K, Aronow WS, Desai H, Amin H, Sharma M, Lai HM, Singh P. Cardiovascular manifestations in patients with thrombotic thrombocytopenic purpura: a single-center experience. *Clin Cardiol* 2010; **33**: 213-216 [PMID: 20394041 DOI: 10.1002/clc.20731]
- 9 Hawkins BM, Abu-Fadel M, Vesely SK, George JN. Clinical cardiac involvement in thrombotic thrombocytopenic purpura: a systematic review. *Transfusion* 2008; **48**: 382-392 [PMID: 18028268 DOI: 10.1111/j.1537-2995.2007.01534.x]
- 10 Patschan D, Witzke O, Dührsen U, Erbel R, Philipp T, Herget-Rosenthal S. Acute myocardial infarction in thrombotic microangiopathies—clinical characteristics, risk factors and outcome. *Nephrol Dial Transplant* 2006; **21**: 1549-1554 [PMID: 16574680 DOI: 10.1093/ndt/gfl127]
- 11 Wahla AS, Ruiz J, Nouredine N, Upadhyay B, Sane DC, Owen J. Myocardial infarction in thrombotic thrombocytopenic purpura: a single-center experience and literature review. *Eur J Haematol* 2008; **81**: 311-316 [PMID: 18616514 DOI: 10.1111/j.1600-0609.2008.01112.x]
- 12 Hughes C, McEwan JR, Longair I, Hughes S, Cohen H, Machin S, Scully M. Cardiac involvement in acute thrombotic thrombocytopenic purpura: association with troponin T and IgG antibodies

- to ADAMTS 13. *J Thromb Haemost* 2009; **7**: 529-536 [PMID: [19175494](#) DOI: [10.1111/j.1538-7836.2009.03285.x](#)]
- 13 **Jorfi F**, Sanati HR, Zahedmehr A, Shakerian F, Zahedi L, Firouzi A, Kiani R, Elmi G. Difficult management of coronary artery disease in a patient with thrombotic thrombocytopenic purpura. *J Tehran Heart Cent* 2014; **9**: 140-142 [PMID: [25870634](#)]
- 14 **Wiernek SL**, Dai X. Obstructive coronary artery disease in patient with acute thrombotic thrombocytopenic purpura. *BMJ Case Rep* 2017; **2017** [PMID: [29038197](#) DOI: [10.1136/bcr-2017-222437](#)]
- 15 **James TN**, Alperin JB. Apoptotic myocardial degeneration in thrombotic thrombocytopenic purpura. *Apoptosis* 1997; **2**: 384-394 [PMID: [14646535](#) DOI: [10.1023/A:1026457724661](#)]
- 16 **Balasubramaniam N**, Kolte D, Palaniswamy C, Yalamanchili K, Aronow WS, McClung JA, Khera S, Sule S, Peterson SJ, Frishman WH. Predictors of in-hospital mortality and acute myocardial infarction in thrombotic thrombocytopenic purpura. *Am J Med* 2013; **126**: 1016.e1-1016.e7 [PMID: [23993262](#) DOI: [10.1016/j.amjmed.2013.03.021](#)]
- 17 **Benhamou Y**, Boelle PY, Baudin B, Ederhy S, Gras J, Galicier L, Azoulay E, Provôt F, Maury E, Pène F. Cardiac troponin-I on diagnosis predicts early death and refractoriness in acquired thrombotic thrombocytopenic purpura. Experience of the French Thrombotic Microangiopathies Reference Center. *J Thromb Haemost* 2015; **13**: 293-302 [PMID: [25403270](#) DOI: [10.1111/jth.12790](#)]
- 18 **Sane DC**, Streer NP, Owen J. Myocardial necrosis in patients with thrombotic thrombocytopenic purpura: pathophysiology and rationale for specific therapy. *Eur J Haematol* 2009; **82**: 83-92 [PMID: [19067741](#) DOI: [10.1111/j.1600-0609.2008.01172.x](#)]
- 19 **American College of Cardiology Foundation Appropriate Use Criteria Task Force**, American Society of Echocardiography, American Heart Association; American Society of Nuclear Cardiology, Heart Failure Society of America, Heart Rhythm Society, Society for Cardiovascular Angiography and Interventions, Society of Critical Care Medicine, Society of Cardiovascular Computed Tomography, Society for Cardiovascular Magnetic Resonance, American College of Chest Physicians, Douglas PS, Garcia MJ, Haines DE, Lai WW, Manning WJ, Patel AR, Picard MH, Polk DM, Ragosta M, Parker Ward R, Weiner RB. ACCF/AHA/ASA/ASNC/HFSA/HRS/SCAI/SCCM/SCCT/SCMR 2011 Appropriate Use Criteria for Echocardiography. A Report of the American College of Cardiology Foundation Appropriate Use Criteria Task Force, American Society of Echocardiography, American Heart Association, American Society of Nuclear Cardiology, Heart Failure Society of America, Heart Rhythm Society, Society for Cardiovascular Angiography and Interventions, Society of Critical Care Medicine, Society of Cardiovascular Computed Tomography, Society for Cardiovascular Magnetic Resonance American College of Chest Physicians. *J Am Soc Echocardiogr* 2011; **24**: 229-267 [PMID: [21338862](#) DOI: [10.1016/j.echo.2010.12.008](#)]
- 20 **Camici PG**, d'Amati G, Rimoldi O. Coronary microvascular dysfunction: mechanisms and functional assessment. *Nat Rev Cardiol* 2015; **12**: 48-62 [PMID: [25311229](#) DOI: [10.1038/nrcardio.2014.160](#)]
- 21 **Shufelt CL**, Thomson LE, Goykhman P, Agarwal M, Mehta PK, Sedlak T, Li N, Gill E, Samuels B, Azabal B. Cardiac magnetic resonance imaging myocardial perfusion reserve index assessment in women with microvascular coronary dysfunction and reference controls. *Cardiovasc Diagn Ther* 2013; **3**: 153-160 [PMID: [24282764](#) DOI: [10.3978/j.issn.2223-3652.2013.08.02](#)]
- 22 **Ho HH**, Minutello R, Juliano N, Wong SC. A rare cause of acute myocardial infarction: thrombotic thrombocytopenic purpura. *Int J Cardiol* 2009; **133**: e1-e2 [PMID: [18068236](#) DOI: [10.1016/j.ijcard.2007.08.063](#)]
- 23 **Lapp H**, Shin DI, Kroells W, Boerrigter G, Horlitz M, Schley P, Stoerker S, Guelker H. Cardiogenic shock due to thrombotic thrombocytopenic purpura. *Z Kardiol* 2004; **93**: 486-492 [PMID: [15252743](#) DOI: [10.1007/s00392-004-0077-1](#)]
- 24 **Schiviz A**, Wuersch K, Piskernik C, Dietrich B, Hoellriegel W, Rottensteiner H, Scheiflinger F, Schwarz HP, Muchitsch EM. A new mouse model mimicking thrombotic thrombocytopenic purpura: correction of symptoms by recombinant human ADAMTS13. *Blood* 2012; **119**: 6128-6135 [PMID: [22529289](#) DOI: [10.1182/blood-2011-09-380535](#)]
- 25 **Doll JA**, Kelly JP. ST-segment elevation myocardial infarction treated with thrombolytic therapy in a patient with thrombotic thrombocytopenic purpura. *J Thromb Thrombolysis* 2014; **38**: 124-126 [PMID: [24189934](#) DOI: [10.1007/s11239-013-1018-5](#)]
- 26 **Zhu T**, Pan K, Wang Y. Successful resuscitation with thrombolysis of pulmonary embolism due to thrombotic thrombocytopenic purpura during cardiac arrest. *Am J Emerg Med* 2015; **33**: 132.e3-132.e4 [PMID: [25070193](#) DOI: [10.1016/j.ajem.2014.06.025](#)]
- 27 **Wolff M**, Dorent R, Veyradier A, Deschamps L, Raffoul R. Heart transplantation for acute cardiac failure caused by thrombotic thrombocytopenic purpura (TTP). *Intensive Care Med* 2012; **38**: 1908-1910 [PMID: [22773037](#) DOI: [10.1007/s00134-012-2637-6](#)]
- 28 **Rock GA**, Shumak KH, Buskard NA, Blanchette VS, Kelton JG, Nair RC, Spasoff RA. Comparison of plasma exchange with plasma infusion in the treatment of thrombotic thrombocytopenic purpura. Canadian Apheresis Study Group. *N Engl J Med* 1991; **325**: 393-397 [PMID: [2062330](#) DOI: [10.1056/NEJM199108083250604](#)]
- 29 **Myers TJ**, Wakem CJ, Ball ED, Tremont SJ. Thrombotic thrombocytopenic purpura: combined treatment with plasmapheresis and antiplatelet agents. *Ann Intern Med* 1980; **92**: 149-155 [PMID: [7188723](#) DOI: [10.7326/0003-4819-92-2-149](#)]
- 30 **Bobbio-Pallavicini E**, Gugliotta L, Centurioni R, Porta C, Vianelli N, Billio A, Tacconi F, Ascarì E. Antiplatelet agents in thrombotic thrombocytopenic purpura (TTP). Results of a randomized multicenter trial by the Italian Cooperative Group for TTP. *Haematologica* 1997; **82**: 429-435 [PMID: [9299856](#)]
- 31 **Quintini G**, Barbera V, Iannitto E, Spadola V, Fadda R, Greco G, Mazzola G, Mariani G. Continuous intravenous infusion of dipyridamole as adjunctive therapy in the treatment of thrombotic thrombocytopenic purpura. *Transfus Apher Sci* 2003; **29**: 141-145 [PMID: [12941352](#) DOI: [10.1016/S1473-0502\(03\)00118-6](#)]
- 32 **Rosove MH**, Ho WG, Goldfinger D. Ineffectiveness of aspirin and dipyridamole in the treatment of thrombotic thrombocytopenic purpura. *Ann Intern Med* 1982; **96**: 27-33 [PMID: [7032379](#) DOI: [10.7326/0003-4819-96-1-27](#)]
- 33 **Coppo P**, Veyradier A. Current management and therapeutical perspectives in thrombotic

- thrombocytopenic purpura. *Presse Med* 2012; **41**: e163-e176 [PMID: [22265954](#) DOI: [10.1016/j.lpm.2011.10.024](#)]
- 34 **Jacob S**, Dunn BL, Qureshi ZP, Bandarenko N, Kwaan HC, Pandey DK, McKoy JM, Barnato SE, Winters JL, Cursio JF. Ticlopidine-, clopidogrel-, and prasugrel-associated thrombotic thrombocytopenic purpura: a 20-year review from the Southern Network on Adverse Reactions (SONAR). *Semin Thromb Hemost* 2012; **38**: 845-853 [PMID: [23111862](#) DOI: [10.1055/s-0032-1328894](#)]
- 35 **Fish RJ**, Yang H, Viglino C, Schorer R, Dunoyer-Geindre S, Kruithof EK. Fluvastatin inhibits regulated secretion of endothelial cell von Willebrand factor in response to diverse secretagogues. *Biochem J* 2007; **405**: 597-604 [PMID: [17472573](#) DOI: [10.1042/BJ20070404](#)]
- 36 **Shen L**, Lu G, Dong N, Ma Z, Ruan C. Simvastatin increases ADAMTS13 expression in podocytes. *Thromb Res* 2013; **132**: 94-99 [PMID: [23816135](#) DOI: [10.1016/j.thromres.2013.05.024](#)]
- 37 **McCarthy LJ**, Porcu P, Fausel CA, Sweeney CJ, Danielson CF. Thrombotic thrombocytopenic purpura and simvastatin. *Lancet* 1998; **352**: 1284-1285 [PMID: [9788466](#) DOI: [10.1016/S0140-6736\(05\)70492-X](#)]
- 38 **Sundram F**, Roberts P, Kennedy B, Pavord S. Thrombotic thrombocytopenic purpura associated with statin treatment. *Postgrad Med J* 2004; **80**: 551-552 [PMID: [15356359](#) DOI: [10.1136/pgmj.2003.017178](#)]
- 39 **Gheorghiade M**, Goldstein S. Beta-blockers in the post-myocardial infarction patient. *Circulation* 2002; **106**: 394-398 [PMID: [12135934](#) DOI: [10.1161/01.CIR.0000019582.39797.EF](#)]
- 40 **Gaddam S**, Pablani L, Chainani V, Kavuda RR, Nagrani T, Abou Rjaili G, Dhar M, Lafferty JC. Complete recovery of ischemic cardiomyopathy from thrombotic thrombocytopenic purpura. *Clin Med Insights Cardiol* 2011; **5**: 29-33 [PMID: [21487455](#) DOI: [10.4137/CMC.S6130](#)]
- 41 **Kayaalti F**, Kalay N, Basar E, Mavili E, Duran M, Ozdogru I, Dogan A, Inanc MT, Kaya MG, Topsakal R. Effects of nebivolol therapy on endothelial functions in cardiac syndrome X. *Heart Vessels* 2010; **25**: 92-96 [PMID: [20339969](#) DOI: [10.1007/s00380-009-1170-1](#)]
- 42 **Ahn YS**, Jy W, Harrington WJ, Shanbaky N, Fernandez LF, Haynes DH. Increased platelet calcium in thrombosis and related disorders and its correction by nifedipine. *Thromb Res* 1987; **45**: 135-143 [PMID: [3563979](#) DOI: [10.1016/0049-3848\(87\)90167-8](#)]
- 43 **Pepine CJ**, Anderson RD, Sharaf BL, Reis SE, Smith KM, Handberg EM, Johnson BD, Sopko G, Bairey Merz CN. Coronary microvascular reactivity to adenosine predicts adverse outcome in women evaluated for suspected ischemia results from the National Heart, Lung and Blood Institute WISE (Women's Ischemia Syndrome Evaluation) study. *J Am Coll Cardiol* 2010; **55**: 2825-2832 [PMID: [20579539](#) DOI: [10.1016/j.jacc.2010.01.054](#)]
- 44 **Lin T**, Rechenmacher S, Rasool S, Varadarajan P, Pai RG. Reduced survival in patients with "coronary microvascular disease". *Int J Angiol* 2012; **21**: 89-94 [PMID: [23730136](#) DOI: [10.1055/s-0032-1315799](#)]
- 45 **Amorosi EL**, Ultman JE. Thrombotic thrombocytopenic purpura: report of 16 cases and review of the literature. *Medicine* 1966; **45**: 139-159 [DOI: [10.1097/00005792-196603000-00003](#)]
- 46 **James TN**, Monto RW. Pathology of the cardiac conduction system in thrombotic thrombocytopenic purpura. *Ann Intern Med* 1966; **65**: 37-43 [PMID: [5949189](#) DOI: [10.7326/0003-4819-65-1-37](#)]
- 47 **Geisinger KR**, Solomon AR. Sudden cardiac death in thrombotic thrombocytopenic purpura. *Arch Pathol Lab Med* 1979; **103**: 599-600 [PMID: [582662](#)]
- 48 **Ridolfi RL**, Hutchins GM, Bell WR. The heart and cardiac conduction system in thrombotic thrombocytopenic purpura. A clinicopathologic study of 17 autopsied patients. *Ann Intern Med* 1979; **91**: 357-363 [PMID: [573083](#) DOI: [10.7326/0003-4819-91-3-357](#)]
- 49 **Ross WK**, Newton NE, Stivers RR. Sudden death due to thrombotic thrombocytopenic purpura. *Am J Forensic Med Pathol* 1987; **8**: 158-163 [PMID: [3605013](#) DOI: [10.1097/0000433-198708020-00015](#)]
- 50 **Bowdler AJ**. Chronic relapsing thrombotic thrombocytopenic purpura. *South Med J* 1987; **80**: 507-510 [PMID: [3563584](#) DOI: [10.1097/00007611-198704000-00023](#)]
- 51 **Siersema PD**, Kros JM, van den Berg B. Cardiac manifestations of thrombotic thrombocytopenic purpura. *Neth J Med* 1989; **35**: 100-107 [PMID: [2779690](#)]
- 52 **Bell MD**, Barnhart JS Jr, Martin JM. Thrombotic thrombocytopenic purpura causing sudden, unexpected death--a series of eight patients. *J Forensic Sci* 1990; **35**: 601-613 [PMID: [2348178](#) DOI: [10.1520/JFS12866J](#)]
- 53 **Webb JG**, Butany J, Langer G, Scott G, Liu PP. Myocarditis and myocardial hemorrhage associated with thrombotic thrombocytopenic purpura. *Arch Intern Med* 1990; **150**: 1535-1537 [PMID: [2369253](#) DOI: [10.1001/archinte.1990.00390190167029](#)]
- 54 Case records of the Massachusetts General Hospital. Weekly clinicopathological exercises. Case 33-1994. A 41-year-old woman with thrombocytopenia, anemia, and sudden death. *N Engl J Med* 1994; **331**: 661-667 [PMID: [8052277](#) DOI: [10.1056/NEJM199409083311008](#)]
- 55 **Podolsky SH**, Zembowicz A, Schoen FJ, Benjamin RJ, Sanna LA. Massive myocardial necrosis in thrombotic thrombocytopenic purpura: a case report and review of the literature. *Arch Pathol Lab Med* 1999; **123**: 937-940 [PMID: [10506449](#)]
- 56 **Wajima T**, Johnson EH. Sudden cardiac death from thrombotic thrombocytopenic purpura. *Clin Appl Thromb Hemost* 2000; **6**: 108-110 [PMID: [10775033](#) DOI: [10.1177/107602960000600212](#)]
- 57 **Hosler GA**, Cusumano AM, Hutchins GM. Thrombotic thrombocytopenic purpura and hemolytic uremic syndrome are distinct pathologic entities. A review of 56 autopsy cases. *Arch Pathol Lab Med* 2003; **127**: 834-839 [PMID: [12823037](#) DOI: [10.1043/1543-2165\(2003\)127<834:TTPAHU>2.0.CO;2](#)]
- 58 **Brandenburg VM**, Gaertner S, Lindemann-Docter K, Ortlepp JR, Westerhuis R, Ketteler M, Westenfeld R, Floege J. Underestimated complications in thrombotic thrombocytopenic purpura-haemolytic uraemic syndrome. *Nephrol Dial Transplant* 2004; **19**: 2142-2146 [PMID: [15252177](#) DOI: [10.1093/ndt/gfh230](#)]
- 59 **Gami AS**, Hayman SR, Grande JP, Garovic VD. Incidence and prognosis of acute heart failure in the thrombotic microangiopathies. *Am J Med* 2005; **118**: 544-547 [PMID: [15866258](#) DOI: [10.1016/j.amjmed.2005.02.019](#)]
- 60 **Iberson M**, Moreso F, Carreras L, Carrera M, Serrano T, Rama I, Bestard O, Torras J, Poveda R, Grinyó JM. Thrombotic thrombocytopenic purpura with severe large artery branch involvement. *Nephrol Dial Transplant* 2005; **20**: 467-468 [PMID: [15673703](#) DOI: [10.1093/ndt/gfh596](#)]

- 61 **Arnold PO**, Klink D, Holmes AK. Fatal cardiac arrhythmia in a patient with thrombotic thrombocytopenic purpura. *Am J Med Sci* 2006; **331**: 320-321 [PMID: [16775439](#) DOI: [10.1097/00000441-200606000-00005](#)]
- 62 **Sarode R**. Atypical presentations of thrombotic thrombocytopenic purpura: a review. *J Clin Apher* 2009; **24**: 47-52 [PMID: [19073011](#) DOI: [10.1002/jca.20182](#)]
- 63 **George JN**, Chen Q, Deford CC, Al-Nouri Z. Ten patient stories illustrating the extraordinarily diverse clinical features of patients with thrombotic thrombocytopenic purpura and severe ADAMTS13 deficiency. *J Clin Apher* 2012; **27**: 302-311 [PMID: [22927184](#) DOI: [10.1002/jca.21248](#)]

P- Reviewer: Canpolat U, Movahed A, Ueda H

S- Editor: Ma RY **L- Editor:** Filipodia **E- Editor:** Song H





Published By Baishideng Publishing Group Inc
7901 Stoneridge Drive, Suite 501, Pleasanton, CA 94588, USA
Telephone: +1-925-2238242
Fax: +1-925-2238243
E-mail: bpgoffice@wjgnet.com
Help Desk: <https://www.f6publishing.com/helpdesk>
<https://www.wjgnet.com>

