

# World Journal of *Clinical Cases*

*World J Clin Cases* 2019 January 6; 7(1): 1-121





### MINIREVIEWS

- 1 Role of endoscopy in the surveillance and management of colorectal neoplasia in inflammatory bowel disease  
*Manchanda S, Rizvi QUA, Singh R*

### ORIGINAL ARTICLE

#### Retrospective Cohort Study

- 10 Risk factors for perforation during endoscopic retrograde cholangiopancreatography in post-reconstruction intestinal tract  
*Takano S, Fukasawa M, Shindo H, Takahashi E, Hirose S, Fukasawa Y, Kawakami S, Hayakawa H, Yokomichi H, Kadokura M, Sato T, Enomoto N*

#### Retrospective Study

- 19 Instant evaluation of contrast enhanced endoscopic ultrasound helps to differentiate various solid pancreatic lesions in daily routine  
*Kannengiesser K, Mahlke R, Petersen F, Peters A, Kucharzik T, Maaser C*
- 28 Correlation of serum albumin and prognostic nutritional index with outcomes following pancreaticoduodenectomy  
*Rungsakulkij N, Tangtawe P, Suragul W, Muangkaew P, Mingphruedhi S, Aeesoa S*

#### Clinical Trials Study

- 39 Efficacy of 0.5-L vs 1-L polyethylene glycol containing ascorbic acid as additional colon cleansing methods for inadequate bowel preparation as expected by last stool examination before colonoscopy  
*Cho JH, Goo EJ, Kim KO, Lee SH, Jang BI, Kim TN*

#### Observational Study

- 49 Value of contrast-enhanced ultrasound combined with elastography in evaluating cervical lymph node metastasis in papillary thyroid carcinoma  
*Jiang W, Wei HY, Zhang HY, Zhuo QL*

### CASE REPORT

- 58 Full-term pregnancy in breast cancer survivor with fertility preservation: A case report and review of literature  
*Garrido-Marín M, Argacha PM, Fernández L, Molfino F, Martínez-Soler F, Tortosa A, Gimenez-Bonafé P*
- 69 Psoriatic fasciitis in a pediatric patient: A case report  
*Otar Yener G, Ekici Tekin Z, Yuksel S*

- 73 Vertebrobasilar artery dissection manifesting as Millard-Gubler syndrome in a young ischemic stroke patient: A case report  
*Li XT, Yuan JL, Hu WL*
  
- 79 Endodontic management of the maxillary first molars with two root canals: A case report and review of the literature  
*Liu J, Que KH, Xiao ZH, Wen W*
  
- 89 Tegafur deteriorates established cardiovascular atherosclerosis in colon cancer: A case report and review of the literature  
*Zhang SC, Yu MY, Xi L, Zhang JX*
  
- 95 Authenticity of pulmonary *Lophomonas blattarum* infection: A case report  
*Meng SS, Dai ZF, Wang HC, Li YX, Wei DD, Yang RL, Lin XH*
  
- 102 Co-occurrence of IPMN and malignant IPNB complicated by a pancreatobiliary fistula: A case report and review of the literature  
*Ren X, Zhu CL, Qin XF, Jiang H, Xia T, Qu YP*
  
- 109 Bilateral and symmetric C1-C2 dumbbell ganglioneuromas associated with neurofibromatosis type 1: A case report  
*Tan CY, Liu JW, Lin Y, Tie XX, Cheng P, Qi X, Gao Y, Guo ZZ*
  
- 116 Follicular dendritic cell sarcoma detected in hepatogastric ligament: A case report and review of the literature  
*Yan WX, Yu YX, Zhang P, Liu XK, Li Y*

**ABOUT COVER**

Editor-in-Chief of *World Journal of Clinical Cases*, Sandro Vento, MD, Full Professor, (E-mail: ventosandro@yahoo.it) Department of Medicine, Nazarbayev University School of Medicine and University Medical Center, Astana 010000, Kazakhstan

**AIMS AND SCOPE**

*World Journal of Clinical Cases* (*World J Clin Cases*, *WJCC*, online ISSN 2307-8960, DOI: 10.12998) is a peer-reviewed open access academic journal that aims to guide clinical practice and improve diagnostic and therapeutic skills of clinicians.

The primary task of *WJCC* is to rapidly publish high-quality Autobiography, Case Report, Clinical Case Conference (Clinicopathological Conference), Clinical Management, Diagnostic Advances, Editorial, Field of Vision, Frontier, Medical Ethics, Original Articles, Clinical Practice, Meta-Analysis, Minireviews, Review, Therapeutics Advances, and Topic Highlight, in the fields of allergy, anesthesiology, cardiac medicine, clinical genetics, clinical neurology, critical care, dentistry, dermatology, emergency medicine, endocrinology, family medicine, gastroenterology and hepatology, geriatrics and gerontology, hematology, immunology, etc.

**INDEXING/ABSTRACTING**

*World Journal of Clinical Cases* (*WJCC*) is now indexed in PubMed, PubMed Central, Science Citation Index Expanded (also known as SciSearch®), and Journal Citation Reports/Science Edition. The 2018 Edition of Journal Citation Reports cites the 2017 impact factor for *WJCC* as 1.931 (5-year impact factor: N/A), ranking *WJCC* as 60 among 154 journals in Medicine, General and Internal (quartile in category Q2).

**RESPONSIBLE EDITORS FOR THIS ISSUE**

Responsible Electronic Editor: Ying-Na Bian

Proofing Editorial Office Director: Jin-Lei Wang

**NAME OF JOURNAL**

*World Journal of Clinical Cases*

**ISSN**

ISSN 2307-8960 (online)

**LAUNCH DATE**

April 16, 2013

**FREQUENCY**

Semimonthly

**EDITORS-IN-CHIEF**

Dennis A Bloomfield, Sandro Vento

**EDITORIAL BOARD MEMBERS**

<https://www.wjnet.com/2307-8960/editorialboard.htm>

**EDITORIAL OFFICE**

Jin-Lei Wang, Director

**PUBLICATION DATE**

January 6, 2019

**COPYRIGHT**

© 2019 Baishideng Publishing Group Inc

**INSTRUCTIONS TO AUTHORS**

<https://www.wjnet.com/bpg/gerinfo/204>

**GUIDELINES FOR ETHICS DOCUMENTS**

<https://www.wjnet.com/bpg/GerInfo/287>

**GUIDELINES FOR NON-NATIVE SPEAKERS OF ENGLISH**

<https://www.wjnet.com/bpg/gerinfo/240>

**PUBLICATION MISCONDUCT**

<https://www.wjnet.com/bpg/gerinfo/208>

**ARTICLE PROCESSING CHARGE**

<https://www.wjnet.com/bpg/gerinfo/242>

**STEPS FOR SUBMITTING MANUSCRIPTS**

<https://www.wjnet.com/bpg/GerInfo/239>

**ONLINE SUBMISSION**

<https://www.f6publishing.com>

## Retrospective Study

## Instant evaluation of contrast enhanced endoscopic ultrasound helps to differentiate various solid pancreatic lesions in daily routine

Klaus Kannengiesser, Reiner Mahlke, Frauke Petersen, Anja Peters, Torsten Kucharzik, Christian Maaser

## ORCID number: Klaus

Kannengiesser  
(0000-0002-2661-8795); Reiner  
Mahlke (0000-0003-0835-0630);  
Frauke Petersen  
(0000-0002-6427-6060); Anja Peters  
(0000-0002-8610-4163); Torsten  
Kucharzik (0000-0002-0183-4483);  
Christian Maaser  
(0000-0002-3889-405X).

## Author contributions:

Kannengiesser K, Kucharzik T,  
Petersen F and Maaser C designed  
the research; Kannengiesser K,  
Mahlke R, Kucharzik T and Maaser  
C performed EUS investigations;  
Petersen A performed histological  
analyses; Kannengiesser K,  
Kucharzik T and Maaser C  
analysed the data and wrote the  
manuscript; All authors revised the  
manuscript.

## Institutional review board

**statement:** The local ethics  
committee state that for this  
retrospective anonymous data  
analysis no formal approval was  
necessary.

**Informed consent statement:** All  
patients signed informed consent  
for the investigations carried out.  
As an anonymous retrospective  
analysis there was no formal  
informed consent for the data  
analysis later on.

**Conflict-of-interest statement:** No  
conflicts of interest.

**Open-Access:** This article is an  
open-access article which was  
selected by an in-house editor and  
fully peer-reviewed by external  
reviewers. It is distributed in  
accordance with the Creative

Klaus Kannengiesser, Reiner Mahlke, Frauke Petersen, Torsten Kucharzik, Christian Maaser,  
Department of General Internal Medicine and Gastroenterology, University Teaching Hospital  
Lueneburg, Lueneburg 21339, Germany

Anja Peters, Department of Pathology, University Teaching Hospital Lueneburg, Lueneburg  
21339, Germany

**Corresponding author:** Klaus Kannengiesser, MD, Academic Fellow, Doctor, Department of  
General Internal Medicine and Gastroenterology, University Teaching Hospital Lueneburg,  
Boegelstrasse 1, Lueneburg 21339, Germany. [klaus.kannengiesser@klinikum-lueneburg.de](mailto:klaus.kannengiesser@klinikum-lueneburg.de)  
**Telephone:** +49-4131-772241

**Fax:** +49-4131-772245

## Abstract

## BACKGROUND

Contrast enhanced harmonic endoscopic ultrasound (CEH-EUS) is a spreading  
technique; some studies have shown its value in the diagnosis of pancreatic  
adenocarcinoma using quantitative analysis.

## AIM

To examine the value of CEH-EUS for differentiating various pancreatic lesions  
in everyday routine with qualitative and quantitative analysis.

## METHODS

Data of 55 patients with pancreatic lesions who underwent CEH-EUS were  
analysed retrospectively. Perfusion characteristics were classified by the  
investigator qualitatively immediately upon investigation, quantitative analysis  
was performed later on. Samples from fine needle aspiration (EUS-FNA) or  
surgical specimen served as gold standard.

## RESULTS

CEH-EUS showed 39 hypoenhanced lesions, 3 non-enhanced and 13  
hyperenhanced lesions. Concordance of the investigators qualitative classification  
of peak contrast enhancement with quantitative analysis later on was 100%, while  
other parameters such as arrival time, time to peak or area under the curve did  
not show additional value. 34 of 39 hypoenhanced lesions were pancreatic  
adenocarcinoma; of the hyperenhanced lesions 4 were inflammatory, 3  
neuroendocrine carcinomas, 1 lymphoma, 1 insulinoma and 4 metastases (2 of  
renal cell carcinoma, 2 of lung cancer). Non-enhanced lesions showed up as  
necroses. Sensitivity for the detection of pancreatic adenocarcinoma was 100%,

Commons Attribution Non Commercial (CC BY-NC 4.0) license, which permits others to distribute, remix, adapt, build upon this work non-commercially, and license their derivative works on different terms, provided the original work is properly cited and the use is non-commercial. See: <http://creativecommons.org/licenses/by-nc/4.0/>

**Manuscript source:** Invited manuscript

**Received:** October 30, 2018

**Peer-review started:** October 31, 2018

**First decision:** November 28, 2018

**Revised:** December 4, 2018

**Accepted:** December 21, 2018

**Article in press:** December 21, 2018

**Published online:** January 6, 2019

specificity 87.2% for hypoenhancement alone; in otherwise healthy pancreatic tissue all hypoenhanced lesions were pancreatic adenocarcinoma (sensitivity and specificity 100%, PPV and NPV for adenocarcinoma 100%).

## CONCLUSION

This study again shows the excellent value of CEH-EUS in everyday routine for diagnostics of various focal pancreatic lesions suggesting that qualitatively assessed hypoenhancement is highly predictive for adenocarcinoma. Additional quantitative analysis of perfusion parameters does not add diagnostic yield. In case of the various hyperenhanced pancreatic lesions in our data set, histologic sampling is essential for further treatment.

**Key words:** Endoscopic ultrasound; Contrast enhanced endoscopic ultrasound; Pancreatic adenocarcinoma; Neuroendocrine carcinoma; Pancreatic metastases; Lymphoma

©The Author(s) 2019. Published by Baishideng Publishing Group Inc. All rights reserved.

**Core tip:** In the diagnostic of focal pancreatic lesions, several studies showed a good value of Contrast enhanced endoscopic ultrasound (CEH-EUS) in detecting pancreatic adenocarcinoma, while less is known about other focal pancreatic pathologies. In our retrospective cohort, we can confirm the good value of CEH-EUS for the detection of pancreatic adenocarcinoma. We additionally show the high value of instant qualitative evaluation of CEH-EUS images in everyday routine as well as the limitations of quantitative analyses, making precise quantification dispensable. Moreover, we describe perfusion characteristics of several other solid pancreatic masses of different origin.

**Citation:** Kannengiesser K, Mahlke R, Petersen F, Peters A, Kucharzik T, Maaser C. Instant evaluation of contrast enhanced endoscopic ultrasound helps to differentiate various solid pancreatic lesions in daily routine. *World J Clin Cases* 2019; 7(1): 19-27  
**URL:** <https://www.wjgnet.com/2307-8960/full/v7/i1/19.htm>  
**DOI:** <https://dx.doi.org/10.12998/wjcc.v7.i1.19>

## INTRODUCTION

After its first introduction in 1980, endoscopic ultrasound (EUS) has been established as an effective tool in the diagnostic of intestinal organs. With ongoing technical development image resolution has advanced and ultrasound guided fine needle aspiration (EUS-FNA) opened the chance to cytological assessment of suspicious lesions. In particular identification and evaluation of pancreatic solid and cystic masses as well as their relationship to adjacent vessels and organs have improved through EUS techniques<sup>[1]</sup>.

However, the precise discrimination between benign and malignant pancreatic lesions remains often difficult, amongst other reasons due to non-diagnostic cytological results or misguided fine needle aspirates. Early detection of malignancies is crucial, as surgery is the only potential curative treatment. Unfortunately, both EUS and EUS-FNA lack sufficient accuracy, leading to false positive and false negative results in up to one fifth of cases<sup>[2-5]</sup>.

Surgery should be carried out as soon as possible in malignant lesions due to rapid disease progression. As morbidity and mortality of pancreatic surgery are high, it is crucial to identify benign pancreatic or non-adenocarcinoma lesions<sup>[6,7]</sup>.

Contrast enhanced ultrasound has been shown to be a helpful tool in transabdominal ultrasound. There is increasing experience with benign and malignant masses of the liver, kidney and other solid organs, as well as neoplastic, inflammatory and ischemic lesions *e.g.*, in the intestine<sup>[8-12]</sup>.

Ultrasound contrast agents contain microbubbles filled with gas surrounded by a shell. In harmonic imaging, low acoustic energies with a mechanical index between 0.1 and 0.06 lead to an oscillation of microbubbles in harmonic frequencies, which enhances the scattered ultrasound signal. Moreover, low acoustic energies allow subtraction of the tissue-derived ultrasound signals. As the microbubbles do not leave the microvasculature, this leads to improved detectability of arteries, veins, microvessels and blood perfusion characteristics in different perfusion phases<sup>[13]</sup>.



Sensitivity of transabdominal ultrasound of the pancreas is often limited, mostly due to meteorism. Accuracy of EUS in detection of pancreatic lesions is significantly better<sup>[14,15]</sup>.

New echo-endoscopes allow the use of ultrasound contrast agents in harmonic EUS imaging<sup>[16,17]</sup>.

In some studies, the value of contrast enhanced EUS in the diagnostic of pancreatic masses has been evaluated<sup>[18-23]</sup>, showing good diagnostic value. This was in principally reached with the help of time consuming quantitative ultrasound data analysis later on.

With this study, we want to determine the diagnostic value of qualitative, immediately analysed contrast enhanced harmonic EUS (CEH-EUS) in comparison with precise quantitative analyses for the diagnostic of various pancreatic masses in daily routine in a single centre cohort.

## MATERIALS AND METHODS

Data of all patients with undetermined solid pancreatic masses who underwent EUS procedures with application of contrast agent was included in the retrospective analysis. Patients with predominantly cystic pancreatic lesions were not included.

Video documented data sets of CEH-EUS investigations of these patients were evaluated. All investigations have been performed during clinical routine procedures.

Investigations were carried out as follows: Standard B-mode EUS was performed in all patients with suspected pancreatic masses. If undetermined masses were found, size, location and echogenicity were documented. The patient underwent CEH-EUS if no contraindications, including, age under 18 years, pregnancy, lactation, severe heart failure, severe chronic obstructive pulmonary disease, known allergic disposition to SonoVue®, were present.

CEH-EUS was performed as follows: Numerous patients with focal pancreatic lesions undergoing EUS investigations in our facility from April 2011 till September 2016 received 5mL SonoVue (Bracco s.p.a., Milan, Italy) *via* cubital vein catheter, followed by a saline flush. The echoendoscope used was Hitachi/Pentax EG3670URK or EG3870UTK (Hitachi Medical Corp., Tokyo, Japan) the ultrasound processor Hitachi Preirus (Hitachi Medical Corp., Tokyo, Japan). Observation of the pancreatic lesion was performed for at least one minute after SonoVue® injection.

The investigator was not blinded to the previous history of each patient. First clinical evaluation of qualitative contrast agent characteristics (hypo-enhanced, iso-enhanced, hyper-enhanced or non-enhanced) was performed immediately by the investigator upon the endoscopic procedure and documented in the physician's report. Investigations were carried out by TK, RM, KK and CM, blinded video data analysis later on was performed by KK; all investigators had several years of experience with both EUS and contrast enhanced ultrasound.

Ultrasound video sequences were continuously recorded and then analysed later on, using the analysis software of the ultrasound processor (Hitachi Preirus). This software allows quantification of ultrasound signal intensity over time in regions of interest, which are defined by the analysing physician.

Analysis of the recorded video data included arrival time (AT), time to peak (TTP), maximum intensity gain and area under the curve. To rule out circulation time error, two regions of interest were defined; one in the suspicious pancreatic lesion, one in pancreatic tissue besides the lesion. Hypo-enhancement was defined as signal intensity of at least 5 db below, hyper-enhancement as signal intensity of at least 5 db above the intensity of the pancreatic tissue surrounding the lesion.

In all patients EUS-FNA, transcutaneous biopsy or surgical resection was performed to allow cytology or histology assessment, which served as the gold standard.

For statistical analyses calculation of means and standard deviations as well as sensitivity, specificity, positive and negative predictive values were carried out with the help of SPSS SigmaPlot, V.10.0.0.54. Predictive values were calculated on the basis of the investigated cohort.

As a retrospective analysis, institutional review board approval was seen not to be necessary by the local ethics committee. However, all patients signed informed consent for the investigations and for the contrast agent application.

## RESULTS

Data sets of 55 patients were analysed. The mean patient age was  $66.5 \pm 12.5$  years

(range: 24-83 years). 32 patients were male and 23 patients were female.

Of those 55 patients, CEH-EUS showed hypoenhanced lesions in 39 cases, while in 13 patients contrast agent characteristics were classified as hyperenhanced by the investigator upon investigation and 3 lesions as non-enhanced. Calculation of signal intensity later on showed signal intensity of  $6.1 \pm 3.2$  db for lesions classified as hypoenhanced and  $39.0 \pm 13.0$  db for lesions classified as hyperenhanced. Non-enhanced lesions showed signal intensity of  $1.3 \pm 0.3$  db (Table 1).

Endosonographic healthy appearing pancreatic tissue showed signal intensity of  $23.1 \pm 9.1$  db.

Concordance of the investigators evaluation and classification of contrast enhancement with precise analysis later on was found to be 100%.

Regarding hypoenhanced lesions, 34 lesions with low contrast enhancement were proven as pancreatic adenocarcinoma (intensity  $5.7 \pm 2.5$  db) and in 5 patients chronic pancreatitis lesions showed up hypoenhanced ( $6.0 \pm 3.0$  db). Those patients remained under endosonographic follow up including FNA. Figure 1 shows an example of time intensity curves of pancreatic adenocarcinoma compared to healthy pancreatic tissue. All non-enhanced lesions showed up as necrosis of the pancreas.

Hyperenhanced lesions were of inflammatory origin in 4 cases (1 patient with autoimmune pancreatitis, 3 patients with active chronic pancreatitis) showing signal intensity of  $34.0 \pm 11.9$  db, in 3 patients due to neuroendocrine carcinoma ( $33.0 \pm 12.0$  db), in 1 case a lymphoma (45 db), in 1 case an insulinoma (29 db) and in 4 patients metastases, of which 2 were of renal cell carcinoma and 2 of lung cancer, was diagnosed ( $56.0 \pm 5.6$  db). Figure 2 shows ultrasound images of hyperenhanced neuroendocrine carcinoma and pancreatic adenocarcinoma.

Sensitivity for the detection of pancreatic adenocarcinoma was 100%, specificity 73.6% for low contrast agent enhancement alone. Taking also standard EUS evaluation of the whole pancreas into account, all hypoenhanced lesions in otherwise endosonographically healthy appearing pancreatic tissue were pancreatic adenocarcinoma (sensitivity and specificity 100%). In our cohort, positive predictive value for pancreatic adenocarcinoma was 87.2% for contrast agent characteristics alone, taking native tissue characteristics into account 100%. Negative predictive value was 100% in both cases. Statistics of inflammatory and neoplastic lesions are given in Table 2.

The analysis of further contrast agent characteristics [area under the time intensity curve (AUC), TTP, AT] did not yield helpful results in everyday routine; in 13 hypoenhanced lesions calculation of these parameters was impossible due to low contrast enhancement. In 5 cases data sets of areas used as reference in macroscopic normal appearing tissue could not be analysed for these parameters, mostly due to breathing artefacts. While analysis of AT and TTP did not show clear differences between any lesions and their reference areas, AUC analysis, where possible, showed the same tendency as the maximum peak intensity data, but suffered from substantial interindividual differences and did therefore not improve the diagnostic value (Table 3).

With the limitations of a retrospective analysis no side effects of contrast agent application were documented.

## DISCUSSION

In the present study, we assessed the value of the qualitative, immediate analysis of CEH-EUS in the diagnostic of solid pancreatic lesions in comparison to precise and time consuming quantitative processing.

As shown above, CEH-EUS had an excellent diagnostic value if hypoenhanced lesions were detected. Of those lesions located in healthy pancreatic tissue all were diagnosed with pancreatic adenocarcinoma, making cytology results possibly dispensable, especially in the case of resectable lesions preoperatively, thereby reducing the risk for complications *e.g.*, bleeding, infection, or causing local tumor cell seeding. Especially in case of nondiagnostic FNA results, hypoenhanced masses in otherwise healthy pancreatic tissue could be surgically resected without further efforts of cytology sampling.

Accuracy was independent from patient characteristics such as gender, age, comorbidities and tumor size. As harmonic imaging technique, CEH-EUS offers better image resolution than power doppler imaging of suspicious lesions.

While in some other studies quantitative evaluations were helpful<sup>[21,24]</sup>, our data shows the value of this technique in everyday routine by the investigators immediate evaluation of contrast agent characteristics without complex and time consuming image analysis after the actual examination. Moreover, precise quantitative



**Table 1 Patient characteristics**

	Hypoenhanced lesions	Hyperenhanced lesions	$\Sigma$
Patient age (yr)	72.1 $\pm$ 6.7	66.7 $\pm$ 15.3	66.5 $\pm$ 12.5
Gender (m/f)	23/19	9/4	32/23
Lesion size (mm)	34.8 $\pm$ 13.7	36.0 $\pm$ 15.6	35.1 $\pm$ 14.0
Peak signal intensity (db)	6.1 $\pm$ 3.2	39.0 $\pm$ 13.0	

db: Decibel.

assessment including AUC analysis was of no better value than both measurement of ultrasound signal intensity and qualitative contrast enhancement evaluation during the investigations.

Despite some recent studies<sup>[24-26]</sup> the value of CEH-EUS to distinguish chronic pancreatitis lesions from malignancies was very limited in our cohort, as on the one hand also benign chronic inflammatory lesions showed up hypoenhanced, on the other hand active inflammation resulted in stronger contrast enhancement. Especially with the increased risk of malignancies in patients with chronic pancreatitis, accurate diagnostic tools are needed, and at least in our hands CEH-EUS alone showed an unsatisfactory sensitivity and specificity. This suggests that in abnormal pancreatic tissue, CEH-EUS still does not offer sufficient accuracy to exclude malignancies, which makes EUS-FNA essential.

The low perfusion of both chronic pancreatitis lesions and pancreatic adenocarcinoma can be explained through the stromal richness of both lesions with only few capillaries. Possibly, EUS elastography of the pancreas may be able to distinguish these lesions from each other<sup>[27,28]</sup>, while data is still limited.

Looking at hyperenhanced lesions, various pathologies including metastases could be detected. This makes histologic or cytologic sampling essential for further treatment and diagnosis.

Diagnostic tools should be easily accessible, quick and easy to apply and safe while showing reliable and reproducible results. Regarding side effects, none were documented in this retrospective analysis, which is consistent with the general experience of SonoVue® application. Although not exactly measured, contrast agent application required only a few extra minutes of investigation and sedation time.

In a prospective analysis, Gincul *et al*<sup>[29]</sup> could show that various perfusion parameters which were analysed after CEH-EUS procedures showed good correlation with the diagnosis of pancreatic adenocarcinoma, which is confirmed by our data. Taking time effectiveness into account, initial evaluation of the contrast agent behaviour was consistent with precise analysis later on. Further calculation of ultrasound data later on does not increase the diagnostic value and therefore does not appear to be necessary, making the contrast enhancement evaluation easy and quick.

EUS itself has become a standard procedure for the diagnostic of intestinal diseases, offering better image resolutions and fewer limitations like meteorism. Although risk of intestinal injury is slightly increased, EUS is in general a well-tolerated and fast spreading technique also with the elderly patients<sup>[1,30]</sup>.

Although it has become a routine procedure, biopsy sampling *via* EUS-FNA sometimes lacks diagnostic accuracy<sup>[3,31]</sup>, showing false negative and sometimes false positive results while there is the risk of bleeding and infectious complications in addition to a low but potential risk of local seeding of tumor cells<sup>[32-35]</sup>.

Patient safety could therefore be increased and treatment costs could be reduced if patients with potentially resectable hypoenhanced lesions could be preoperatively diagnosed in an outpatient setting without cytologic sampling while those with hyperenhanced lesions definitely require further diagnostics as surgery might not be the optimal choice of treatment.

In conclusion, CEH-EUS showed good diagnostic accuracy, especially in case of hypoenhanced lesions. If situated in healthy pancreatic lesions, pancreatic adenocarcinoma is highly suspicious and patients may be sent for surgical resection without further cytology assessment. In case of hyperenhanced lesions, cytology or histology are crucial for guiding further treatment, as a variety of pathologies may show up with hyperenhancement.

In our hands, CEH-EUS showed excellent results also using qualitative analysis of contrast agent characteristics without complicated and time consuming analyses of ultrasound data later on, proving its value for everyday routine practice.

**Table 2 Statistics**

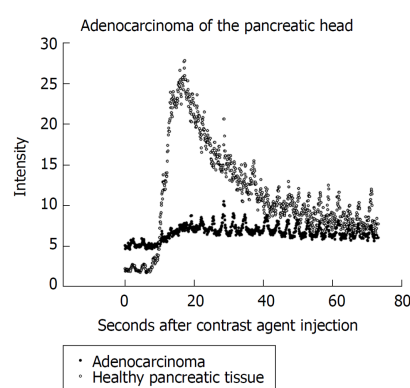
	Peak intensity (db)	Sensitivity	Specificity	PPV	NPV
Hypoenhanced lesions					
Adenocarcinoma (all in healthy pancreas)	5.7 ± 2.5	100%	100%	100%	100%
Chronic pancreatitis lesions	6.0 ± 3.0	100%	23.30%	13%	100%
Hyperenhanced lesions					
Acute inflammatory lesions	34.0 ± 11.9	100%	79.10%	30.80%	81.70%
Neoplastic lesions	32.1 ± 10.2	20.90%	55.50%	69.20%	12.80%

PPV: Positive predictive value; NPV: Negative predictive value; db: Decibel.

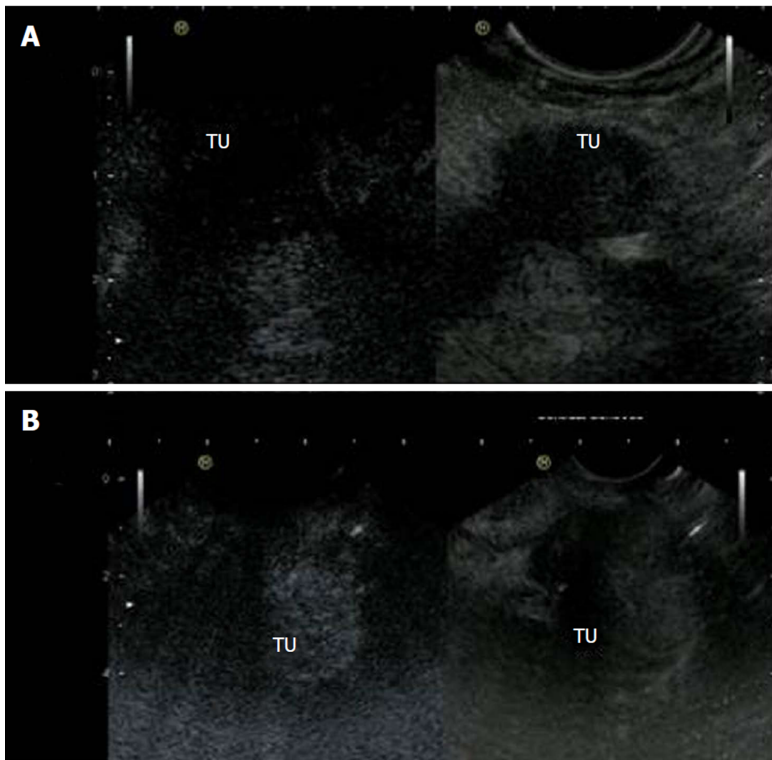
**Table 3 Quantitative analysis of different perfusion parameters**

Lesion	AT lesion (s)	AT non-lesion (s)	TTP lesion (s)	TTP non-lesion (s)	AUC lesion (db × s)	AUC non-lesion (db × s)	PI lesion (db)	PI non-lesion (db)
Pancreatic adenocarcinoma	11.70 ± 3.87 (n = 25/34)	11.49 ± 3.26 (n = 31/34)	20.58 ± 4.89 (n = 25/34)	22.41 ± 6.52 (n = 31/34)	238.52 ± 150.63 (n = 25/34)	912.34 ± 359.40 (n = 31/34)	5.77 ± 2.54 (n = 34/34)	21.6 ± 8.6 (n = 34/34)
Chronic pancreatitis	11.92 ± 4.61 (n = 4/8)	11 ± 1.00 (n = 6/8)	22.42 ± 4.83 (n = 4/8)	22.33 ± 1.52 (n = 6/8)	424.41 ± 188.83 (n = 4/8)	681.96 ± 216.22 (n = 6/8)	13.5 ± 12.0 (n = 8/8)	22.0 ± 5.8 (n = 8/8)
Neuroendocrine Carcinoma	10.2 ± 1.98 (n = 3)	10.0 ± 1.41 (n = 3)	22.00 ± 1.41 (n = 3)	20.50 ± 0.70 (n = 3)	1410.80 ± 535.56 (n = 3)	855.55 ± 190.14 (n = 3)	31 ± 8.3 (n = 3/3)	20.3 ± 7.5 (n = 3/3)
Metastases (RCC / LC)	10.00 ± 2.82 (n = 2/2)	10.5 ± 2.12 (n = 2/2)	30 ± 14.14 (n = 2/2)	31.00 ± 15.55 (n = 2/2)	2941.95 ± 1067.51 (n = 2/2)	1081.40 ± 1096.43 (n = 2/2)	56.0 ± 5.6 (n = 2/2)	31.5 ± 2.1 (n = 2/2)
Immune-pancreatitis	12 (n = 1)	12 (n = 1)	21 (n = 1)	22 (n = 1)	77032 (n = 1)	6036 (n = 1)	28 (n = 1)	16 (n = 1)
Lymphoma	6 (n = 1)	8 (n = 1)	11 (n = 1)	19 (n = 1)	1570.7 (n = 1)	913.1 (n = 1)	45 (n = 1)	28 (n = 1)
Insulinoma	13 (n = 1)	13 (n = 1)	23 (n = 1)	23 (n = 1)	721.0 (n = 1)	802.0 (n = 1)	16 (n = 1)	18 (n = 1)

AT: Arrival time; TTP: Time to peak intensity; AUC: Area under the curve; PI: Peak intensity; RCC: Renal cell carcinoma; LC: Lung cancer; db: Decibel.



**Figure 1** During contrast enhanced harmonic endoscopic ultrasound procedures patients received 5 mL SonoVue® contrast agent. The figure shows an example of ultrasound signal intensity curves of healthy pancreatic tissue and pancreatic adenocarcinoma.



**Figure 2** Contrast enhanced harmonic endoscopic ultrasound images of hypoechoic pancreatic adenocarcinoma and hyperenhancement of neuroendocrine carcinoma. A: Contrast enhanced harmonic endoscopic ultrasound (CEH-EUS) images of hypoechoic pancreatic adenocarcinoma; B: CEH-EUS images of neuroendocrine carcinoma. TU: Tumor left side.

## ARTICLE HIGHLIGHTS

### Research background

While some studies have shown that quantitative analysis of contrast enhanced endoscopic ultrasound (CEH-EUS) helps to identify pancreatic adenocarcinoma, there are less data from everyday routine. For non-adenocarcinoma lesions, less information of contrast agent characteristics has been published so far.

### Research motivation

As in pancreatic malignancies surgery is the only potential cure, quick and efficient diagnostics are needed to guide further therapy and avoid unnecessary delay. As biopsy sampling from fine needle aspiration (EUS-FNA) requires diagnostics in an inpatient setting, alternative methods with good diagnostic accuracy would make outpatient diagnostics possible, which would be both time saving and less expensive.

### Research objectives

The main research objective was to show the value of CEH-EUS in the daily routine diagnostic of various pancreatic lesions. Besides the hypoechoic pancreatic adenocarcinoma, which was quantitatively shown before, various other pancreatic lesions warrant future research.

### Research methods

CEH-EUS data of 55 patients with solid pancreatic lesions were analysed regarding contrast agent characteristics. Statistical analysis of time to peak, peak intensity, area under the time intensity curve, arrival time were compared to qualitative evaluation during the investigation, while histological specimen or FNA results served as gold standard.

### Research results

All pancreatic adenocarcinoma showed up hypoechoic, while several other lesions including metastases of other origin, lymphoma and inflammatory lesions showed up hyperenhanced. Quantitative analysis of the EUS data did not add any value to the qualitative evaluation. Moreover, calculation of the quantitative parameters was in some cases difficult, among others due to low signal intensity in hypoechoic lesions or due to moving artifacts.

### Research conclusions

Qualitative evaluation of contrast agent characteristics is sufficient to identify pancreatic adenocarcinoma in healthy pancreatic tissue and could make EUS-FNA in patients with resectable disease dispensable. Hyperenhanced pancreatic lesions can be of various origin, which

makes histological sampling essential.

### Research perspectives

Especially for hyperenhanced pancreatic lesions, prospective studies are needed to broaden the experience with this interesting technique. Possibly, algorithms with different techniques such as CEH-EUS and EUS-elastography could further help to classify pancreatic masses in difficult situations such as chronic pancreatitis patients.

## REFERENCES

- 1 Sedlack R, Affi A, Vazquez-Sequeiros E, Norton ID, Clain JE, Wiersema MJ. Utility of EUS in the evaluation of cystic pancreatic lesions. *Gastrointest Endosc* 2002; **56**: 543-547 [PMID: [12297771](#) DOI: [10.1067/mge.2002.128106](#)]
- 2 Kliment M, Urban O, Cegan M, Fojtik P, Falt P, Dvorackova J, Lovecek M, Straka M, Jaluvka F. Endoscopic ultrasound-guided fine needle aspiration of pancreatic masses: the utility and impact on management of patients. *Scand J Gastroenterol* 2010; **45**: 1372-1379 [PMID: [20626304](#) DOI: [10.3109/00365521.2010.503966](#)]
- 3 Gleeson FC, Kipp BR, Caudill JL, Clain JE, Clayton AC, Halling KC, Henry MR, Rajan E, Topazian MD, Wang KK, Wiersema MJ, Zhang J, Levy MJ. False positive endoscopic ultrasound fine needle aspiration cytology: incidence and risk factors. *Gut* 2010; **59**: 586-593 [PMID: [20427392](#) DOI: [10.1136/gut.2009.187765](#)]
- 4 Turner BG, Cizginer S, Agarwal D, Yang J, Pitman MB, Brugge WR. Diagnosis of pancreatic neoplasia with EUS and FNA: a report of accuracy. *Gastrointest Endosc* 2010; **71**: 91-98 [PMID: [19846087](#) DOI: [10.1016/j.gie.2009.06.017](#)]
- 5 Laquiere A, Lefort C, Maire F, Aubert A, Gincul R, Prat F, Grandval P, Croizet O, Boulant J, Vanbiervliet G, Pénaranda G, Lecomte L, Napoléon B, Boustière C. 19 G nitinol needle versus 22 G needle for transduodenal endoscopic ultrasound-guided sampling of pancreatic solid masses: a randomized study. *Endoscopy* 2018 [PMID: [30453379](#) DOI: [10.1055/a-0757-7714](#)]
- 6 Taylor B. Carcinoma of the head of the pancreas versus chronic pancreatitis: diagnostic dilemma with significant consequences. *World J Surg* 2003; **27**: 1249-1257 [PMID: [14502404](#) DOI: [10.1007/s00268-003-7245-8](#)]
- 7 Fathy O, Wahab MA, Elghwalby N, Sultan A, EL-Ebidi G, Hak NG, Abu Zeid M, Abd-Allah T, El-Shobary M, Fouad A, Kandeel T, Abo Elenien A, Abd El-Raouf A, Hamdy E, Sultan AM, Hamdy E, Ezzat F. 216 cases of pancreaticoduodenectomy: risk factors for postoperative complications. *Hepatogastroenterology* 2008; **55**: 1093-1098 [PMID: [18705336](#)]
- 8 Rettenbacher T. Focal liver lesions: role of contrast-enhanced ultrasound. *Eur J Radiol* 2007; **64**: 173-182 [PMID: [17900841](#) DOI: [10.1016/j.ejrad.2007.07.026](#)]
- 9 Xu ZF, Xu HX, Xie XY, Liu GJ, Zheng YL, Liang JY, Lu MD. Renal cell carcinoma: real-time contrast-enhanced ultrasound findings. *Abdom Imaging* 2010; **35**: 750-756 [PMID: [19844755](#) DOI: [10.1007/s00261-009-9583-y](#)]
- 10 Bertolotto M, Martegani A, Aiani L, Zappetti R, Cernic S, Cova MA. Value of contrast-enhanced ultrasonography for detecting renal infarcts proven by contrast enhanced CT. A feasibility study. *Eur Radiol* 2008; **18**: 376-383 [PMID: [17851664](#) DOI: [10.1007/s00330-007-0747-2](#)]
- 11 Girlich C, Schacherer D, Lamby P, Scherer MN, Schreyer AG, Jung EM. Innovations in contrast enhanced high resolution ultrasound improve sonographic imaging of the intestine. *Clin Hemorheol Microcirc* 2010; **45**: 207-215 [PMID: [20675901](#)]
- 12 Kannengiesser K, Mahlke R, Petersen F, Peters A, Ross M, Kucharzik T, Maaser C. Contrast-enhanced harmonic endoscopic ultrasound is able to discriminate benign submucosal lesions from gastrointestinal stromal tumors. *Scand J Gastroenterol* 2012; **47**: 1515-1520 [PMID: [23148660](#) DOI: [10.3109/00365521.2012.729082](#)]
- 13 Sanchez MV, Varadarajulu S, Napoleon B. EUS contrast agents: what is available, how do they work, and are they effective? *Gastrointest Endosc* 2009; **69**: S71-S77 [PMID: [19179175](#) DOI: [10.1016/j.gie.2008.12.004](#)]
- 14 Nakaizumi A, Uehara H, Iishi H, Tatsuta M, Kitamura T, Kuroda C, Ohigashi H, Ishikawa O, Okuda S. Endoscopic ultrasonography in diagnosis and staging of pancreatic cancer. *Dig Dis Sci* 1995; **40**: 696-700 [PMID: [7895567](#)]
- 15 Reddymasu SC, Gupta N, Singh S, Oropeza-Vail M, Jafri SF, Olyae M. Pancreato-biliary malignancy diagnosed by endoscopic ultrasonography in absence of a mass lesion on transabdominal imaging: prevalence and predictors. *Dig Dis Sci* 2011; **56**: 1912-1916 [PMID: [21188524](#) DOI: [10.1007/s10620-010-1511-z](#)]
- 16 Kitano M, Sakamoto H, Matsui U, Ito Y, Maekawa K, von Schrenck T, Kudo M. A novel perfusion imaging technique of the pancreas: contrast-enhanced harmonic EUS (with video). *Gastrointest Endosc* 2008; **67**: 141-150 [PMID: [18155437](#) DOI: [10.1016/j.gie.2007.07.045](#)]
- 17 Imazu H, Uchiyama Y, Matsunaga K, Ikeda K, Kakutani H, Sasaki Y, Sumiyama K, Ang TL, Omar S, Tajiri H. Contrast-enhanced harmonic EUS with novel ultrasonographic contrast (Sonazoid) in the preoperative T-staging for pancreaticobiliary malignancies. *Scand J Gastroenterol* 2010; **45**: 732-738 [PMID: [20205504](#) DOI: [10.3109/00365521003690269](#)]
- 18 Hocke M, Ignee A, Dietrich CF. Contrast-enhanced endoscopic ultrasound in the diagnosis of autoimmune pancreatitis. *Endoscopy* 2011; **43**: 163-165 [PMID: [21165827](#) DOI: [10.1055/s-0030-1256022](#)]
- 19 Napoleon B, Alvarez-Sanchez MV, Gincoul R, Pujol B, Lefort C, Lepilliez V, Labadie M, Souquet JC, Queneau PE, Scoazec JY, Chayvialle JA, Ponchon T. Contrast-enhanced harmonic endoscopic ultrasound in solid lesions of the pancreas: results of a pilot study. *Endoscopy* 2010; **42**: 564-570 [PMID: [20593334](#) DOI: [10.1055/s-0030-1255537](#)]
- 20 Kitano M, Kudo M, Yamao K, Takagi T, Sakamoto H, Komaki T, Kamata K, Imai H, Chiba Y, Okada M, Murakami T, Takeyama Y. Characterization of small solid tumors in the pancreas: the value of contrast-enhanced harmonic endoscopic ultrasonography. *Am J Gastroenterol* 2012; **107**: 303-310 [PMID: [22008892](#) DOI: [10.1038/ajg.2011.354](#)]

- 21 **Matsubara H**, Itoh A, Kawashima H, Kasugai T, Ohno E, Ishikawa T, Itoh Y, Nakamura Y, Hiramatsu T, Nakamura M, Miyahara R, Ohmiya N, Ishigami M, Katano Y, Goto H, Hirooka Y. Dynamic quantitative evaluation of contrast-enhanced endoscopic ultrasonography in the diagnosis of pancreatic diseases. *Pancreas* 2011; **40**: 1073-1079 [PMID: [21633317](#) DOI: [10.1097/MPA.0b013e31821f57b7](#)]
- 22 **Săftoiu A**, Vilman P, Dietrich CF, Iglesias-Garcia J, Hocke M, Seicean A, Ignee A, Hassan H, Streba CT, Ioniță AM, Gheonea DI, Ciurea T. Quantitative contrast-enhanced harmonic EUS in differential diagnosis of focal pancreatic masses (with videos). *Gastrointest Endosc* 2015; **82**: 59-69 [PMID: [25792386](#) DOI: [10.1016/j.gie.2014.11.040](#)]
- 23 **Yamashita Y**, Kato J, Ueda K, Nakamura Y, Kawaji Y, Abe H, Nuta J, Tamura T, Itonaga M, Yoshida T, Maeda H, Maekita T, Iguchi M, Tamai H, Ichinose M. Contrast-Enhanced Endoscopic Ultrasonography for Pancreatic Tumors. *Biomed Res Int* 2015; **2015**: 491782 [PMID: [26090411](#) DOI: [10.1155/2015/491782](#)]
- 24 **Gheonea DI**, Streba CT, Ciurea T, Săftoiu A. Quantitative low mechanical index contrast-enhanced endoscopic ultrasound for the differential diagnosis of chronic pseudotumoral pancreatitis and pancreatic cancer. *BMC Gastroenterol* 2013; **13**: 2 [PMID: [23286918](#) DOI: [10.1186/1471-230X-13-2](#)]
- 25 **Gong TT**, Hu DM, Zhu Q. Contrast-enhanced EUS for differential diagnosis of pancreatic mass lesions: a meta-analysis. *Gastrointest Endosc* 2012; **76**: 301-309 [PMID: [22703697](#) DOI: [10.1016/j.gie.2012.02.051](#)]
- 26 **Park JS**, Kim HK, Bang BW, Kim SG, Jeong S, Lee DH. Effectiveness of contrast-enhanced harmonic endoscopic ultrasound for the evaluation of solid pancreatic masses. *World J Gastroenterol* 2014; **20**: 518-524 [PMID: [24574720](#) DOI: [10.3748/wjg.v20.i2.518](#)]
- 27 **Iglesias-Garcia J**, Domínguez-Muñoz JE, Castiñeira-Alvarino M, Luaces-Regueira M, Lariño-Noia J. Quantitative elastography associated with endoscopic ultrasound for the diagnosis of chronic pancreatitis. *Endoscopy* 2013; **45**: 781-788 [PMID: [24019131](#) DOI: [10.1055/s-0033-1344614](#)]
- 28 **Săftoiu A**, Vilman P. Differential diagnosis of focal pancreatic masses by semiquantitative EUS elastography: between strain ratios and strain histograms. *Gastrointest Endosc* 2013; **78**: 188-189 [PMID: [23820413](#) DOI: [10.1016/j.gie.2013.01.024](#)]
- 29 **Gincul R**, Palazzo M, Pujol B, Tubach F, Palazzo L, Lefort C, Fumex F, Lombard A, Ribeiro D, Fabre M, Hervieu V, Labadie M, Ponchon T, Napoléon B. Contrast-harmonic endoscopic ultrasound for the diagnosis of pancreatic adenocarcinoma: a prospective multicenter trial. *Endoscopy* 2014; **46**: 373-379 [PMID: [24532350](#) DOI: [10.1055/s-0034-1364969](#)]
- 30 **Kurt M**, Oguz D, Oztas E, Kalkan IH, Sayilir A, Beyazit Y, Sasmaz N. Safety of endoscopic ultrasonography in elderly patients: a single center prospective trial. *Aging Clin Exp Res* 2013; **25**: 571-574 [PMID: [24026626](#) DOI: [10.1007/s40520-013-0138-2](#)]
- 31 **Madhoun MF**, Wani SB, Rastogi A, Early D, Gaddam S, Tierney WM, Maple JT. The diagnostic accuracy of 22-gauge and 25-gauge needles in endoscopic ultrasound-guided fine needle aspiration of solid pancreatic lesions: a meta-analysis. *Endoscopy* 2013; **45**: 86-92 [PMID: [23307148](#) DOI: [10.1055/s-0032-1325992](#)]
- 32 **Kien-Fong Vu C**, Chang F, Doig L, Meenan J. A prospective control study of the safety and cellular yield of EUS-guided FNA or Trucut biopsy in patients taking aspirin, nonsteroidal anti-inflammatory drugs, or prophylactic low molecular weight heparin. *Gastrointest Endosc* 2006; **63**: 808-813 [PMID: [16650543](#) DOI: [10.1016/j.gie.2005.09.033](#)]
- 33 **Levy MJ**, Gleeson FC, Campion MB, Caudill JL, Clain JE, Halling K, Rajan E, Topazian MD, Wang KK, Wiersma MJ, Clayton A. Prospective cytological assessment of gastrointestinal luminal fluid acquired during EUS: a potential source of false-positive FNA and needle tract seeding. *Am J Gastroenterol* 2010; **105**: 1311-1318 [PMID: [20197762](#) DOI: [10.1038/ajg.2010.80](#)]
- 34 **Levy MJ**, Norton ID, Wiersma MJ, Schwartz DA, Clain JE, Vazquez-Sequeiros E, Wilson WR, Zinsmeister AR, Jondal ML. Prospective risk assessment of bacteremia and other infectious complications in patients undergoing EUS-guided FNA. *Gastrointest Endosc* 2003; **57**: 672-678 [PMID: [12709695](#) DOI: [10.1067/mge.2003.204](#)]
- 35 **Tomonari A**, Katanuma A, Matsumori T, Yamazaki H, Sano I, Minami R, Sen-yo M, Ikarashi S, Kin T, Yane K, Takahashi K, Shinohara T, Maguchi H. Resected tumor seeding in stomach wall due to endoscopic ultrasonography-guided fine needle aspiration of pancreatic adenocarcinoma. *World J Gastroenterol* 2015; **21**: 8458-8461 [PMID: [26217099](#) DOI: [10.3748/wjg.v21.i27.8458](#)]

**P- Reviewer:** Isik A, Kopljär M, Cui XW

**S- Editor:** Dou Y **L- Editor:** A **E- Editor:** Bian YN





Published By Baishideng Publishing Group Inc  
7901 Stoneridge Drive, Suite 501, Pleasanton, CA 94588, USA  
Telephone: +1-925-2238242  
Fax: +1-925-2238243  
E-mail: [bpgoffice@wjgnet.com](mailto:bpgoffice@wjgnet.com)  
Help Desk: <https://www.f6publishing.com/helpdesk>  
<https://www.wjgnet.com>

