


World Journal of *Clinical Cases*

World J Clin Cases 2019 February 26; 7(4): 405-547



**MINIREVIEWS**

- 405** Immune checkpoint inhibitor-induced colitis: A comprehensive review
Som A, Mandaliya R, Alsaadi D, Farshidpour M, Charabaty A, Malhotra N, Mattar MC

ORIGINAL ARTICLE**Basic Study**

- 419** Formalin fixation on HER-2 and PD-L1 expression in gastric cancer: A pilot analysis using the same surgical specimens with different fixation times
Kai K, Yoda Y, Kawaguchi A, Minesaki A, Iwasaki H, Aishima S, Noshiro H

Case Control Study

- 431** Nested case-control study of multiple serological indexes and Brighton pediatric early warning score in predicting death of children with sepsis
Xie X, Li M, Xiong TT, Wang R, Xiao L

Retrospective Study

- 441** Intestinal endometriosis: Diagnostic ambiguities and surgical outcomes
Bong JW, Yu CS, Lee JL, Kim CW, Yoon YS, Park IJ, Lim SB, Kim JC

Randomized Controlled Trial

- 452** Efficacy of 1.2 L polyethylene glycol plus ascorbic acid for bowel preparations
Tamaki H, Noda T, Morita M, Omura A, Kubo A, Ogawa C, Matsunaka T, Shibato M

CASE REPORT

- 466** Congenital analbuminemia in a patient affected by hypercholesterolemia: A case report
Suppressa P, Carbonara C, Lugani F, Campagnoli M, Troiano T, Minchiotti L, Sabbà C
- 473** Primary leiomyosarcoma of the thyroid gland with prior malignancy and radiotherapy: A case report and review of literature
Vujosevic S, Krnjevic D, Bogojevic M, Vuckovic L, Filipovic A, Dunđerović D, Sopta J
- 482** Endoscopic resection for residual lesion of metastatic gastric cancer: A case report
Hayashi K, Suzuki S, Ikehara H, Okuno H, Irie A, Esaki M, Kusano C, Gotoda T, Moriyama M
- 489** Peritoneal cavernous hemangiomas: A case report
Fu LY, Chen HY, Diao XL, Wang ZJ
- 494** Recurrent acute liver failure associated with novel SCYL1 mutation: A case report
Li JQ, Gong JY, Knisely AS, Zhang MH, Wang JS

- 500** Therapeutic plasma exchange and continuous renal replacement therapy for severe hyperthyroidism and multi-organ failure: A case report
Ba JH, Wu BQ, Wang YH, Shi YF
- 508** Hydrochloric acid enhanced radiofrequency ablation for treatment of large hepatocellular carcinoma in the caudate lobe: Report of three cases
Deng HX, Huang JH, Lau WY, Ai F, Chen MS, Huang ZM, Zhang TQ, Zuo MX
- 516** Long-term follow-up of a patient with venlafaxine-induced diurnal bruxism treated with an occlusal splint: A case report
Chen JM, Yan Y
- 525** Primary hepatic leiomyosarcoma successfully treated by transcatheter arterial chemoembolization: A case report
Zhu KL, Cai XJ
- 532** Anterior cervical corpectomy decompression and fusion for cervical kyphosis in a girl with Ehlers-Danlos syndrome: A case report
Fang H, Liu PF, Ge C, Zhang WZ, Shang XF, Shen CL, He R
- 538** Rhombencephalitis caused by *Listeria monocytogenes* with hydrocephalus and intracranial hemorrhage: A case report and review of the literature
Liang JJ, He XY, Ye H

ABOUT COVER

Editorial Board Member of *World Journal of Clinical Cases*, Xi Jin, PhD, Associate Professor, Doctor, Department of Gastroenterology, Institution of Gastroenterology, the First Affiliated Hospital, School of Medicine Zhejiang University, Zhejiang Province, Hangzhou 310003, China

AIMS AND SCOPE

World Journal of Clinical Cases (*World J Clin Cases*, *WJCC*, online ISSN 2307-8960, DOI: 10.12998) is a peer-reviewed open access academic journal that aims to guide clinical practice and improve diagnostic and therapeutic skills of clinicians.

The primary task of *WJCC* is to rapidly publish high-quality Case Report, Clinical Management, Editorial, Field of Vision, Frontier, Medical Ethics, Original Articles, Meta-Analysis, Minireviews, and Review, in the fields of allergy, anesthesiology, cardiac medicine, clinical genetics, clinical neurology, critical care, dentistry, dermatology, emergency medicine, endocrinology, family medicine, gastroenterology and hepatology, etc.

INDEXING/ABSTRACTING

The *WJCC* is now indexed in PubMed, PubMed Central, Science Citation Index Expanded (also known as SciSearch®), and Journal Citation Reports/Science Edition. The 2018 Edition of Journal Citation Reports cites the 2017 impact factor for *WJCC* as 1.931 (5-year impact factor: N/A), ranking *WJCC* as 60 among 154 journals in Medicine, General and Internal (quartile in category Q2).

RESPONSIBLE EDITORS FOR THIS ISSUE

Responsible Electronic Editor: *Wen-Wen Tan*

Proofing Editorial Office Director: *Jin-Lai Wang*

NAME OF JOURNAL

World Journal of Clinical Cases

ISSN

ISSN 2307-8960 (online)

LAUNCH DATE

April 16, 2013

FREQUENCY

Semimonthly

EDITORS-IN-CHIEF

Dennis A Bloomfield, Sandro Vento

EDITORIAL BOARD MEMBERS

<https://www.wjgnet.com/2307-8960/editorialboard.htm>

EDITORIAL OFFICE

Jin-Lai Wang, Director

PUBLICATION DATE

February 26, 2019

COPYRIGHT

© 2019 Baishideng Publishing Group Inc

INSTRUCTIONS TO AUTHORS

<https://www.wjgnet.com/bpg/gerinfo/204>

GUIDELINES FOR ETHICS DOCUMENTS

<https://www.wjgnet.com/bpg/GerInfo/287>

GUIDELINES FOR NON-NATIVE SPEAKERS OF ENGLISH

<https://www.wjgnet.com/bpg/gerinfo/240>

PUBLICATION MISCONDUCT

<https://www.wjgnet.com/bpg/gerinfo/208>

ARTICLE PROCESSING CHARGE

<https://www.wjgnet.com/bpg/gerinfo/242>

STEPS FOR SUBMITTING MANUSCRIPTS

<https://www.wjgnet.com/bpg/GerInfo/239>

ONLINE SUBMISSION

<https://www.f6publishing.com>

Endoscopic resection for residual lesion of metastatic gastric cancer: A case report

Kaori Hayashi, Sho Suzuki, Hisatomo Ikehara, Hiroaki Okuno, Akira Irie, Mitsuru Esaki, Chika Kusano, Takuji Gotoda, Mitsuhiko Moriyama

ORCID number: Kaori Hayashi (0000-0001-9210-3186); Sho Suzuki (0000-0003-4831-1409); Hisatomo Ikehara (0000-0001-9239-7495); Hiroaki Okuno (0000-0002-3020-7315); Akira Irie (0000-0002-6651-8510); Mitsuru Esaki (0000-0001-7353-2153); Chika Kusano (0000-0002-3789-4787); Takuji Gotoda (0000-0001-6904-6777); Mitsuhiko Moriyama (0000-0002-4617-508X).

Author contributions: Hayashi K, Suzuki S, Ikehara H, Okuno H, Irie A, Esaki M, Kusano C, Gotoda T, Moriyama M wrote the paper.

Informed consent statement: Consent was obtained from the patient for publication of this report and any accompanying images.

Conflict-of-interest statement: The authors declare that they have no conflicts of interest.

CARE Checklist (2016) statement: The authors have read the CARE Checklist (2016), and the manuscript was prepared and revised according to the CARE Checklist-2016.

Open-Access: This article is an open-access article which was selected by an in-house editor and fully peer-reviewed by external reviewers. It is distributed in accordance with the Creative Commons Attribution Non Commercial (CC BY-NC 4.0) license, which permits others to distribute, remix, adapt, build upon this work non-commercially, and license their derivative works

Kaori Hayashi, Sho Suzuki, Hisatomo Ikehara, Hiroaki Okuno, Akira Irie, Mitsuru Esaki, Chika Kusano, Takuji Gotoda, Mitsuhiko Moriyama, Division of Gastroenterology and Hepatology, Department of Medicine, Nihon University School of Medicine, Tokyo, Chiyoda-ku 1018309, Japan

Corresponding author: Sho Suzuki, MD, PhD, Doctor, Research Associate, Division of Gastroenterology and Hepatology, Department of Medicine, Nihon University School of Medicine, 1-6 Kanda-Surugadai, Tokyo, Chiyoda-ku 1018309, Japan.

s.sho.salubriter.mail@gmail.com

Telephone: +81-3-32931711

Fax: +81-3-32922880

Abstract

BACKGROUND

Chemotherapy is a standard strategy for stage IV gastric cancer patients. However, some cases cannot undergo conversion surgery because of their frailty, even if the patients had response to chemotherapy. For these patients, local tumor progression is a problem. We report here the case of a patient whose residual gastric cancer was resected through endoscopic submucosal dissection (ESD) after concomitant chemotherapy for metastatic gastric cancer.

CASE SUMMARY

An 85-year-old male complained of difficulty swallowing, and examination revealed gastric cancer with multiple liver metastases. Although he received concomitant chemotherapy, a residual tumor was observed in the primary lesion while the metastatic lesions disappeared completely. Conversion surgery was considered optional treatment; however, he could not undergo that because of advanced age and comorbidities. Thus, we performed ESD to treat the residual tumor. As a result, we resected the residual lesion completely. The patient has been alive for 29 mo since ESD, without recurrence.

CONCLUSION

We achieved local control using ESD, and these findings may provide therapeutic improvements both in local control and patient survival outcomes.

Key words: Gastric cancer; Liver metastases; Conversion; Endoscopic submucosal dissection; Chemotherapy; Case report

on different terms, provided the original work is properly cited and the use is non-commercial. See: <http://creativecommons.org/licenses/by-nc/4.0/>

Manuscript source: Invited manuscript

Received: October 29, 2018

Peer-review started: October 29, 2018

First decision: November 27, 2018

Revised: December 25, 2018

Accepted: January 8, 2019

Article in press: January 8, 2019

Published online: February 26, 2019

©The Author(s) 2019. Published by Baishideng Publishing Group Inc. All rights reserved.

Core tip: Some cases cannot undergo conversion surgery because of their frailty, even if the patients had response to chemotherapy. For these patients, local tumor progression is a problem. We resected a residual tumor completely using endoscopic submucosal dissection (ESD) after chemotherapy in an elderly patient who was unable to undergo conversion surgery due to his age and comorbidities. The patient has been alive without recurrence for 29 mo after the ESD. ESD may provide therapeutic improvements in both local control and patient survival outcomes.

Citation: Hayashi K, Suzuki S, Ikehara H, Okuno H, Irie A, Esaki M, Kusano C, Gotoda T, Moriyama M. Endoscopic resection for residual lesion of metastatic gastric cancer: A case report. *World J Clin Cases* 2019; 7(4): 482-488

URL: <https://www.wjgnet.com/2307-8960/full/v7/i4/482.htm>

DOI: <https://dx.doi.org/10.12998/wjcc.v7.i4.482>

INTRODUCTION

For patients with stage IV gastric cancer, chemotherapy is a standard treatment option. Improvements in chemotherapy regimens have improved patient survival^[1]; for example, patients' median survival time is longer and the response rate continues to rise^[2,3]. However, treatment outcomes for metastatic gastric cancer (mGC) remain unsatisfactory. Regardless, the improved efficacy of chemotherapy has led to the ability to perform surgery on tumors that were originally regarded as technically or oncologically unresectable or only marginally resectable. Conversion surgery is one treatment option with the potential to improve survival outcomes^[4]. Yet, some factors prevent surgical resection, particularly advanced age, low performance status, and comorbidity, even if the patient achieves a complete response from chemotherapy. Many of these patients also experience difficulties with continuing intensive chemotherapy; thus, palliative treatment is often performed. Additionally, gastric stenosis and gastroparesis caused by local recurrence are major problems that decrease a patient's quality of life.

Endoscopic submucosal dissection (ESD) is a common practice used to resect early gastric cancer. It is a minimally intensive procedure that can preserve quality of life. Moreover, the procedure can resect the whole specimen, which allows for correct histopathological assessment. We report herein a case of a patient with mGC that responded to chemotherapy and who underwent a complete resection of the residual tumor using ESD. Twenty-nine months after the ESD, no local recurrence or distant metastases have been found.

CASE PRESENTATION

An 85-year-old Japanese male complained of difficulty swallowing and visited a hospital. He had a medical history of untreated abdominal aortic aneurysm and pulmonary phthisis. He underwent esophagogastroduodenoscopy to diagnose his symptoms, and a protruding lesion at the gastric cardia was found. Endoscopic biopsy confirmed a moderately differentiated adenocarcinoma. Abdominal computed tomography (CT) showed no evidence of the tumor invading the muscularis propria and serosa, enlarged lymph nodes, or distant metastases. Therefore, this lesion was diagnosed as stage IA gastric cancer (cT1N0M0, 7th edition of UICC TNM Classification of Malignant Tumors).

Four months after diagnosis, the patient visited our institution for treatment of this lesion. It took a long time for the patient to visit because he could not decide which treatment to take, with his options being surgery and endoscopic treatment. The tumor (Figure 1A) grew to 20 mm in size, and abdominal CT result showed clear evidence of multiple mass lesions (range: 10-30 mm) in the liver, suggesting metastases of his gastric cancer (Figure 1B); however, there was no evidence of the tumor invading the muscularis propria and serosa or of lymph nodes' swelling. Therefore, the diagnosis was changed to stage IV gastric cancer.

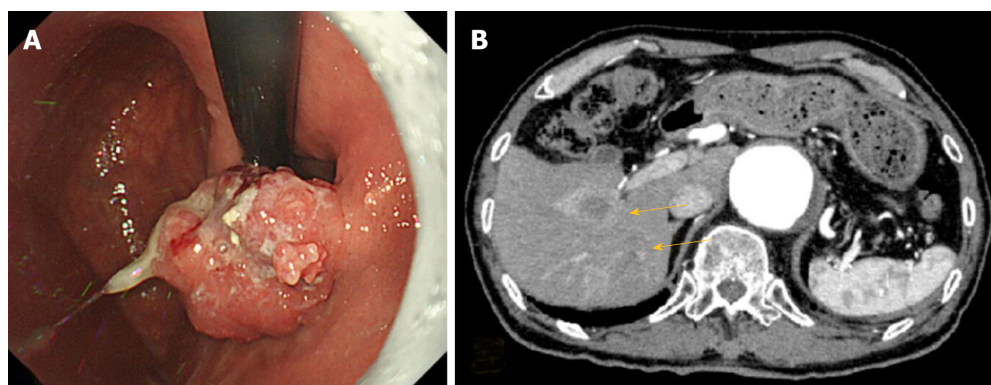


Figure 1 Objective image findings at the first visit to our institute. A: EGD findings before treatment. EGD found a protruding lesion, 20 mm in diameter, at the gastric cardia; B: Abdominal CT with contrast before treatment; CT showed multiple mass lesions throughout the liver (arrows). EGD: Esophagogastroduodenoscopy; CT: Computed tomography.

FINAL DIAGNOSIS

The clinical diagnosis was gastric cancer with liver metastases; stage IV (cT1N0M1).

TREATMENT

Although the patient was elderly, he was in the Eastern Cooperative Oncology Group performance status of 1 and had adequate organ functions; therefore, chemotherapy was deemed appropriate.

S-1 and oxaliplatin combination therapy (SOX) were administered. S-1 was administered orally (100 mg/d), and oxaliplatin was delivered *via* intravenous infusion (70 mg/m² diluted in 500 mL of saline over 120 min). The patient underwent four cycles of SOX, beginning 1 mo after the diagnosis of mGC. Each SOX cycle lasted 3 wk, with S-1 administered daily on days 1 to 14 of each cycle, and oxaliplatin administered only on day 1 of each cycle. After SOX, the primary lesion decreased, although it was confirmed macroscopically, and endoscopic biopsy revealed no atypia. Additionally, CT confirmed no evidence of liver metastases. However, the patient had grade 3 sensory peripheral neuropathy (Common Terminology Criteria for Adverse Events version 4.0; CTCAE4.0); thus, oxaliplatin was discontinued and S-1 was continued for two additional cycles. Thereafter, the primary lesion macroscopically appeared smooth and protruded, and it appeared similar to a submucosal tumor (Figure 2A). The endoscopic biopsy still revealed no atypia. CT results showed no lymph node swelling or distant metastasis (Figure 2B). Therefore, we determined that the patient had had a complete response to the chemotherapy. At that point, the patient's difficulty in swallowing had improved, but he had grade 3 anorexia and sensory peripheral neuropathy (CTCAE4.0); therefore, S-1 was discontinued.

Due to the patient's response to chemotherapy, conversion surgery was considered. The patient's liver metastases had completely disappeared and the primary lesion became unclear macroscopically; however, conversion surgery was difficult because of his advanced age and comorbidities. Although the biopsy specimen at the mucosa of the primary lesion revealed no atypia after chemotherapy, a residual tumor was suspected under the mucosal layer because it looked like there was submucosal tumor. Therefore, ESD was performed for the primary lesion. The lesion was resected with no complications.

OUTCOME AND FOLLOW-UP

The pathological diagnosis of the specimen was 28 mm × 12 mm, U, type 0-IIc, 1.0 mm × 1.0 mm, well-differentiated tubular adenocarcinoma (tub1), ypT1b (SM), ly0, v0, pHM(-), and pVM(-) in the Japanese Classification of Gastric Cancer (Figure 3A and 3B). After ESD, no recurrence was observed during the 29 mo follow-up period.

DISCUSSION

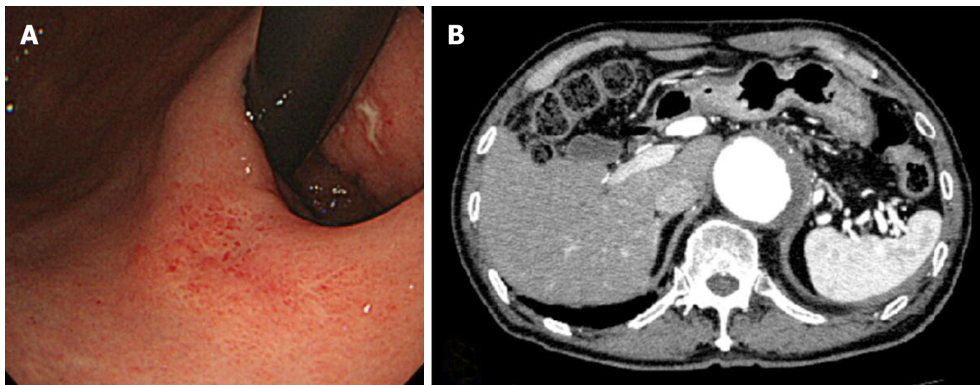


Figure 2 Objective image findings after chemotherapy. A: EGD finding after chemotherapy. The lesion became unclear. It appeared smooth and protruded, and looked like a submucosal tumor; B: Abdominal CT with contrast after chemotherapy showed multiple lesions had disappeared and no evidence of disease in the liver. EGD: Esophagogastroduodenoscopy; CT: Computed tomography.

To our knowledge, this is the first report describing the efficacy of ESD to prevent local recurrence and help maintain quality of life for a patient with mGC. Effective chemotherapy, followed by complete resection with negative margin using ESD, contributed to a good clinical course.

SOX was an effective and safe chemotherapeutic treatment in our patient's case. A previous phase III study (G-SOX study) showed that SOX was not inferior to S-1 plus cisplatin therapy (CS) inefficacy^[5]. Regarding safety, SOX has shown better tolerability than CS in elderly patients, with a lower frequency of grade 3 or worse adverse events, as well as lower occurrence of increased creatinine levels^[6]. In clinical practice, SOX is administered more frequently than CS because of its feasibility.

In this case, the patient achieved a complete response for multiple liver masses, and the primary lesion size decreased from SOX, but it was difficult to continue chemotherapy due to adverse events (*i.e.*, peripheral sensory neuropathy and anorexia). Recently, conversion surgery has been proposed and clinically performed following successful chemotherapy. Some studies showed that a microscopically margin-negative (R0) resection for a primary lesion after a good response to chemotherapy improved survival outcomes for mGC patients^[7,8]. Additionally, cytoreductive or volume-reduction surgery has not shown survival benefits in similar patients^[9,10]. Sato *et al*^[11] reported a 5-year overall survival (OS) (median survival time of 47.9 mo) of 48.6% in patients with stage IV gastric cancer who had undergone R0 resection after chemotherapy. Additionally, R0 resection led to a significantly longer OS than did R1 (microscopic residual tumor) and R2 (macroscopic residual tumor) resections. Similarly, in patients with stage IV gastric cancer who had a gastrectomy after chemotherapy, OS was significantly longer from R0 resection only (median OS = 19.2 mo)^[12].

Based on newly proposed classification categories for stage IV gastric cancer^[13], our case was Category 2. Category 2 is indicative of the absence of macroscopic peritoneal dissemination, with marginally resectable metastatic lesions that are oncologically or technically unresectable. Furthermore, the proposed treatment strategy for Category 2 is conversion surgery, if the patient achieves a satisfactory response to chemotherapy. Therefore, our case was theoretically a good candidate for conversion surgery; however, the patient was elderly and had an untreated large abdominal aortic aneurysm. Moreover, the patient was concerned about decreased performance status due to total gastrectomy.

In cases in which the patient cannot undergo surgery and continue intensive chemotherapy, similar to the case of our patient, most patients shift to less-intensive chemotherapy or supportive care. In the current standard chemotherapy, subsequent chemotherapies are not always less-intensive. In clinical practice, some reports state that less intensive monotherapy was conducted for frail patients^[14,15]. Nishimura *et al*^[16] reported that irinotecan monotherapy after refractory response to fluoropyrimidine, platinum and taxanes showed modest activity. However, in these reports, even though most patients' PS were 0-1, their prognoses were poor. For frail patients, if chemotherapy may decrease PS level and worsen prognosis, then supportive care is often chosen as the best alternative. Radiotherapy is one of the therapeutic strategies for these patients to manage localized tumors^[17,18]. However, in this case, radiotherapy was not conducted due to comorbidity.

Local tumor progression is a problem in many of these patients. Gastric stenosis, obstruction, gastroparesis, bleeding, and pain are common conditions caused by local

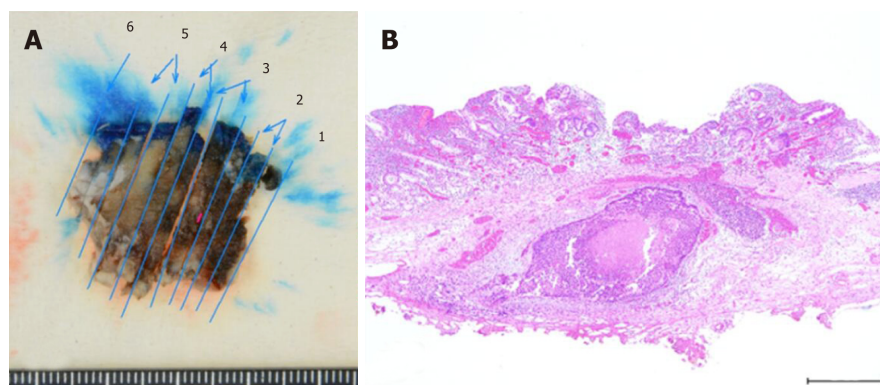


Figure 3 Result of gastric submucosal dissection. A: Macroscopic findings from a resected specimen; B: Histopathological result of a resected specimen: 28 mm × 12 mm, U, type 0-IIc, 1.0 mm × 1.0 mm, well-differentiated tubular adenocarcinoma (tub1), ypT1b, ly0, v0, pHM(-), and pVM(-).

recurrence or advanced primary lesions that ultimately decrease a patient's quality of life. For these cases, there are some available strategies, such as palliative gastrectomy, palliative gastrojejunostomy, or endoscopic stent. In this case, the patient did not suffer from obstruction at the end of chemotherapy. Although biopsy results both during and after chemotherapy were categorized as Group 1, the primary lesion appeared similar to a submucosal tumor. Considering that a lesion sometimes exists at the submucosa like an inverted polyp^[19], a residual tumor was suspected. If the residual tumor had remained and grown, there would have been a risk of obstruction. Therefore, ESD was used to first confirm the residual tumor and then resect the lesion completely. The results of this case suggest that when clinically possible, conversion surgery is a better treatment option, because a tumor may remain even without macroscopic evidence of the disease.

ESD is a less-intensive treatment and common practice to resect early gastric cancer, rather than surgical resection^[20,21]. ESD enables resection of the whole lesion, thereby allowing a correct histopathological assessment. Furthermore, the procedure is safe and effective in elderly patients. Abe *et al*^[22] reported that the complication rate (bleeding and perforation rates of 3.2% and 2.8%, respectively) of ESD was similar in elderly (≥ 80 years) and non-elderly patients with early gastric cancer, indicating that ESD was a safe procedure, even for the elderly. Additionally, Watanabe *et al*^[23] reported no significant differences in adverse events (*i.e.*, rate of perforation, postoperative bleeding, aspiration pneumonia, or stricture) among patients with early gastric cancer, regardless of age. Several studies reported that endoscopic therapies, such as ESD, for locoregional recurrence of esophageal cancer after definitive chemoradiotherapy ensured safety. Furthermore, endoscopic therapy can be locally controlled and may improve both overall and disease-specific survival rates^[24,25]. In the presented case, we achieved local control from the resection using ESD, which may provide therapeutic improvements in both local control and survival outcomes for the patient.

CONCLUSION

In conclusion, we presented a rare case of a complete resection with negative margins using ESD for a remnant submucosal lesion after chemotherapy for mGC. The patient has been alive for the past 29 mo after ESD, with no sign of local recurrence.

REFERENCES

- 1 **Japanese Gastric Cancer Association.** Japanese gastric cancer treatment guidelines 2014 (ver. 4). *Gastric Cancer* 2017; **20**: 1-19 [PMID: 27342689 DOI: 10.1007/s10120-016-0622-4]
- 2 **Bang YJ, Van Cutsem E, Feyereislova A, Chung HC, Shen L, Sawaki A, Lordick F, Ohtsu A, Omuro Y, Satoh T, Aprile G, Kulikov E, Hill J, Lehle M, Rüschoff J, Kang YK; ToGA Trial Investigators.** Trastuzumab in combination with chemotherapy versus chemotherapy alone for treatment of HER2-positive advanced gastric or gastro-oesophageal junction cancer (ToGA): a phase 3, open-label, randomised controlled trial. *Lancet* 2010; **376**: 687-697 [PMID: 20728210 DOI: 10.1016/S0140-6736(10)61121-X]
- 3 **Koizumi W, Narahara H, Hara T, Takagane A, Akiya T, Takagi M, Miyashita K, Nishizaki T, Kobayashi O, Takiyama W, Toh Y, Nagaie T, Takagi S, Yamamura Y, Yanaoka K, Orita H, Takeuchi M.** S-1 plus

- cisplatin versus S-1 alone for first-line treatment of advanced gastric cancer (SPIRITS trial): a phase III trial. *Lancet Oncol* 2008; **9**: 215-221 [PMID: 18282805 DOI: 10.1016/S1470-2045(08)70035-4]
- 4 **Schildberg CW**, Weidinger T, Hohenberger W, Wein A, Langheinrich M, Neurath M, Boxberger F. Metastatic adenocarcinomas of the stomach or esophagogastric junction (UICC stage IV) are not always a palliative situation: a retrospective analysis. *World J Surg* 2014; **38**: 419-425 [PMID: 24146196 DOI: 10.1007/s00268-013-2293-1]
 - 5 **Yamada Y**, Higuchi K, Nishikawa K, Gotoh M, Fuse N, Sugimoto N, Nishina T, Amagai K, Chin K, Niwa Y, Tsuji A, Imamura H, Tsuda M, Yasui H, Fujii H, Yamaguchi K, Yasui H, Hironaka S, Shimada K, Miwa H, Hamada C, Hyodo I. Phase III study comparing oxaliplatin plus S-1 with cisplatin plus S-1 in chemotherapy-naïve patients with advanced gastric cancer. *Ann Oncol* 2015; **26**: 141-148 [PMID: 25316259 DOI: 10.1093/annonc/mdl472]
 - 6 **Bando H**, Yamada Y, Tanabe S, Nishikawa K, Gotoh M, Sugimoto N, Nishina T, Amagai K, Chin K, Niwa Y, Tsuji A, Imamura H, Tsuda M, Yasui H, Fujii H, Yamaguchi K, Yasui H, Hironaka S, Shimada K, Miwa H, Hamada C, Hyodo I. Efficacy and safety of S-1 and oxaliplatin combination therapy in elderly patients with advanced gastric cancer. *Gastric Cancer* 2016; **19**: 919-926 [PMID: 26474989 DOI: 10.1007/s10120-015-0549-1]
 - 7 **Fukuchi M**, Ishiguro T, Ogata K, Suzuki O, Kumagai Y, Ishibashi K, Ishida H, Kuwano H, Mochiki E. Prognostic Role of Conversion Surgery for Unresectable Gastric Cancer. *Ann Surg Oncol* 2015; **22**: 3618-3624 [PMID: 25663597 DOI: 10.1245/s10434-015-4422-6]
 - 8 **Yamaguchi K**, Yoshida K, Tanahashi T, Takahashi T, Matsuhashi N, Tanaka Y, Tanabe K, Ohdan H. The long-term survival of stage IV gastric cancer patients with conversion therapy. *Gastric Cancer* 2018; **21**: 315-323 [PMID: 28616743 DOI: 10.1007/s10120-017-0738-1]
 - 9 **Fujitani K**, Yang HK, Mizusawa J, Kim YW, Terashima M, Han SU, Iwasaki Y, Hyung WJ, Takagane A, Park DJ, Yoshikawa T, Hahn S, Nakamura K, Park CH, Kurokawa Y, Bang YJ, Park BJ, Sasako M, Tsujinaka T; REGATTA study investigators. Gastrectomy plus chemotherapy versus chemotherapy alone for advanced gastric cancer with a single non-curative factor (REGATTA): a phase 3, randomised controlled trial. *Lancet Oncol* 2016; **17**: 309-318 [PMID: 26822397 DOI: 10.1016/S1470-2045(15)00553-7]
 - 10 **Mahar AL**, Coburn NG, Singh S, Law C, Helyer LK. A systematic review of surgery for non-curative gastric cancer. *Gastric Cancer* 2012; **15** Suppl 1: S125-S137 [PMID: 22033891 DOI: 10.1007/s10120-011-0088-3]
 - 11 **Sato Y**, Ohnuma H, Nobuoka T, Hirakawa M, Sagawa T, Fujikawa K, Takahashi Y, Shinya M, Katsuki S, Takahashi M, Maeda M, Okagawa Y, Naoki U, Kikuch S, Okamoto K, Miyamoto H, Shimada M, Takemasa I, Kato J, Takayama T. Conversion therapy for inoperable advanced gastric cancer patients by docetaxel, cisplatin, and S-1 (DCS) chemotherapy: a multi-institutional retrospective study. *Gastric Cancer* 2017; **20**: 517-526 [PMID: 27553665 DOI: 10.1007/s10120-016-0633-1]
 - 12 **Satoh S**, Okabe H, Teramukai S, Hasegawa S, Ozaki N, Ueda S, Tsuji A, Sakabayashi S, Fukushima M, Sakai Y. Phase II trial of combined treatment consisting of preoperative S-1 plus cisplatin followed by gastrectomy and postoperative S-1 for stage IV gastric cancer. *Gastric Cancer* 2012; **15**: 61-69 [PMID: 21667134 DOI: 10.1007/s10120-011-0066-9]
 - 13 **Yoshida K**, Yamaguchi K, Okumura N, Tanahashi T, Kadera Y. Is conversion therapy possible in stage IV gastric cancer: the proposal of new biological categories of classification. *Gastric Cancer* 2016; **19**: 329-338 [PMID: 26643880 DOI: 10.1007/s10120-015-0575-z]
 - 14 **Shirao K**, Boku N, Yamada Y, Yamaguchi K, Doi T, Goto M, Nasu J, Denda T, Hamamoto Y, Takashima A, Fukuda H, Ohtsu A; Gastrointestinal Oncology Study Group of the Japan Clinical Oncology Group. Randomized Phase III study of 5-fluorouracil continuous infusion vs. sequential methotrexate and 5-fluorouracil therapy in far advanced gastric cancer with peritoneal metastasis (JCOG0106). *Jpn J Clin Oncol* 2013; **43**: 972-980 [PMID: 24014884 DOI: 10.1093/jjco/hyt114]
 - 15 **Muranaka T**, Yuki S, Komatsu Y, Sawada K, Harada K, Kawamoto Y, Nakatsumi H, Sakamoto N. Efficacy and Safety of Bolus 5-Fluorouracil and L-Leucovorin as Salvage Chemotherapy for Oral Fluoropyrimidine-Resistant Unresectable or Recurrent Gastric Cancer: A Single Center Experience. *J Gastric Cancer* 2016; **16**: 177-181 [PMID: 27752395 DOI: 10.5230/jgc.2016.16.3.177]
 - 16 **Nishimura T**, Iwasa S, Nagashima K, Okita N, Takashima A, Honma Y, Kato K, Hamaguchi T, Yamada Y, Shimada Y, Boku N. Irinotecan monotherapy as third-line treatment for advanced gastric cancer refractory to fluoropyrimidines, platinum, and taxanes. *Gastric Cancer* 2017; **20**: 655-662 [PMID: 27858180 DOI: 10.1007/s10120-016-0670-9]
 - 17 **Hashimoto K**, Mayahara H, Takashima A, Nakajima TE, Kato K, Hamaguchi T, Ito Y, Yamada Y, Kagami Y, Itami J, Shimada Y. Palliative radiation therapy for hemorrhage of unresectable gastric cancer: a single institute experience. *J Cancer Res Clin Oncol* 2009; **135**: 1117-1123 [PMID: 19205735 DOI: 10.1007/s00432-009-0553-0]
 - 18 **Asakura H**, Hashimoto T, Harada H, Mizumoto M, Furutani K, Hasuike N, Matsuoka M, Ono H, Boku N, Nishimura T. Palliative radiotherapy for bleeding from advanced gastric cancer: is a schedule of 30 Gy in 10 fractions adequate? *J Cancer Res Clin Oncol* 2011; **137**: 125-130 [PMID: 20336314 DOI: 10.1007/s00432-010-0866-z]
 - 19 **Odashima M**, Otake M, Nanjo H, Jin M, Horikawa Y, Matsuhashi T, Ohba R, Koizumi S, Kinoshita N, Takahashi T, Shima H, Watanabe S. Hamartomatous inverted polyp successfully treated by endoscopic submucosal dissection. *Intern Med* 2008; **47**: 259-262 [PMID: 18277026]
 - 20 **Isomoto H**, Shikuwa S, Yamaguchi N, Fukuda E, Ikeda K, Nishiyama H, Ohnita K, Mizuta Y, Shiozawa J, Kohno S. Endoscopic submucosal dissection for early gastric cancer: a large-scale feasibility study. *Gut* 2009; **58**: 331-336 [PMID: 19001058 DOI: 10.1136/gut.2008.165381]
 - 21 **Ono H**, Kondo H, Gotoda T, Shirao K, Yamaguchi H, Saito D, Hosokawa K, Shimoda T, Yoshida S. Endoscopic mucosal resection for treatment of early gastric cancer. *Gut* 2001; **48**: 225-229 [PMID: 11156645]
 - 22 **Abe N**, Gotoda T, Hirasawa T, Hoteya S, Ishido K, Ida Y, Imaeda H, Ishii E, Kokawa A, Kusano C, Maehata T, Ono S, Takeuchi H, Sugiyama M, Takahashi S. Multicenter study of the long-term outcomes of endoscopic submucosal dissection for early gastric cancer in patients 80 years of age or older. *Gastric Cancer* 2012; **15**: 70-75 [PMID: 21667133 DOI: 10.1007/s10120-011-0067-8]
 - 23 **Watanabe K**, Hikichi T, Nakamura J, Takagi T, Suzuki R, Sugimoto M, Wagarai Y, Kikuchi H, Konno N, Asama H, Takasumi M, Obara K, Ohira H. Endoscopic submucosal dissection for early gastric cancer in very elderly patients age 85 or older. *Endosc Int Open* 2017; **5**: E17-E24 [PMID: 28191493 DOI: 10.1055/s-0042-122960]

- 24 **Koizumi S**, Jin M, Matsuhashi T, Tawaraya S, Watanabe N, Sawaguchi M, Kanazawa N, Yamada Y, Onochi K, Kimura Y, Ohba R, Kataoka J, Hatakeyama N, Mashima H, Ohnishi H. Salvage endoscopic submucosal dissection for the esophagus-localized recurrence of esophageal squamous cell cancer after definitive chemoradiotherapy. *Gastrointest Endosc* 2014; **79**: 348-353 [PMID: [24125510](#) DOI: [10.1016/j.gie.2013.09.012](#)]
- 25 **Takeuchi M**, Kobayashi M, Hashimoto S, Mizuno K, Kawaguchi G, Sasamoto R, Aoyama H, Aoyagi Y. Salvage endoscopic submucosal dissection in patients with local failure after chemoradiotherapy for esophageal squamous cell carcinoma. *Scand J Gastroenterol* 2013; **48**: 1095-1101 [PMID: [23906093](#) DOI: [10.3109/00365521.2013.822092](#)]

P- Reviewer: Fogli L, Zhu YL, Kim JH

S- Editor: Dou Y **L- Editor:** Filipodia **E- Editor:** Tan WW





Published By Baishideng Publishing Group Inc
7901 Stoneridge Drive, Suite 501, Pleasanton, CA 94588, USA
Telephone: +1-925-2238242
Fax: +1-925-2238243
E-mail: bpgoffice@wjgnet.com
Help Desk: <https://www.f6publishing.com/helpdesk>
<https://www.wjgnet.com>

